Study smart with Student Consult

GRAY'S ATLAS OF ANATOMY

SECOND EDITION

Richard L. Drake A. Wayne Vogl Adam W. M. Mitchell
Richard M. Tibbitts Paul E. Richardson

CHURCHILL LIVINGSTONE
ELSEVIER

tahir99-VRG & vip.persianss.ir

Study smart with Student CONSULT
Built with inkling

Elsevier | StudentConsult.com

Transform the way you learn.

Compatible with PC, Mac®, most mobile devices, and eReaders, Student Consult allows you to browse, search, and interact with this title – online *and* offline. Redeem your PIN at studentconsult.com today!

Start using these innovative features today:

- Seamless, real-time integration between devices
- Straightforward navigation and search
- Notes and highlights sharing with other users through social media
- Enhanced images with annotations, labels, and hot spots for zooming on specific details *
- Live streaming video and animations *
- Self-assessment tools such as questions embedded within the text and multiple-format quizzes *

** some features vary by title*

PIN REDEMPTION INSTRUCTIONS

1. Login or Sign Up at StudentConsult.com
2. Scratch off your PIN code below
3. Enter PIN into the "Redeem a Book Code" box
4. Click "Redeem"
5. Go to "My Library"

Use of the current edition of the electronic version of this book (eBook) is subject to the terms of the nontransferable, limited license granted on StudentConsult.com. Access to the eBook is limited to the first individual who redeems the PIN, located on the inside cover of this book, at StudentConsult.com and may not be transferred to another party by resale, lending, or other means.

For technical assistance: Email: online.help@elsevier.com;
Call: within the US and Canada: 800-401-9962;
outside the US and Canada: +1-314-447-8200

tahir99-VRG & vip.persianss.ir

GRAY'S ATLAS OF ANATOMY

SECOND EDITION

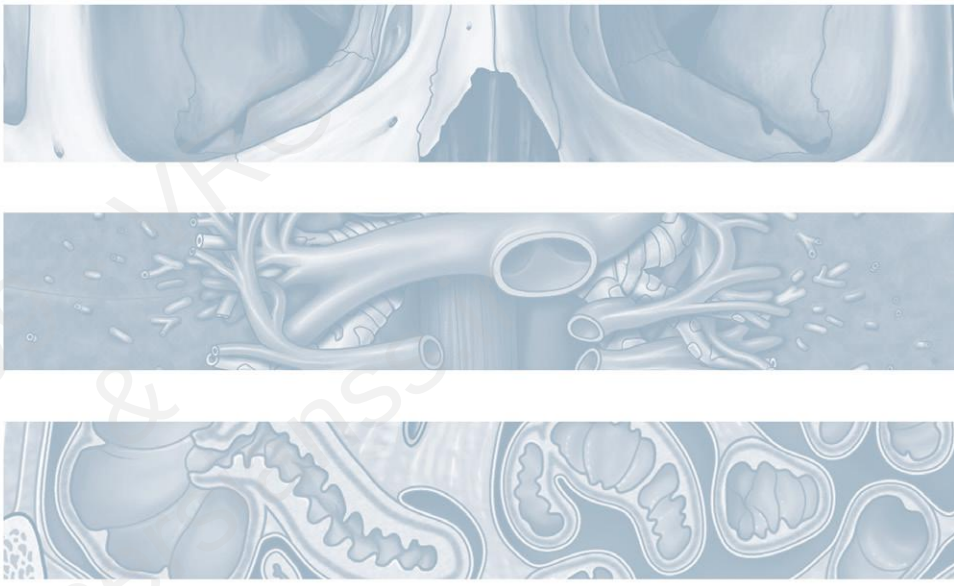

tahir99-VRG & vip.persianss.ir

Richard L. Drake, PhD, FAAA
Director of Anatomy
Professor of Surgery
Cleveland Clinic Lerner College of Medicine
Case Western Reserve University
Cleveland, Ohio, USA

A. Wayne Vogl, PhD, FAAA
Professor of Anatomy and Cell Biology
Department of Cellular and Physiological Sciences
Faculty of Medicine
University of British Columbia
Vancouver, British Columbia, Canada

Adam W. M. Mitchell, MBBS, FRCS, FRCR
Consultant Radiologist and Senior Lecturer Imperial College
Chelsea and Westminster Hospital
London, UK

Illustrated by

Richard M. Tibbitts
Saffron Walden, UK

Paul E. Richardson
Cambridge, UK

Photographs by

Ansell Horn

tahir99 - VRG & vip.persianss.ir

tahir99-VRG & vip.persianss.ir

GRAY'S ATLAS OF ANATOMY

SECOND EDITION

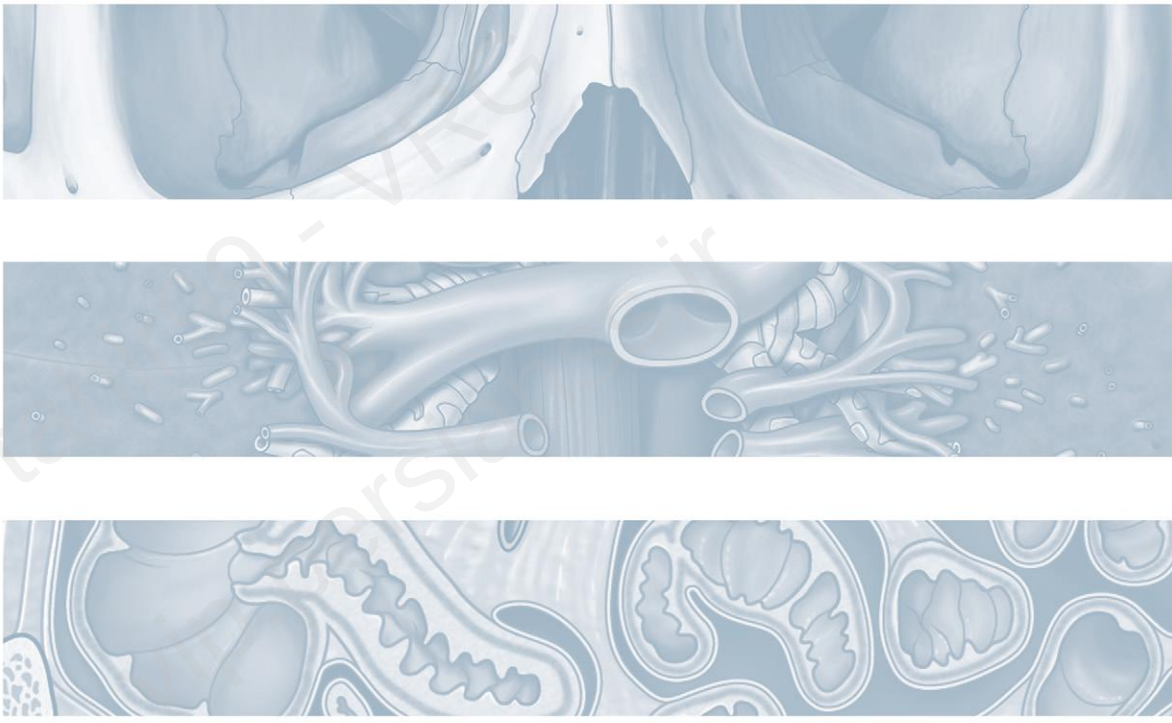

Richard L. Drake A. Wayne Vogl Adam W. M. Mitchell
Richard M. Tibbitts Paul E. Richardson

CHURCHILL LIVINGSTONE
ELSEVIER

tahir99-VRG & vip.persianss.ir

CHURCHILL
LIVINGSTONE
ELSEVIER

1600 John F. Kennedy Blvd.
Ste 1800
Philadelphia, PA 19103-2899

GRAY'S ATLAS OF ANATOMY, SECOND EDITION
INTERNATIONAL EDITION

ISBN: 978-1-4557-4802-0
ISBN: 978-0-7020-5237-8

Copyright © 2015, 2008 by Churchill Livingstone, an imprint of Elsevier Inc.

All rights reserved. No part of this publication may be reproduced or transmitted in any form or by any means, electronic or mechanical, including photocopying, recording, or any information storage and retrieval system, without permission in writing from the publisher. Details on how to seek permission, further information about the Publisher's permissions policies and our arrangements with organizations such as the Copyright Clearance Center and the Copyright Licensing Agency, can be found at our website: www.elsevier.com/permissions.

Notices

Knowledge and best practice in this field are constantly changing. As new research and experience broaden our understanding, changes in research methods, professional practices, or medical treatment may become necessary.

Practitioners and researchers must always rely on their own experience and knowledge in evaluating and using any information, methods, compounds, or experiments described herein. In using such information or methods they should be mindful of their own safety and the safety of others, including parties for whom they have a professional responsibility.

With respect to any drug or pharmaceutical products identified, readers are advised to check the most current information provided (i) on procedures featured or (ii) by the manufacturer of each product to be administered, to verify the recommended dose or formula, the method and duration of administration, and contraindications. It is the responsibility of practitioners, relying on their own experience and knowledge of their patients, to make diagnoses, to determine dosages and the best treatment for each individual patient, and to take all appropriate safety precautions.

To the fullest extent of the law, neither the Publisher nor the authors, contributors, or editors, assume any liability for any injury and/or damage to persons or property as a matter of products liability, negligence or otherwise, or from any use or operation of any methods, products, instructions, or ideas contained in the material herein.

The Publisher

ISBN: 978-1-4557-4802-0

VP Global Medical Education Content: Madelene Hyde
Senior Manager, Content Development: Rebecca Gruliow
Publishing Services Manager: Patricia Tannian
Senior Project Manager: John Casey
Design and Art Direction: Antbits Ltd.

Working together to grow
libraries in developing countries
www.elsevier.com | www.bookaid.org | www.sabre.org
ELSEVIER BOOK AID International Sabre Foundation

Printed in Canada
Last digit is the print number: 9 8 7 6 5 4 3 2 1

tahir99-VRG & vip.persianss.ir

To my wife who supports me and to my parents who are always with me.
Richard L. Drake

To my family, to my professional colleagues and role models, and to my students.
Wayne Vogl

Thanks, to Cathy, Max and Elsa
Adam W. M. Mitchell

To my family – my inspiration, Evi, Zoë, and Nicholas x
Richard M. Tibbitts

To Lesley and in memory of AMR and JER
Paul Richardson

tahir99-VRG & vip.persianss.ir

ACKNOWLEDGMENTS

The following reviewers helped enormously with their detailed critiques and suggestions for every chapter. Their assistance was invaluable.

Mark Hankin, PhD, University of Toledo College of Medicine, Toledo, Ohio

Marios Loukas, MD, PhD, St. George's University School of Medicine, Grenada

James J. Rechtien, DO, PhD, Michigan State University School of Medicine, East Lansing, Michigan

William A. Roy, PT, PhD, Touro University, Henderson, Nevada

Susan Standring, PhD, DSc, Professor of Experimental Neurobiology and Head, Division of Anatomy, Cell and Human Biology, Guy's, King's and St Thomas' School of Biomedical Sciences, King's College London, London

William Swartz, PhD, Louisiana State University Health Sciences Center, Baton Rouge, Louisiana

Mark F. Teaford, PhD, Johns Hopkins University School of Medicine, Baltimore, Maryland

We want to thank Dr. Bruce Crawford for a radiograph of the head and neck and Dr. Murray Morrison for laryngoscopic images of the larynx; Dr. Jerry Healy for three images in the Abdomen section: the celiac artery, the bile duct system, and a three-dimensional view of abdominal vessels; and Siemens Medical Solutions USA and the following individuals with that company: Mollie Beaver, Director, CT Clinical Solutions, and Dr. Louise McKenna, Global Clinical Marketing Manager, CT Oncology, who supplied a *syngo* Multi-modality Workplace, which was used to acquire the majority of the clinical images.

Stuart Morrison, MD, helped with all aspects of coordinating the collection of the radiographic material. Radiological assistance and images were contributed in each of the following areas:

Back	Mark Kayanja, MD, PhD Jeffrey S. Ross, MD
Thorax	Mario Garcia, MD A. Michael Lincoff, MD
Abdomen	Namita Gandhi, MD Michelle Inkster, MD, PhD Brian R. Lane, MD Anand Rao, MD James S. Wu, MD
Pelvis	Matthew Barber, MD, MHS Tommaso Falcone, MD J. Stephen Jones, MD Eunice Moon, MD James S. Newman, MD, PhD
Extremities	Hakan Ilaslan, MD Bradford J. Richmond, MD Joshua Polster, MD
Head and Neck	Todd W. Stultz, DDS, MD J. Martin Paloma, DDS, MSD Cindy McConnaughy Ronald Lemmo, DDS

tahir99-VRG & vip.persianss.ir

A working knowledge of anatomy is not an "optional extra" for health care professionals – it is fundamental. Acquiring that knowledge has always challenged even the most motivated students. Over many generations, learning materials that aid the process effectively have been warmly welcomed by students and their teachers (and by patients, who are the ultimate beneficiaries of that knowledge). I remember my own students' response when I first included illustrations from *Gray's Anatomy for Students* in a lecture—afterward, I was asked repeatedly for the source of the marvelous pictures. Looking beyond the "wow" factor that leapt from the pages of the book, it was clear that an enormous amount of thought and skill had gone into producing the artwork.

This atlas contains a series of additional outstanding pieces of anatomical art from the illustrative team of Richard Tibbitts and Paul Richardson that will complement those in *Gray's Anatomy for Students*, combined with relevant clinical pictures, surface anatomy, and images from a range of modern imaging procedures. Of course, anatomy cannot be learned from books and interactive DVDs alone, no matter how excellent they may be. Anatomy is a practical subject, best learned by gaining hands-on experience of the body. Students should spend as much time as they can examining cadaveric dissections (if they do not have the opportunity to dissect themselves) and should always read from screen or page with the appropriate bones in front of them. They need to combine and correlate information from a wide variety of sources in order to gain the working knowledge mentioned earlier.

This atlas will provide a valuable companion to their studies, and I am confident that it will remain in their libraries long after they have completed the early stages of their training.

Susan Standring, PhD, DSc, FKC, Hon FRCS
Emeritus Professor of Anatomy
King's College, London

tahir99-VRG & vip.persianss.ir

FOREWORD

We began working on *Gray's Atlas of Anatomy* in 2005 following the publication of our textbook, *Gray's Anatomy for Students*. We wanted to produce an atlas that would build on themes and concepts established in the textbook and that would couple artistic renderings of "internal" gross anatomy with actual "living" anatomy, as visualized with modern imaging techniques and with surface anatomy. We believe that the final atlas presents a fresh and integrated approach to anatomy that is accessible to entry-level students in anatomy, as well as to students at more advanced levels.

Because an atlas is used in a much different way than a textbook, we could not simply repackage figures used in *Gray's Anatomy for Students* and put them in the atlas. Consequently, most of the figures in the atlas are new and were designed to present structures in a more complete context than in the textbook, even though the color palette and overall look of the figures in both the atlas and textbook are similar. Also, figures in the atlas provide additional detail not included in the textbook and directly correlate artistic representations of anatomy with computed tomography (CT) and magnetic resonance imaging (MRI). Where appropriate, we have included endoscopic, laryngoscopic, and laparoscopic views of the anatomy and have included examples of ultrasound images. In a number of regions, we also have reconstructed the internal anatomy of patients by abstracting specific information from multiple MR or CT images, and we present these reconstructions together with artwork of the same anatomy. Although the artwork was done independently of the reconstructed images, the two types of representations are strikingly similar.

Each page of this atlas was planned prior to beginning work on the figures, and all of the artwork was generated digitally. Most of the figures were created from an extensive digital database created for the textbook. Each figure was reviewed for accuracy and revised accordingly.

We hope that the textbook and atlas used together will provide new and powerful learning tools for students of human gross anatomy.

The Authors

tahir99-VRG & vip.persianss.ir

The 2nd edition of *Gray's Atlas of Anatomy* continues in the tradition of the 1st edition, coupling artistic rendering with actual living anatomy as visualized with modern imaging techniques and surface anatomy. The combination of modern illustrations, imaging, and surface anatomy is unique among atlases available today.

We have also added additional study aids that should enhance the learning experience. At the end of every chapter tables and schematic drawings have been added for quick review of subject matter. These include major nerves plexuses throughout the body, branching patterns of major arteries, summaries of muscles organized into compartments or regions, and other helpful information. This material is designed to provide the reader quick access to information.

It's our hope that the 2nd edition of *Gray's Atlas of Anatomy* will become a valuable learning aid for students encountering anatomy for the first time or for the individual seeking to review information critical to their daily experiences.

The Authors

tahir99-VRG & vip.persianss.ir

This page intentionally left blank

tahir99-VRG & vip.persianss.ir

1 THE BODY

Anatomical position, terms, and planes 2
Anatomical planes and imaging 3
Surface anatomy: anterior view 4
Surface anatomy: posterior view 5
Skeleton: anterior 6
Skeleton: posterior 7
Muscles: anterior 8
Muscles: posterior 9
Vascular system: arteries 10
Vascular system: veins 11
Lymphatic system 12
Nervous system 13
Sympathetics 14
Parasympathetics 15
Dermatomes 16
Cutaneous nerves 17

2 BACK

Surface anatomy 20
Vertebral column 21
Regional vertebrae 22
Cervical vertebrae 23
Thoracic vertebrae 26
Lumbar vertebrae 28
Sacrum 31
Intervertebral foramina and discs 32
Intervertebral disc problems 33
Joints and ligaments 35
Back musculature: surface anatomy 36
Superficial musculature 37
Intermediate musculature 39
Deep musculature 40
Back musculature: transverse section 42
Suboccipital region 43
Spinal nerves 44
Spinal cord 45
Spinal cord vasculature 46
Venous drainage of spinal cord 47
Meninges 48
Spinal cord: imaging 50
Transverse section: thoracic region 52
Dermatomes and cutaneous nerves 53
Tables 54

3 THORAX

Surface anatomy with bones 62
Bony framework 63
Ribs 65
Articulations 66
Breast 68
Pectoral region 70
Thoracic wall muscles 72
Diaphragm 73
Arteries of the thoracic wall 74
Veins of the thoracic wall 75
Nerves of the thoracic wall 76
Lymphatics of the thoracic wall 77
Intercostal nerves and arteries 78
Pleural cavities and mediastinum 79
Parietal pleura 80
Surface projections of pleural recesses 81
Right lung 82
Left lung 83
Lung lobes: surface relationship 84
Lung lobes: imaging 85
Bronchial tree 86
Bronchopulmonary segments 87
Pulmonary vessels and plexus 88
Pulmonary vessels: imaging 89
Mediastinum 91
Pericardium 92
Pericardial layers 93
Anterior surface of heart 94
Base and diaphragmatic surface of heart 95
Right atrium 96
Right ventricle 97
Left atrium 98
Left ventricle 99

tahir99-VRG & vip.persianss.ir

Aortic valve and cardiac skeleton **100**
Cardiac chambers and heart valves **101**
Coronary vessels **102**
Coronary arteries and variations **103**
Cardiac conduction system **105**
Auscultation points and heart sounds **106**
Cardiac innervation **107**
Superior mediastinum: thymus **108**
Superior mediastinum: veins and arteries **109**
Superior mediastinum: arteries and nerves **110**
Superior mediastinum: imaging **111**
Superior mediastinum: veins and trachea **112**
Mediastinum: imaging **113**
Mediastinum: view from right **114**
Mediastinum: imaging – view from right **115**
Mediastinum: view from left **116**
Mediastinum: imaging – view from left **117**
Posterior mediastinum **118**
Mediastinum: imaging **120**
Transverse section: TVIII level **124**
Dermatomes and cutaneous nerves **125**
Visceral efferent (motor) innervation of the heart **126**
Visceral afferents **127**
Tables **128**

4 ABDOMEN

Surface anatomy **134**
Quadrants and regions **135**
Abdominal wall **136**
Muscles **138**
Muscles: rectus sheath **141**
Vessels of the abdominal wall **142**
Arteries and lymphatics of the abdominal wall **143**
Nerves of the abdominal wall **144**
Dermatomes and cutaneous nerves **145**
Inguinal region **146**
Inguinal canal **148**
Inguinal hernias **150**
Anterior abdominal wall **151**
Greater omentum **152**
Abdominal viscera **153**
Peritoneal cavity **154**
Abdominal sagittal section **155**
Abdominal coronal section **156**
Arterial supply of viscera **157**
Stomach **158**
Spleen **159**
Arteries of stomach and spleen **160**
Duodenum **162**
Small intestine **164**
Large intestine **166**
Ileocecal junction **168**
Gastrointestinal tract: imaging **169**
Mesenteric arteries **170**
Liver **172**
Vessels of the liver **174**
Segments of the liver **175**
Pancreas and gallbladder **176**
Vasculature of pancreas and duodenum **179**
Venous drainage of viscera **180**
Portosystemic anastomoses **182**
Posterior wall **183**
Vessels of the posterior wall **184**
Diaphragm **185**
Kidneys **186**
Gross structure of kidneys **188**
Kidneys: imaging **189**
Renal vasculature **190**
Branches of the abdominal aorta **192**
Inferior vena cava **193**
Abdominal aorta and inferior vena cava: imaging **194**
Lumbar plexus **196**
Lumbar plexus: cutaneous distribution **197**
Lymphatics **198**
Abdominal innervation **199**
Splanchnic nerves **200**
Visceral efferent (motor) innervation diagram **201**
Visceral afferent (sensory) innervation and referred pain diagram **202**
Kidney and ureter visceral afferent (sensory) diagram **204**
Tables **206**

tahir99-VRG & vip.persianss.ir

5 PELVIS AND PERINEUM

Surface anatomy and articulated pelvis in men **212**
Surface anatomy and articulated pelvis in women **214**
Pelvic girdle **216**
Pelvic girdle: imaging **217**
Lumbosacral joint **218**
Sacro-iliac joint **219**
Pelvic inlet and outlet **220**
Orientation of pelvic girdle and pelvic brim **221**
Pelvic viscera and perineum in men **222**
Pelvic viscera and perineum in men: imaging **223**
Pelvic viscera and perineum in women **224**
Pelvic viscera and perineum in women: imaging **225**
Lateral wall of pelvic cavity **226**
Floor of pelvic cavity: pelvic diaphragm **227**
Rectum and bladder in situ **230**
Rectum **231**
Bladder in men **232**
Bladder in women **233**
Reproductive system in men **234**
Prostate **235**
Prostate and seminal vesicles **237**
Scrotum **238**
Testes **239**
Penis **240**
Reproductive system in women **241**
Uterus and ovaries **242**
Uterus **243**
Uterus: imaging **244**
Pelvic fascia **245**
Arterial supply of pelvis **246**
Venous drainage of pelvis **247**
Vasculature of the pelvic viscera **248**
Vasculature of uterus **249**
Venous drainage of prostate and penis **250**
Venous drainage of rectum **251**
Sacral and coccygeal nerve plexuses **252**
Pelvic nerve plexus **253**
Hypogastric plexus **254**
Surface anatomy of the perineum **255**
Borders and ceiling of the perineum **258**
Deep pouch and perineal membrane **259**
Muscles and erectile tissues in men **260**
Erectile tissue in men: imaging **261**
Muscles and erectile tissues in women **262**
Erectile tissue in women: imaging **263**
Internal pudendal artery and vein **264**
Pudendal nerve **265**
Vasculature of perineum **266**
Nerves of perineum **267**
Lymphatics of pelvis and perineum in men **268**
Lymphatics of pelvis and perineum in women **269**
Lymphatics **270**
Dermatomes **271**
Innervation of reproductive system in men **272**
Innervation of reproductive system in women **273**
Innervation of bladder **274**
Pelvic cavity imaging in men **275**
Pelvic cavity imaging in women **278**
Tables **284**

6 LOWER LIMB

Surface anatomy **292**
Bones of the lower limb **293**
Pelvic bones and sacrum **294**
Articulated pelvis **295**
Proximal femur **296**
Hip joint **297**
Hip joint: structure and arterial supply **299**
Gluteal region: attachments and superficial musculature **300**
Gluteal region: superficial and deep muscles **301**
Gluteal region: arteries and nerves **302**
Distal femur and proximal tibia and fibula **304**
Thigh: muscle attachments **305**
Thigh: anterior superficial musculature **306**
Thigh: posterior superficial musculature **307**
Thigh: anterior compartment muscles **308**
Thigh: medial compartment muscles **309**
Femoral triangle **310**

Anterior thigh: arteries and nerves **311**
Anterior thigh: arteries **312**
Thigh: posterior compartment muscles **313**
Posterior thigh: arteries and nerves **314**
Transverse sections: thigh **316**
Knee joint **318**
Ligaments of the knee **320**
Menisci and cruciate ligaments **322**
Knee: bursa and capsule **326**
Knee surface: muscles, capsule, and arteries **327**
Popliteal fossa **328**
Tibia and fibula **329**
Bones of the foot **330**
Bones and joints of the foot **333**
Talus and calcaneus **334**
Ankle joint **335**
Ligaments of the ankle joint **336**
Leg: muscle attachments **339**
Posterior leg: superficial muscles **340**
Posterior compartment: deep muscles **341**
Posterior leg: arteries and nerves **342**
Lateral compartment: muscles **343**
Anterior leg: superficial muscles **344**
Anterior compartment: muscles **345**
Anterior leg: arteries and nerves **346**
Leg: cutaneous nerves **347**
Transverse sections: leg **348**
Foot: muscle attachments **350**
Foot: ligaments **351**
Dorsum of foot **353**
Dorsum of foot: arteries and nerves **354**
Plantar aponeurosis **356**
Plantar region (sole) musculature: first layer **357**
Plantar region (sole) musculature: second layer **358**
Plantar region (sole) musculature: third layer **359**
Plantar region (sole) musculature: fourth layer **360**
Plantar region (sole): arteries and nerves **361**
Dorsal hood and tarsal tunnel **363**
Superficial veins of the lower limb **364**
Lymphatics of the lower limb **365**
Anterior cutaneous nerves and dermatomes of the lower limb **366**
Posterior cutaneous nerves and dermatomes of the lower limb **367**
Tables **368**

7 UPPER LIMB

Surface anatomy **384**
Bones of the upper limb **385**
Bony framework of shoulder **386**
Scapula **387**
Clavicle: joints and ligaments **388**
Proximal humerus **389**
Glenohumeral joint **390**
Muscle attachments **392**
Pectoral region **394**
Deep pectoral region **395**
Walls of the axilla **396**
The four rotator cuff muscles **398**
Deep vessels and nerves of the shoulder **400**
Axillary artery **401**
Brachial artery **402**
Brachial plexus **403**
Medial and lateral cords **404**
Posterior cord **405**
Distal end of humerus and proximal end of radius and ulna **406**
Muscle attachments **407**
Anterior compartment: muscles **408**
Anterior compartment: arteries and nerves **410**
Veins of the arm **411**
Posterior compartment: muscles **412**
Posterior compartment: arteries and nerves **414**
Lymphatics of the arm **415**
Transverse sections: arm **416**
Anterior cutaneous nerves of the arm **418**
Posterior cutaneous nerves of the arm **419**
Elbow joint **420**
Elbow joint: capsule and ligaments **422**
Cubital fossa **424**
Radius and ulna **425**
Bones of the hand and wrist joint **426**

Imaging of the hand and wrist joint **427**
Bones of the hand **428**
Joints and ligaments of the hand **429**
Muscle attachments of forearm **430**
Anterior compartment of forearm: muscles **431**
Anterior compartment of forearm: arteries and nerves **434**
Posterior compartment of forearm: muscles **435**
Posterior compartment of forearm: arteries and nerves **437**
Transverse sections: forearm **438**
Carpal tunnel **440**
Muscle attachments of the hand **442**
Superficial palmar region (palm) of hand **443**
Tendon sheaths of hand **444**
Lumbrical muscles **445**
Intrinsic muscles of hand **446**
Palmar region (palm) of hand: arteries and nerves **448**
Arteries of the hand **450**
Innervation of the hand: median and ulnar nerves **451**
Dorsum of hand **452**
Dorsal hoods **453**
Dorsum of hand: arteries **454**
Dorsum of hand: nerves **455**
Anatomical snuffbox **456**
Superficial veins and lymphatics of forearm **457**
Anterior cutaneous nerves of forearm **458**
Posterior cutaneous nerves of upper limb **459**
Tables **460**

8 HEAD AND NECK

Surface anatomy with bones **476**
Bones of the skull **477**
Skull: anterior view **478**
Skull: lateral view **480**
Skull: posterior view **482**
Skull: superior view and roof **483**
Skull: inferior view **484**
Skull: cranial cavity **485**
Ethmoid, lacrimal bone, inferior concha, and vomer **486**
Maxilla and palatine bone **487**
Skull: muscle attachments **488**
Scalp and meninges **490**
Dural partitions **491**
Dural arteries and nerves **492**
Dural venous sinuses **493**
Brain **494**
Brain: imaging **496**
Cranial nerves **498**
Arterial supply to brain **500**
Cutaneous distribution of trigeminal nerve [V] **503**
Facial muscles **504**
Vasculature, facial nerve [VII] and lymphatics **506**
Deep arteries and veins of parotid region **507**
Bony orbit **508**
Section through orbit and structures of eyelid **509**
Eyelids and lacrimal apparatus **510**
Innervation of the lacrimal gland **511**
Muscles of the eyeball **512**
Innervation of the orbit and eyeball **513**
Eye movements **514**
Vasculature of orbit **515**
Eyeball **516**
Eye imaging **517**
Ear surface and sensory innervation **520**
Ear **521**
Middle ear **522**
Internal ear **524**
Ear imaging **525**
Temporal and infratemporal fossae **526**
Bones of the temporal and infratemporal fossae **527**
Temporal and infratemporal fossae **528**
Temporomandibular joint **530**
Mandibular division of the trigeminal nerve [V] **531**
Parasympathetic innervation **532**
Arteries and veins of temporal and infratemporal fossae **533**
Pterygopalatine fossa **534**
Neck surface anatomy **536**
Bones of the neck **537**
Compartments and fascia of the neck **538**
Superficial veins of the neck **539**

CONTENTS

Muscles of the neck **540**
Nerves in the neck **542**
Cranial nerves in the neck **543**
Cervical plexus and sympathetic trunk **544**
Arteries of the neck **546**
Root of the neck: arteries **548**
Lymphatics of the neck **550**
Pharynx **552**
Muscles of the pharynx **554**
Innervation of the pharynx **556**
Vasculature of the pharynx **557**
Larynx **558**
Laryngeal cavity **560**
Muscles of the larynx **561**
Innervation of the larynx **562**
Thyroid gland **563**
Vasculature of the thyroid gland **564**
Nose and paranasal sinuses **566**
Nasal cavity: bones **567**
Nasal cavity: mucosal linings **568**
Vasculature and innervation of the nasal cavity **569**
Sinus imaging **570**
Oral cavity: bones **572**
Teeth **573**
Teeth: imaging **574**
Anatomy of teeth **575**
Vessels and nerves supplying teeth **576**
Innervation of teeth and gums **577**
Muscles and salivary glands of the oral cavity **578**
Vessels and nerves of the tongue **579**
Tongue **580**
Hard and soft palate **581**
Palate **582**
Innervation of oral cavity **583**
Cranial nerves **584**
Visceral motor pathways in the head **586**
Tables **588**

INDEX **609**

1

THE BODY

CONTENTS

Anatomical position, terms, and planes	**2**
Anatomical planes and imaging	**3**
Surface anatomy: anterior view	**4**
Surface anatomy: posterior view	**5**
Skeleton: anterior	**6**
Skeleton: posterior	**7**
Muscles: anterior	**8**
Muscles: posterior	**9**
Vascular system: arteries	**10**
Vascular system: veins	**11**
Lymphatic system	**12**
Nervous system	**13**
Sympathetics	**14**
Parasympathetics	**15**
Dermatomes	**16**
Cutaneous nerves	**17**

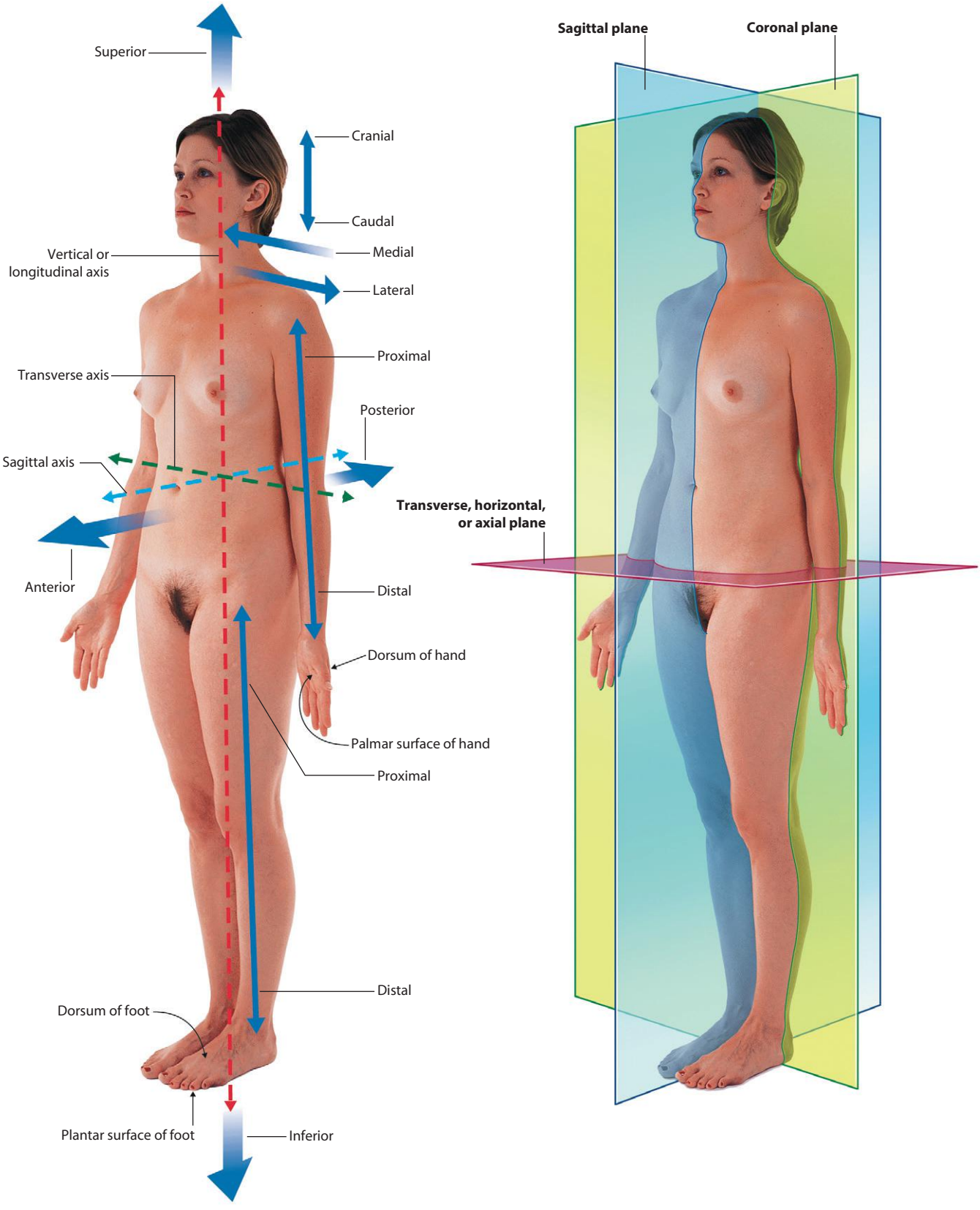
Superior
Cranial
Caudal
Vertical or longitudinal axis
Medial
Lateral
Proximal
Transverse axis
Posterior
Sagittal axis
Anterior
Distal
Dorsum of hand
Palmar surface of hand
Proximal
Distal
Dorsum of foot
Plantar surface of foot
Inferior
Sagittal plane
Coronal plane
Transverse, horizontal, or axial plane

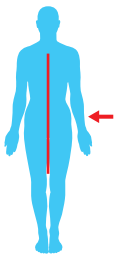

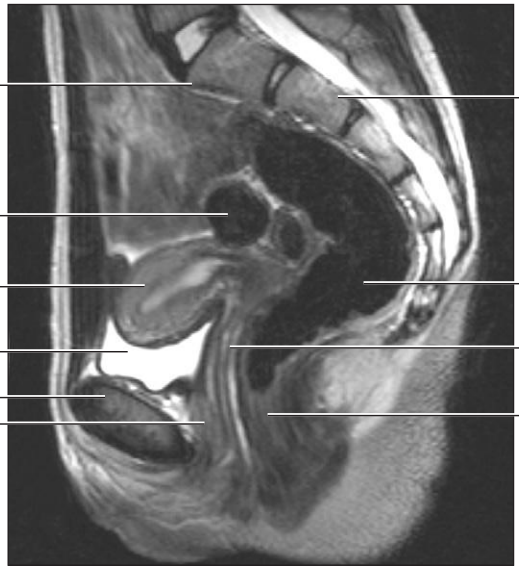

T2-weighted MR image, in sagittal plane

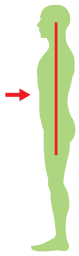

CT image, with contrast, in coronal plane

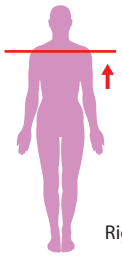

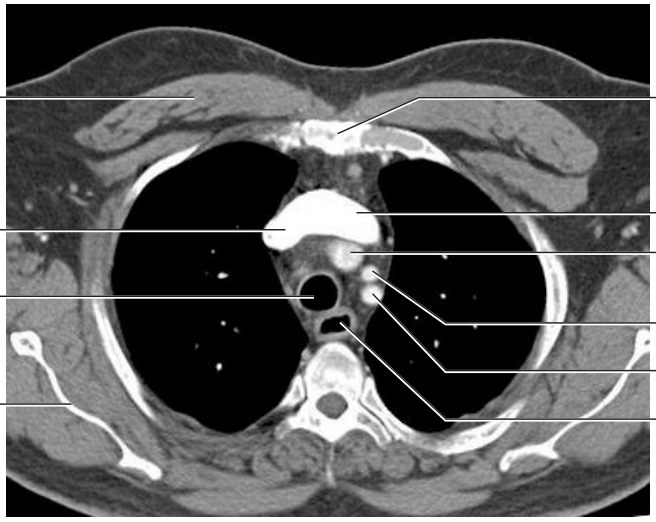

CT image, with contrast, in axial plane

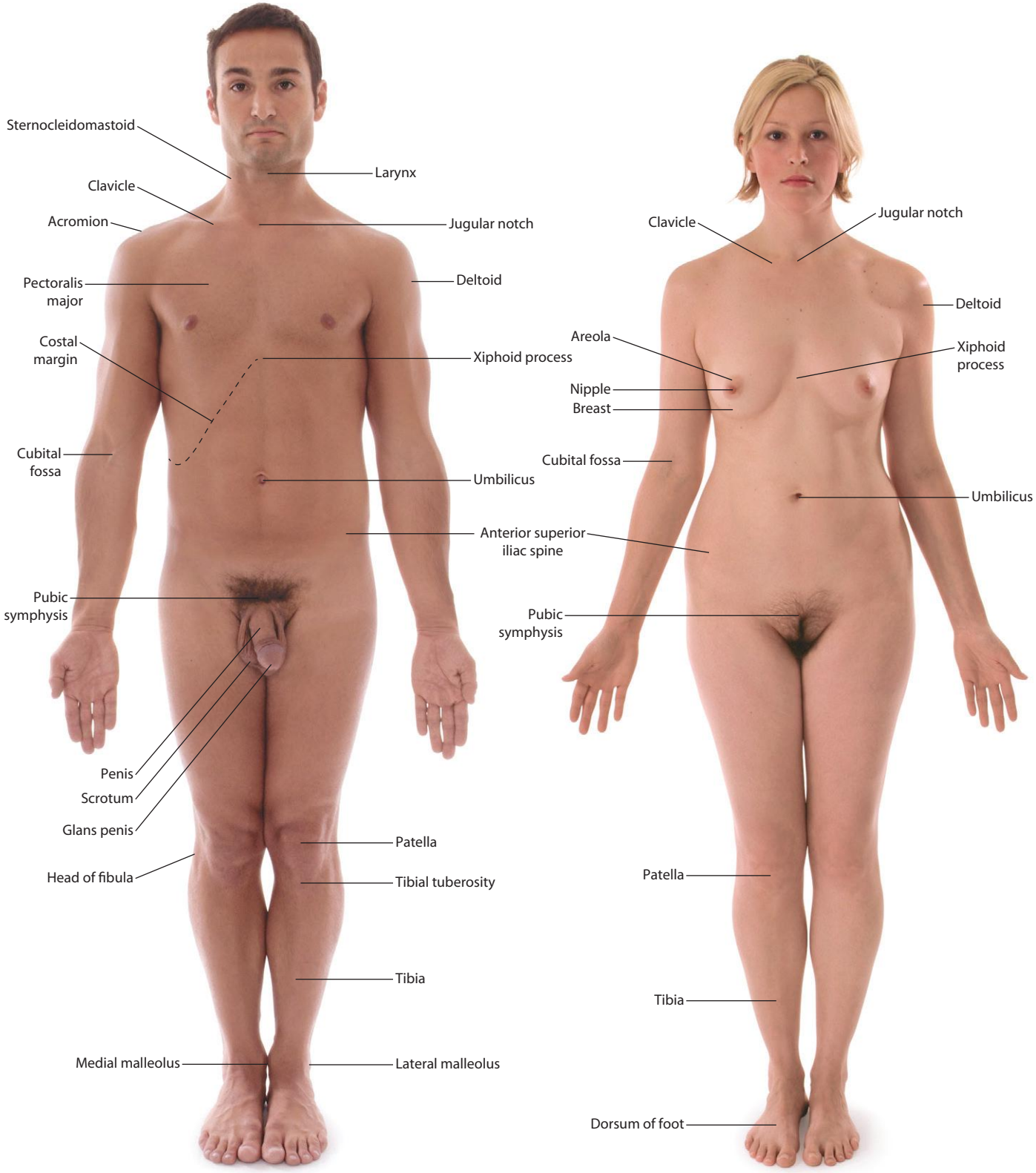
Sternocleidomastoid
Larynx
Clavicle
Acromion
Jugular notch
Pectoralis major
Deltoid
Costal margin
Xiphoid process
Cubital fossa
Umbilicus
Anterior superior iliac spine
Pubic symphysis
Penis
Scrotum
Glans penis
Patella
Head of fibula
Tibial tuberosity
Tibia
Medial malleolus
Lateral malleolus
Clavicle
Jugular notch
Deltoid
Areola
Xiphoid process
Nipple
Breast
Cubital fossa
Umbilicus
Pubic symphysis
Patella
Tibia
Dorsum of foot

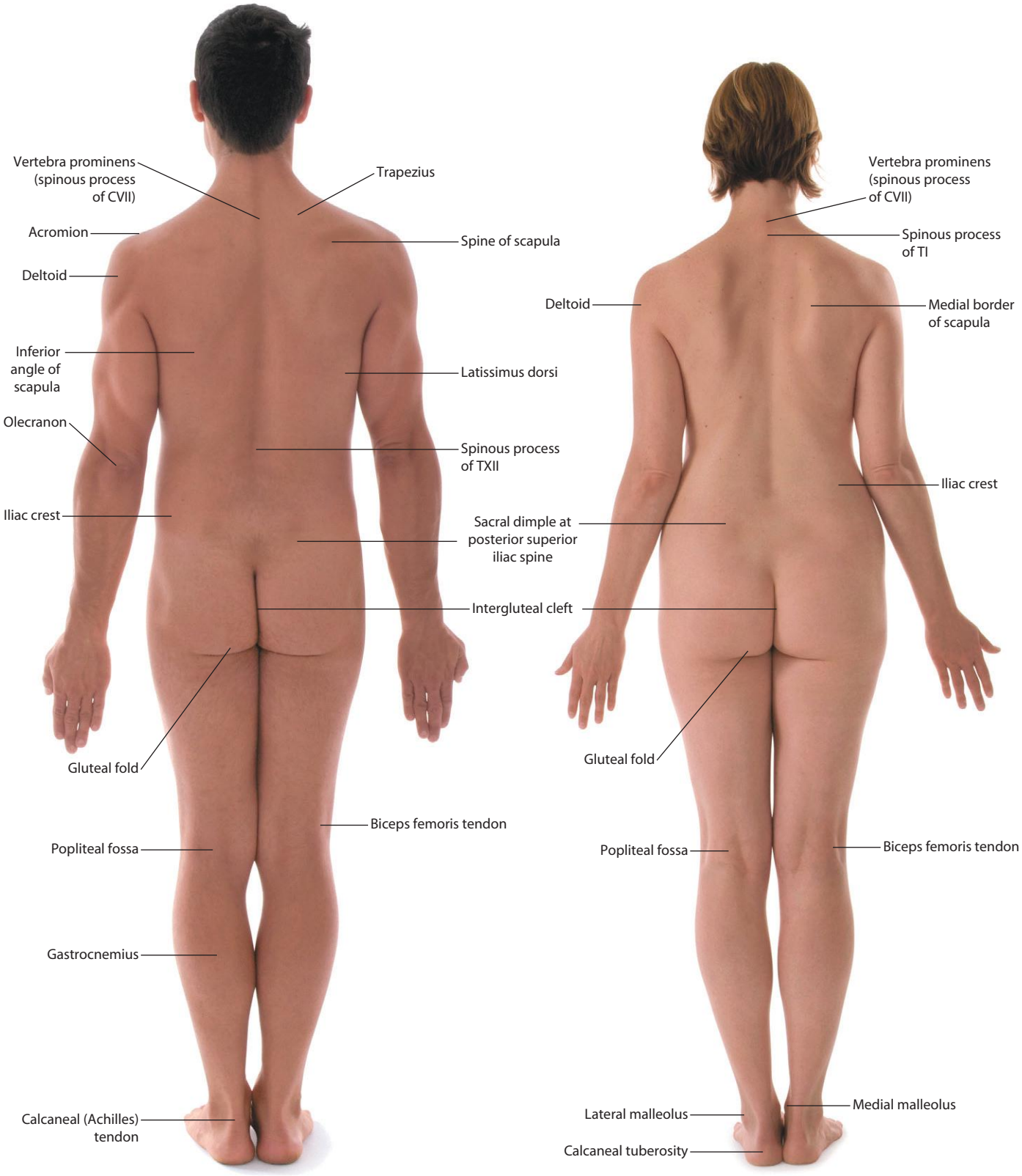
Vertebra prominens (spinous process of CVII)
Trapezius
Acromion
Spine of scapula
Deltoid
Inferior angle of scapula
Latissimus dorsi
Olecranon
Spinous process of TXII
Iliac crest
Sacral dimple at posterior superior iliac spine
Intergluteal cleft
Gluteal fold
Biceps femoris tendon
Popliteal fossa
Gastrocnemius
Calcaneal (Achilles) tendon
Vertebra prominens (spinous process of CVII)
Spinous process of TI
Deltoid
Medial border of scapula
Iliac crest
Gluteal fold
Popliteal fossa
Biceps femoris tendon
Lateral malleolus
Medial malleolus
Calcaneal tuberosity

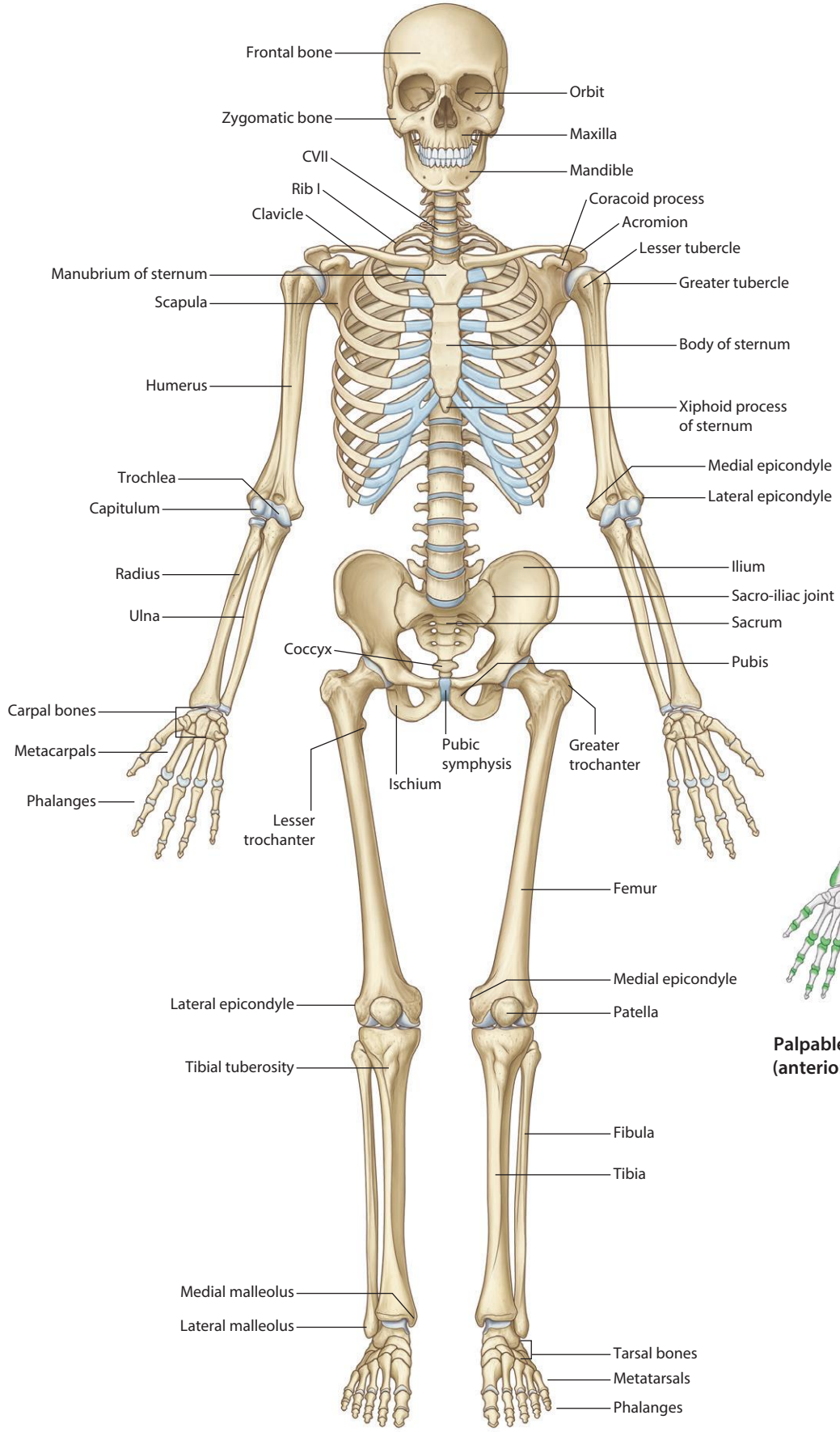

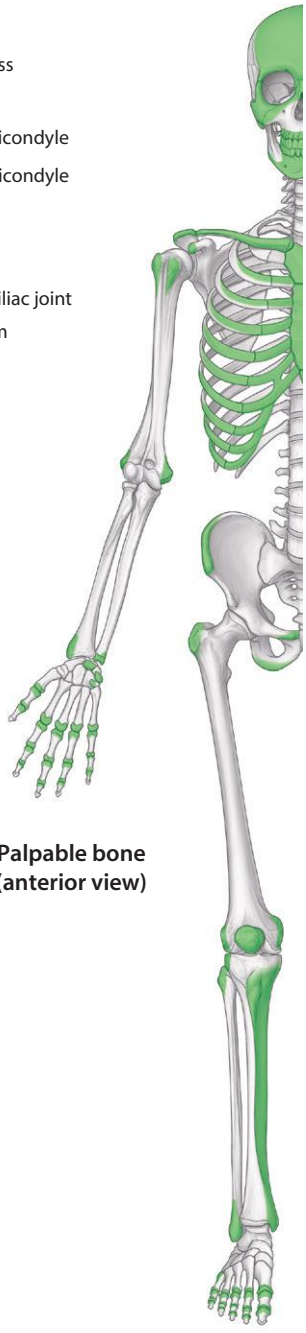

Palpable bone (anterior view)

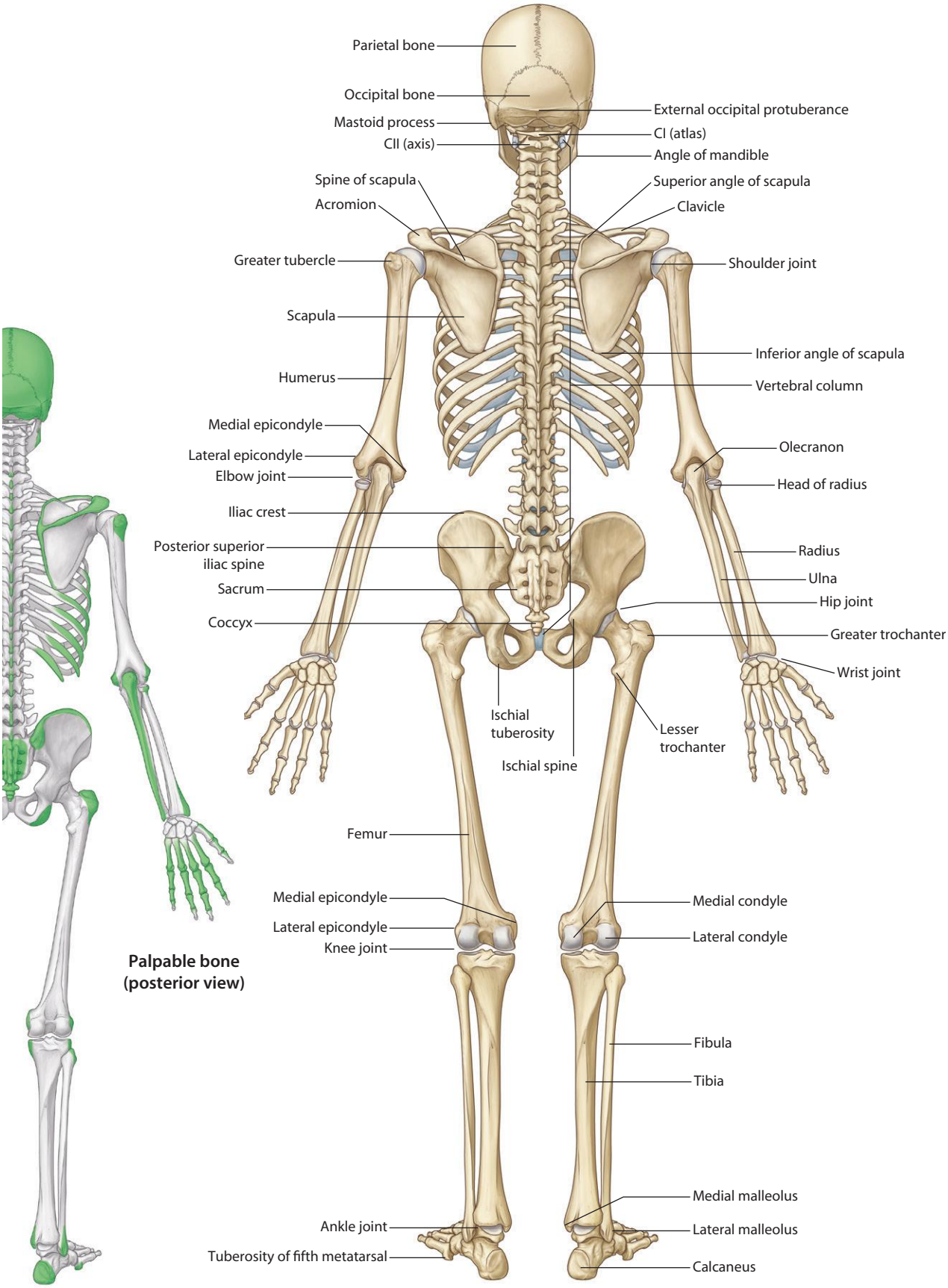

Palpable bone (posterior view)

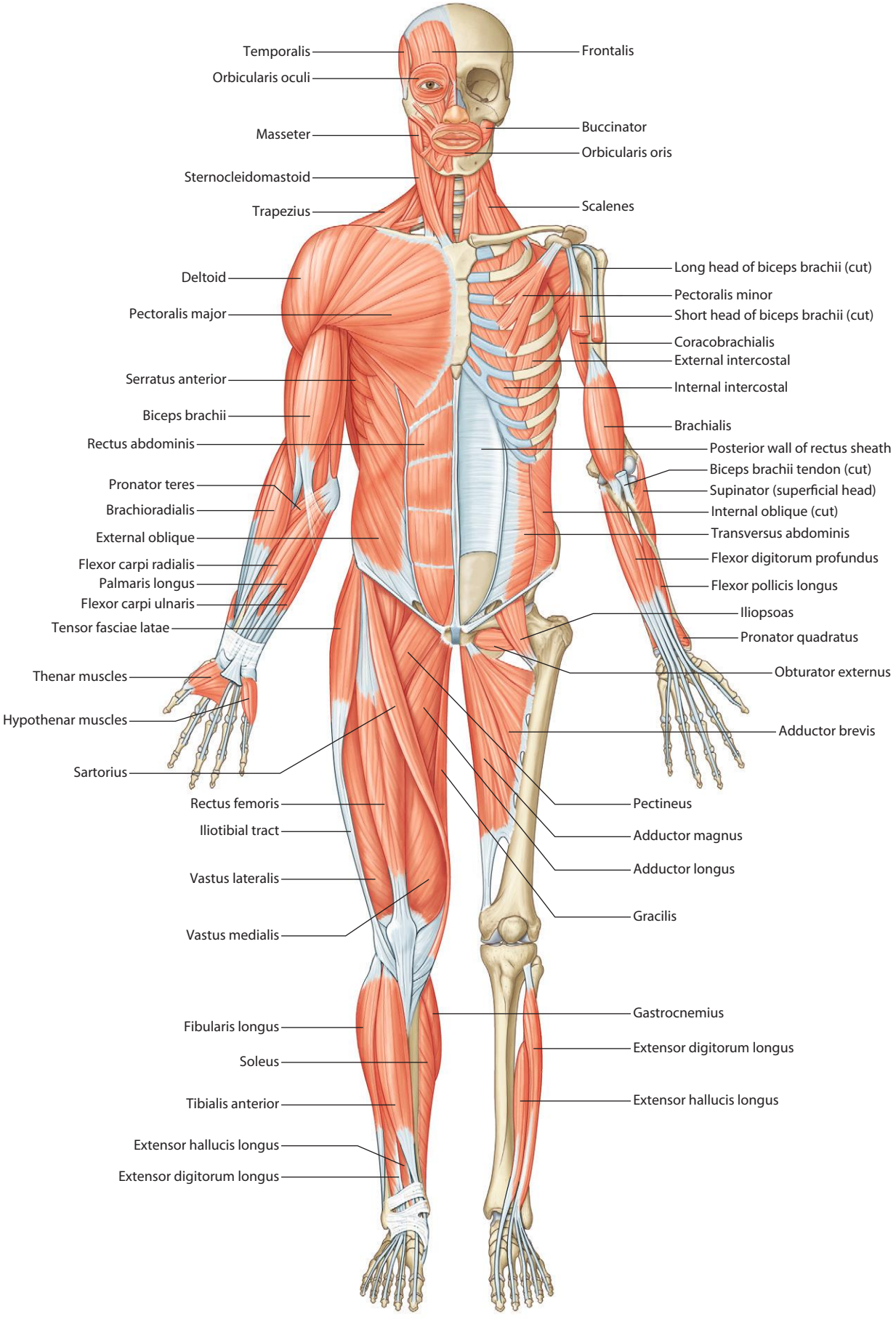
Temporalis
Orbicularis oculi
Masseter
Sternocleidomastoid
Trapezius
Deltoid
Pectoralis major
Serratus anterior
Biceps brachii
Rectus abdominis
Pronator teres
Brachioradialis
External oblique
Flexor carpi radialis
Palmaris longus
Flexor carpi ulnaris
Tensor fasciae latae
Thenar muscles
Hypothenar muscles
Sartorius
Rectus femoris
Iliotibial tract
Vastus lateralis
Vastus medialis
Fibularis longus
Soleus
Tibialis anterior
Extensor hallucis longus
Extensor digitorum longus
Frontalis
Buccinator
Orbicularis oris
Scalenes
Long head of biceps brachii (cut)
Pectoralis minor
Short head of biceps brachii (cut)
Coracobrachialis
External intercostal
Internal intercostal
Brachialis
Posterior wall of rectus sheath
Biceps brachii tendon (cut)
Supinator (superficial head)
Internal oblique (cut)
Transversus abdominis
Flexor digitorum profundus
Flexor pollicis longus
Iliopsoas
Pronator quadratus
Obturator externus
Adductor brevis
Pectineus
Adductor magnus
Adductor longus
Gracilis
Gastrocnemius
Extensor digitorum longus
Extensor hallucis longus

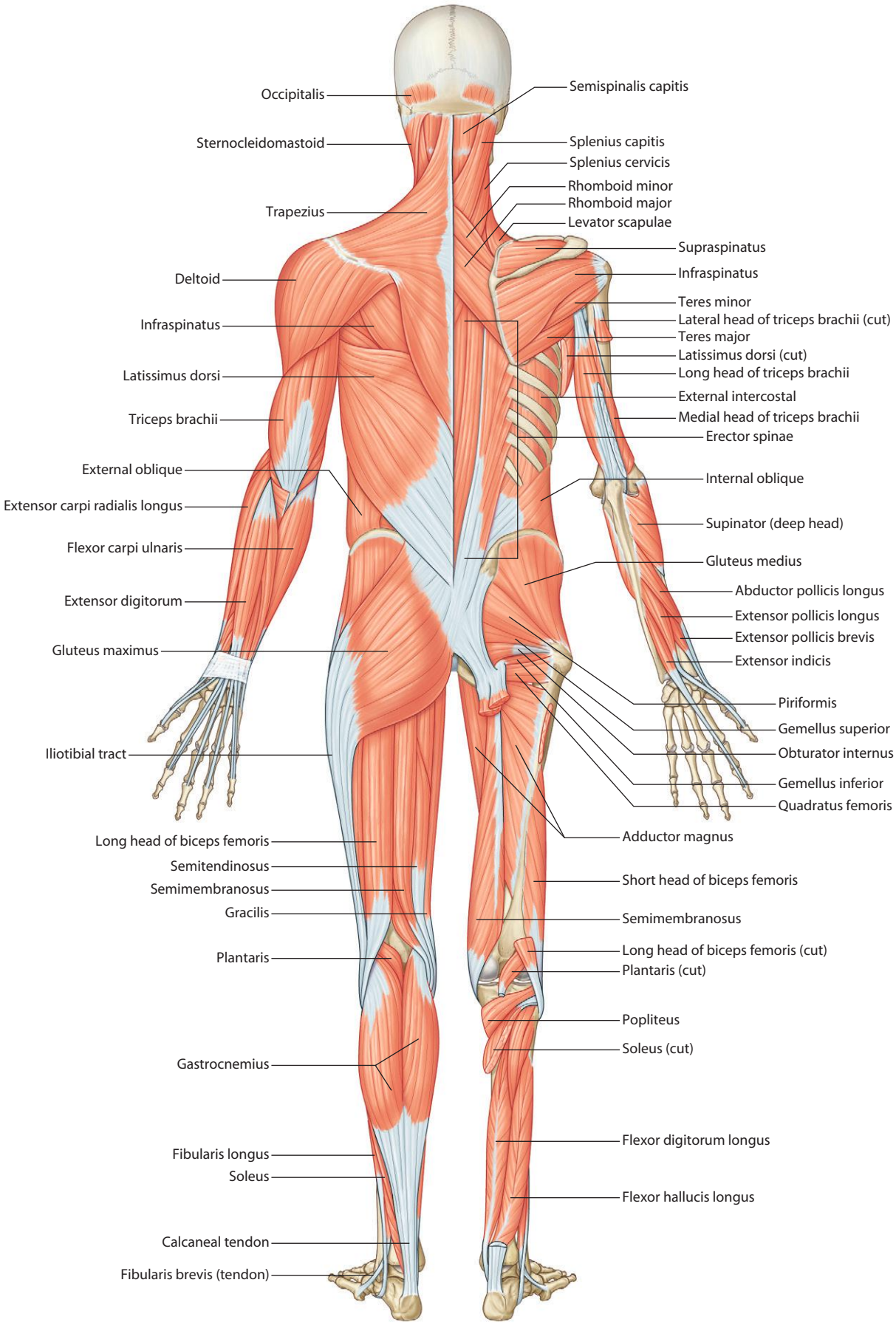
Occipitalis
Sternocleidomastoid
Trapezius
Deltoid
Infraspinatus
Latissimus dorsi
Triceps brachii
External oblique
Extensor carpi radialis longus
Flexor carpi ulnaris
Extensor digitorum
Gluteus maximus
Iliotibial tract
Long head of biceps femoris
Semitendinosus
Semimembranosus
Gracilis
Plantaris
Gastrocnemius
Fibularis longus
Soleus
Calcaneal tendon
Fibularis brevis (tendon)
Semispinalis capitis
Splenius capitis
Splenius cervicis
Rhomboid minor
Rhomboid major
Levator scapulae
Supraspinatus
Infraspinatus
Teres minor
Lateral head of triceps brachii (cut)
Teres major
Latissimus dorsi (cut)
Long head of triceps brachii
External intercostal
Medial head of triceps brachii
Erector spinae
Internal oblique
Supinator (deep head)
Gluteus medius
Abductor pollicis longus
Extensor pollicis longus
Extensor pollicis brevis
Extensor indicis
Piriformis
Gemellus superior
Obturator internus
Gemellus inferior
Quadratus femoris
Adductor magnus
Short head of biceps femoris
Semimembranosus
Long head of biceps femoris (cut)
Plantaris (cut)
Popliteus
Soleus (cut)
Flexor digitorum longus
Flexor hallucis longus

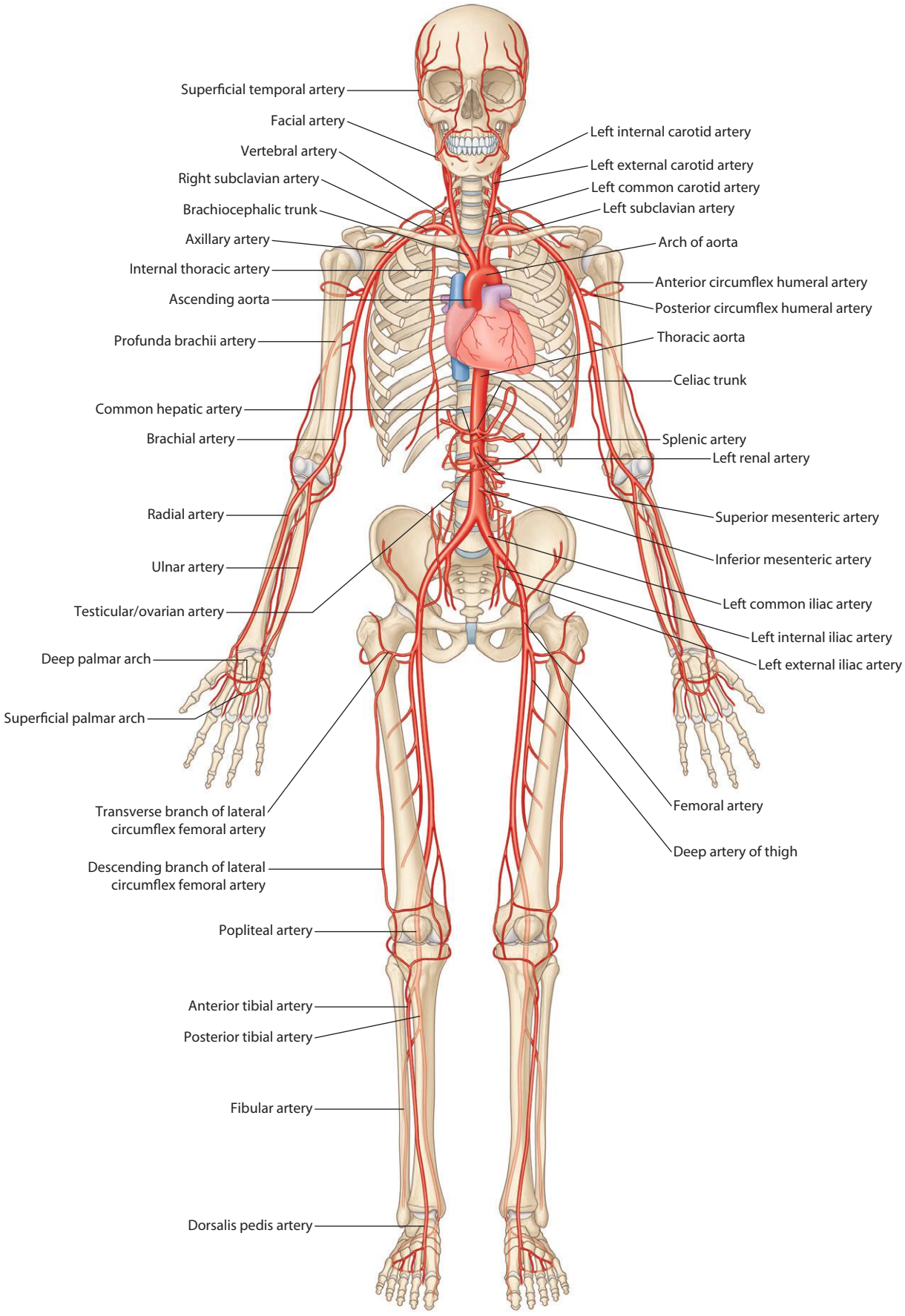
Superficial temporal artery
Facial artery
Vertebral artery
Right subclavian artery
Brachiocephalic trunk
Axillary artery
Internal thoracic artery
Ascending aorta
Profunda brachii artery
Common hepatic artery
Brachial artery
Radial artery
Ulnar artery
Testicular/ovarian artery
Deep palmar arch
Superficial palmar arch
Transverse branch of lateral circumflex femoral artery
Descending branch of lateral circumflex femoral artery
Popliteal artery
Anterior tibial artery
Posterior tibial artery
Fibular artery
Dorsalis pedis artery
Left internal carotid artery
Left external carotid artery
Left common carotid artery
Left subclavian artery
Arch of aorta
Anterior circumflex humeral artery
Posterior circumflex humeral artery
Thoracic aorta
Celiac trunk
Splenic artery
Left renal artery
Superior mesenteric artery
Inferior mesenteric artery
Left common iliac artery
Left internal iliac artery
Left external iliac artery
Femoral artery
Deep artery of thigh

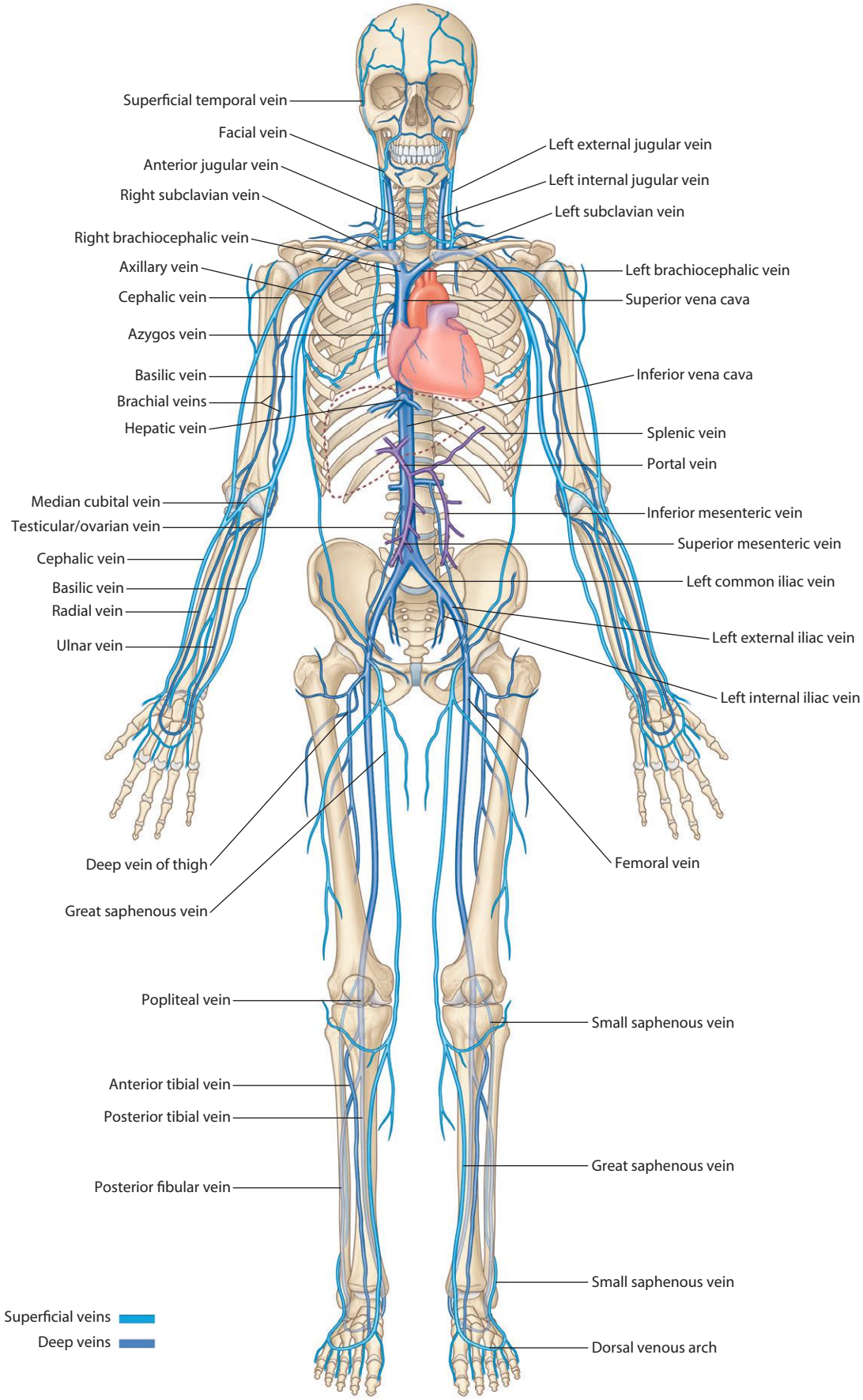
Superficial temporal vein
Facial vein
Anterior jugular vein
Right subclavian vein
Right brachiocephalic vein
Axillary vein
Cephalic vein
Azygos vein
Basilic vein
Brachial veins
Hepatic vein
Median cubital vein
Testicular/ovarian vein
Cephalic vein
Basilic vein
Radial vein
Ulnar vein
Deep vein of thigh
Great saphenous vein
Popliteal vein
Anterior tibial vein
Posterior tibial vein
Posterior fibular vein
Left external jugular vein
Left internal jugular vein
Left subclavian vein
Left brachiocephalic vein
Superior vena cava
Inferior vena cava
Splenic vein
Portal vein
Inferior mesenteric vein
Superior mesenteric vein
Left common iliac vein
Left external iliac vein
Left internal iliac vein
Femoral vein
Small saphenous vein
Great saphenous vein
Small saphenous vein
Dorsal venous arch
Superficial veins
Deep veins

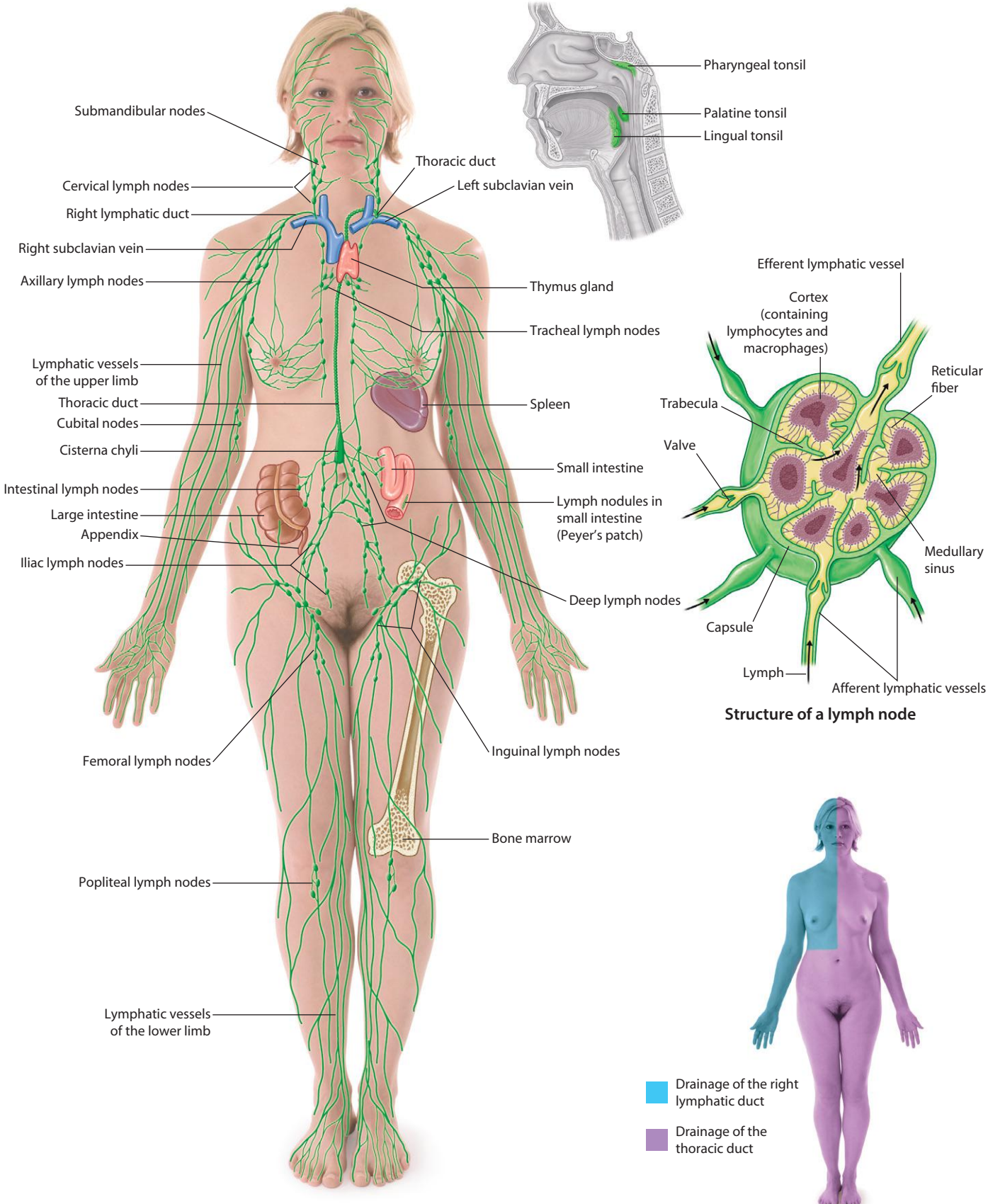

Principal components of the lymphatic system

Structure of a lymph node

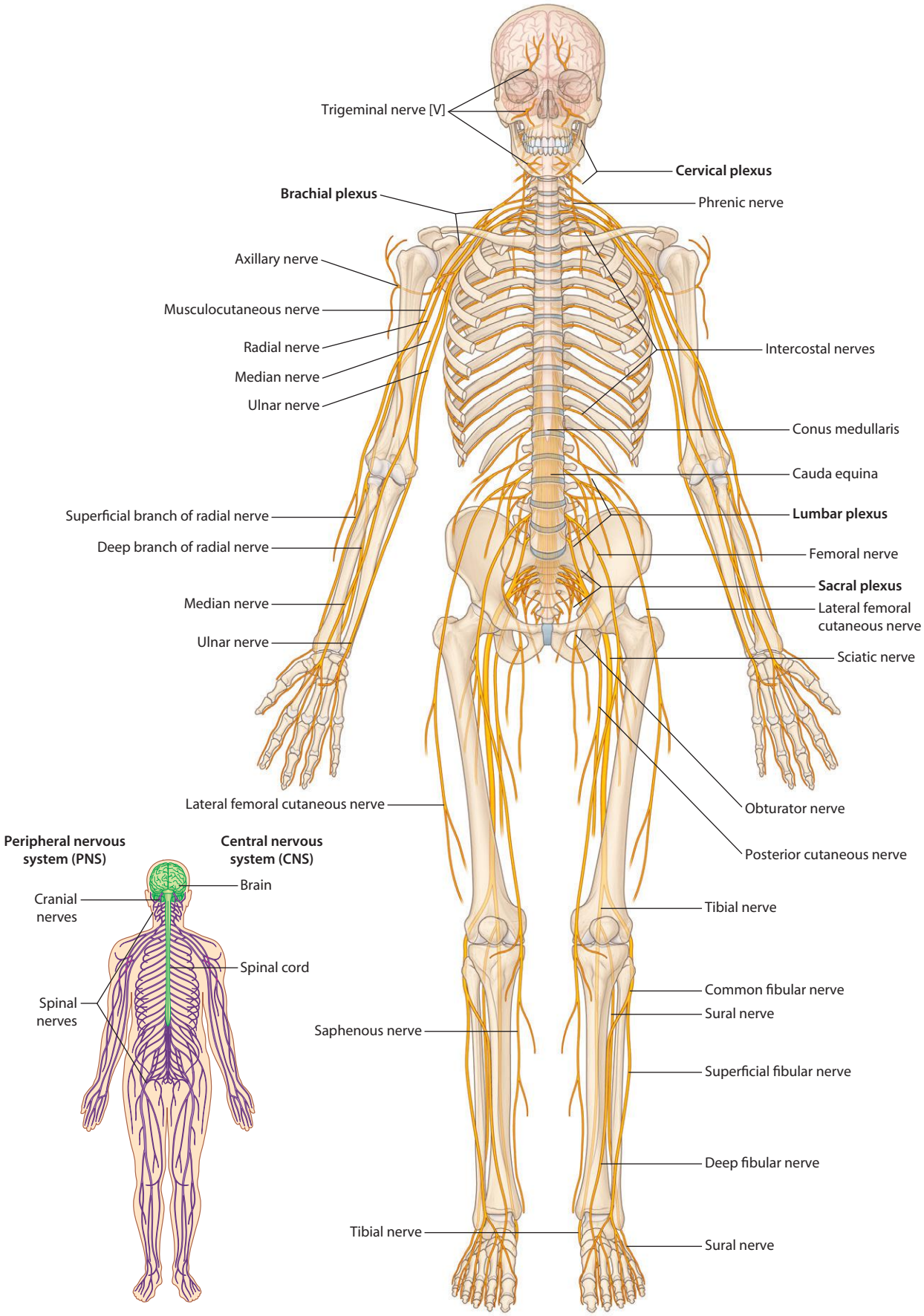
Trigeminal nerve [V]
Cervical plexus
Brachial plexus
Phrenic nerve
Axillary nerve
Musculocutaneous nerve
Radial nerve
Median nerve
Ulnar nerve
Intercostal nerves
Conus medullaris
Cauda equina
Superficial branch of radial nerve
Deep branch of radial nerve
Lumbar plexus
Femoral nerve
Sacral plexus
Median nerve
Lateral femoral cutaneous nerve
Ulnar nerve
Sciatic nerve
Lateral femoral cutaneous nerve
Obturator nerve
Posterior cutaneous nerve
Peripheral nervous system (PNS)
Central nervous system (CNS)
Brain
Cranial nerves
Spinal cord
Spinal nerves
Tibial nerve
Common fibular nerve
Sural nerve
Saphenous nerve
Superficial fibular nerve
Deep fibular nerve
Tibial nerve
Sural nerve

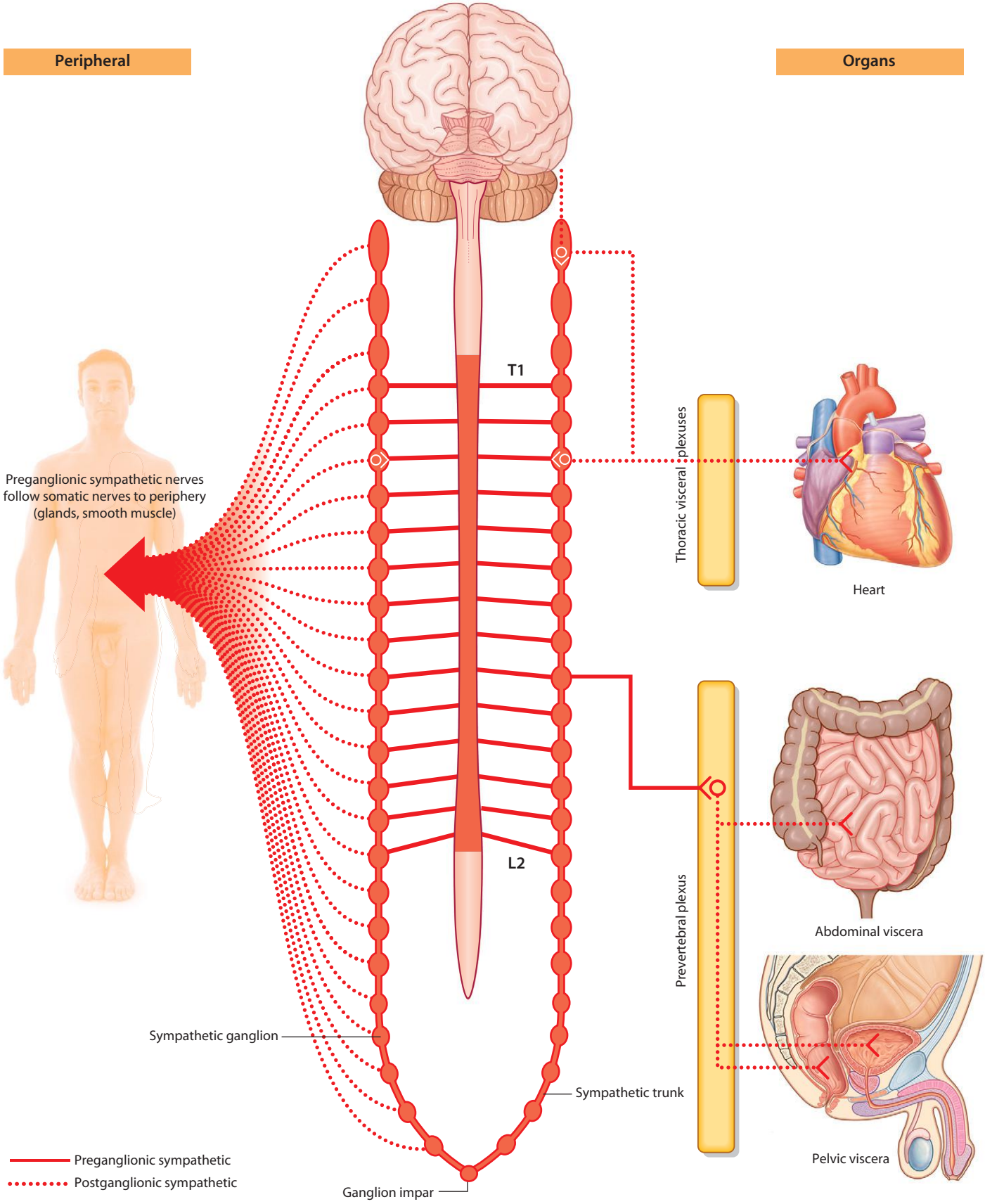

All sympathetic visceral efferent (motor) nerves originate from spinal levels T1–L2 and pass into the associated spinal nerves

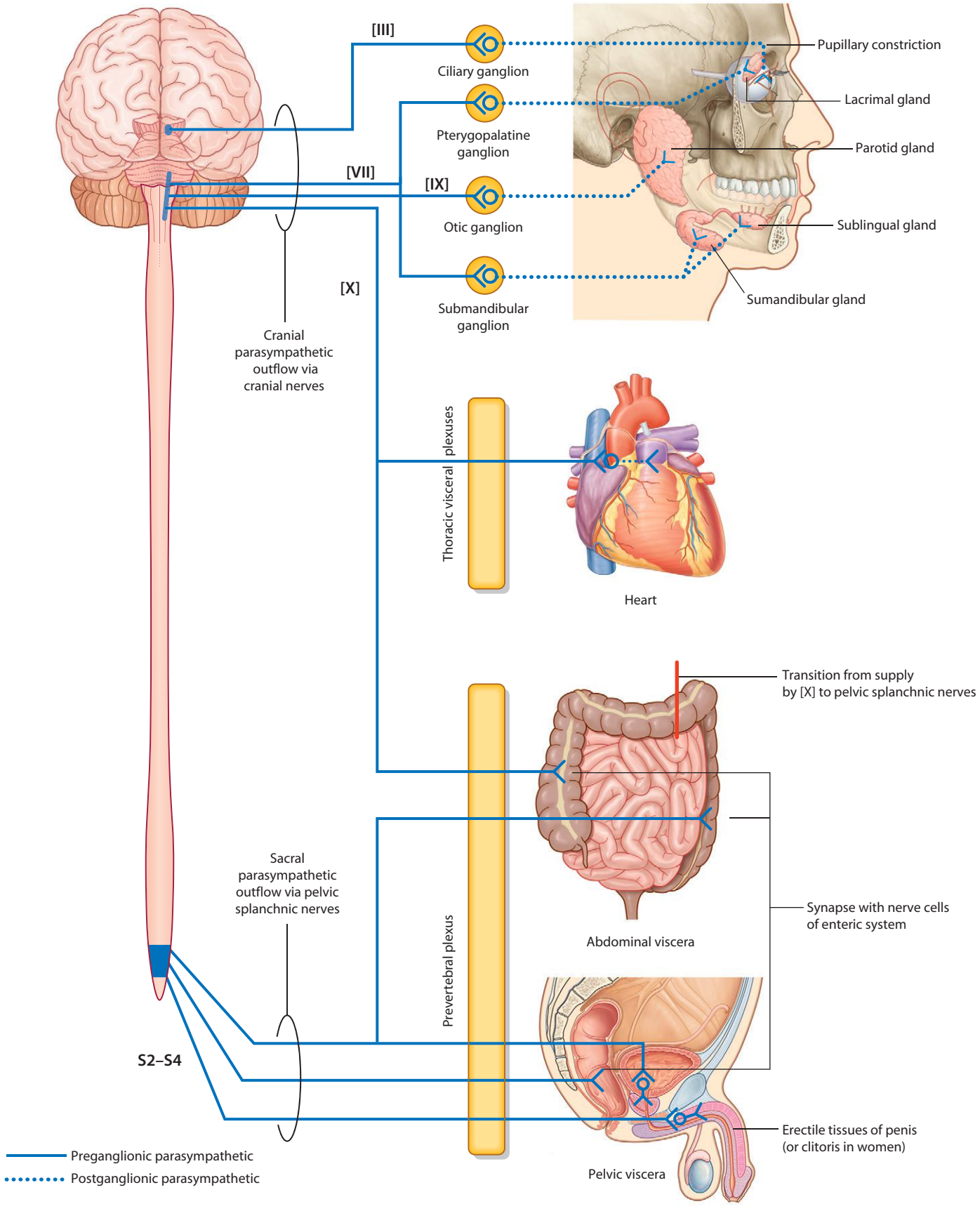

All paraympathetic visceral efferent (motor) nerves emerge from the brain in cranial nerves III, VII, IX, and X and from spinal levels S2–S4

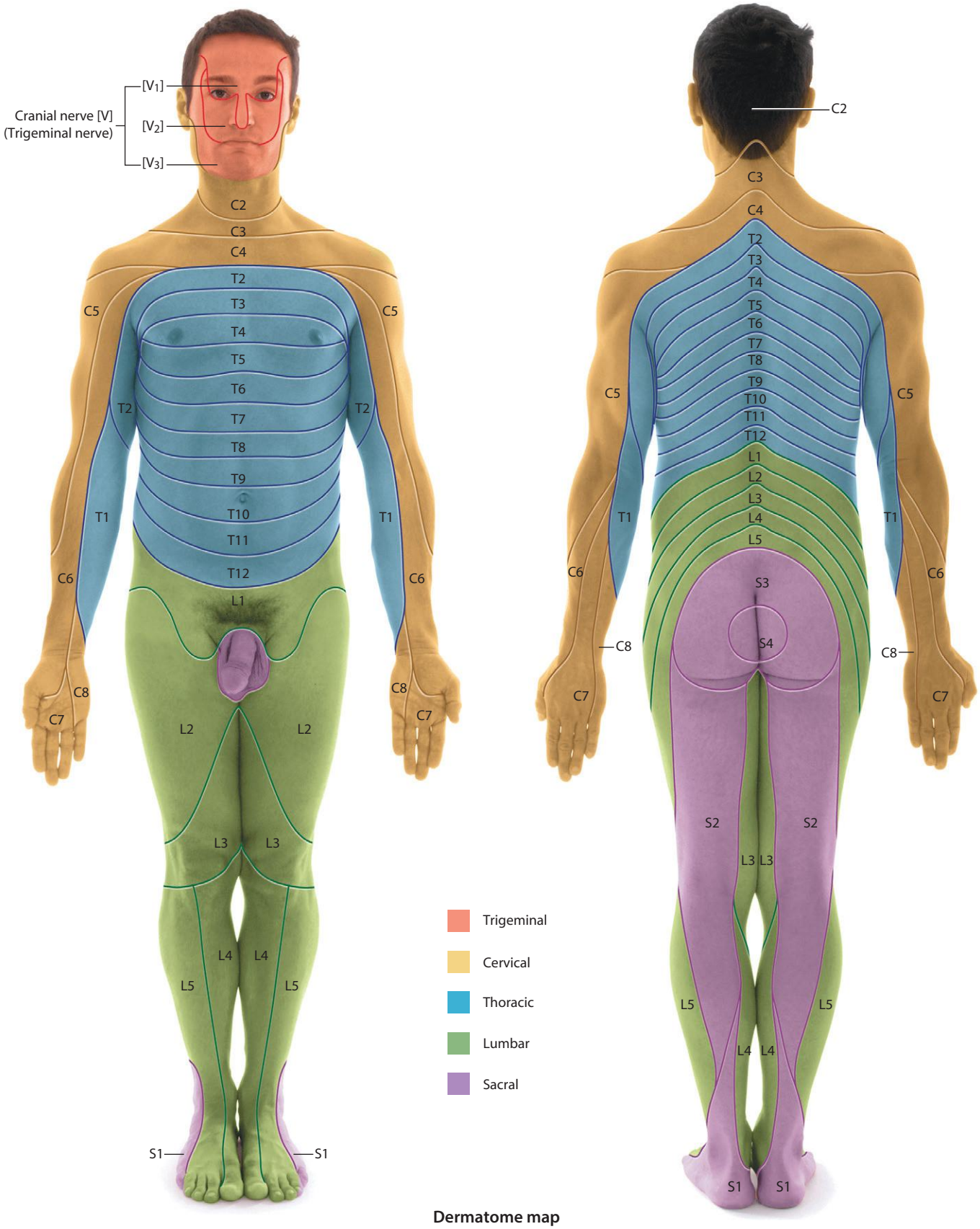

Dermatome map
(cutaneous distribution of nerves)

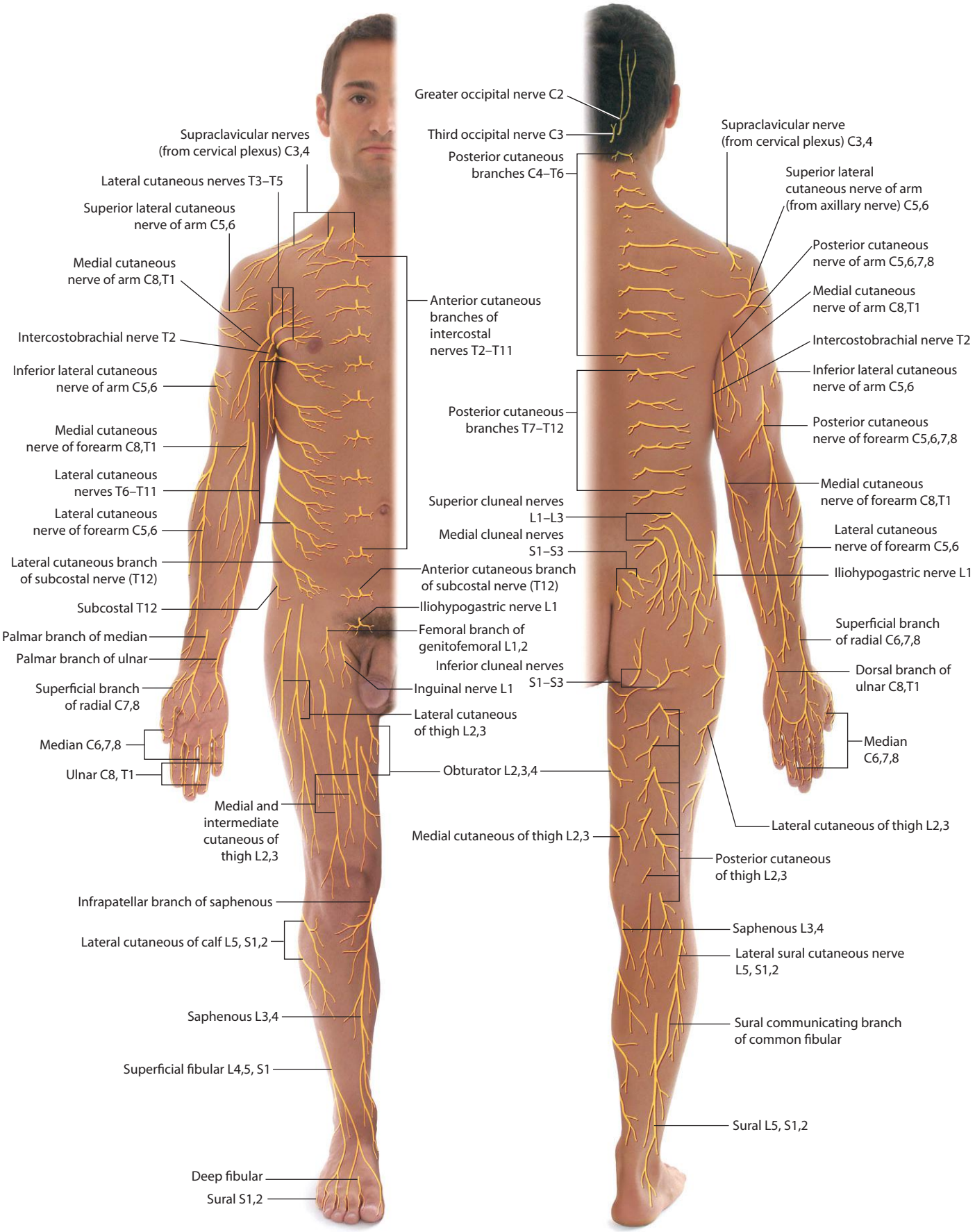
Supraclavicular nerves (from cervical plexus) C3,4
Lateral cutaneous nerves T3–T5
Superior lateral cutaneous nerve of arm C5,6
Medial cutaneous nerve of arm C8,T1
Intercostobrachial nerve T2
Inferior lateral cutaneous nerve of arm C5,6
Medial cutaneous nerve of forearm C8,T1
Lateral cutaneous nerves T6–T11
Lateral cutaneous nerve of forearm C5,6
Lateral cutaneous branch of subcostal nerve (T12)
Subcostal T12
Palmar branch of median
Palmar branch of ulnar
Superficial branch of radial C7,8
Median C6,7,8
Ulnar C8, T1
Medial and intermediate cutaneous of thigh L2,3
Infrapatellar branch of saphenous
Lateral cutaneous of calf L5, S1,2
Saphenous L3,4
Superficial fibular L4,5, S1
Deep fibular
Sural S1,2
Anterior cutaneous branches of intercostal nerves T2–T11
Posterior cutaneous branches T7–T12
Superior cluneal nerves L1–L3
Medial cluneal nerves S1–S3
Anterior cutaneous branch of subcostal nerve (T12)
Iliohypogastric nerve L1
Femoral branch of genitofemoral L1,2
Inferior cluneal nerves S1–S3
Inguinal nerve L1
Lateral cutaneous of thigh L2,3
Obturator L2,3,4
Greater occipital nerve C2
Third occipital nerve C3
Posterior cutaneous branches C4–T6
Supraclavicular nerve (from cervical plexus) C3,4
Superior lateral cutaneous nerve of arm (from axillary nerve) C5,6
Posterior cutaneous nerve of arm C5,6,7,8
Medial cutaneous nerve of arm C8,T1
Intercostobrachial nerve T2
Inferior lateral cutaneous nerve of arm C5,6
Posterior cutaneous nerve of forearm C5,6,7,8
Medial cutaneous nerve of forearm C8,T1
Lateral cutaneous nerve of forearm C5,6
Iliohypogastric nerve L1
Superficial branch of radial C6,7,8
Dorsal branch of ulnar C8,T1
Median C6,7,8
Lateral cutaneous of thigh L2,3
Medial cutaneous of thigh L2,3
Posterior cutaneous of thigh L2,3
Saphenous L3,4
Lateral sural cutaneous nerve L5, S1,2
Sural communicating branch of common fibular
Sural L5, S1,2

This page intentionally left blank

2

BACK

CONTENTS

Surface anatomy	**20**
Vertebral column	**21**
Regional vertebrae	**22**
Cervical vertebrae	**23**
Thoracic vertebrae	**26**
Lumbar vertebrae	**28**
Sacrum	**31**
Intervertebral foramina and discs	**32**
Intervertebral disc problems	**33**
Joints and ligaments	**35**
Back musculature: surface anatomy	**36**
Superficial musculature	**37**
Intermediate musculature	**39**
Deep musculature	**40**
Back musculature: transverse section	**42**
Suboccipital region	**43**
Spinal nerves	**44**
Spinal cord	**45**
Spinal cord vasculature	**46**
Venous drainage of spinal cord	**47**
Meninges	**48**
Spinal cord: imaging	**50**
Transverse section: thoracic region	**52**
Dermatomes and cutaneous nerves	**53**
Tables	**54**

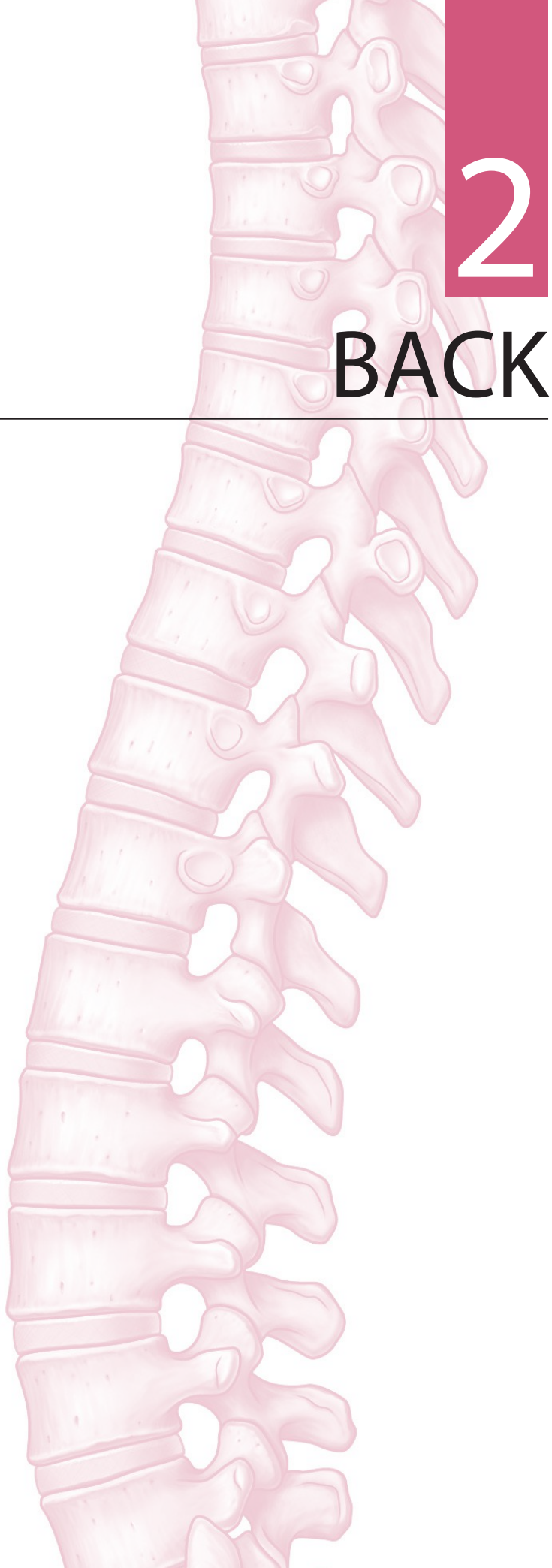

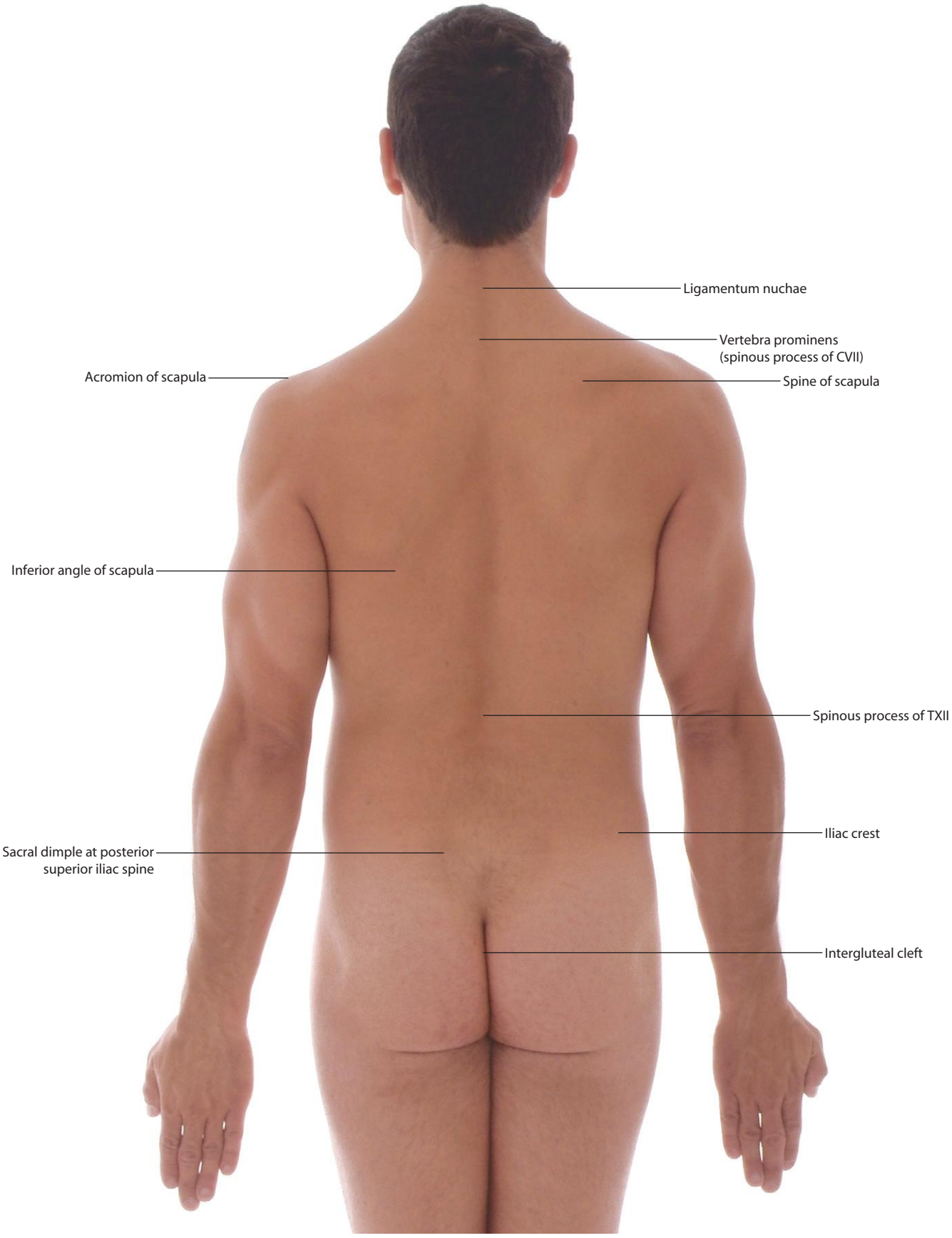

Surface anatomy of the back

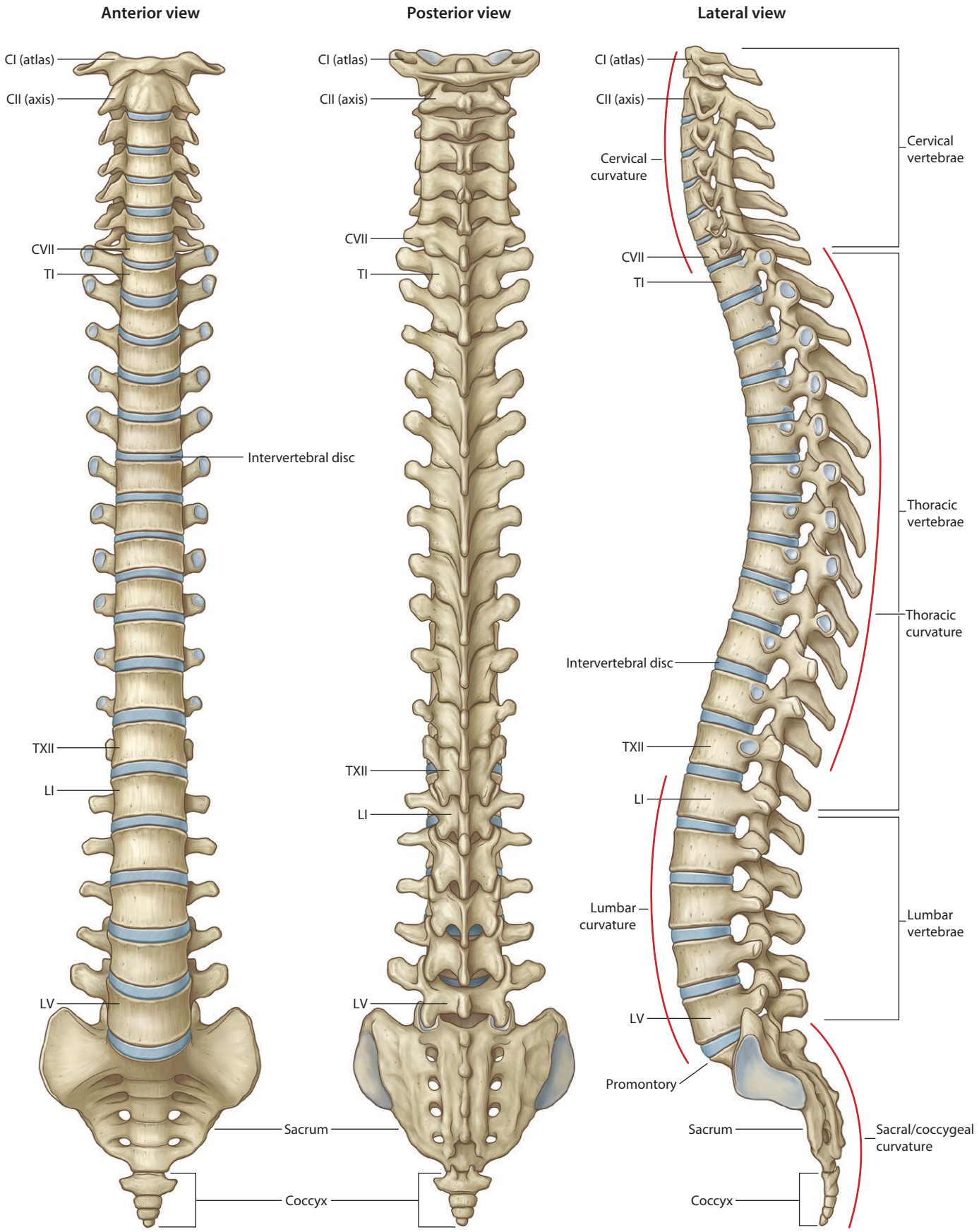
Anterior view
Posterior view
Lateral view
CI (atlas)
CII (axis)
CVII
TI
Intervertebral disc
TXII
LI
LV
Sacrum
Coccyx
Cervical curvature
Cervical vertebrae
Thoracic vertebrae
Thoracic curvature
Lumbar curvature
Lumbar vertebrae
Promontory
Sacral/coccygeal curvature

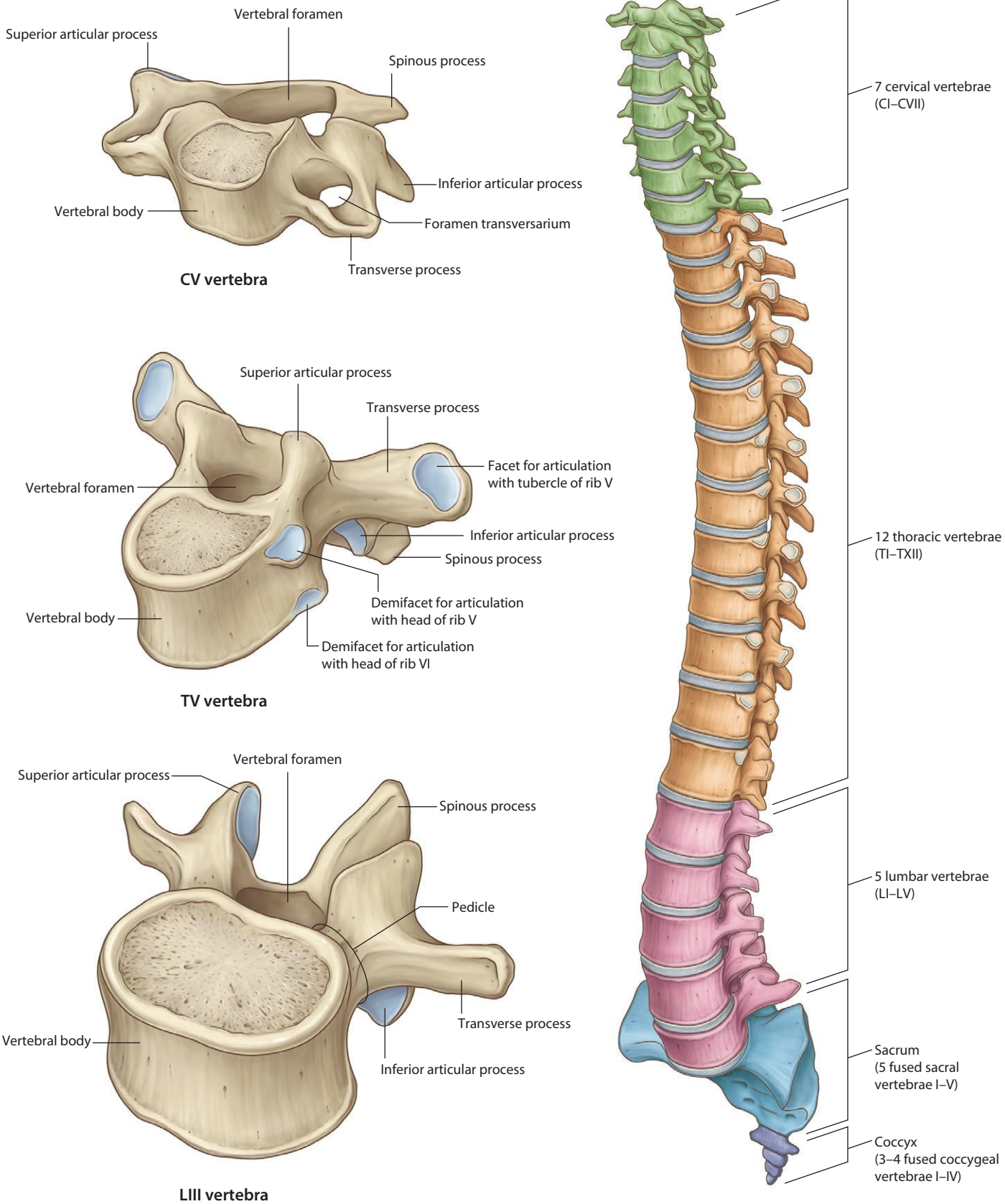
Vertebral foramen
Superior articular process
Spinous process
Inferior articular process
Vertebral body
Foramen transversarium
Transverse process
CV vertebra
Superior articular process
Transverse process
Facet for articulation with tubercle of rib V
Vertebral foramen
Inferior articular process
Spinous process
Demifacet for articulation with head of rib V
Vertebral body
Demifacet for articulation with head of rib VI
TV vertebra
Vertebral foramen
Superior articular process
Spinous process
Pedicle
Transverse process
Vertebral body
Inferior articular process
LIII vertebra
7 cervical vertebrae (CI–CVII)
12 thoracic vertebrae (TI–TXII)
5 lumbar vertebrae (LI–LV)
Sacrum (5 fused sacral vertebrae I–V)
Coccyx (3–4 fused coccygeal vertebrae I–IV)

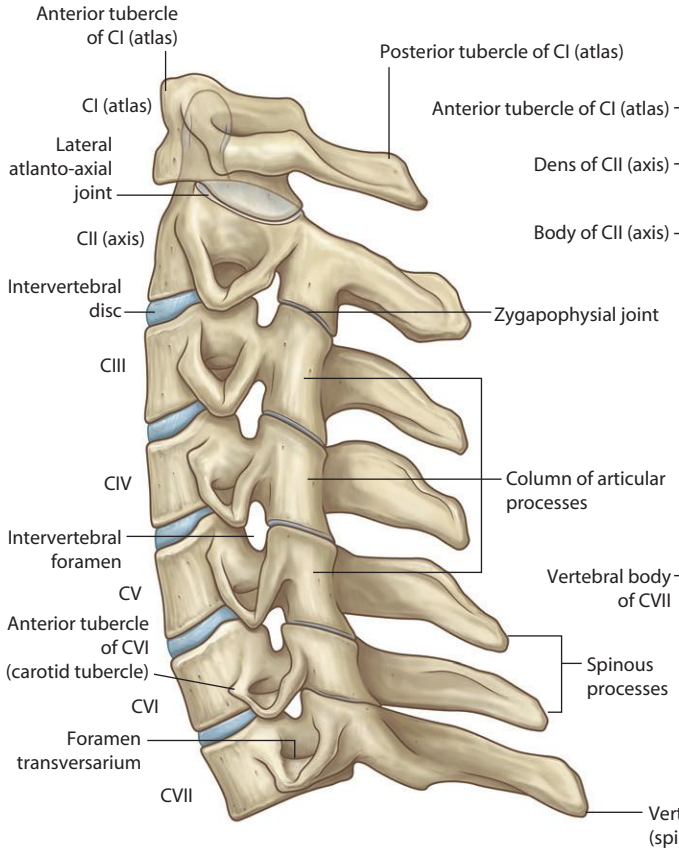

Cervical vertebrae (lateral view)

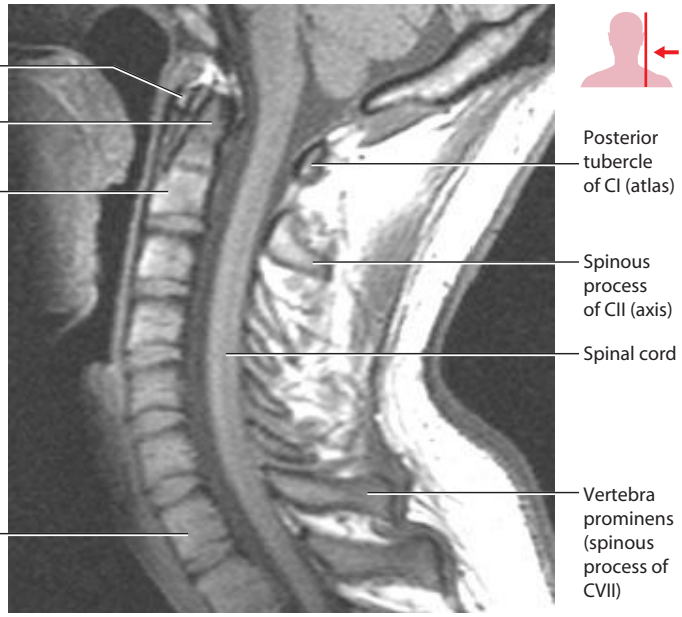

Cervical region of vertebral column.
T1-weighted MR image in the sagittal plane

Cervical region of vertebral column.
Radiograph, AP view

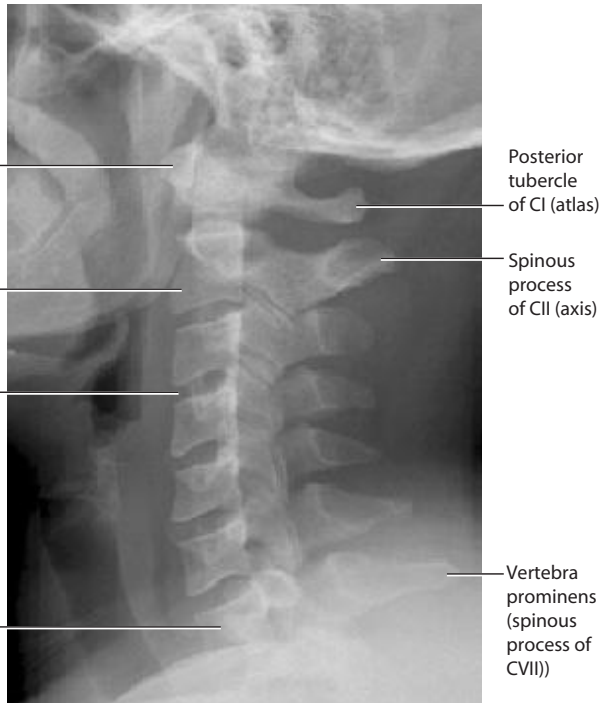

Cervical region of vertebral column.
Radiograph, lateral view

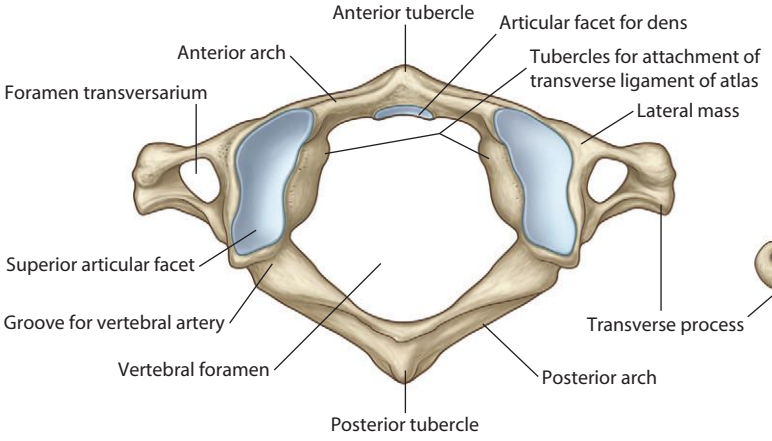

CI vertebra (atlas; superior view)

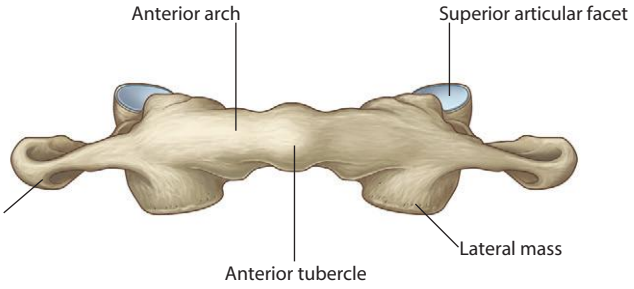

CI vertebra (atlas; anterior view)

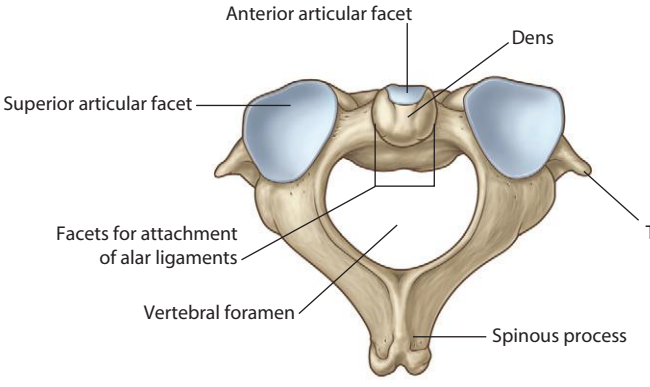

CII vertebra (axis; superior view)

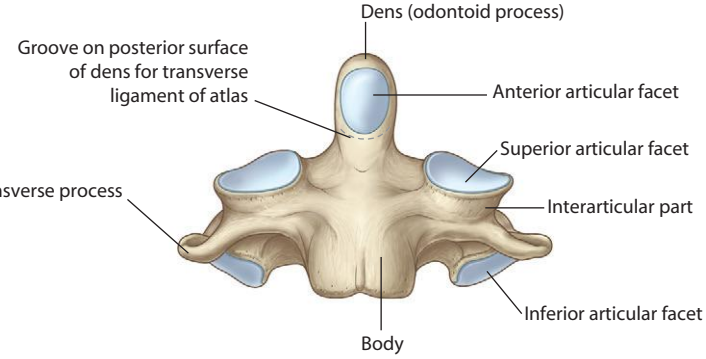

CII vertebra (axis; anterior view)

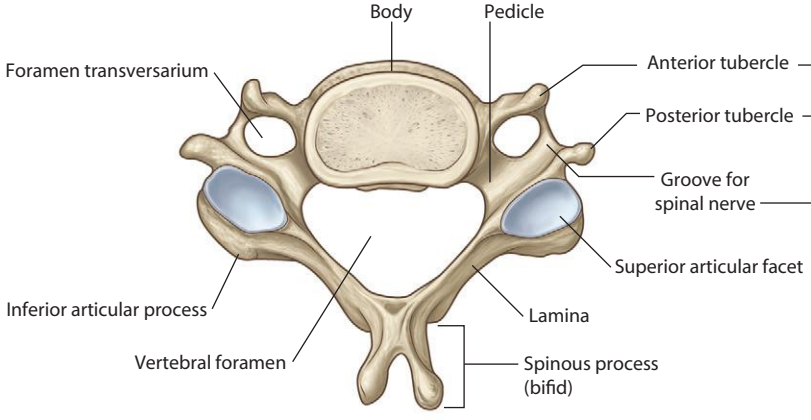

CV vertebra (superior view)

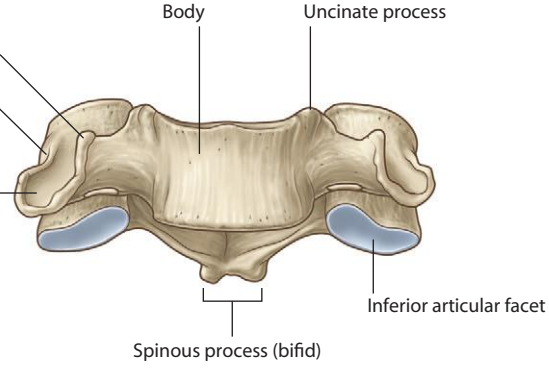

CV vertebra (anterior view)

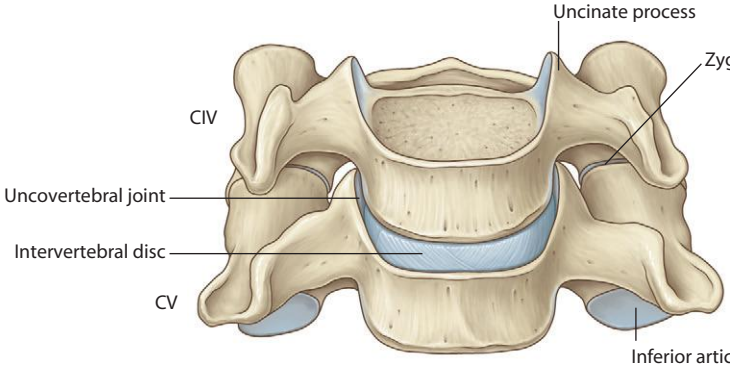

CIV/CV vertebrae (anterior view)

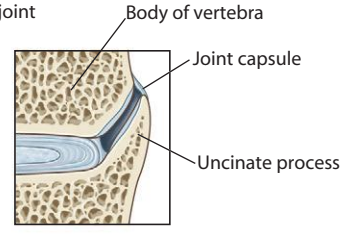

Uncovertebral joint



Anterior

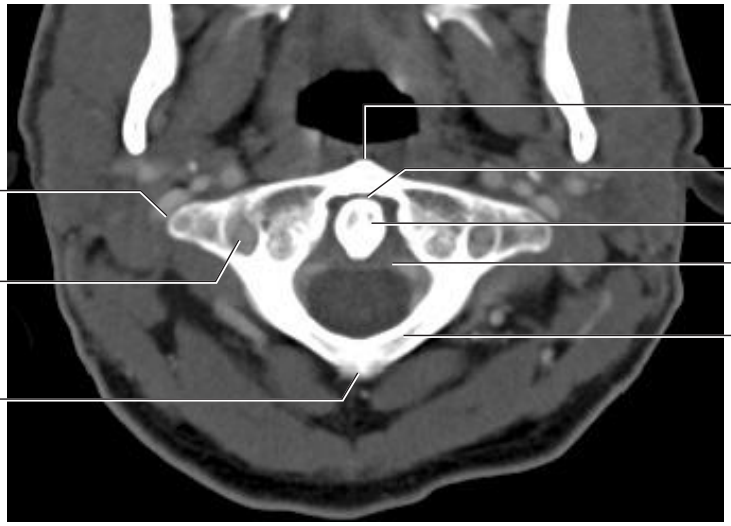

Posterior

First cervical vertebra (atlas).
CT image in axial plane

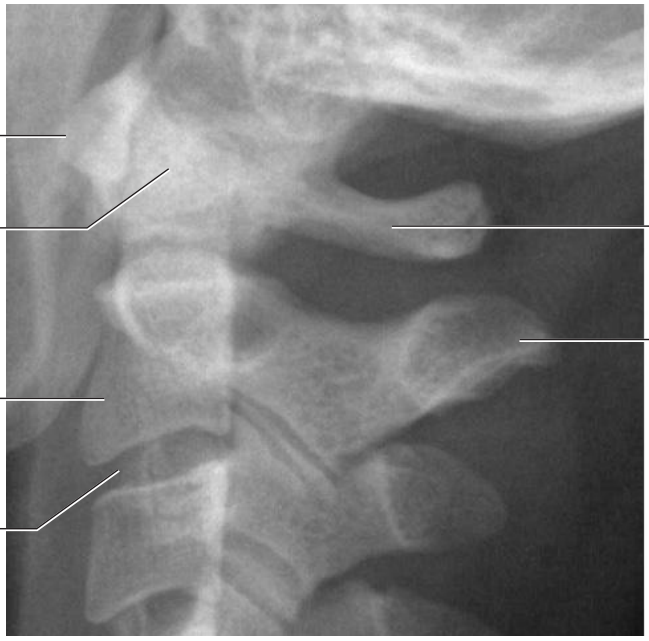

Cervical vertebrae CI–CIII.
Radiograph, lateral view



Anterior

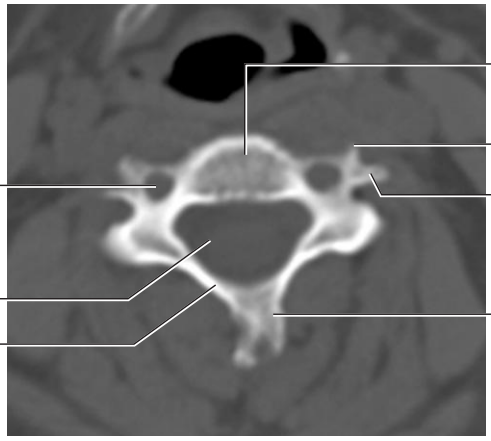

Posterior

Typical cervical vertebra.
CT image in axial plane

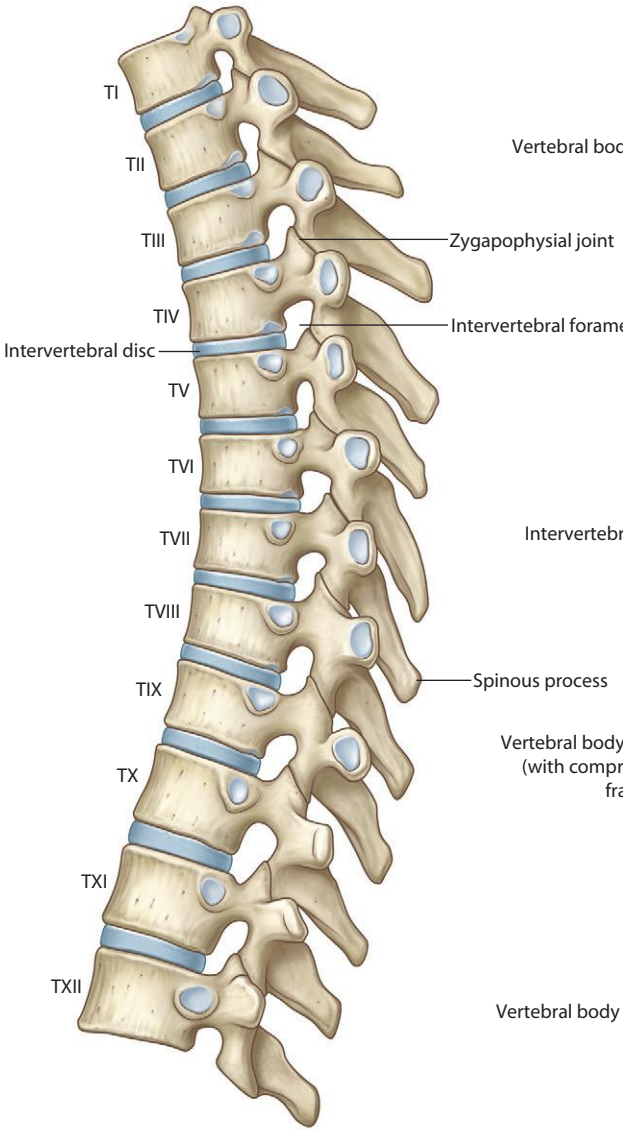

Thoracic vertebrae (lateral view)

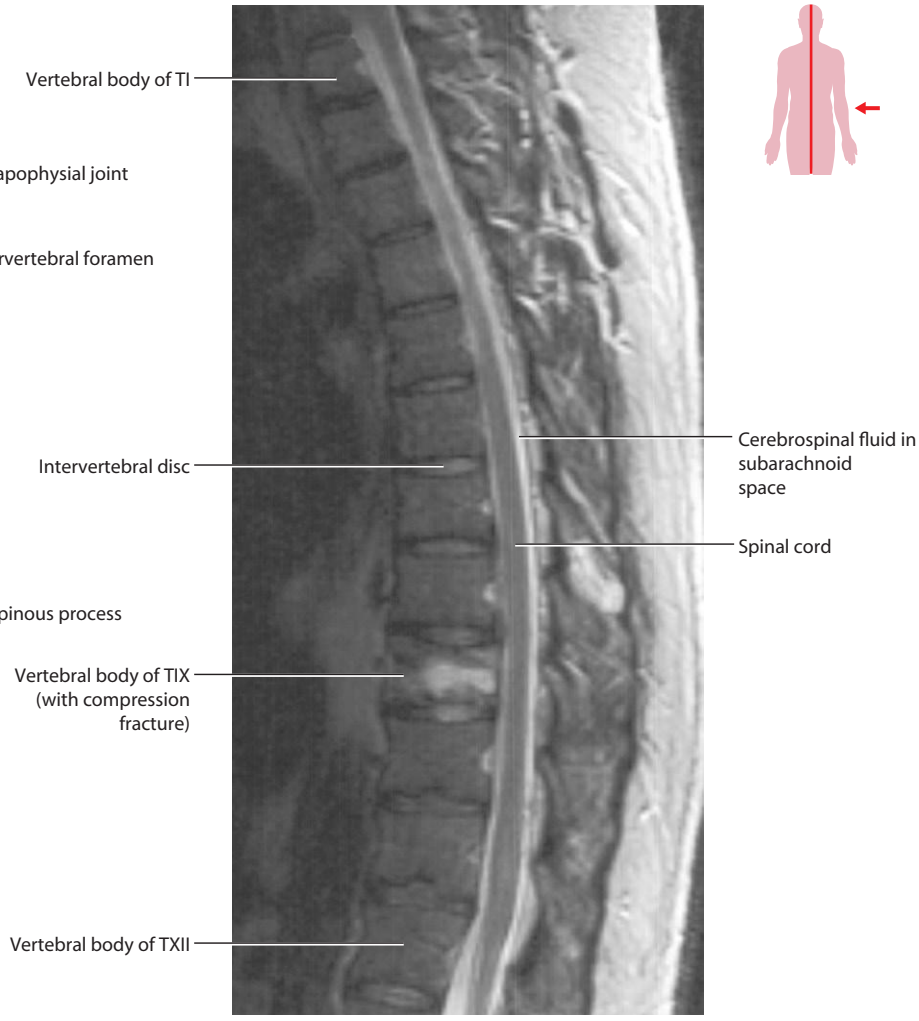

Thoracic region of vertebral column.
T2-weighted MR image in sagittal plane (compression fracture TIX)

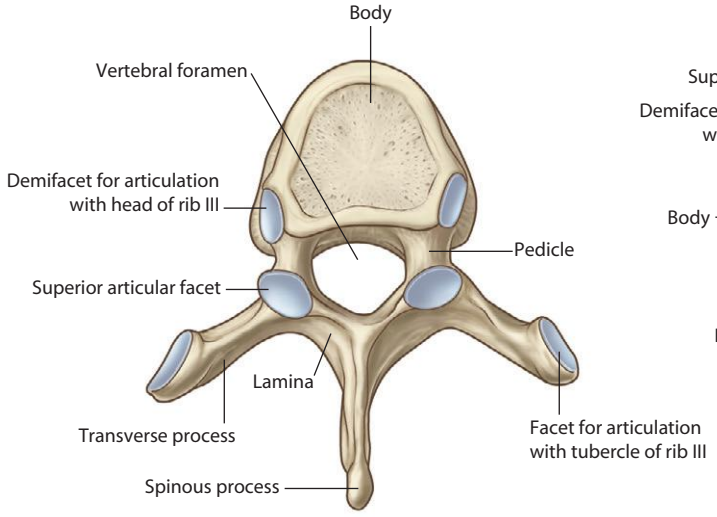

TIII vertebra (superior view)

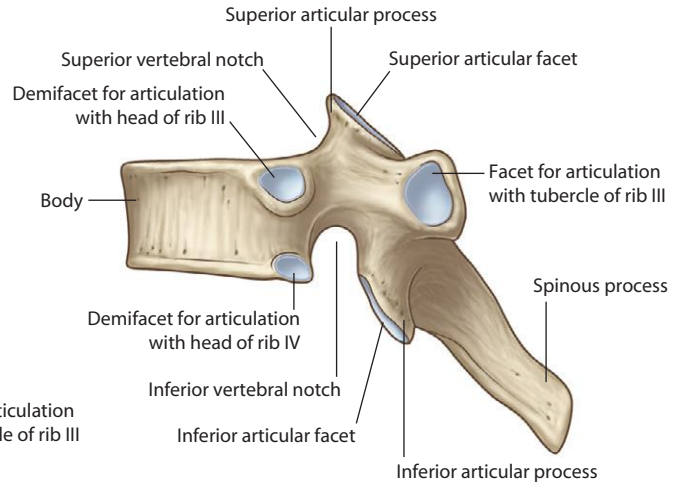

TIII vertebra (lateral view)

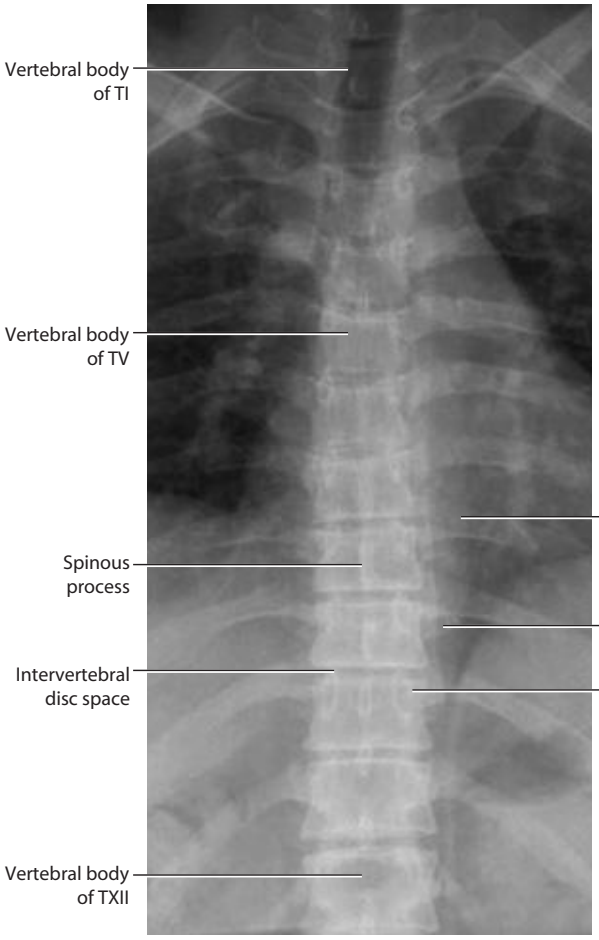

Thoracic region of vertebral column.
Radiograph, AP view

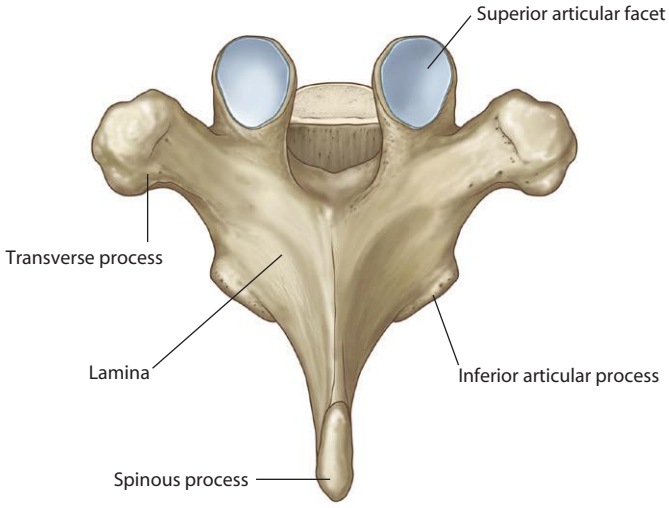

TIII vertebra (posterior view)

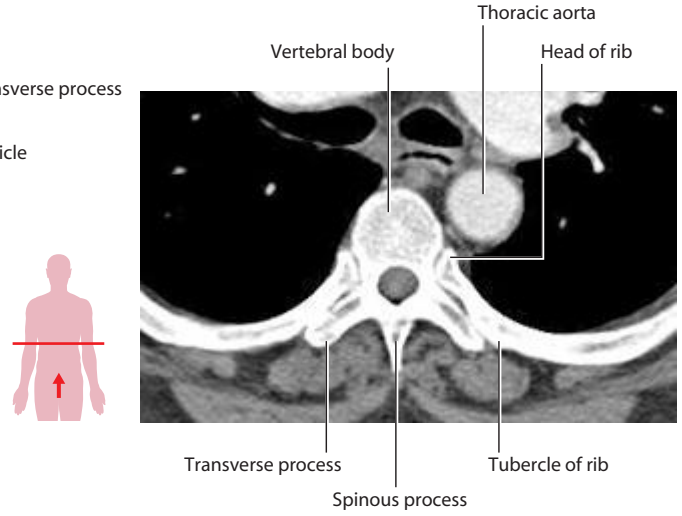

Thoracic vertebra with rib articulations.
CT image in axial plane

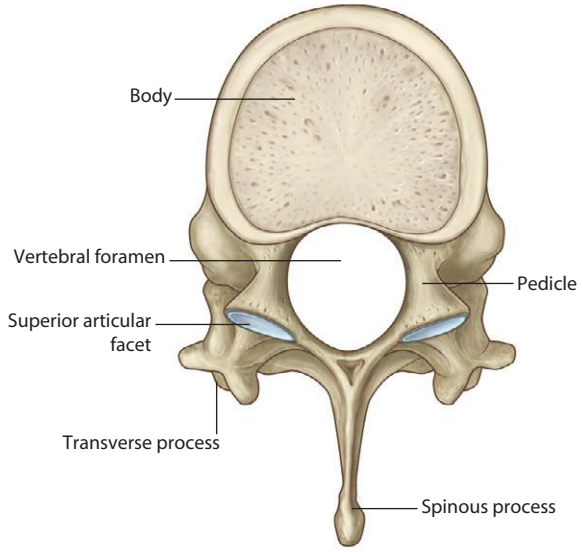

TXII vertebra (superior view)

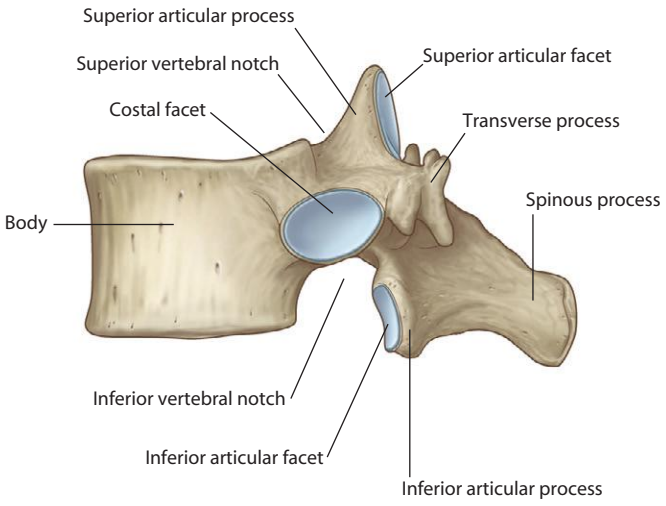

TXII vertebra (lateral view)

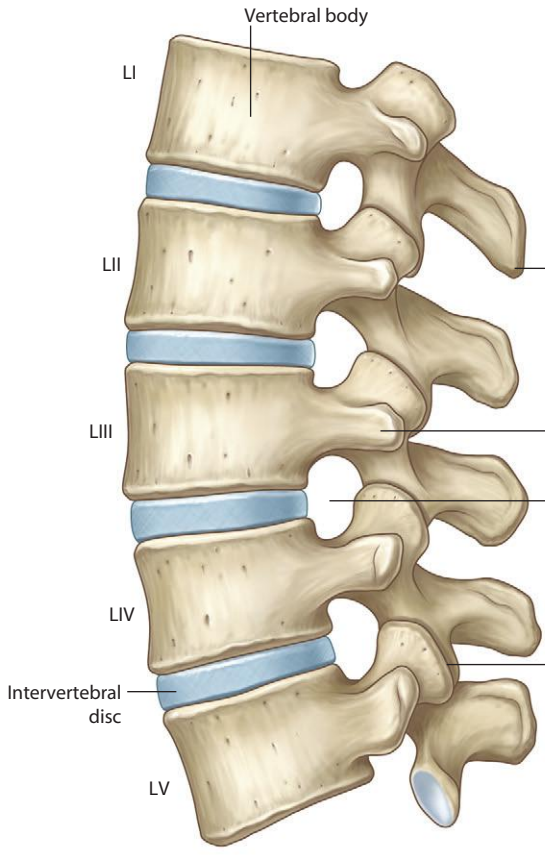

Lumbar vertebrae (lateral view)

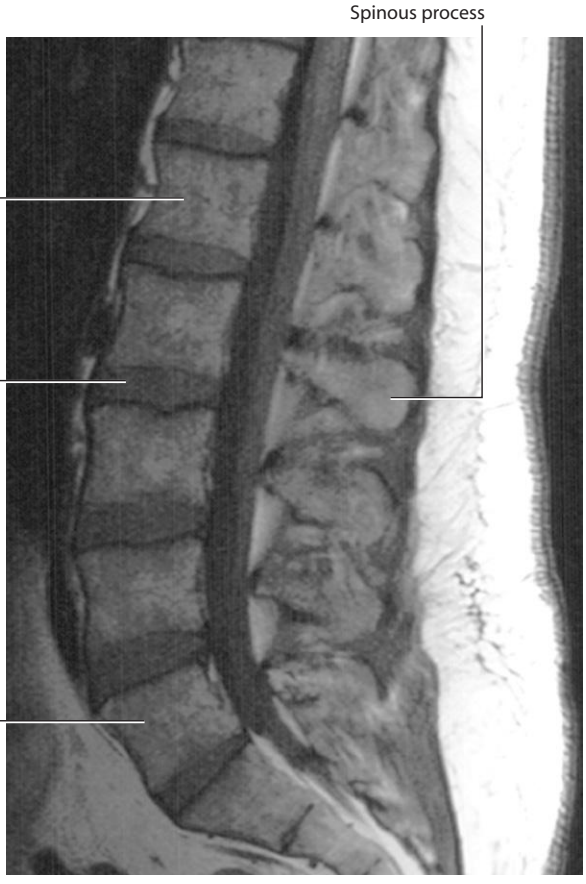

Lumbar region of vertebral column.
T1-weighted MR image in sagittal plane

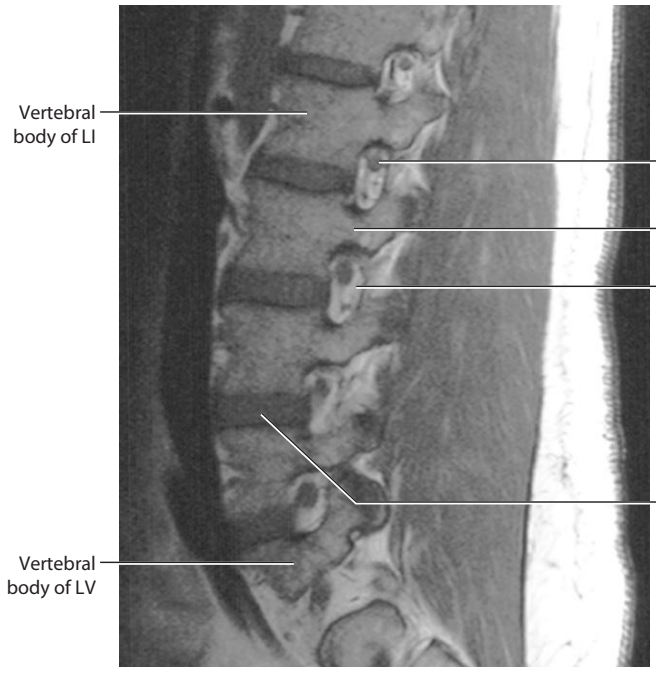

Intervertebral foramina of lumbar region of vertebral column.
T1-weighted MR image in sagittal plane

Lumbar region of vertebral column.
Radiograph, lateral view

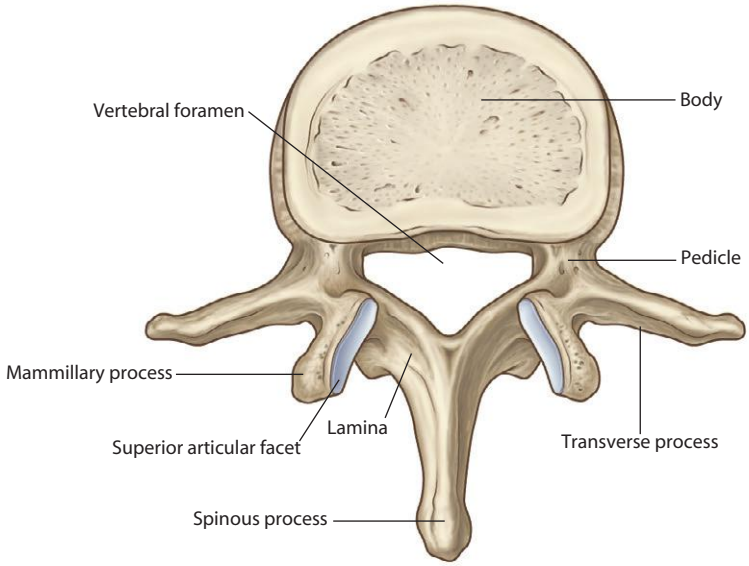

LIV vertebra (superior view)

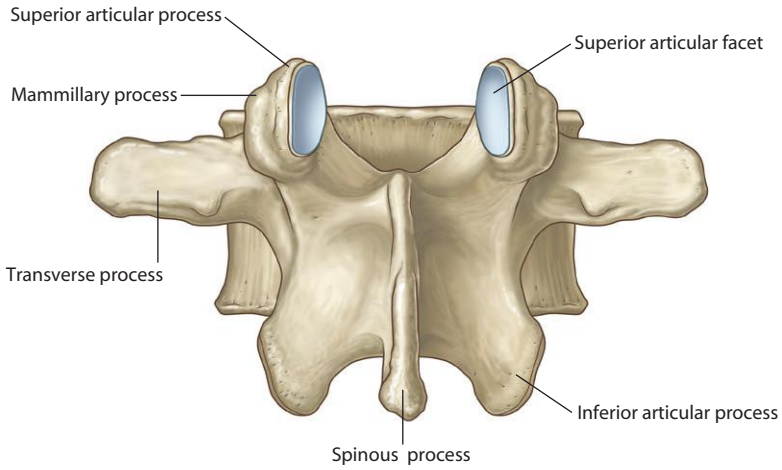

LIV vertebra (posterior view)

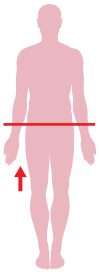

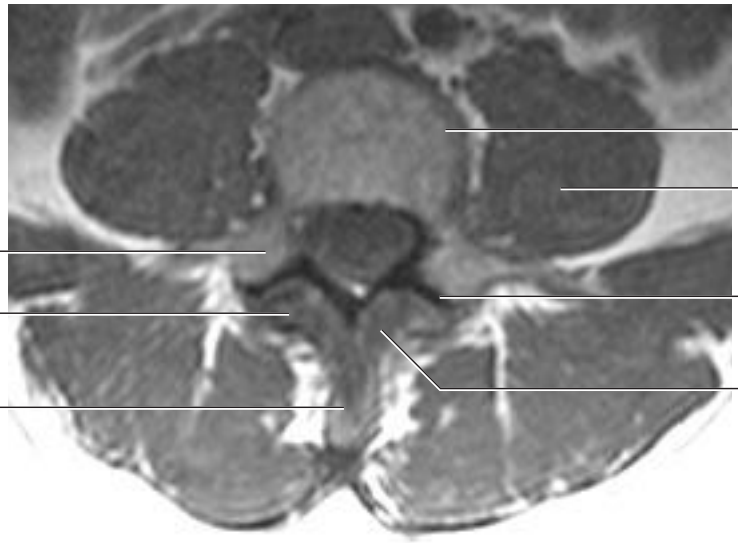

Articulation of lumbar vertebrae.
T1-weighted MR image in axial plane

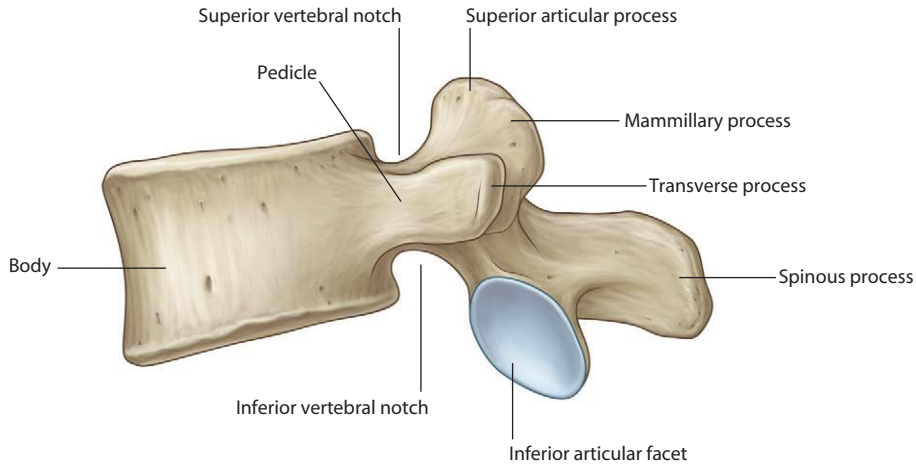

LIV vertebra (lateral view)

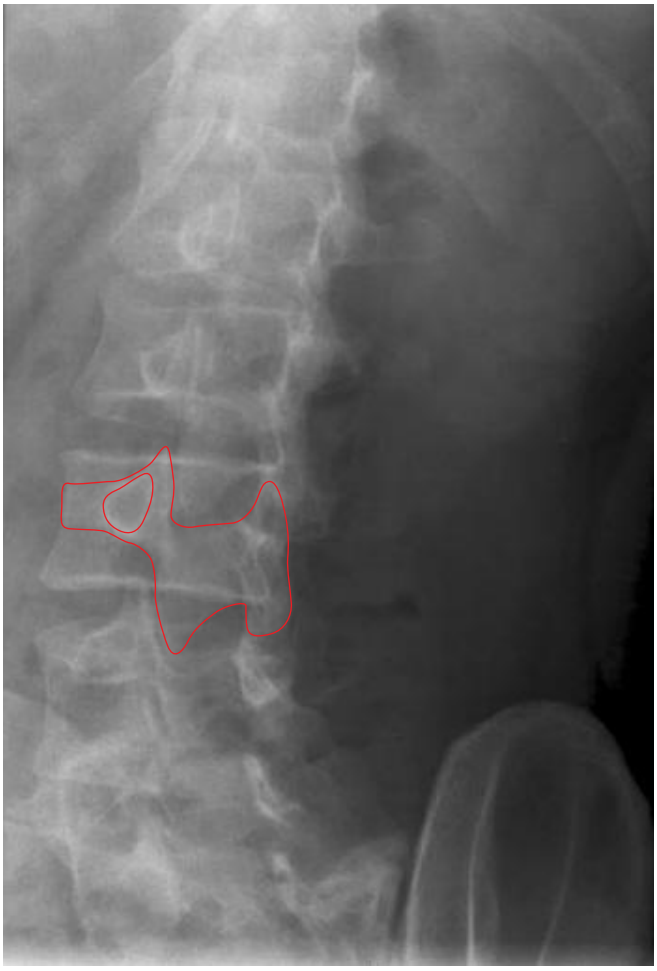

Lumbar region of vertebral column ("Scottie dog").
Radiograph, oblique view

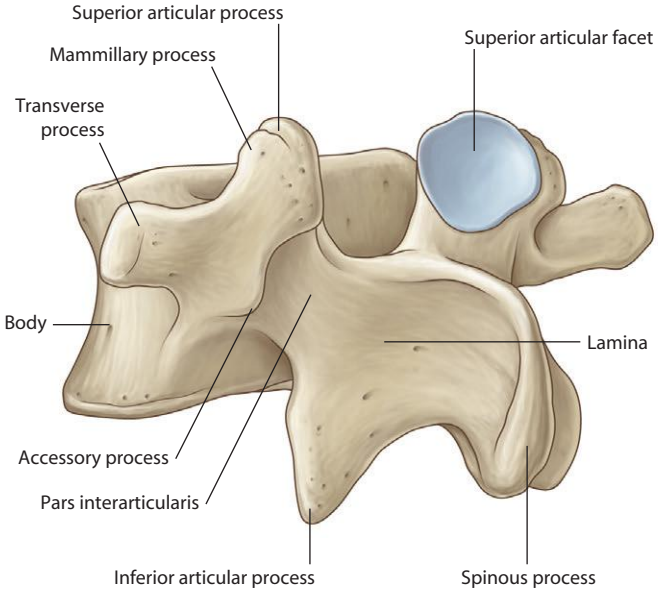

LIV vertebra (oblique view)

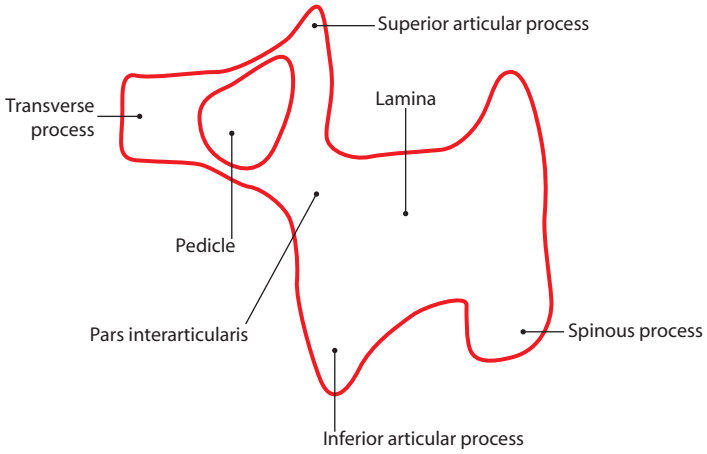

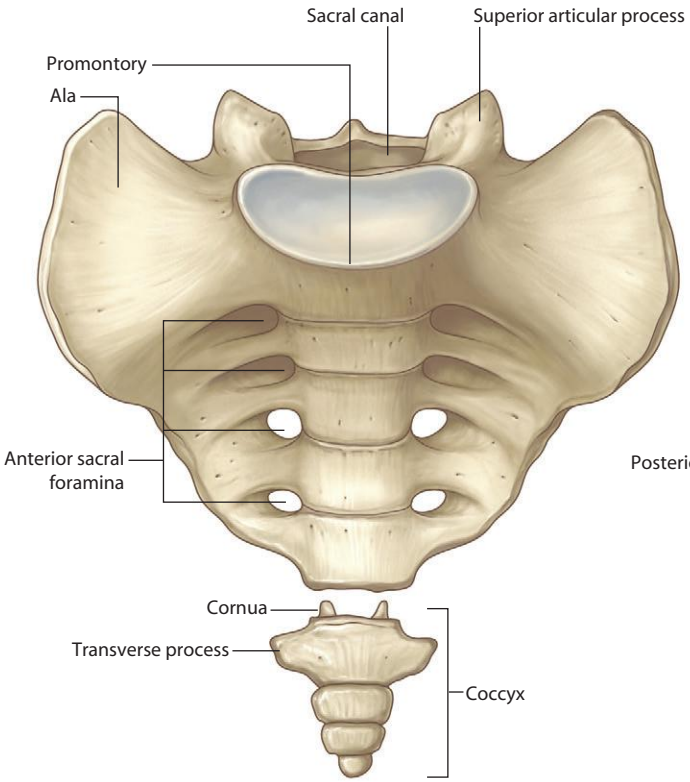

Sacrum and coccyx (anterior view)

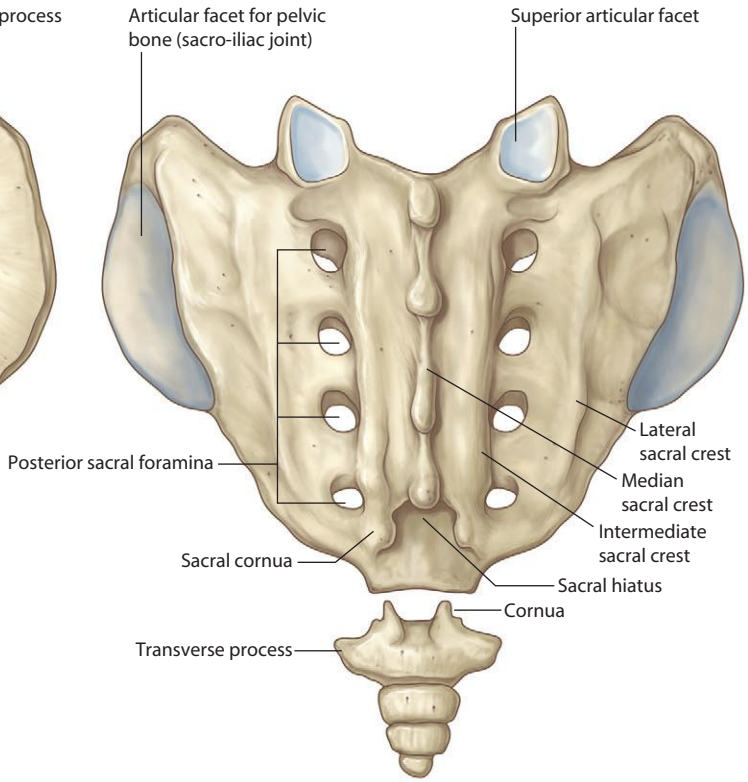

Sacrum and coccyx (posterior view)

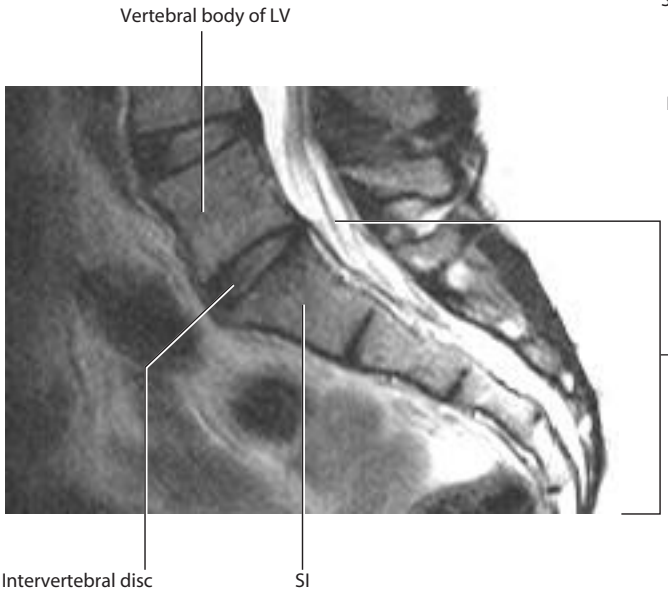

Sacral region of vertebral column.
T2-weighted MR image in sagittal plane

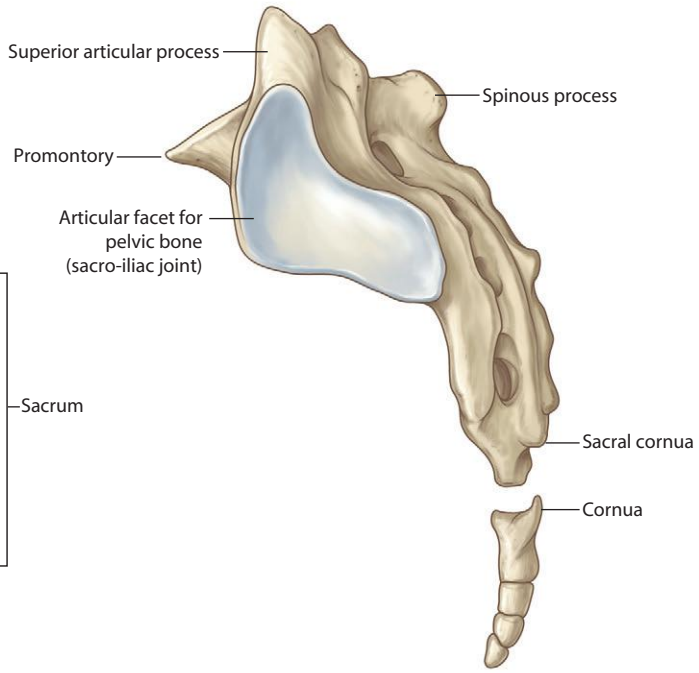

Sacrum and coccyx (lateral view)

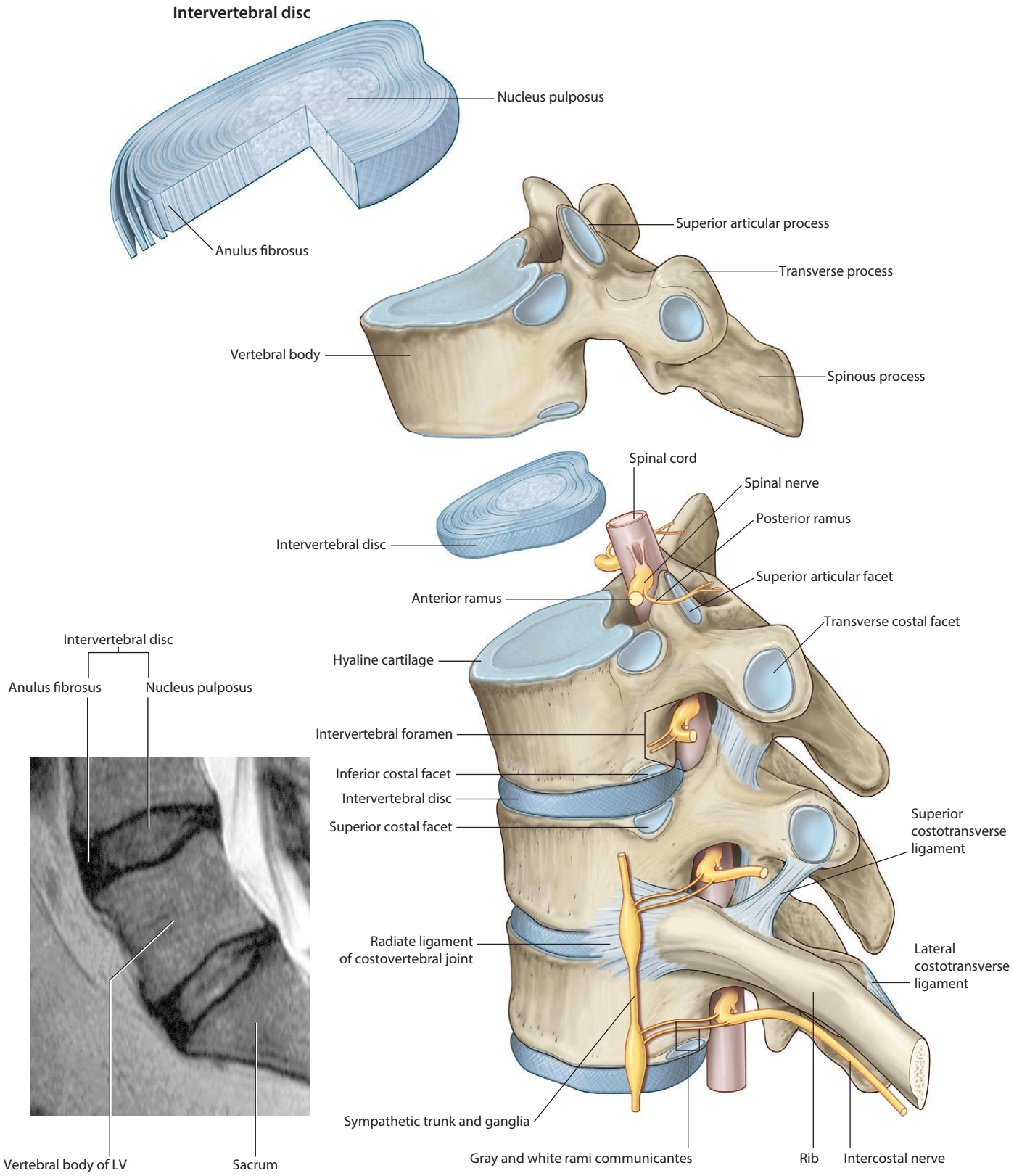

Intervertebral disc in lower lumbar region of vertebral column.
T2-weighted MR image in sagittal plane

Intervertebral foramina and discs in the thoracic region

tahir99-VRG & vip.persianss.ir

Intervertebral disc protrusion in lower lumbar region of vertebral column.
T2-weighted MR image in sagittal plane

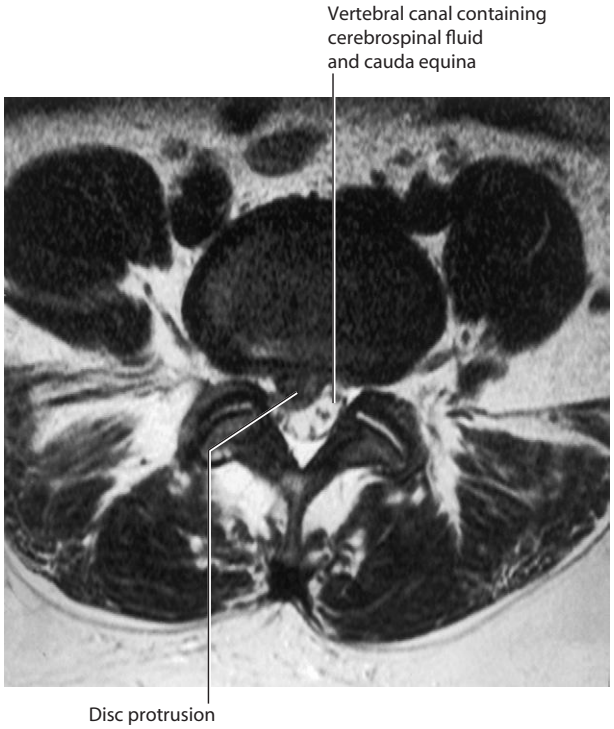

Intervertebral disc protrusion in lower lumbar region of vertebral column.
T2-weighted MR image in axial plane

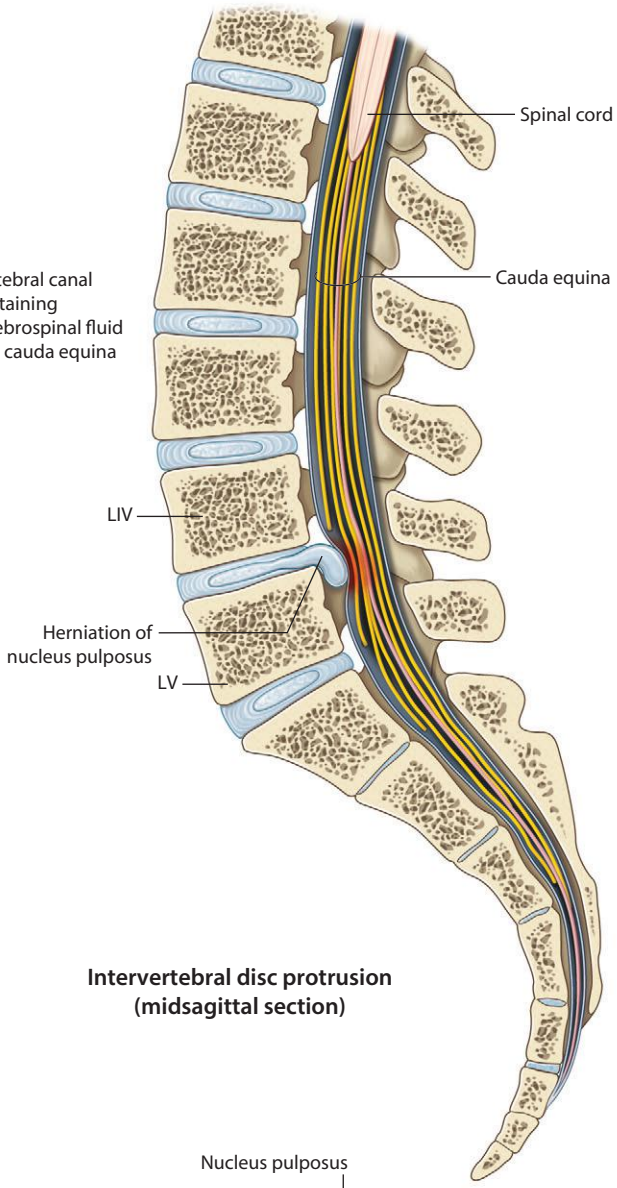

Intervertebral disc protrusion (midsagittal section)

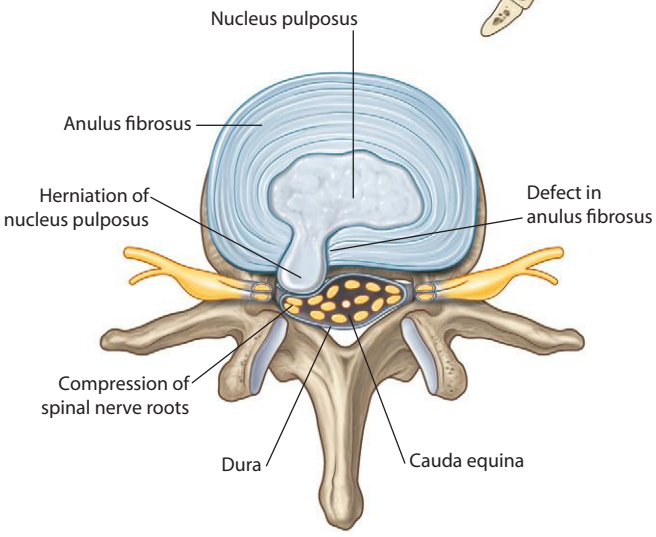

Intervertebral disc protrusion (superior view)

tahir99-VRG & vip.persianss.ir

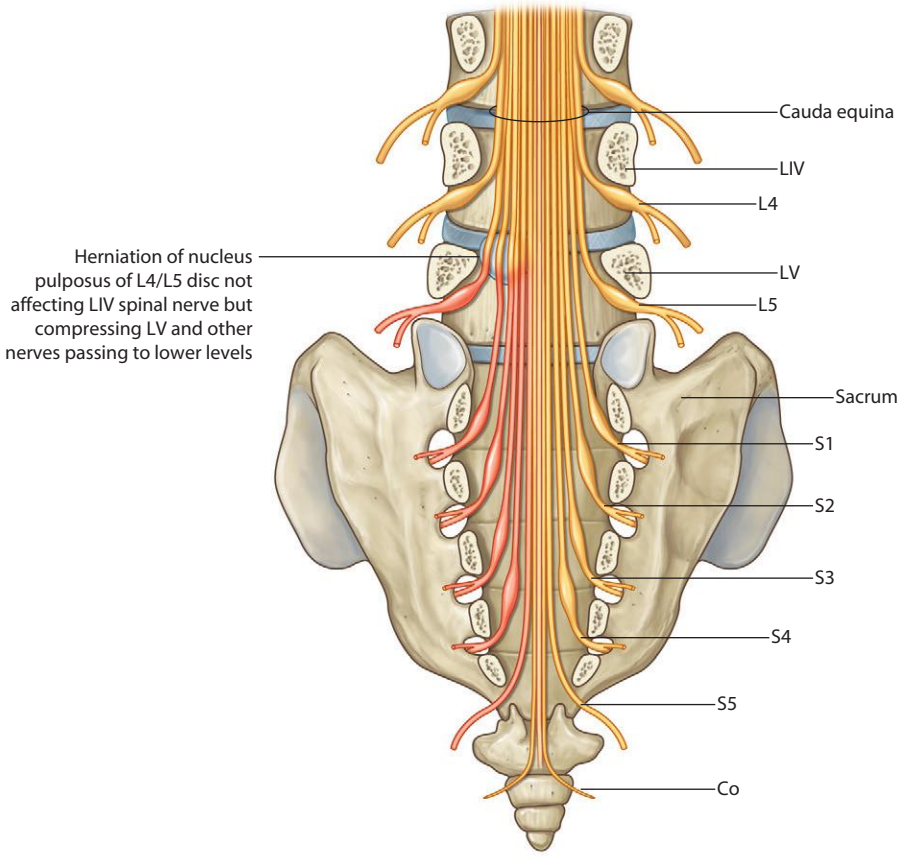

Intervertebral disc protrusion (posterior view)

Nerve root	Main weakness	Reflex decreased	Area of sensory decrease	Disc involved
C5	Deltoid (biceps)	(biceps, pectoralis)	Shoulder, upper lateral arm	C4–C5
C6	Wrist extension	(biceps, brachioradialis)	1st and 2nd digits (lateral forearm)	C5–C6
C7	Triceps	Triceps	Third finger	C6–C7
C8	Intrinsic hand muscles		4th and 5th digits (medial forearm)	C7–T1

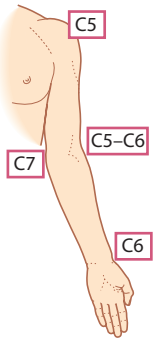

Clinically important nerve roots in the upper limb

Nerve root	Main weakness	Reflex decreased	Area of sensory decrease	Disc involved
L4	Iliopsoas and quadriceps	Patellar tendon (knee jerk)	Knee, medial lower leg	L3–L4
L5	Dorsiflexion of foot at ankle (big toe extension, foot eversion and inversion)		Dorsum of foot, big toe	L4–L5
S1	Plantar flexion of foot at ankle	Achilles tendon (ankle jerk)	Lateral foot, small toe, sole	L5–S1

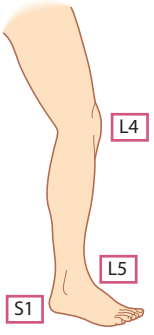

Clinically important nerve roots in the lower limb

tahir99-VRG & vip.persianss.ir

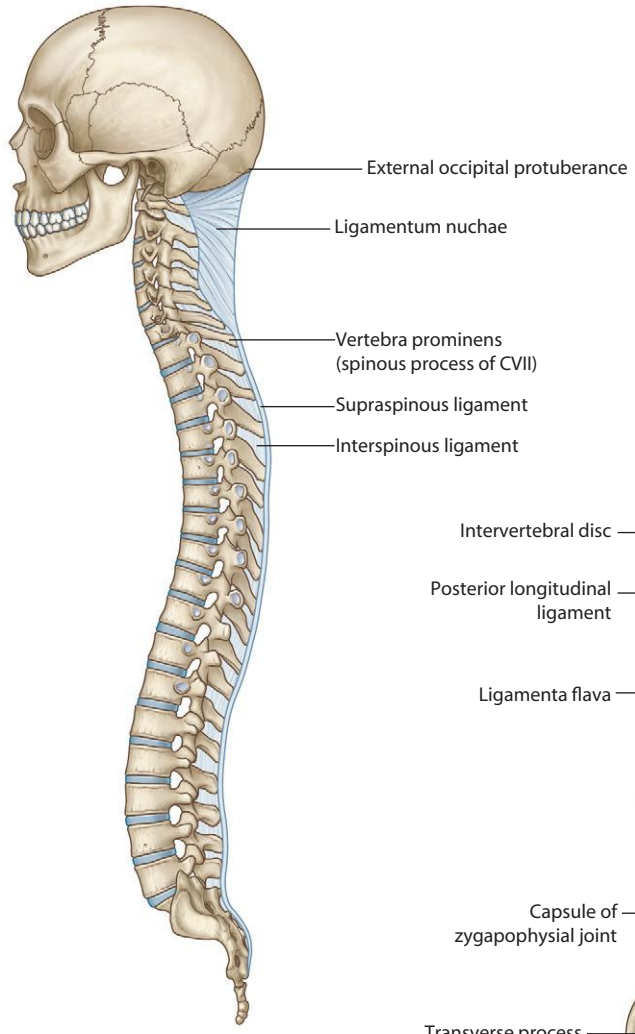

Ligamentum nuchae and supraspinous ligament (lateral view)

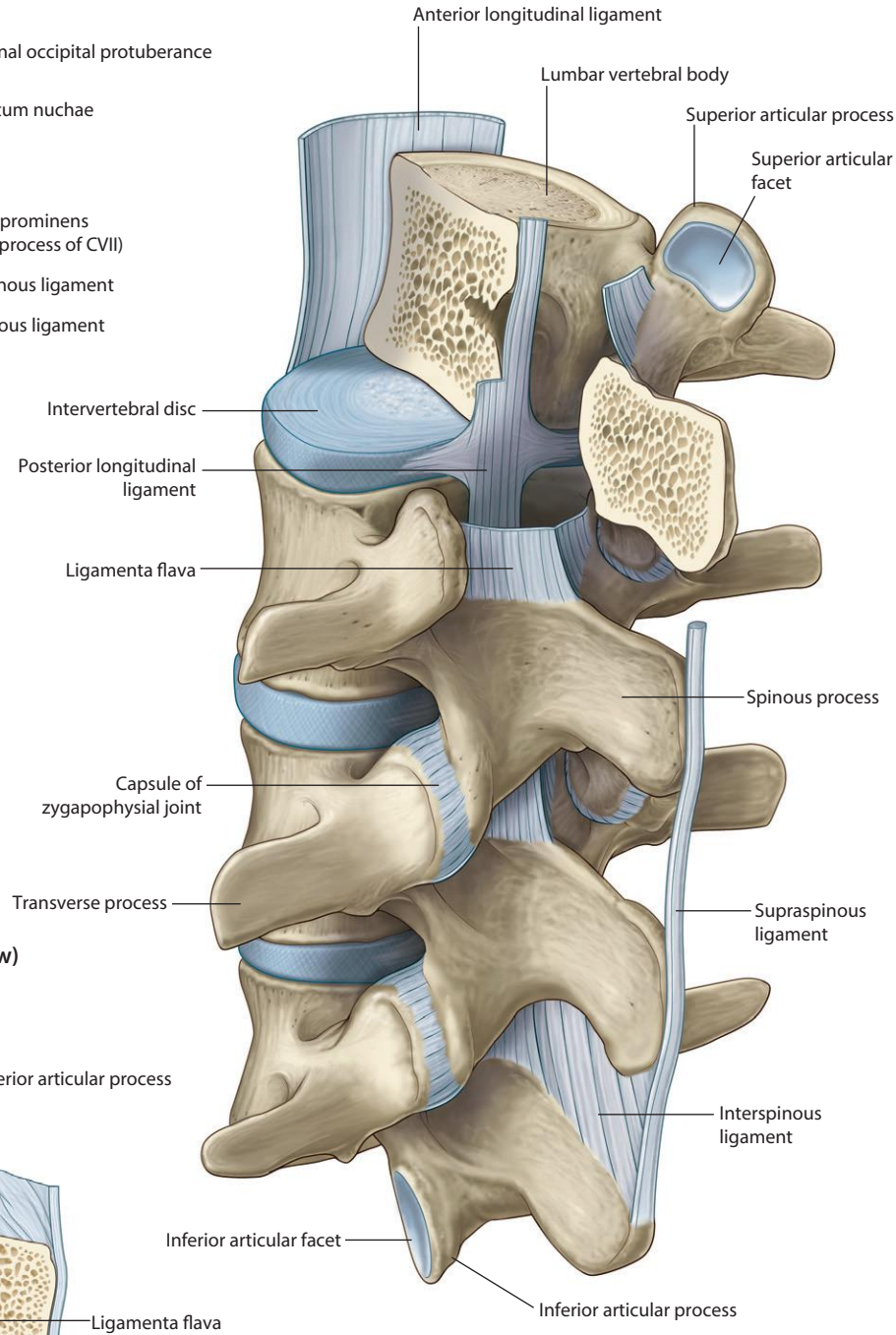

Vertebral ligaments of the lumbar region (posterior oblique view)

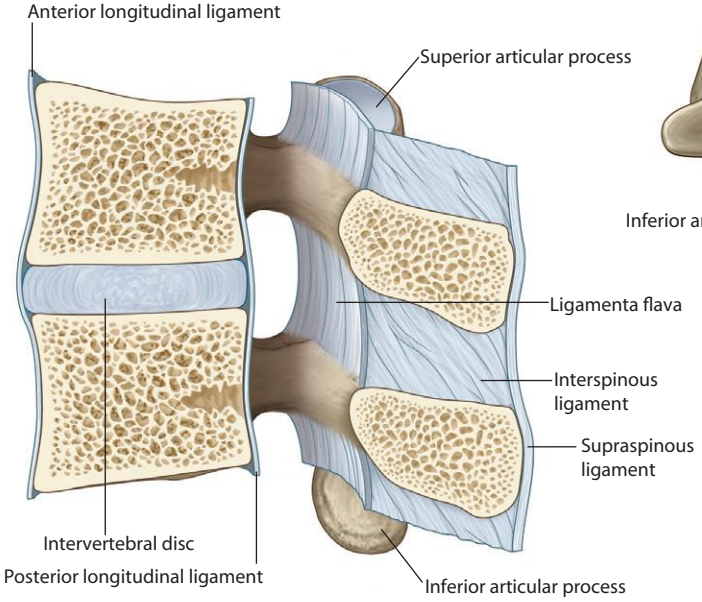

Ligamenta flava

tahir99-VRG & vip.persianss.ir

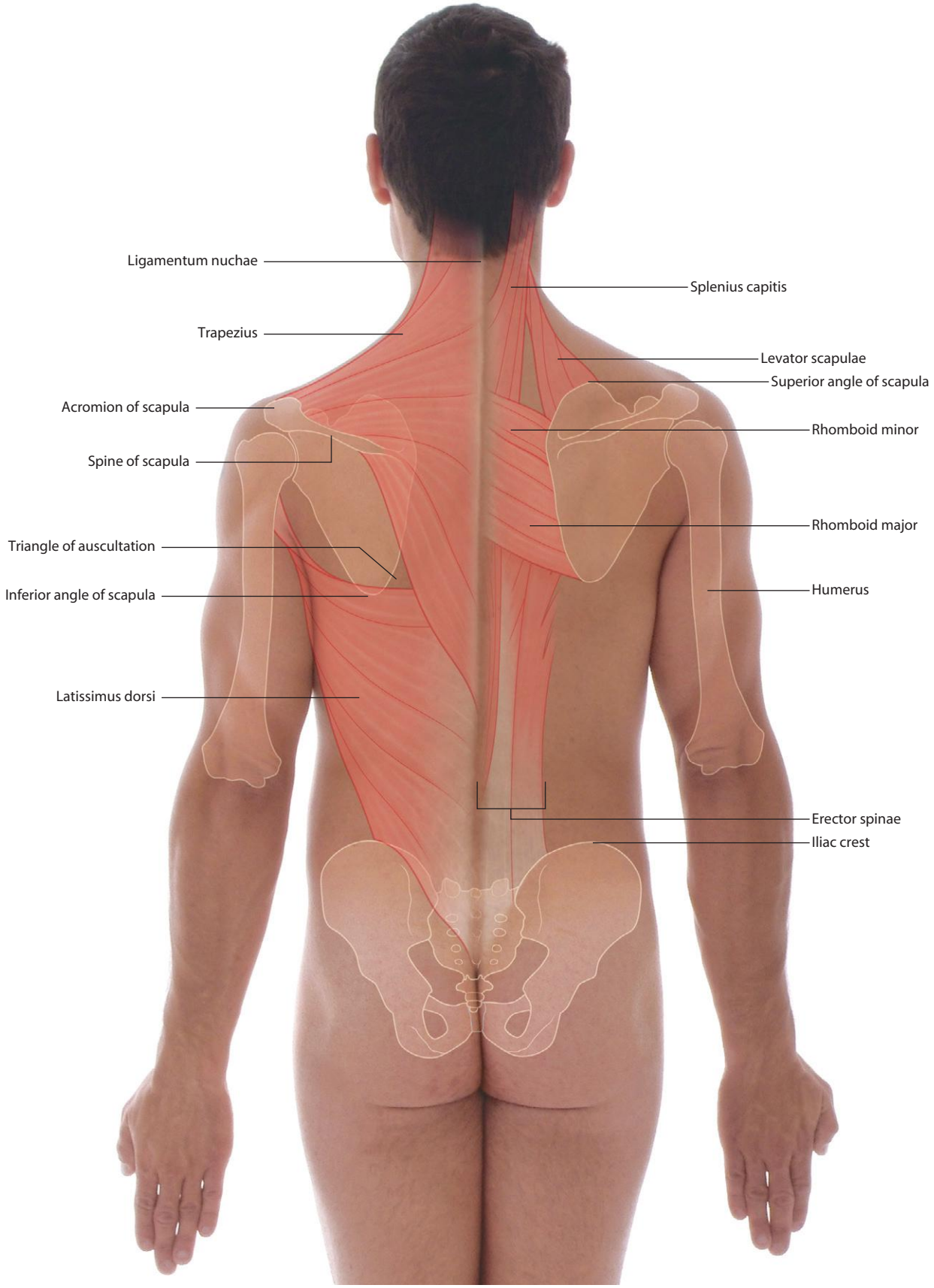

Posterior view of male showing surface projections of back muscles

tahir99-VRG & vip.persianss.ir

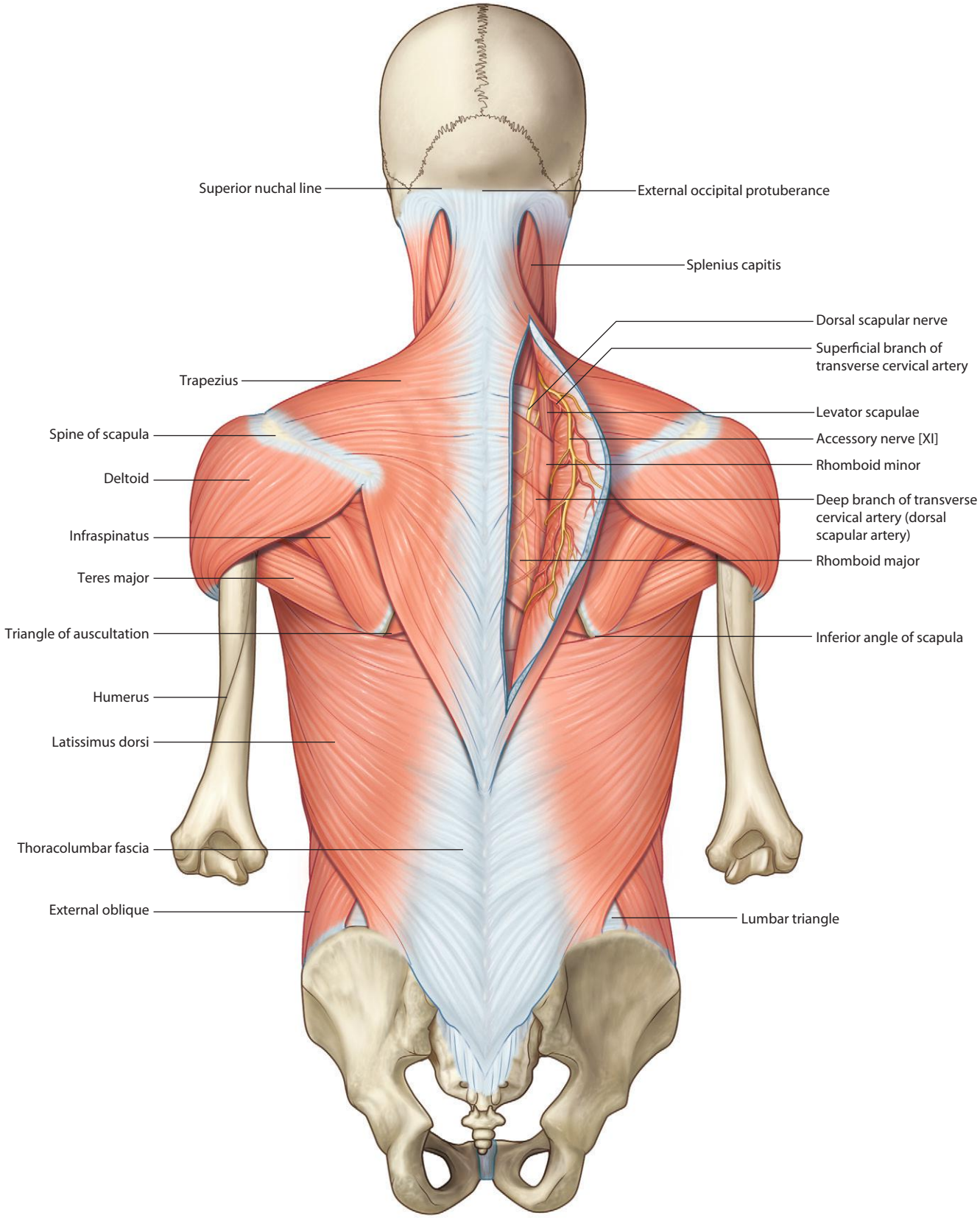

Superficial musculature – trapezius and latissimus dorsi

tahir99-VRG & vip.persianss.ir

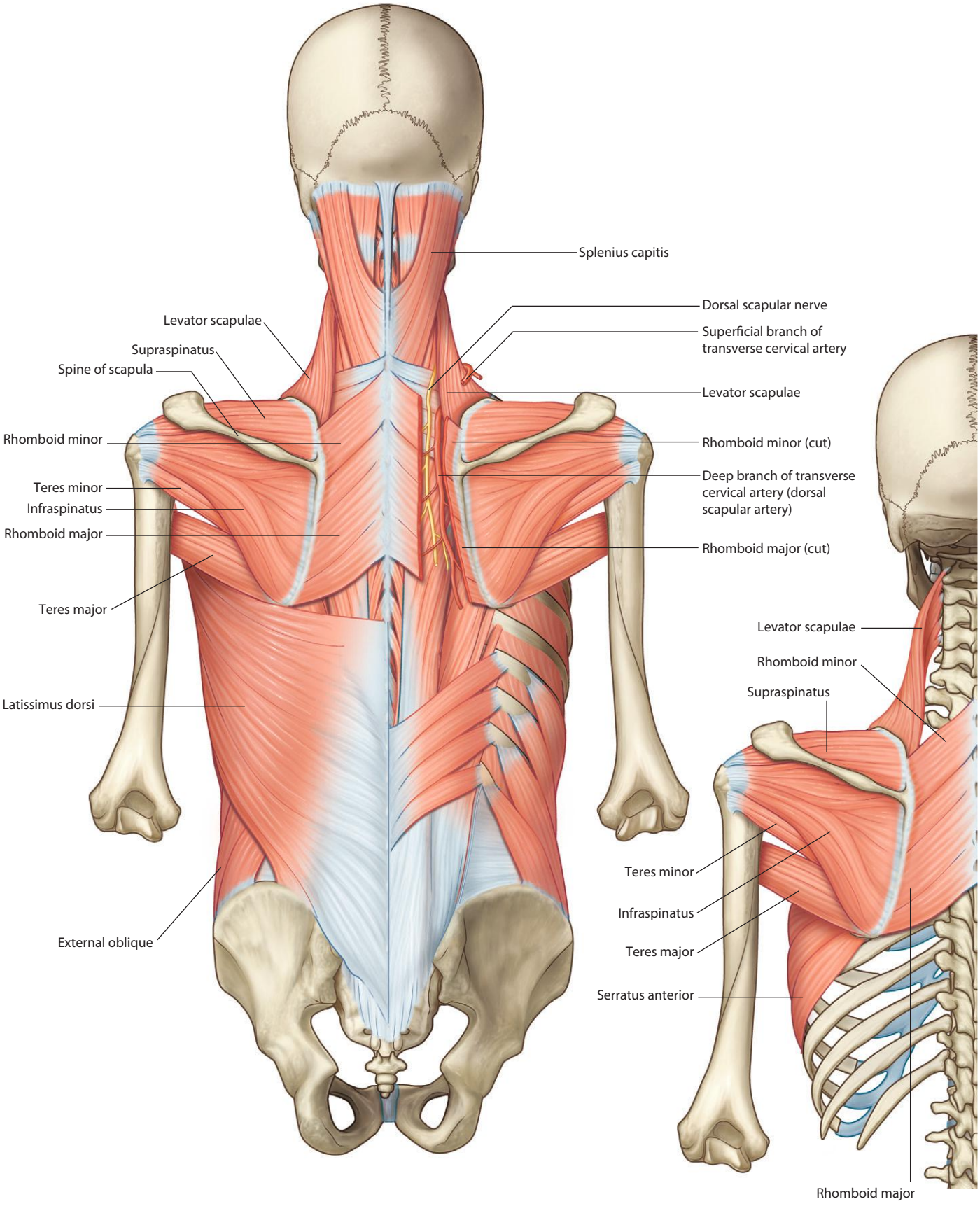

Superficial musculature – levator scapulae and rhomboid major and minor

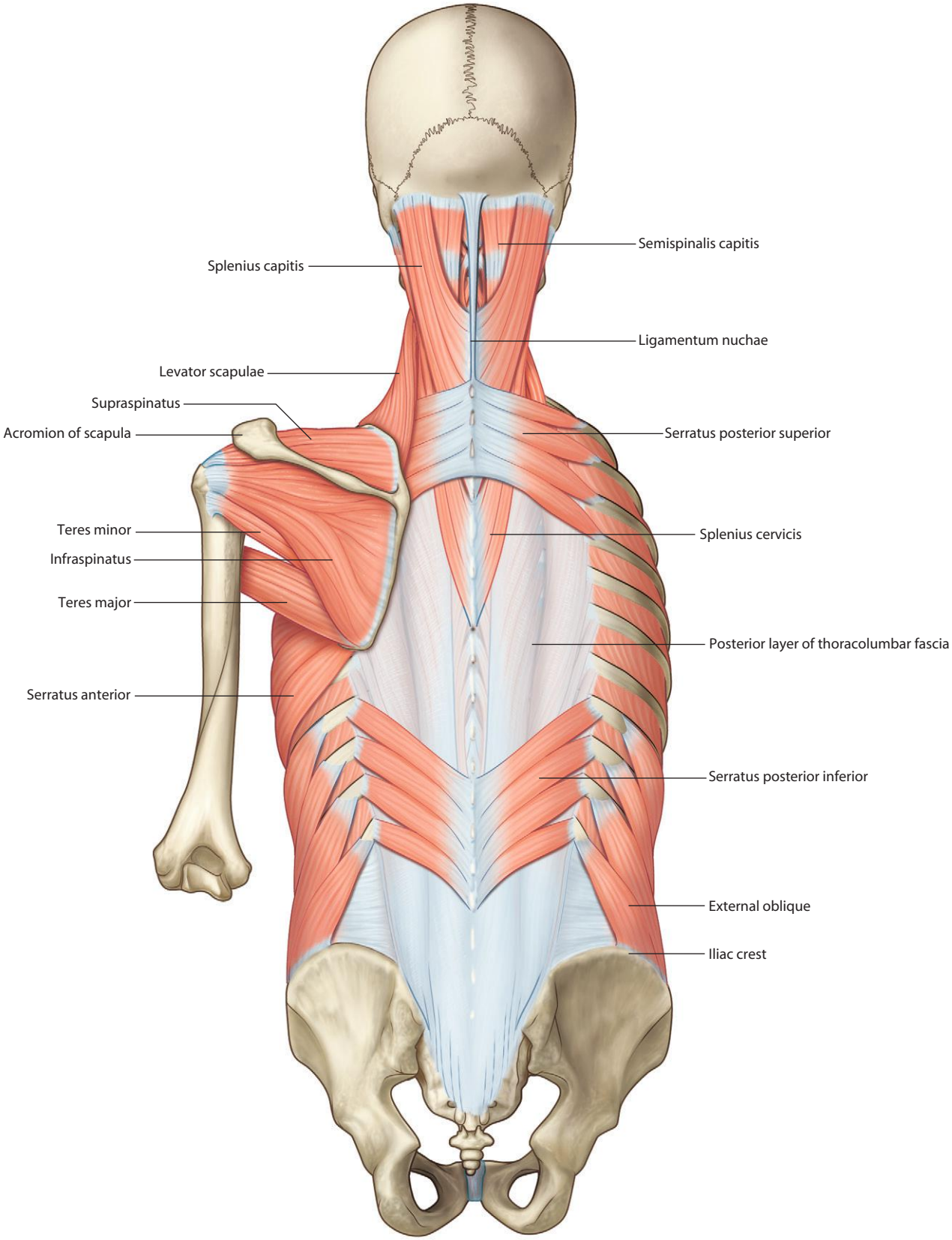

Intermediate musculature

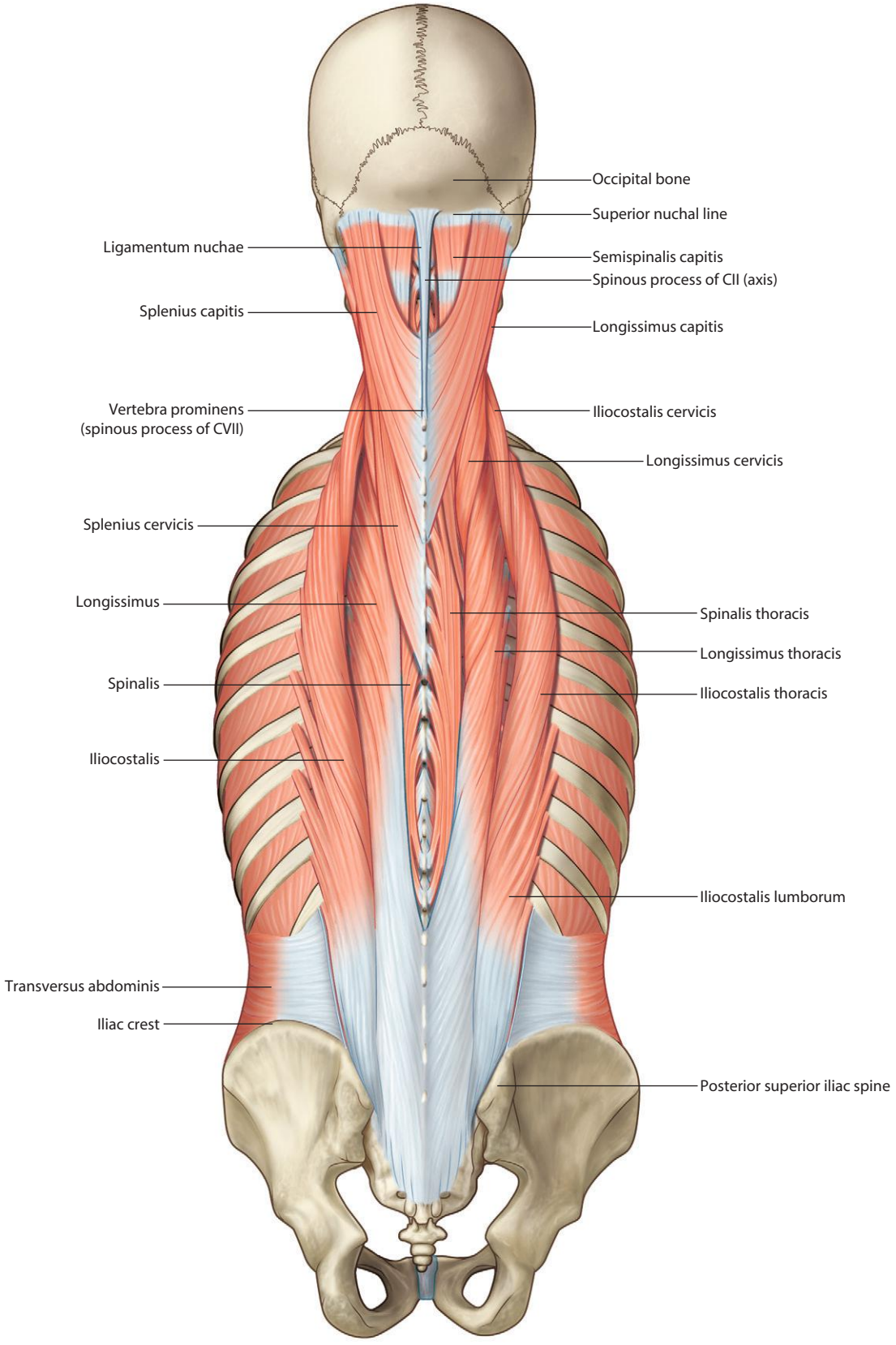

Deep group of back muscles – erector spinae muscles

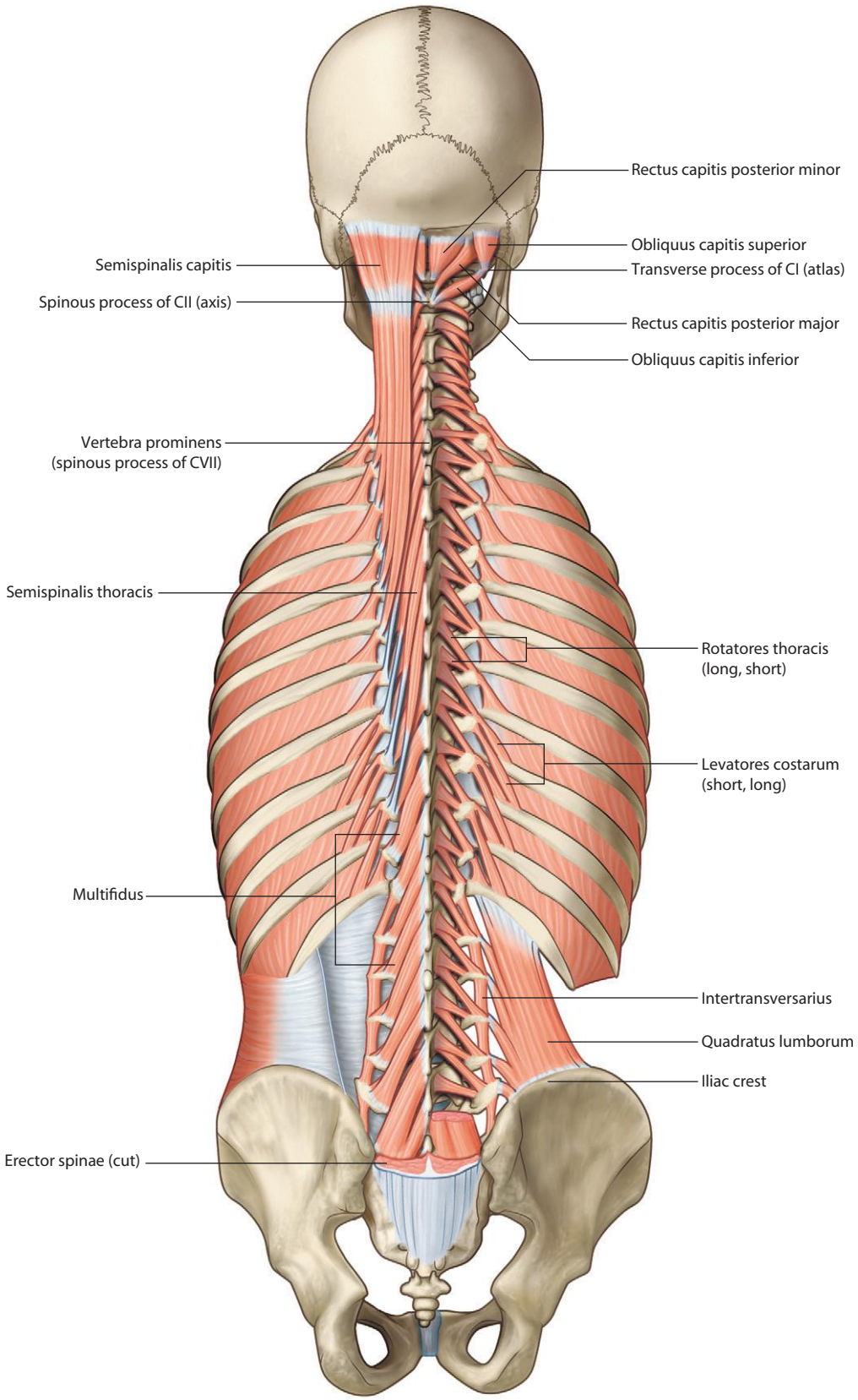

Deep group of back muscles – transversospinales and segmental muscles

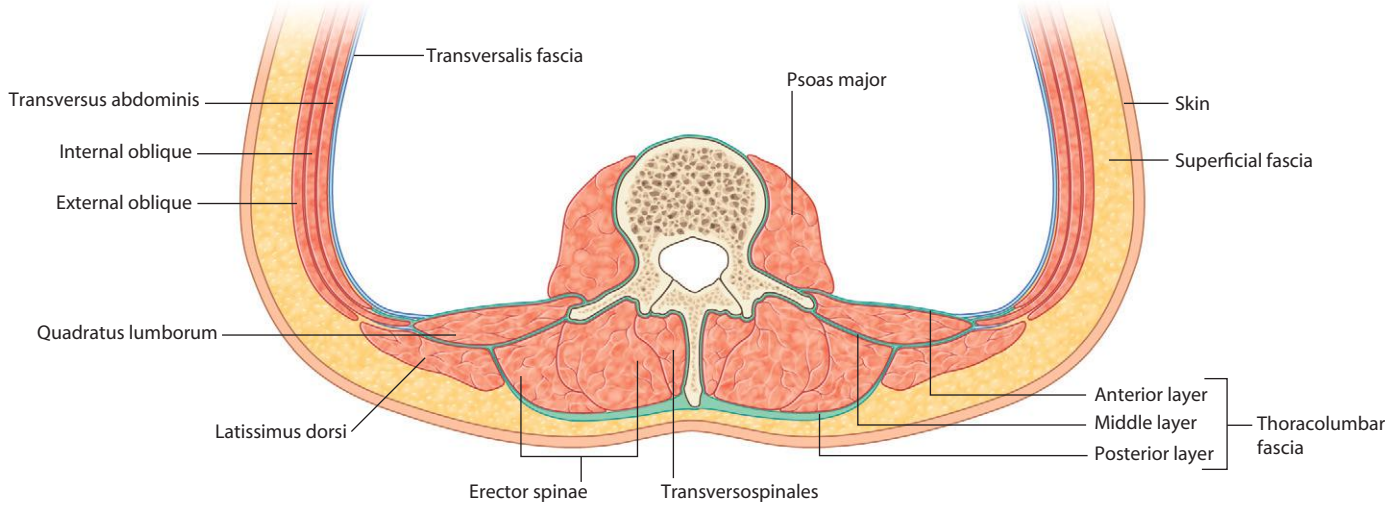

Thoracolumbar fascia and the deep back muscles (transverse section – lumbar region)

Lumbar region (LIII) showing back musculature.
CT image in axial plane

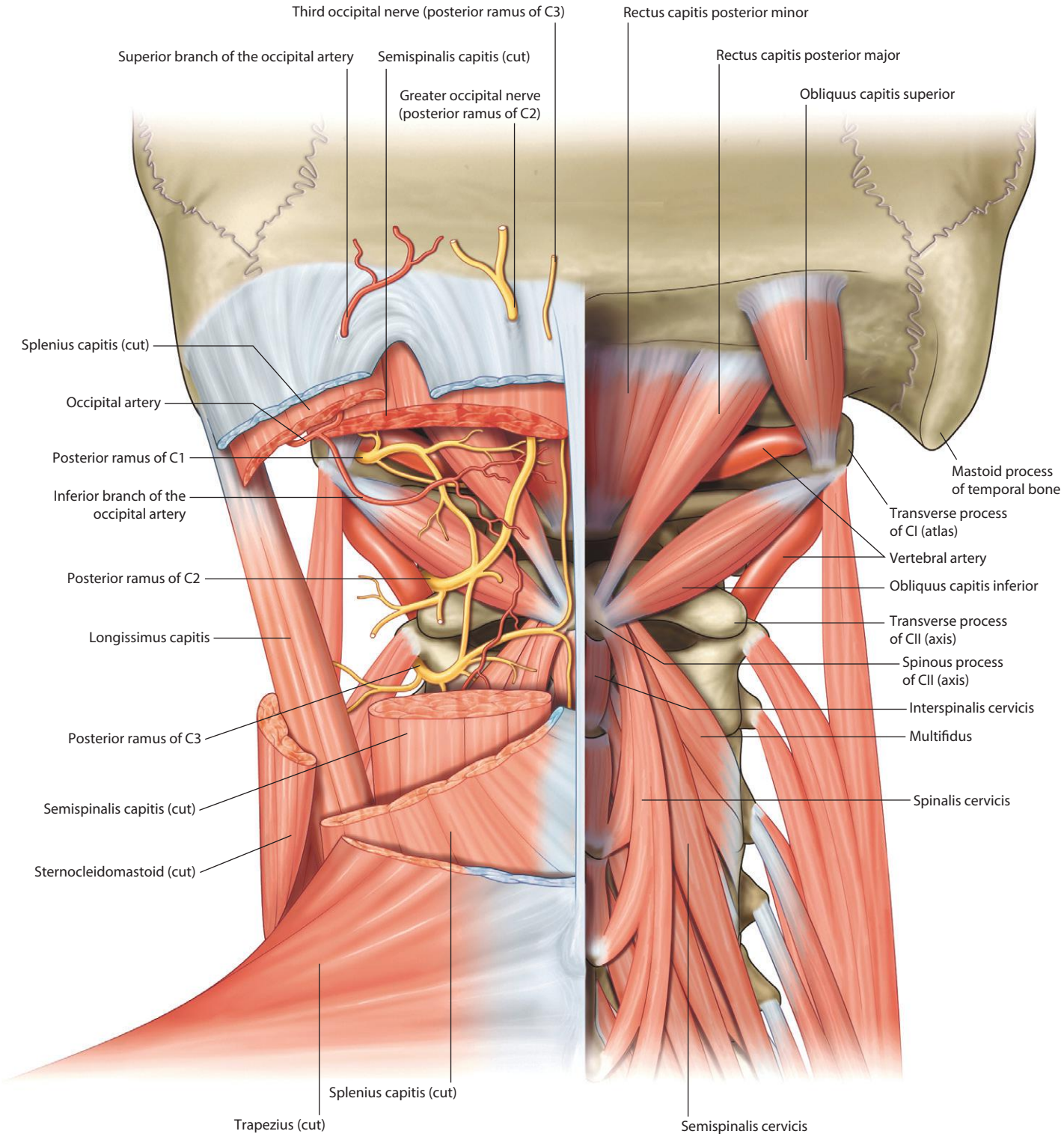

Suboccipital region

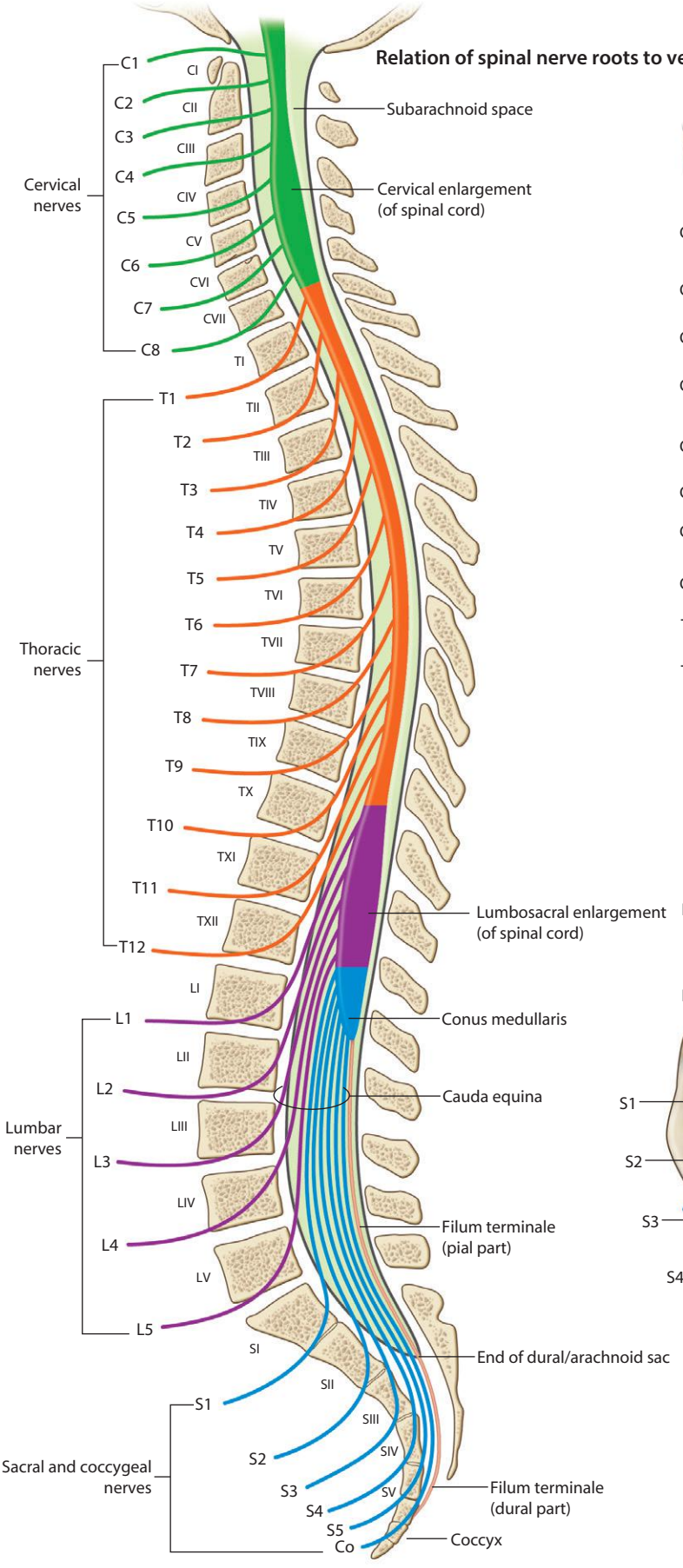

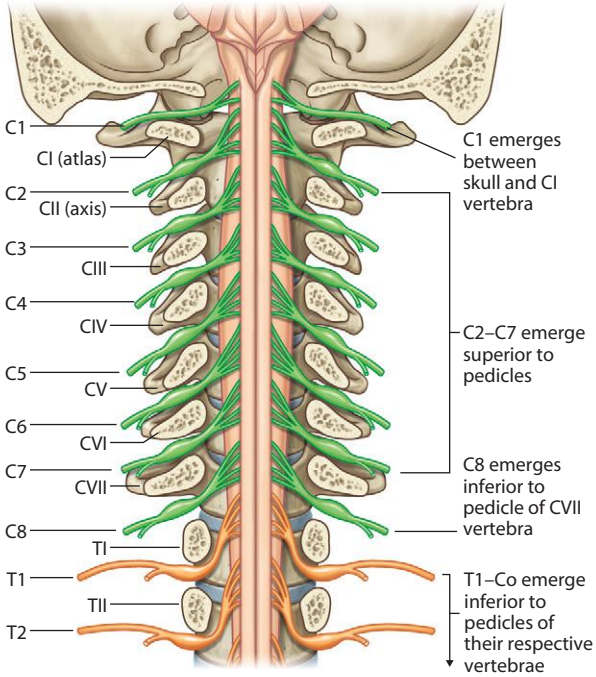

Nomenclature of spinal nerves (posterior view)

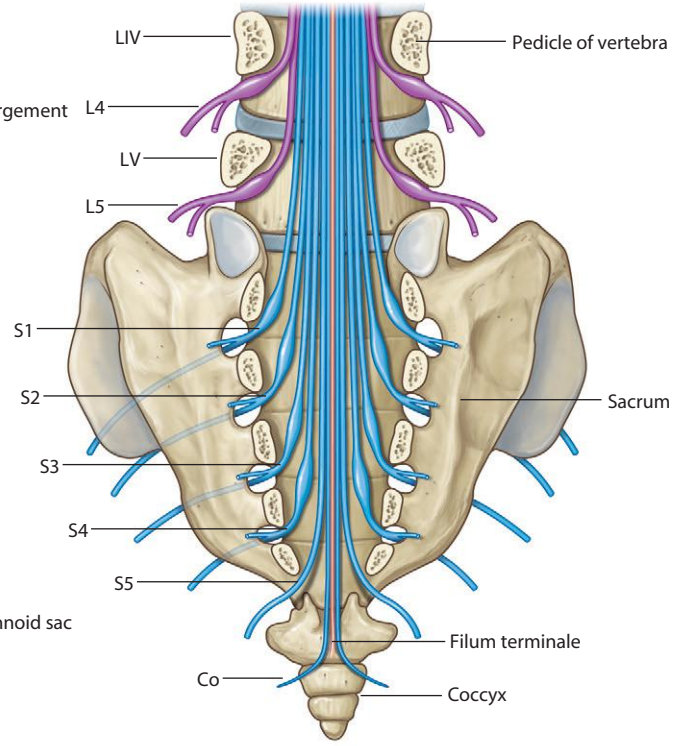

Sacral and coccygeal nerves (posterior view – vertebral arches removed)

Spinal cord and spinal nerves in vertebral canal

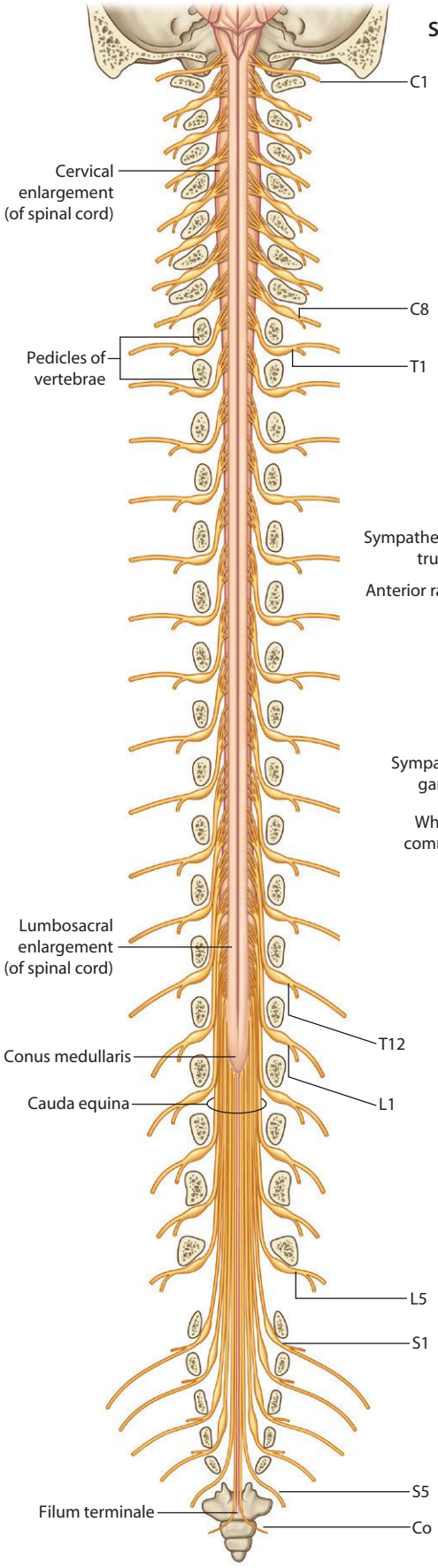

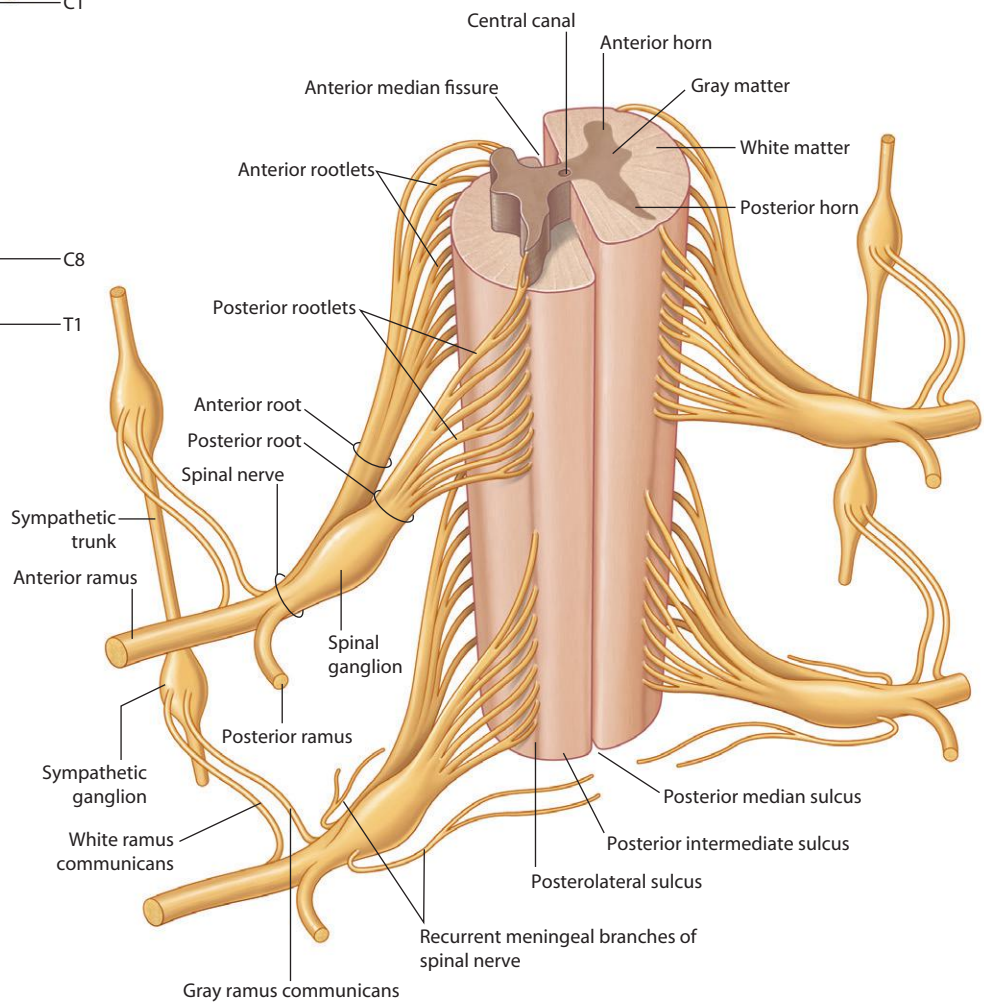

Features of the spinal cord (thoracic region) and basic organization of a spinal nerve (posterior view)

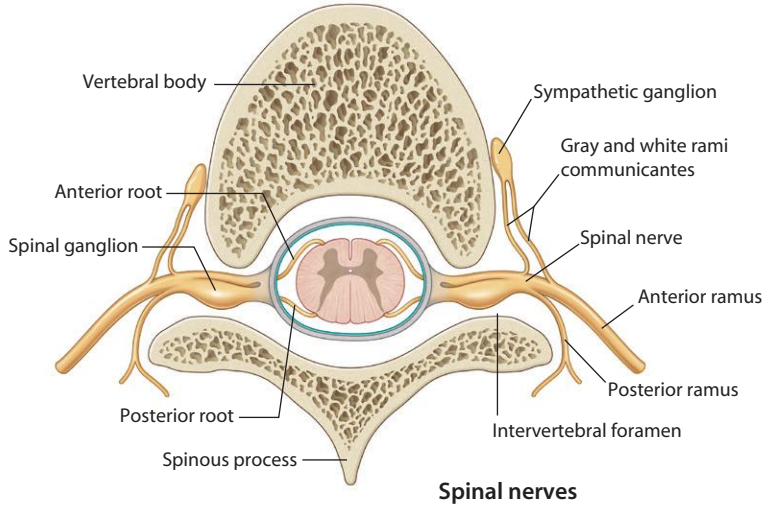

Spinal nerves (transverse section)

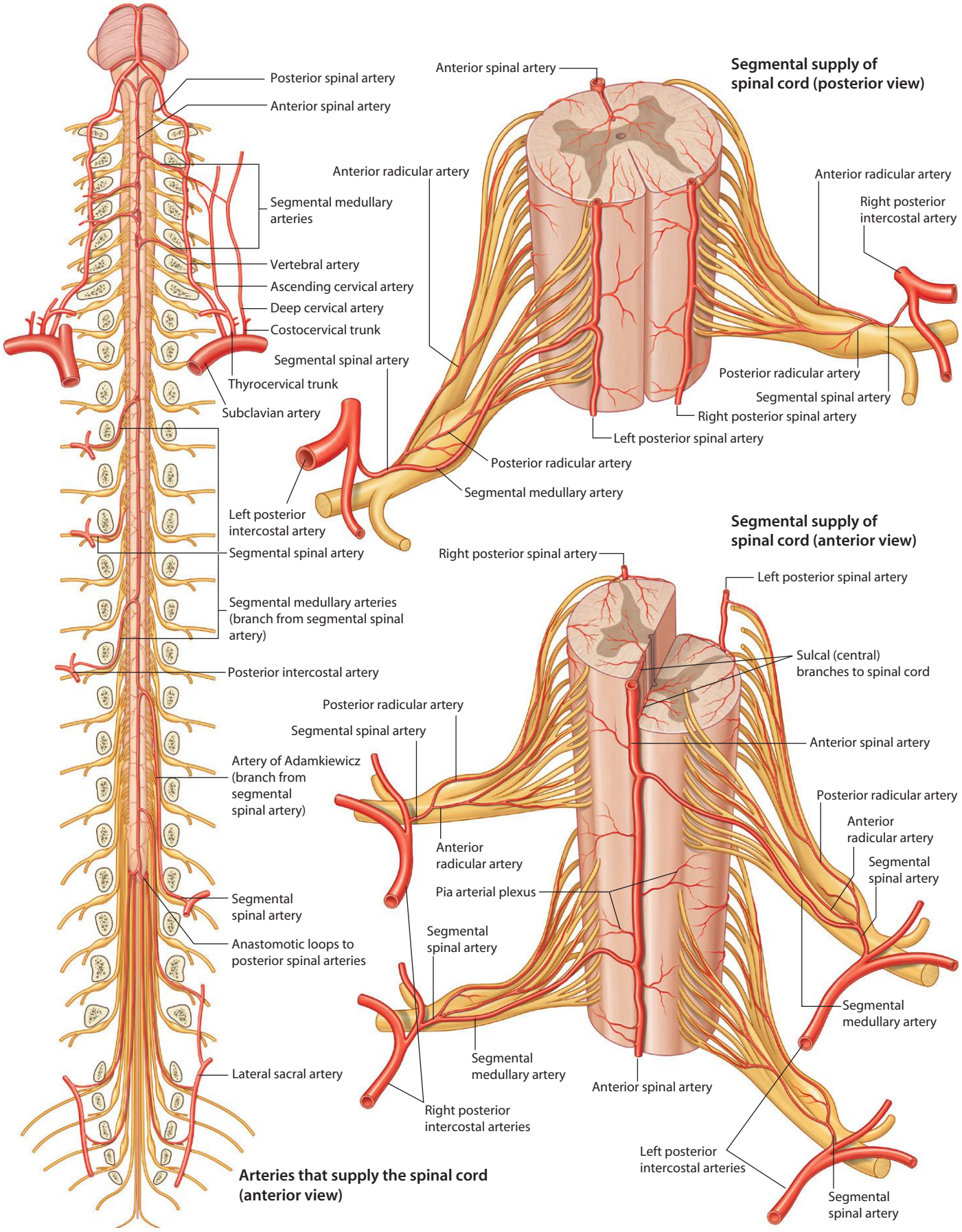
Posterior spinal artery
Anterior spinal artery
Segmental medullary arteries
Vertebral artery
Ascending cervical artery
Deep cervical artery
Costocervical trunk
Thyrocervical trunk
Subclavian artery
Segmental spinal artery
Left posterior intercostal artery
Segmental spinal artery
Segmental medullary arteries (branch from segmental spinal artery)
Posterior intercostal artery
Artery of Adamkiewicz (branch from segmental spinal artery)
Segmental spinal artery
Anastomotic loops to posterior spinal arteries
Lateral sacral artery
Arteries that supply the spinal cord (anterior view)
Anterior spinal artery
Anterior radicular artery
Segmental spinal artery
Posterior radicular artery
Segmental medullary artery
Segmental supply of spinal cord (posterior view)
Anterior radicular artery
Right posterior intercostal artery
Posterior radicular artery
Segmental spinal artery
Right posterior spinal artery
Left posterior spinal artery
Right posterior spinal artery
Left posterior spinal artery
Segmental supply of spinal cord (anterior view)
Sulcal (central) branches to spinal cord
Posterior radicular artery
Segmental spinal artery
Anterior spinal artery
Anterior radicular artery
Pia arterial plexus
Posterior radicular artery
Anterior radicular artery
Segmental spinal artery
Segmental spinal artery
Segmental medullary artery
Segmental medullary artery
Anterior spinal artery
Right posterior intercostal arteries
Left posterior intercostal arteries
Segmental spinal artery

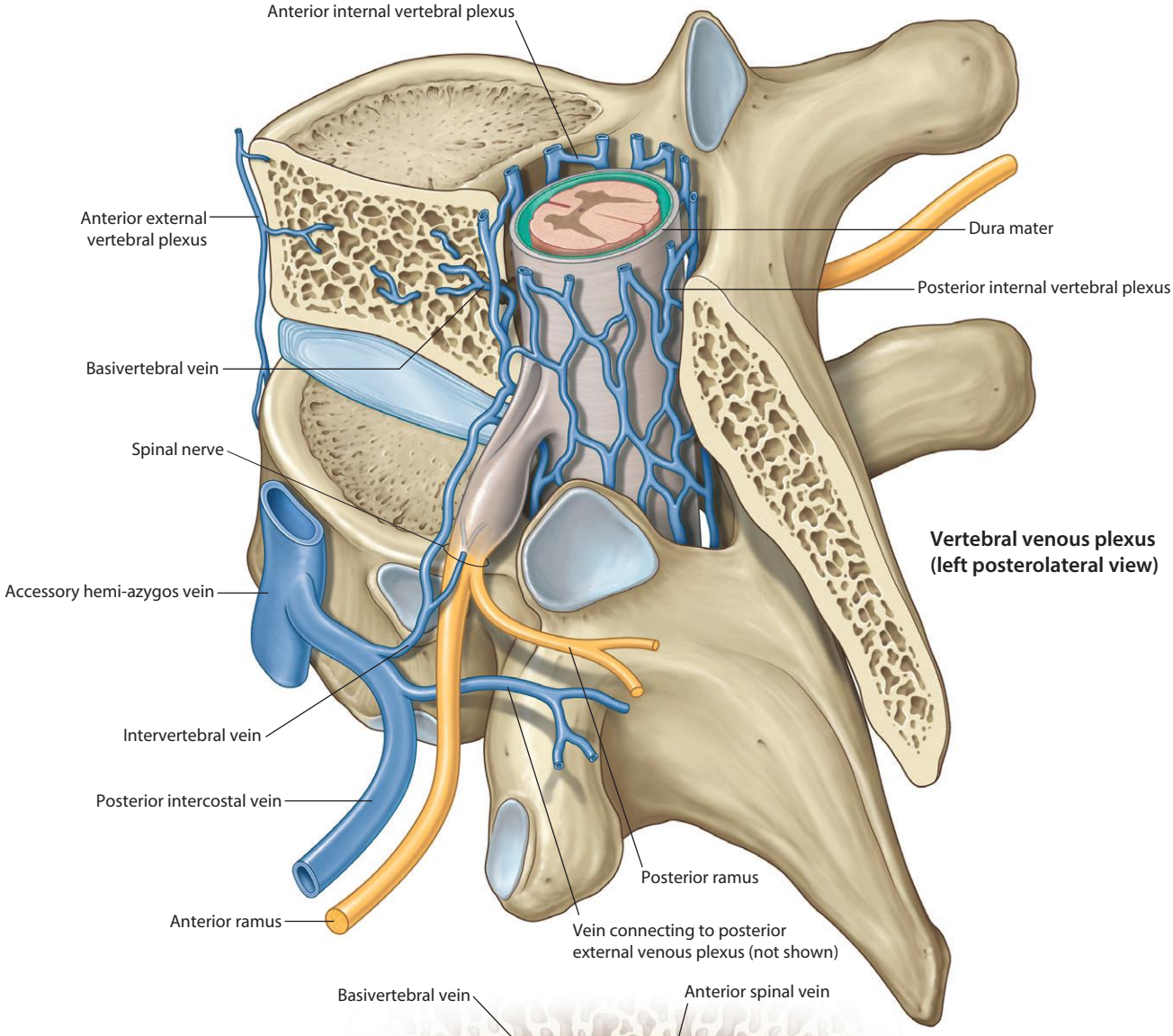

Vertebral venous plexus (left posterolateral view)

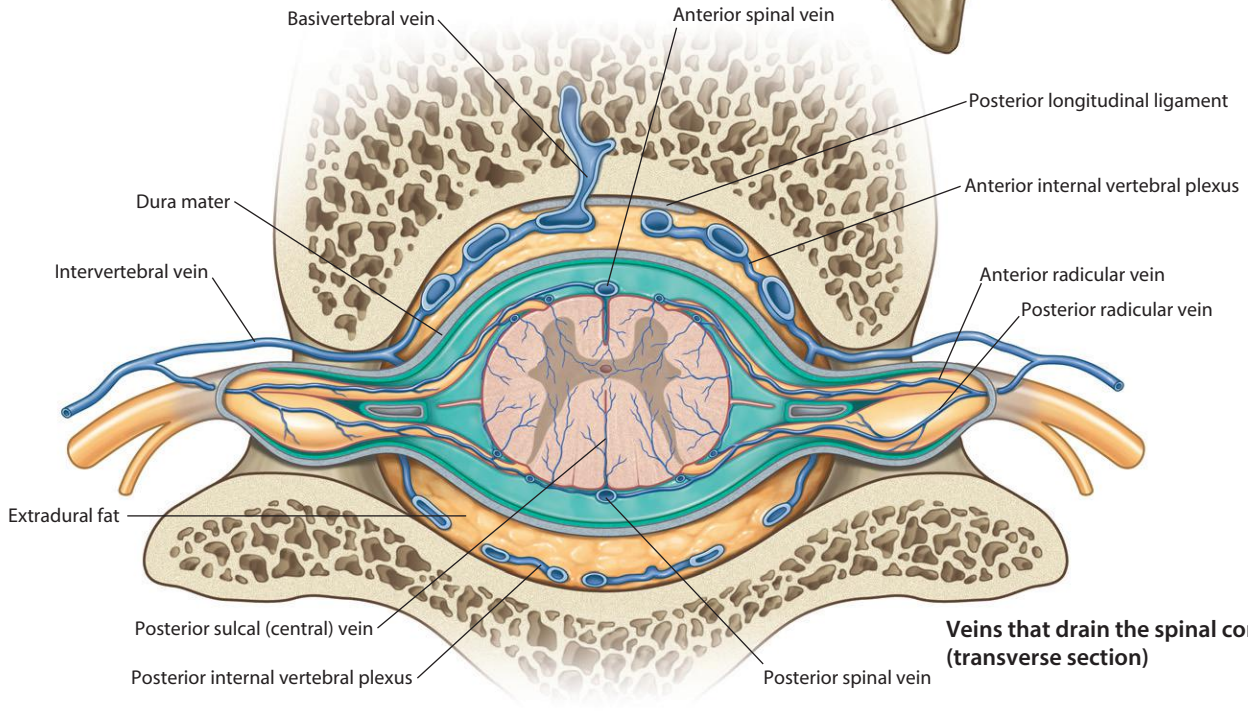

Veins that drain the spinal cord (transverse section)

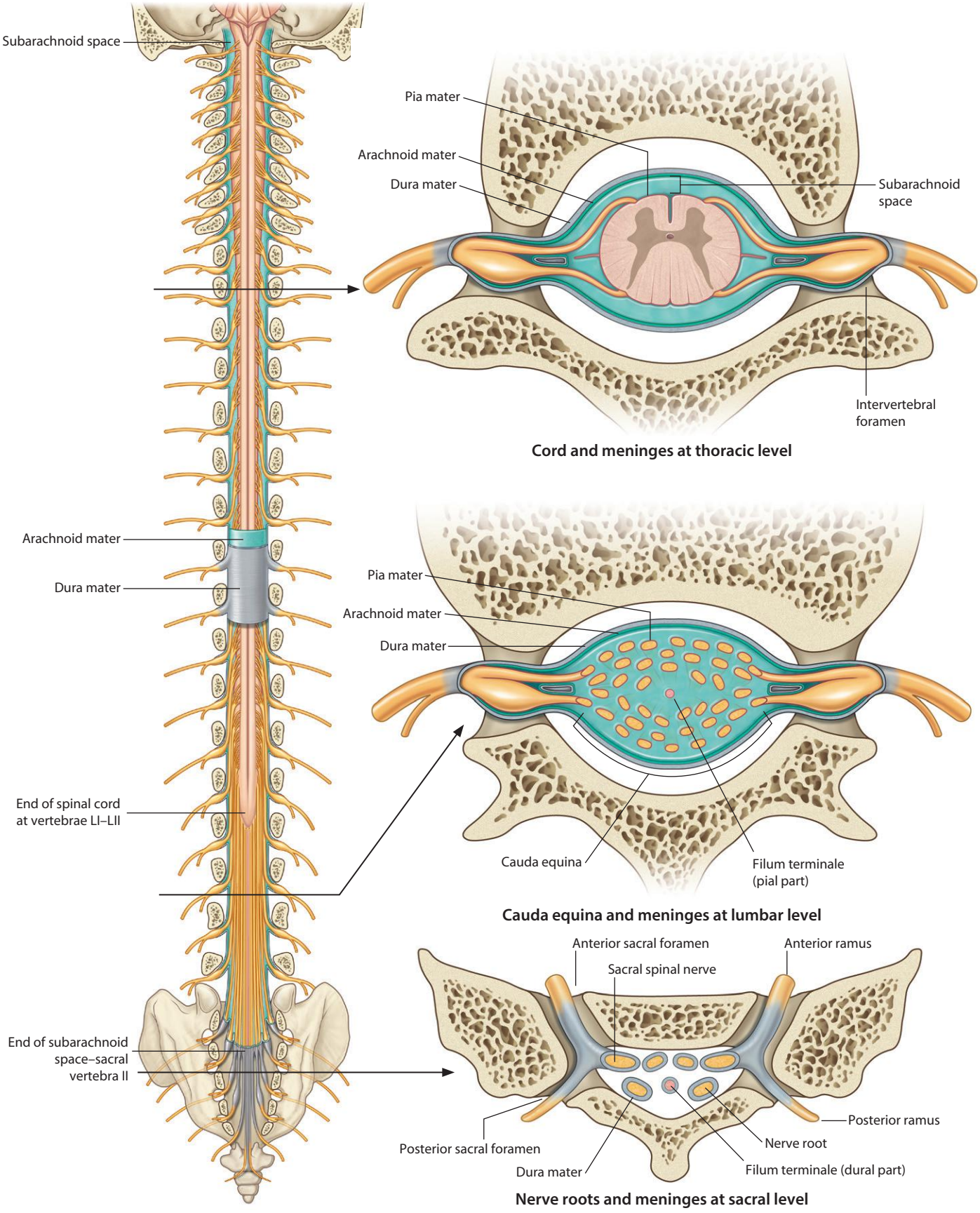
Subarachnoid space
Arachnoid mater
Dura mater
End of spinal cord at vertebrae LI–LII
End of subarachnoid space–sacral vertebra II
Pia mater
Arachnoid mater
Dura mater
Subarachnoid space
Intervertebral foramen
Cord and meninges at thoracic level
Pia mater
Arachnoid mater
Dura mater
Cauda equina
Filum terminale (pial part)
Cauda equina and meninges at lumbar level
Anterior sacral foramen
Sacral spinal nerve
Anterior ramus
Posterior ramus
Nerve root
Filum terminale (dural part)
Posterior sacral foramen
Dura mater
Nerve roots and meninges at sacral level

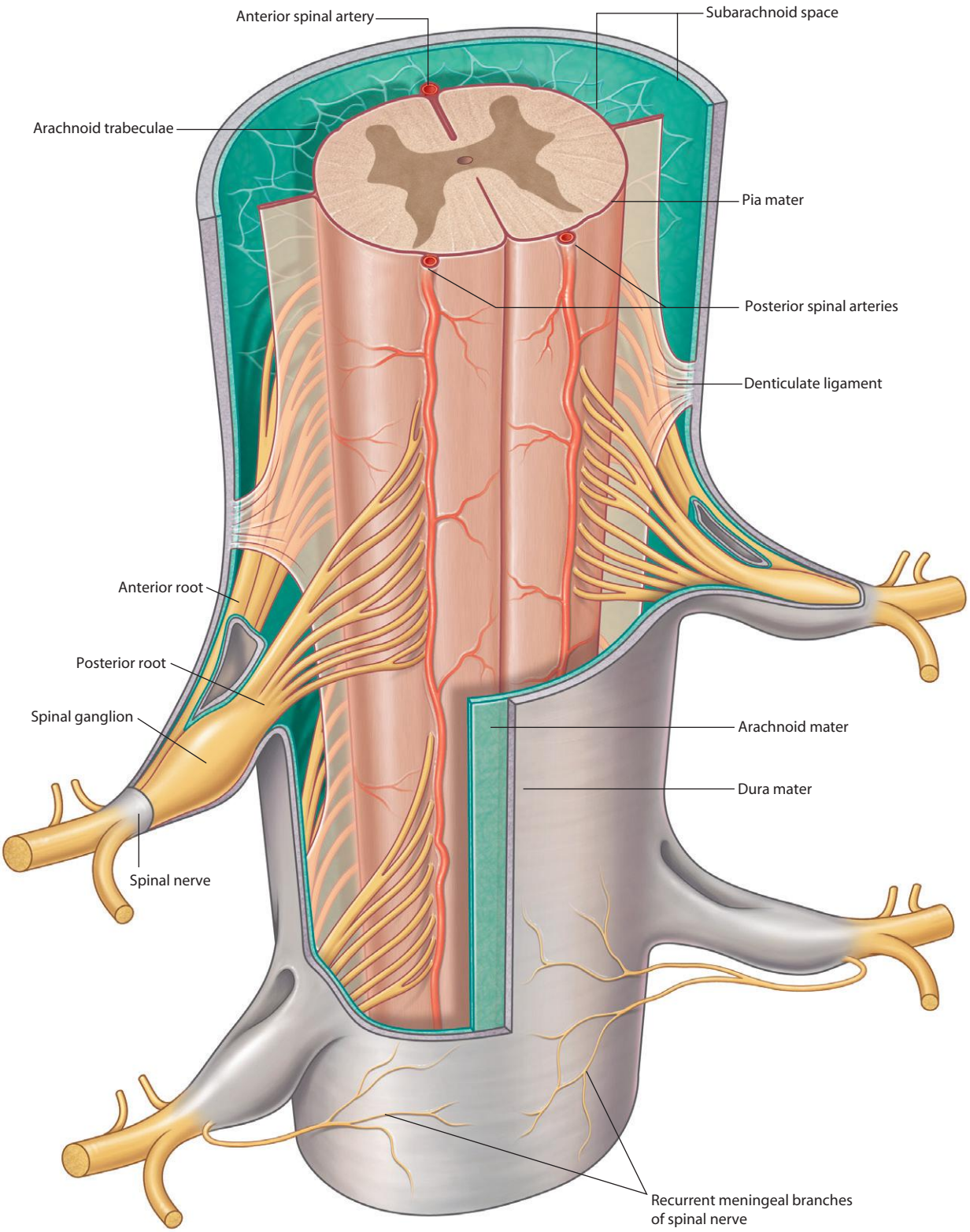

Meninges covering parts of the thoracic region of the spinal cord (posterior view)

Cervical and upper thoracic vertebral column showing upper and middle portions of spinal cord.
T2-weighted MR image in sagittal plane

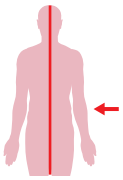

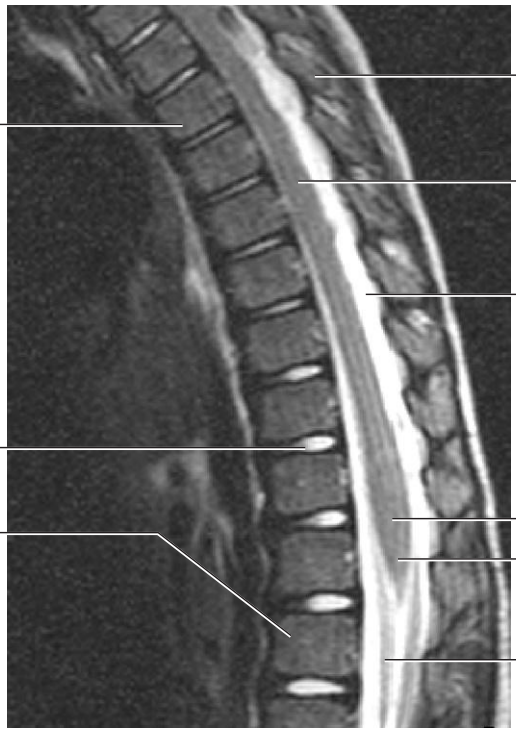

Thoracic and upper lumbar vertebral column showing middle and lower portions of spinal cord and its termination.
T2-weighted MR image in sagittal plane

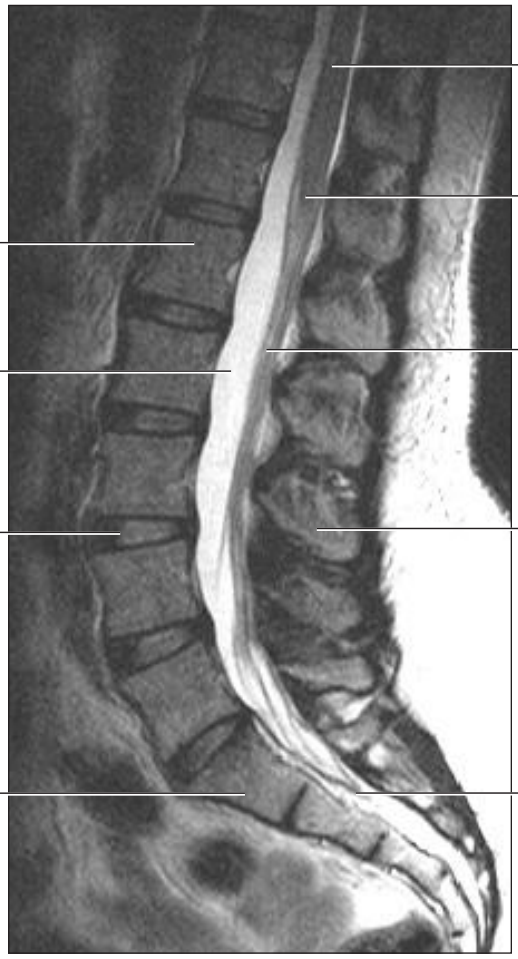

Lumbar and sacral vertebral column showing termination of spinal cord and continuation and termination of dural/arachnoid sac.
T2-weighted MR image in sagittal plane

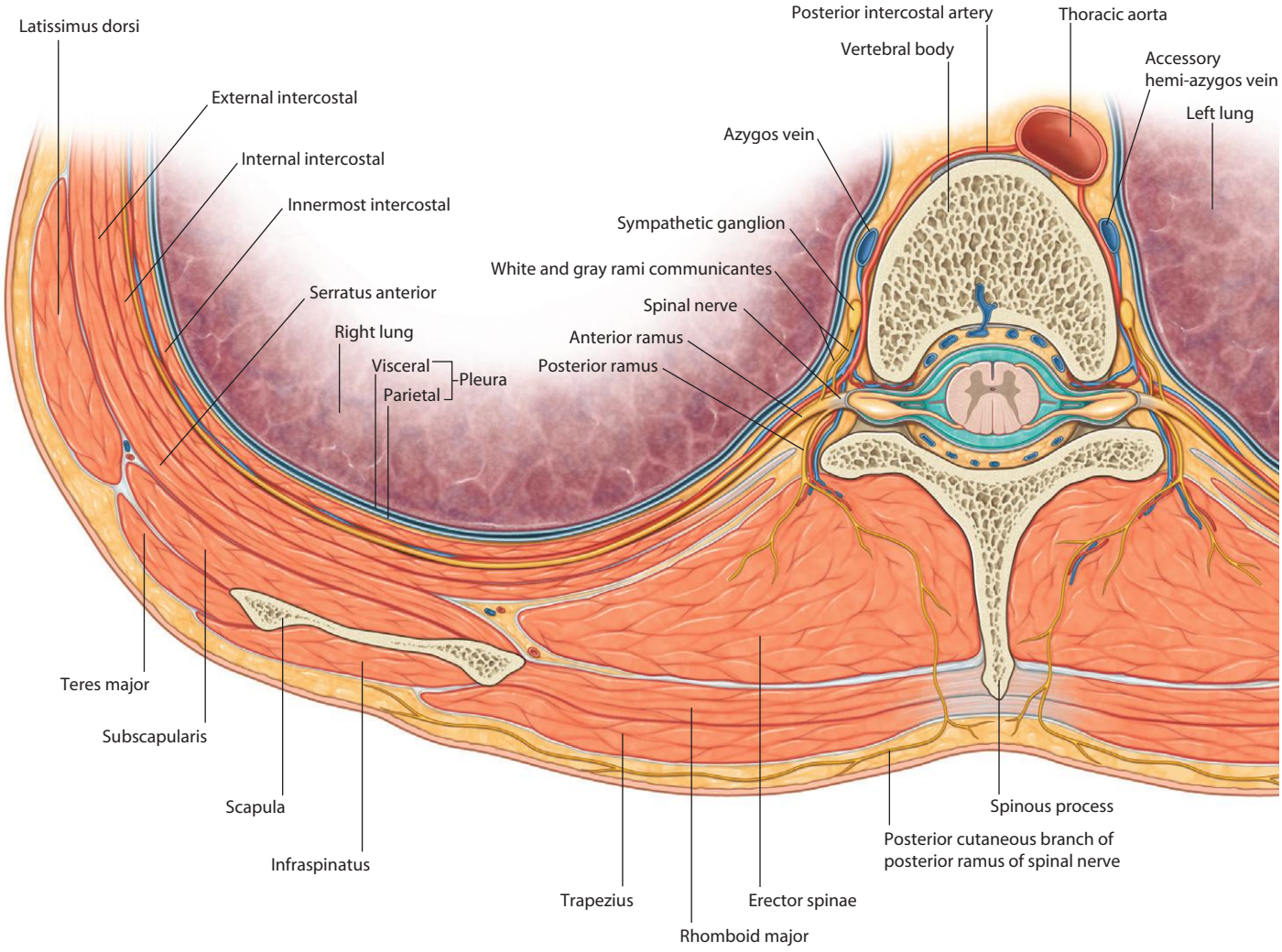

Transverse section through thoracic region of vertebral column

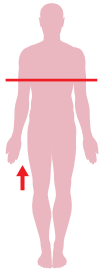

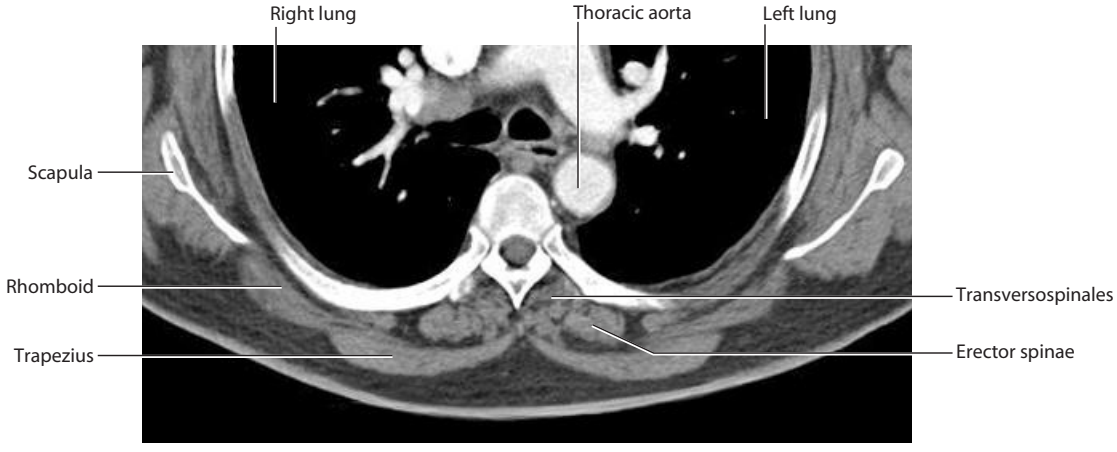

Thoracic region of back.
CT image in axial plane

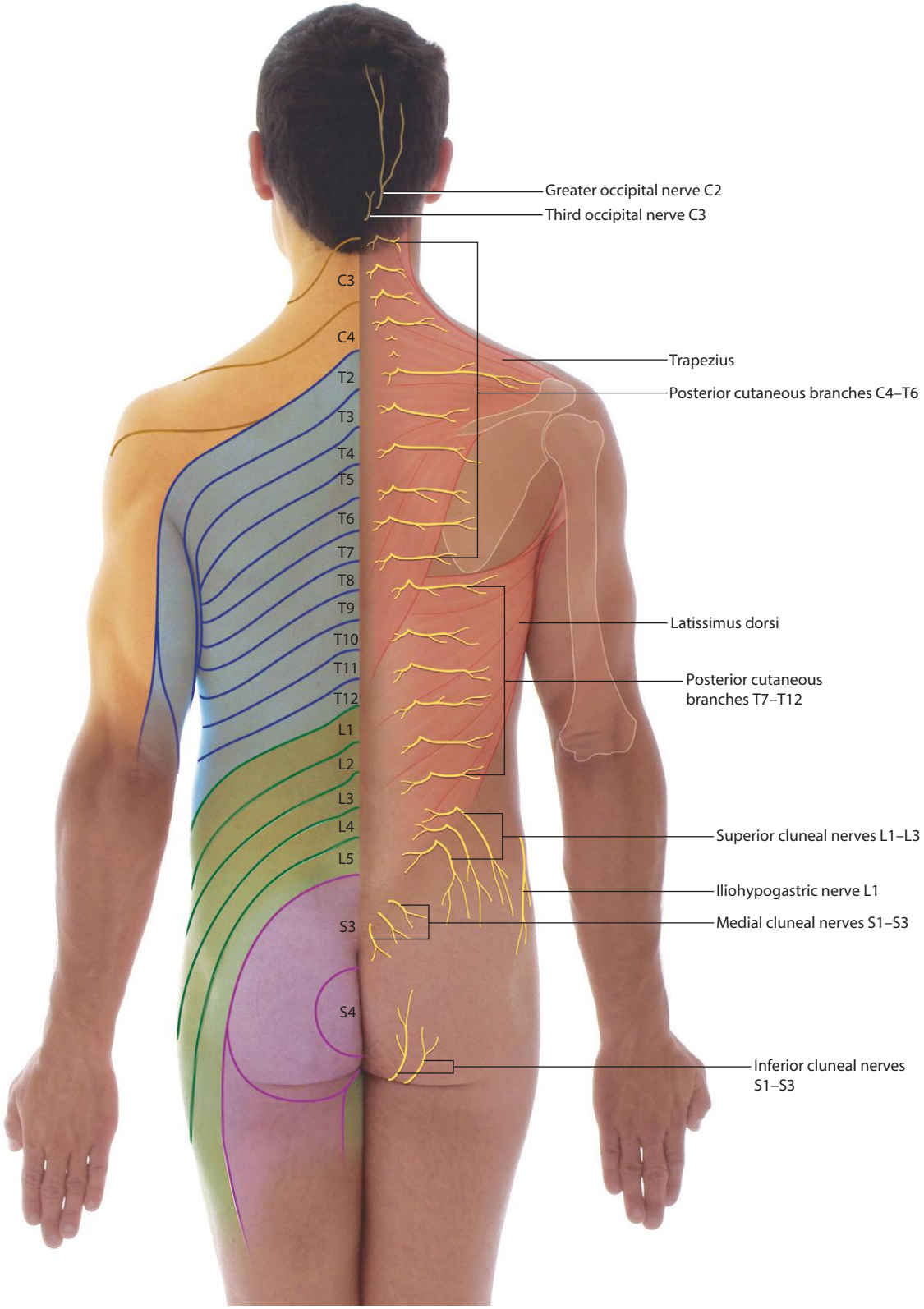

Dermatomes and cutaneous nerves of the back

Superficial (appendicular) group of back muscles

Muscle		Origin	Insertion	Innervation	Function
Trapezius	1	Superior nuchal line, external occipital protuberance, ligamentum nuchae, spinous processes of CVII to TXII	Lateral one third of clavicle, acromion, spine of scapula	Motor—accessory nerve [XI]; proprioception—C3 and C4	Assists in rotating the scapula during abduction of humerus above horizontal; upper fibers elevate, middle fibers adduct, and lower fibers depress scapula
Latissimus dorsi	2	Spinous processes of TVII to LV and sacrum, iliac crest, ribs X to XII	Floor of intertubercular sulcus of humerus	Thoracodorsal nerve (C6 to C8)	Extends, adducts, and medially rotates humerus
Levator scapulae	3	Transverse processes of CI to CIV	Upper portion of medial border of scapula	C3 to C4 and dorsal scapular nerve (C4, C5)	Elevates scapula
Rhomboid major	4	Spinous processes of TII to TV	Medial border of scapula between spine and inferior angle	Dorsal scapular nerve (C4, C5)	Retracts (adducts) and elevates scapula
Rhomboid minor	5	Lower portion of ligamentum nuchae, spinous processes of CVII and TI	Medial border of scapula at the spine of scapula	Dorsal scapular nerve (C4, C5)	Retracts (adducts) and elevates scapula

Intermediate (respiratory) group of back muscles

Serratus posterior superior	6	Lower portion of ligamentum nuchae, spinous processes of CVII to TIII and supraspinous ligaments	Mastoid process, skull below lateral one third of superior nuchal line	Anterior rami of upper thoracic nerves (T2 to T5)	Elevates ribs II to V
Serratus posterior inferior	7	Spinous processes of TXI to LIII and supraspinous ligaments	Lower border of ribs IX to XII just lateral to their angles	Anterior rami of lower thoracic nerves (T9 to T12)	Depresses ribs IX to XII and may prevent lower ribs from being elevated when the diaphragm contracts

Spinotransversales muscles

Splenius capitis	8	Lower half of ligamentum nuchae, spinous processes of CVII to TIV	Mastoid process, skull below lateral one third of superior nuchal line	Posterior rami middle cervical nerves	Together—draw head backward, extending neck; individually—draw and rotate head to one side (turn face to same side)
Splenius cervicis	9	Spinous processes of TIII to TVI	Transverse processes of CI to CIII	Posterior rami lower cervical nerves	Together—extend neck; individually—draw and rotate head to one side (turn face to same side)

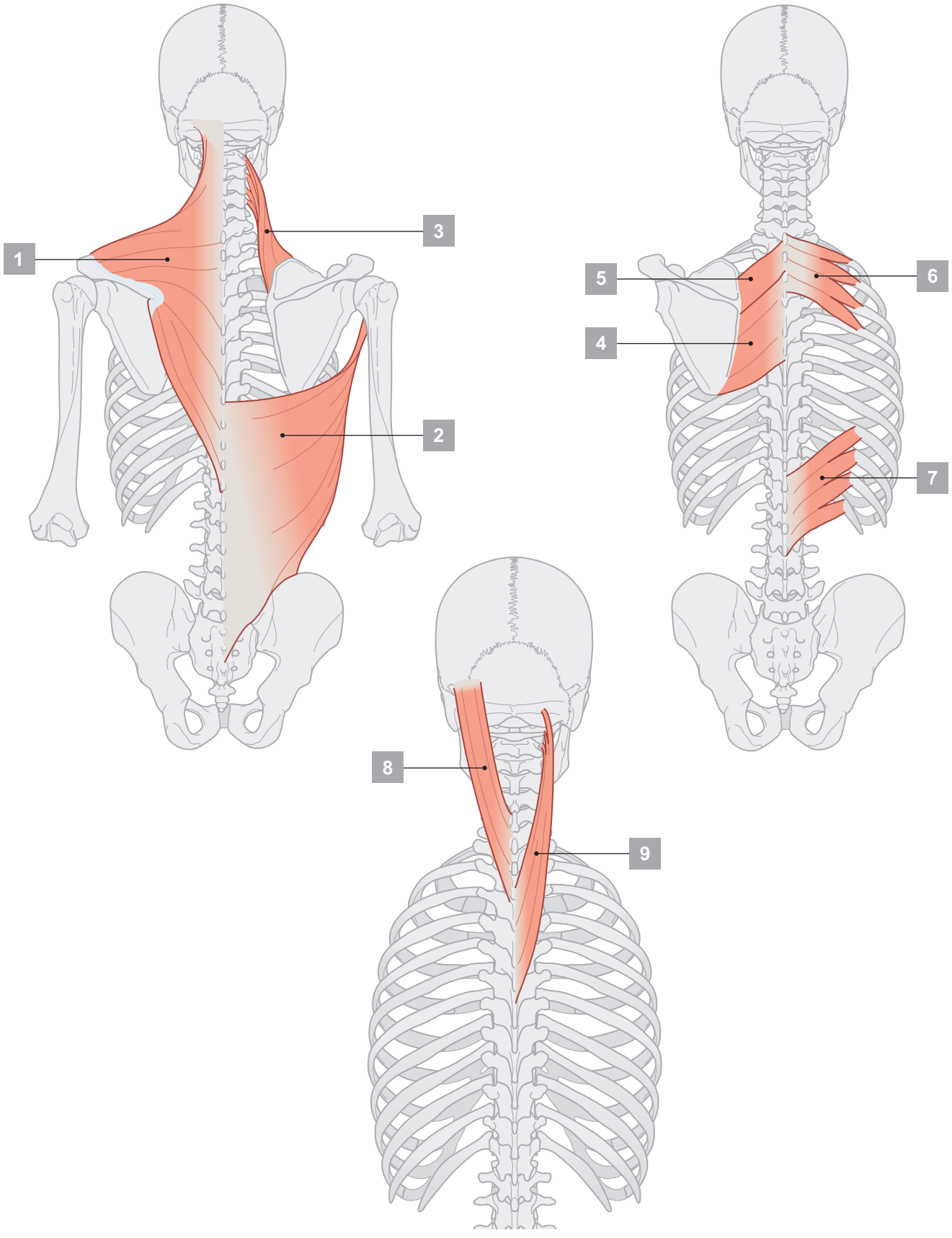
1
2
3
4
5
6
7
8
9

Erector spinae group of back muscles

Muscle		Origin	Insertion
Iliocostalis lumborum	1	Sacrum, spinous processes of lumbar and lower two thoracic vertebrae and their supraspinous ligaments, and the iliac crest	Angles of the lower six or seven ribs
Iliocostalis thoracis	2	Angles of the lower six ribs	Angles of the upper six ribs and the transverse process of CVII
Iliocostalis cervicis	3	Angles of ribs III to VI	Transverse processes of CIV to CVI
Longissimus thoracis	4	Blends with iliocostalis in lumbar region and is attached to transverse processes of lumbar vertebrae	Transverse processes of all thoracic vertebrae and just lateral to the tubercles of the lower nine or ten ribs
Longissimus cervicis	5	Transverse processes of upper four or five thoracic vertebrae	Transverse processes of CII to CVI
Longissimus capitis	6	Blends with iliocostalis in lumbar region and is attached to transverse processes of lumbar vertebrae	Transverse processes of all thoracic vertebrae and just lateral to the tubercles of the lower nine or ten ribs
Spinalis thoracis	7	Spinous processes of TX or TXI to LII	Spinous processes of TI to TVIII (varies)
Spinalis cervicis	8	Lower part of ligamentum nuchae and spinous process of CVII (sometimes TI to TII)	Spinous process of CII (axis)
Spinalis capitis	9	Usually blends with semispinalis capitis	With semispinalis capitis

Transversospinales group of back muscles

Semispinalis thoracis	10	Transverse processes of TVI to TX	Spinous processes of upper four thoracic and lower two cervical vertebrae
Semispinalis cervicis	11	Transverse processes of upper five or six thoracic vertebrae	Spinous processes of CII (axis) to CV
Semispinalis capitis	12	Transverse processes of TI to TVI (or TVII) and CVII and articular processes of CIV to CVI	Medial area between the superior and inferior nuchal lines of occipital bone
Multifidus	13	Sacrum, origin of erector spinae, posterior superior iliac spine, mammillary processes of lumbar vertebrae, transverse processes of thoracic vertebrae, and articular processes of lower four cervical vertebrae	Base of spinous processes of all vertebrae from LV to CII (axis)
Rotatores lumborum	14	Mammillary processes of lumbar vertebrae	Spinous processes of lumbar vertebrae
Rotatores thoracis	15	Transverse processes of thoracic vertebrae	Spinous processes of thoracic vertebrae
Rotatores cervicis	16	Articular processes of cervical vertebrae	Spinous processes of cervical vertebrae

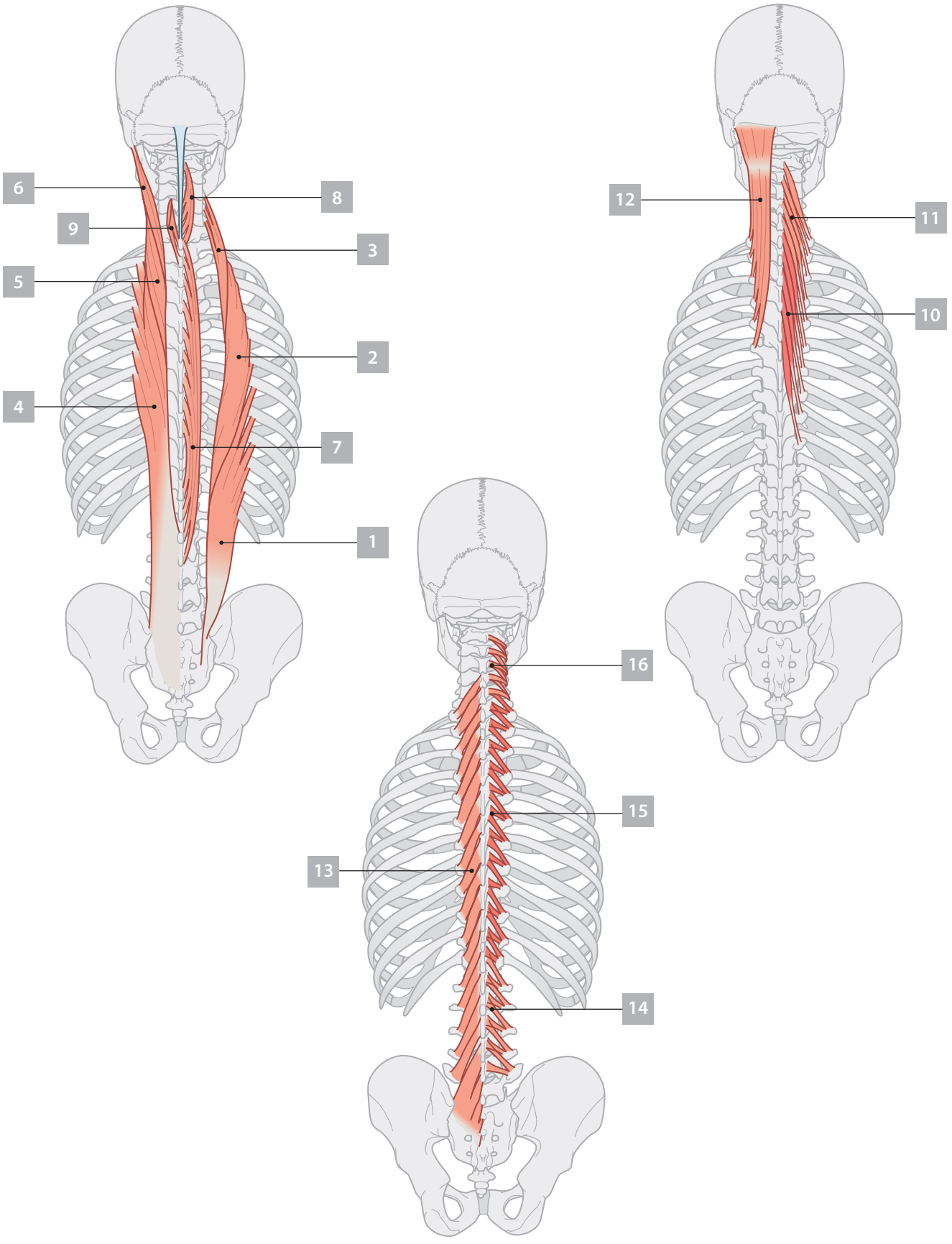
6
8
9
3
5
2
4
7
1
12
11
10
16
15
13
14

Segmental back muscles

Muscle		Origin	Insertion	Function
Levatores costarum	1	Short paired muscles arising from transverse processes of CVII to TXI	The rib below vertebra of origin near tubercle	Contraction elevates rib
Interspinales	2	Short paired muscles attached to the spinous processes of contiguous vertebrae, one on each side of the interspinous ligament		Postural muscles that stabilize adjoining vertebra during movements of vertebral column
Intertransversarii	3	Small muscles between the transverse processes of contiguous vertebrae		Postural muscles that stabilize adjoining vertebra during movements of vertebral column

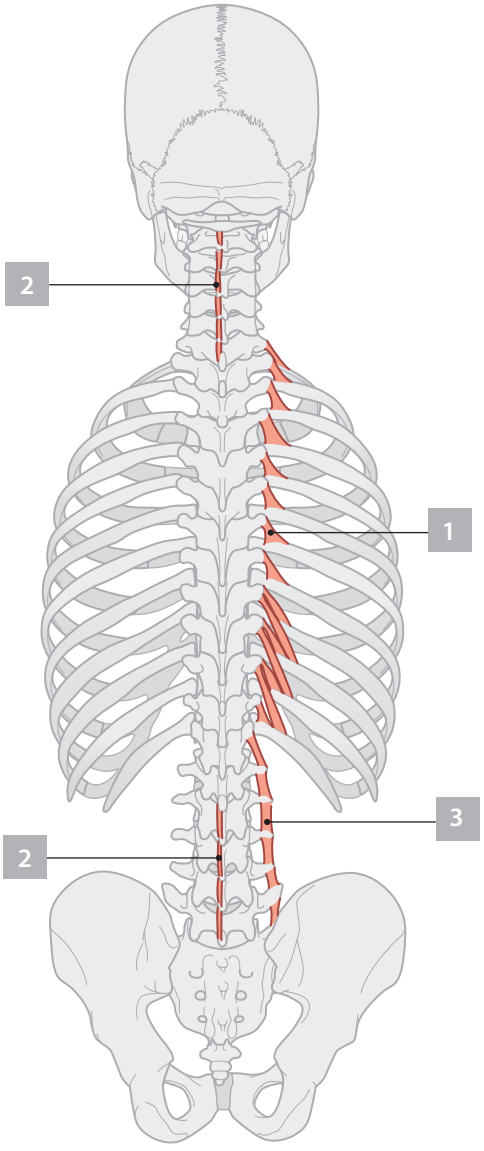

Suboccipital group of back muscles

Muscle		Origin	Insertion	Innervation	Function
Rectus capitis posterior major	1	Spinous process of axis (CII)	Lateral portion of occipital bone below inferior nuchal line	Posterior ramus of C1	Extension of head; rotation of face to same side as muscle
Rectus capitis posterior minor	2	Posterior tubercle of atlas (CI)	Medial portion of occipital bone below inferior nuchal line	Posterior ramus of C1	Extension of head
Obliquus capitis superior	3	Transverse process of atlas (CI)	Occipital bone between superior and inferior nuchal lines	Posterior ramus of C1	Extension of head and bends it to same side
Obliquus capitis inferior	4	Spinous process of axis (CII)	Transverse process of atlas (CI)	Posterior ramus of C1	Rotation of face to same side

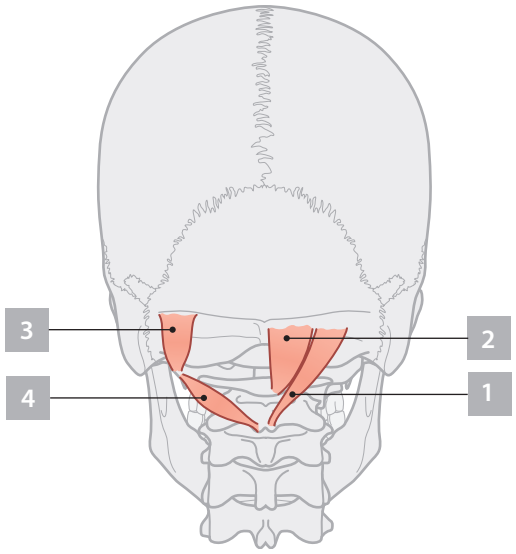

This page intentionally left blank

3

THORAX

CONTENTS

Surface anatomy with bones **62**
Bony framework **63**
Ribs **65**
Articulations **66**
Breast **68**
Pectoral region **70**
Thoracic wall muscles **72**
Diaphragm **73**
Arteries of the thoracic wall **74**
Veins of the thoracic wall **75**
Nerves of the thoracic wall **76**
Lymphatics of the thoracic wall **77**
Intercostal nerves and arteries **78**
Pleural cavities and mediastinum **79**
Parietal pleura **80**
Surface projections of pleural recesses **81**
Right lung **82**
Left lung **83**
Lung lobes: surface relationship **84**
Lung lobes: imaging **85**
Bronchial tree **86**
Bronchopulmonary segments **87**
Pulmonary vessels and plexus **88**
Pulmonary vessels: imaging **89**
Mediastinum **91**
Pericardium **92**
Pericardial layers **93**
Anterior surface of heart **94**
Base and diaphragmatic surface of heart **95**
Right atrium **96**
Right ventricle **97**
Left atrium **98**
Left ventricle **99**
Aortic valve and cardiac skeleton **100**
Cardiac chambers and heart valves **101**
Coronary vessels **102**
Coronary arteries and variations **103**
Cardiac conduction system **105**
Auscultation points and heart sounds **106**
Cardiac innervation **107**
Superior mediastinum: thymus **108**
Superior mediastinum: veins and arteries **109**
Superior mediastinum: arteries and nerves **110**
Superior mediastinum: imaging **111**
Superior mediastinum: veins and trachea **112**
Mediastinum: imaging **113**
Mediastinum: view from right **114**
Mediastinum: imaging – view from right **115**
Mediastinum: view from left **116**
Mediastinum: imaging – view from left **117**
Posterior mediastinum **118**
Mediastinum: imaging **120**
Transverse section: TVIII level **124**
Dermatomes and cutaneous nerves **125**
Visceral efferent (motor) innervation of the heart **126**
Visceral afferents **127**
Tables **128**

1

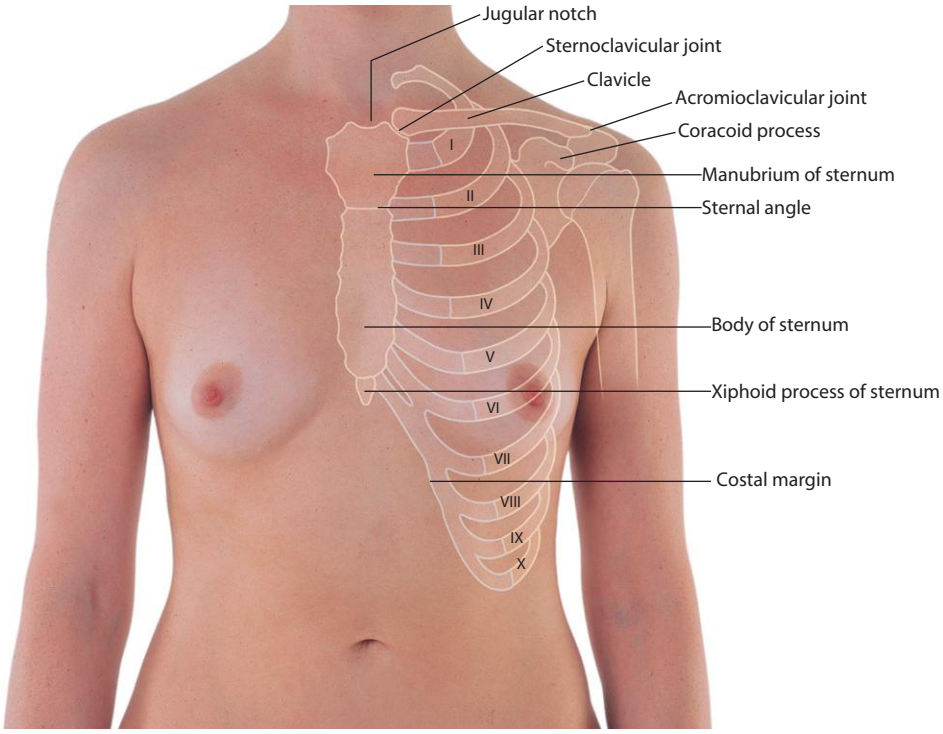

Anterior chest wall in a woman

2

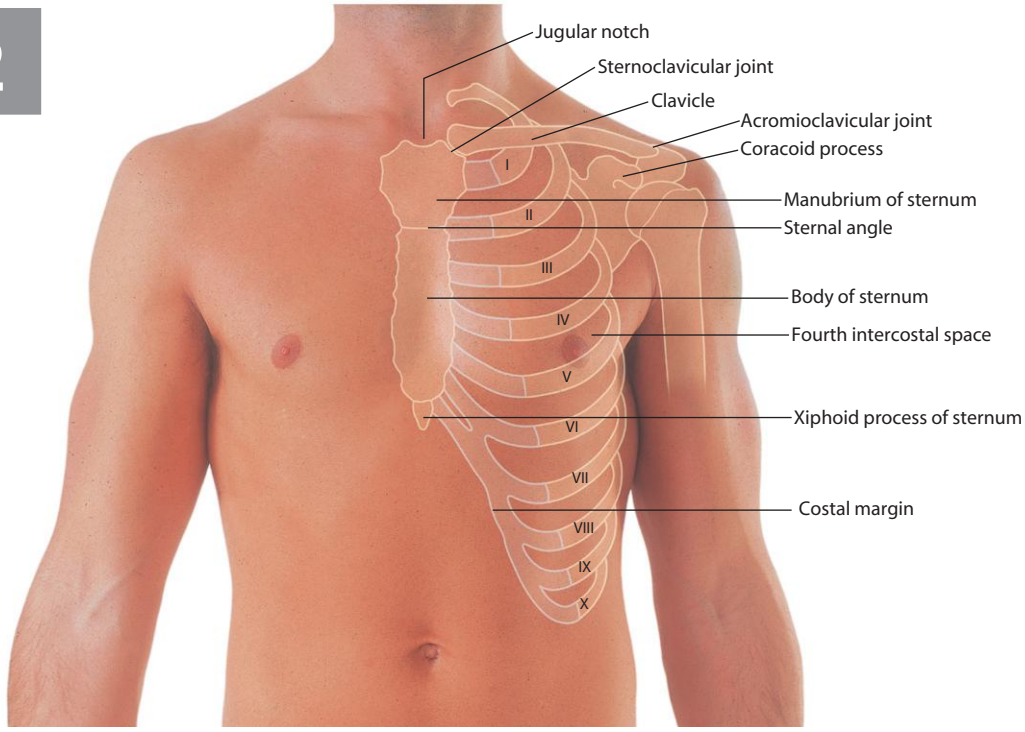

Anterior chest wall in a man

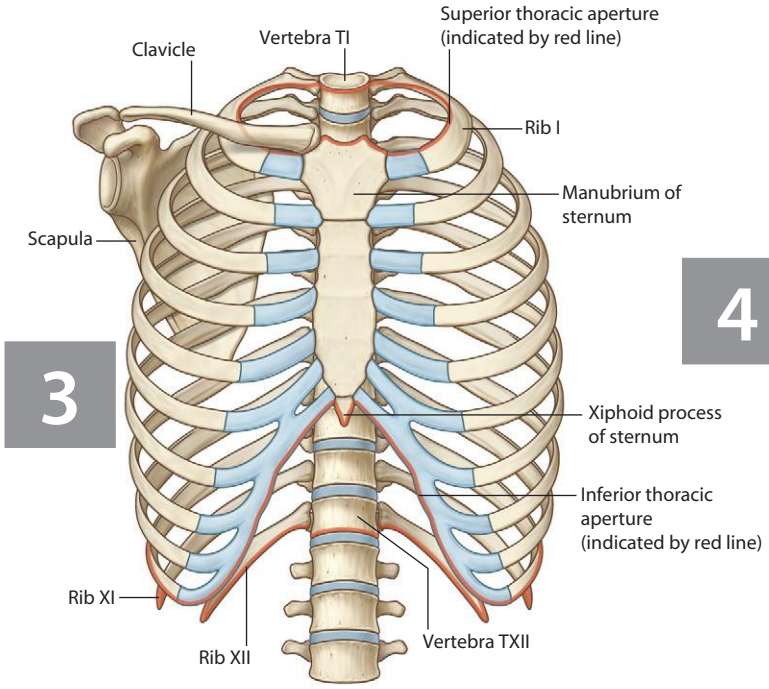

Bony framework of thorax (anterior view)

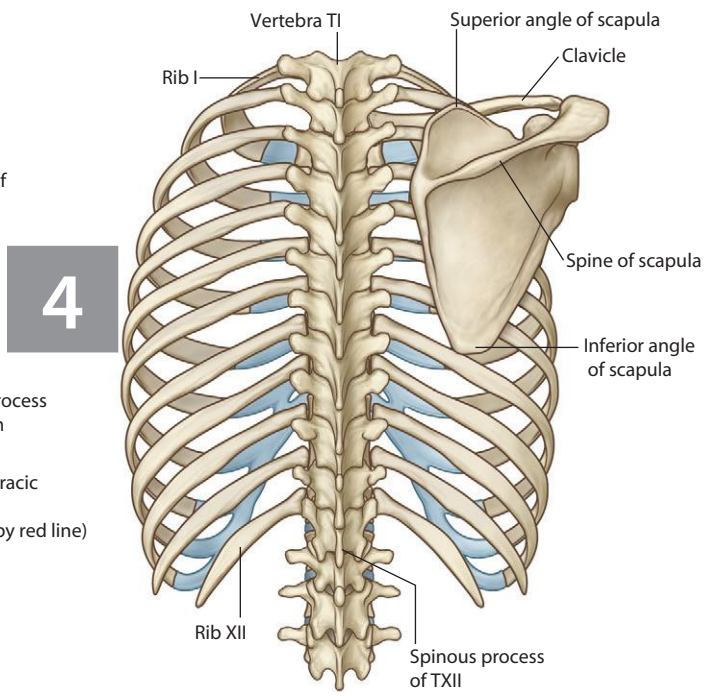

Bony framework of thorax (posterior view)

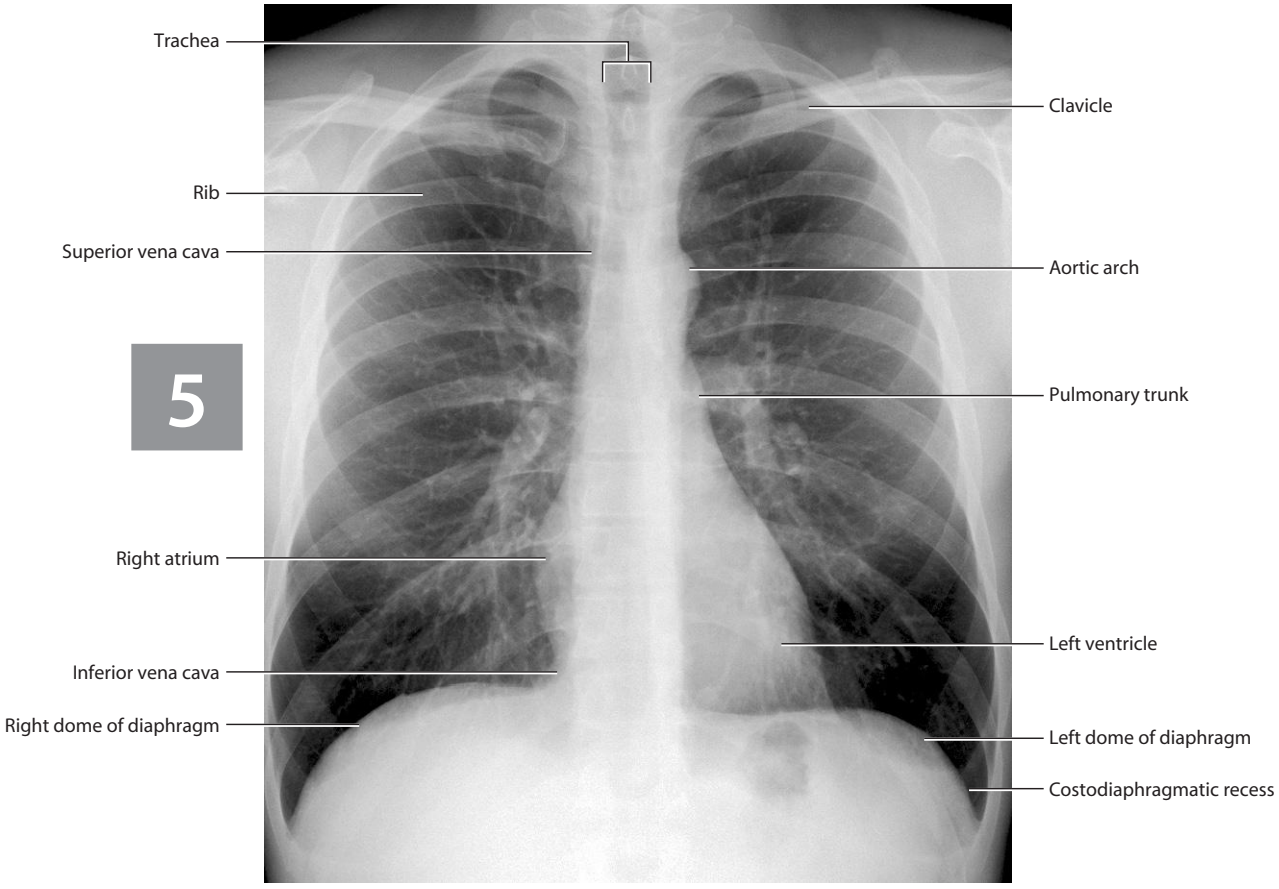

Positioning of structures in chest.
Radiograph, AP view

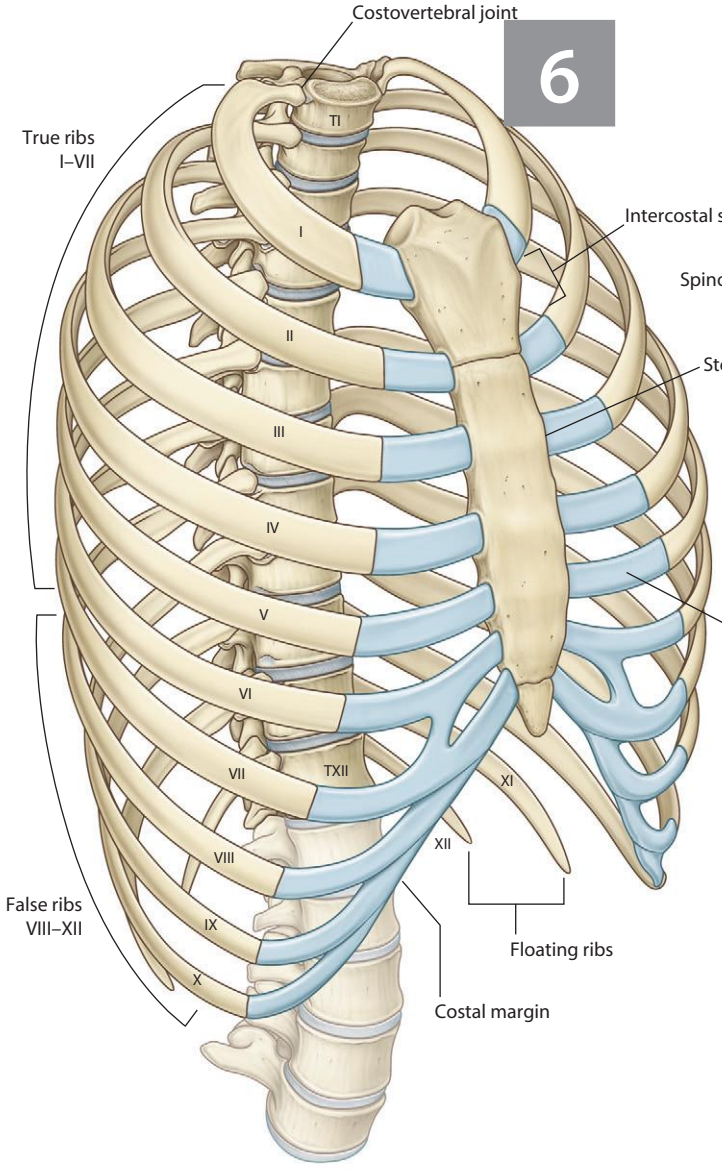
6
Costovertebral joint
True ribs
I–VII
TI
I
II
III
IV
V
VI
VII
TXII
XI
XII
VIII
IX
X
False ribs
VIII–XII
Intercostal space
Sternocostal joint
Costal cartilage
Floating ribs
Costal margin

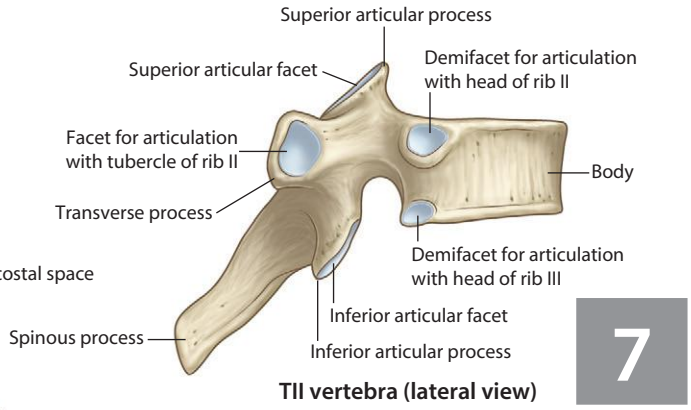
Superior articular process
Superior articular facet
Demifacet for articulation with head of rib II
Facet for articulation with tubercle of rib II
Body
Transverse process
Demifacet for articulation with head of rib III
Inferior articular facet
Spinous process
Inferior articular process
7
TII vertebra (lateral view)

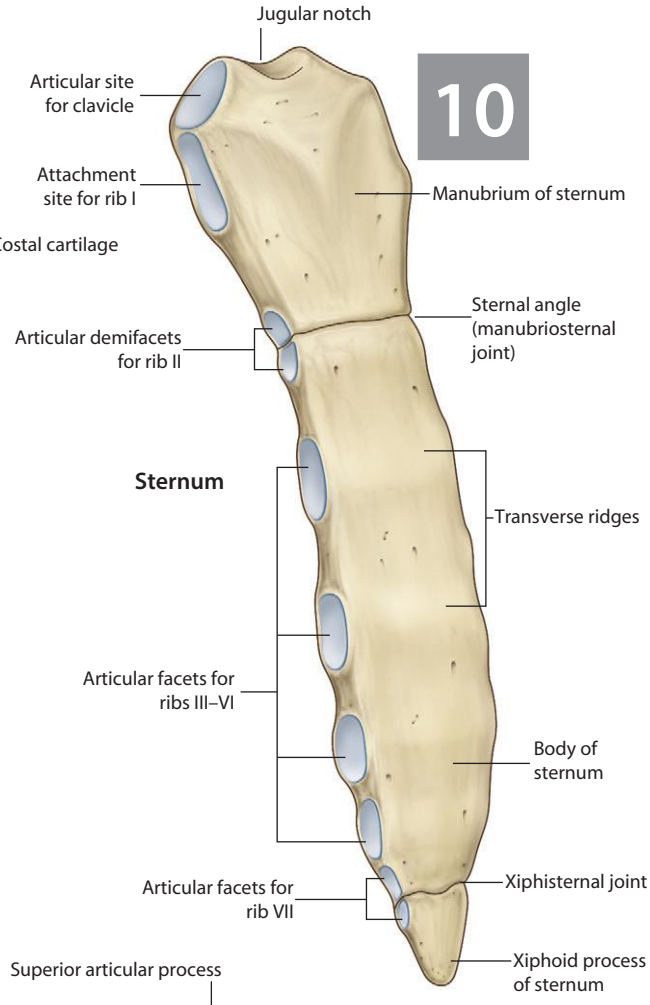
Jugular notch
10
Articular site for clavicle
Attachment site for rib I
Manubrium of sternum
Sternal angle (manubriosternal joint)
Articular demifacets for rib II
Sternum
Transverse ridges
Articular facets for ribs III–VI
Body of sternum
Articular facets for rib VII
Xiphisternal joint
Xiphoid process of sternum

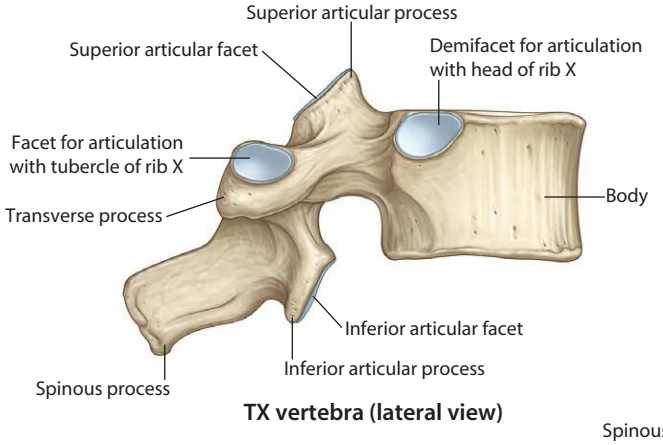
Superior articular process
Superior articular facet
Demifacet for articulation with head of rib X
Facet for articulation with tubercle of rib X
Body
Transverse process
Inferior articular facet
Inferior articular process
Spinous process
TX vertebra (lateral view)
9

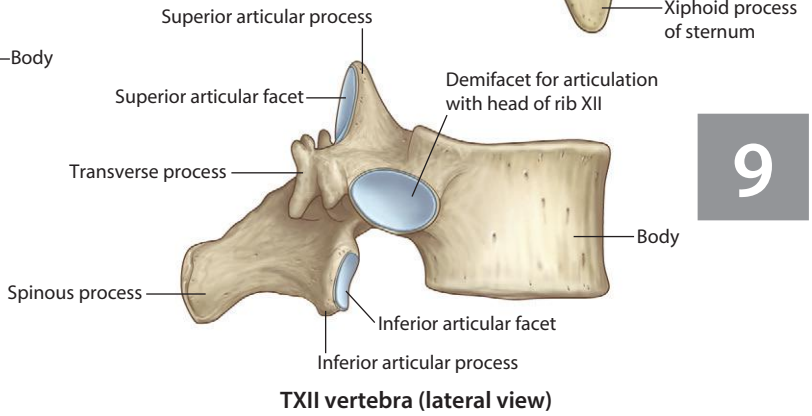
Superior articular process
Superior articular facet
Demifacet for articulation with head of rib XII
Transverse process
9
Body
Spinous process
Inferior articular facet
Inferior articular process
TXII vertebra (lateral view)

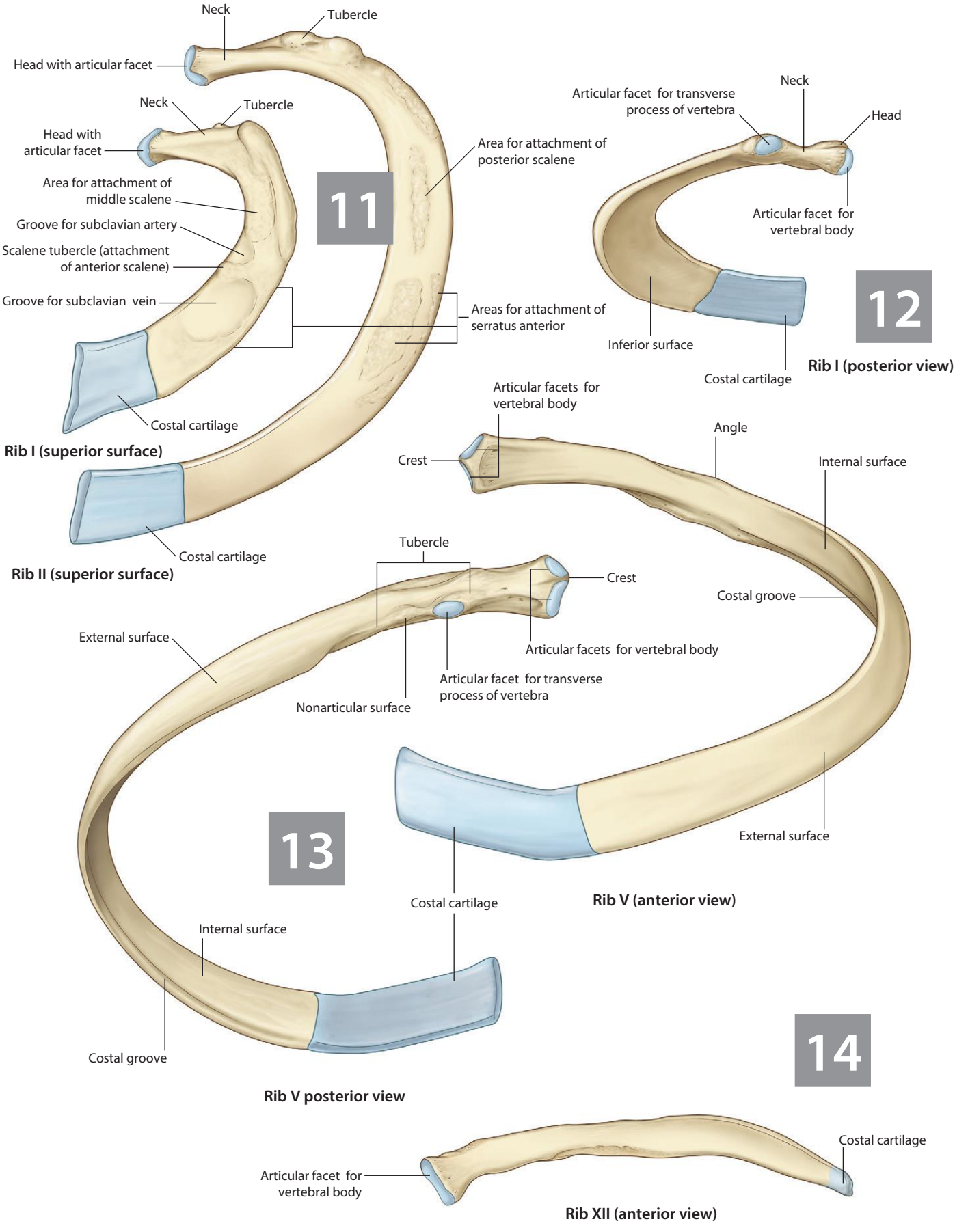
Neck
Tubercle
Head with articular facet
Neck
Tubercle
Head with articular facet
Area for attachment of middle scalene
Groove for subclavian artery
Scalene tubercle (attachment of anterior scalene)
Groove for subclavian vein
Area for attachment of posterior scalene
Areas for attachment of serratus anterior
11
Costal cartilage
Rib I (superior surface)
Articular facet for transverse process of vertebra
Neck
Head
Articular facet for vertebral body
Inferior surface
Costal cartilage
12
Rib I (posterior view)
Articular facets for vertebral body
Crest
Angle
Internal surface
Costal cartilage
Rib II (superior surface)
Tubercle
Crest
Costal groove
External surface
Articular facets for vertebral body
Articular facet for transverse process of vertebra
Nonarticular surface
13
External surface
Costal cartilage
Rib V (anterior view)
Internal surface
Costal groove
Rib V posterior view
14
Costal cartilage
Articular facet for vertebral body
Rib XII (anterior view)

15

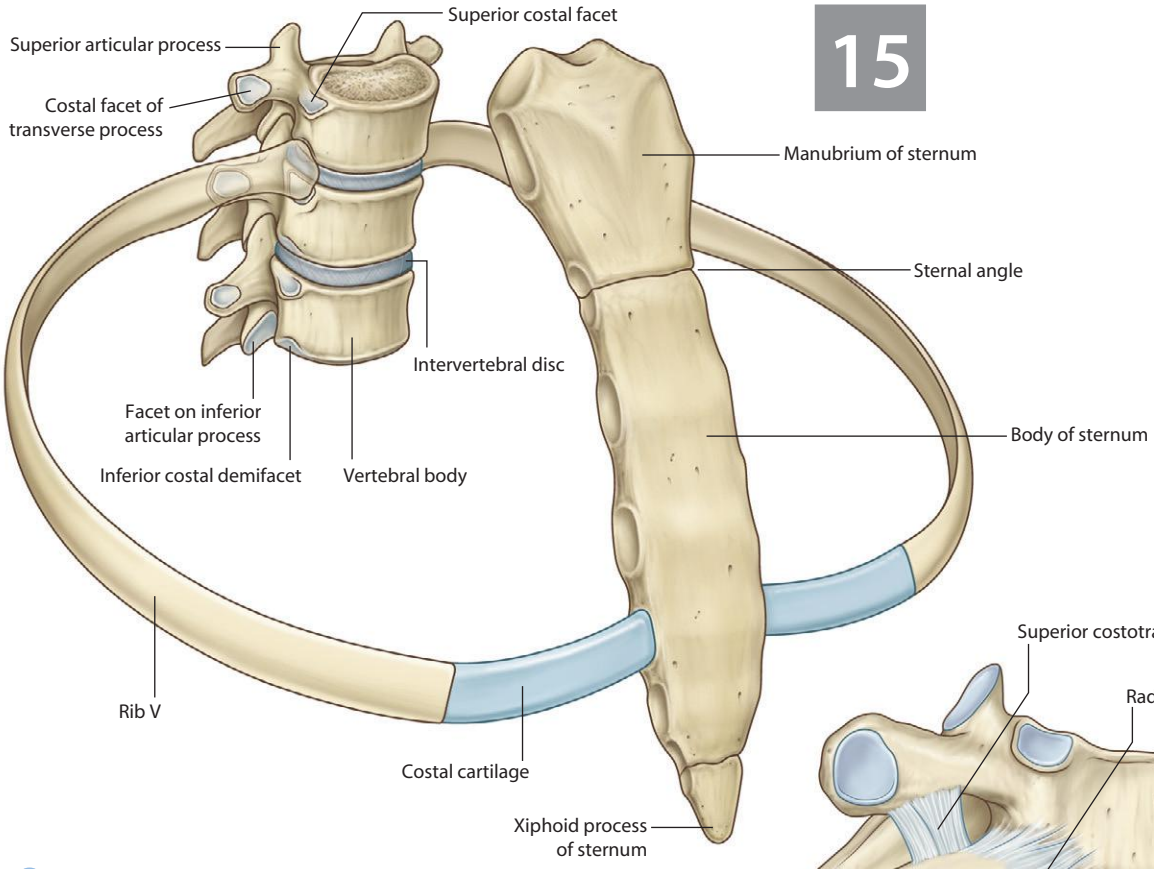

Costovertebral and sternocostal joints

16

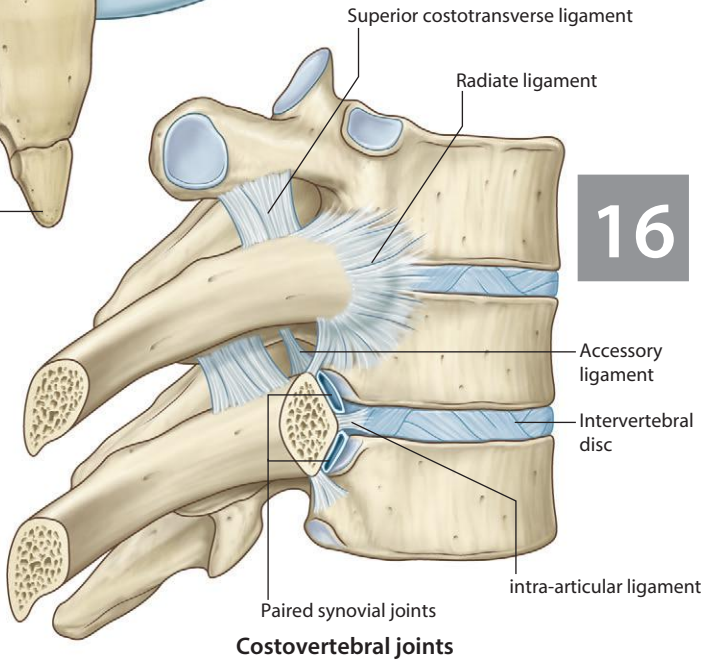

Costovertebral joints (lateral view)

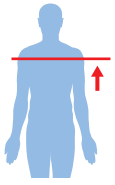

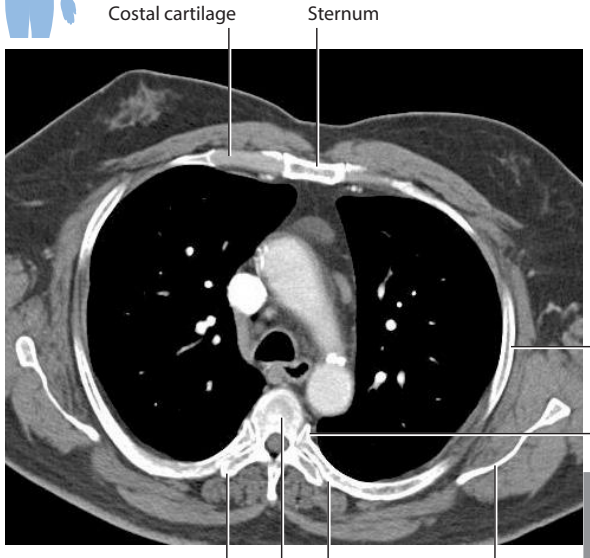

18

Articulation of rib with thoracic vertebra (TIV).
CT image, with contrast, in axial plane

17

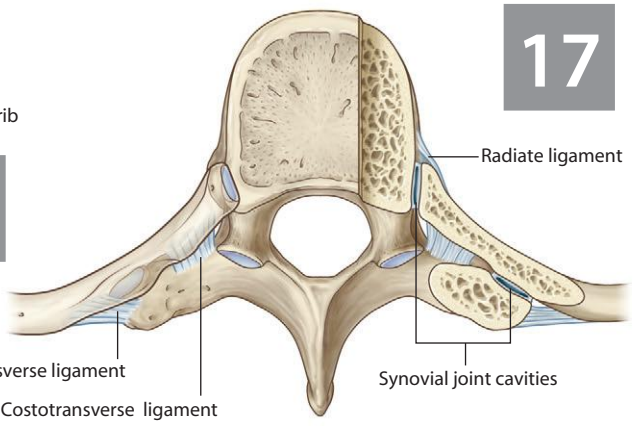

Costovertebral joints (superior view)

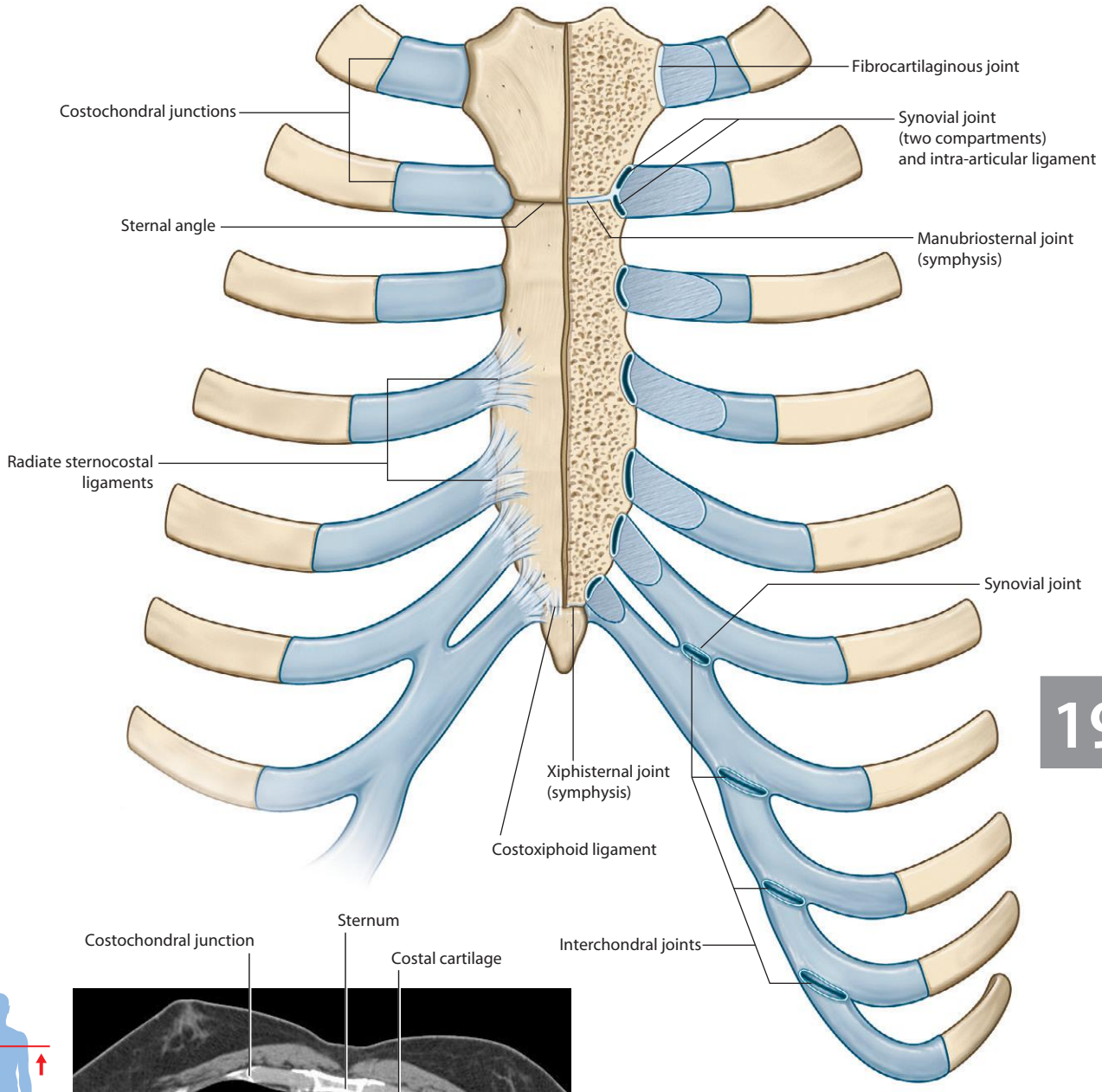

19

Sternocostal and interchondral joints

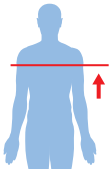

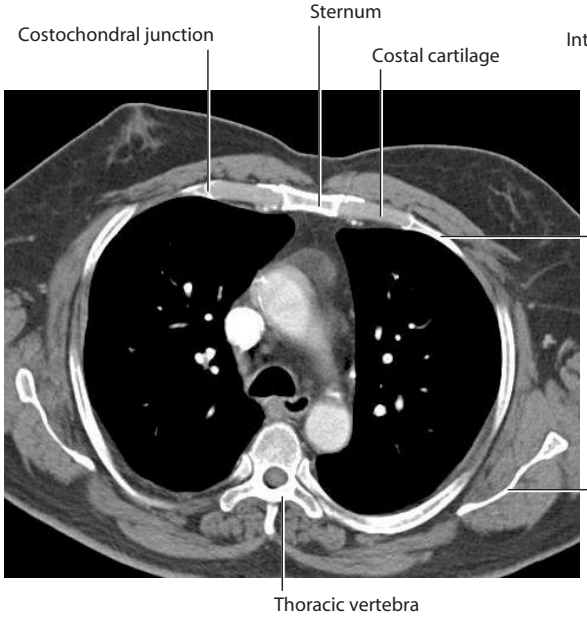

20

Articulation of costal cartilage with sternum.
CT image, with contrast, in axial plane

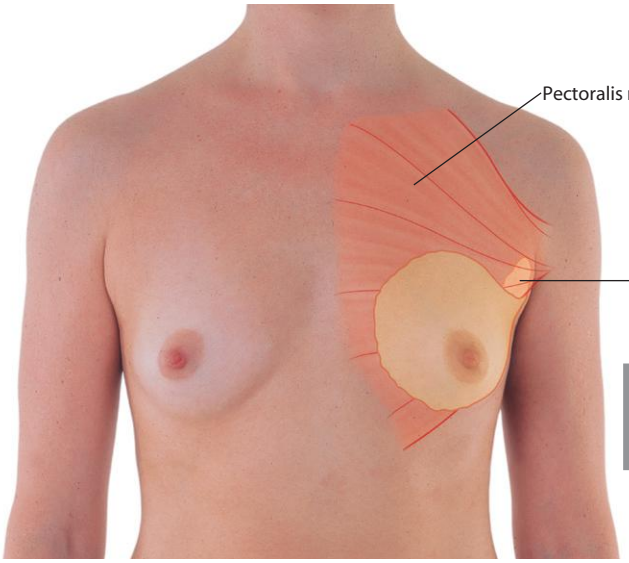

21

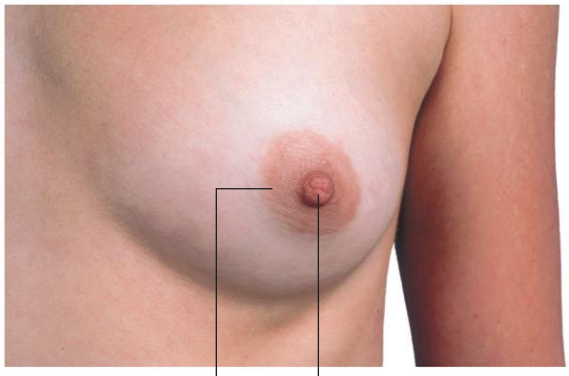

22

Anterior view

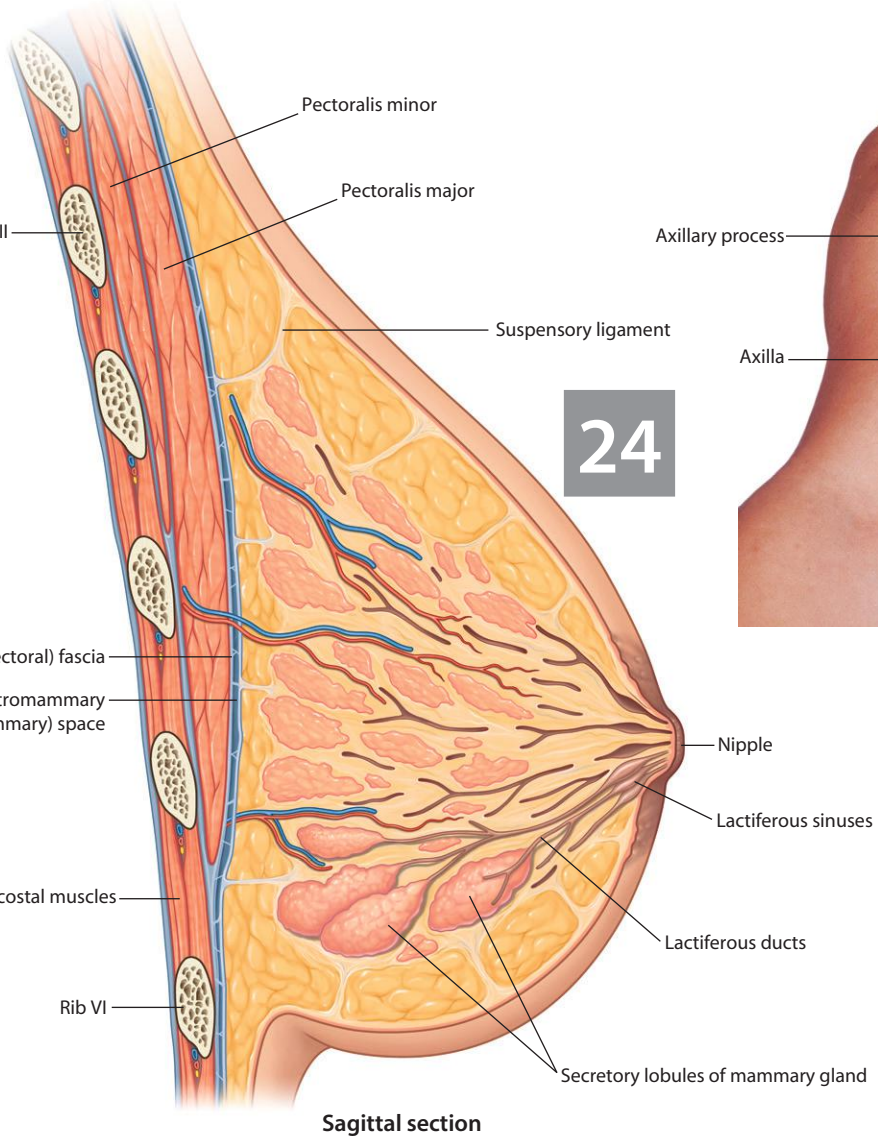

24

Sagittal section

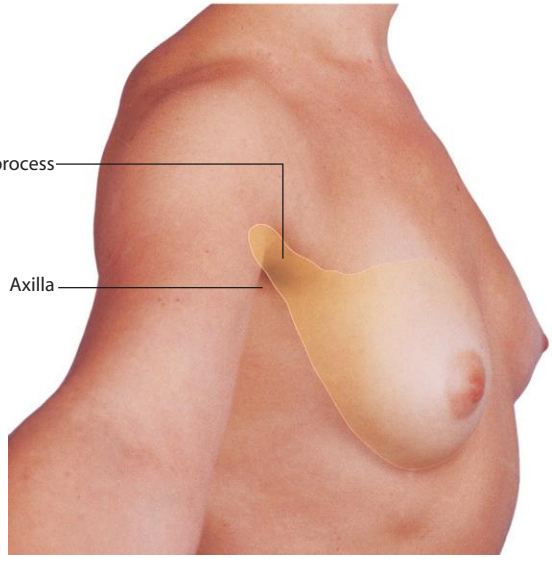

23

Lateral view

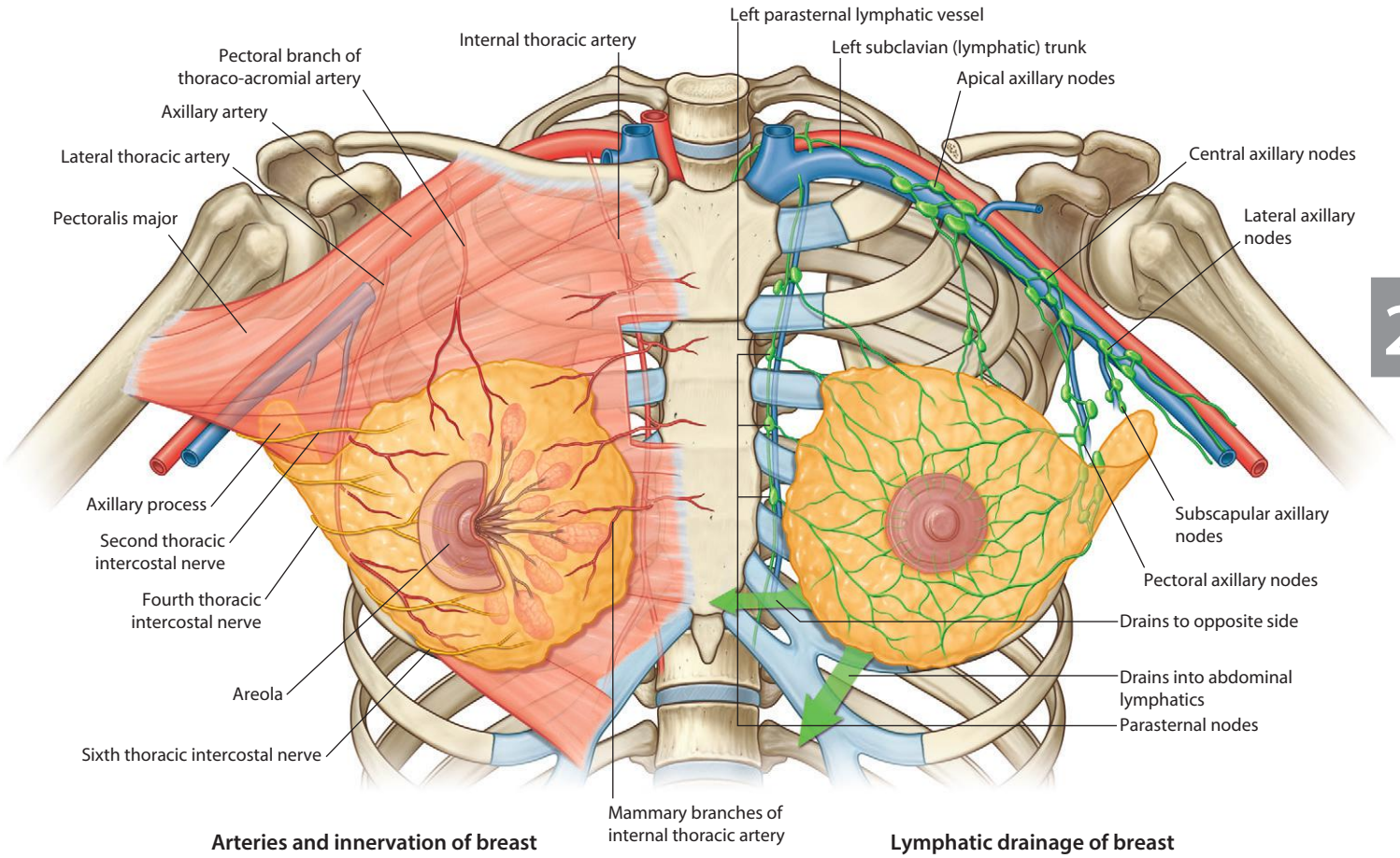

25

Arteries and innervation of breast

Lymphatic drainage of breast

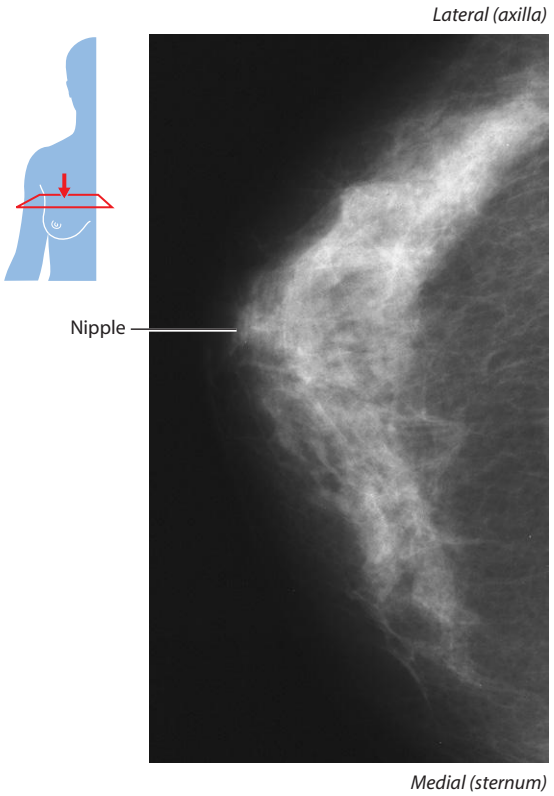

26

Mammography. Craniocaudal (CC) view of a normal right breast showing a heterogeneously dense appearance

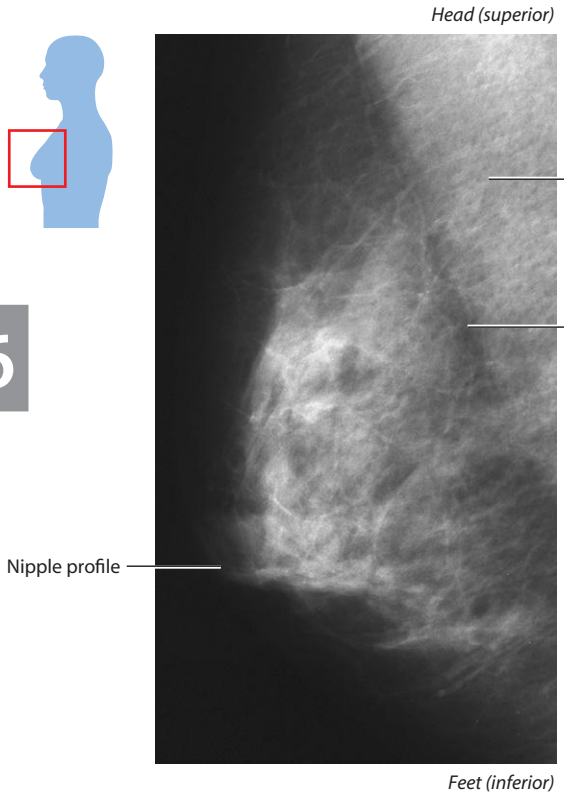

27

Mammography. Mediolateral oblique (MLO) view of a normal right breast showing a heterogeneously dense appearance

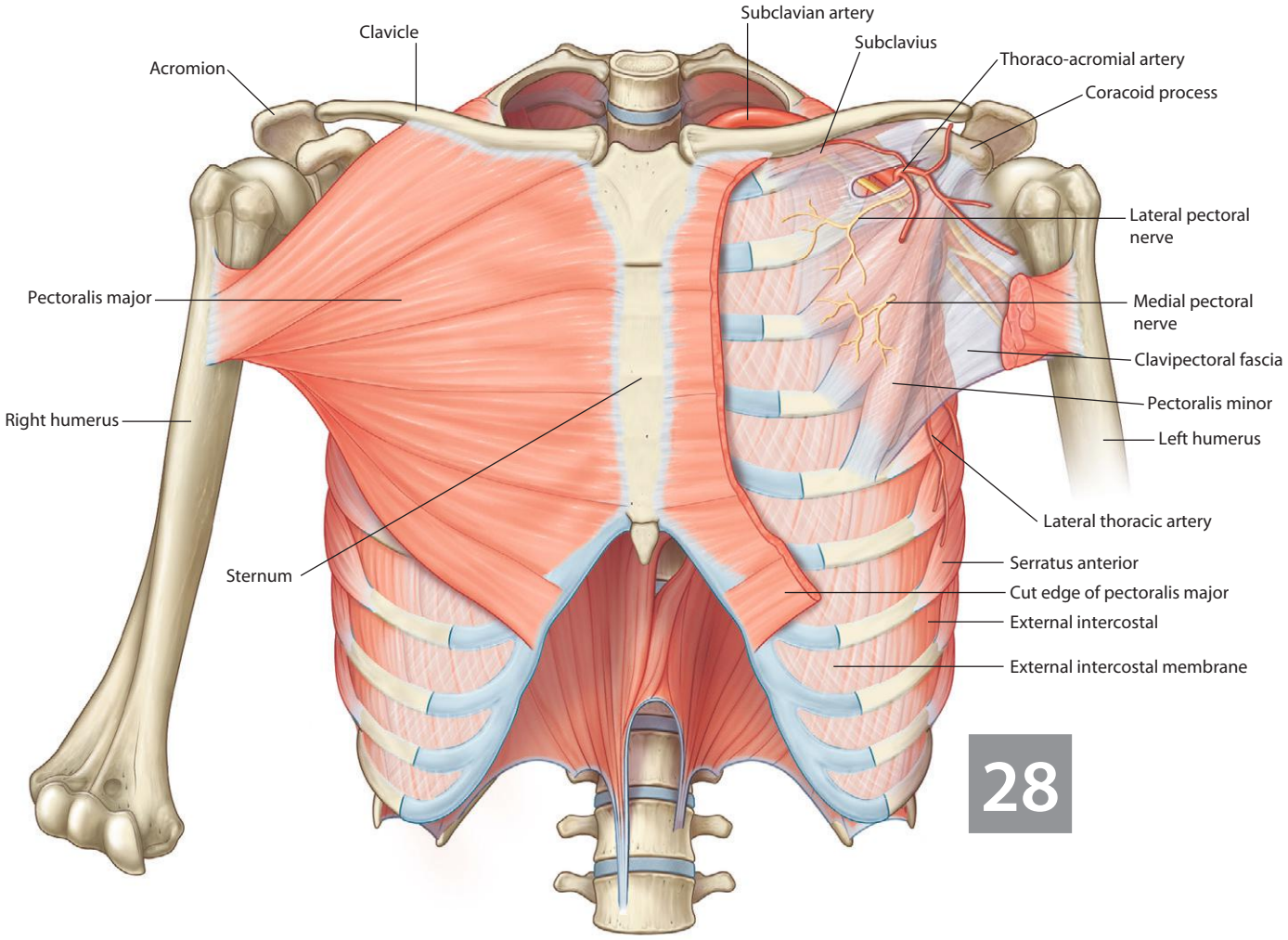

Pectoralis major muscle and related deep structures

Pectoralis major and minor muscles on anterior thoracic wall.
CT image, with contrast, in axial plane

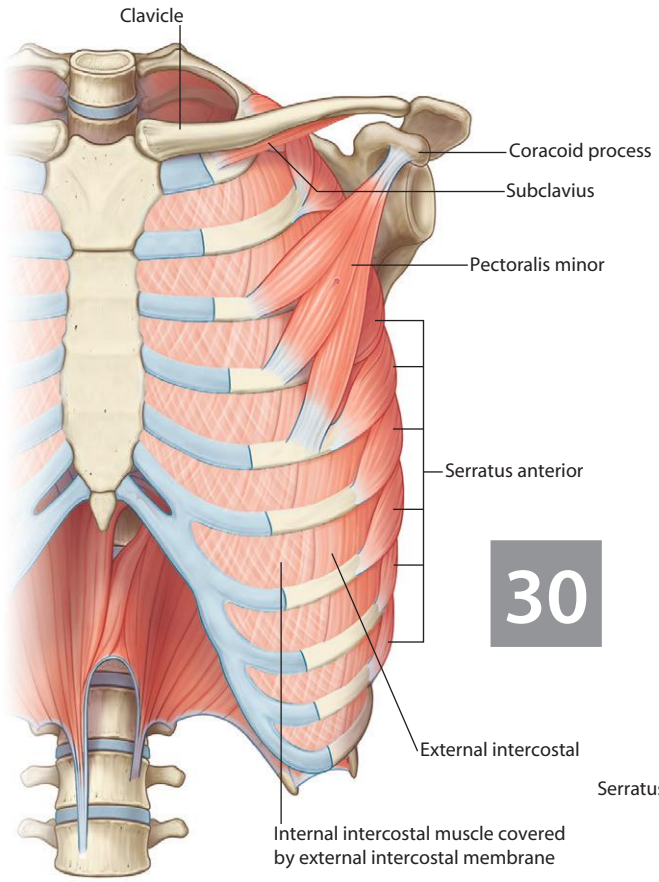

30

Pectoralis minor and the anterior thoracic wall (pectoralis major removed)

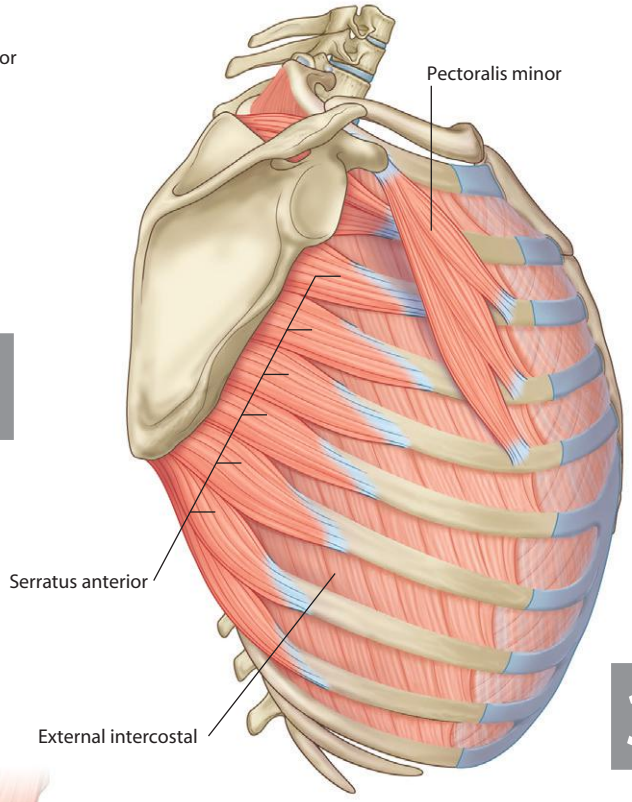

31

Muscles of the lateral thoracic wall (pectoralis major removed)

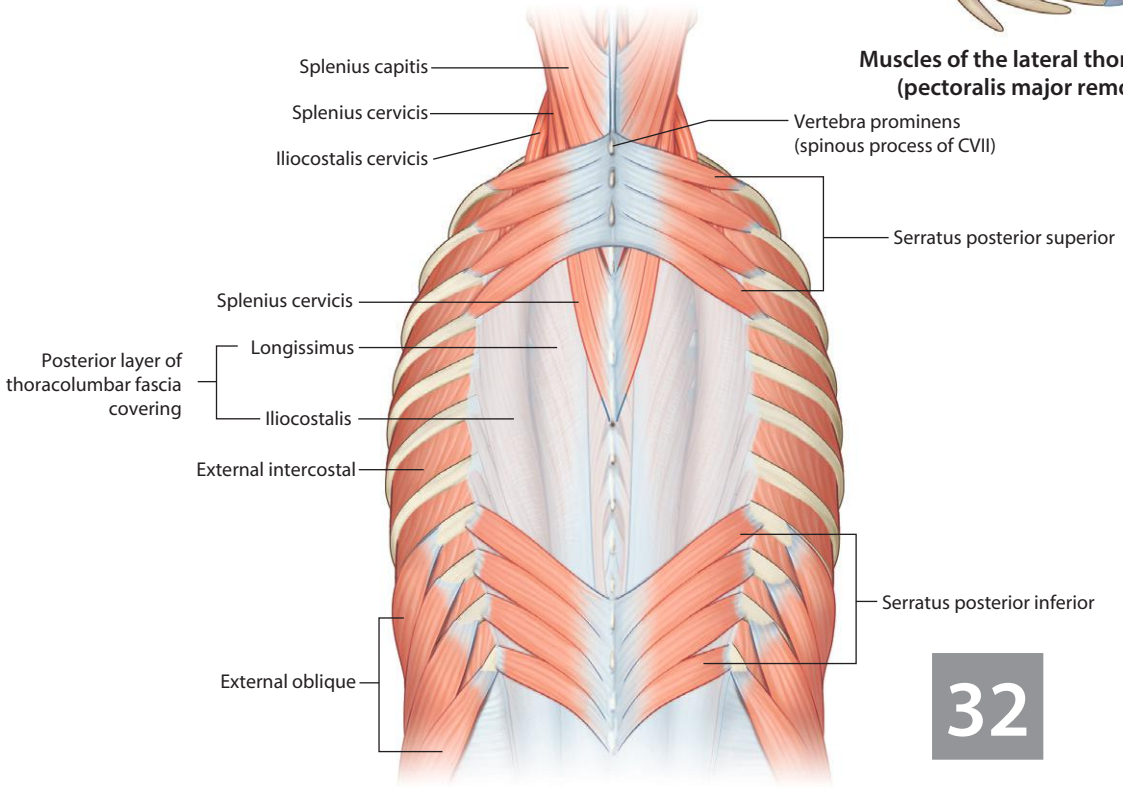

32

Muscles of the posterior thoracic wall

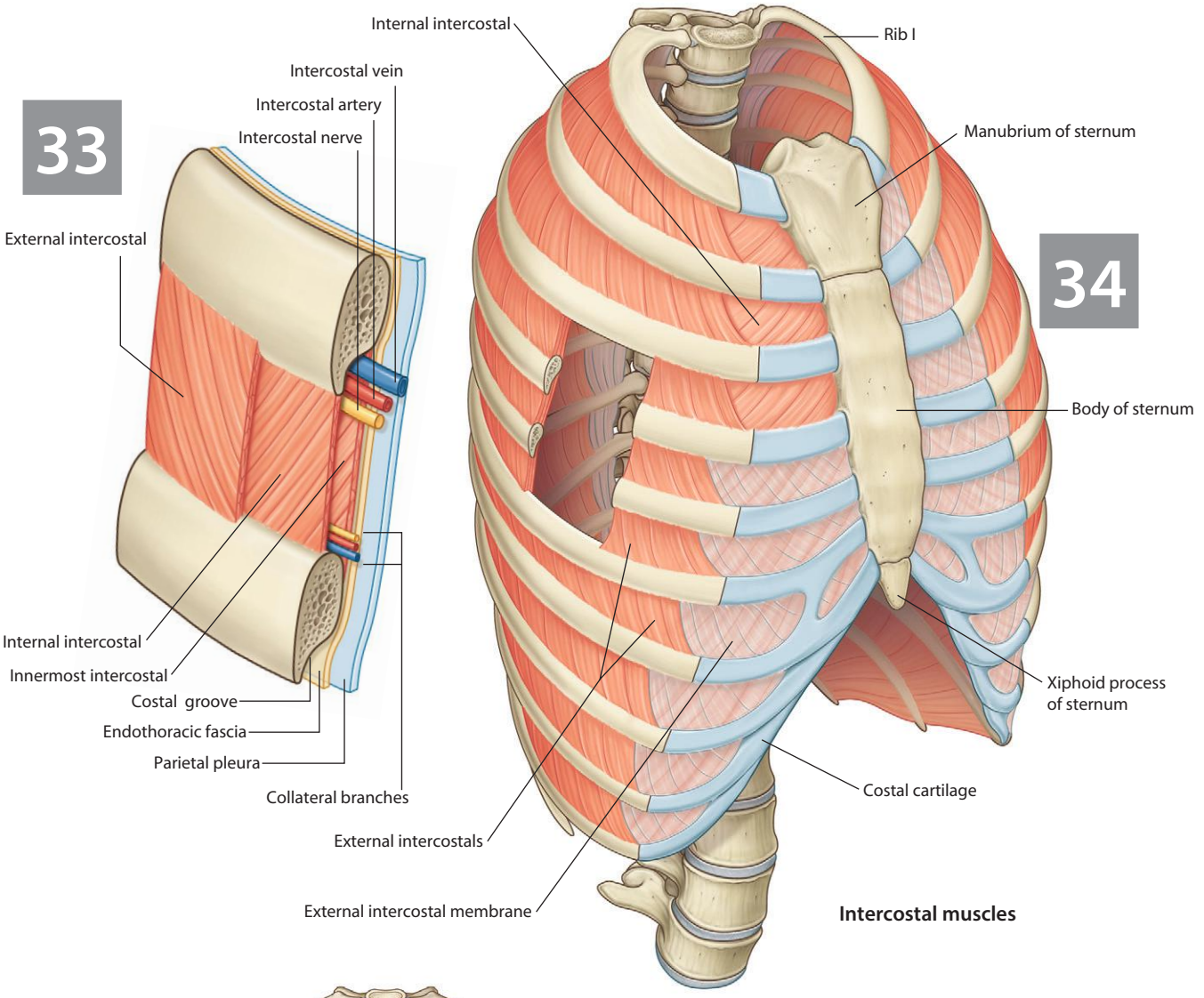
33
Internal intercostal
Intercostal vein
Intercostal artery
Intercostal nerve
External intercostal
Internal intercostal
Innermost intercostal
Costal groove
Endothoracic fascia
Parietal pleura
Collateral branches
External intercostals
External intercostal membrane
Rib I
Manubrium of sternum
34
Body of sternum
Xiphoid process of sternum
Costal cartilage
Intercostal muscles

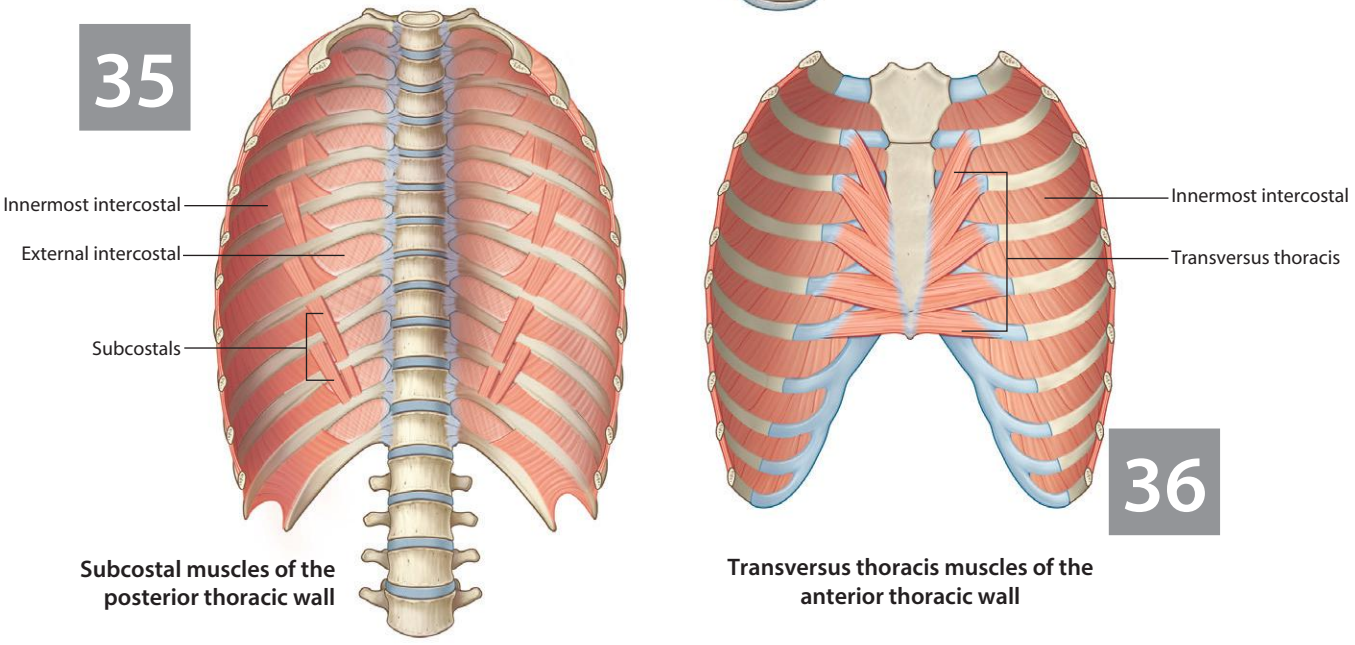
35
Innermost intercostal
External intercostal
Subcostals
Subcostal muscles of the posterior thoracic wall
Innermost intercostal
Transversus thoracis
36
Transversus thoracis muscles of the anterior thoracic wall

37

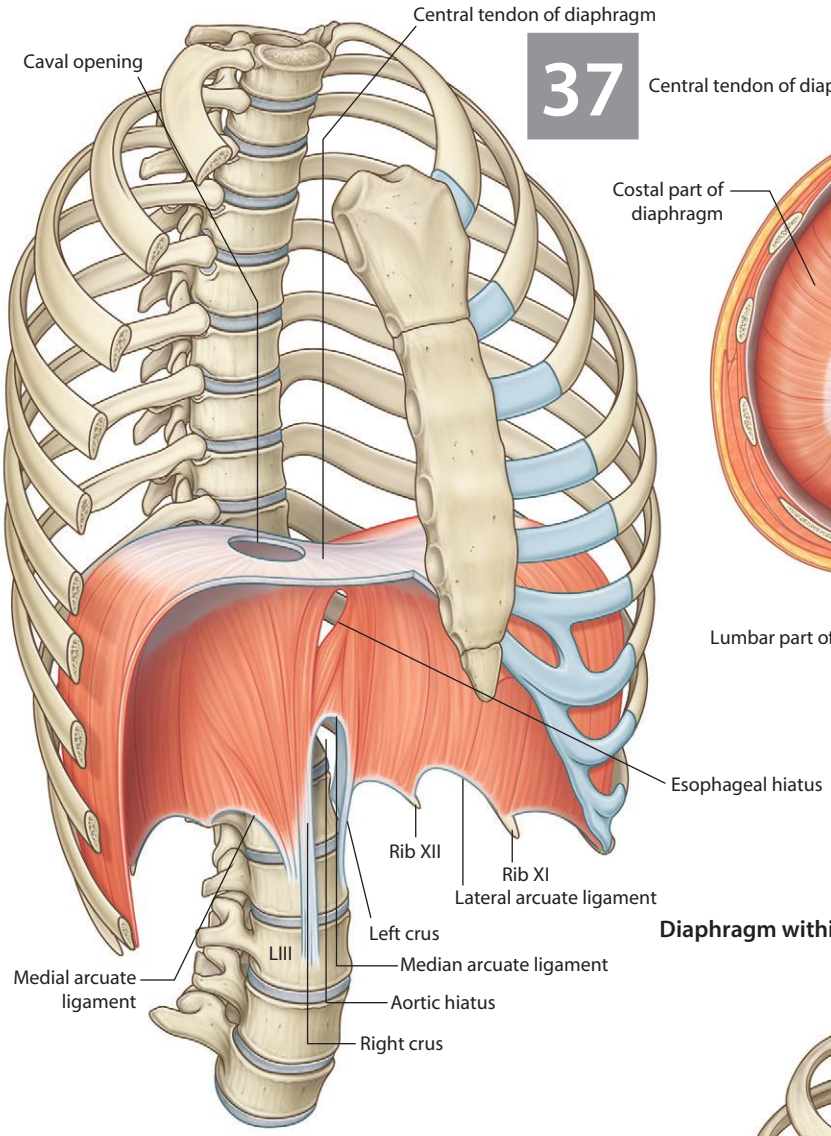

Diaphragm within the rib cage

40

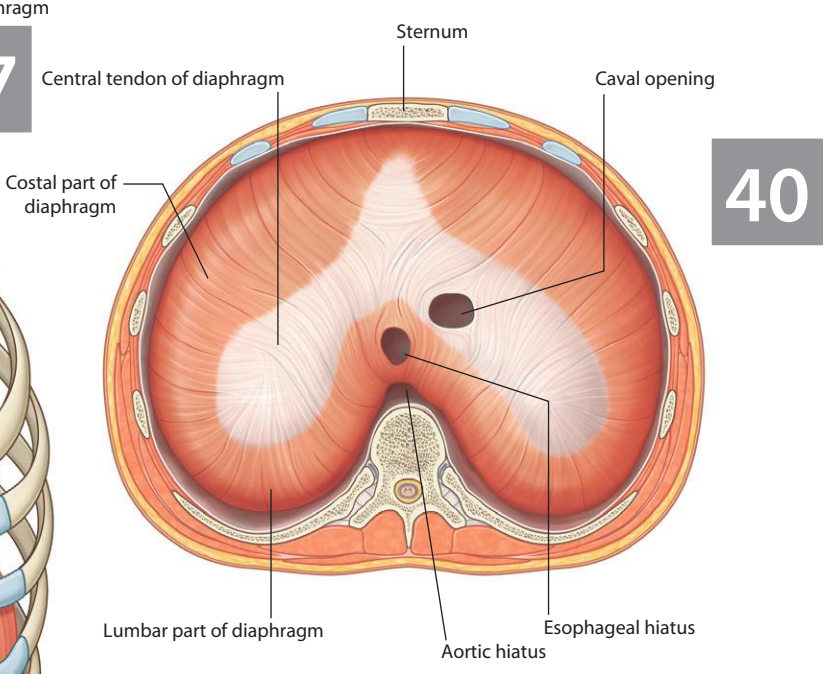

Diaphragm (superior view)

38

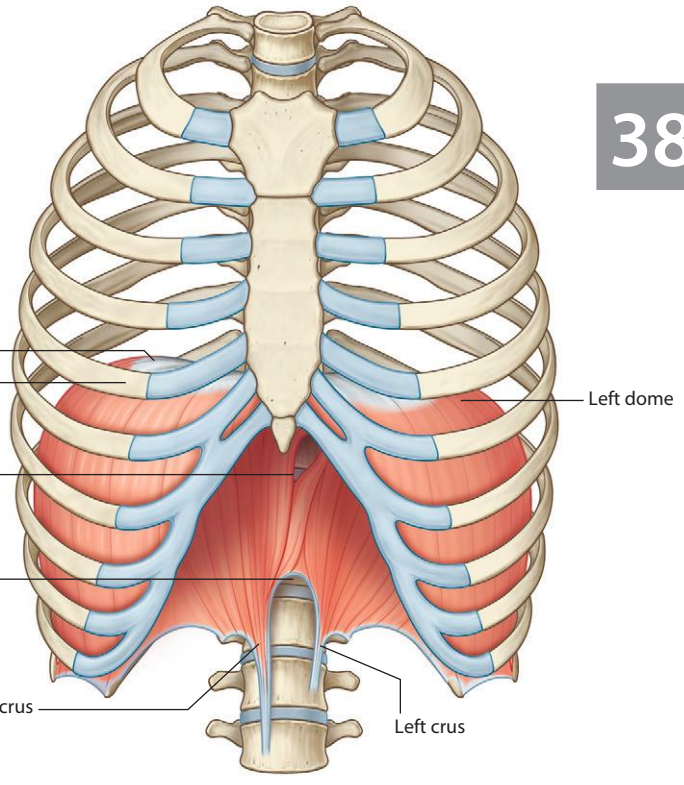

Features of diaphragm

39

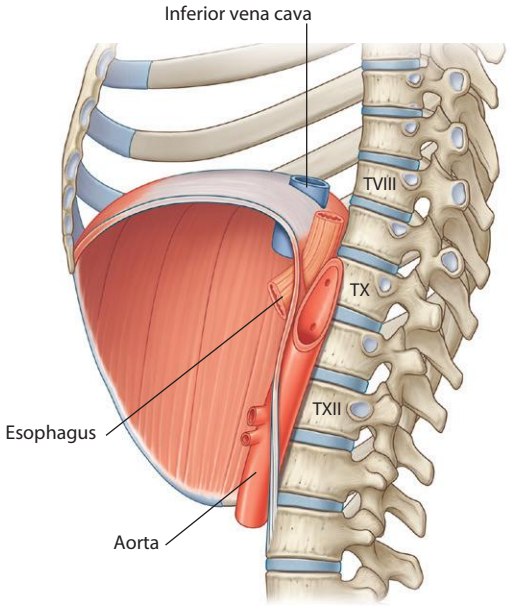

Major structures that pass through the diaphragm

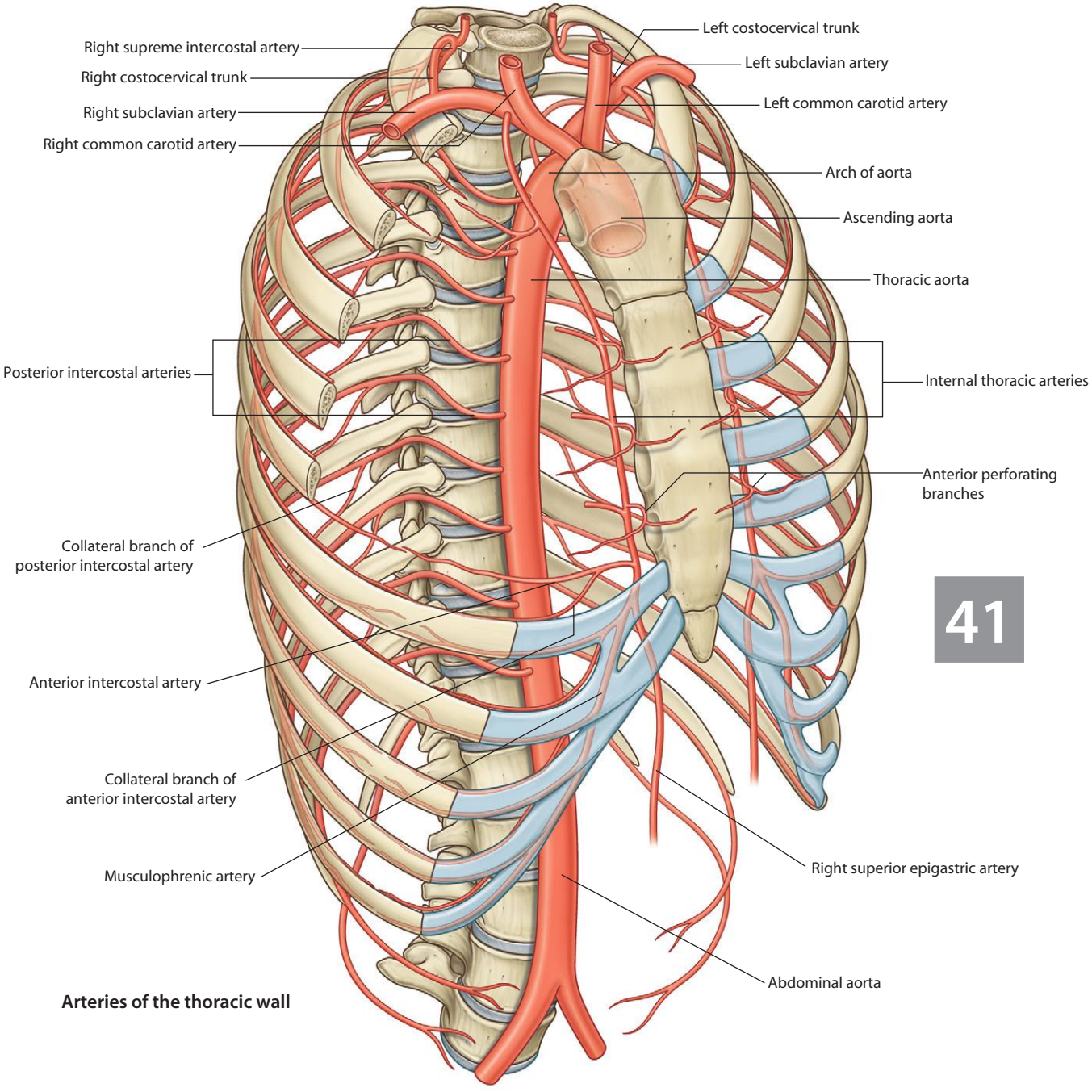

41

Arteries of the thoracic wall

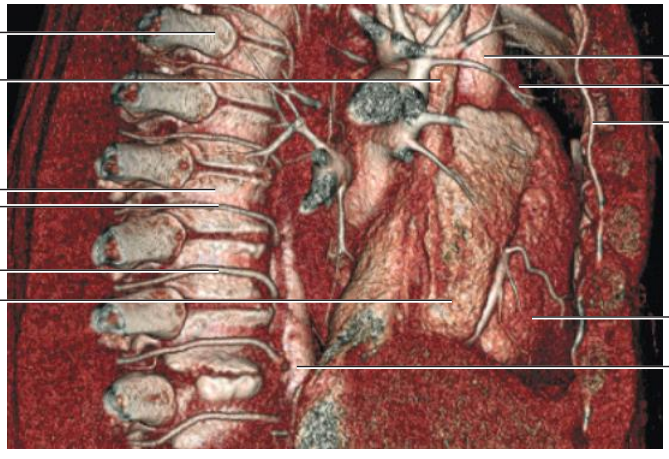

42

Arteries of the thoracic wall. Volume-rendered right lateral view of structures in the thorax using multidetector computed tomography

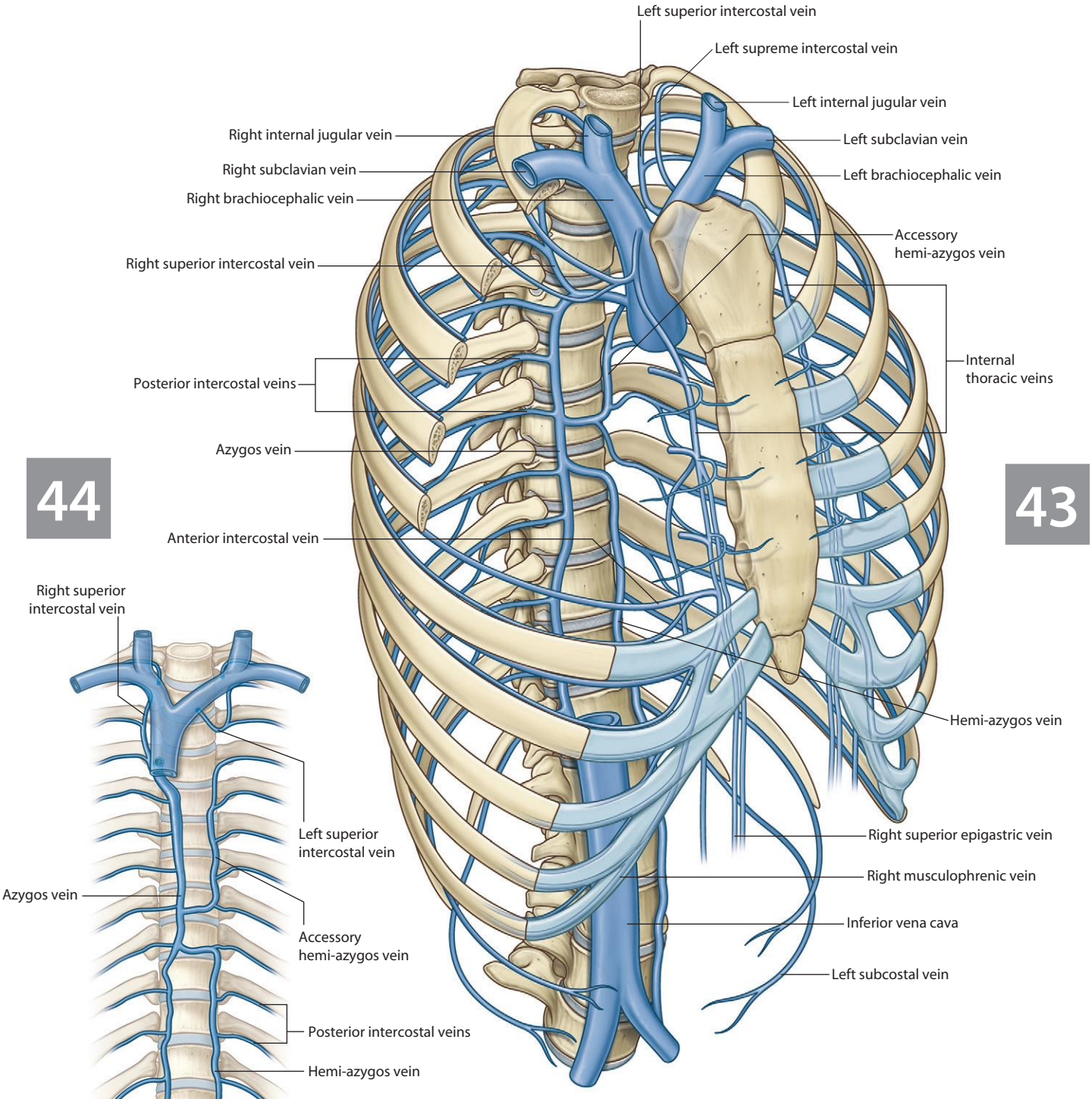

Azygos system of veins

Veins of the thoracic wall

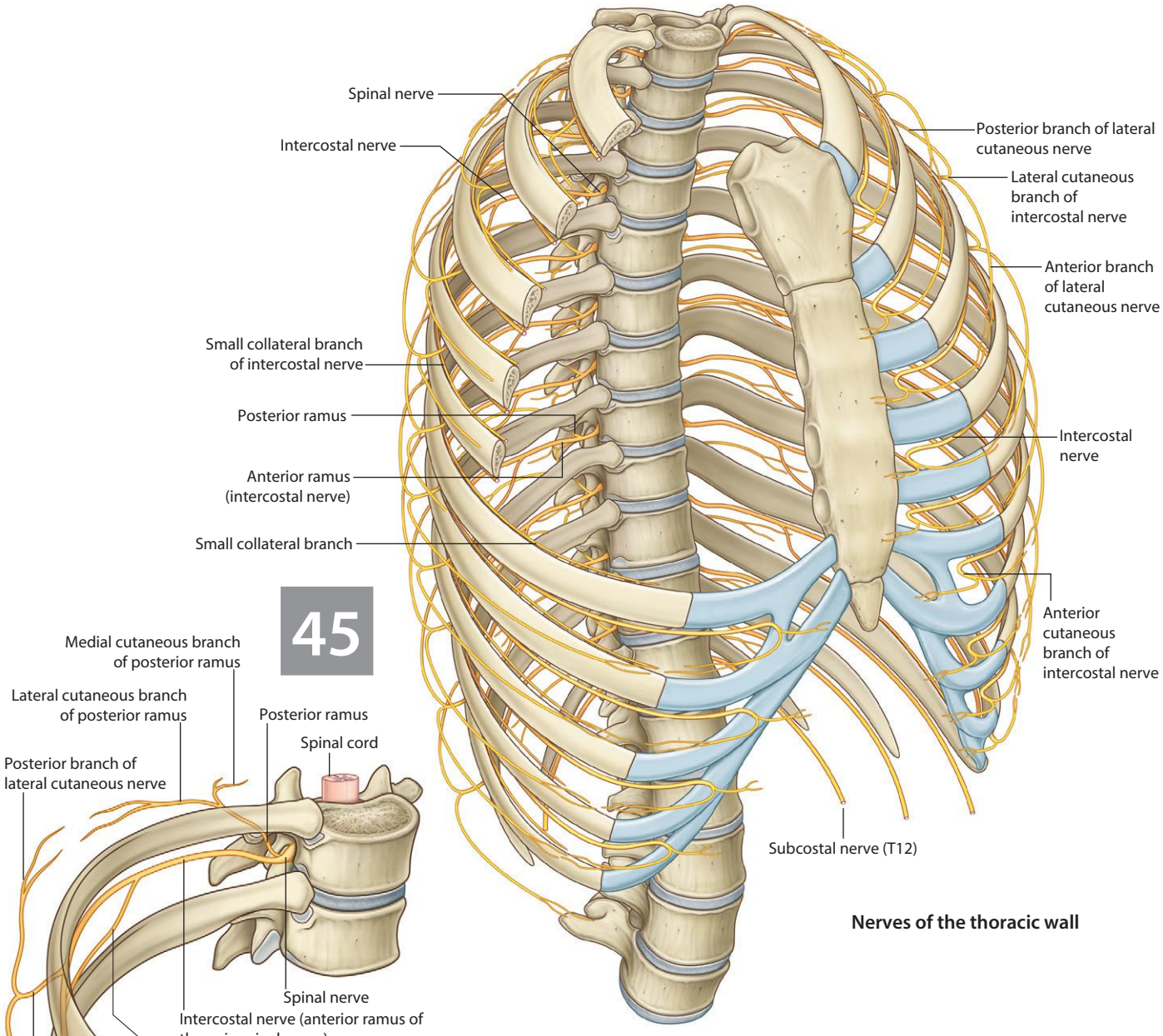

Nerves of the thoracic wall

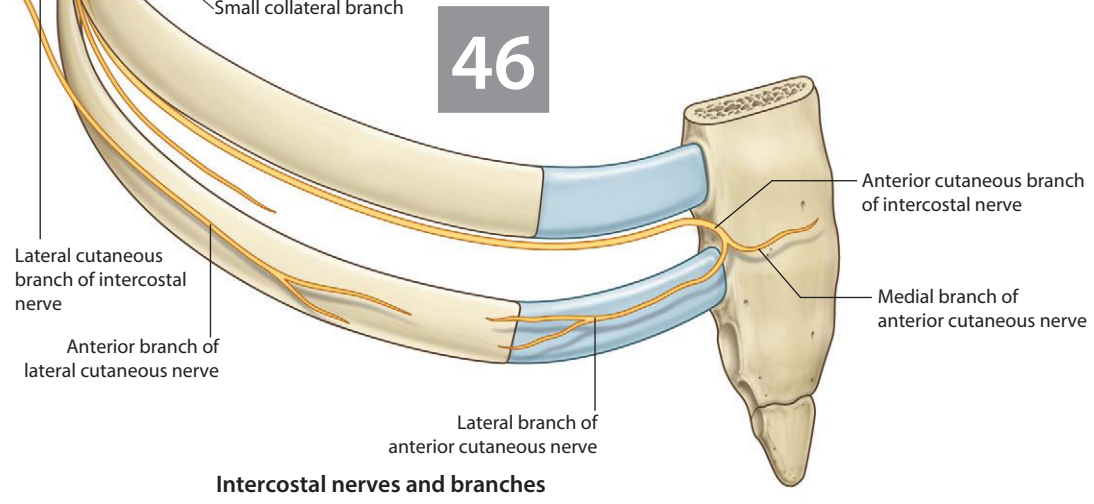

Intercostal nerves and branches

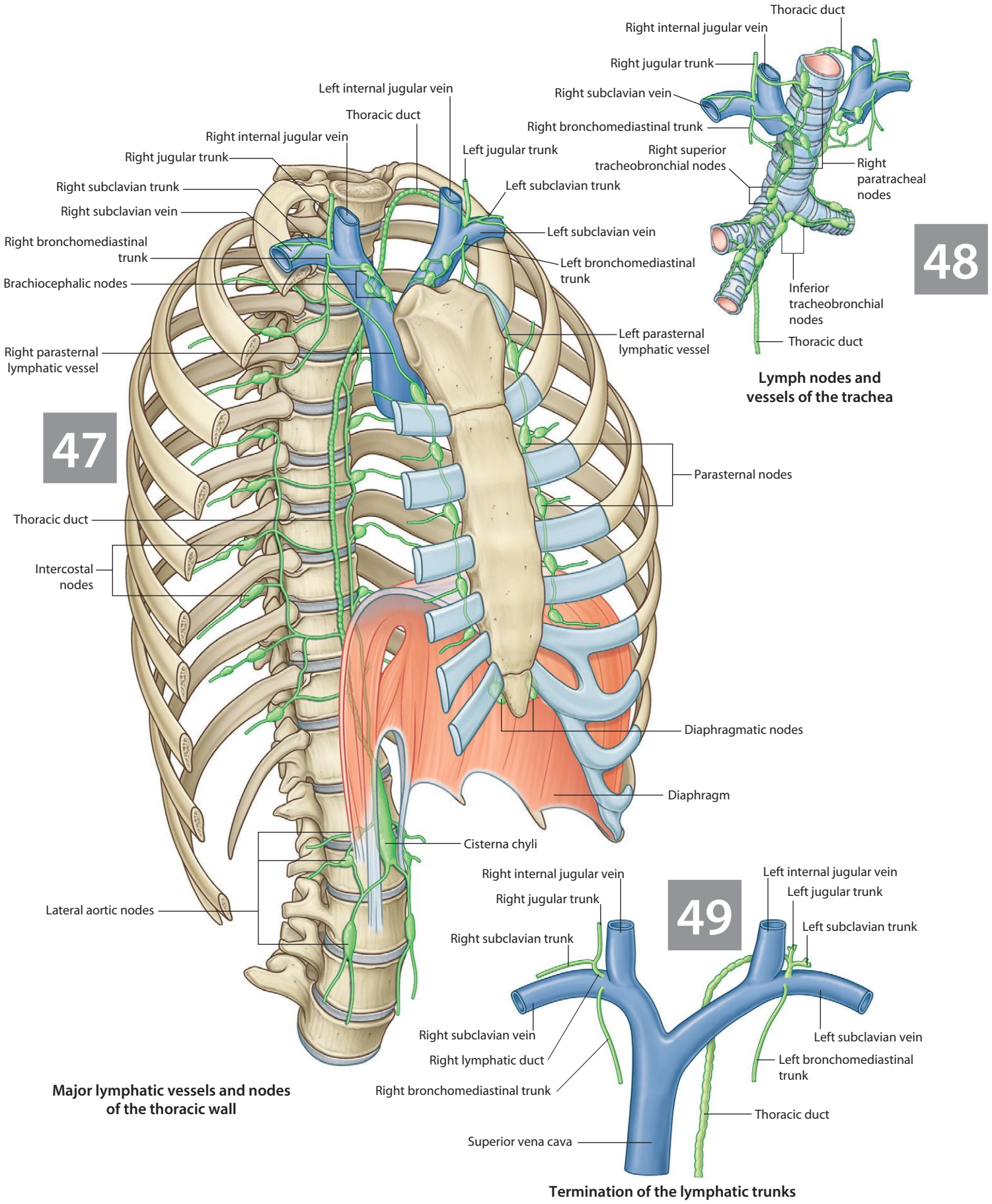
Thoracic duct
Right internal jugular vein
Right jugular trunk
Right subclavian vein
Right bronchomediastinal trunk
Right superior tracheobronchial nodes
Right paratracheal nodes
Inferior tracheobronchial nodes
Thoracic duct
48
Lymph nodes and vessels of the trachea
Left internal jugular vein
Thoracic duct
Right internal jugular vein
Right jugular trunk
Left jugular trunk
Right subclavian trunk
Left subclavian trunk
Right subclavian vein
Left subclavian vein
Right bronchomediastinal trunk
Left bronchomediastinal trunk
Brachiocephalic nodes
Left parasternal lymphatic vessel
Right parasternal lymphatic vessel
47
Parasternal nodes
Thoracic duct
Intercostal nodes
Diaphragmatic nodes
Diaphragm
Cisterna chyli
Lateral aortic nodes
Major lymphatic vessels and nodes of the thoracic wall
Right internal jugular vein
Left internal jugular vein
Right jugular trunk
Left jugular trunk
49
Right subclavian trunk
Left subclavian trunk
Right subclavian vein
Left subclavian vein
Right lymphatic duct
Left bronchomediastinal trunk
Right bronchomediastinal trunk
Thoracic duct
Superior vena cava
Termination of the lymphatic trunks

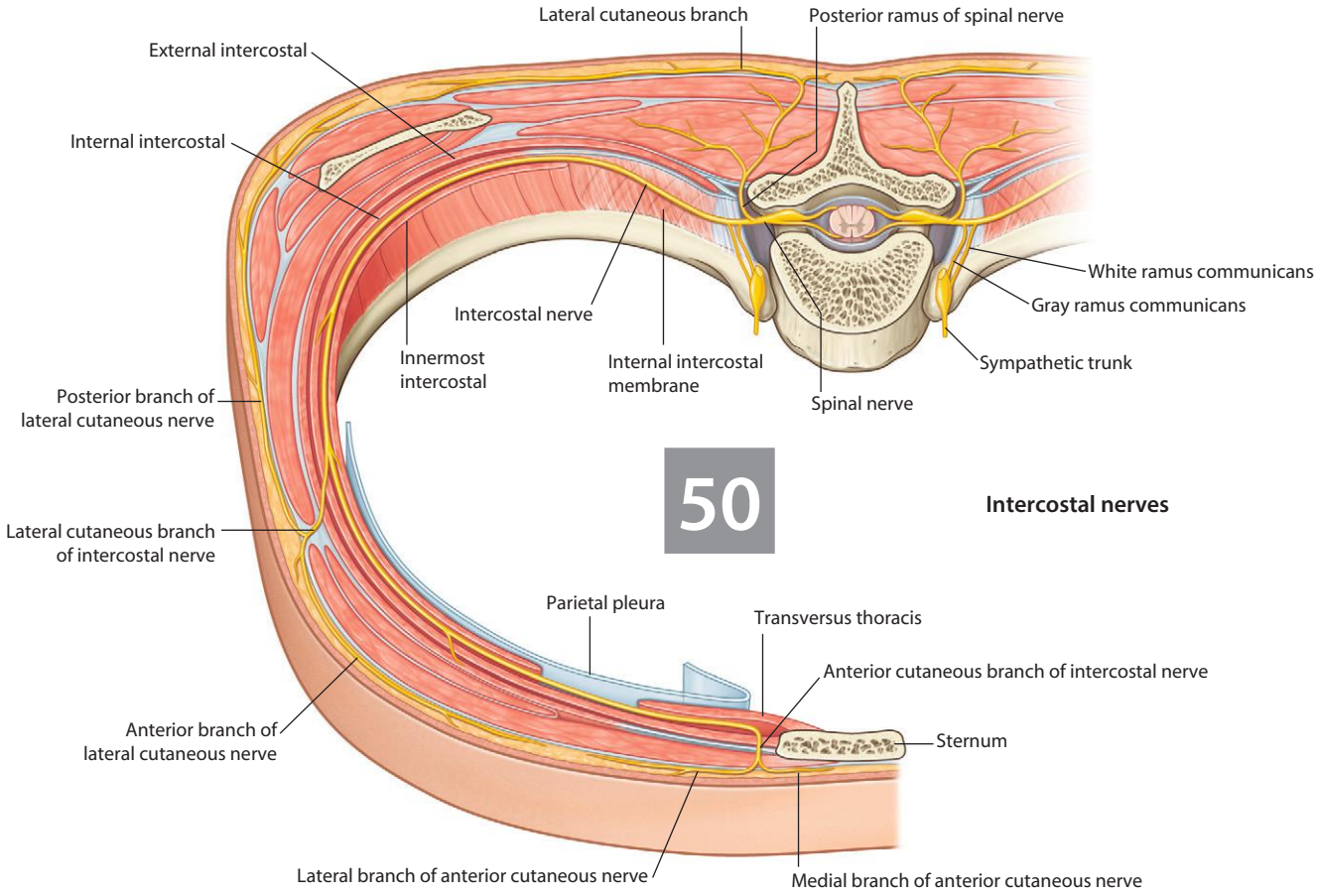

50 **Intercostal nerves**

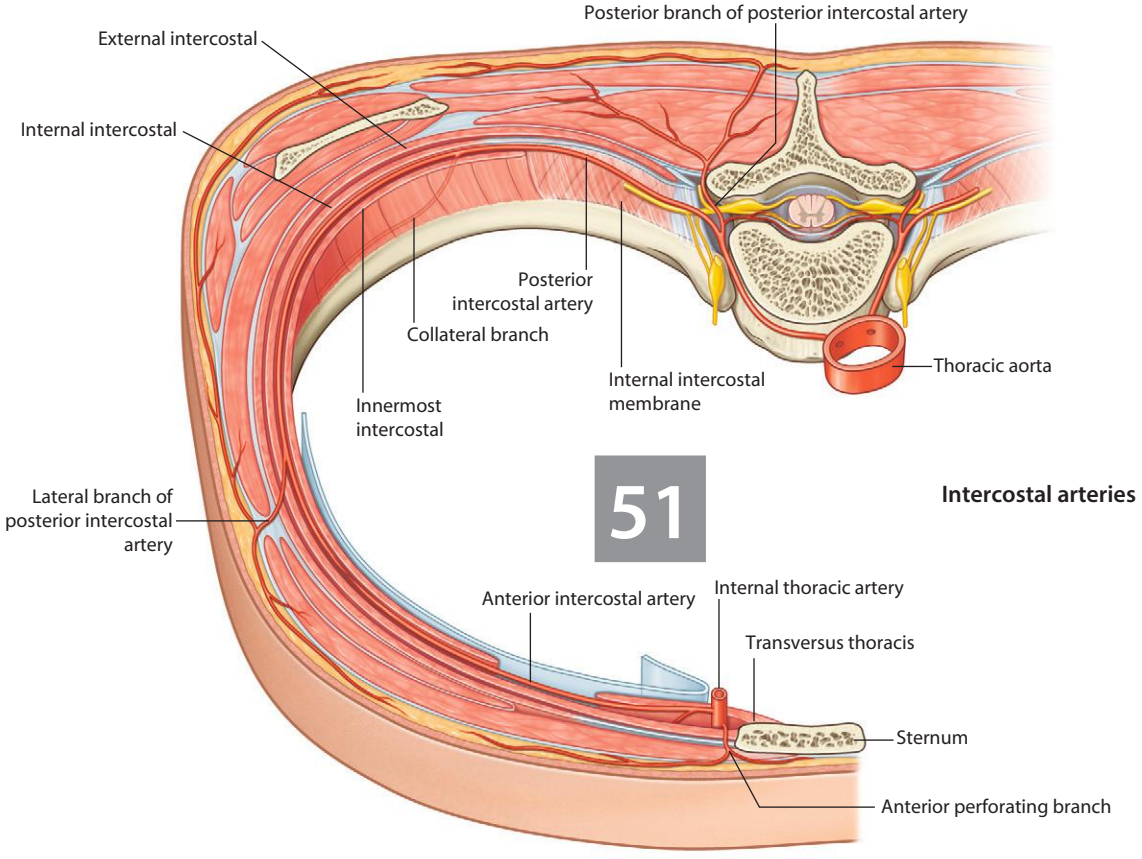

51 **Intercostal arteries**

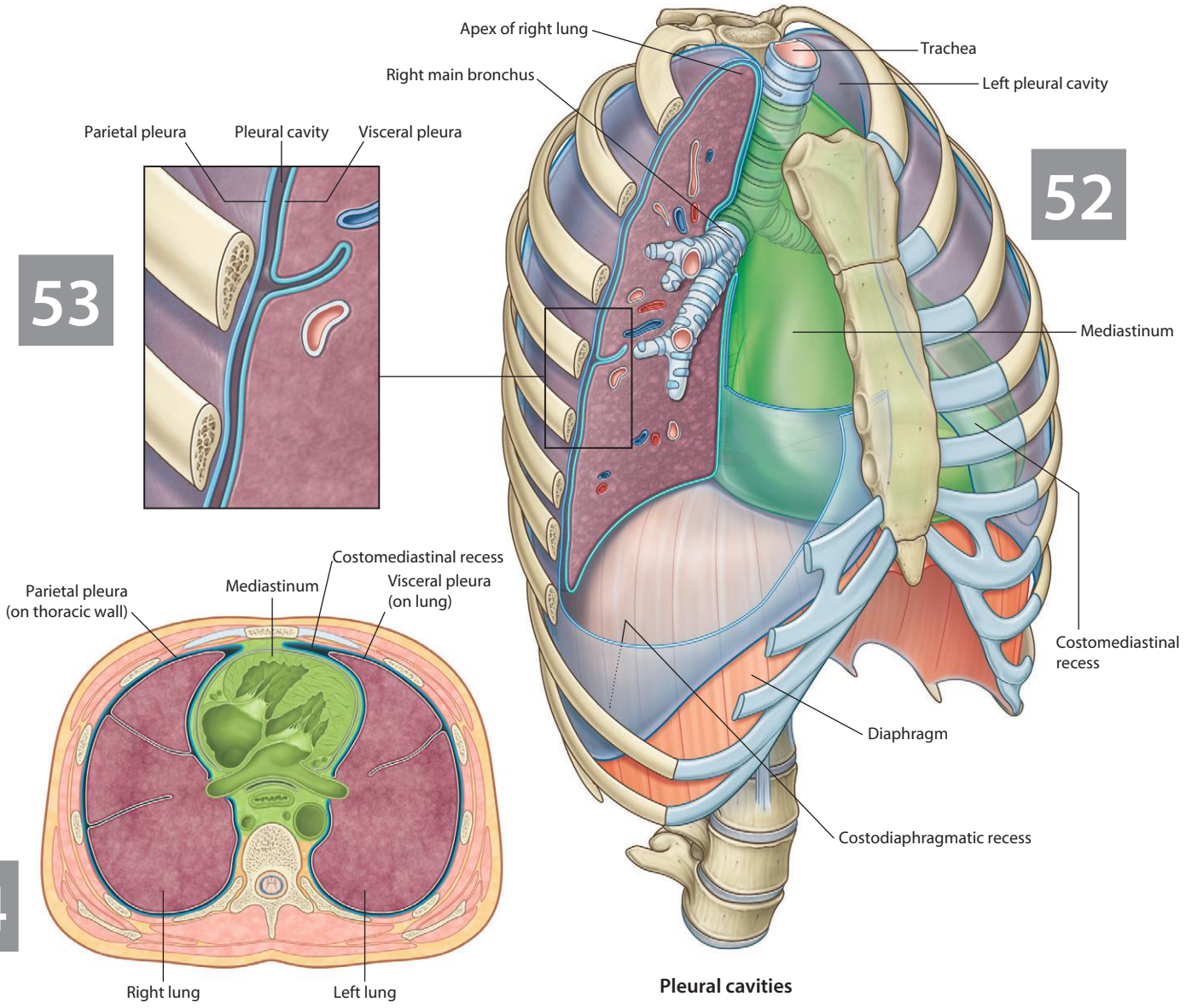

Pleural cavities

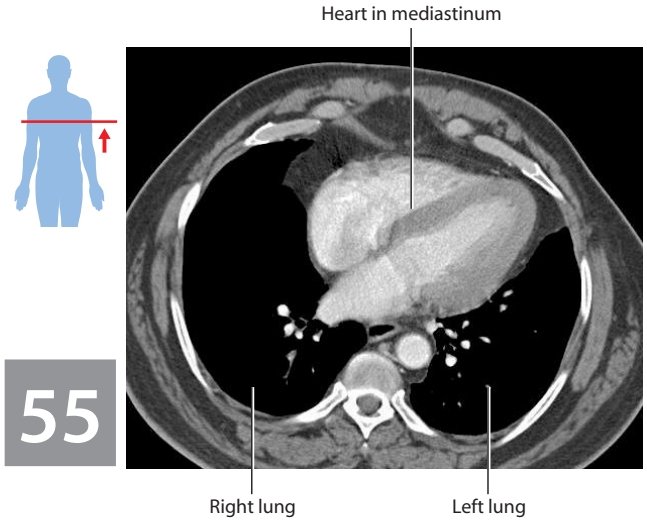

Organization of the thoracic cavity.
CT image, with contrast, in axial plane

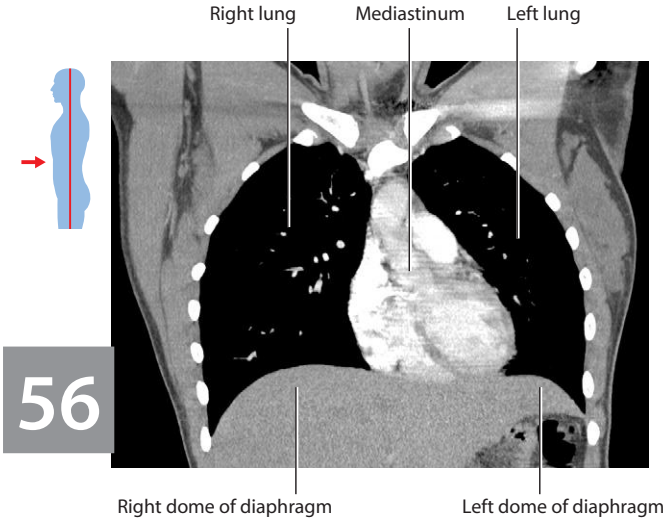

Organization of the thoracic cavity.
CT image, with contrast, in coronal plane

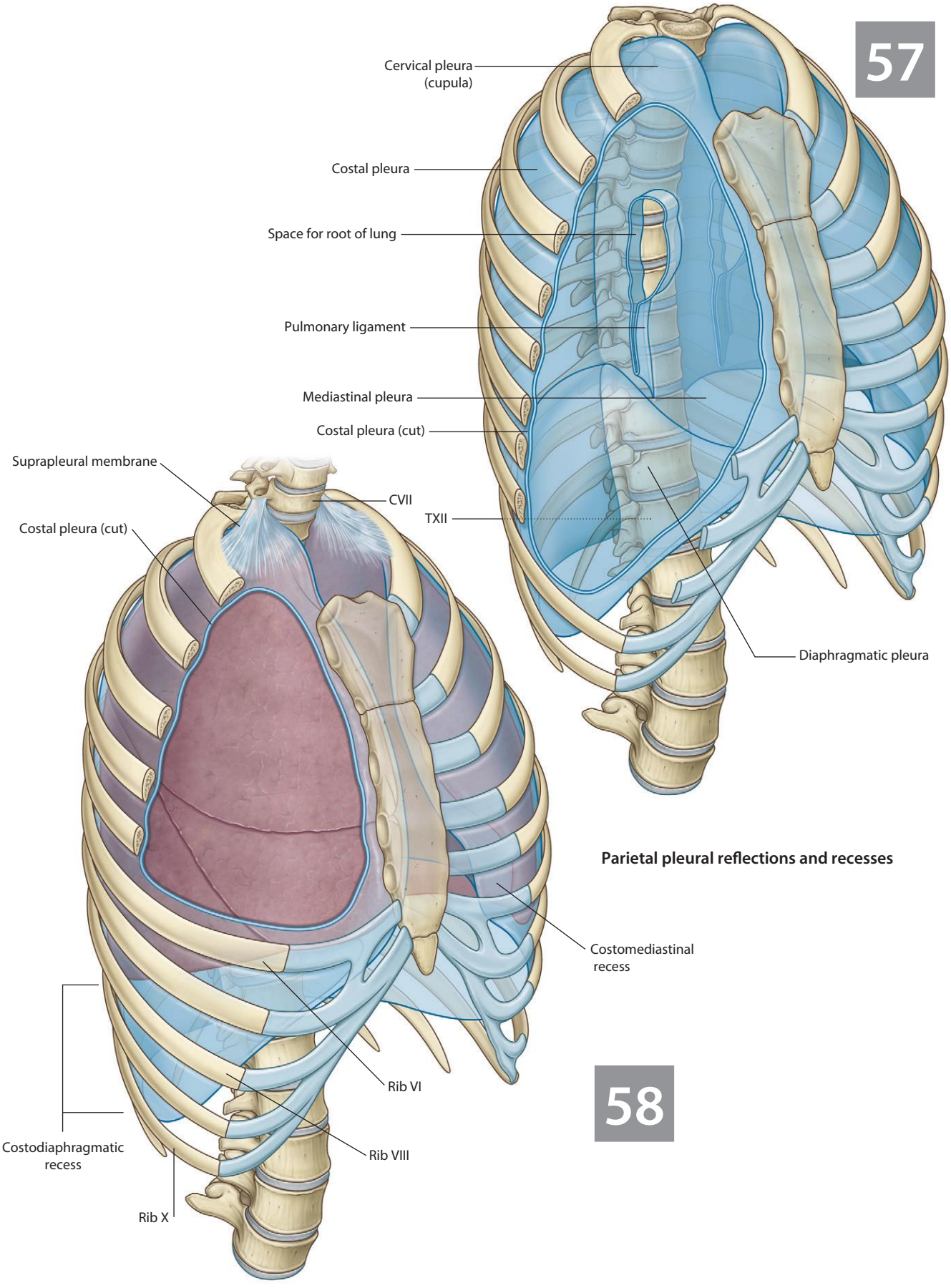

Parietal pleural reflections and recesses

59

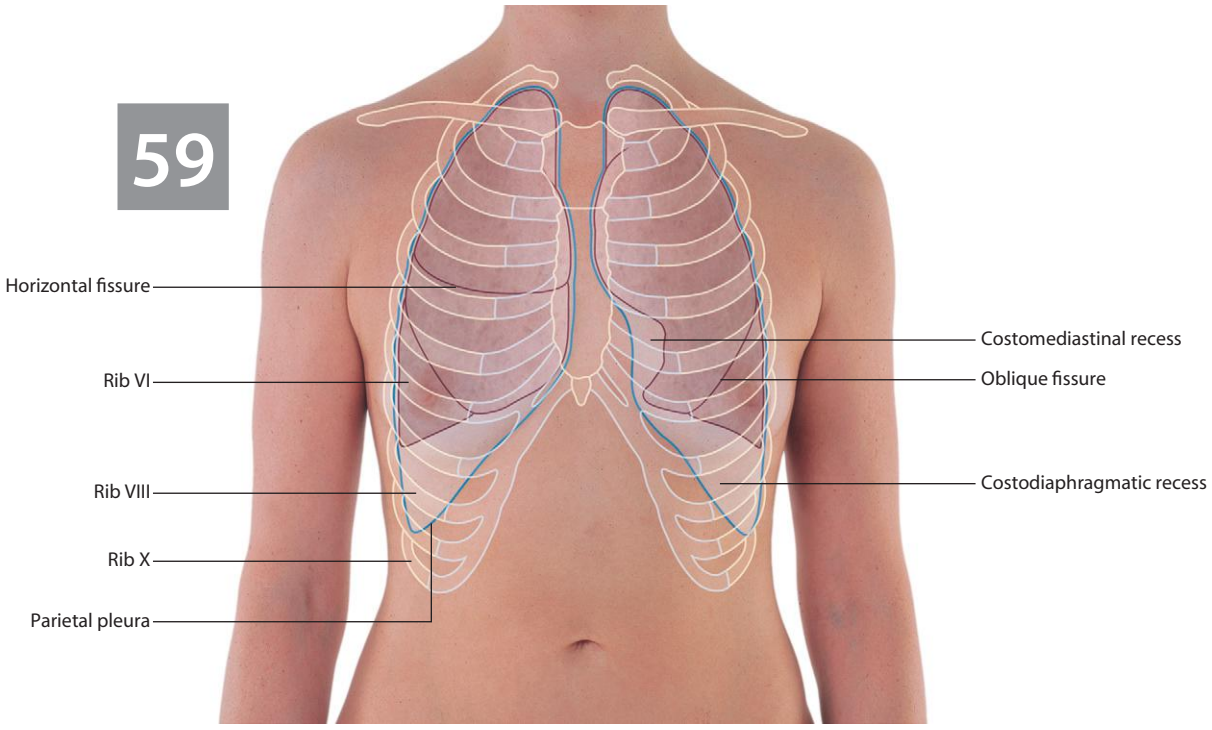

Surface projections of the pleura and lungs (anterior view)

60

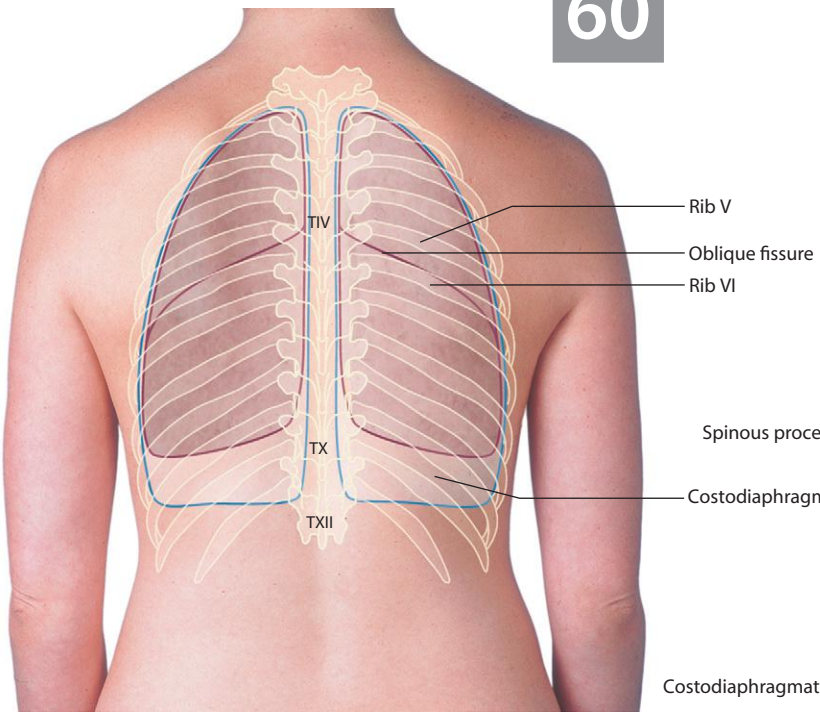

Surface projections of the pleura and lungs (posterior view)

61

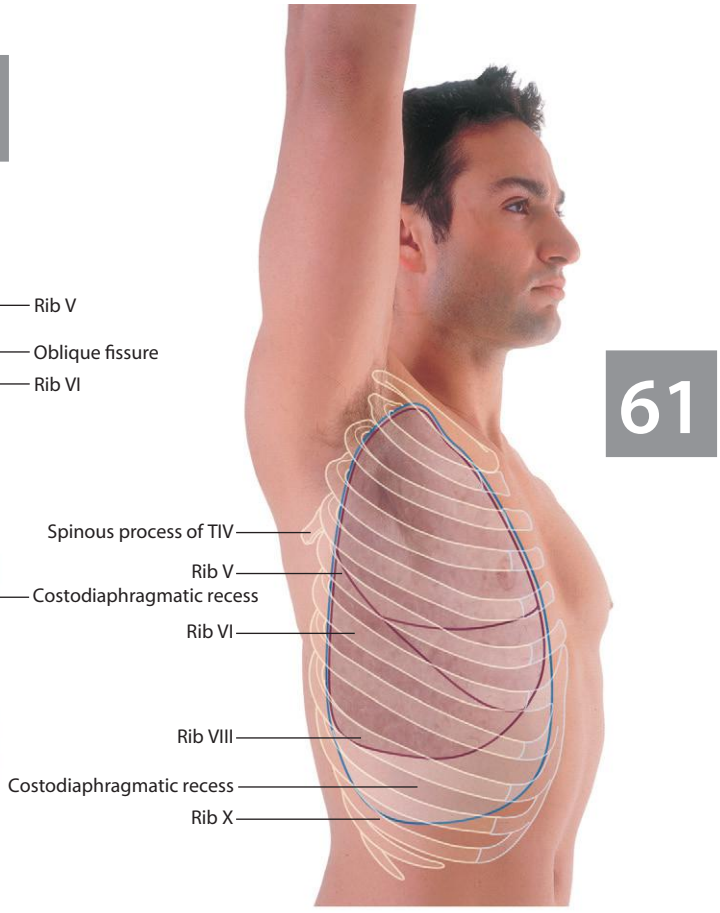

Surface projections of the pleura and right lung (lateral view)

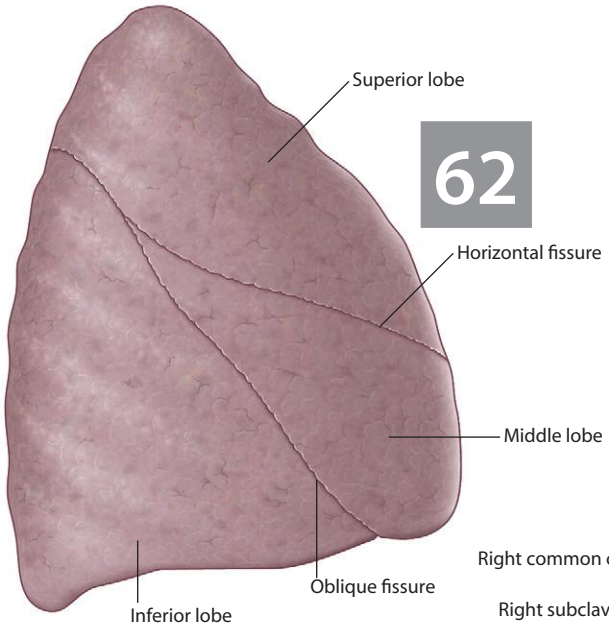

Right lung (lateral view)

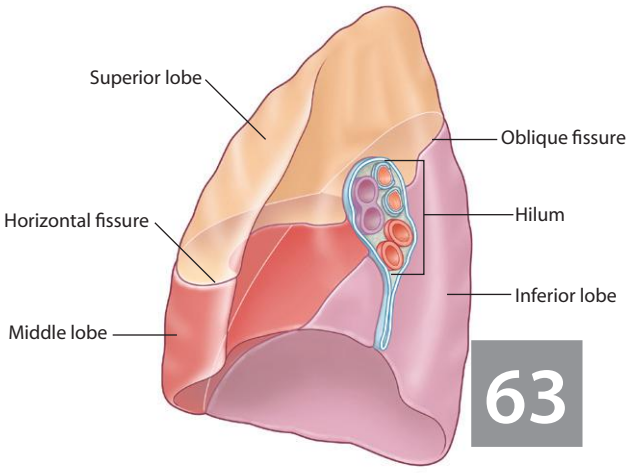

Lobes of the right lung (anteromedial view)

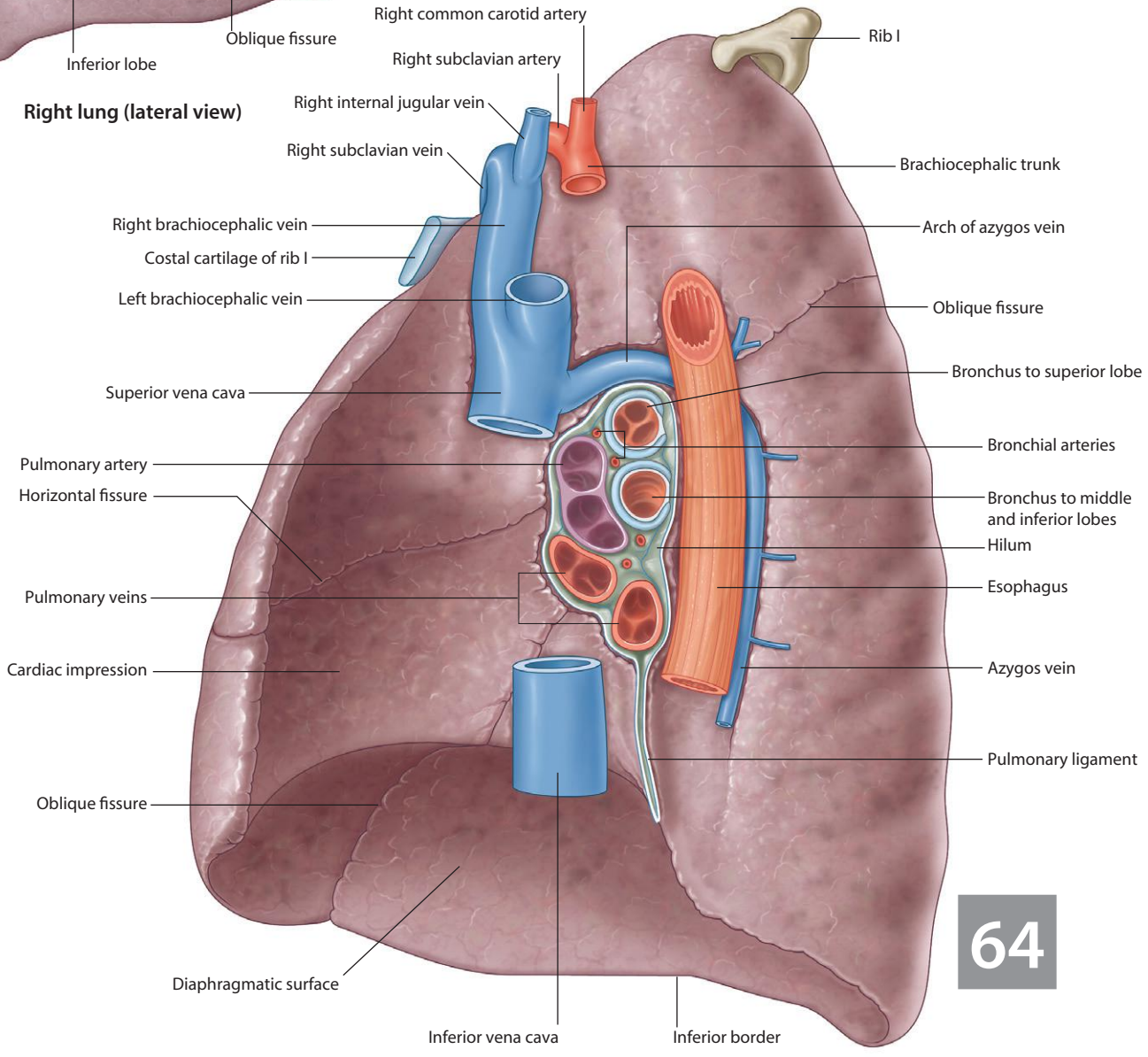

Right lung and related structures (medial view)

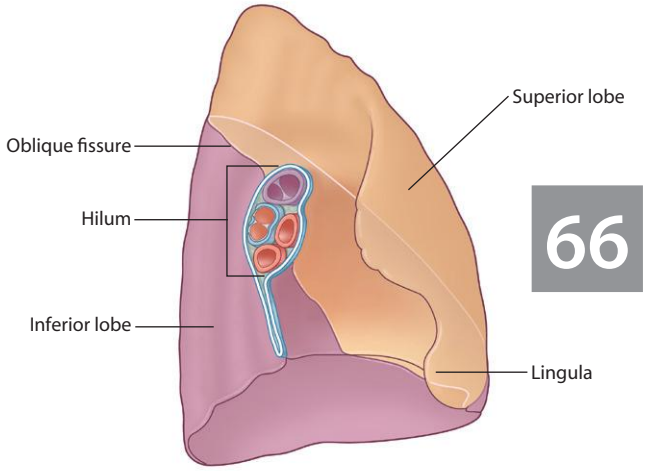

66

Lobes of the left lung (anteromedial view)

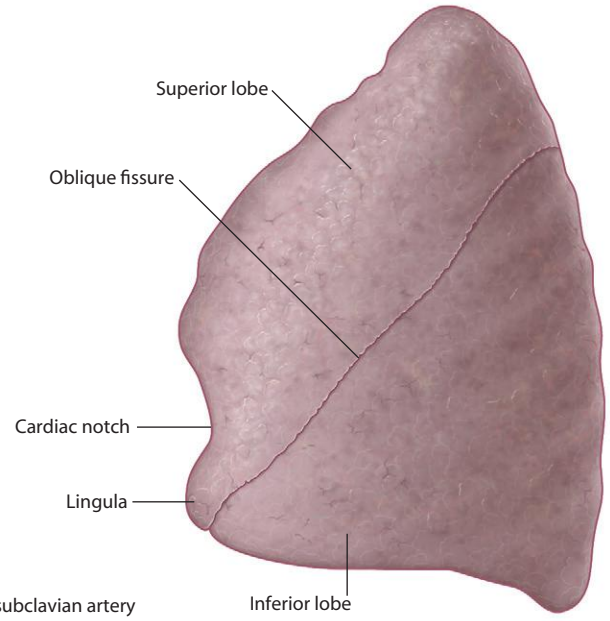

65

Left lung (lateral view)

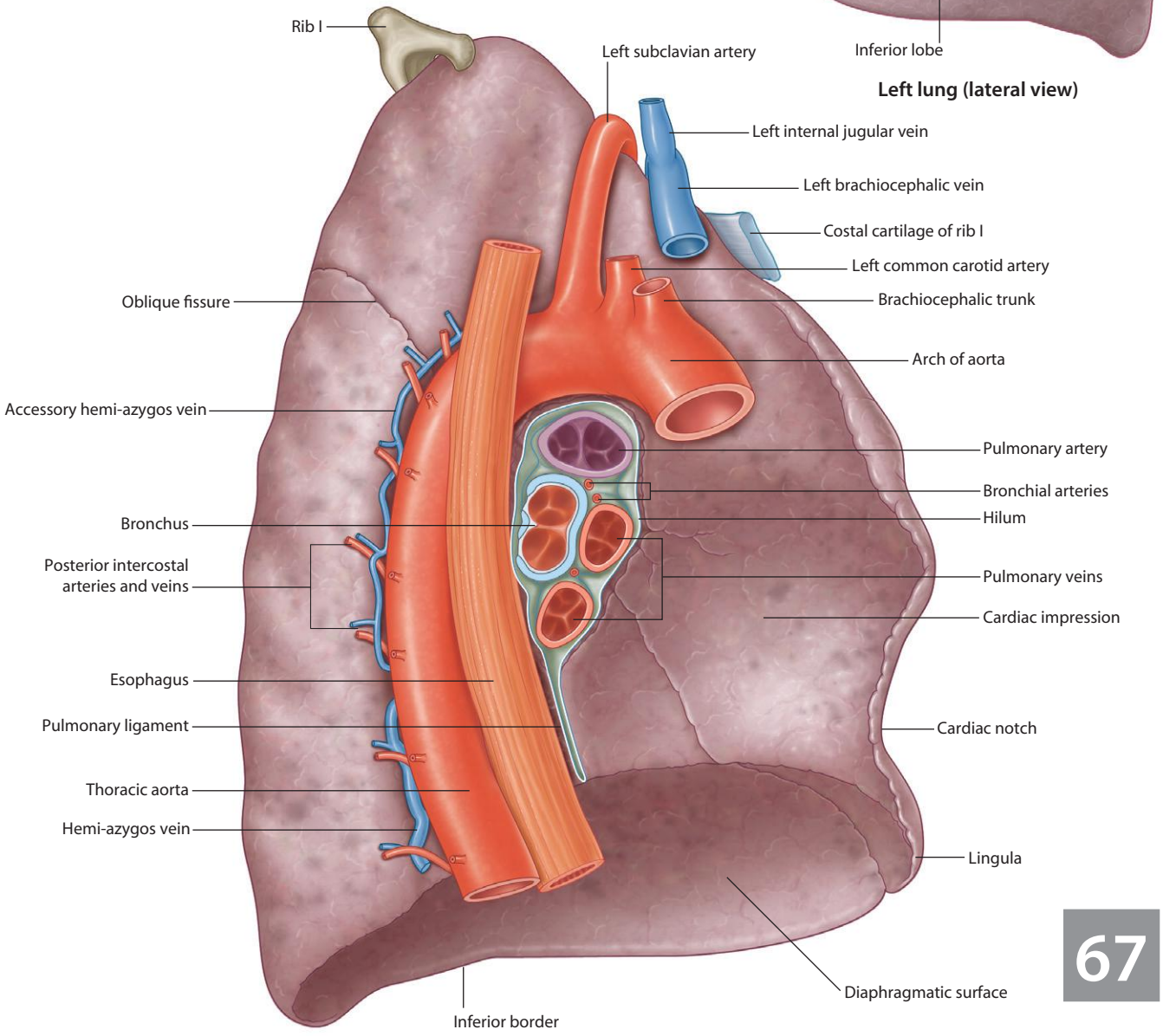

67

Left lung and related structures (medial view)

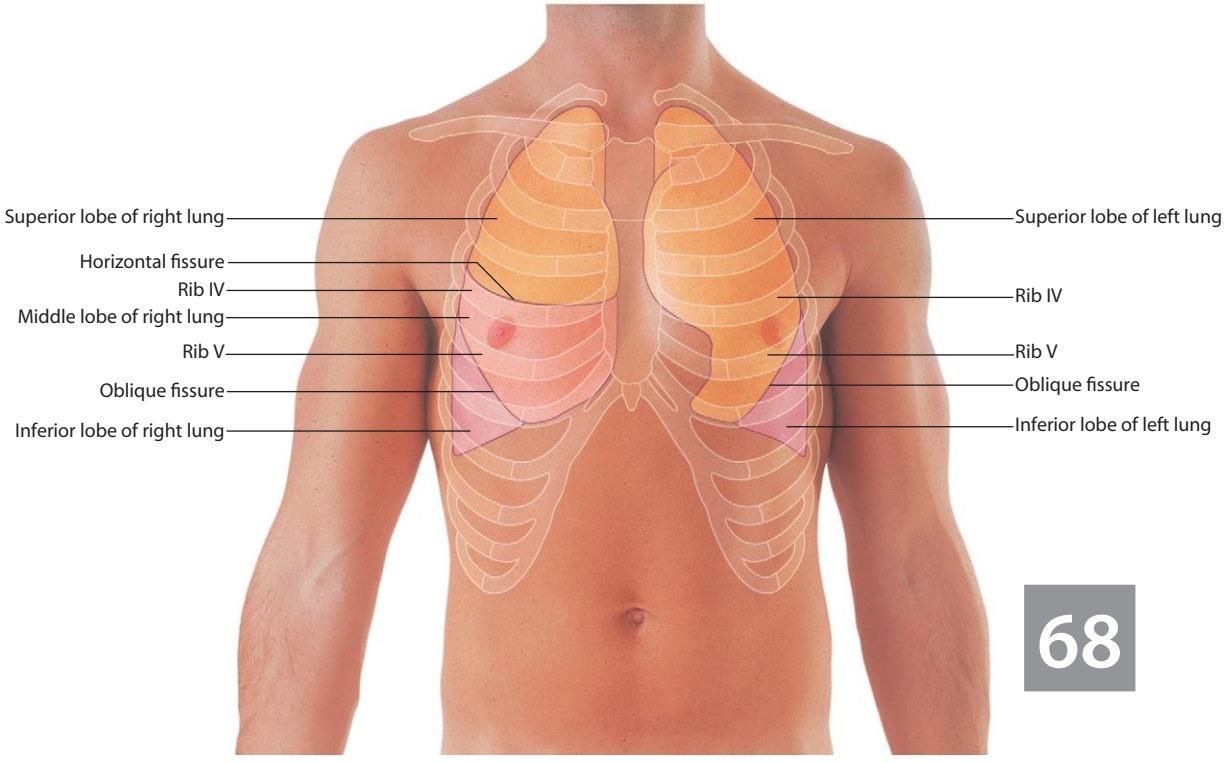

68

Surface projections of the lobes and fissures of the lungs (anterior view)

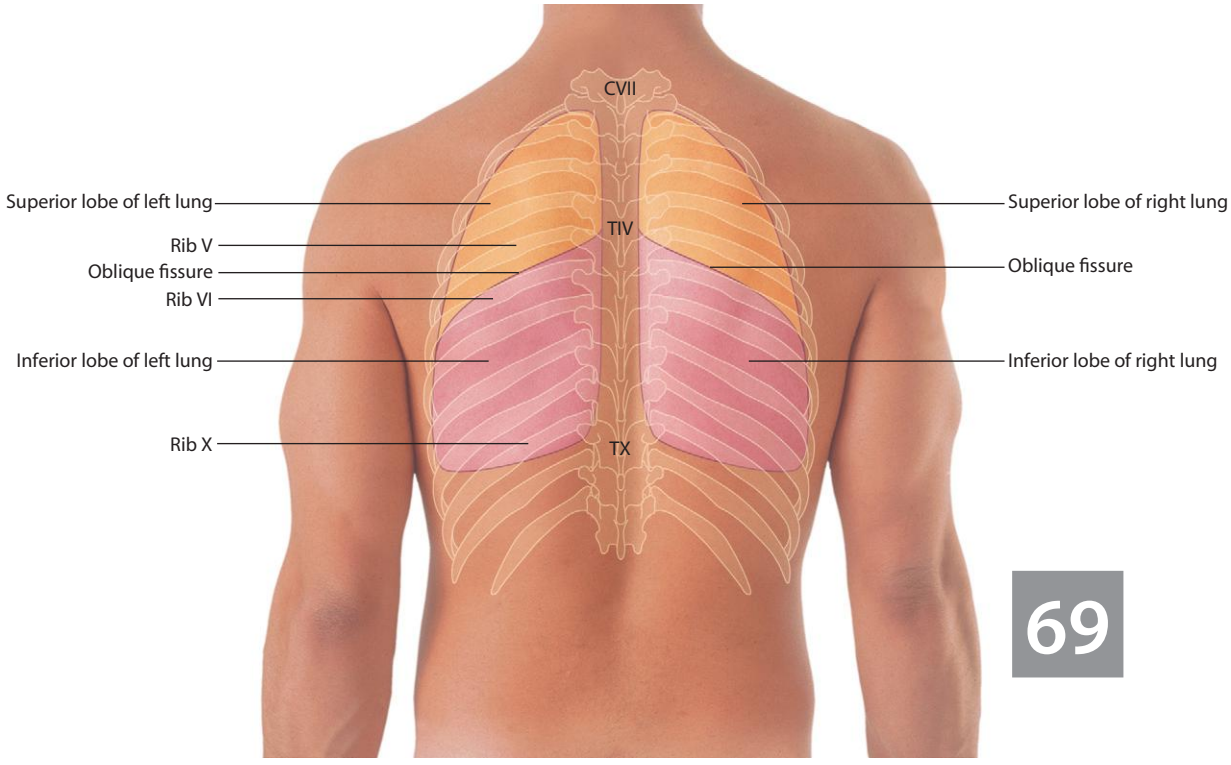

69

Surface projections of the lobes and fissures of the lungs (posterior view)

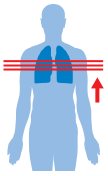

70

Right lung and left lung demonstrating superior and inferior lobes. The oblique fissures are visible.
CT image, with contrast, in axial plane

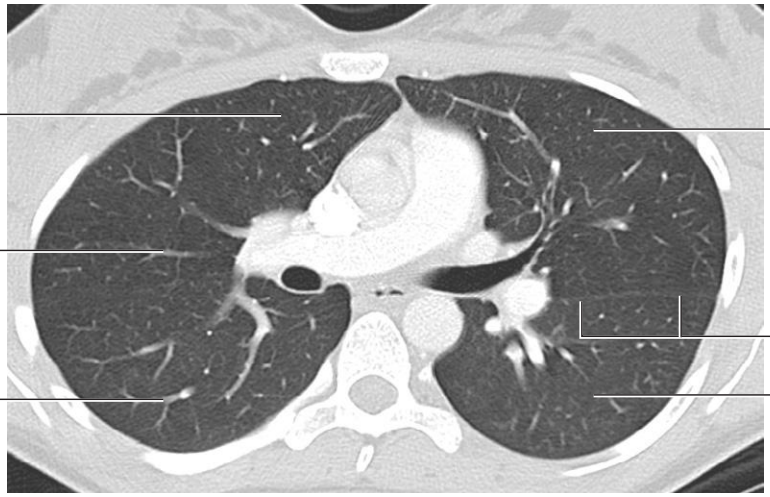

71

Right lung demonstrating superior, middle, and inferior lobes and the left lung demonstrating superior and inferior lobes. The oblique fissure associated with the left lung is visible.
CT image, with contrast, in axial plane

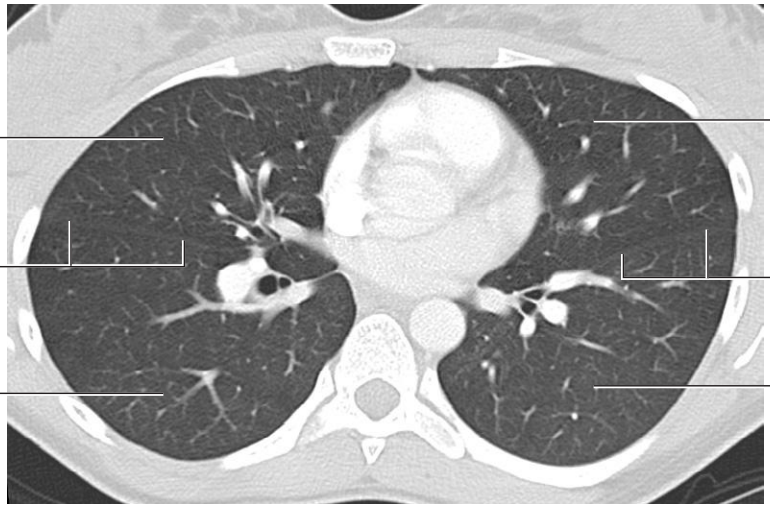

72

Right lung demonstrating middle and inferior lobes and the left lung demonstrating superior and inferior lobes. The oblique fissures are visible.
CT image, with contrast, in axial plane

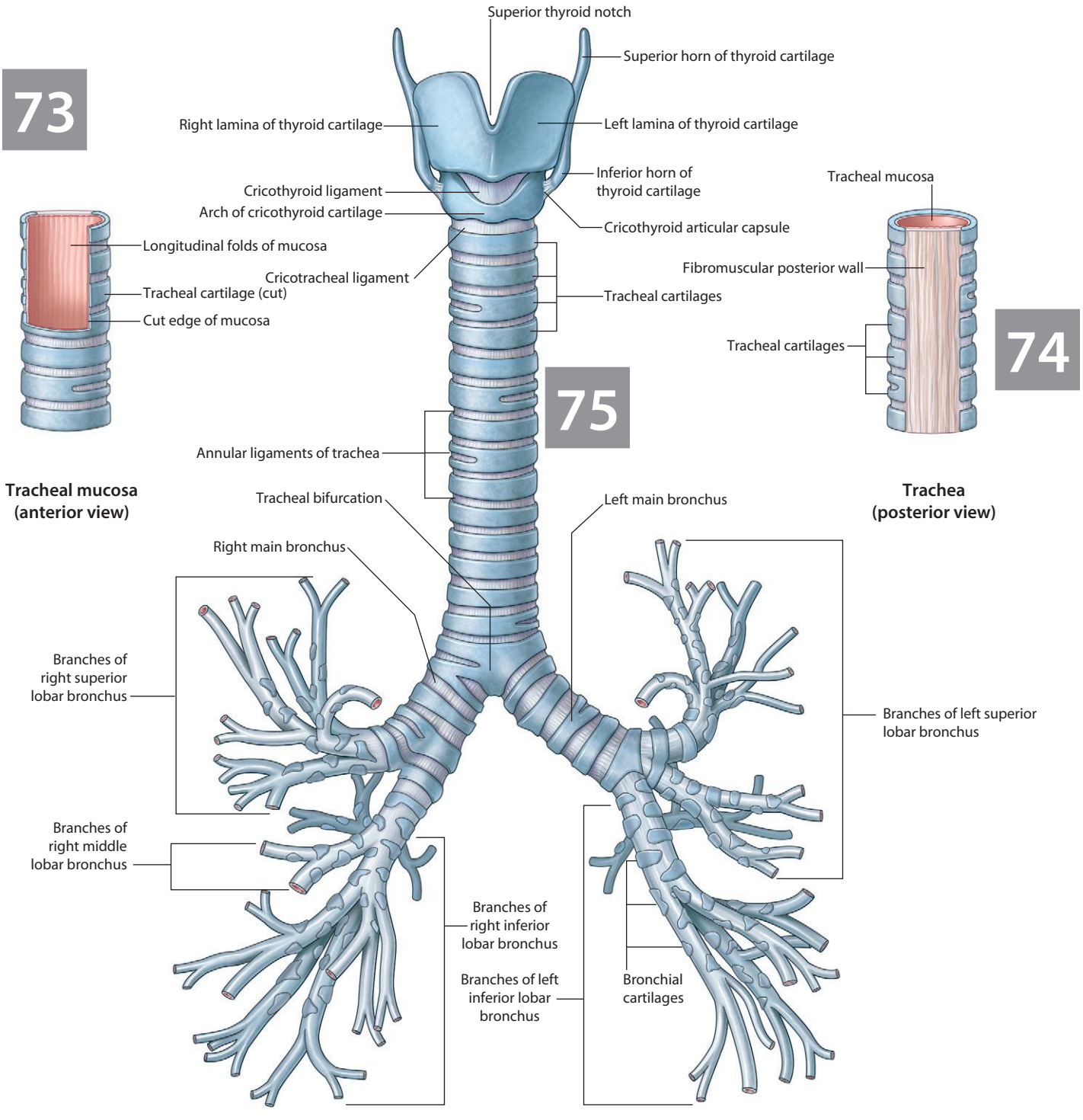

Trachea and bronchial tree

76

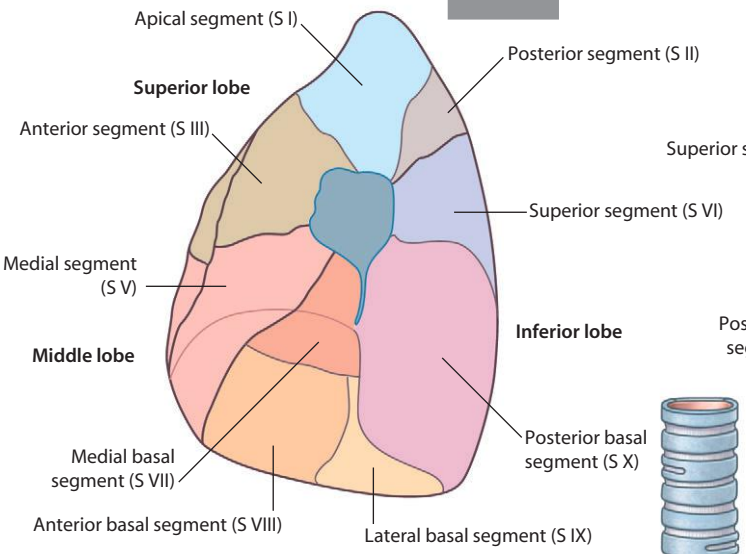

Right lung (medial view)

77

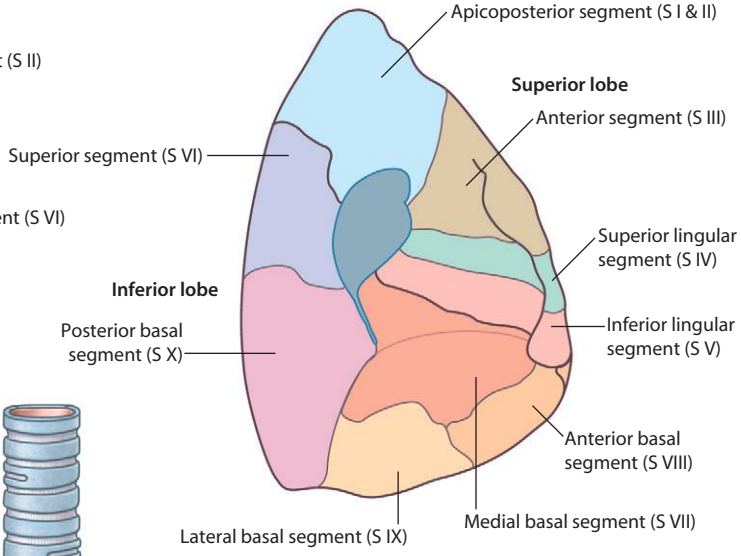

Left lung (medial view)

80

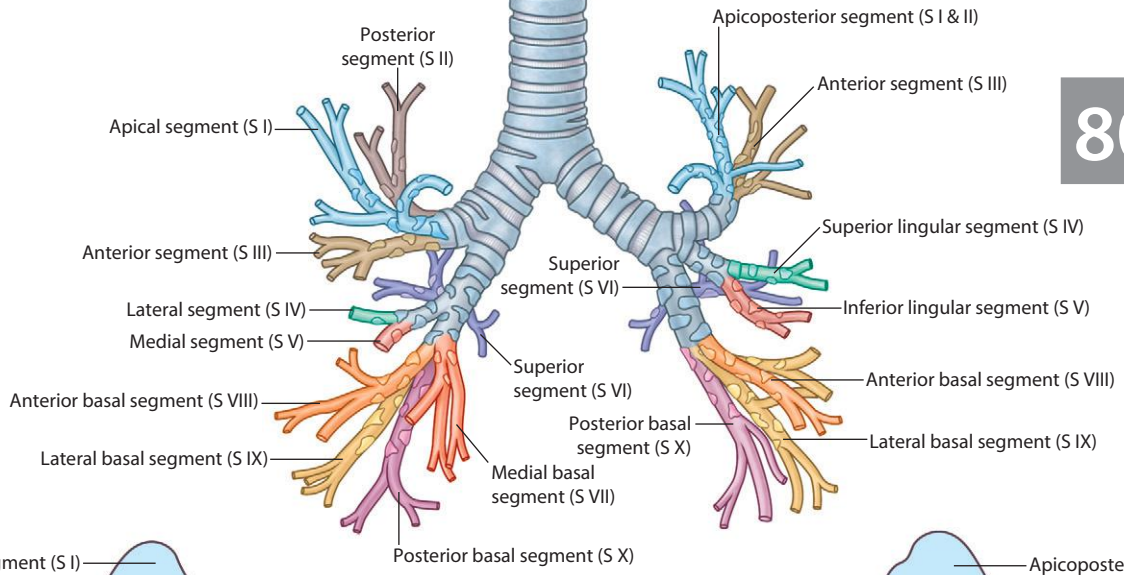

78

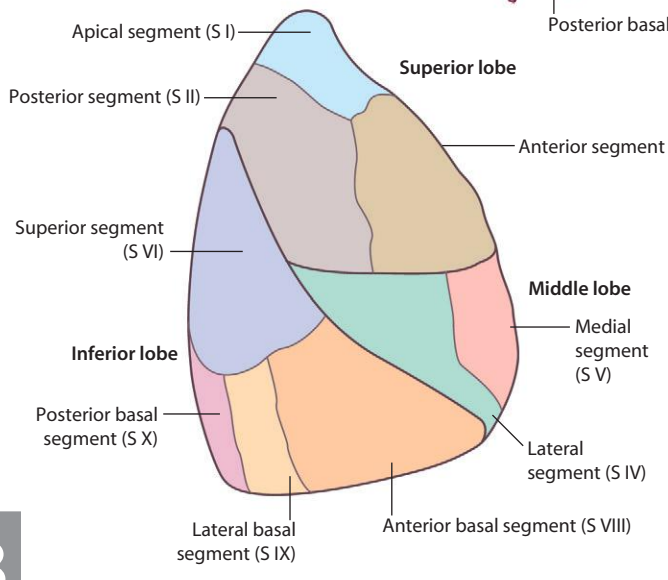

Right lung (lateral view)

79

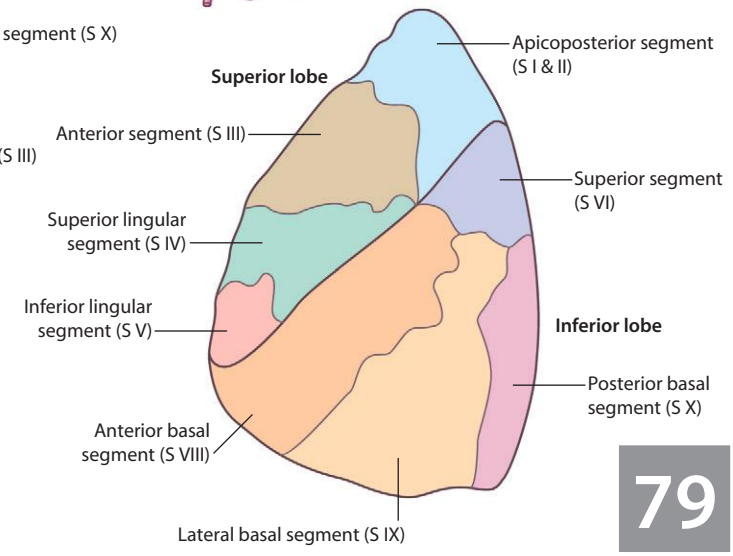

Left lung (lateral view)

Bronchopulmonary segments

81

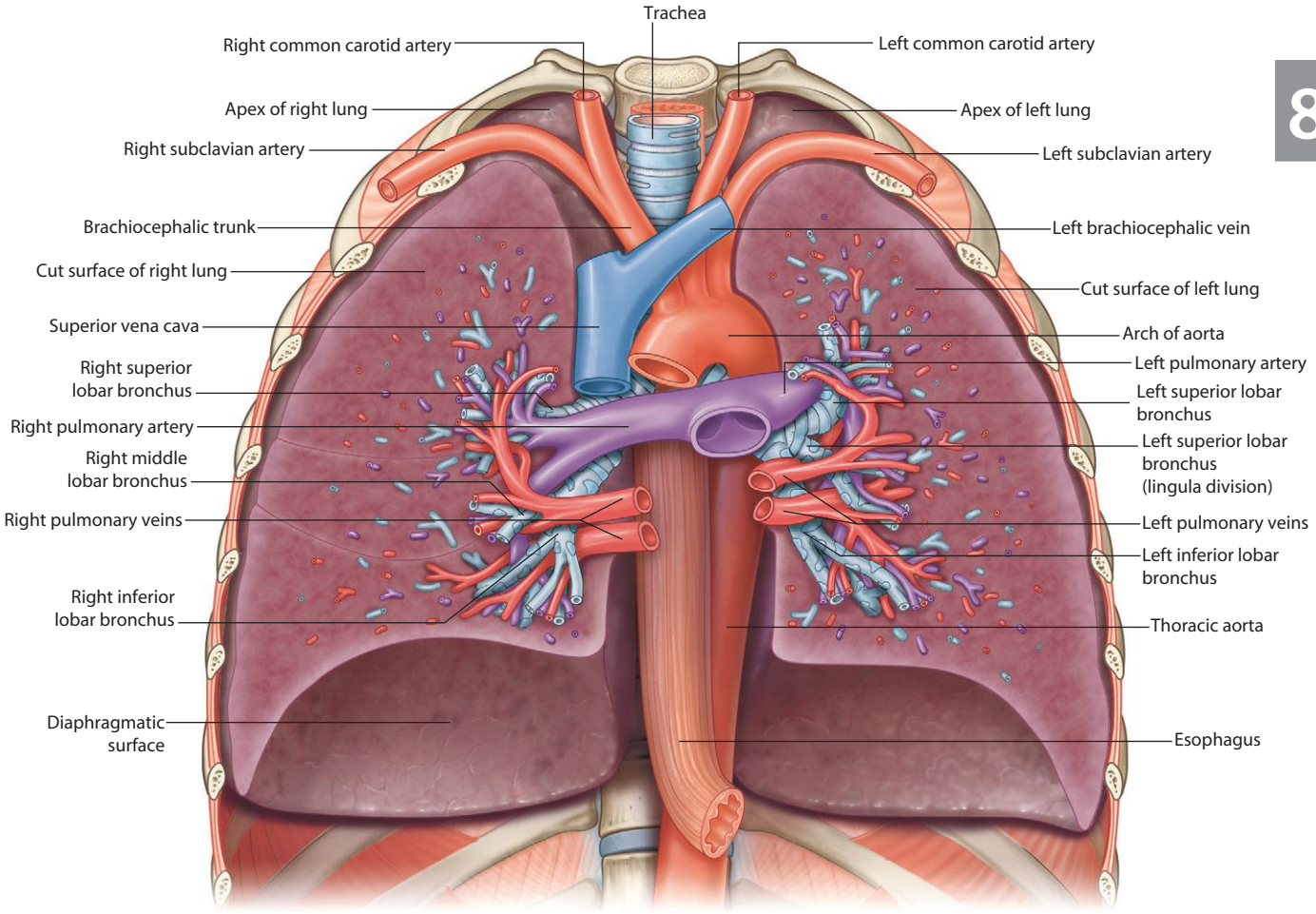

Pulmonary vessels

82

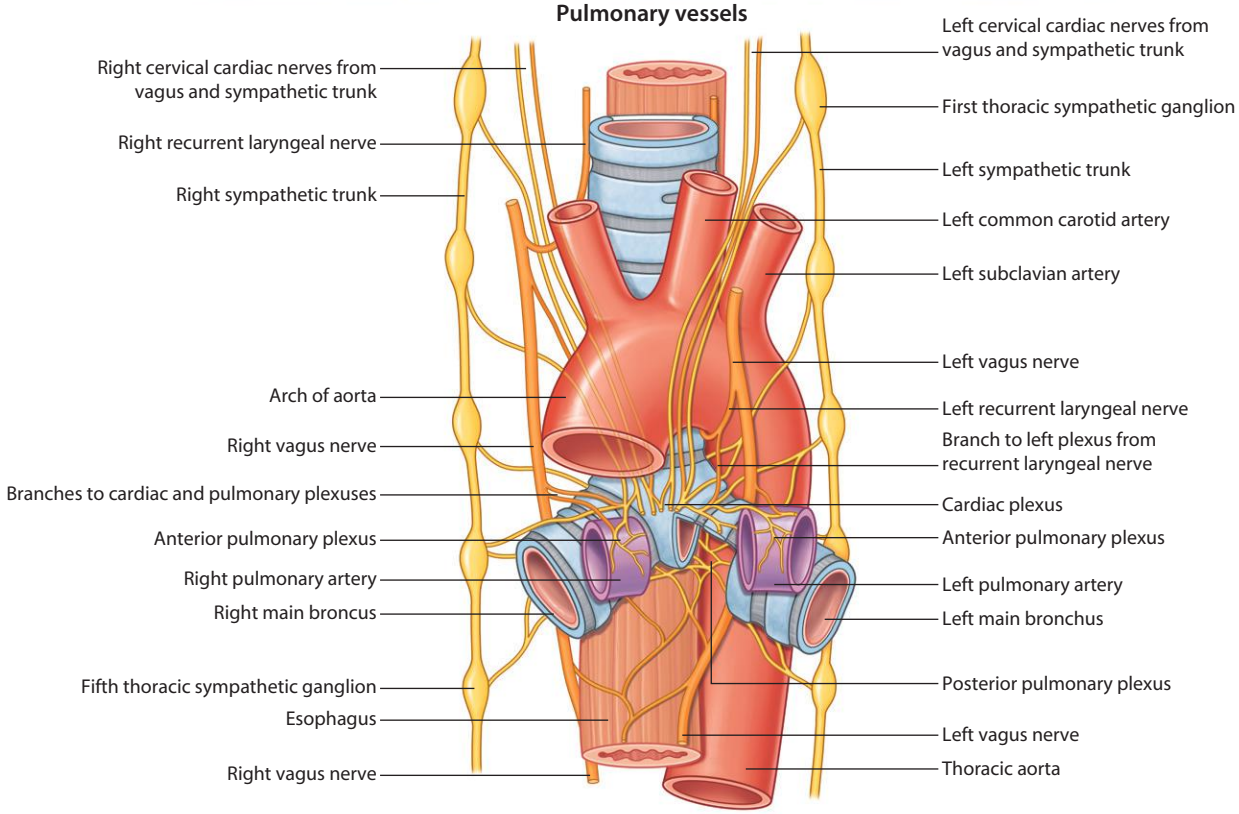

Pulmonary plexus

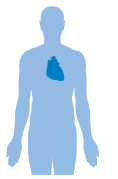

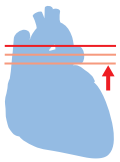

A

83

Ascending aorta
Superior vena cava
Right main bronchus
Esophagus
Pulmonary trunk
Left pulmonary artery
Left main bronchus
Thoracic aorta

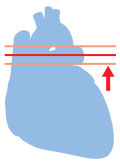

B

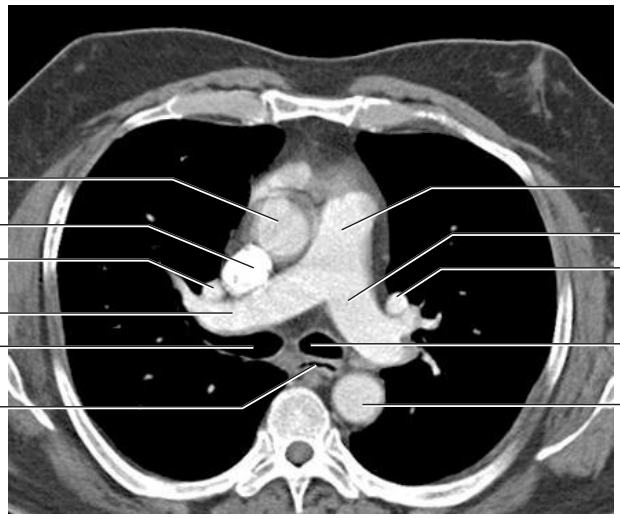

84

Ascending aorta
Superior vena cava
Right superior pulmonary vein
Right pulmonary artery
Right main bronchus
Esophagus
Pulmonary trunk
Left pulmonary artery
Left superior pulmonary vein
Left main bronchus
Thoracic aorta

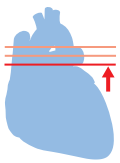

C

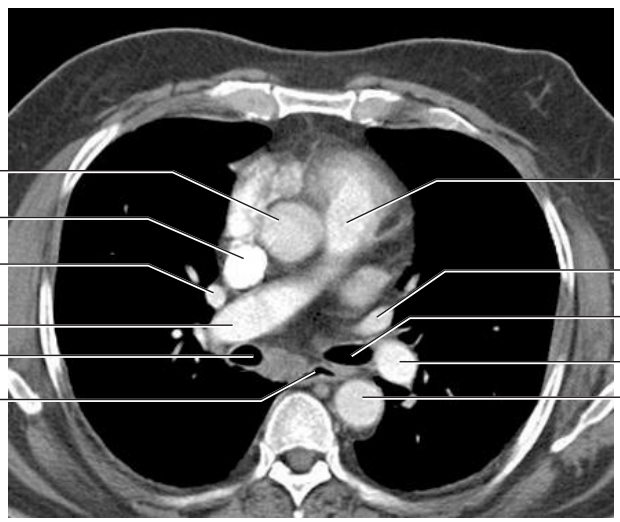

85

Ascending aorta
Superior vena cava
Right superior pulmonary vein
Right pulmonary artery
Right main bronchus
Esophagus
Pulmonary trunk
Left superior pulmonary vein
Left main bronchus
Left pulmonary artery
Thoracic aorta

A through C – Relationships of the pulmonary arteries, pulmonary veins, and bronchi in the mediastinum.
CT images, with contrast, in axial plane

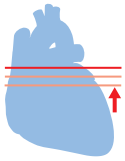

D

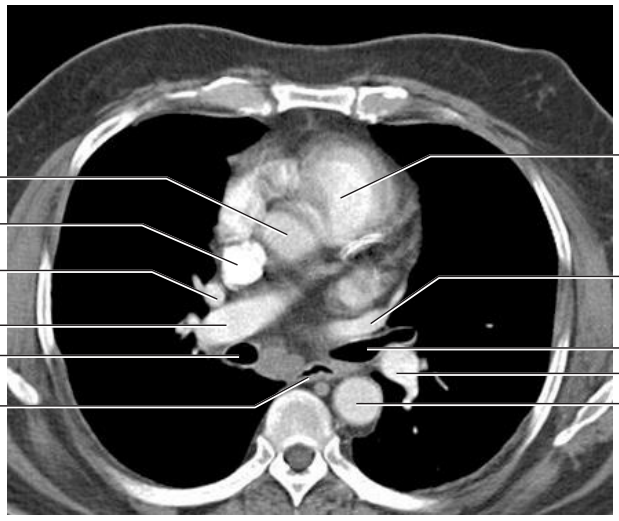

86

Ascending aorta
Superior vena cava
Right superior pulmonary vein
Right pulmonary artery
Right main bronchus
Esophagus

Right ventricle
Left superior pulmonary vein
Left main bronchus
Left pulmonary artery
Thoracic aorta

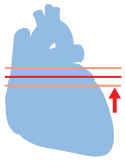

E

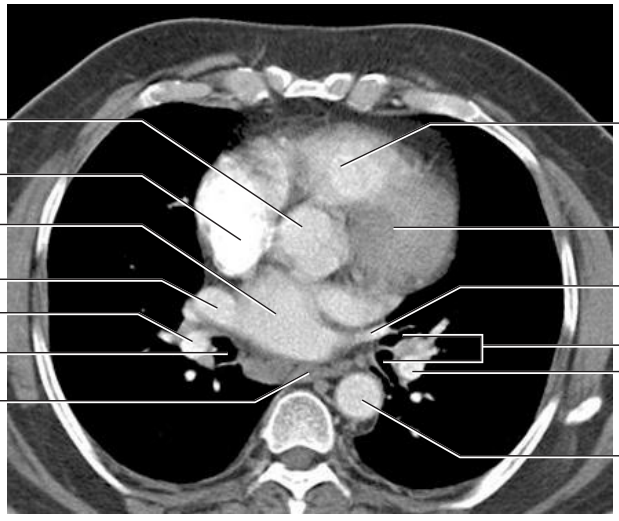

87

Ascending aorta
Right atrium
Left atrium
Right superior pulmonary vein
Right pulmonary artery
Right main bronchus
Esophagus

Right ventricle
Left ventricle
Left superior pulmonary vein
Bronchi
Left pulmonary artery
Thoracic aorta

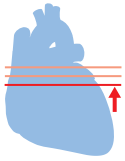

F

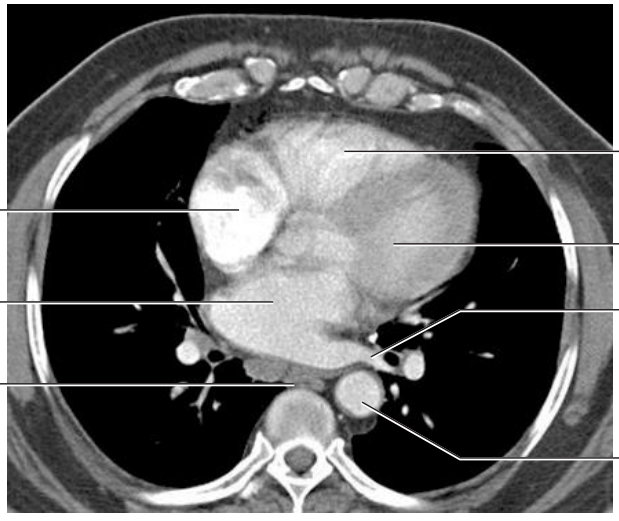

88

Right atrium
Left atrium
Esophagus

Right ventricle
Left ventricle
Left inferior pulmonary vein
Thoracic aorta

D through F – Relationships of the pulmonary arteries, pulmonary veins, and bronchi in the mediastinum.
CT images, with contrast, in axial plane

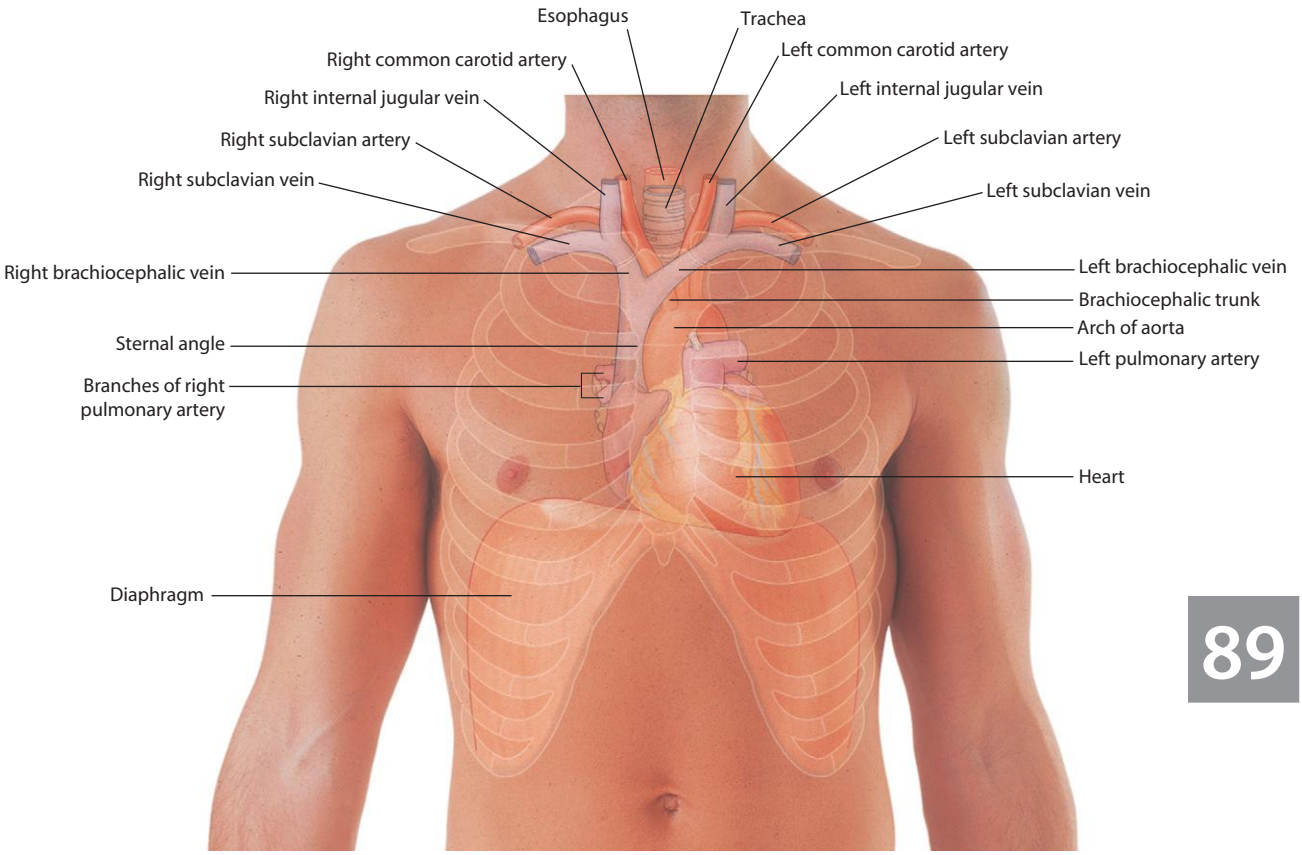

89

Structures of the mediastinum as they relate to the surface

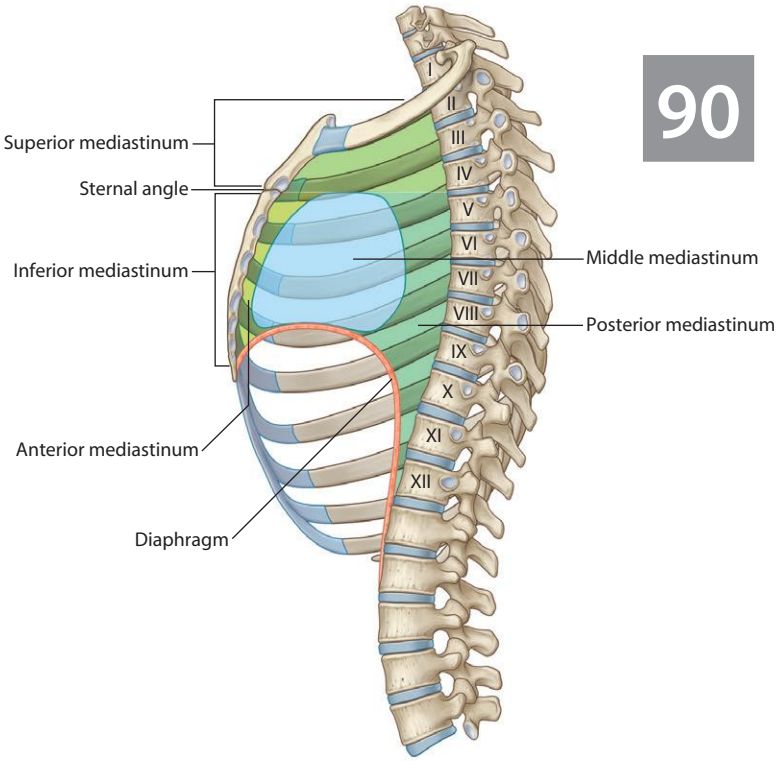

90

Subdivisions of the mediastinum (sagittal section)

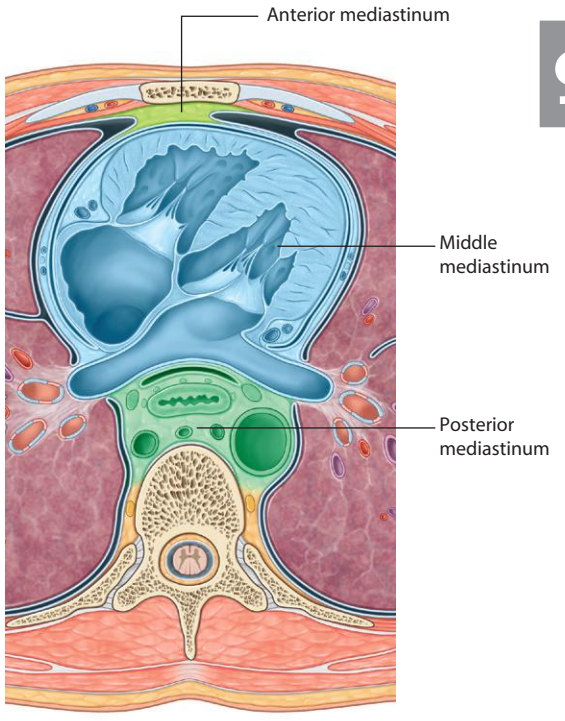

91

Subdivisions of the mediastinum (transverse section)

92

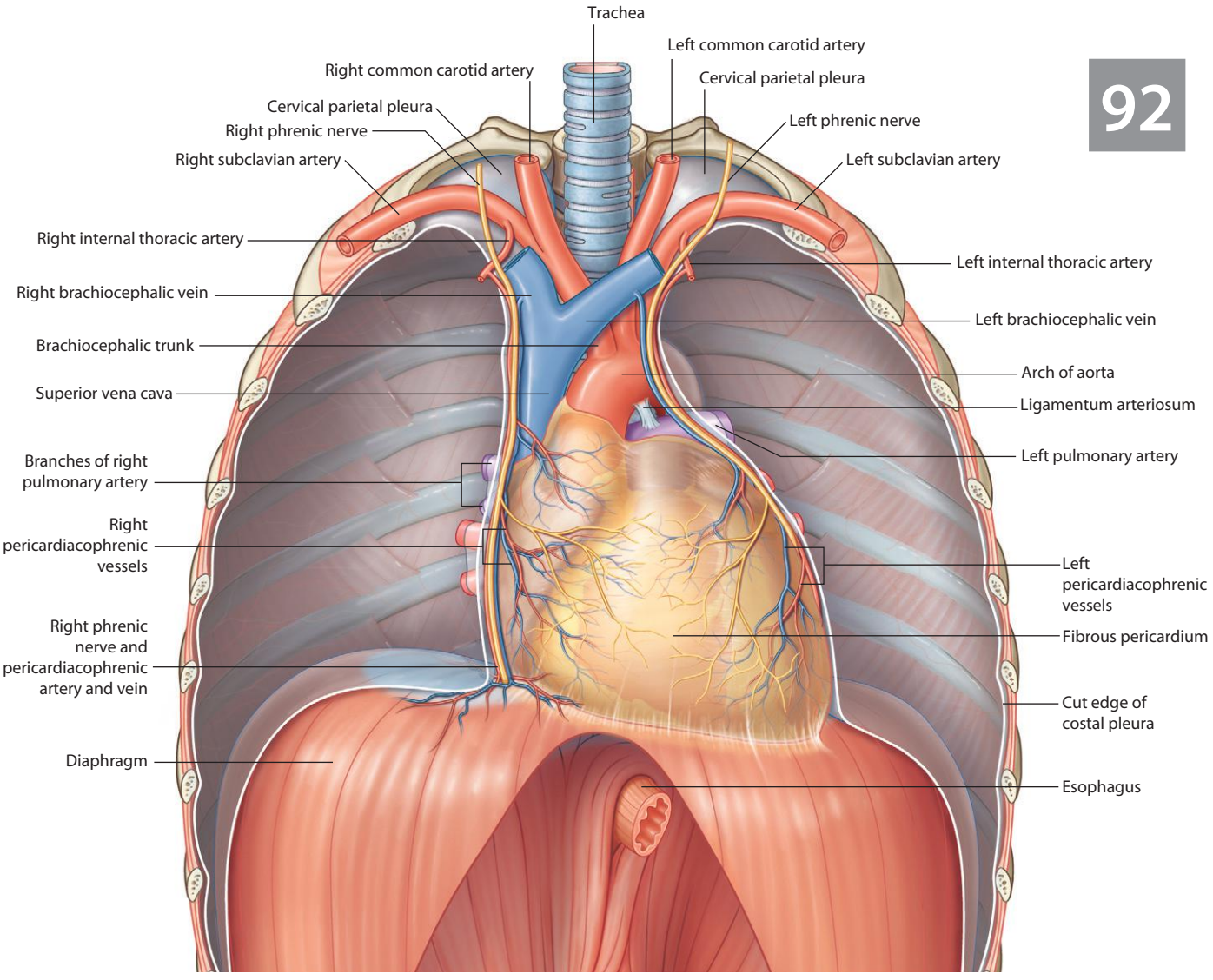

Pericardium with nerves and vessels

93

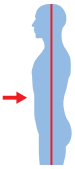

Mediastinal structures and lungs.
CT image, with contrast, in coronal plane

94

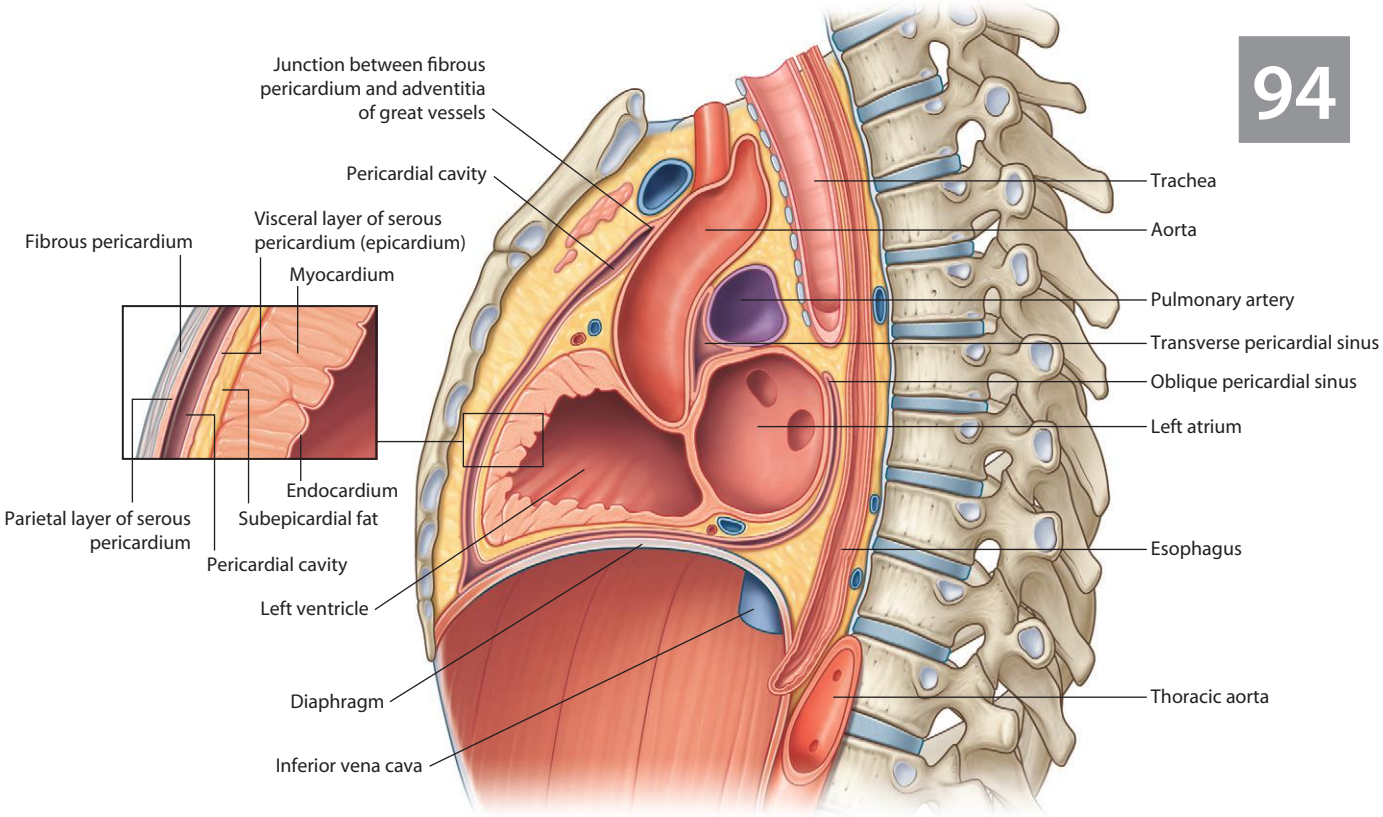

Sagittal section of the pericardium and heart

95

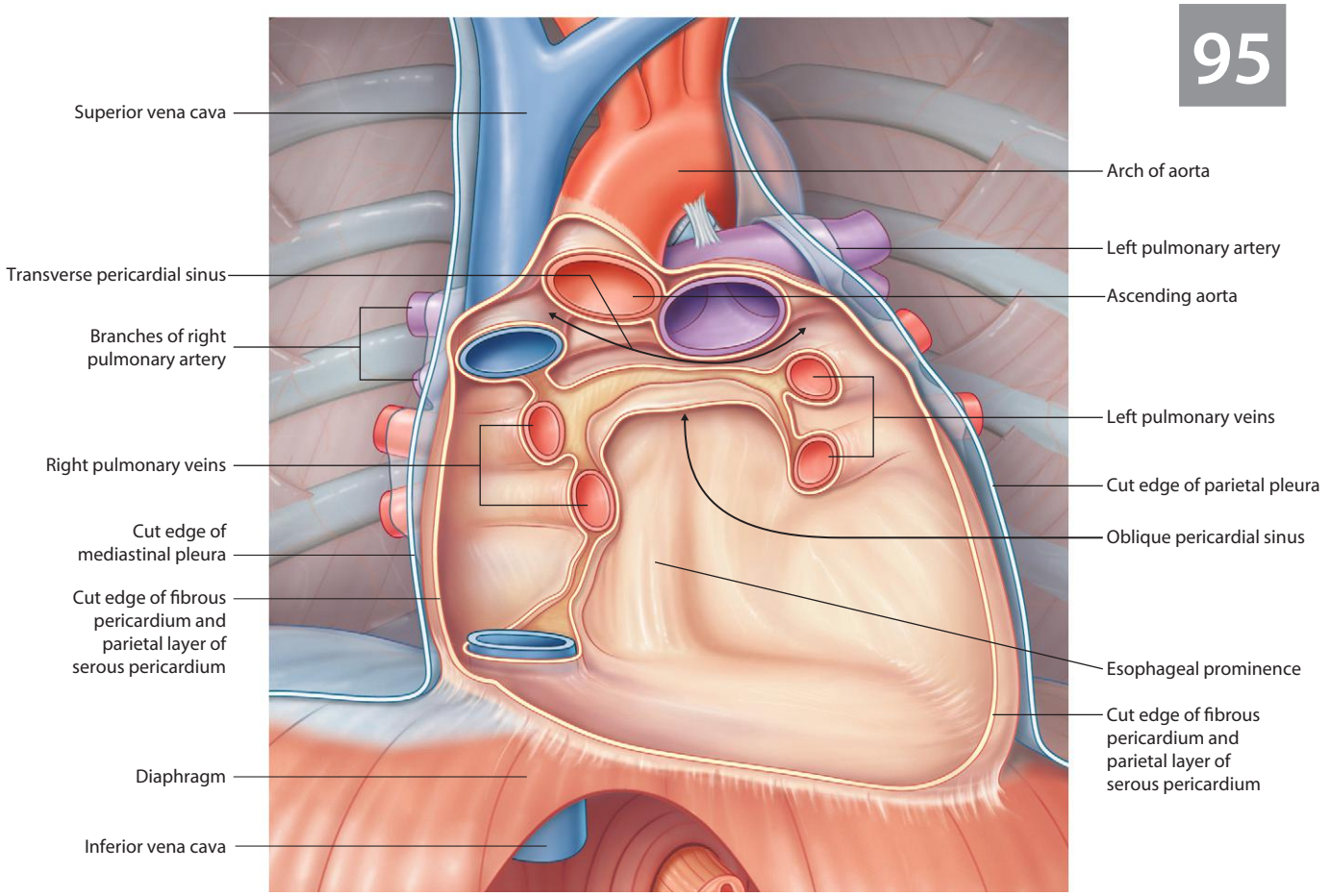

Pericardial sac with heart removed

96

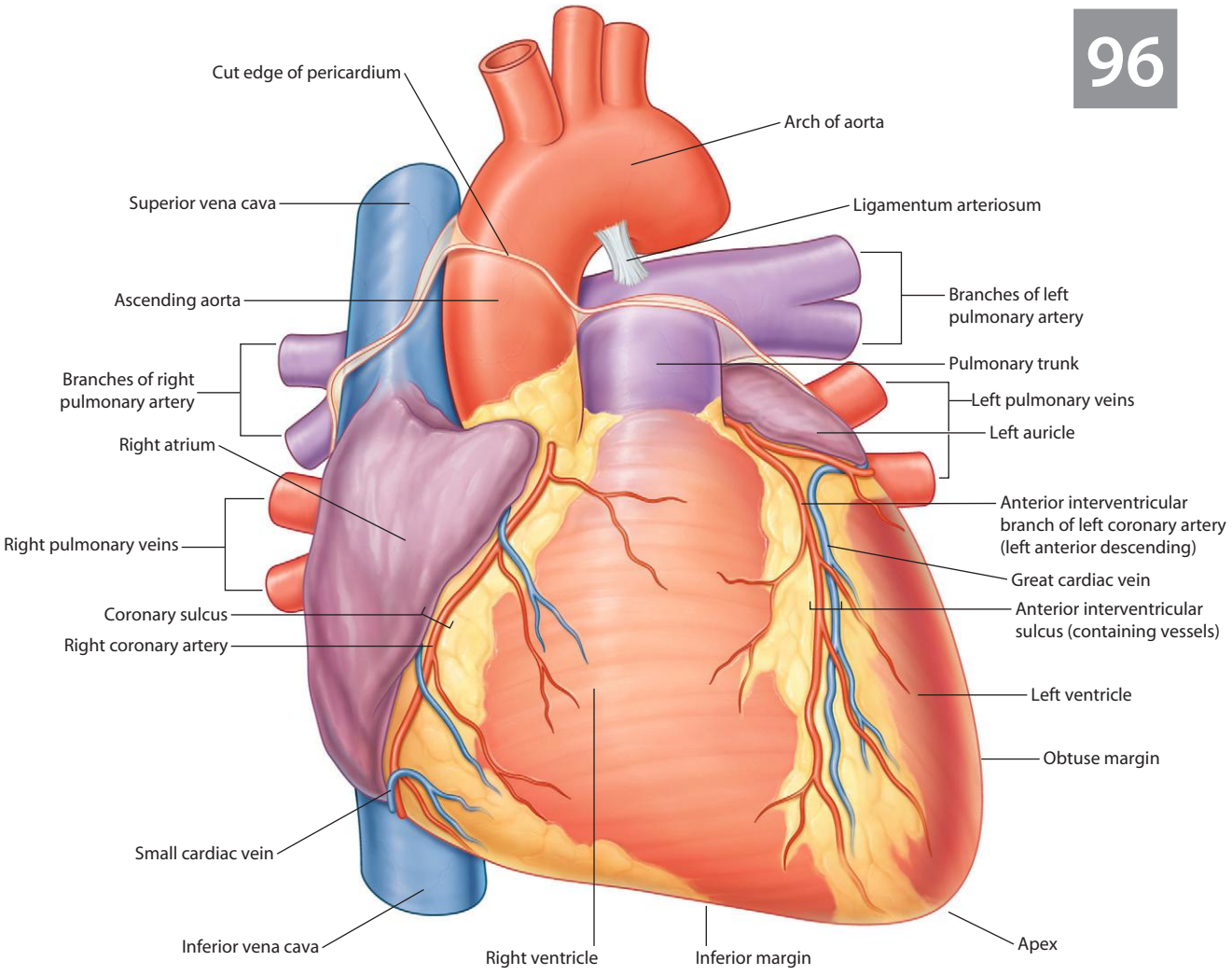

Anterior surface of the heart

97

Anterior view of the heart.
Volume-rendered anterior view using multidetector computed tomography

98

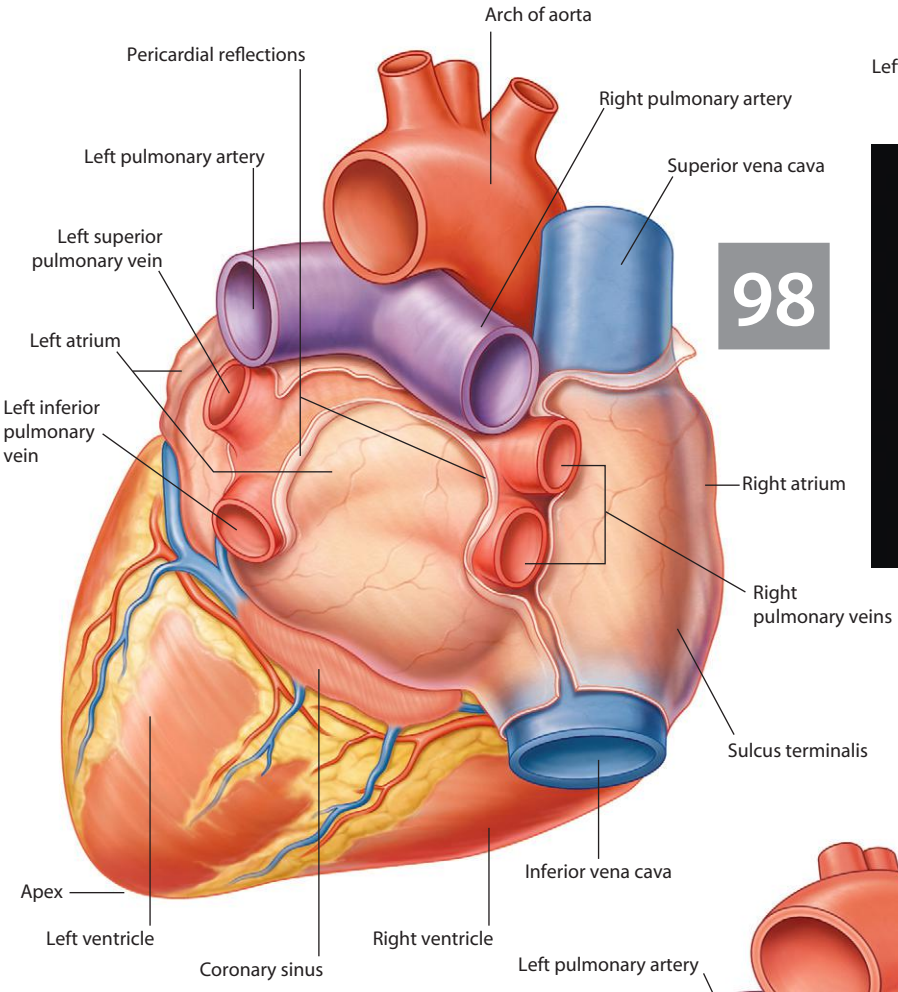

Base of the heart

99

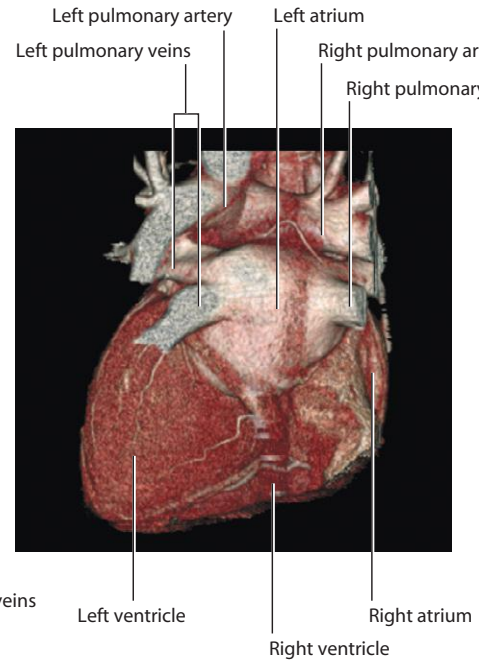

Posterior view of the heart.
Volume-rendered posterior view using multidetector computed tomography

100

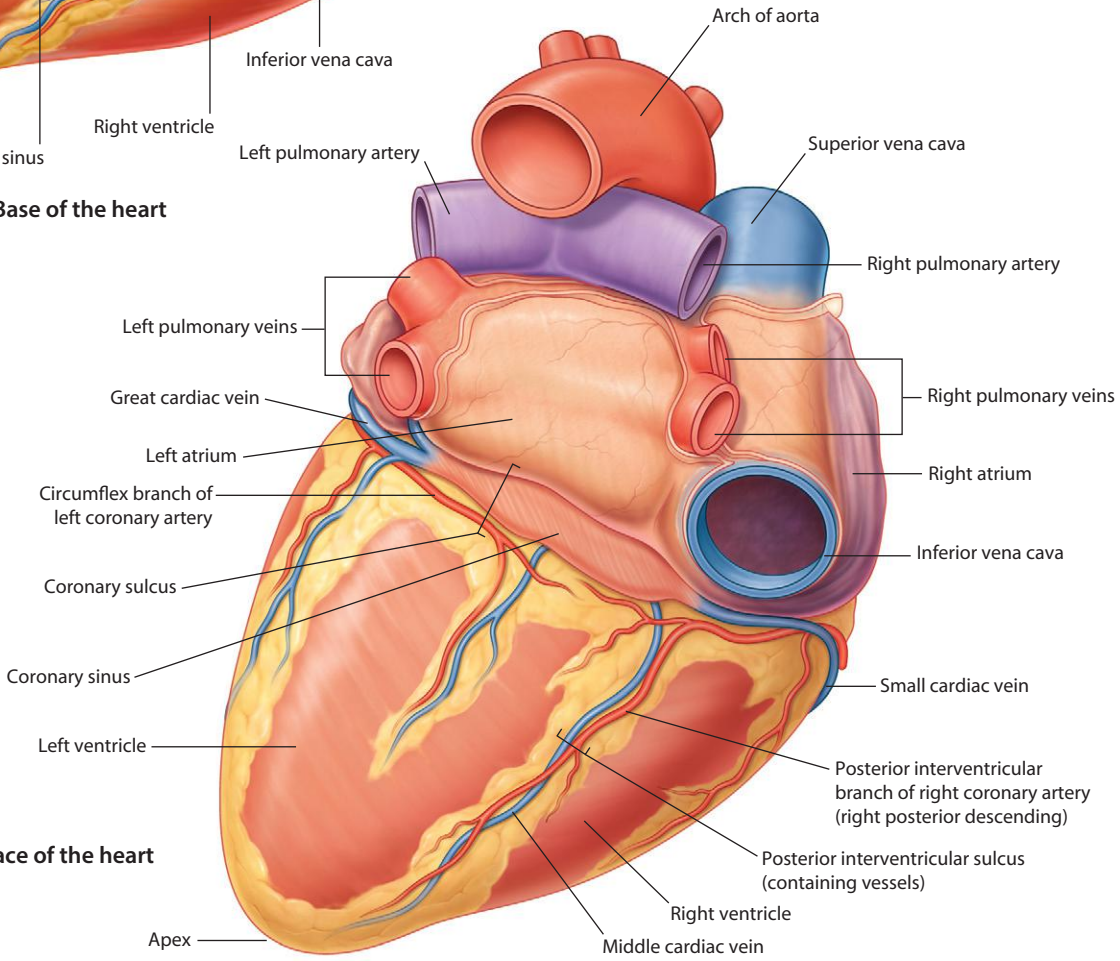

Diaphragmatic surface of the heart

101

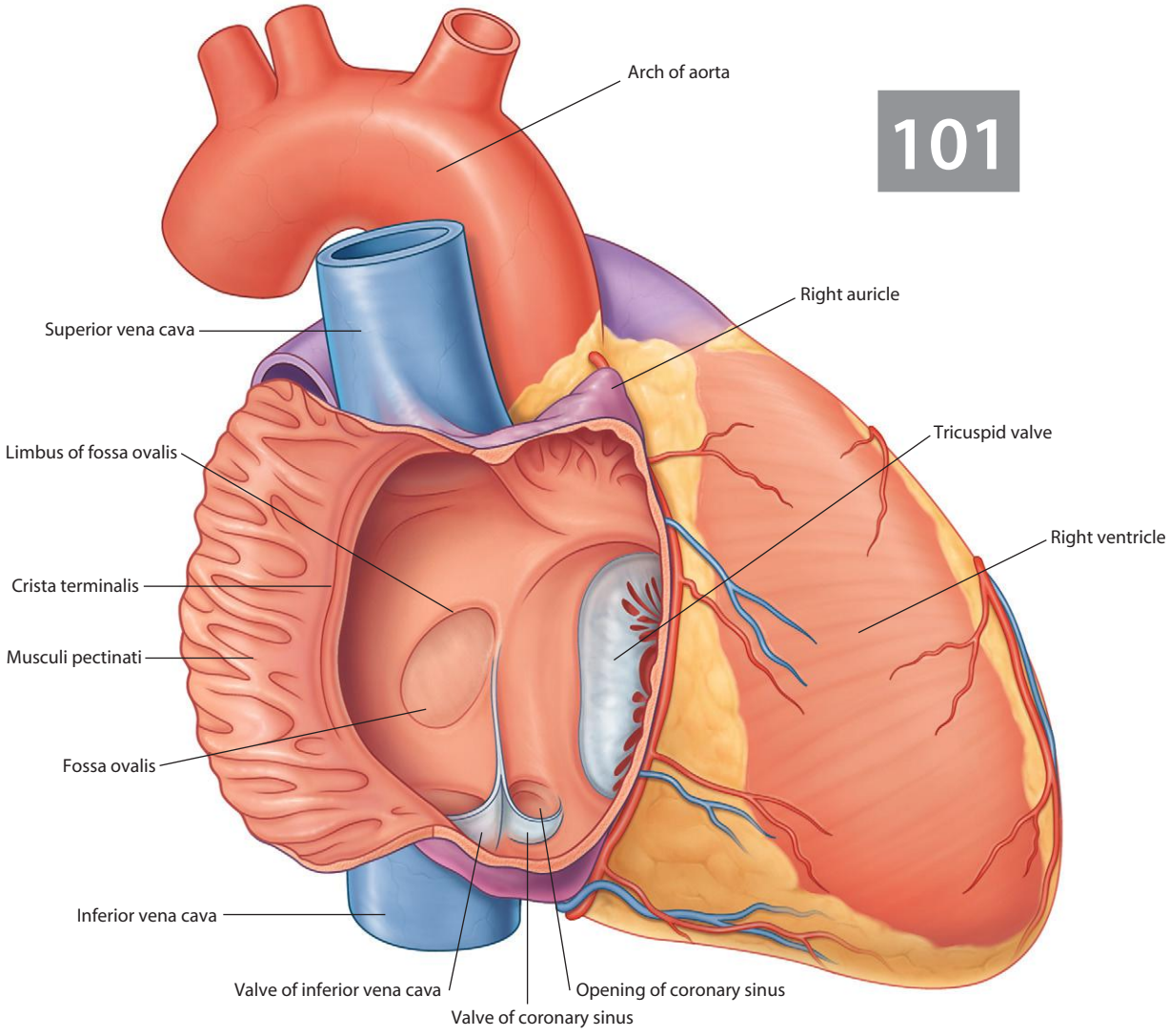

Internal view of right atrium

102

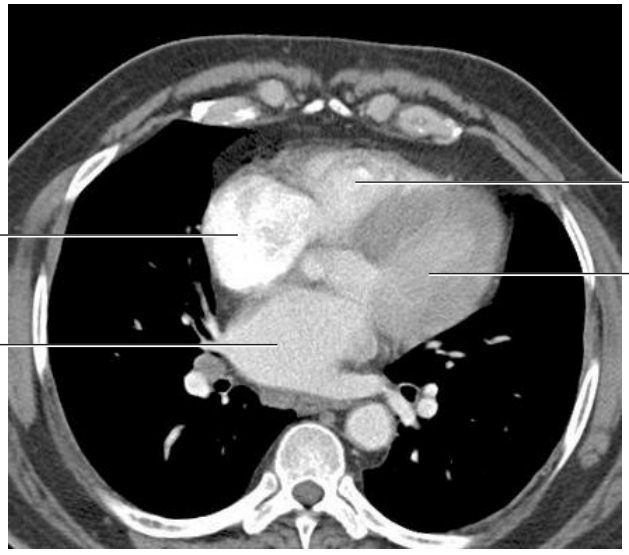

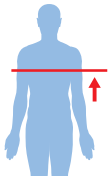

Positioning of right atrium in relation to other cardiac chambers.
CT image, with contrast, in axial plane

103

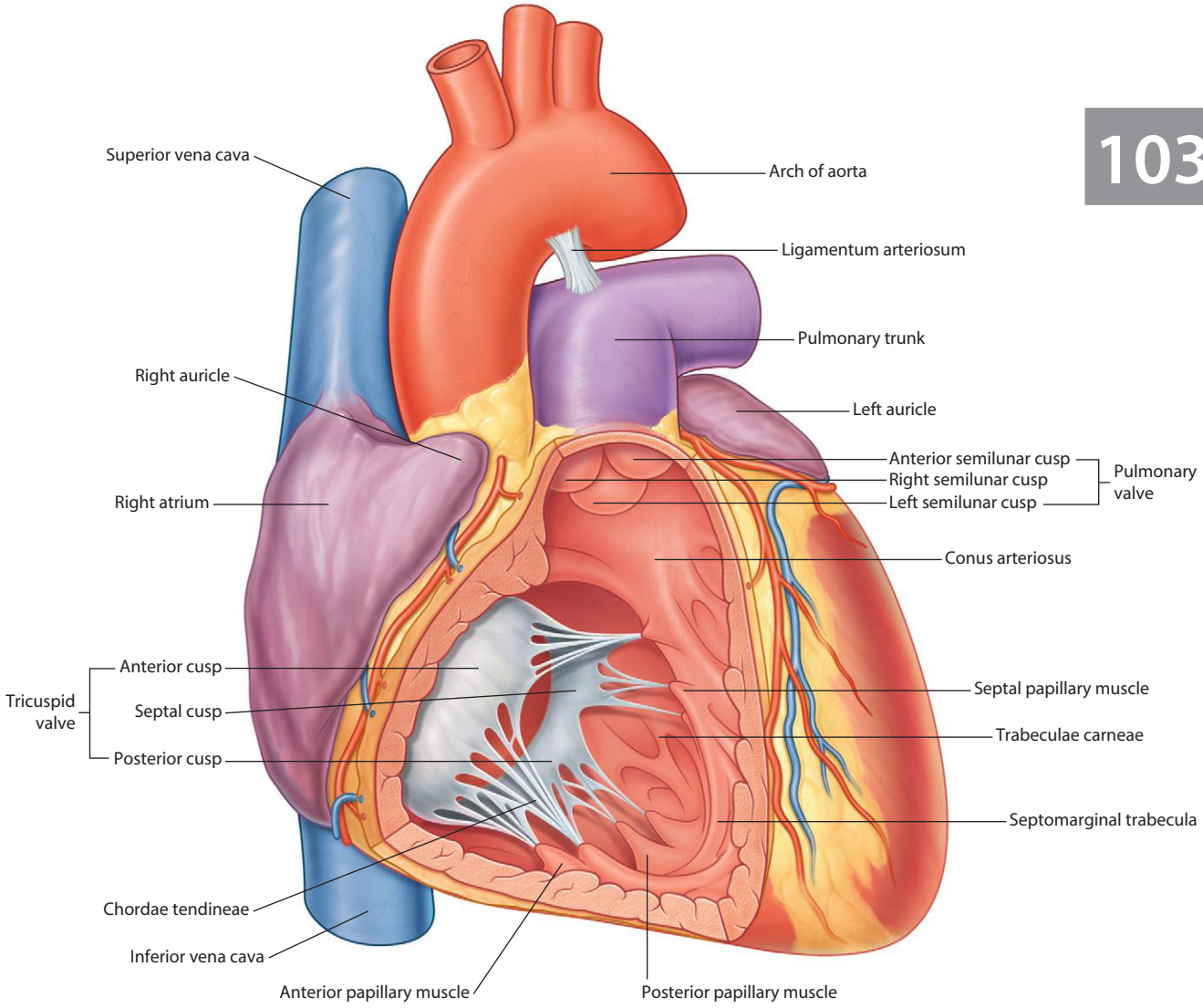

Internal view of right ventricle

104

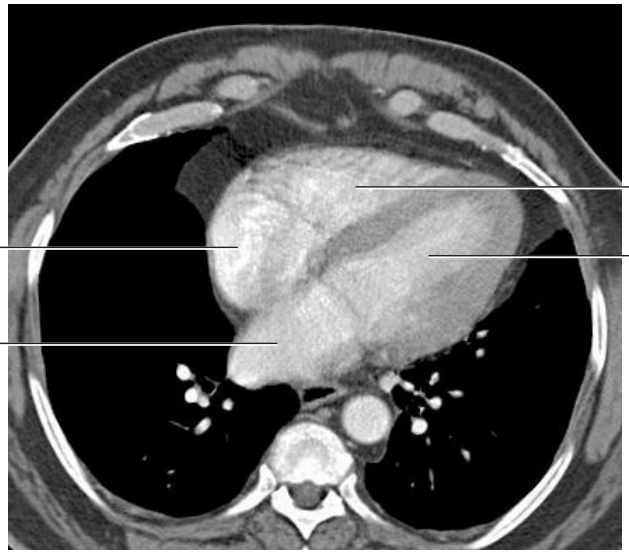

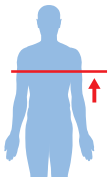

Positioning of right ventricle in relation to other cardiac chambers.
CT image, with contrast, in axial plane

105

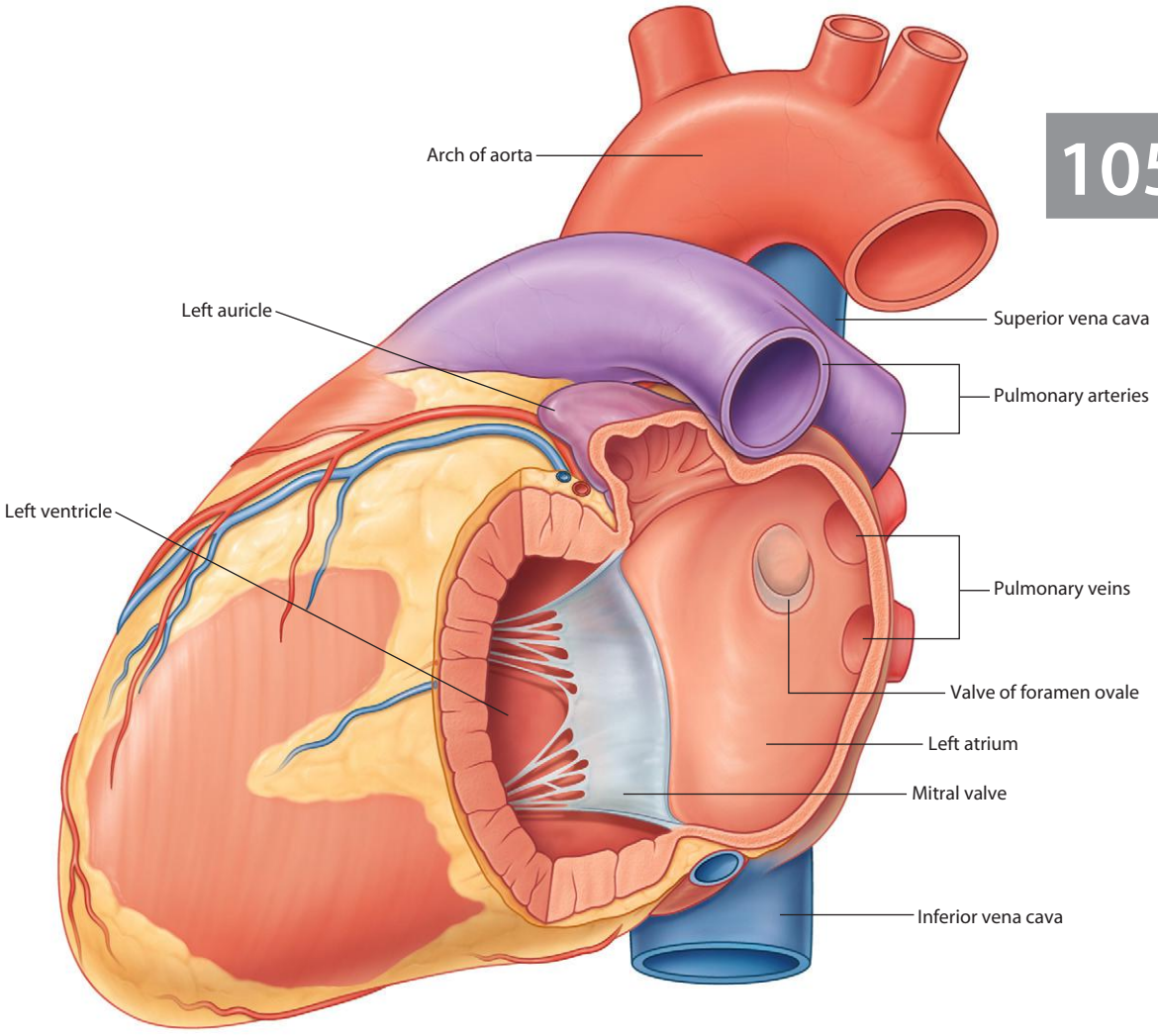

Internal view of left atrium

106

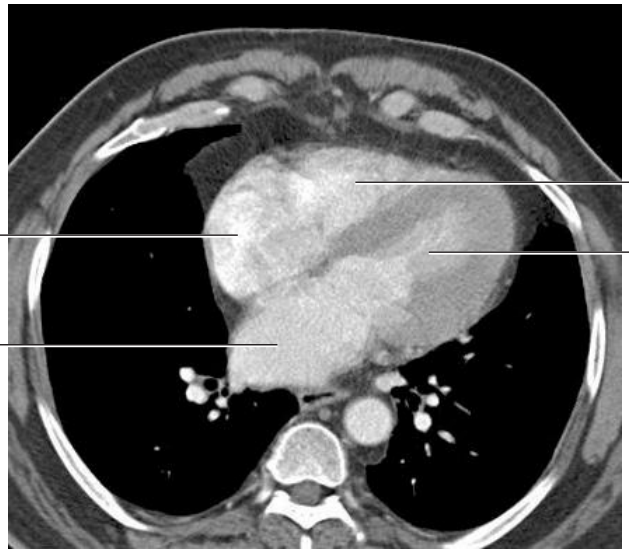

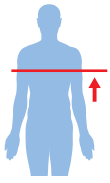

Positioning of left atrium in relation to other cardiac chambers.
CT image, with contrast, in axial plane

107

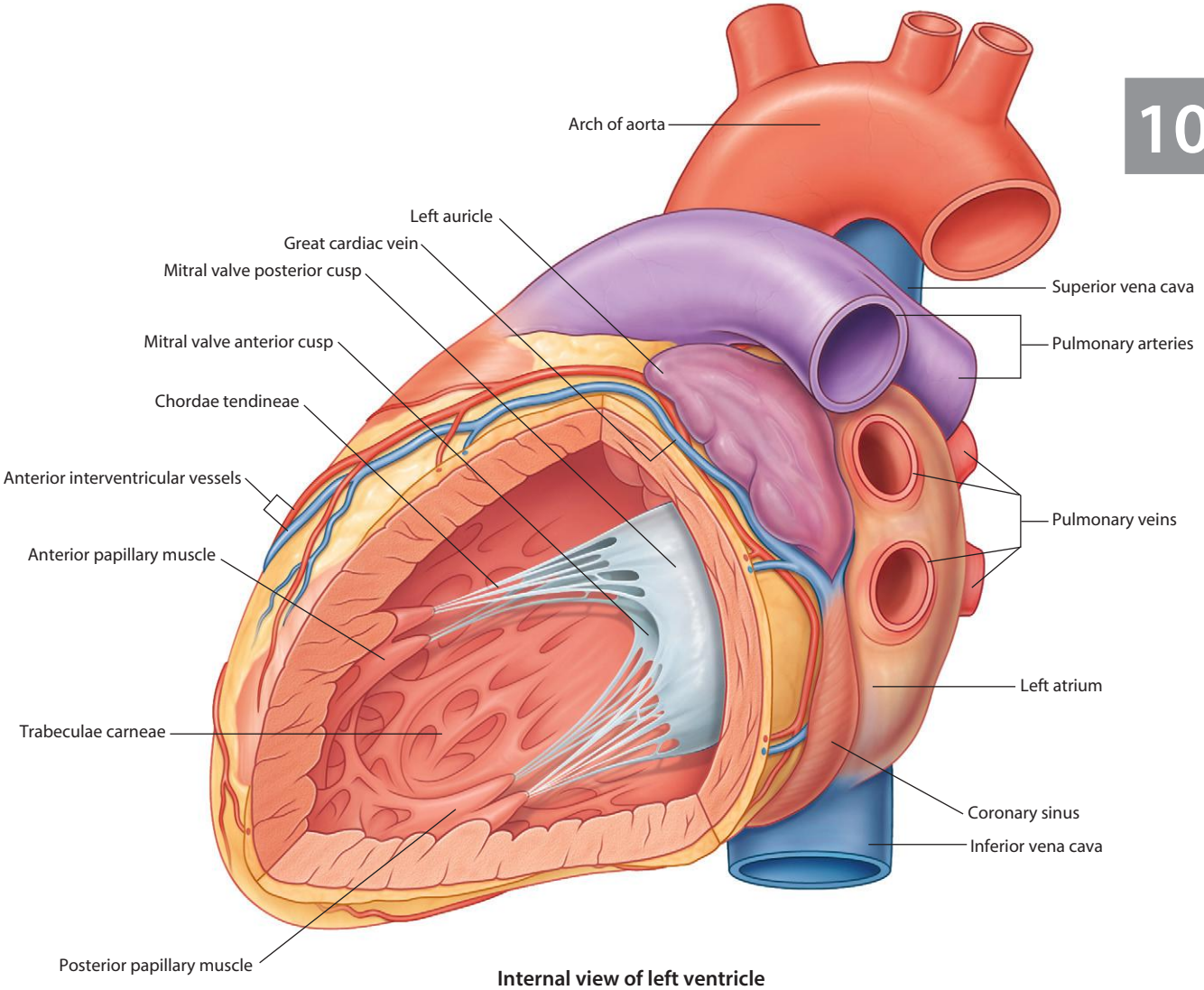

Internal view of left ventricle

108

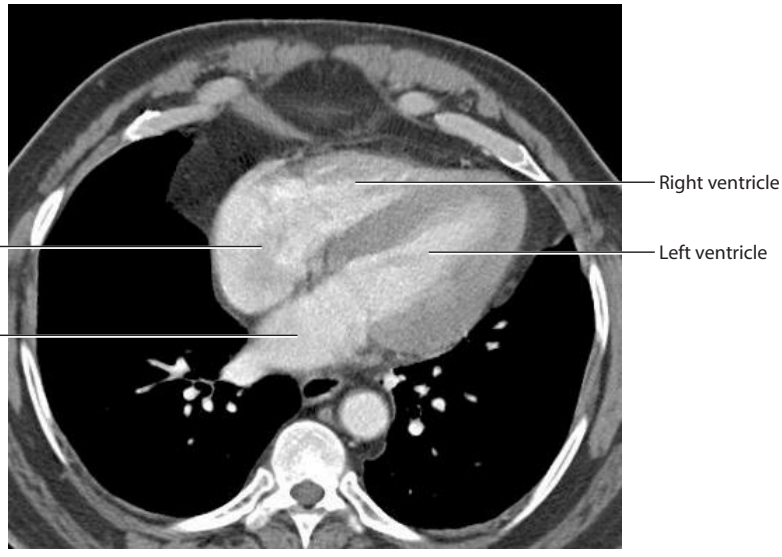

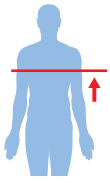

Positioning of left ventricle in relation to other cardiac chambers.
CT image, with contrast, in axial plane

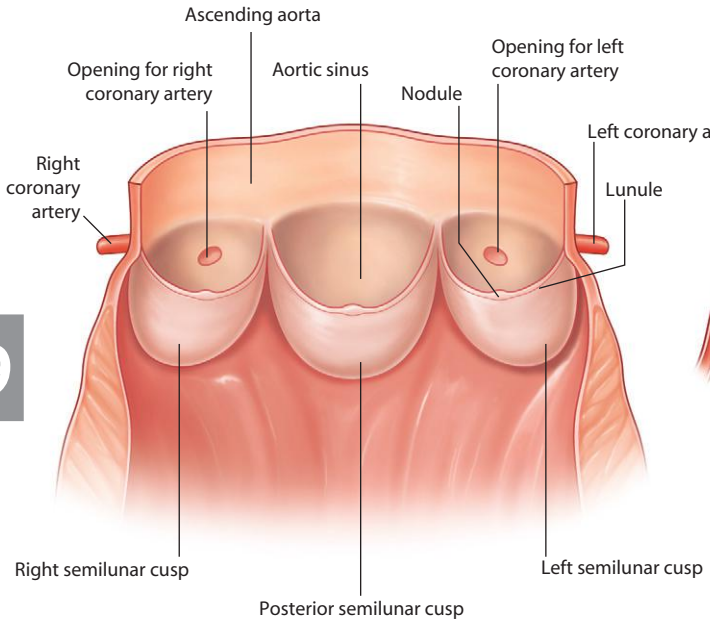

Anterior view of the aortic valve (resected and opened out)

109

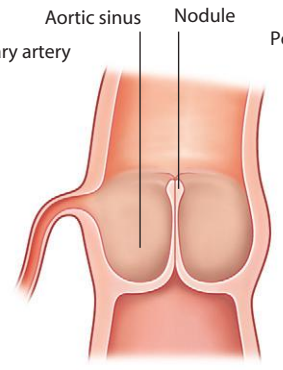

Lateral view of the aortic valve in diastole

110

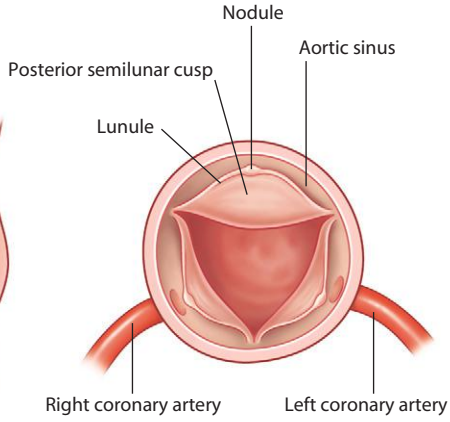

Superior view of the aortic valve in systole

111

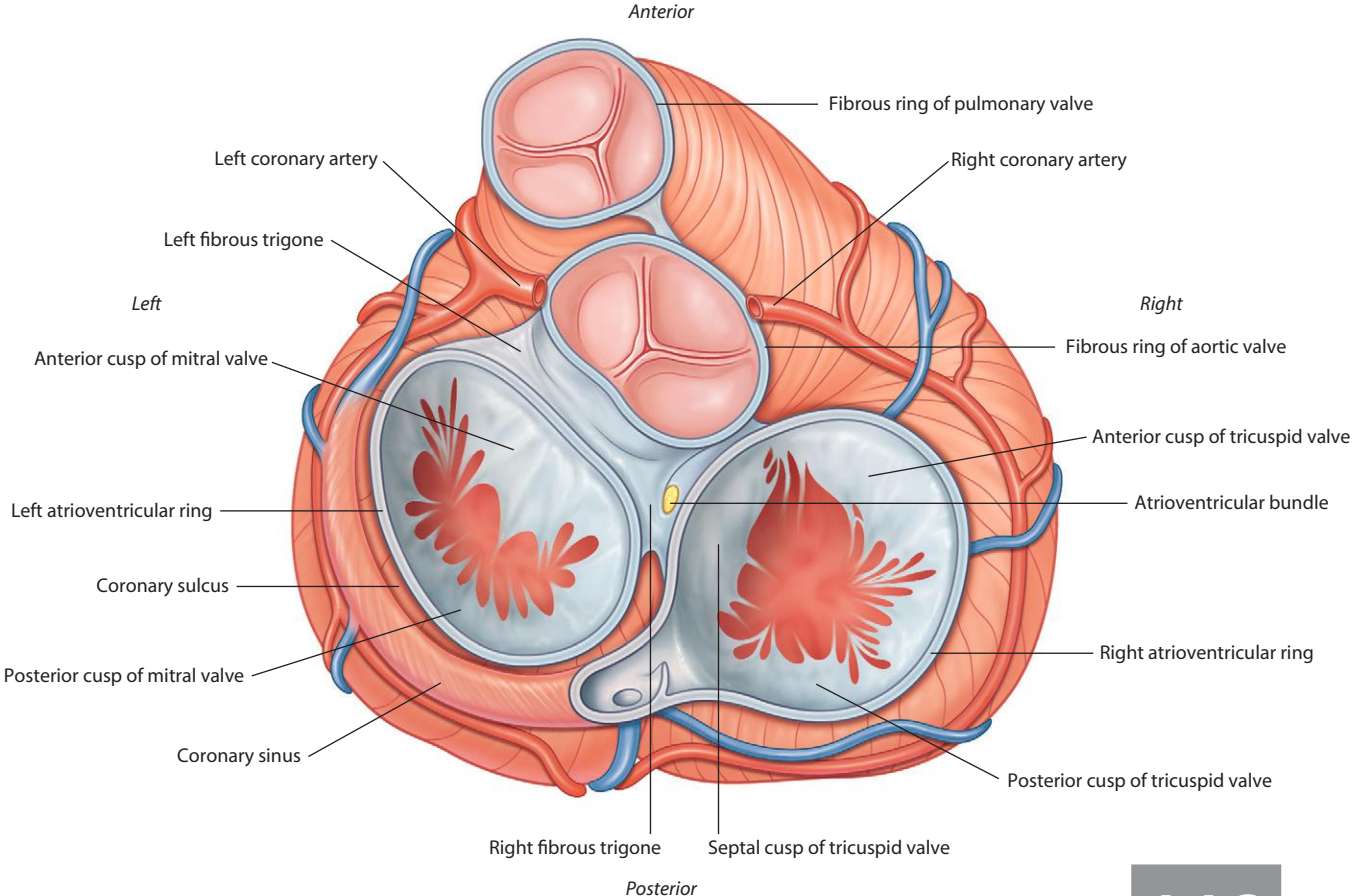

Cardiac skeleton (superior view; atria removed)

112

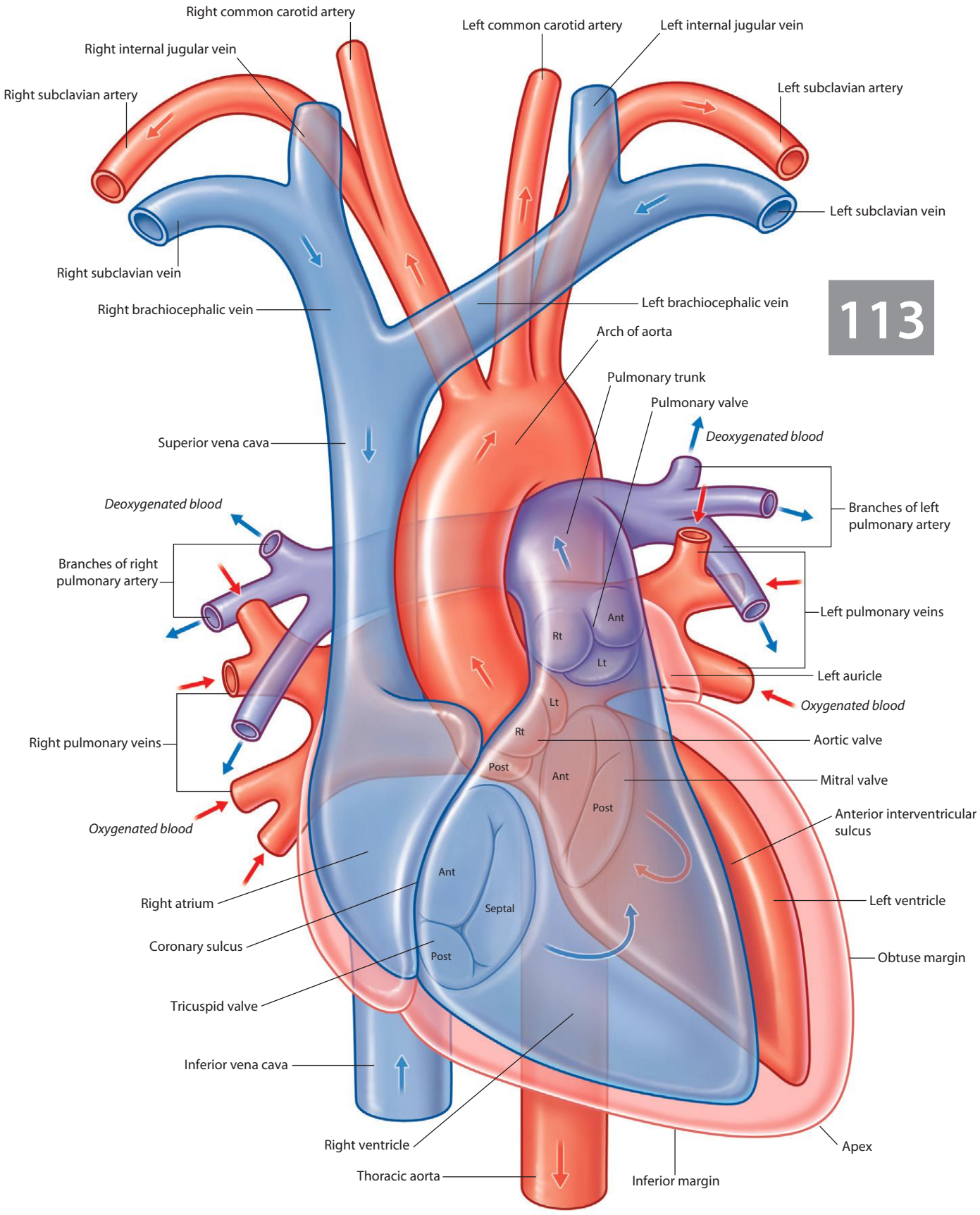

Cardiac chambers and direction of blood flow

114

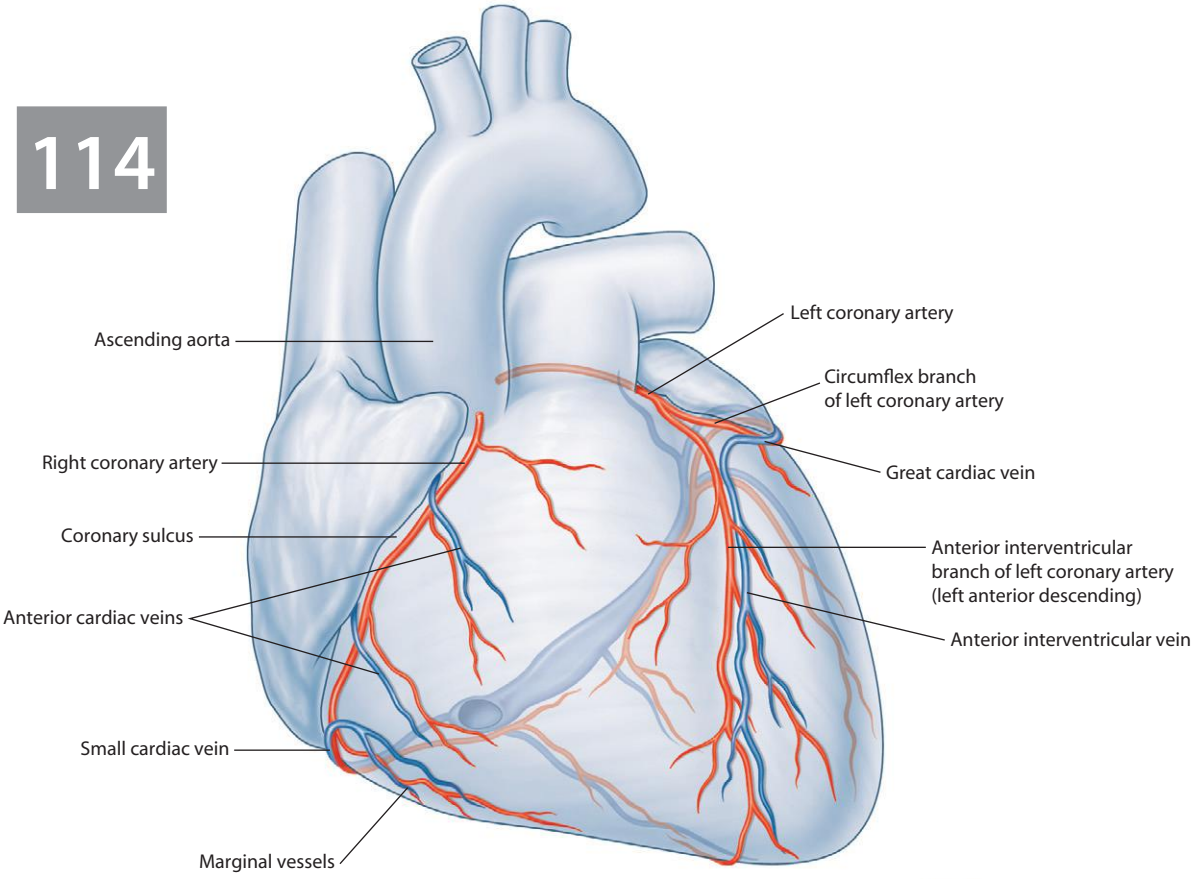

Cardiac vasculature (anterior view)

116

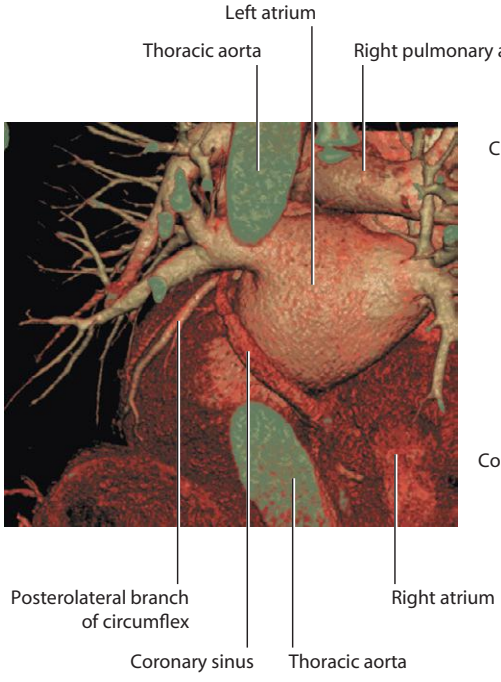

Posterior view of the heart showing the coronary sinus
Volume-rendered posterior view using multidetector computed tomography

115

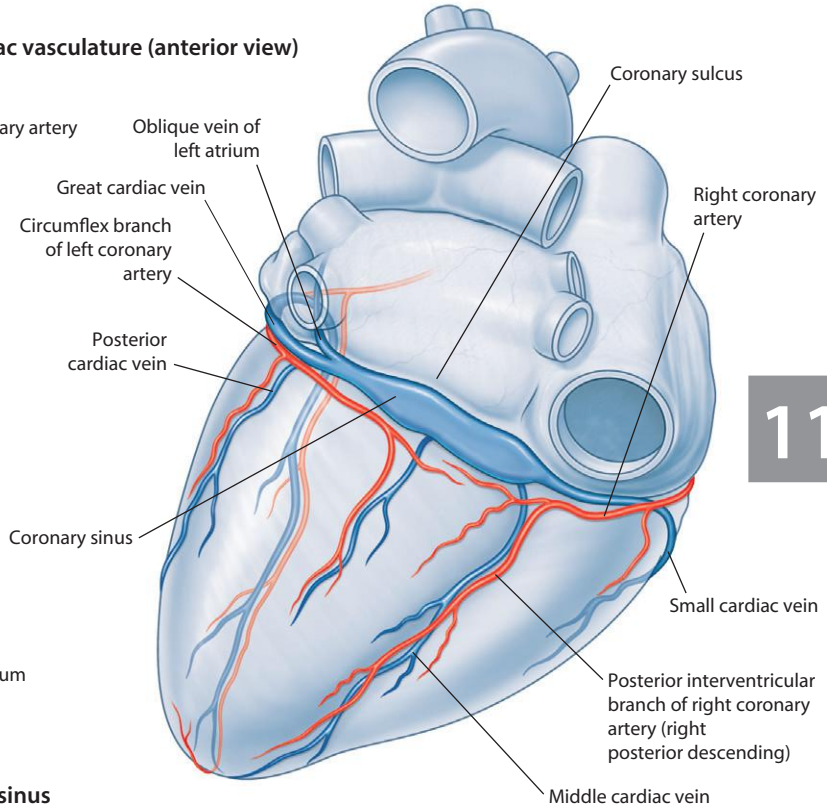

Posteroinferior view

117

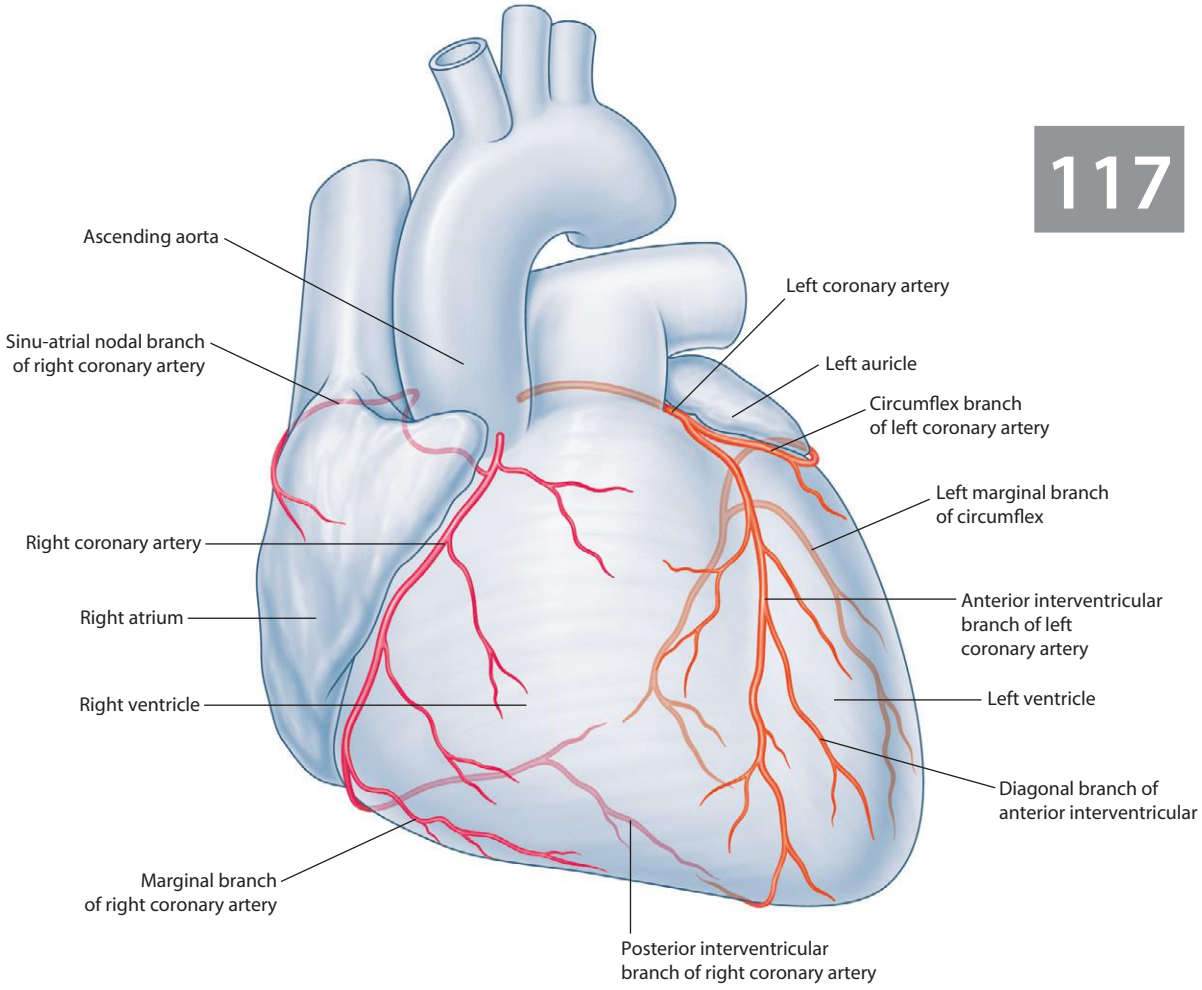

Coronary arteries (right dominant system)

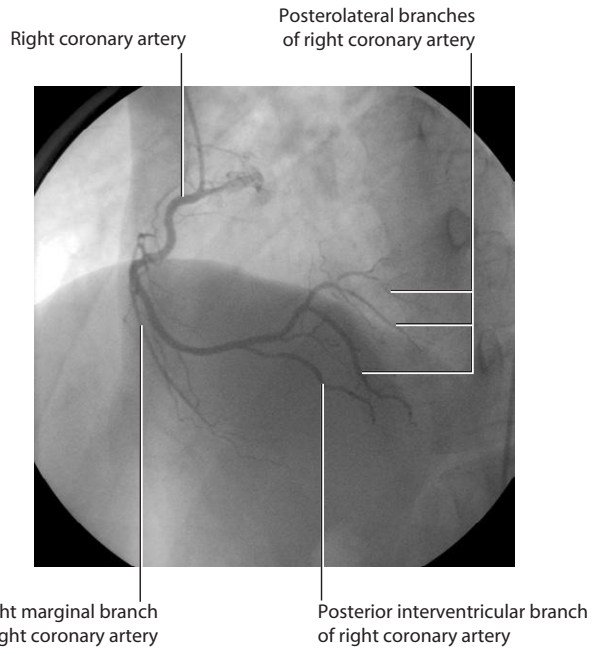

Coronary angiography (right dominant system).
Left anterior oblique projection, cranial angulation, of right coronary artery

118

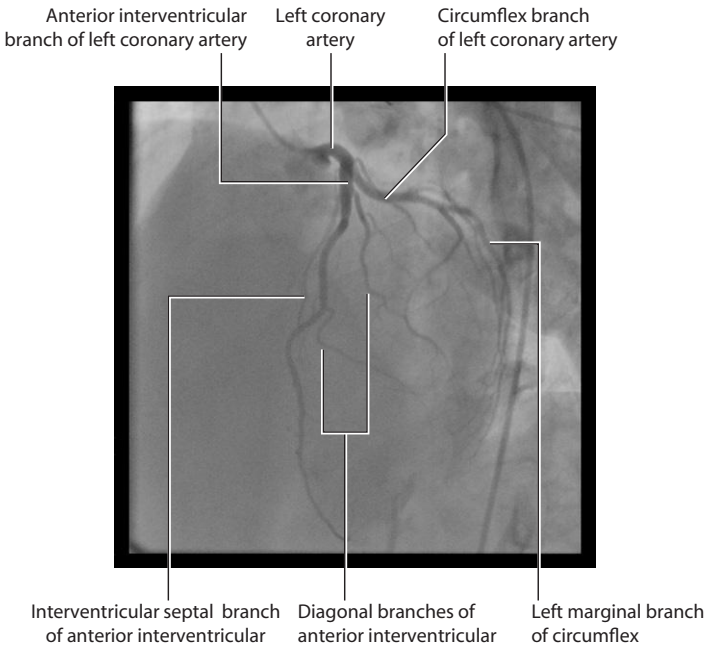

Coronary angiography (right dominant system).
Left anterior oblique projection, cranial angulation, of left coronary artery

119

120

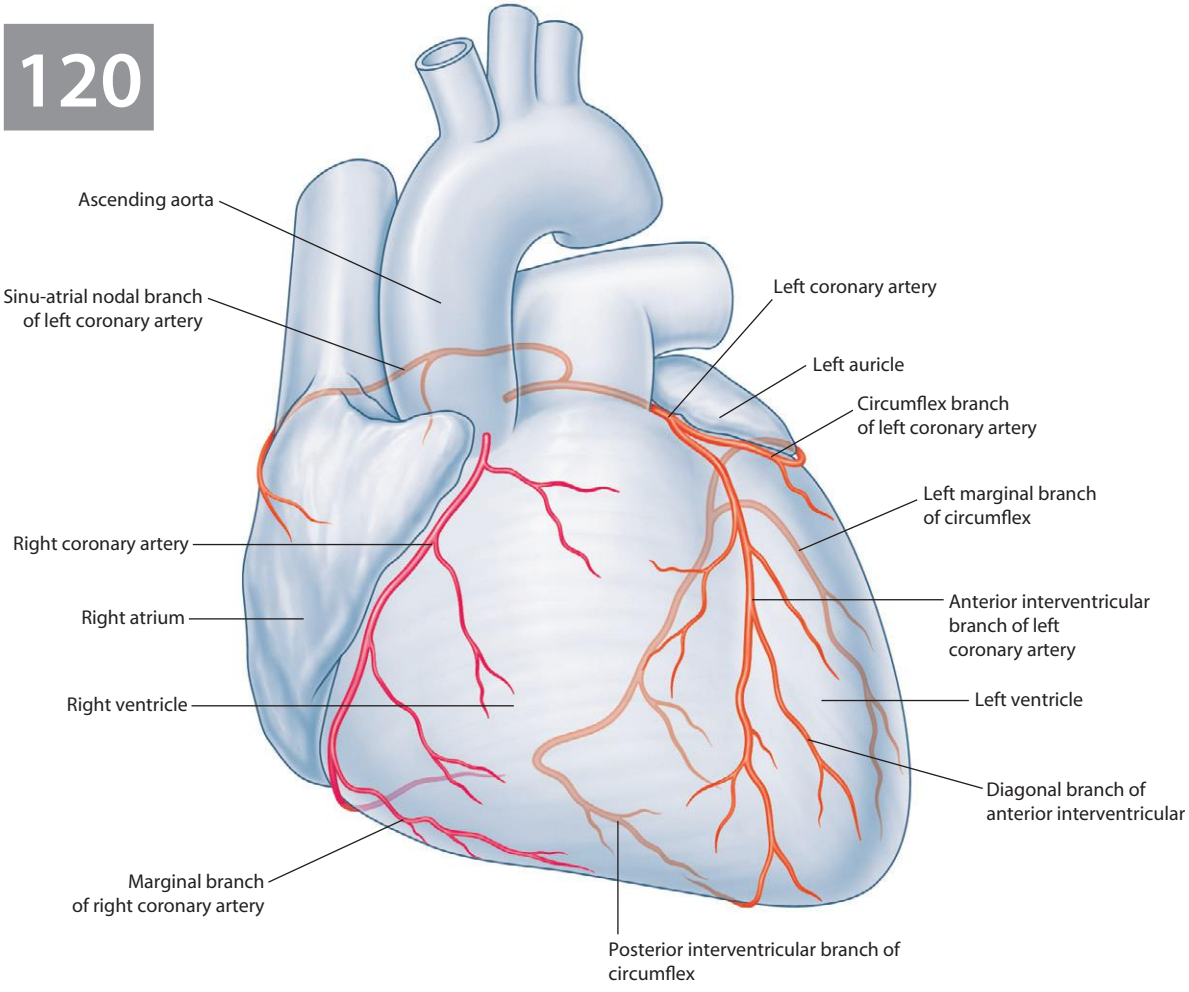

Coronary arteries (left dominant system)

121

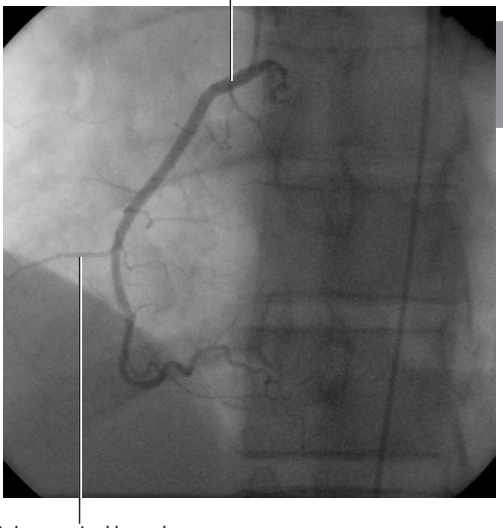

Coronary angiography (left dominant system).
Left anterior oblique projection, cranial angulation, of right coronary artery

122

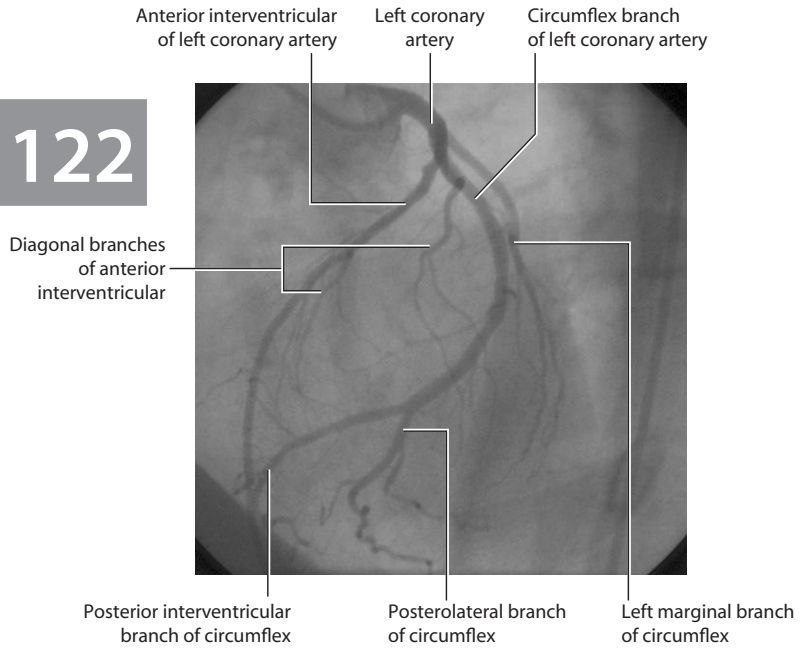

Coronary angiography (left dominant system).
Left anterior oblique projection, cranial angulation, of left coronary artery

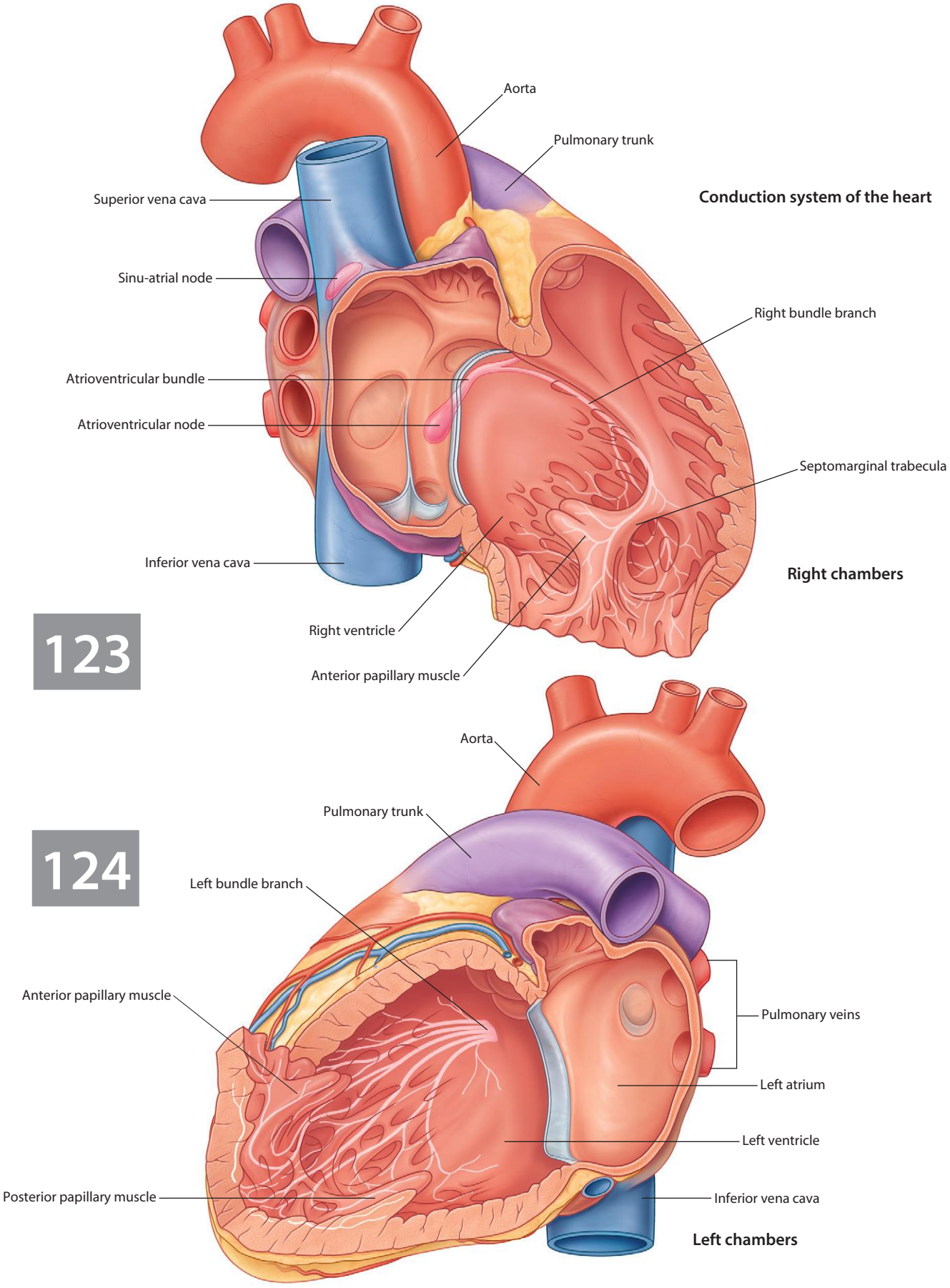
Aorta
Pulmonary trunk
Superior vena cava
Conduction system of the heart
Sinu-atrial node
Right bundle branch
Atrioventricular bundle
Atrioventricular node
Septomarginal trabecula
Inferior vena cava
Right chambers
123
Right ventricle
Anterior papillary muscle
Aorta
Pulmonary trunk
124
Left bundle branch
Anterior papillary muscle
Pulmonary veins
Left atrium
Left ventricle
Posterior papillary muscle
Inferior vena cava
Left chambers

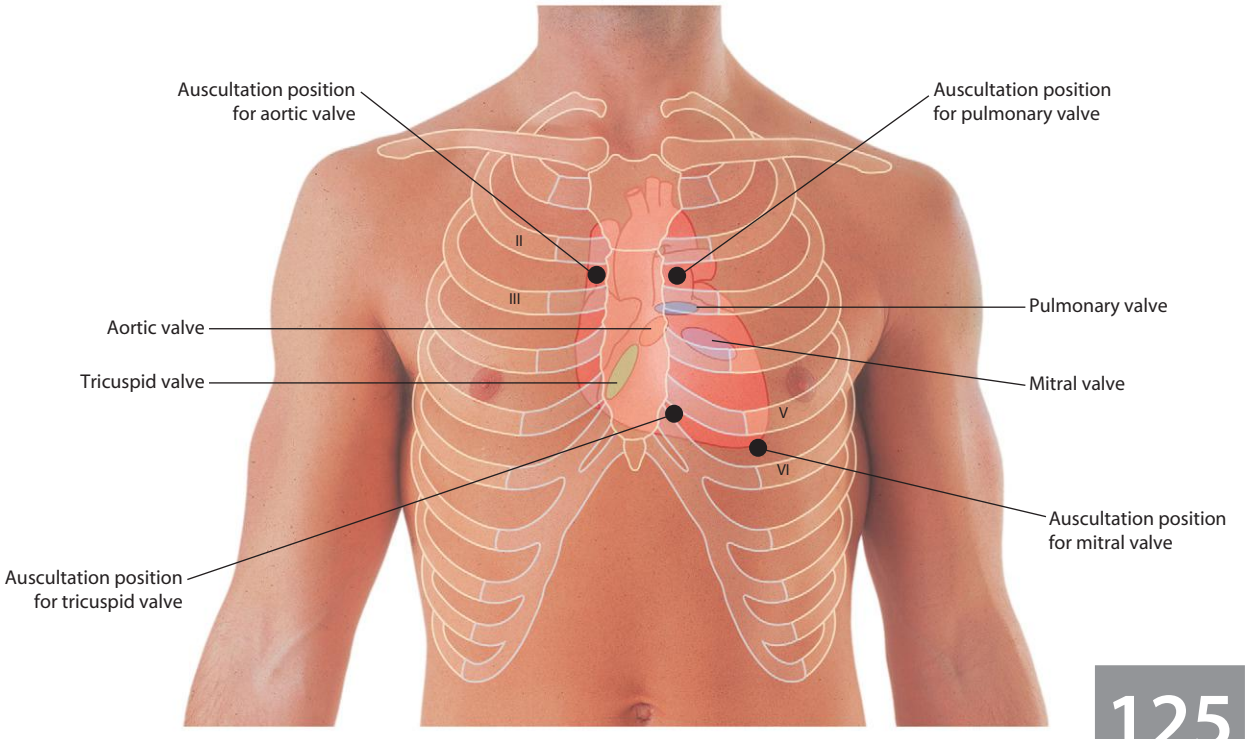

125

Auscultation points

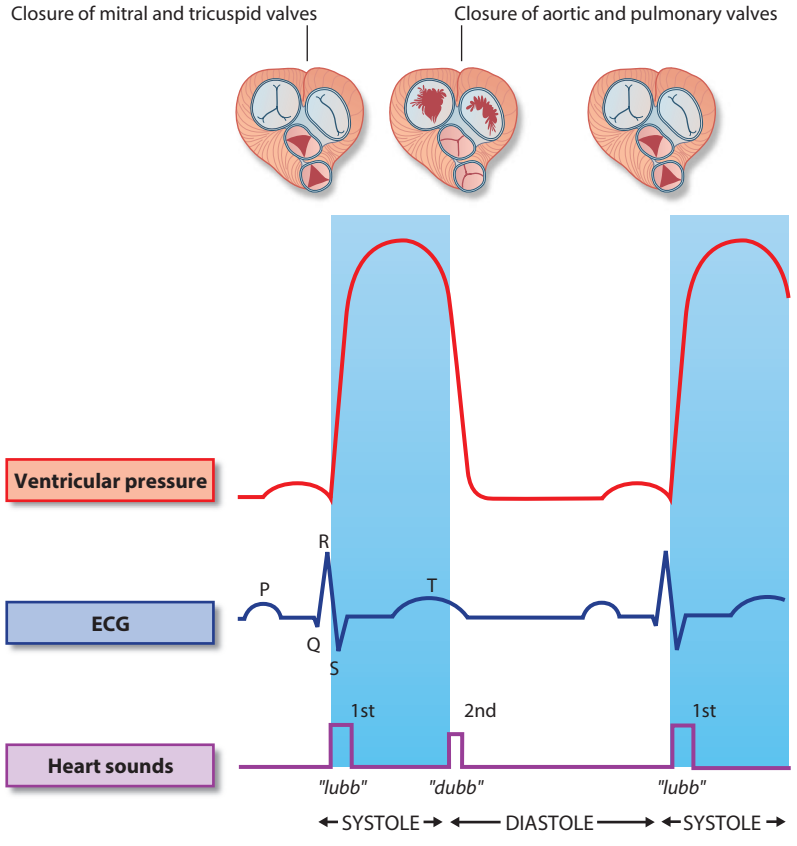

126

Cardiac auscultation

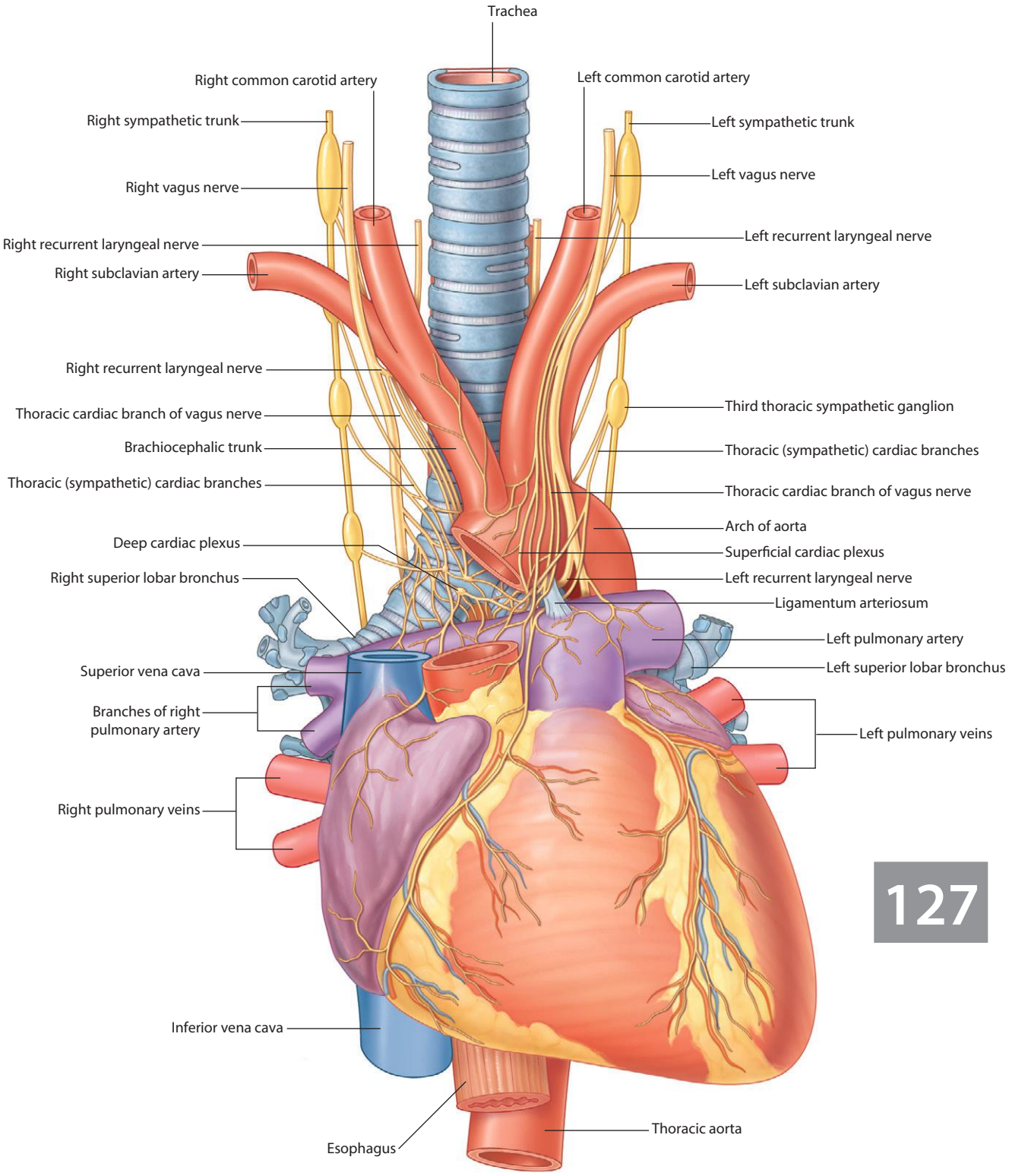

Cardiac plexus and nerves of the heart

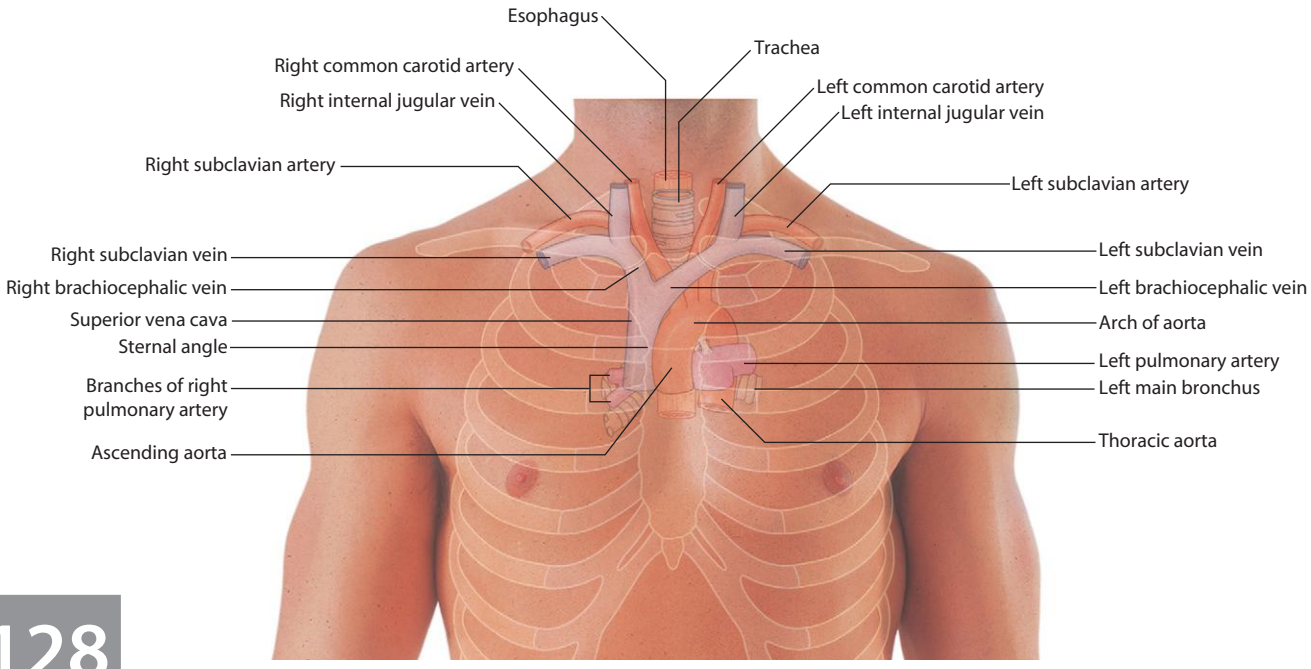

128

Surface projections of structures in the superior mediastinum

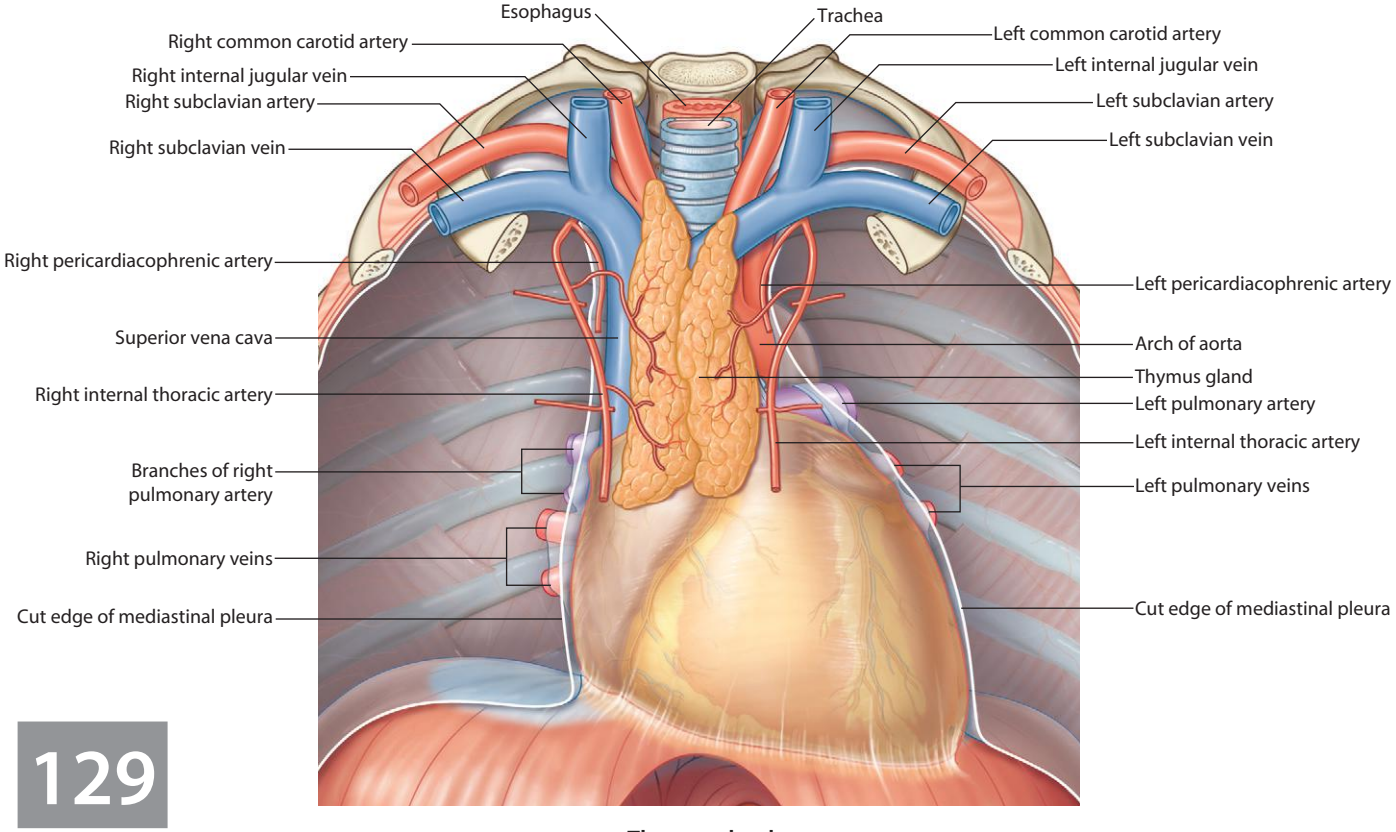

129

Thymus gland

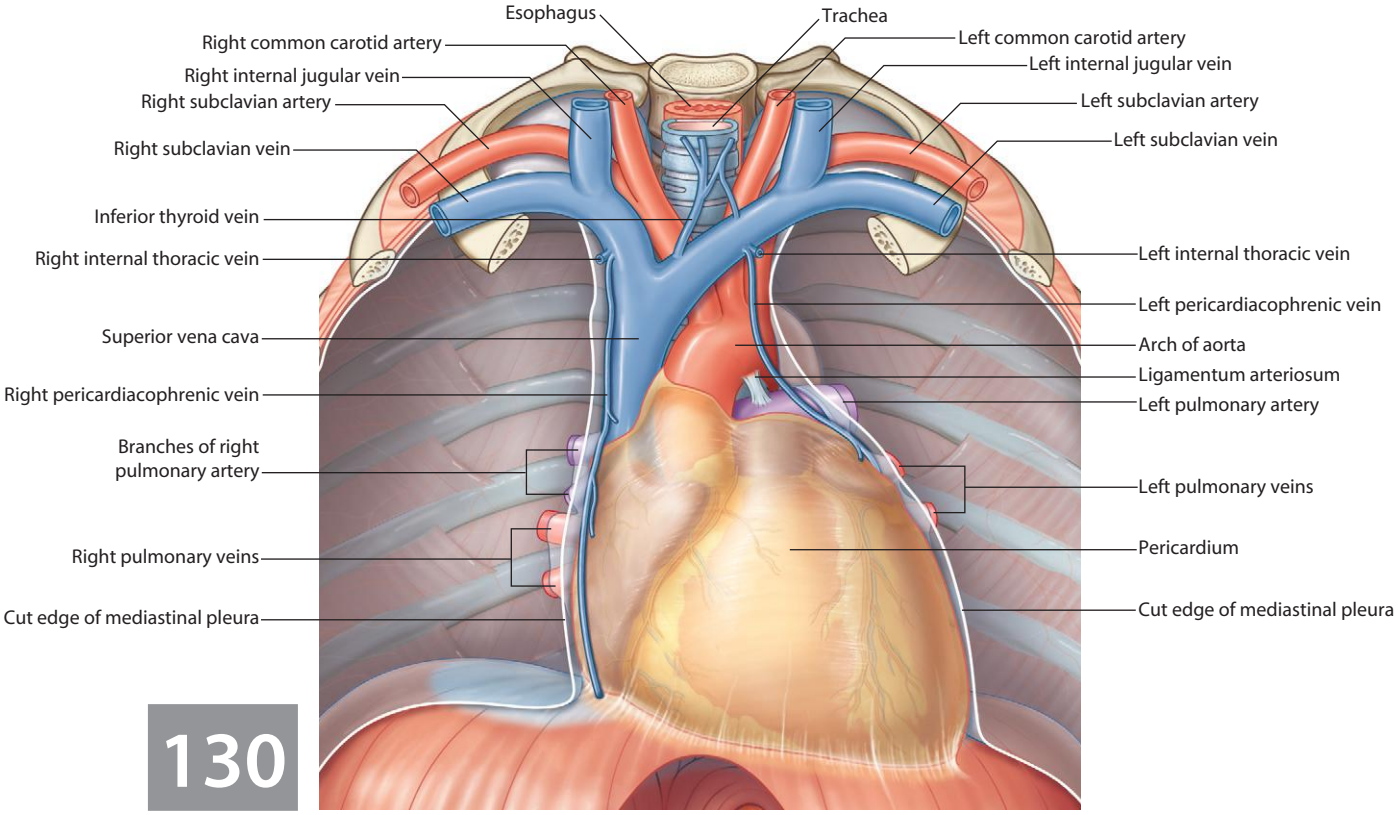

Veins of the superior mediastinum

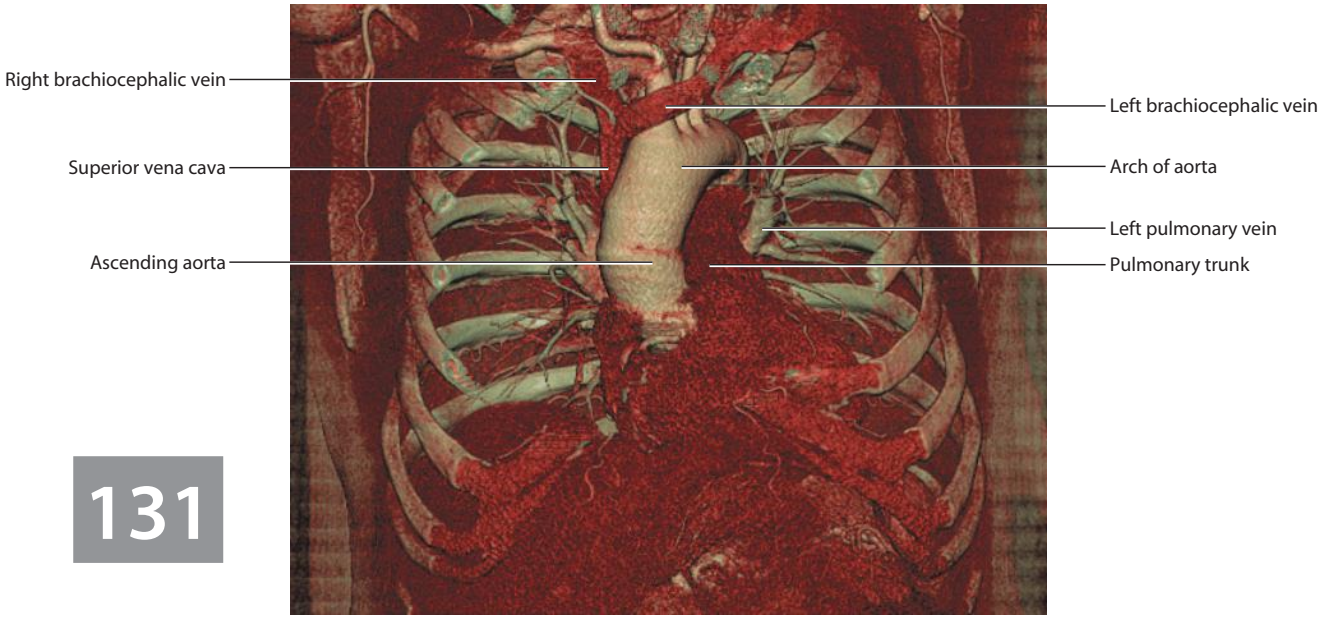

Anterior view of the superior mediastinum showing venous and arterial channels.
Volume-rendered anterior view using multidetector computed tomography

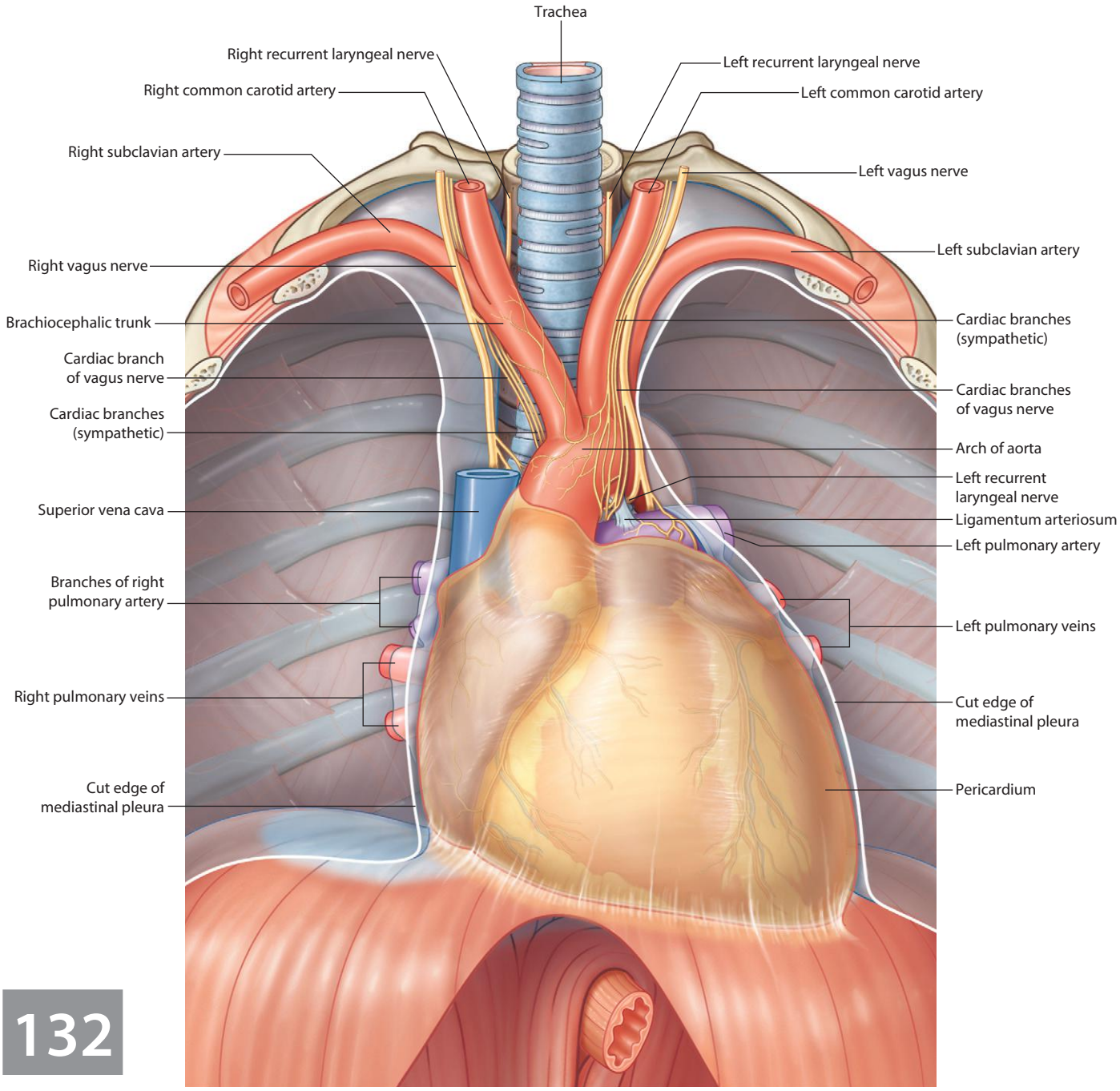

132

Arteries and nerves of the superior mediastinum

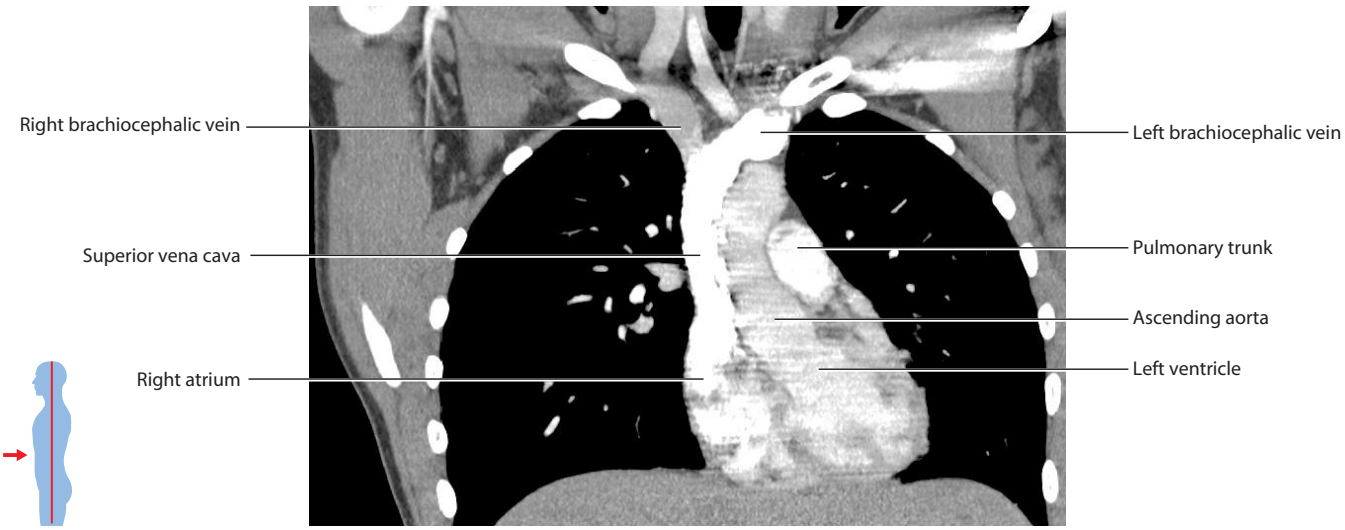

Positioning of venous channels in the superior mediastinum.
CT image, with contrast, in coronal plane

133

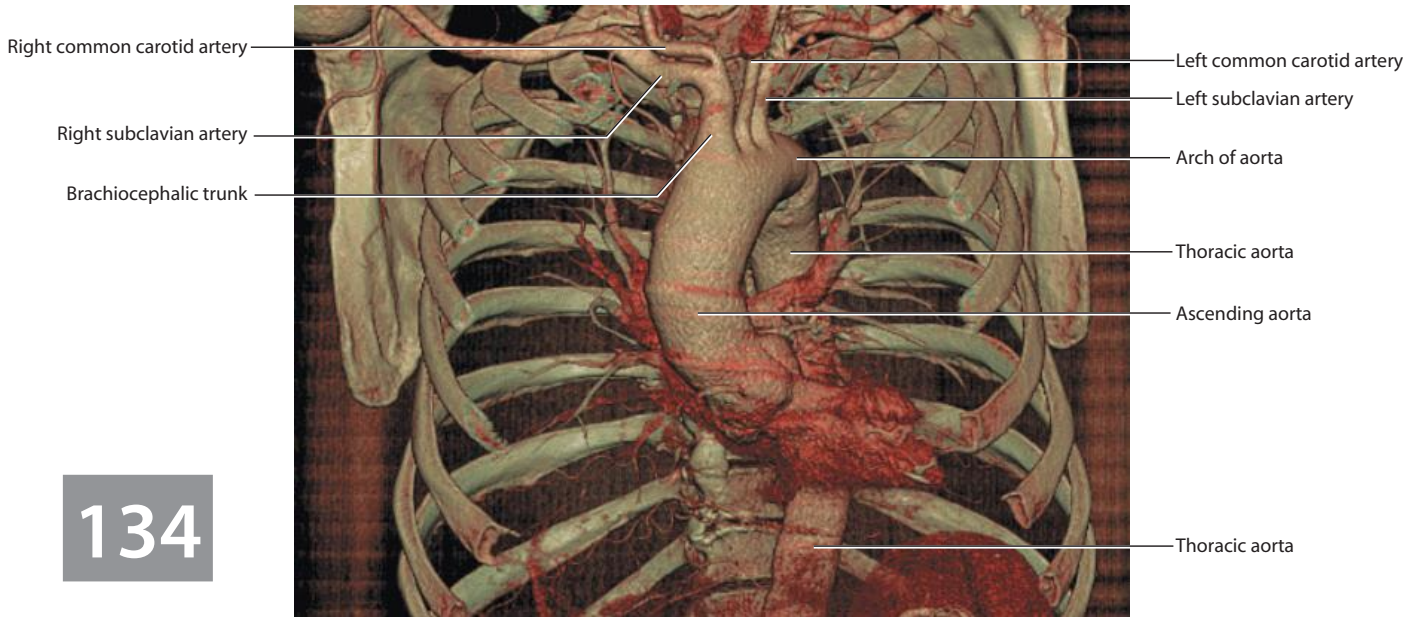

134

Anterior view of the superior mediastinum with the venous channels, pulmonary trunk, and heart removed.
Volume-rendered anterior view using multidetector computed tomography

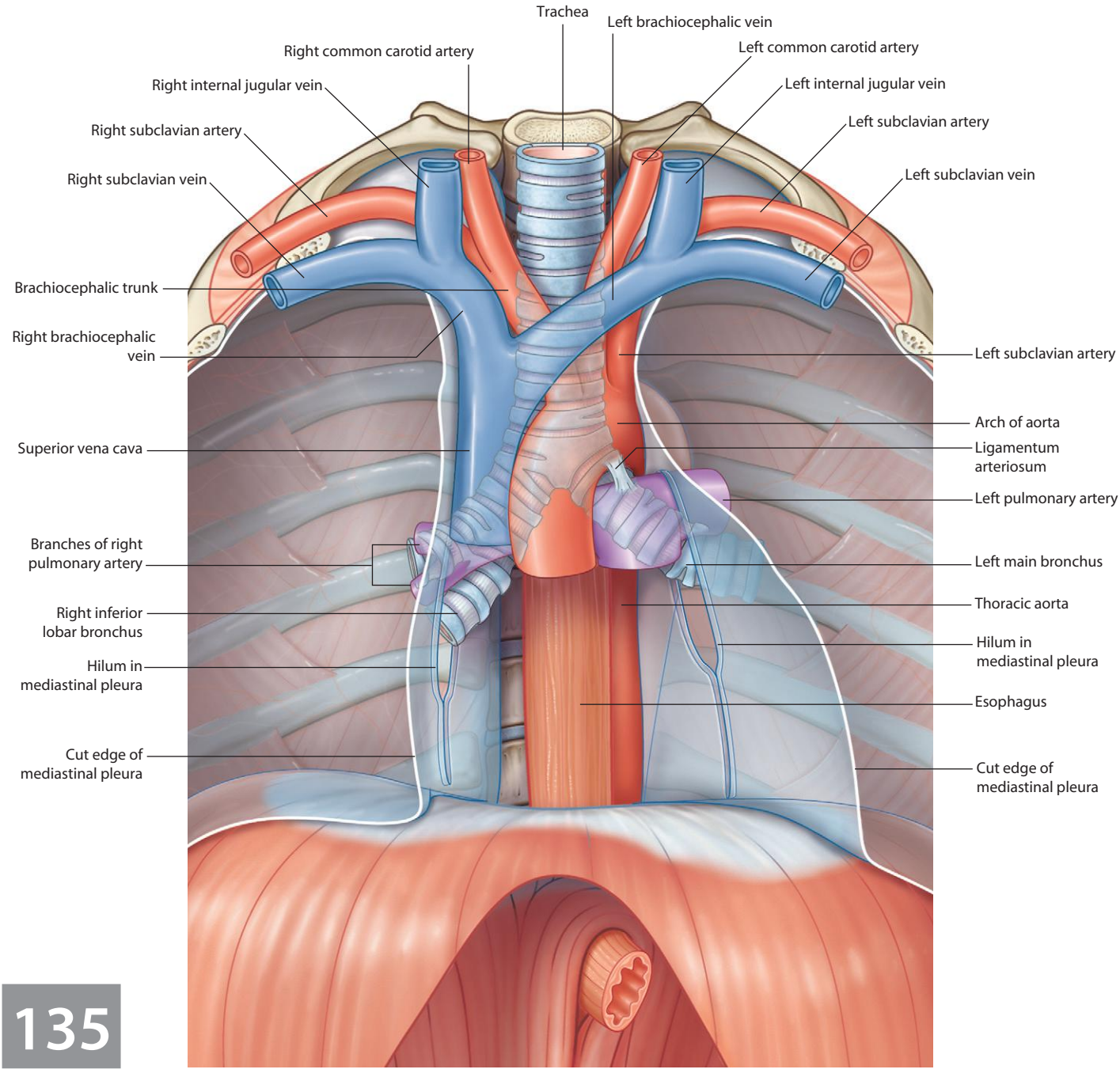

135

Trachea and structures relating to it in the superior mediastinum

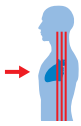

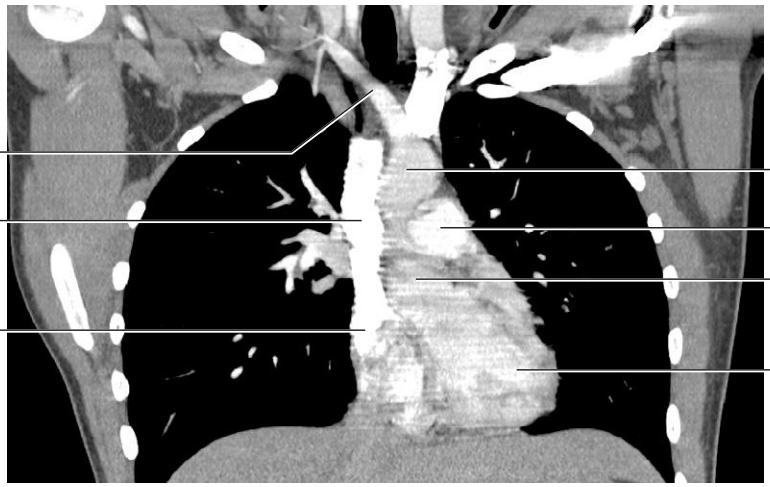

136

Positioning of brachiocephalic trunk in relation to other structures in the superior mediastinum.
CT image, with contrast, in coronal plane

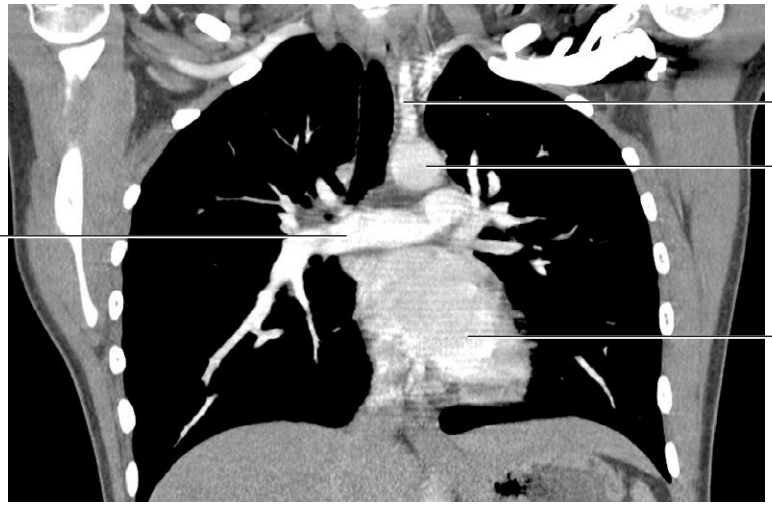

137

Positioning of left common carotid artery in relation to other structures in the superior mediastinum.
CT image, with contrast, in coronal plane

138

Positioning of left subclavian artery and the bifurcation of the trachea in relation to other structures in the superior mediastinum.
CT image, with contrast, in coronal plane

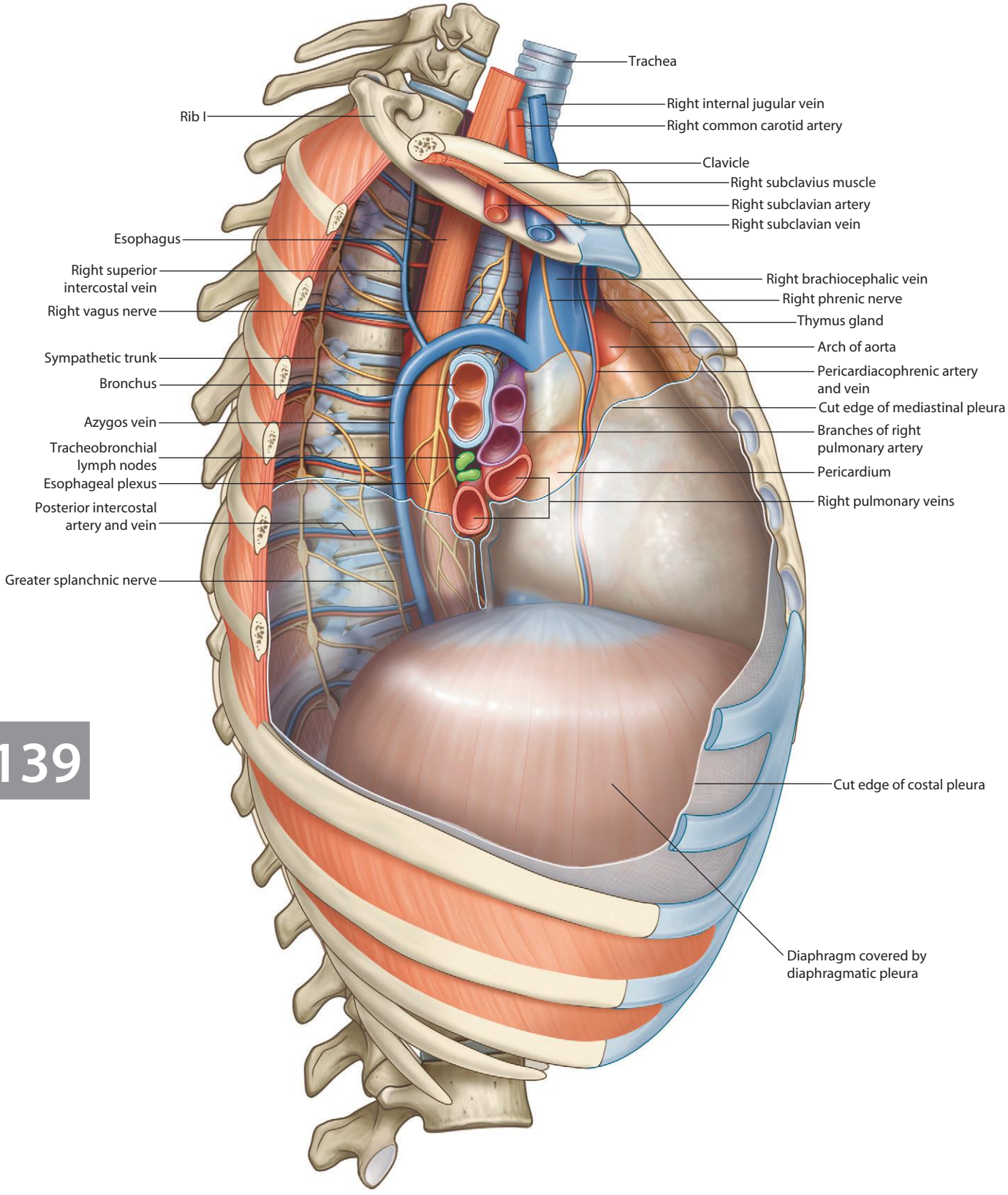

139

Right side of mediastinum and right thoracic cavity

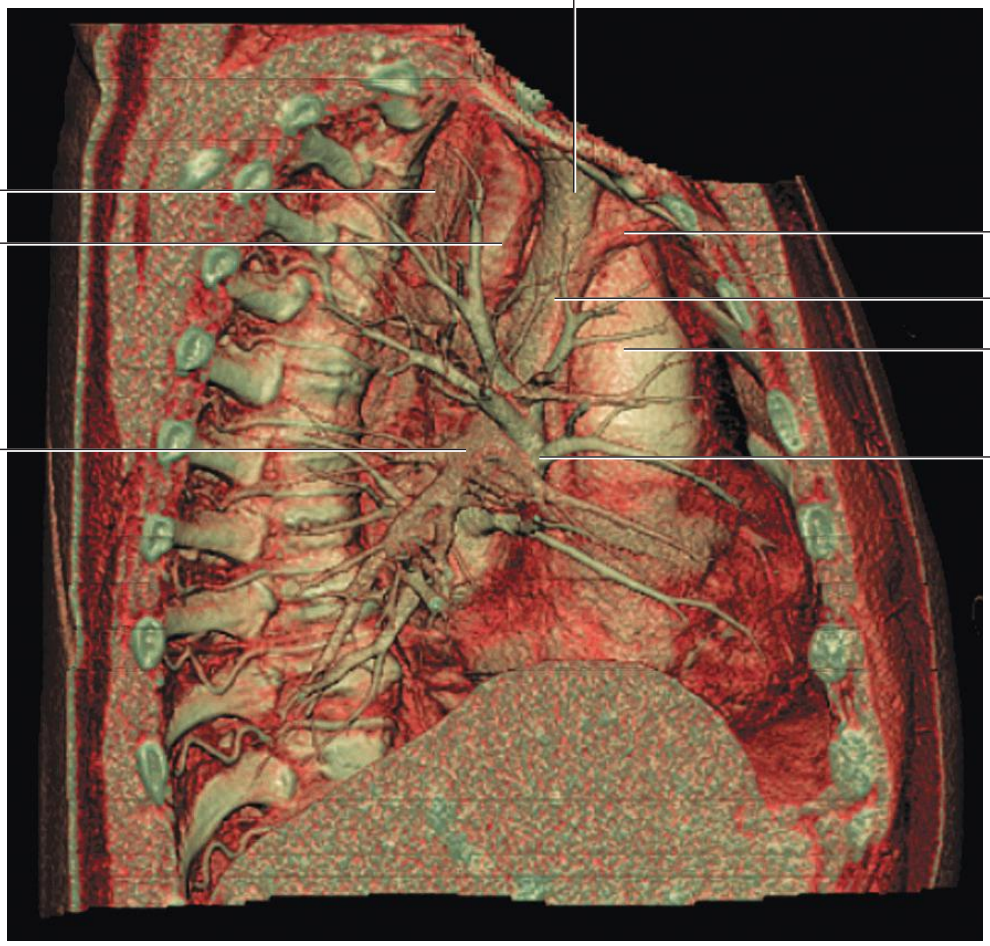

140

View of mediastinal structures from the right side of the thorax.
Volume-rendered lateral view from the right side using multidetector computed tomography

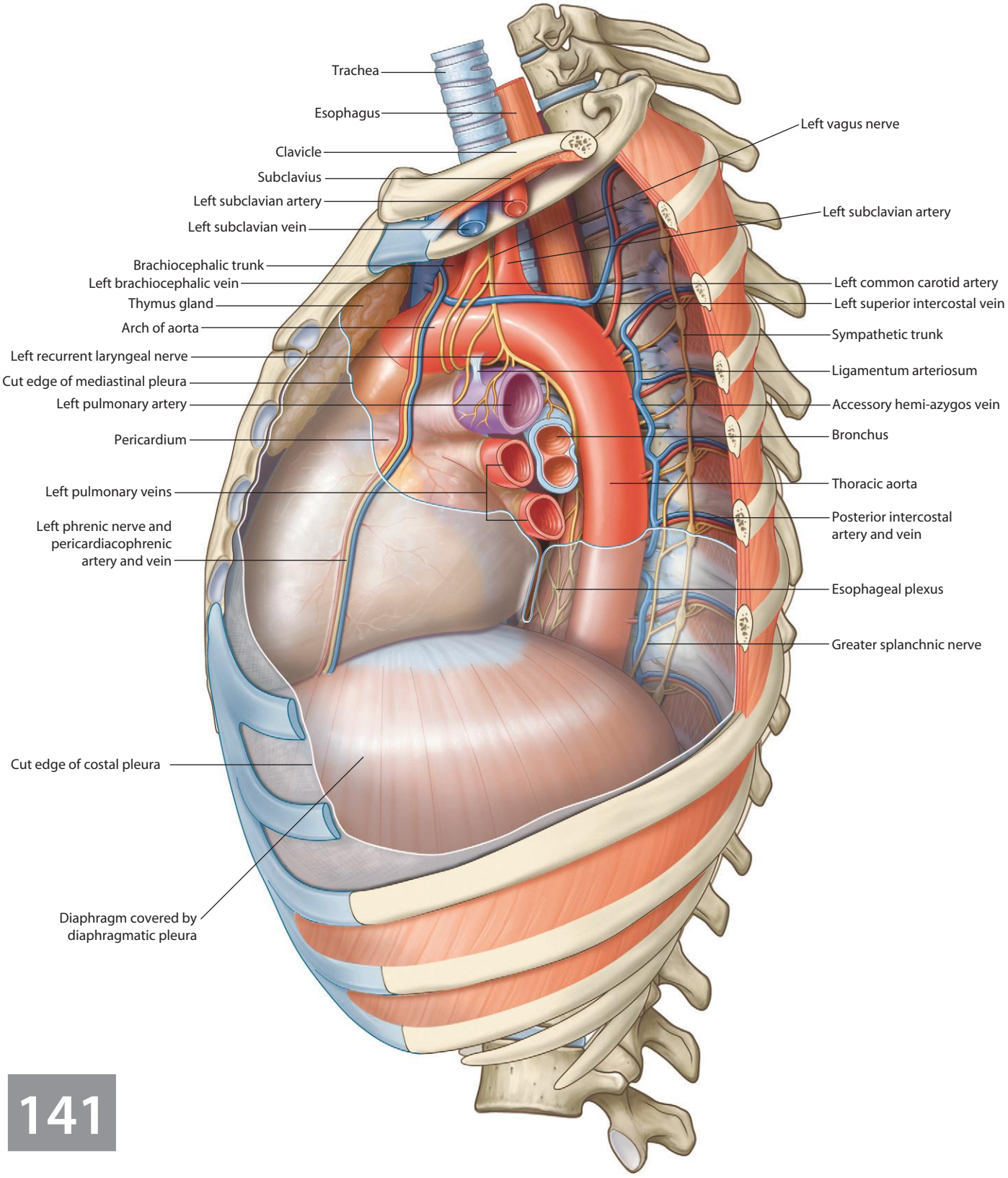

141

Left side of mediastinum and left thoracic cavity

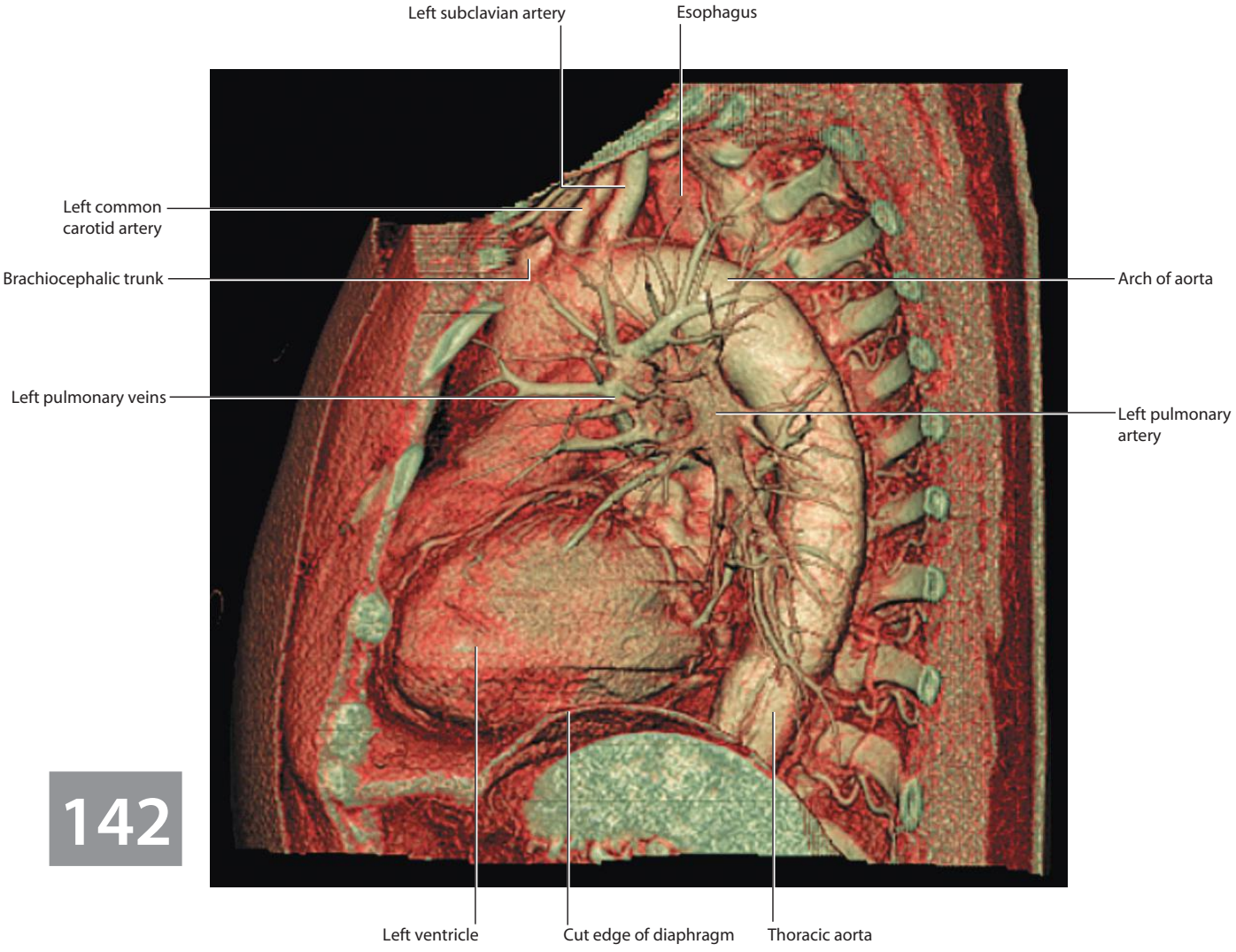

142

View of mediastinal structures from the left side of the thorax.
Volume-rendered lateral view from the left side using multidetector computed tomography

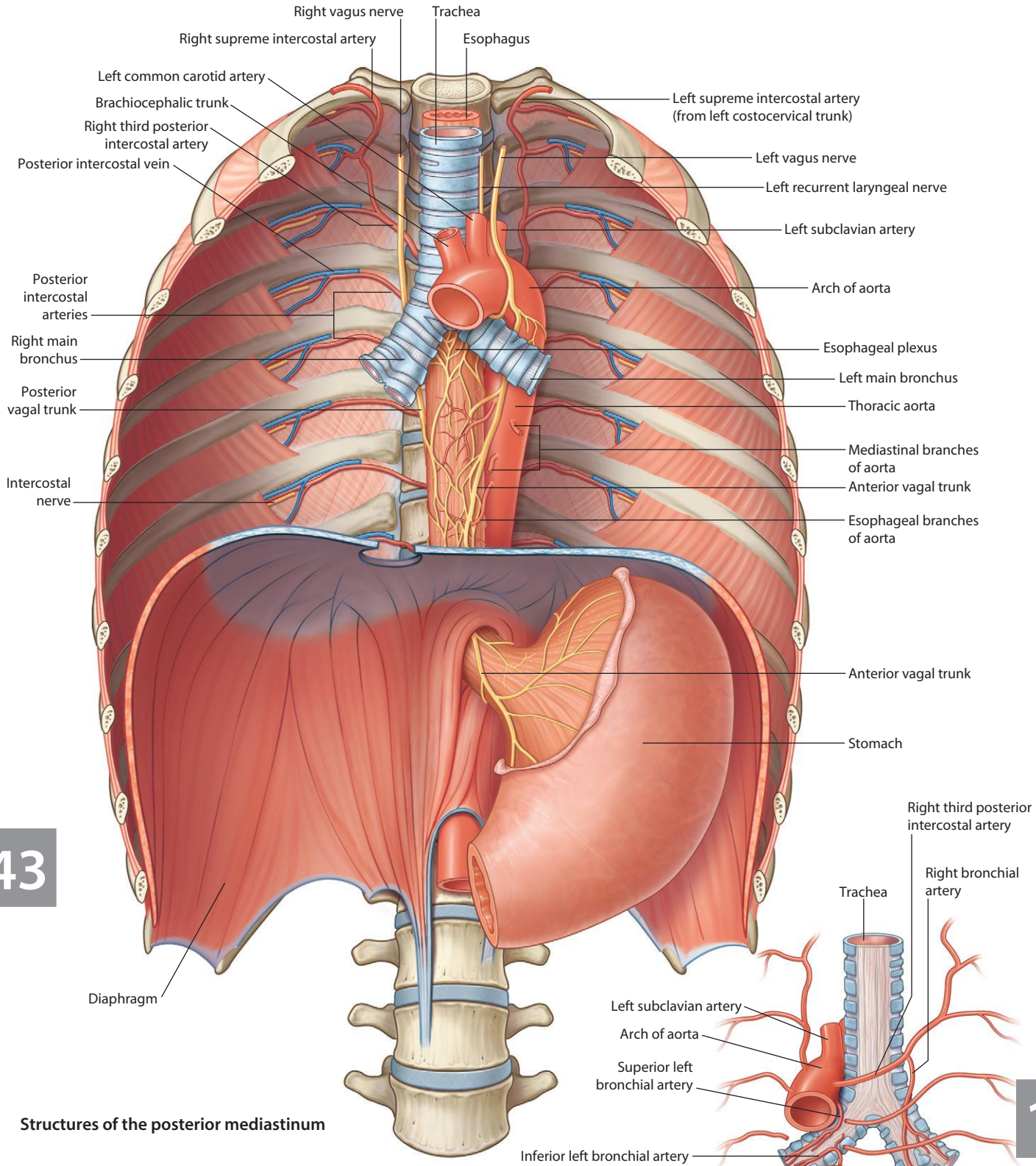

Structures of the posterior mediastinum

143

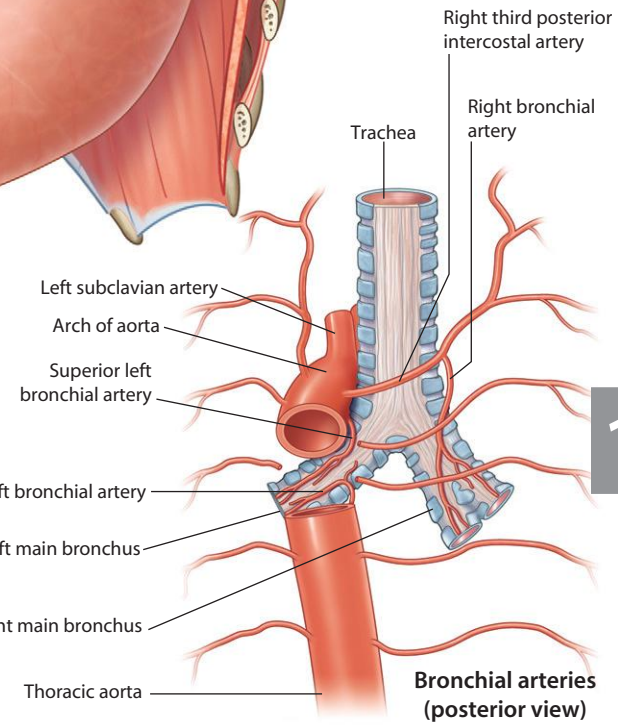

Bronchial arteries (posterior view)

144

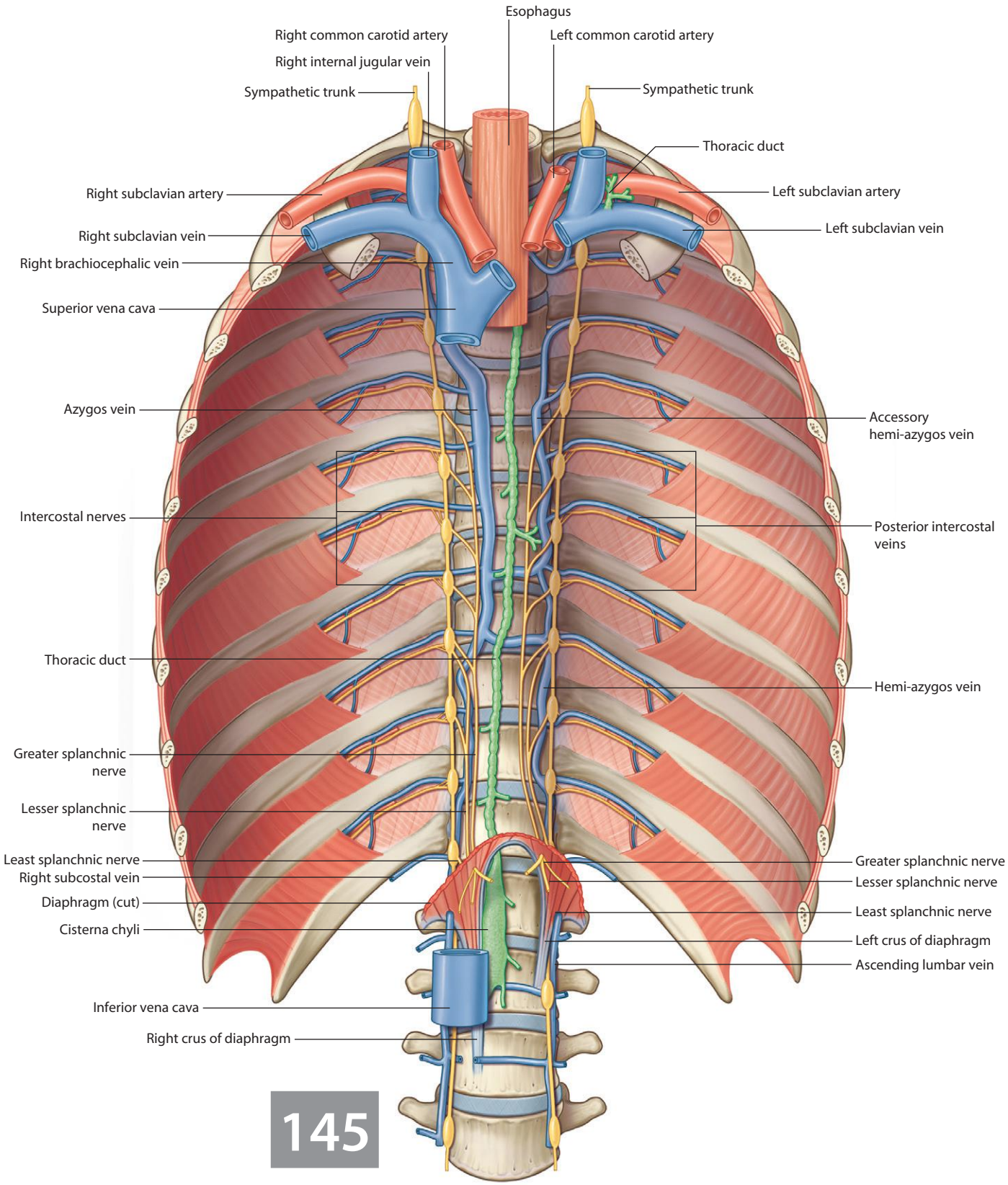

Structures of the posterior mediastinum (thoracic aorta and esophagus removed)

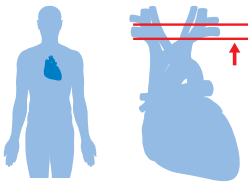

146

147

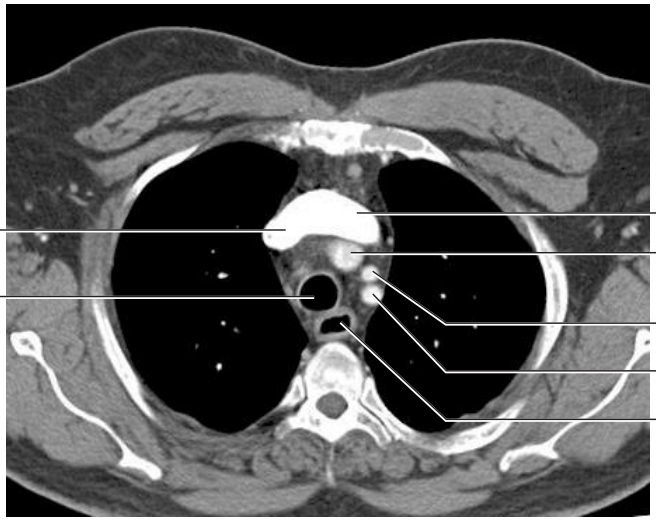

A through I – This is a series of images that pass through the thorax from superior to inferior showing the various mediastinal structures and their relationships with each other.

CT images, with contrast, in axial plane

148

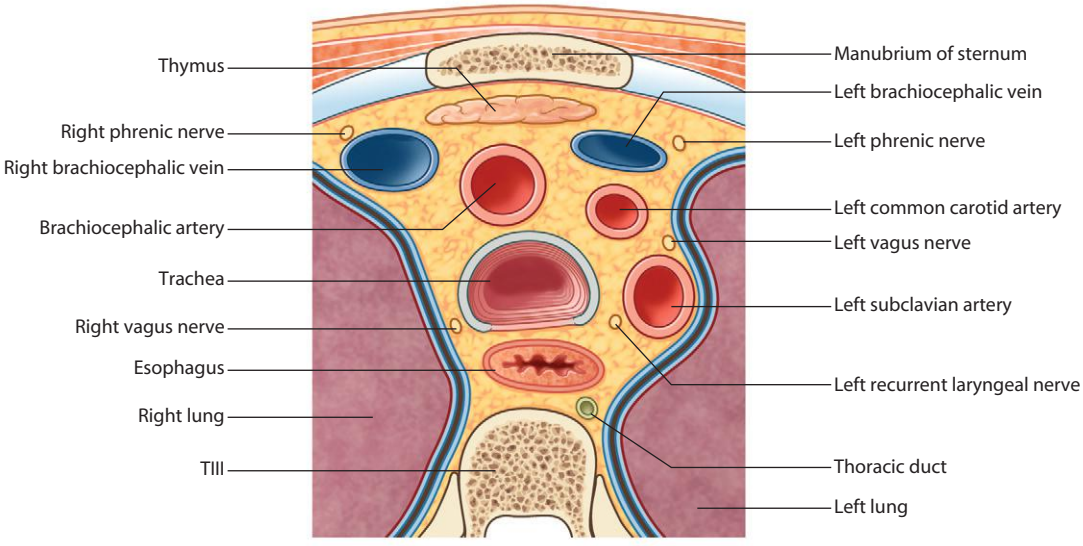

Transverse section through the superior mediastinum at the level of vertebra TIII

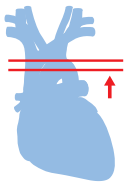

149

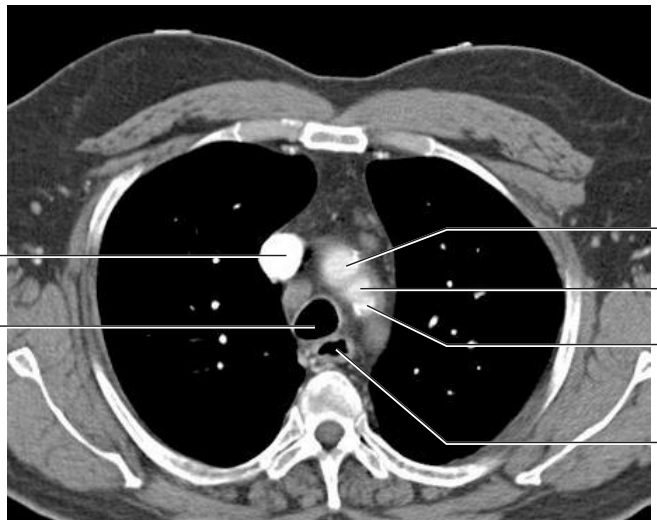

150

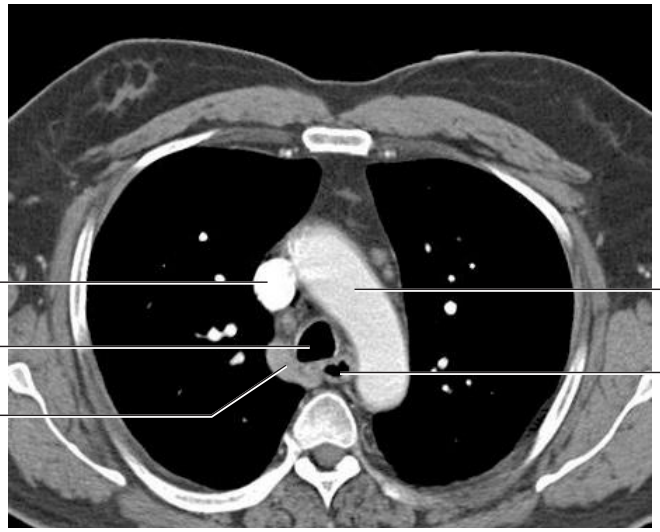

151

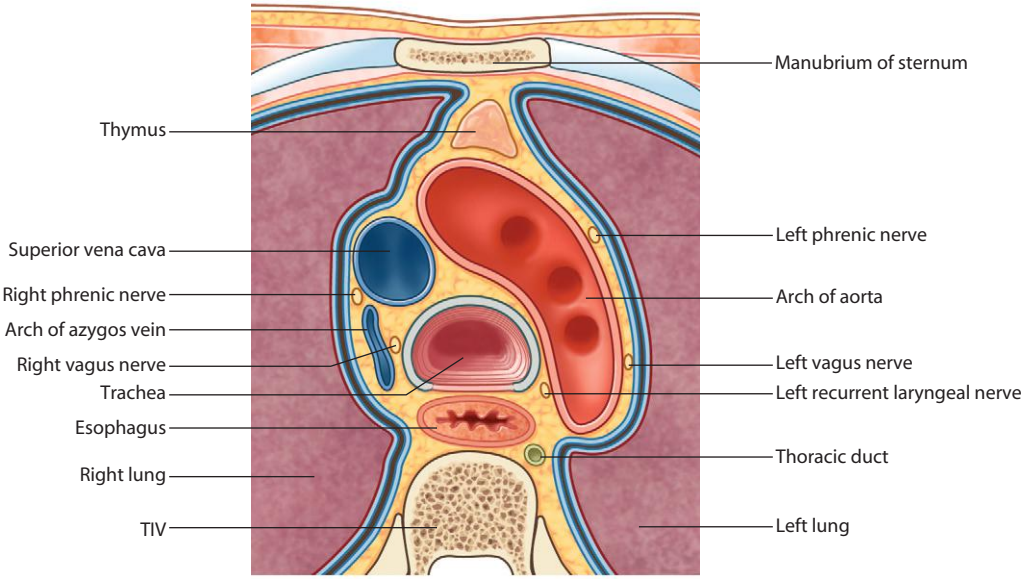

Transverse section through the superior mediastinum at the level of vertebra TIV

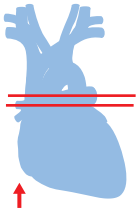

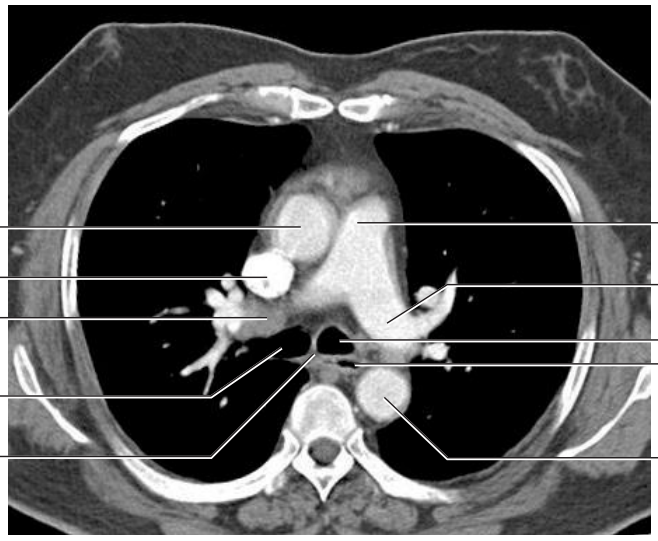

152

Ascending aorta
Superior vena cava
Right pulmonary artery
Right main bronchus
Carina
Pulmonary trunk
Left pulmonary artery
Left main bronchus
Esophagus
Thoracic aorta

E

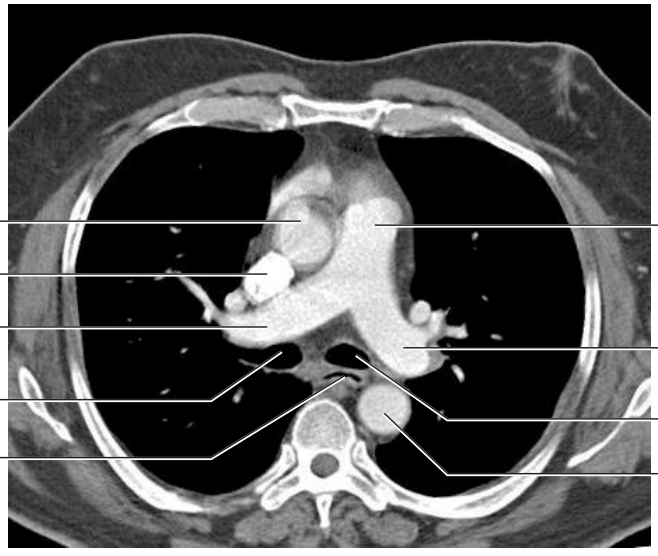

153

Ascending aorta
Superior vena cava
Right pulmonary artery
Right main bronchus
Esophagus
Pulmonary trunk
Left pulmonary artery
Left main bronchus
Thoracic aorta

F

154

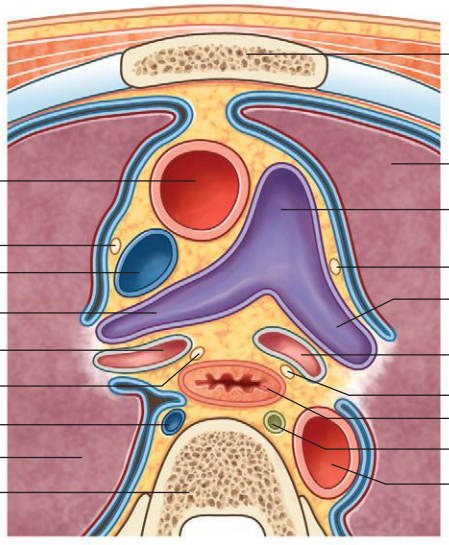

Manubrium of sternum
Ascending aorta
Right phrenic nerve
Superior vena cava
Right pulmonary artery
Right main bronchus
Right vagus nerve
Azygos vein
Right lung
TV
Left lung
Pulmonary trunk
Left phrenic nerve
Left pulmonary artery
Left main bronchus
Left vagus nerve
Esophagus
Thoracic duct
Thoracic aorta

Transverse section through the superior mediastinum at the level of vertebra TV

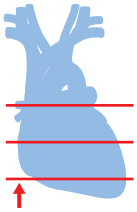

155

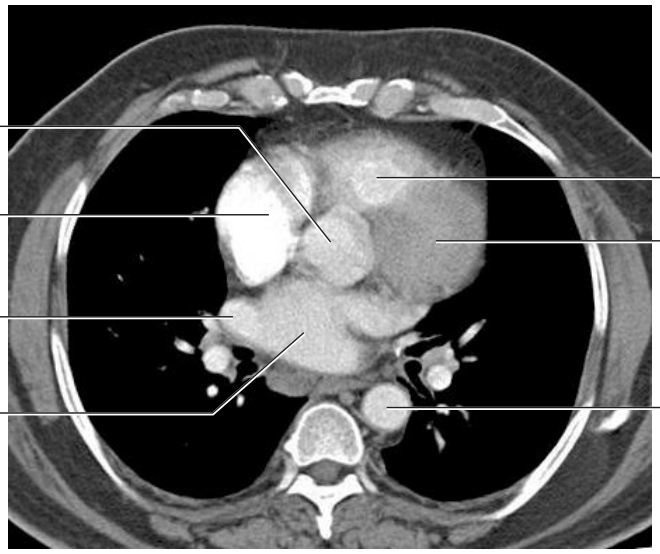

156

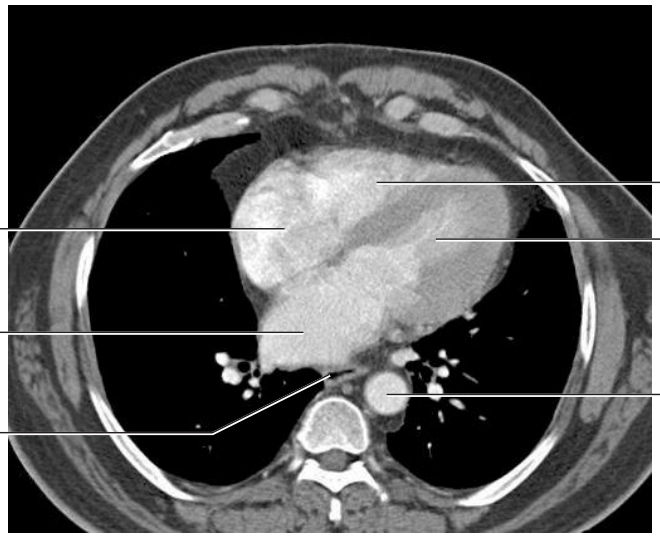

157

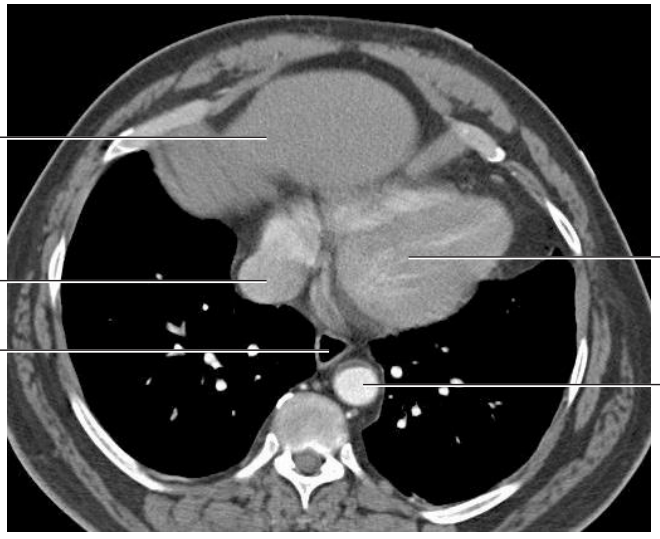

A through I – This is a series of images that pass through the thorax from superior to inferior showing the various mediastinal structures and their relationships with each other.
CT images, with contrast, in axial plane

158

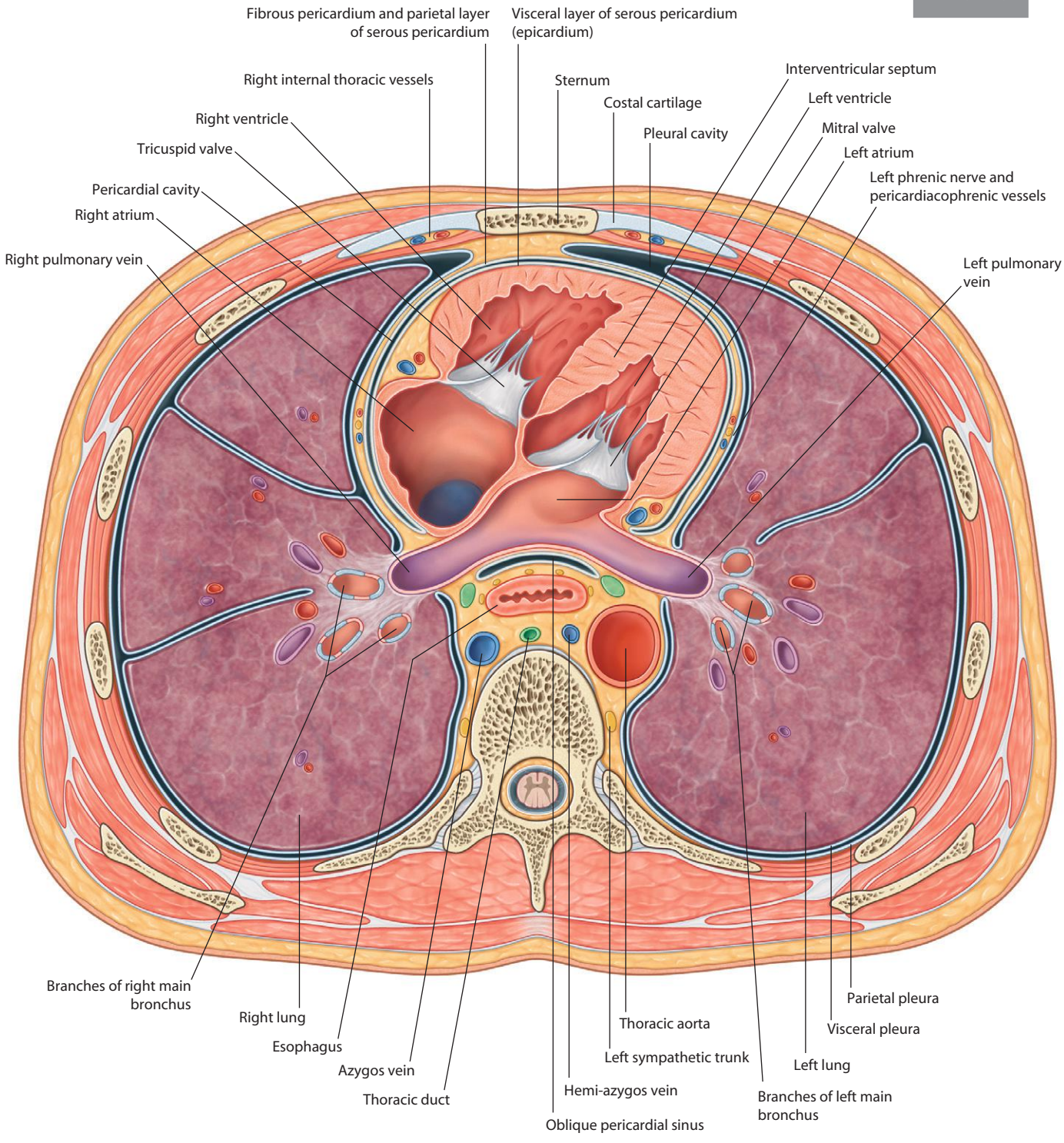

Transverse section through thorax (approximately TVII)

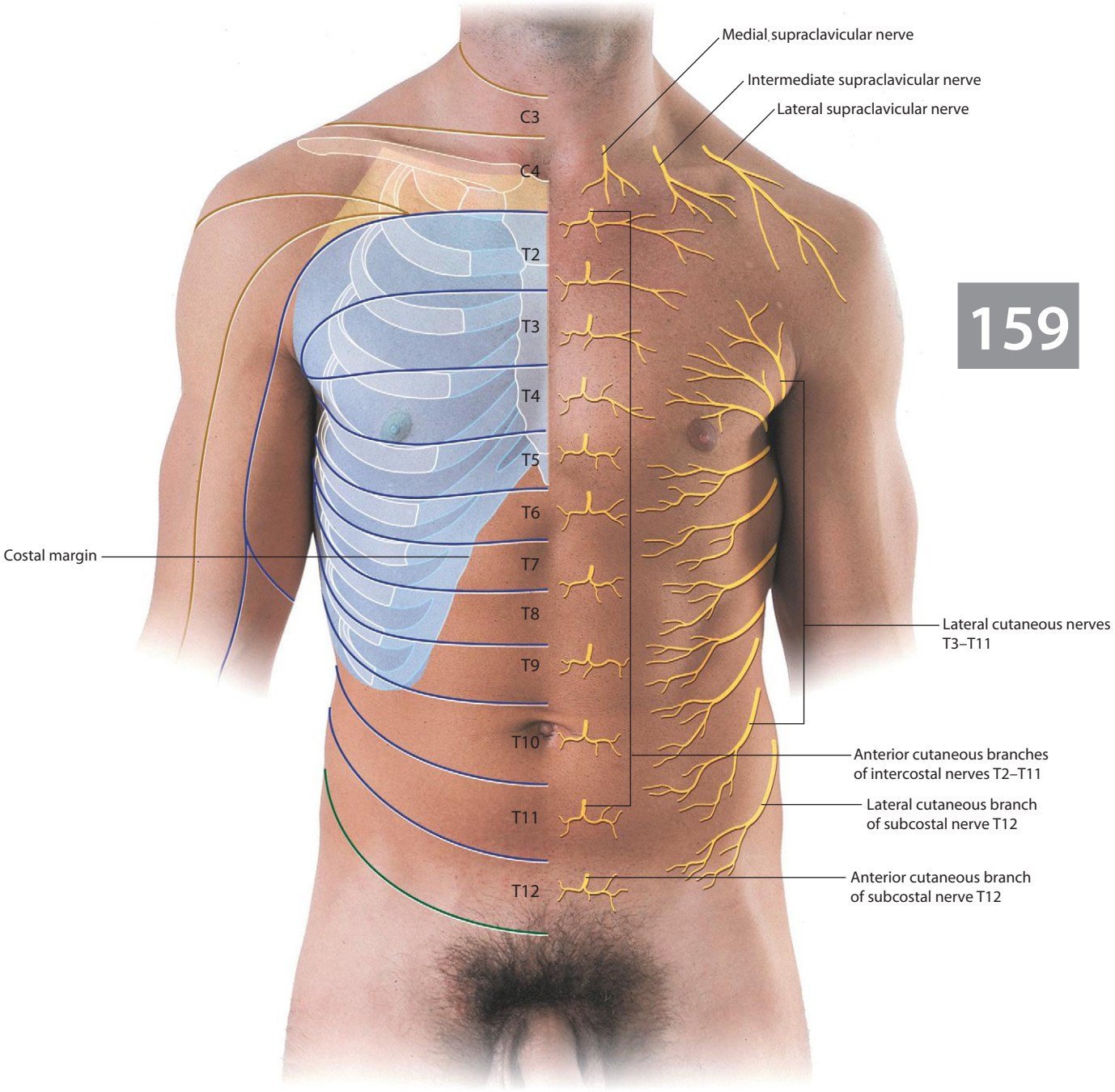

Dermatomes and cutaneous nerves of the thoracic region

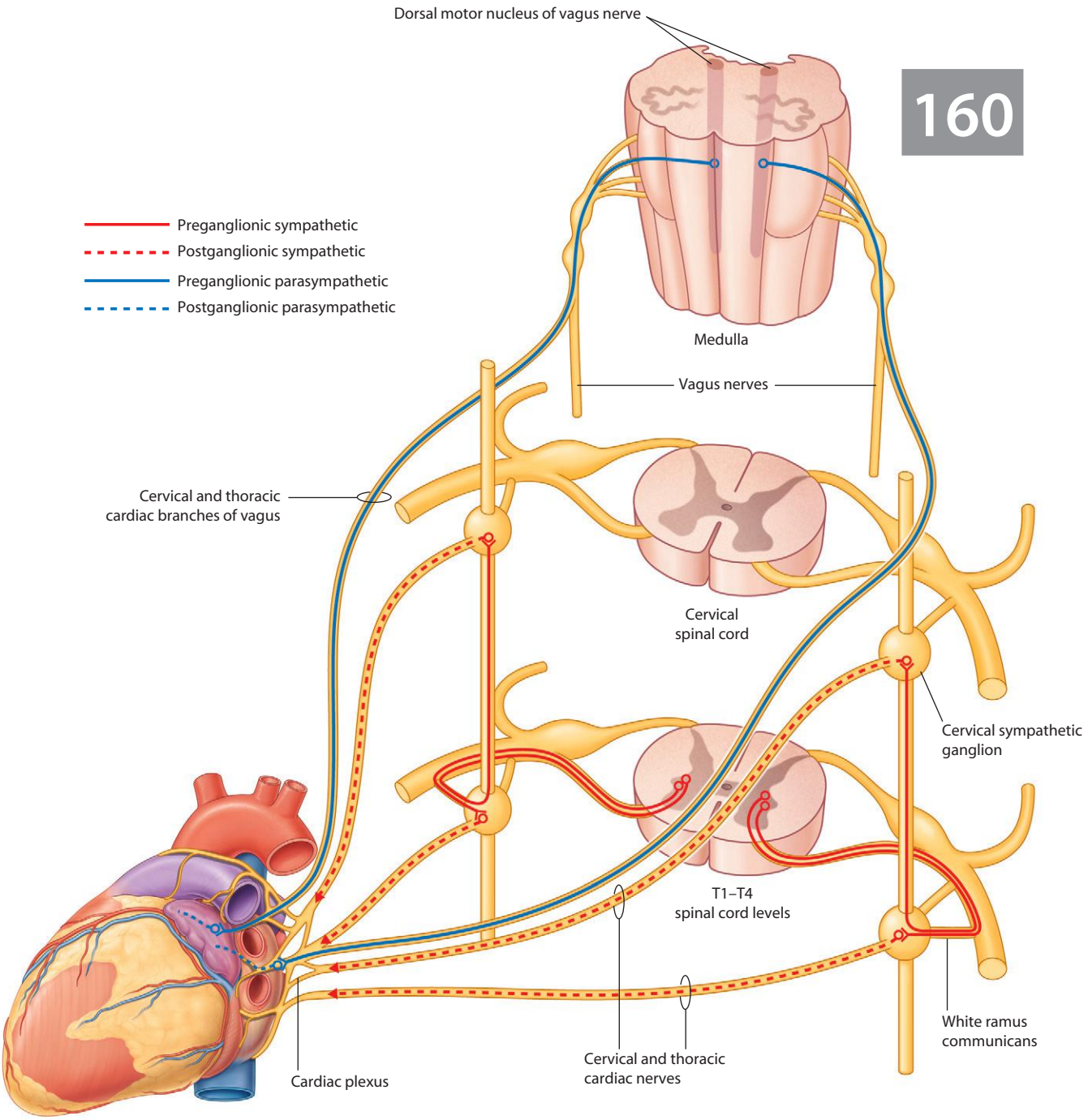

Visceral efferent (motor) innervation of the heart (sympathetic and parasympathetic)

161

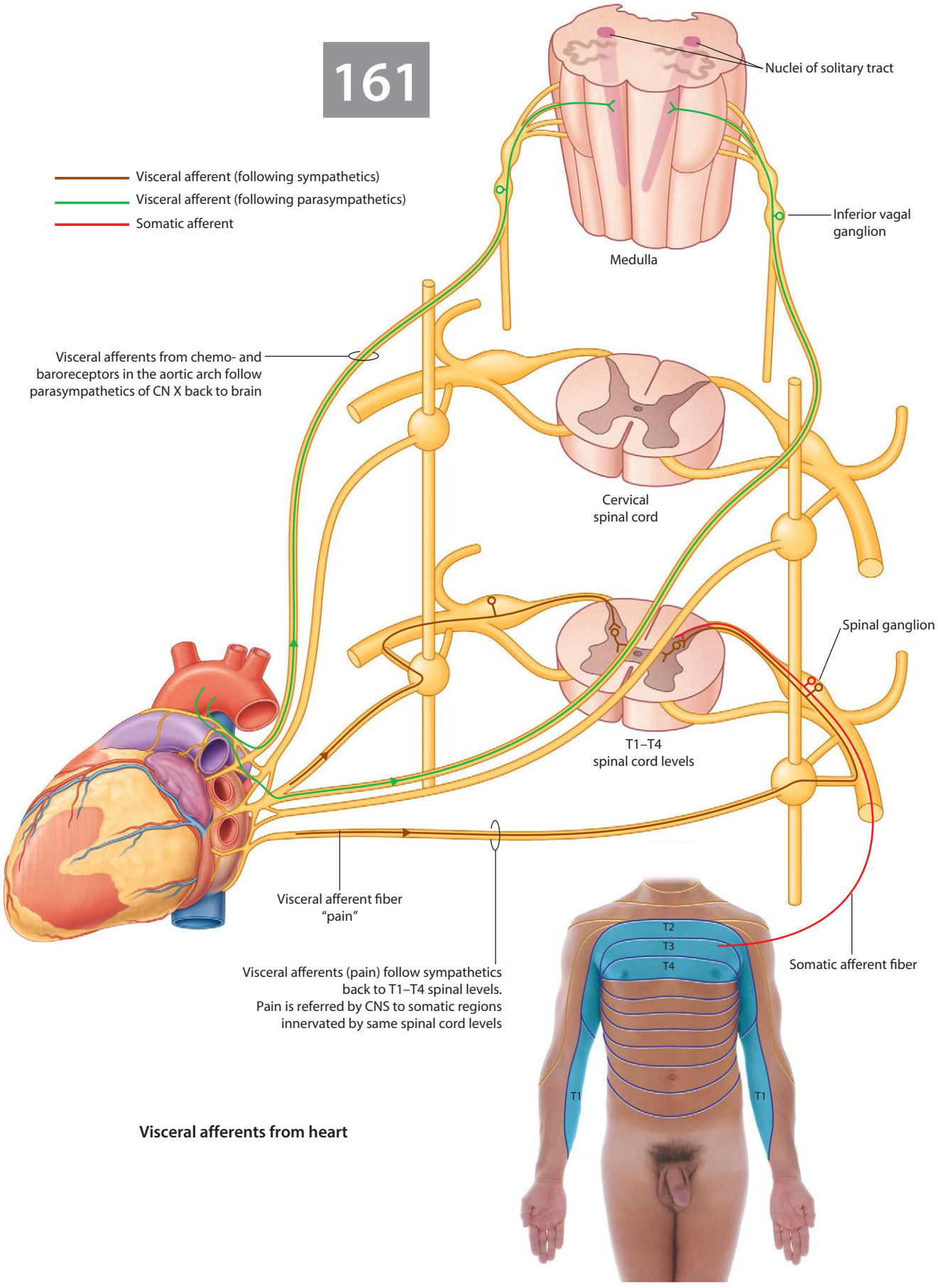

Visceral afferents from heart

Muscles of the pectoral region

Muscle		Origin	Insertion	Innervation	Function
Pectoralis major	1	Medial half of clavicle and anterior surface of sternum, first seven costal cartilages, aponeurosis of external oblique	Lateral lip of intertubercular sulcus of humerus	Medial and lateral pectoral nerves	Adduction, medial rotation, and flexion of the humerus at the shoulder joint
Subclavius	2	Rib I at junction between rib and costal cartilage	Groove on inferior surface of middle third of clavicle	Nerve to subclavius	Pulls clavicle medially to stabilize sternoclavicular joint; depresses tip of shoulder
Pectoralis minor	3	Anterior surfaces of the third, fourth, and fifth ribs, and deep fascia overlying the related intercostal spaces	Coracoid process of scapula	Medial pectoral nerves	Depresses tip of shoulder; protracts scapula

Muscles of the thoracic wall

External intercostal	4	Inferior margin of rib above	Superior margin of rib below	Intercostal nerves; T1–T11	Most active during inspiration; supports intercostal space; moves ribs superiorly
Internal intercostal	5	Lateral edge of costal groove of rib above	Superior margin of rib below deep to the attachment of the related external intercostal	Intercostal nerves; T1–T11	Most active during expiration; supports intercostal space; moves ribs inferiorly
Innermost intercostal	6	Medial edge of costal groove of rib above	Internal aspect of superior margin of rib below	Intercostal nerves; T1–T11	Acts with internal intercostal muscles
Subcostales	7	Internal surface (near angle) of lower ribs	Internal surface of second or third rib below	Related intercostal nerves	May depress ribs
Transversus thoracis	8	Inferior margins and internal surfaces of costal cartilages of second to sixth ribs	Inferior aspect of deep surface of body of sternum, xiphoid process, and costal cartilages ribs IV–VII	Related intercostal nerves	Depresses costal cartilages

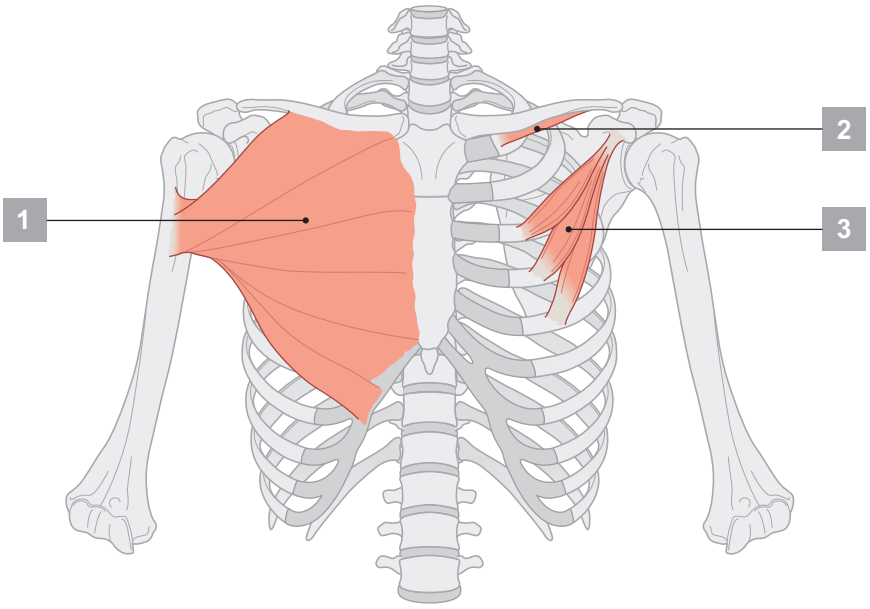
1
2
3

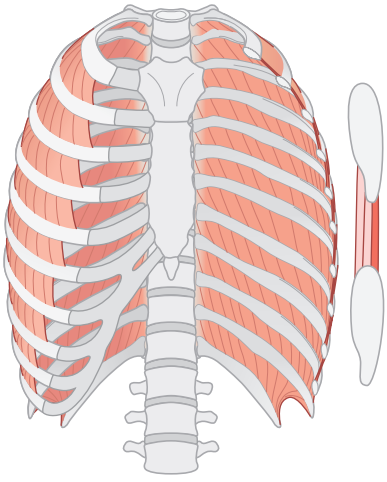
4

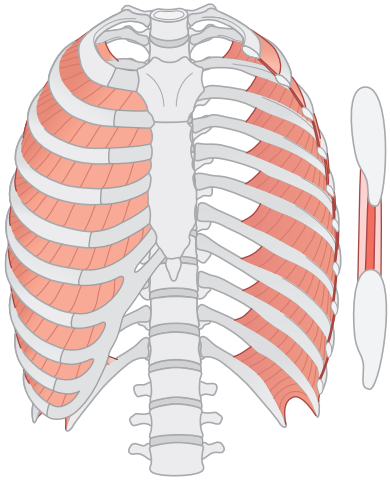
5

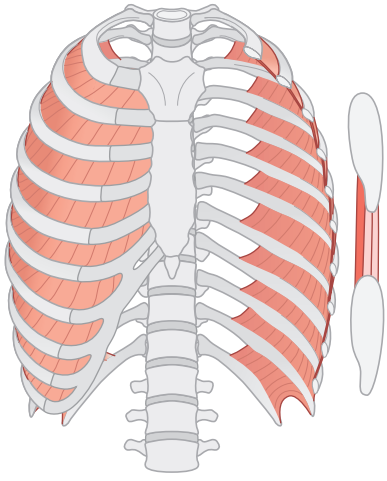
6

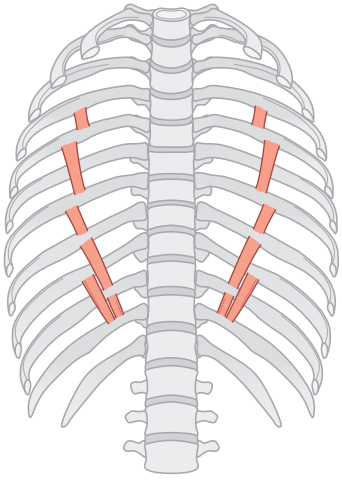
7

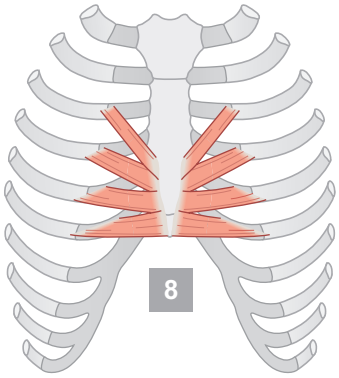
8

Branches of the thoracic aorta

Branches		Origin and course
Pericardial branches	1	A few small vessels to the posterior surface of the pericardial sac
Bronchial branches	2	Vary in number, size, and origin—usually, two left bronchial arteries from the thoracic aorta and one right bronchial artery from the third posterior intercostal artery or the superior left bronchial artery
Esophageal branches	3	Four or five vessels from the anterior aspect of the thoracic aorta, which form a continuous anastomotic chain—anastomotic connections include esophageal branches of the inferior thyroid artery superiorly, and esophageal branches of the left inferior phrenic and the left gastric arteries inferiorly
Mediastinal branches	4	Several small branches supplying lymph nodes, vessels, nerves, and areolar tissue in the posterior mediastinum
Posterior intercostal arteries	5	Usually nine pairs of vessels branching from the posterior surface of the thoracic aorta—usually supply lower nine intercostal spaces (first two spaces are supplied by the supreme intercostal artery—a branch of the costocervical trunk)
Superior phrenic arteries	6	Small vessels from the lower part of the thoracic aorta supplying the posterior part of the superior surface of the diaphragm—they anastomose with the musculophrenic and pericardiacophrenic arteries
Subcostal artery	7	The lowest pair of branches from the thoracic aorta located inferior to rib XII

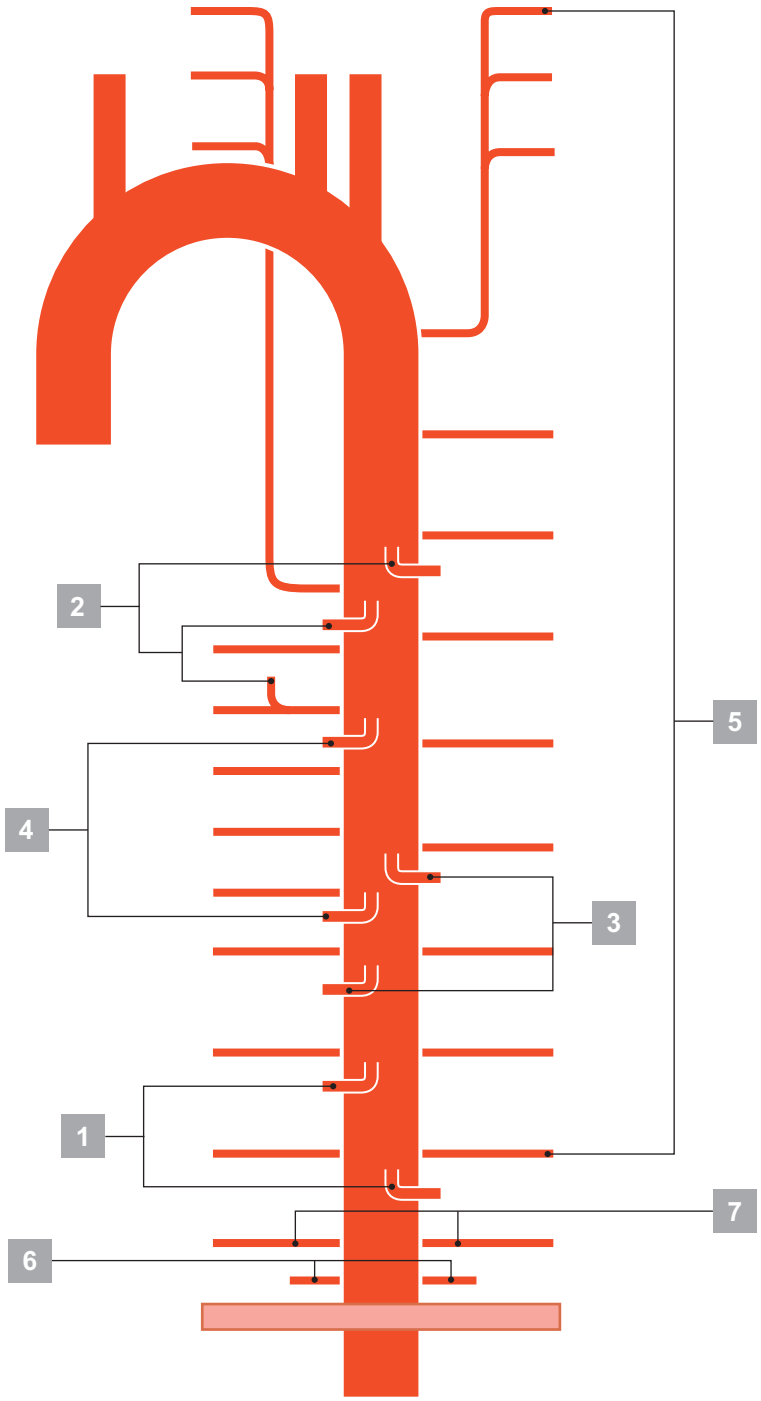
2
5
4
3
1
7
6

This page intentionally left blank

tahir99-VRG & vip.persianss.ir

4

ABDOMEN

CONTENTS

Surface anatomy **134**
Quadrants and regions **135**
Abdominal wall **136**
Muscles **138**
Muscles: rectus sheath **141**
Vessels of the abdominal wall **142**
Arteries and lymphatics of the abdominal wall **143**
Nerves of the abdominal wall **144**
Dermatomes and cutaneous nerves **145**
Inguinal region **146**
Inguinal canal **148**
Inguinal hernias **150**
Anterior abdominal wall **151**
Greater omentum **152**
Abdominal viscera **153**
Peritoneal cavity **154**
Abdominal sagittal section **155**
Abdominal coronal section **156**
Arterial supply of viscera **157**
Stomach **158**
Spleen **159**
Arteries of stomach and spleen **160**
Duodenum **162**
Small intestine **164**
Large intestine **166**
Ileocecal junction **168**
Gastrointestinal tract: imaging **169**
Mesenteric arteries **170**
Liver **172**
Vessels of the liver **174**
Segments of the liver **175**
Pancreas and gallbladder **176**
Vasculature of pancreas and duodenum **179**
Venous drainage of viscera **180**
Portosystemic anastomoses **182**
Posterior wall **183**
Vessels of the posterior wall **184**
Diaphragm **185**
Kidneys **186**
Gross structure of kidneys **188**
Kidneys: imaging **189**
Renal vasculature **190**
Branches of the abdominal aorta **192**
Inferior vena cava **193**
Abdominal aorta and inferior vena cava: imaging **194**
Lumbar plexus **196**
Lumbar plexus: cutaneous distribution **197**
Lymphatics **198**
Abdominal innervation **199**
Splanchnic nerves **200**
Visceral efferent (motor) innervation diagram **201**
Visceral afferent (sensory) innervation and referred pain diagram **202**
Kidney and ureter visceral afferent (sensory) diagram **204**
Tables **206**

tahir99-VRG & vip.persianss.ir

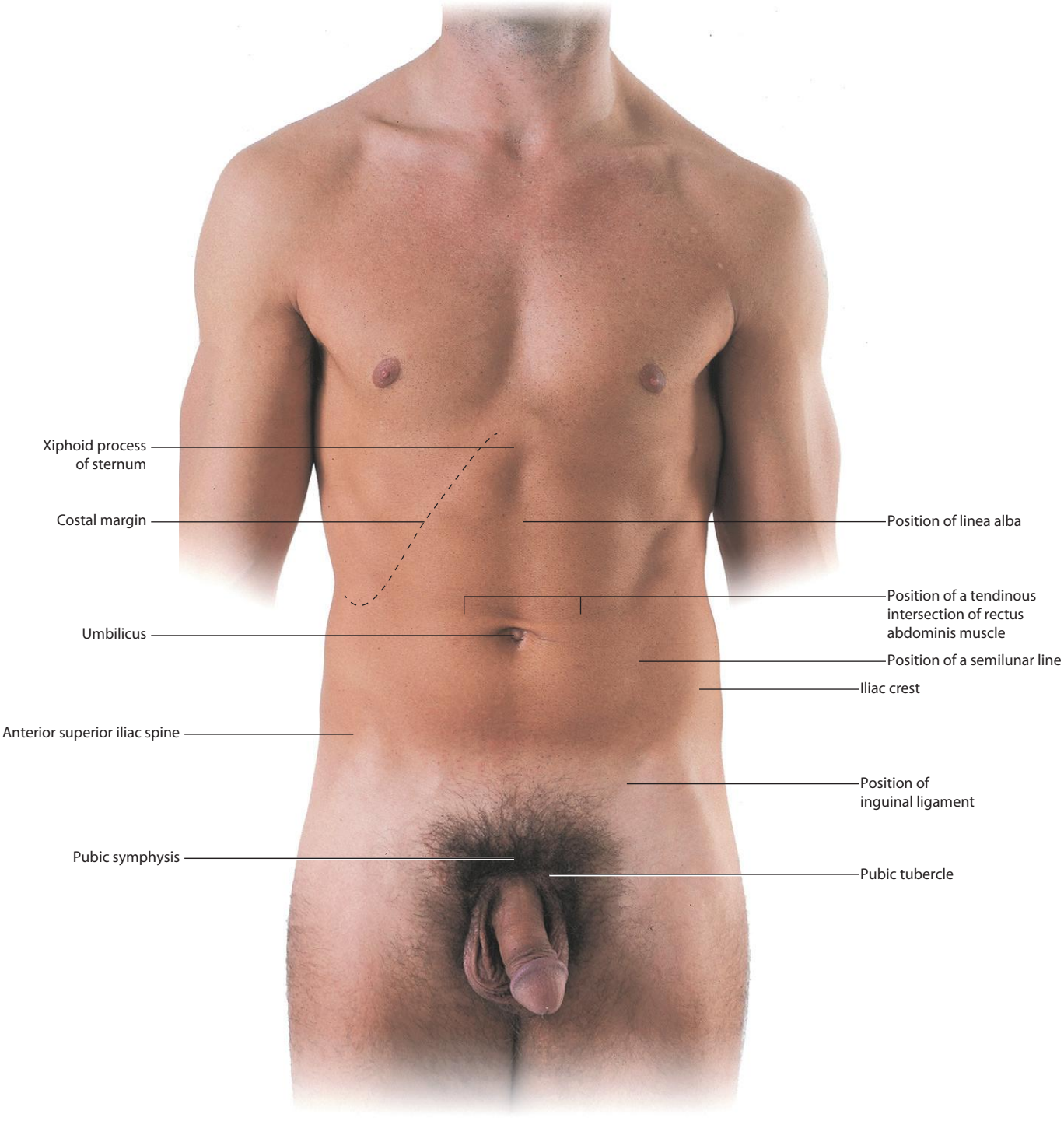

Anterior abdominal wall surface anatomy

tahir99-VRG & vip.persianss.ir

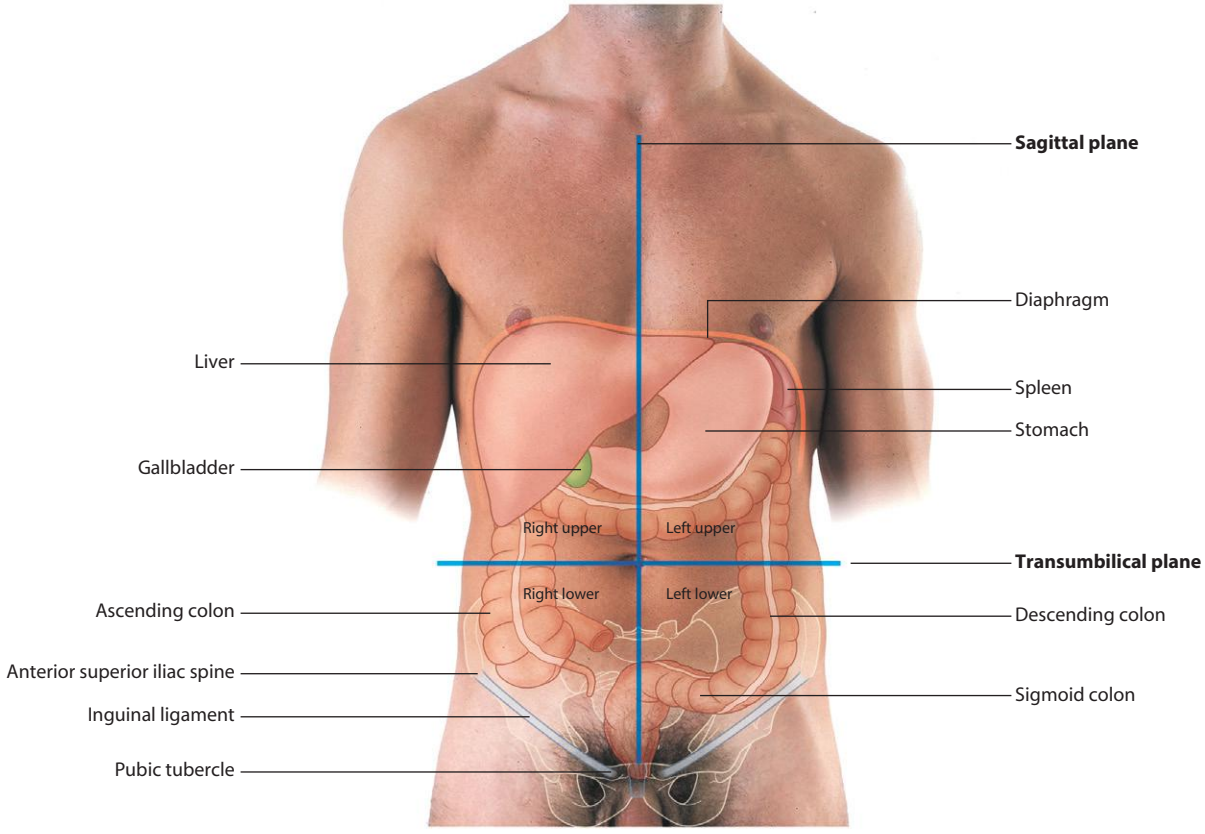

Abdominal quadrants and the positions of major viscera

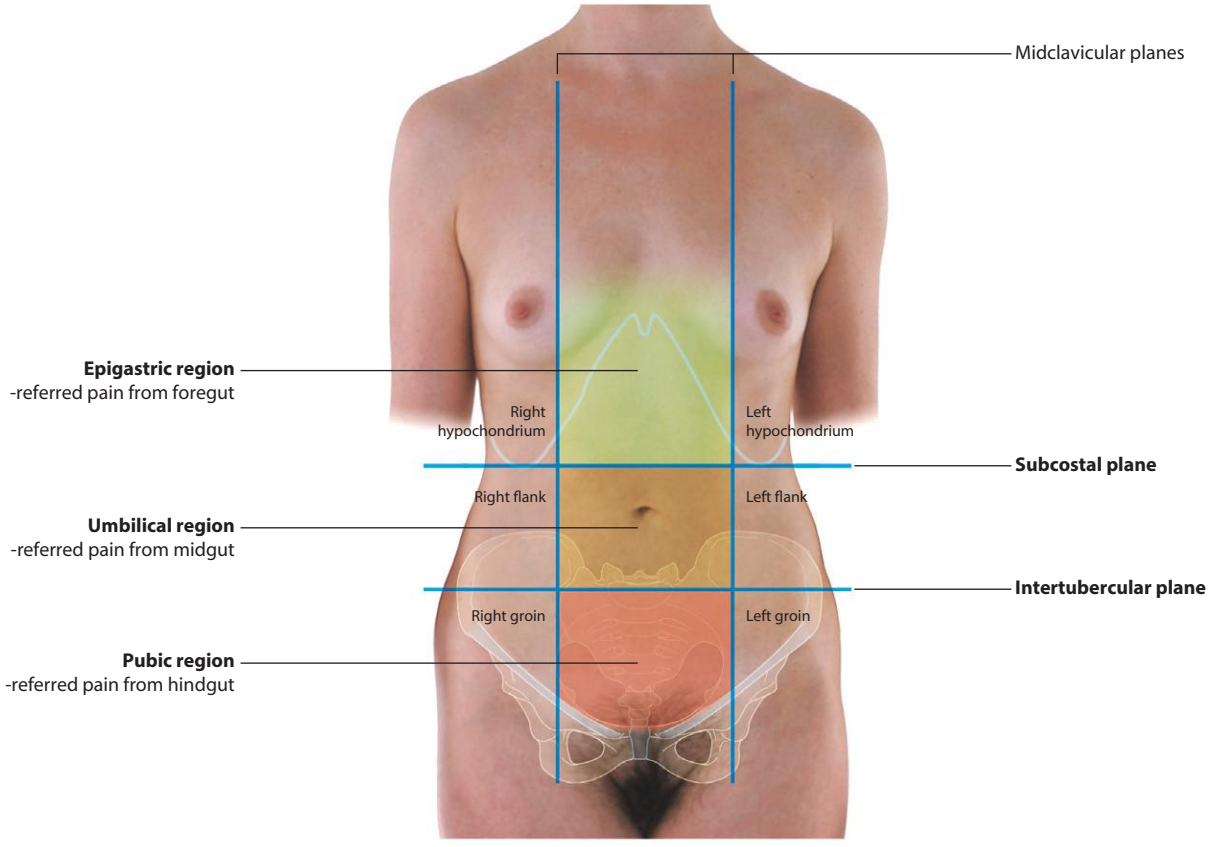

The nine regions of the abdomen

tahir99-VRG & vip.persianss.ir

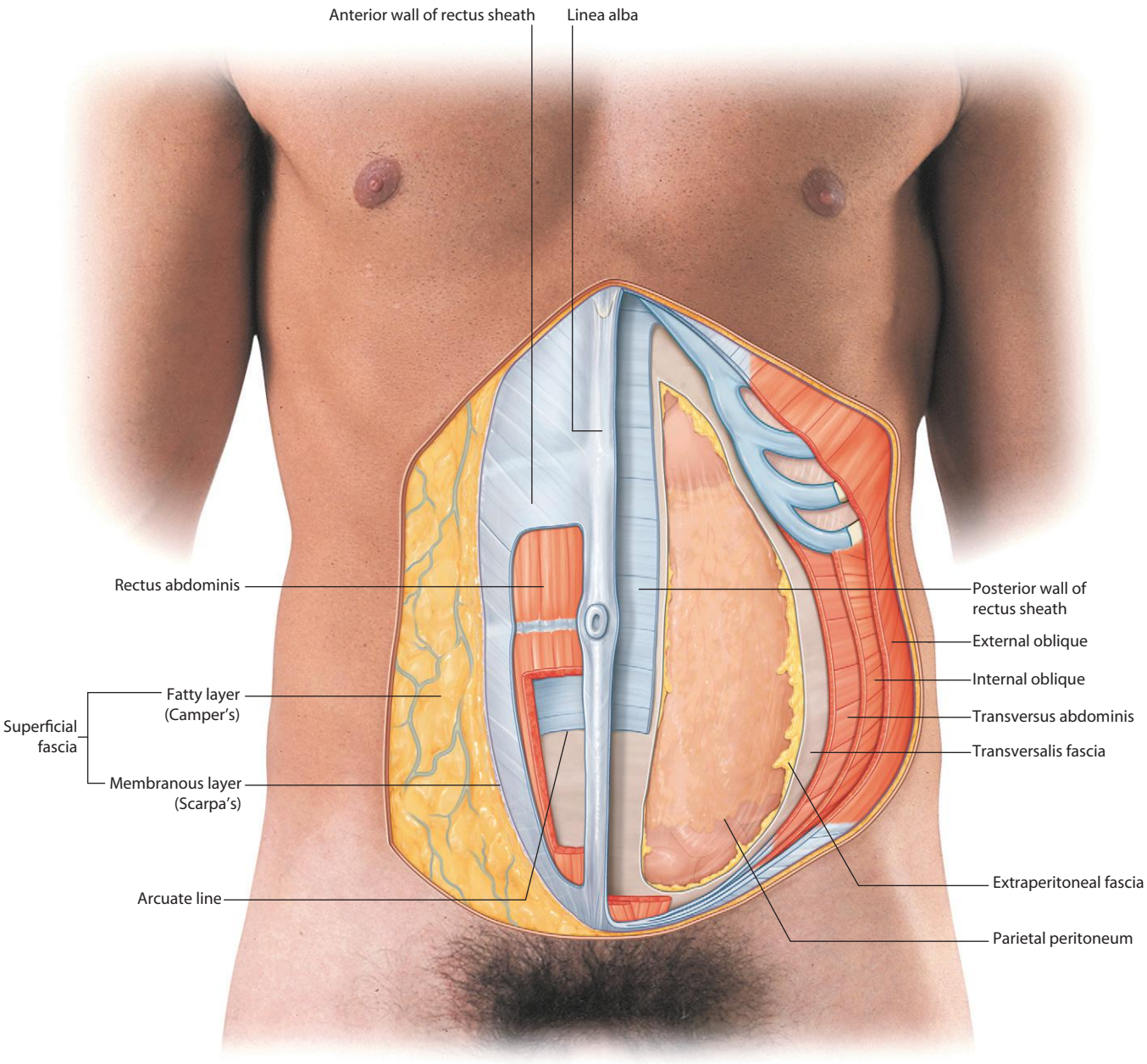

Layers of the abdominal wall

tahir99-VRG & vip.persianss.ir

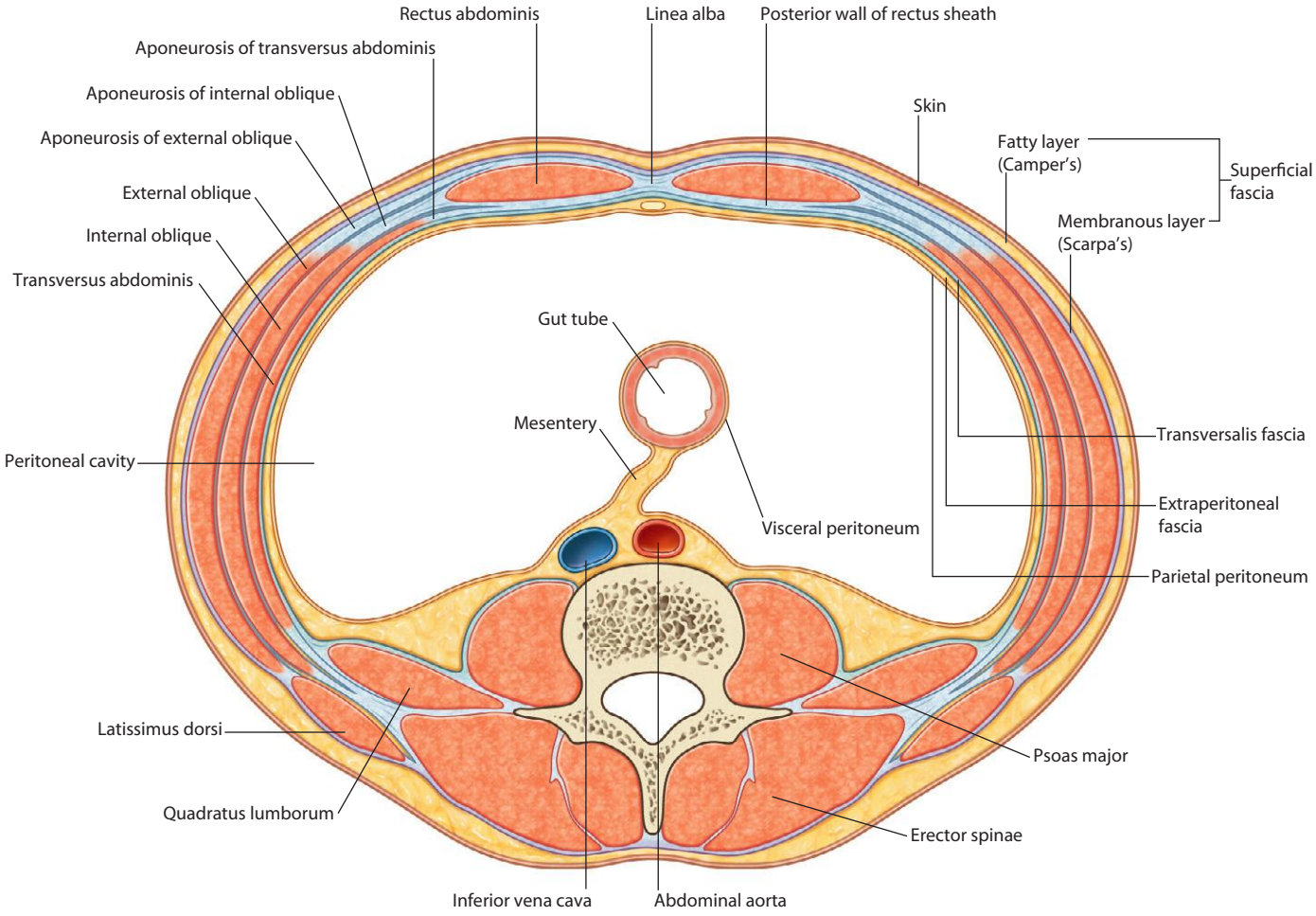

Transverse section showing the layers of the abdominal wall (above umbilicus)

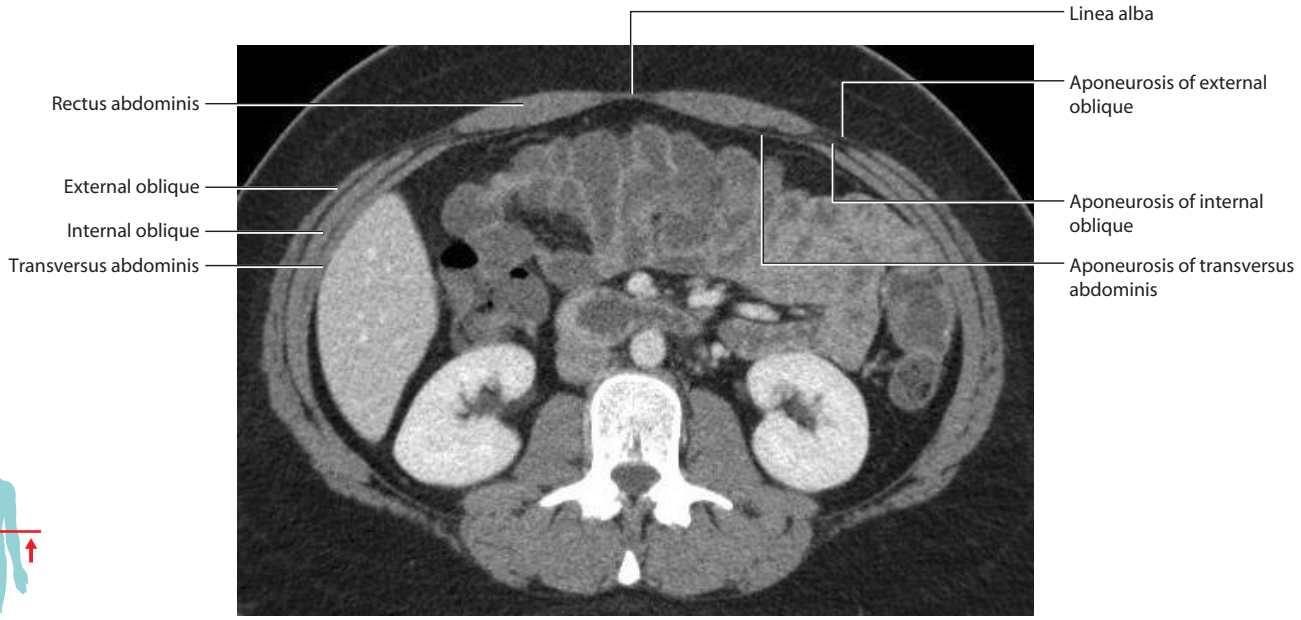

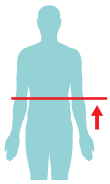

Layers of the abdominal wall.
CT image, with contrast, in axial plane

tahir99-VRG & vip.persianss.ir

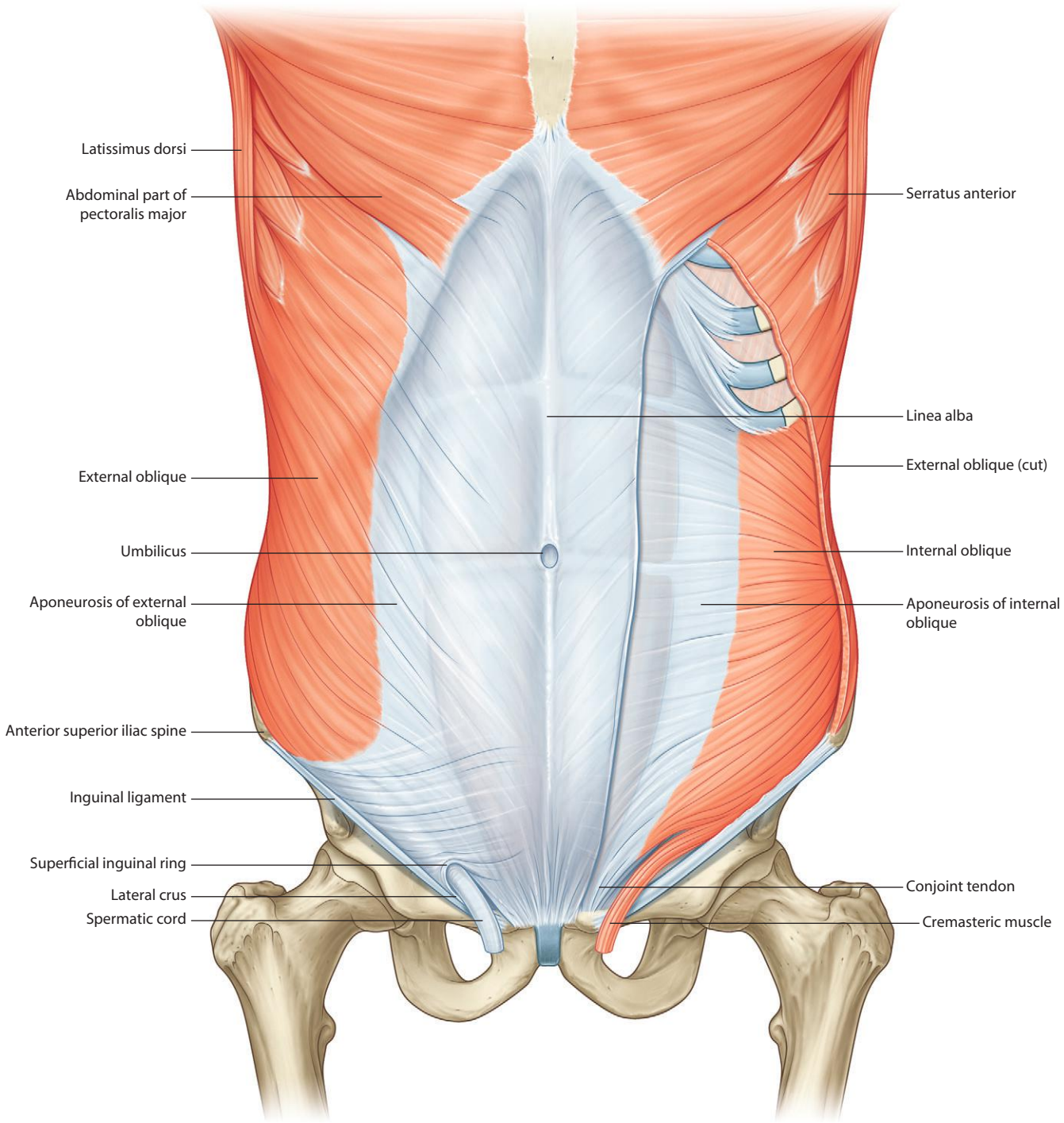

External and internal oblique muscles

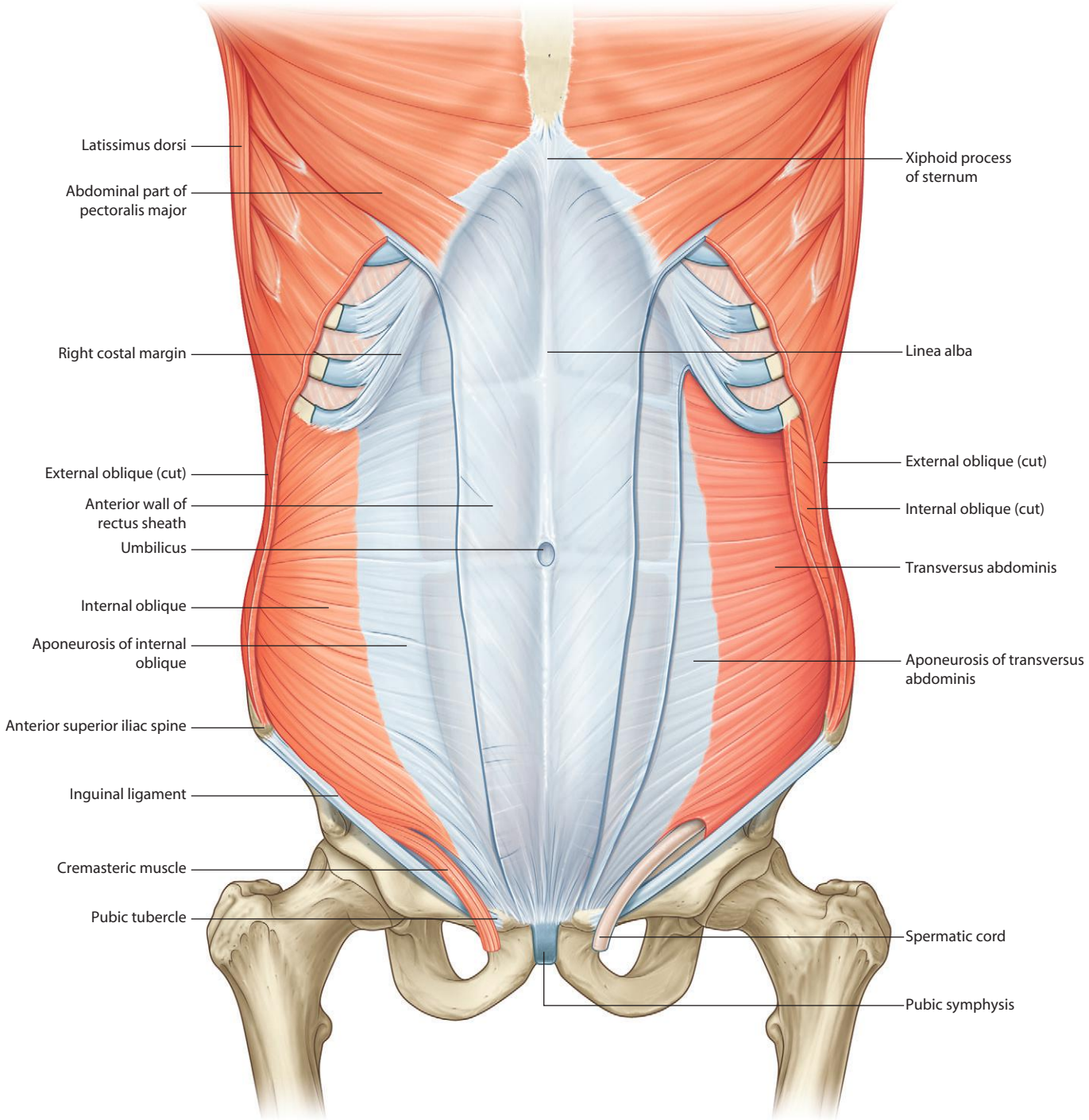

Internal oblique and transversus abdominis muscles

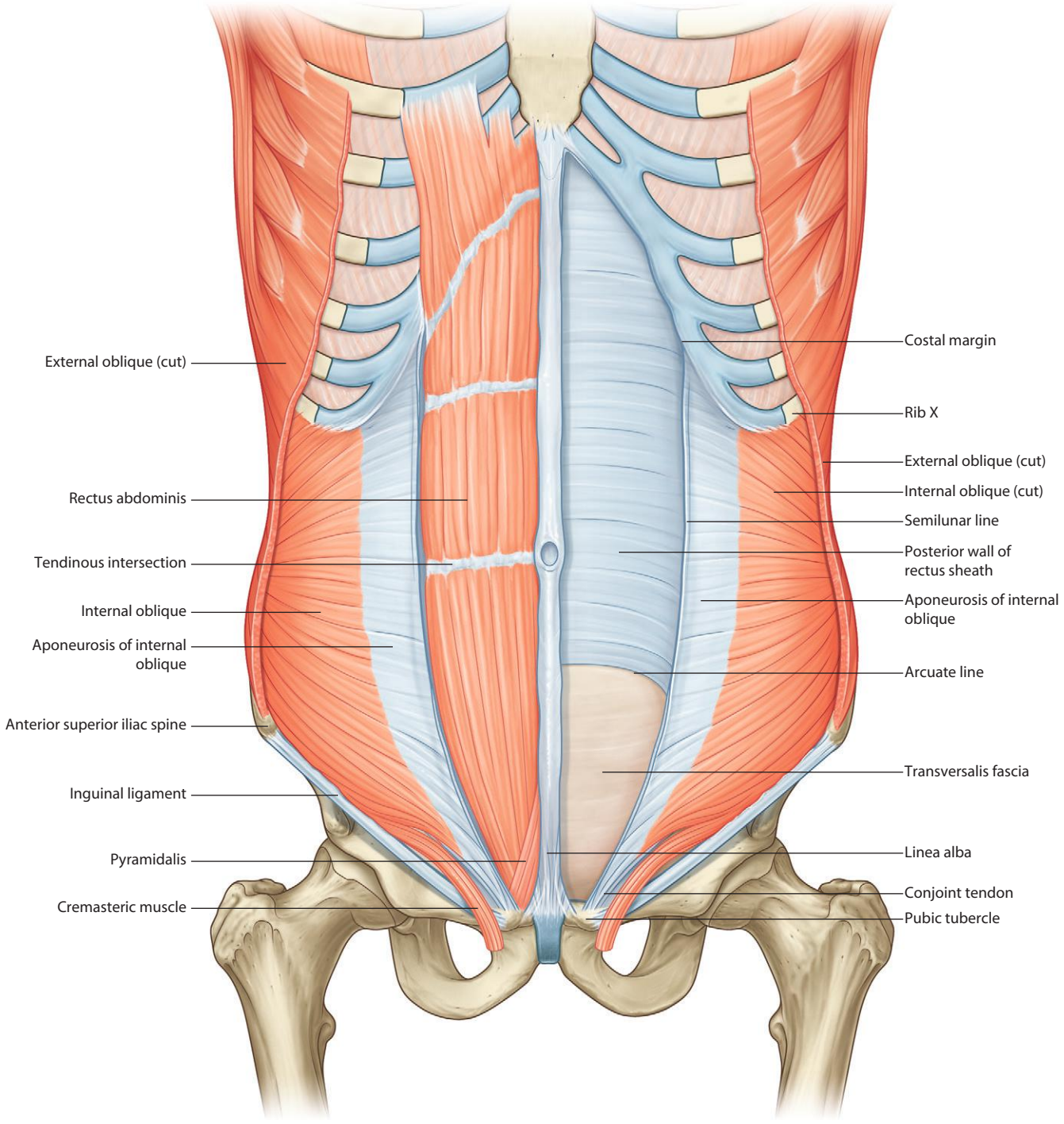

Rectus abdominis and pyramidalis muscles

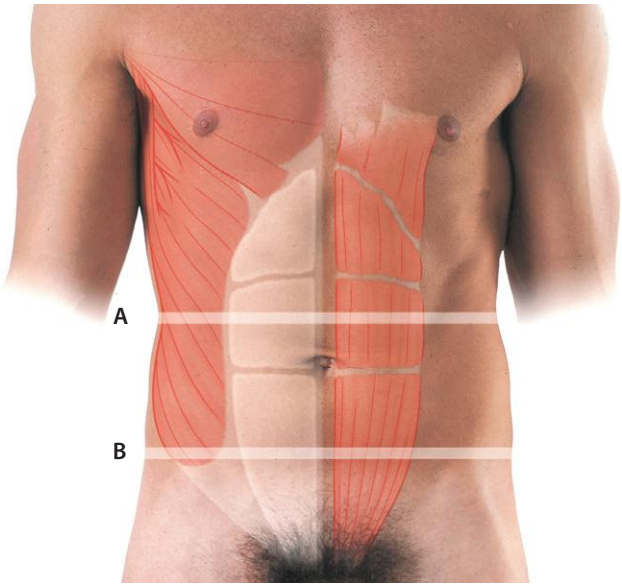

Organization of the rectus sheath.
A. Transverse section through the upper three quarters of the rectus sheath
B. Transverse section through the lower one quarter of the rectus sheath

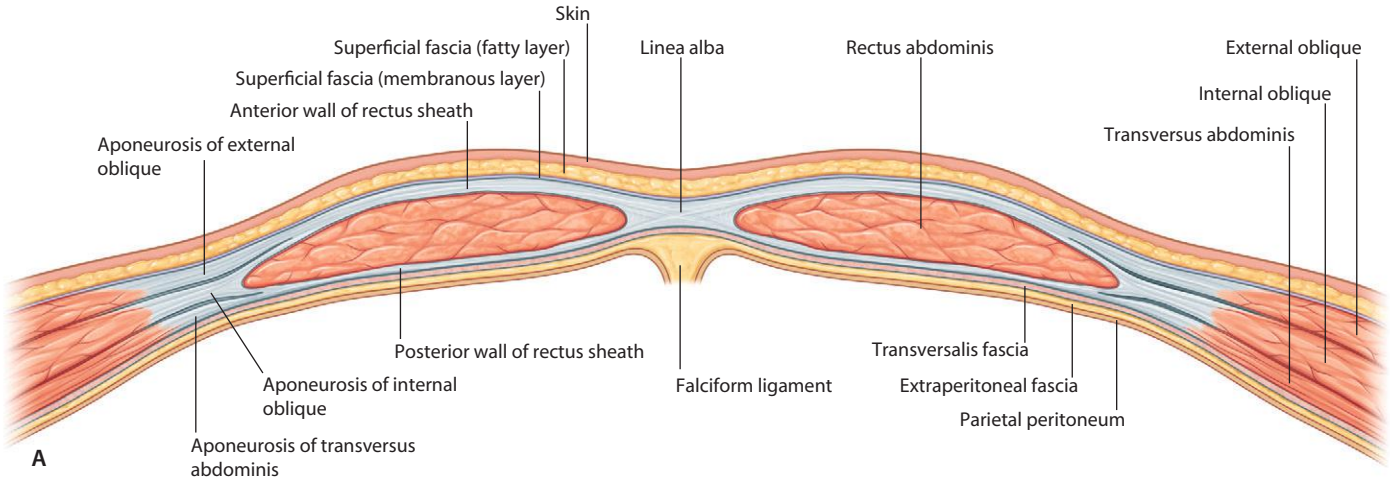

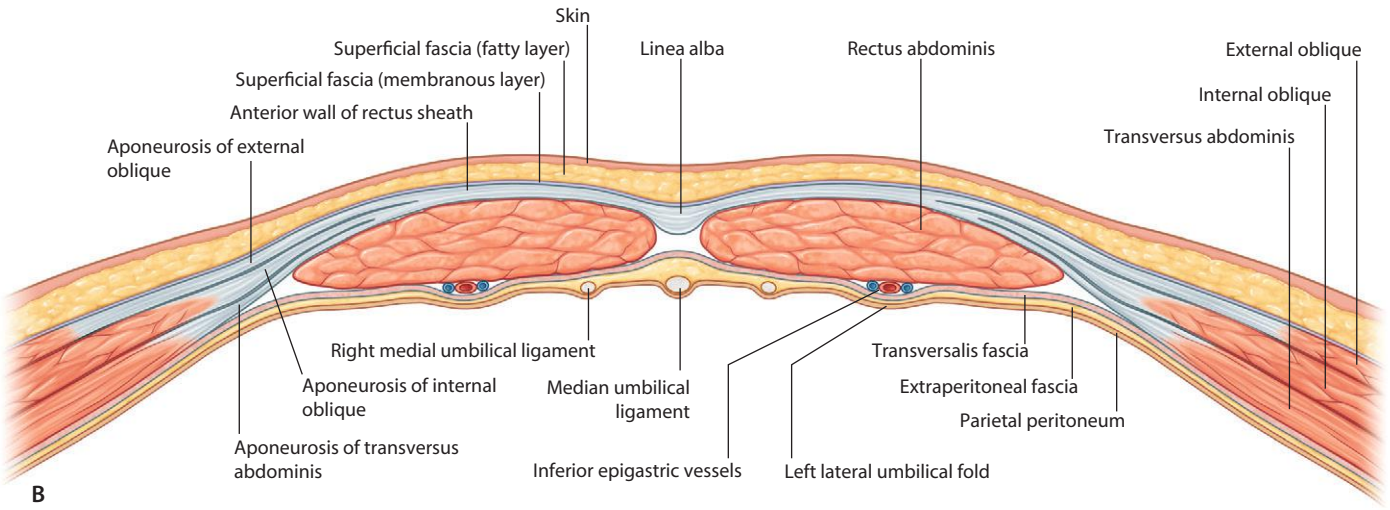

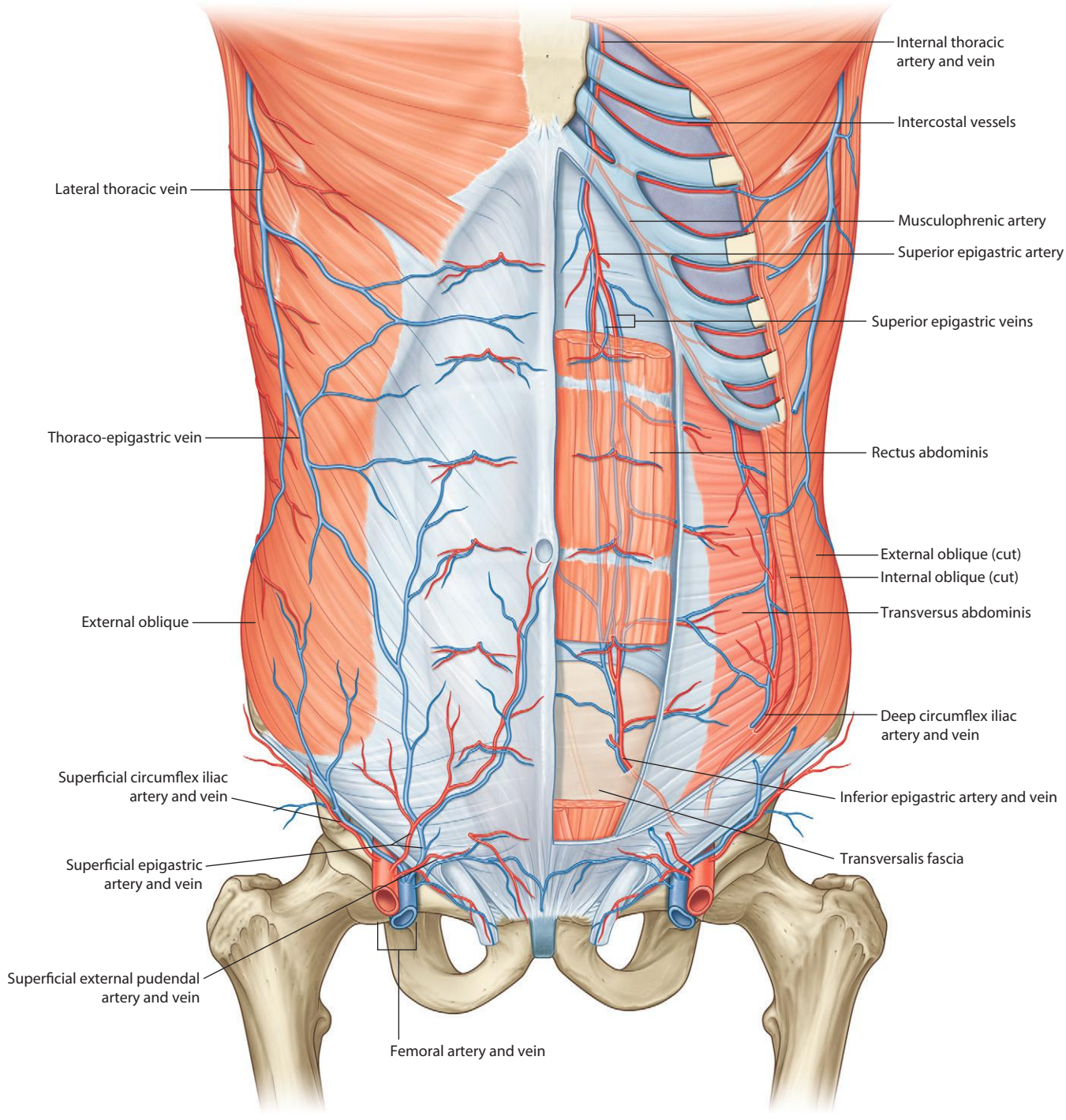

Vasculature of the anterior abdominal wall

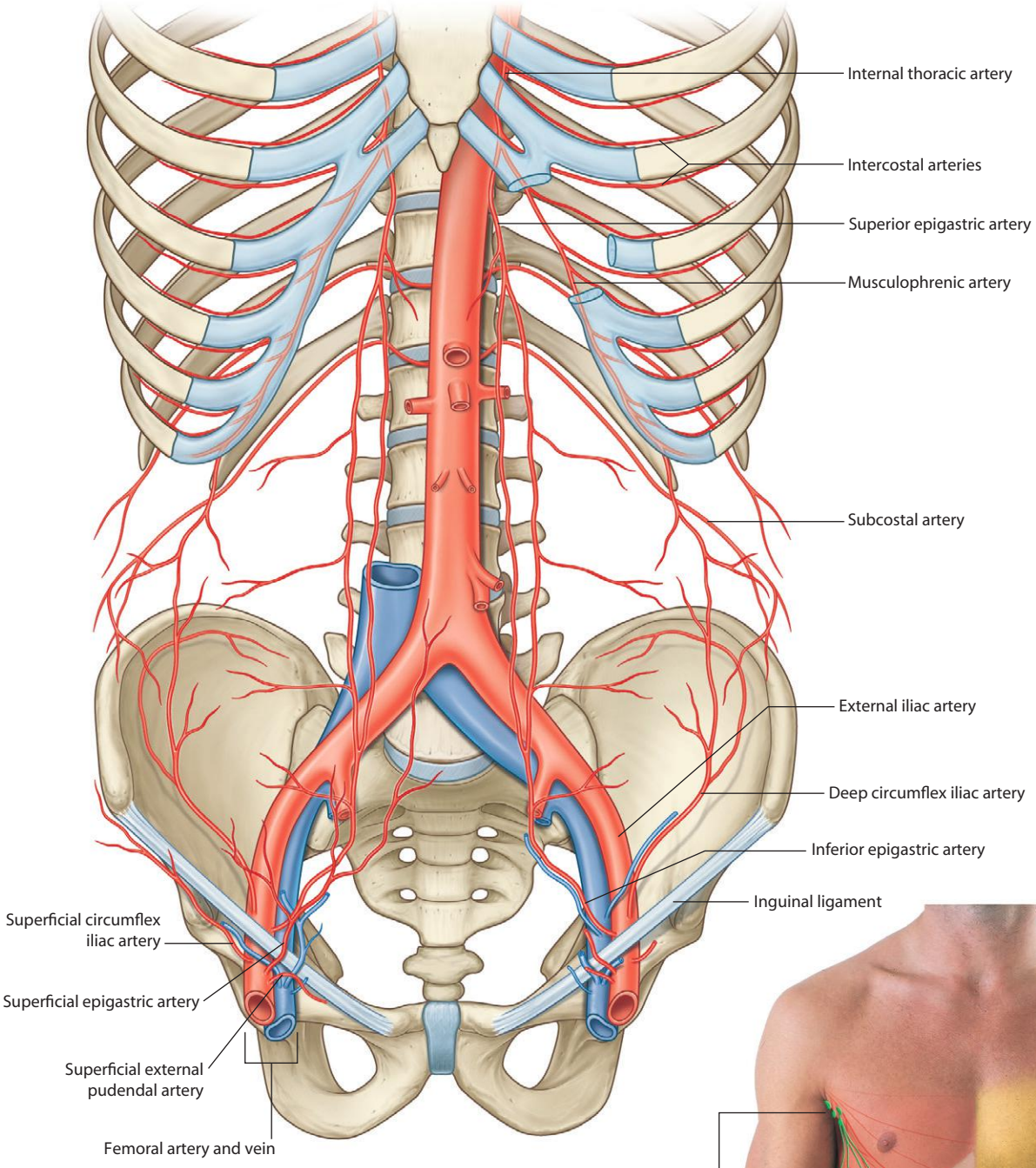

Arteries of the anterior abdominal wall

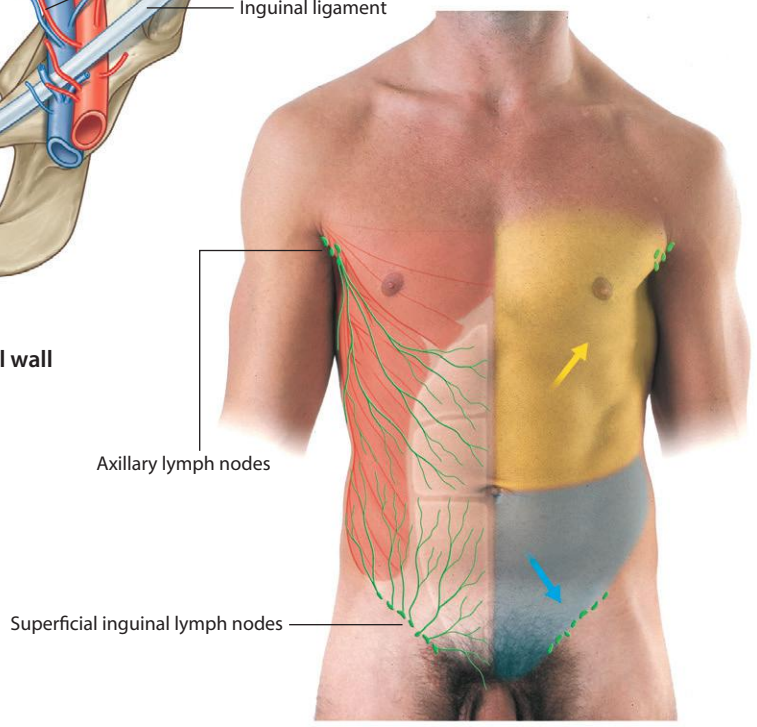

Superficial lymphatic drainage of the anterolateral abdominal wall

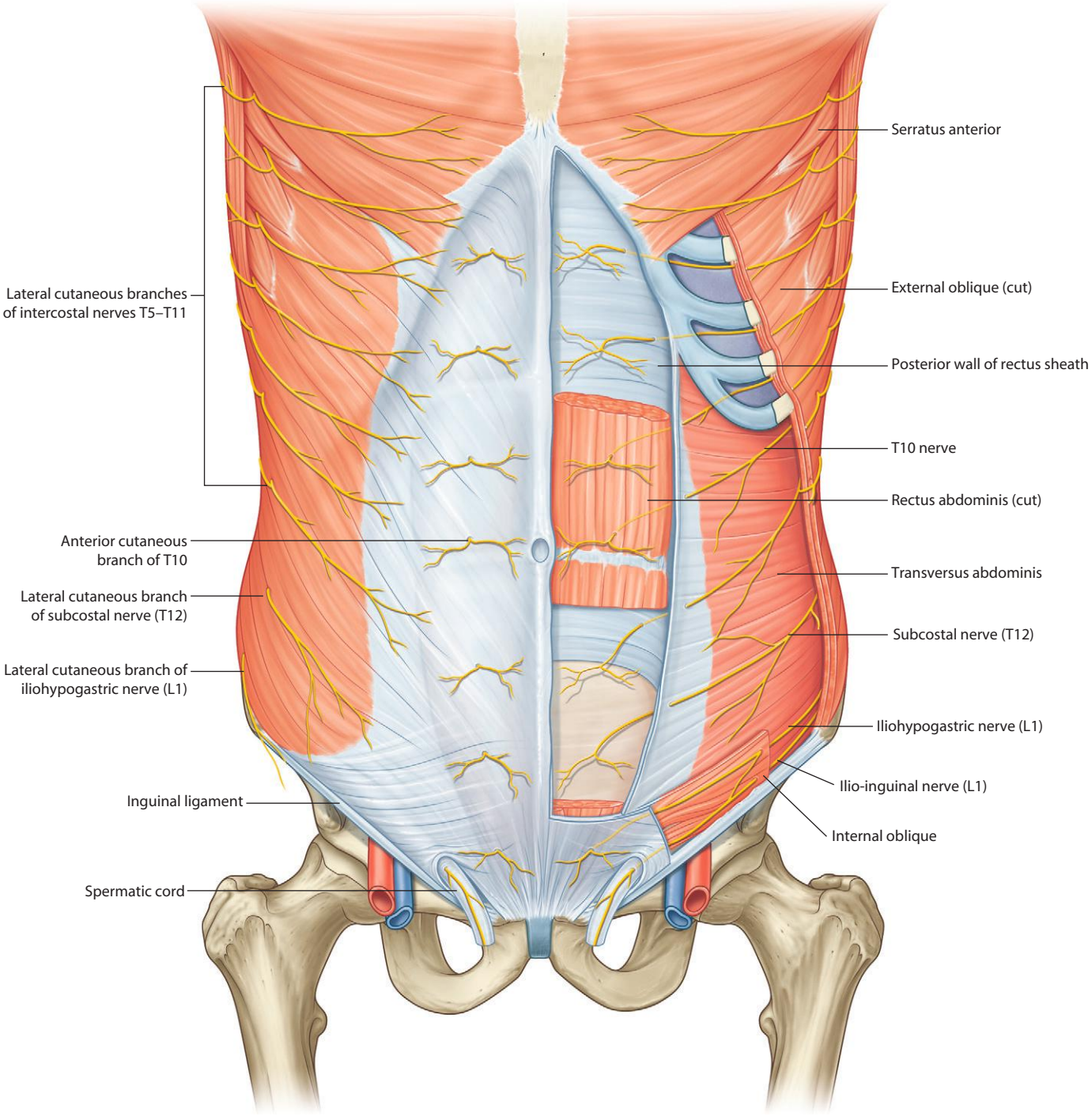

Nerves of the anterolateral abdominal wall

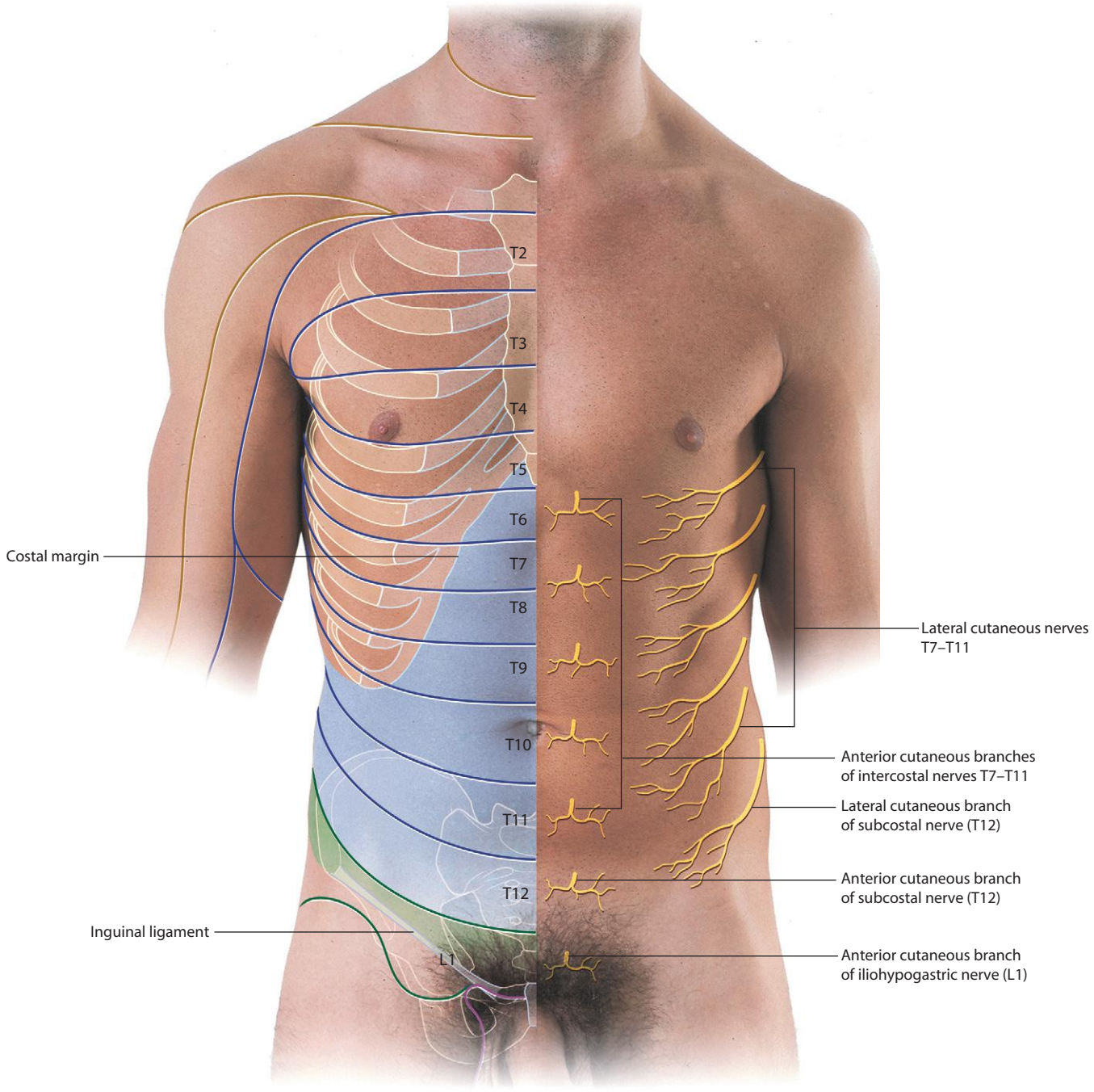

Dermatomes and cutaneous nerves of the anterolateral abdominal wall

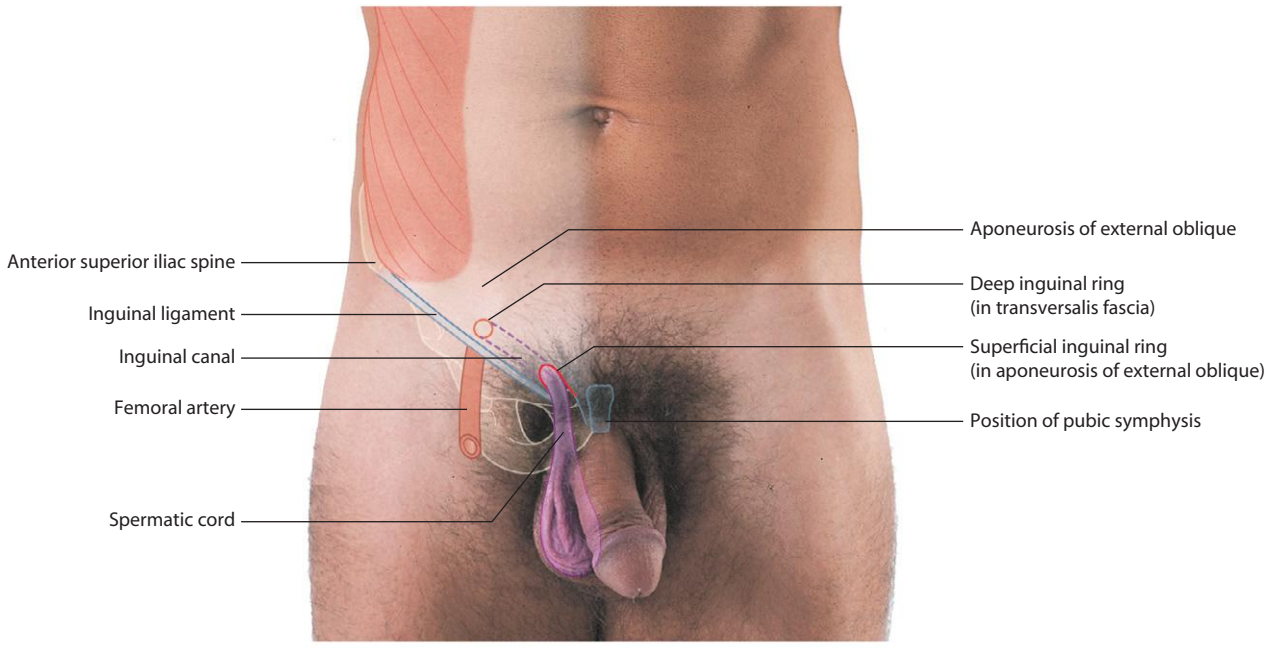

Inguinal region in a man

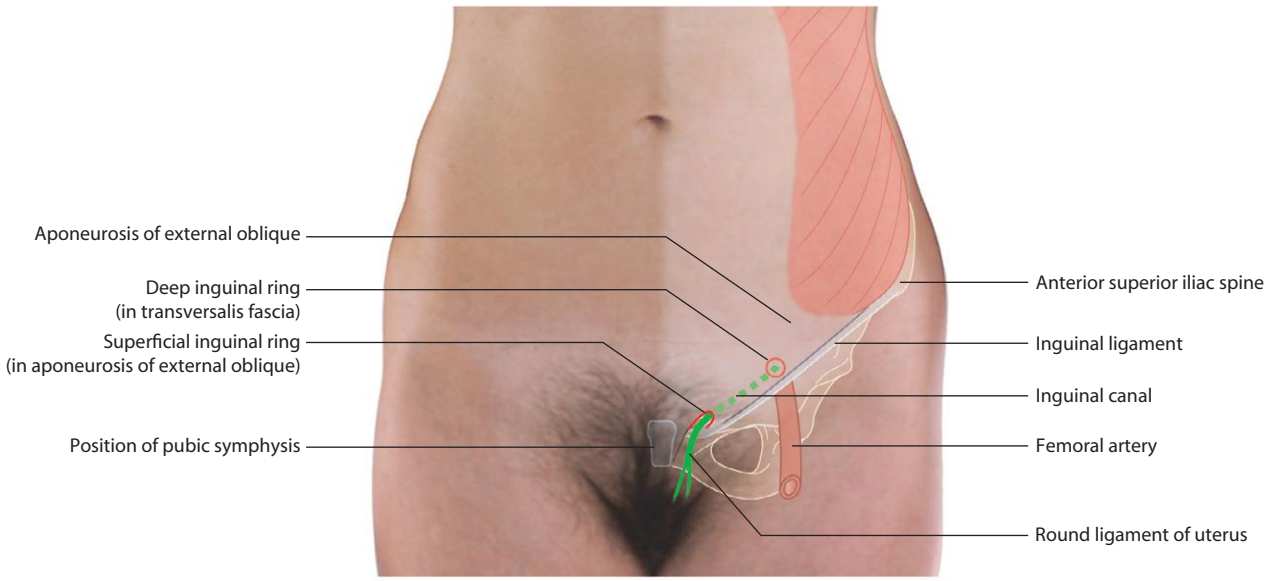

Inguinal region in a woman

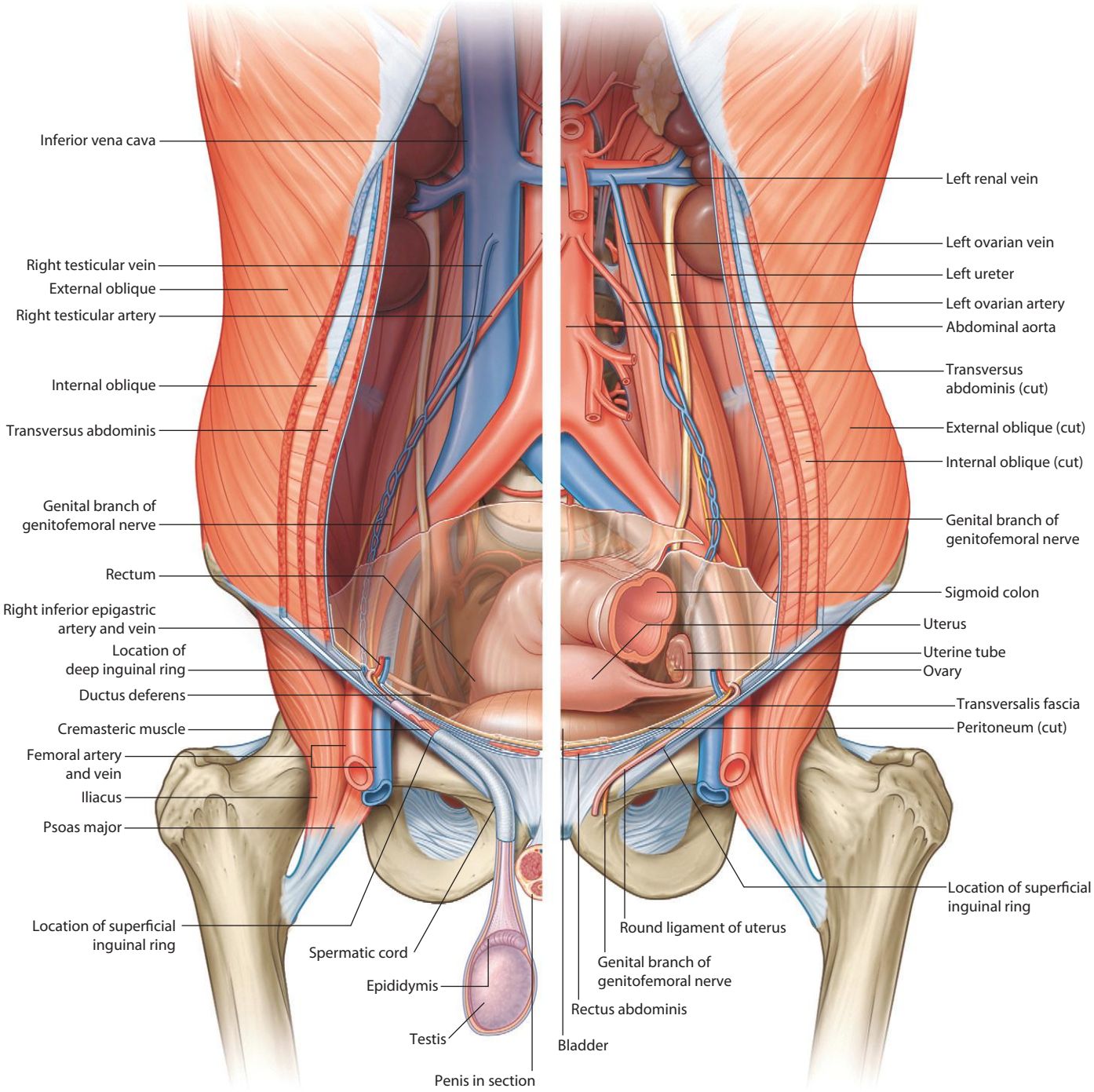

Inguinal region in men **Inguinal region in women**

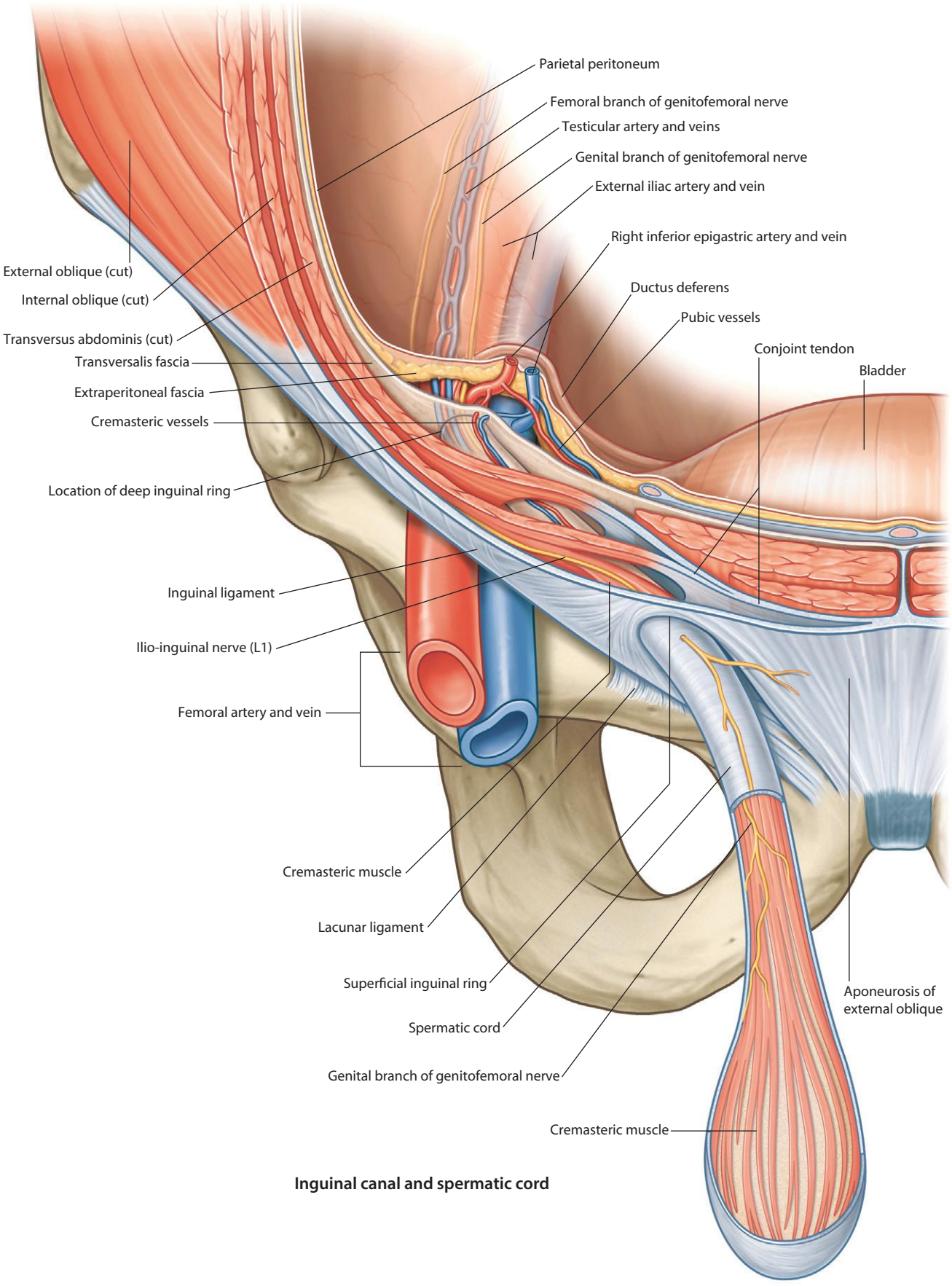

Inguinal canal and spermatic cord

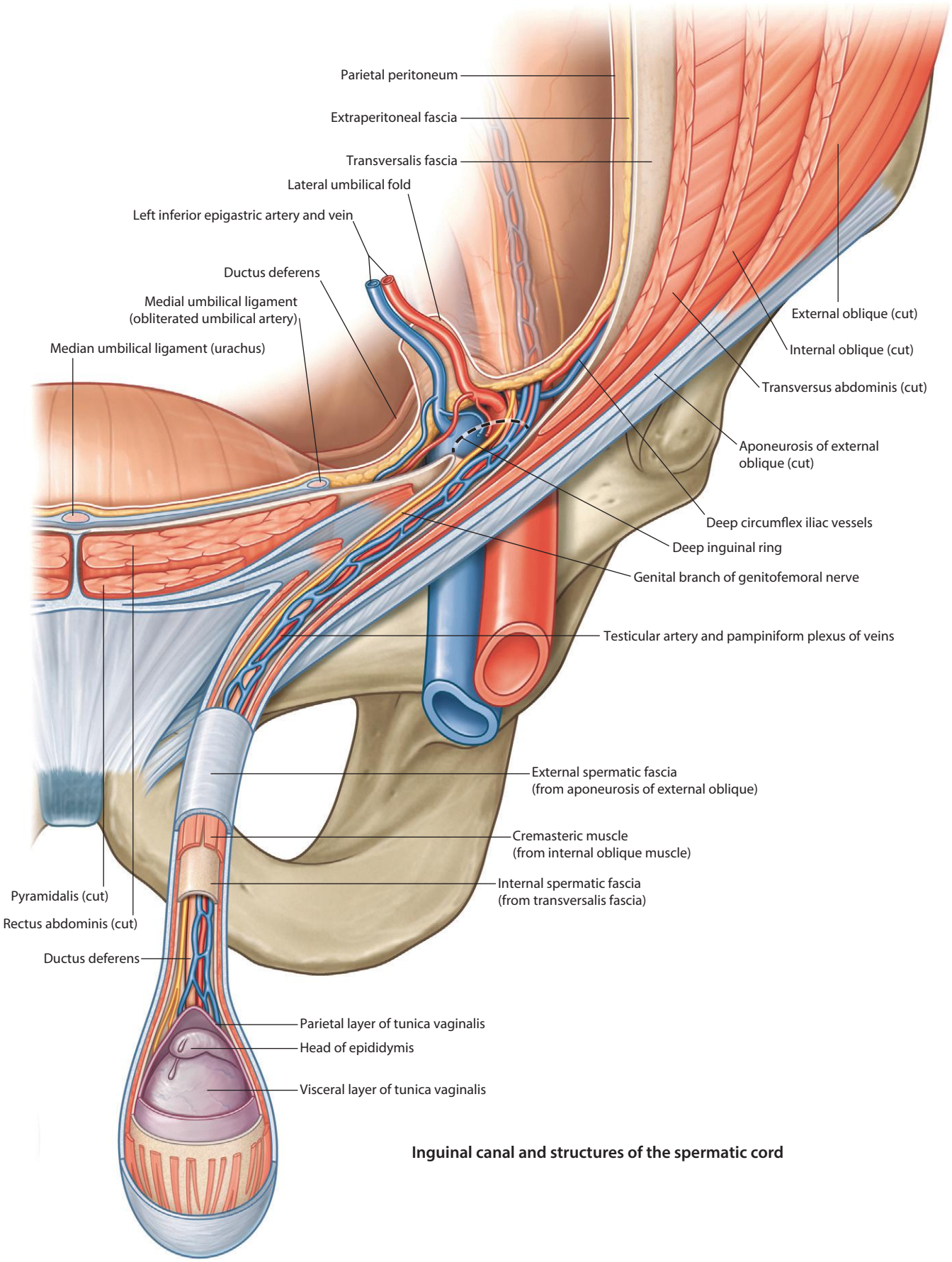

Inguinal canal and structures of the spermatic cord

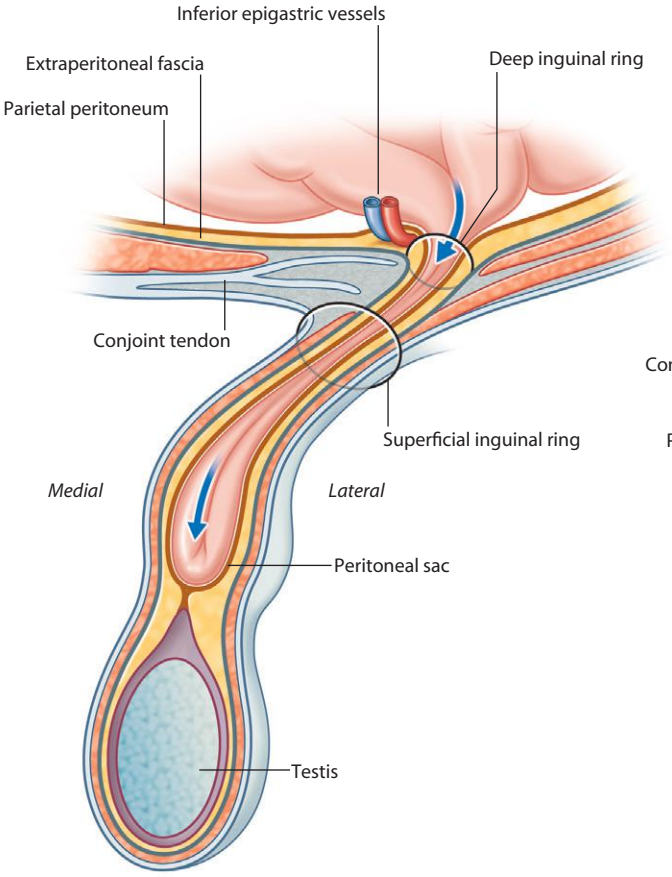

Indirect inguinal hernia

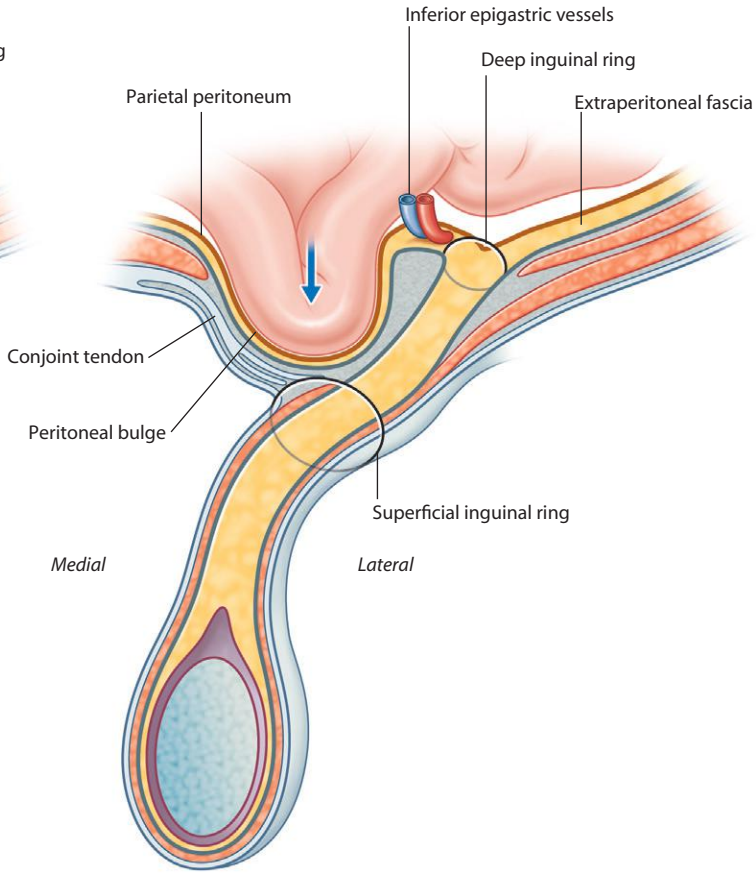

Direct inguinal hernia

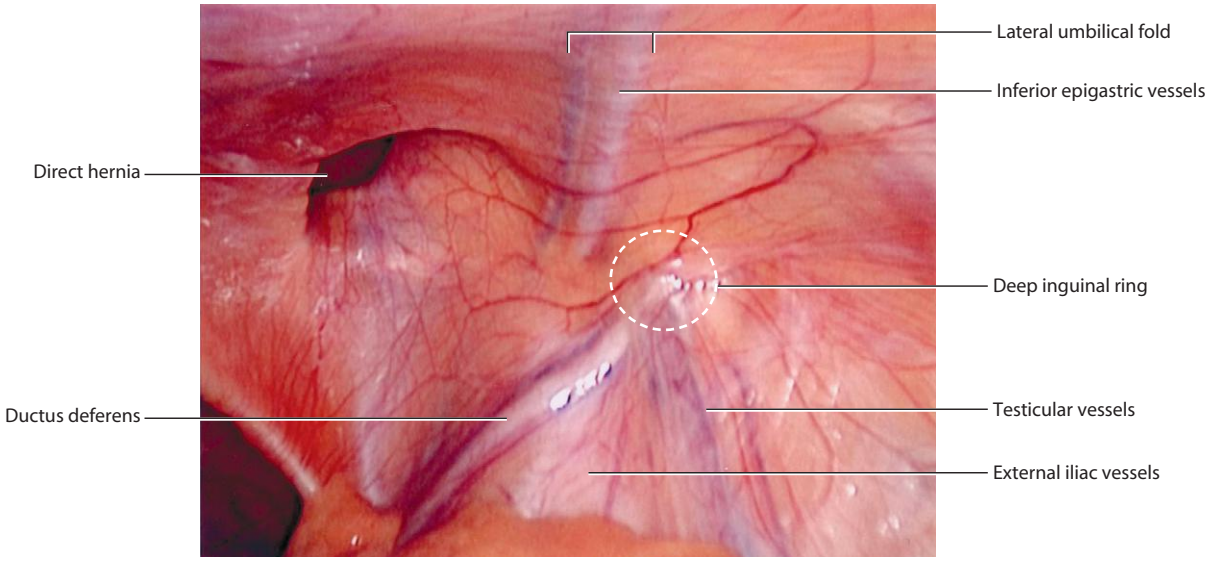

Right inguinal triangle.
Laparoscopic view showing the parietal peritoneum still covering the area (inside the peritoneal cavity looking anteroinferior)

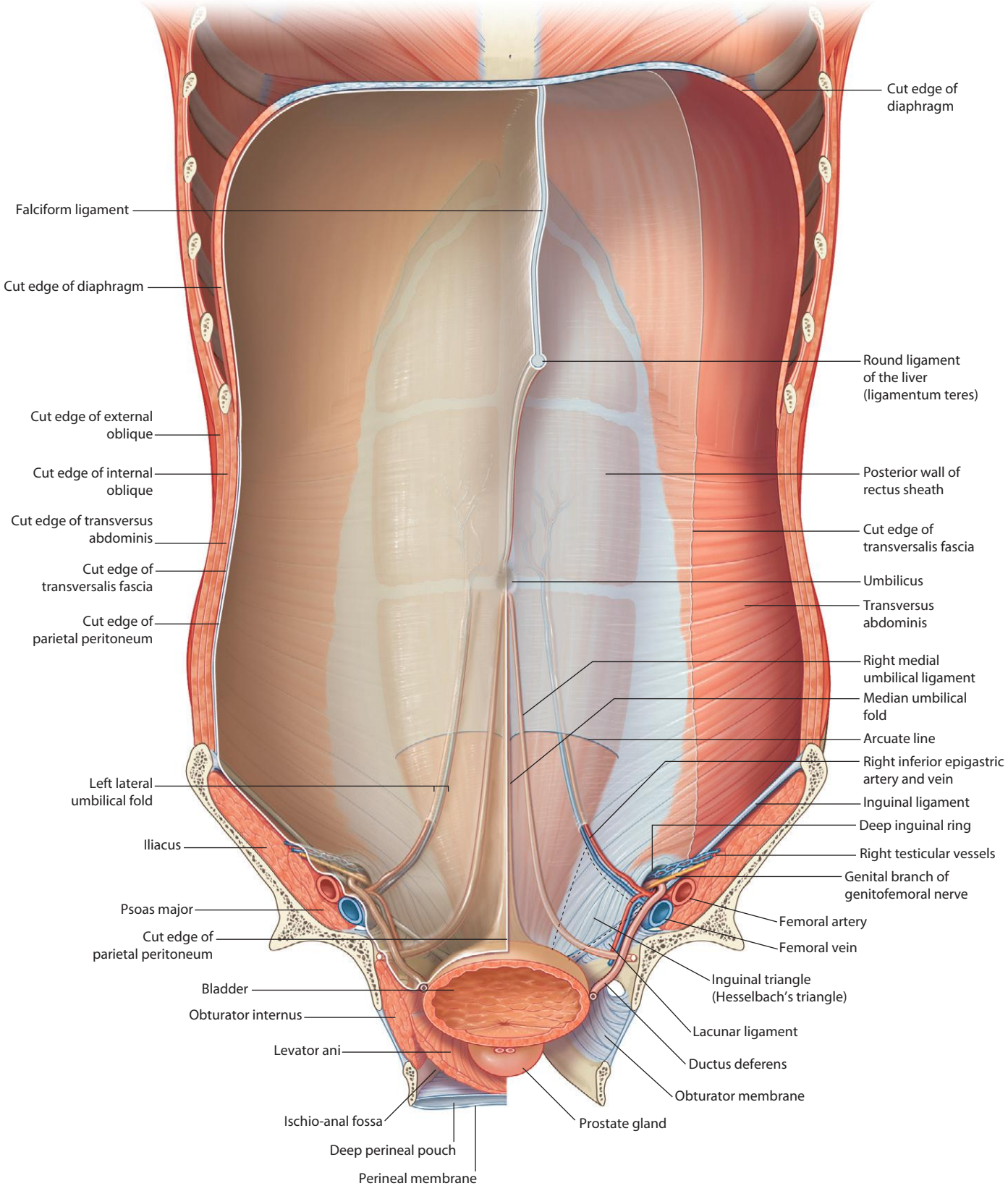

Internal view of anterior abdominal wall in men

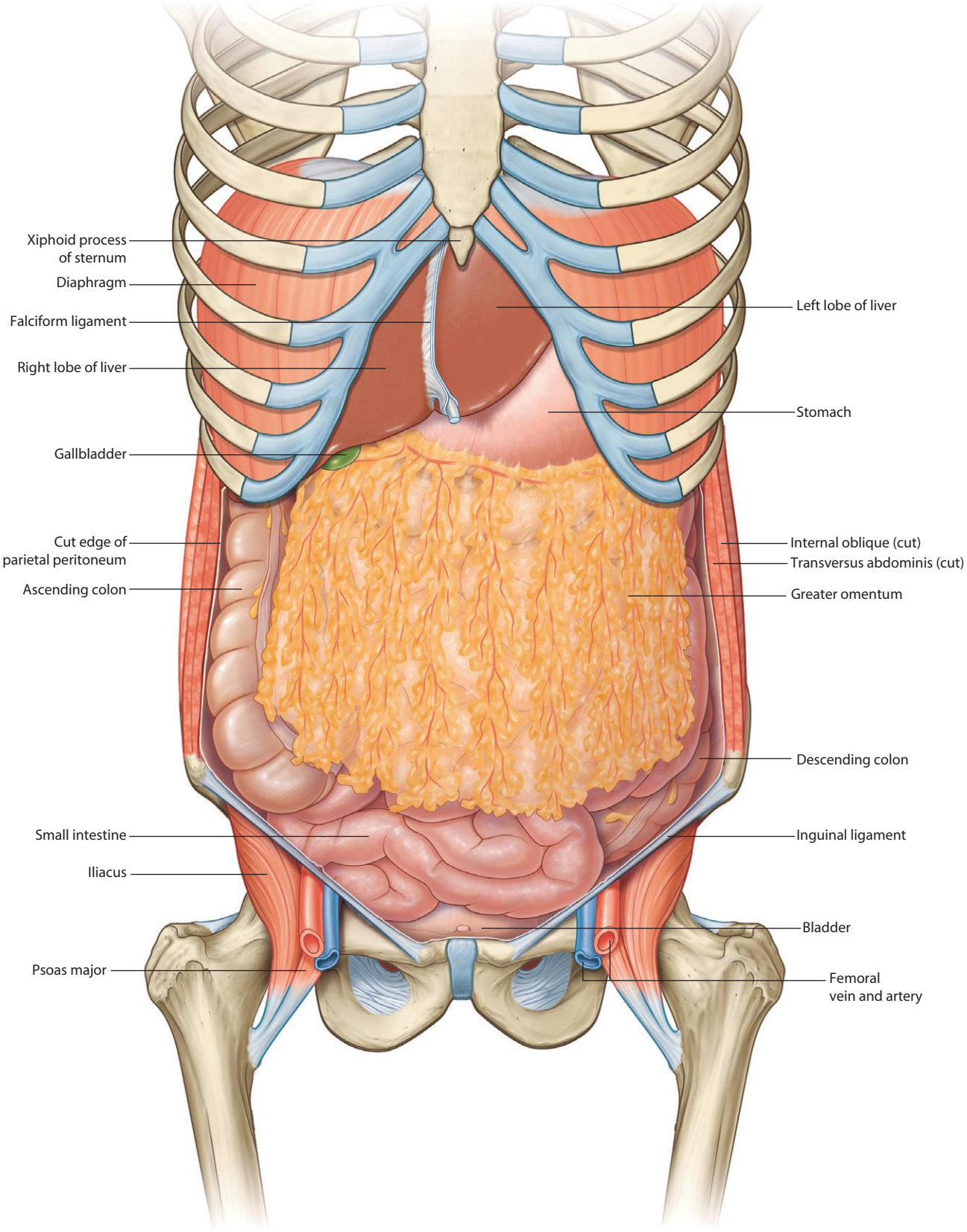

Greater omentum

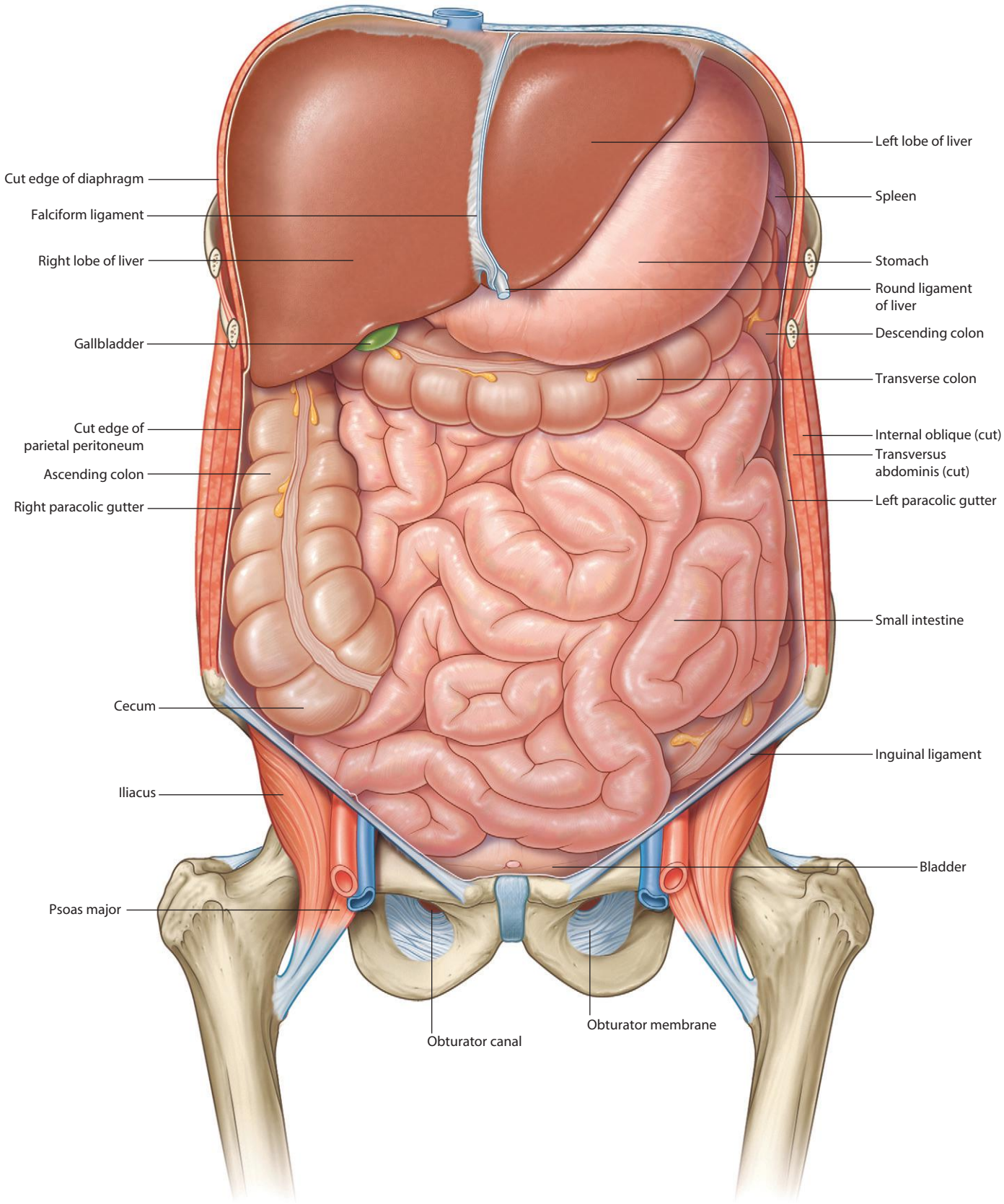

Abdominal viscera (greater omentum removed)

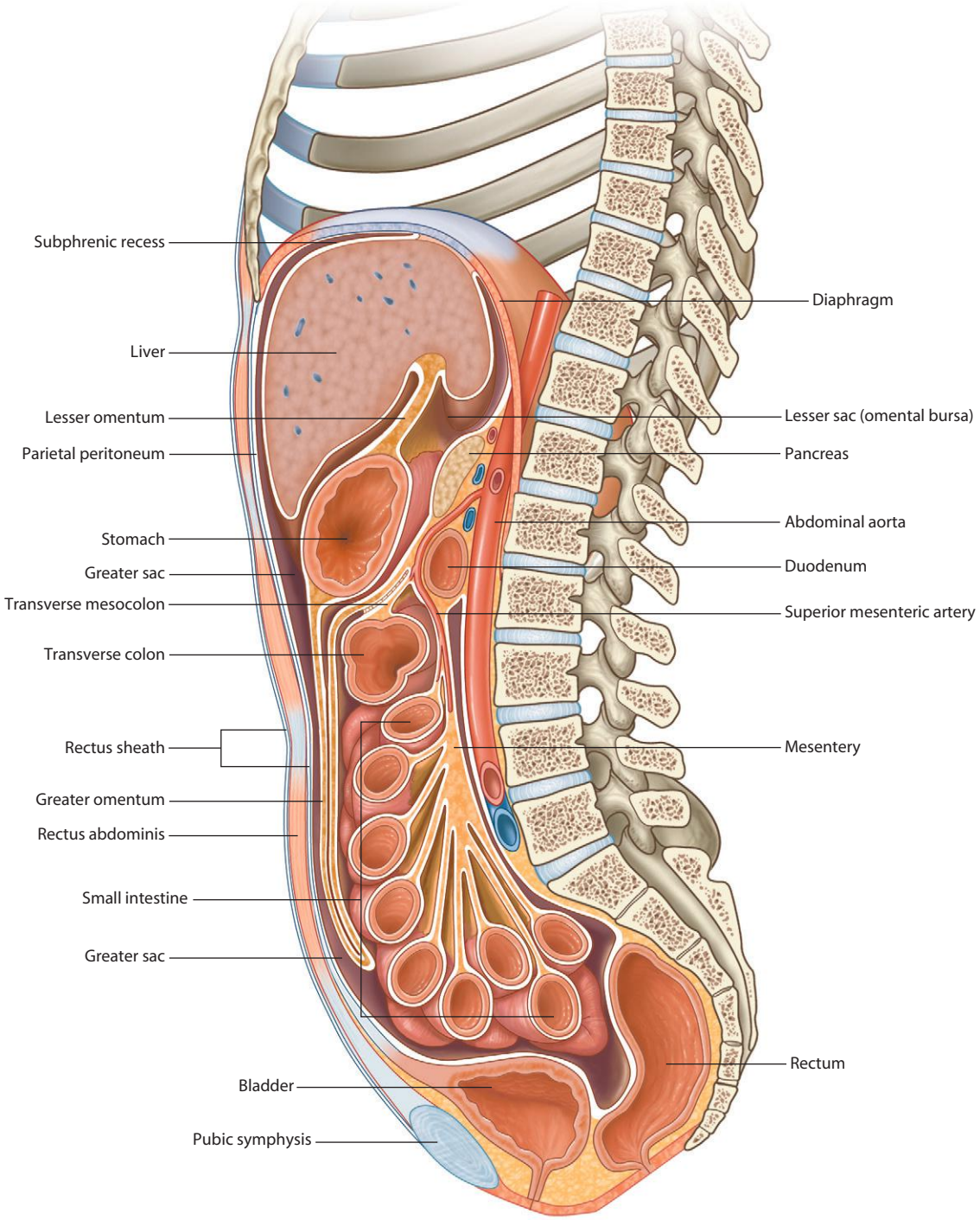

Greater and lesser sacs of the peritoneal cavity

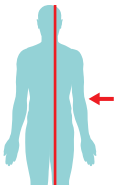

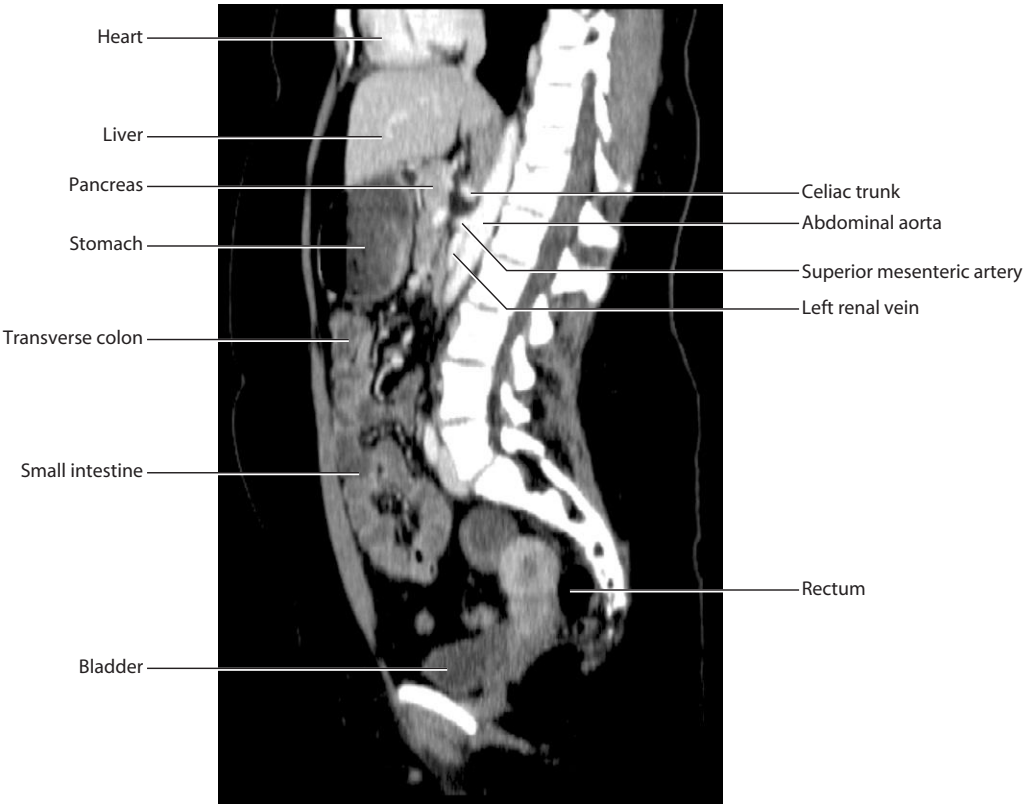

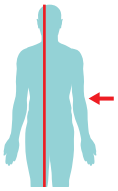

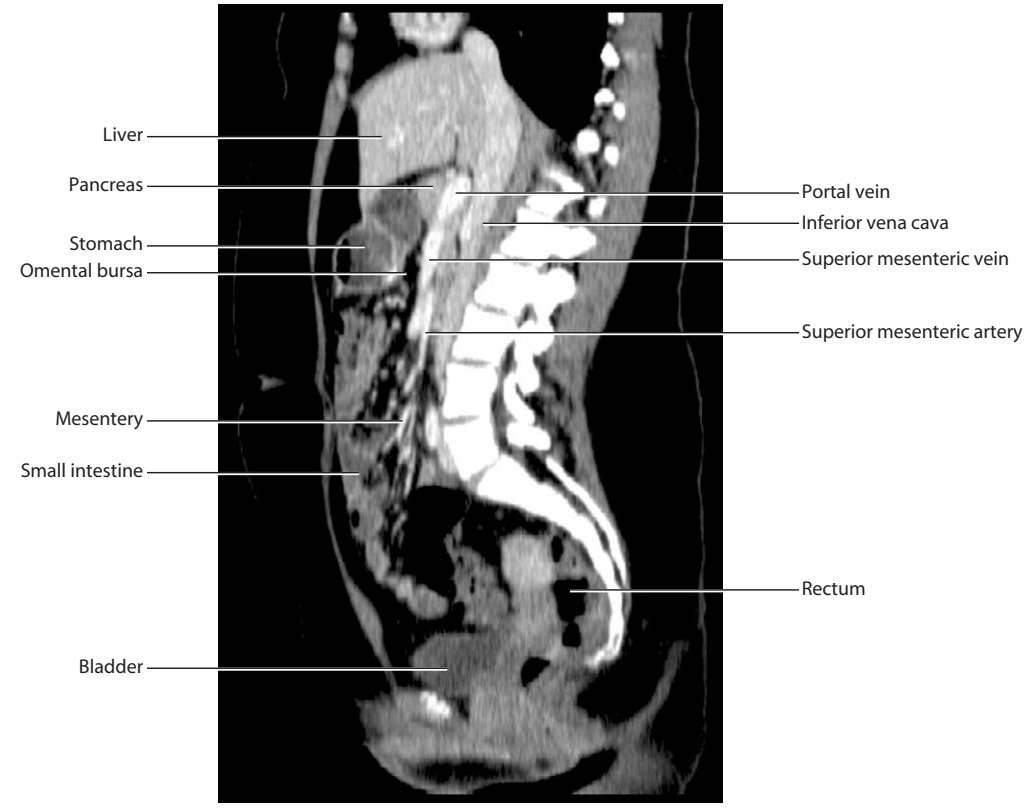

Arrangement of abdominal contents in peritoneal cavity.
CT images, with contrast, in sagittal plane

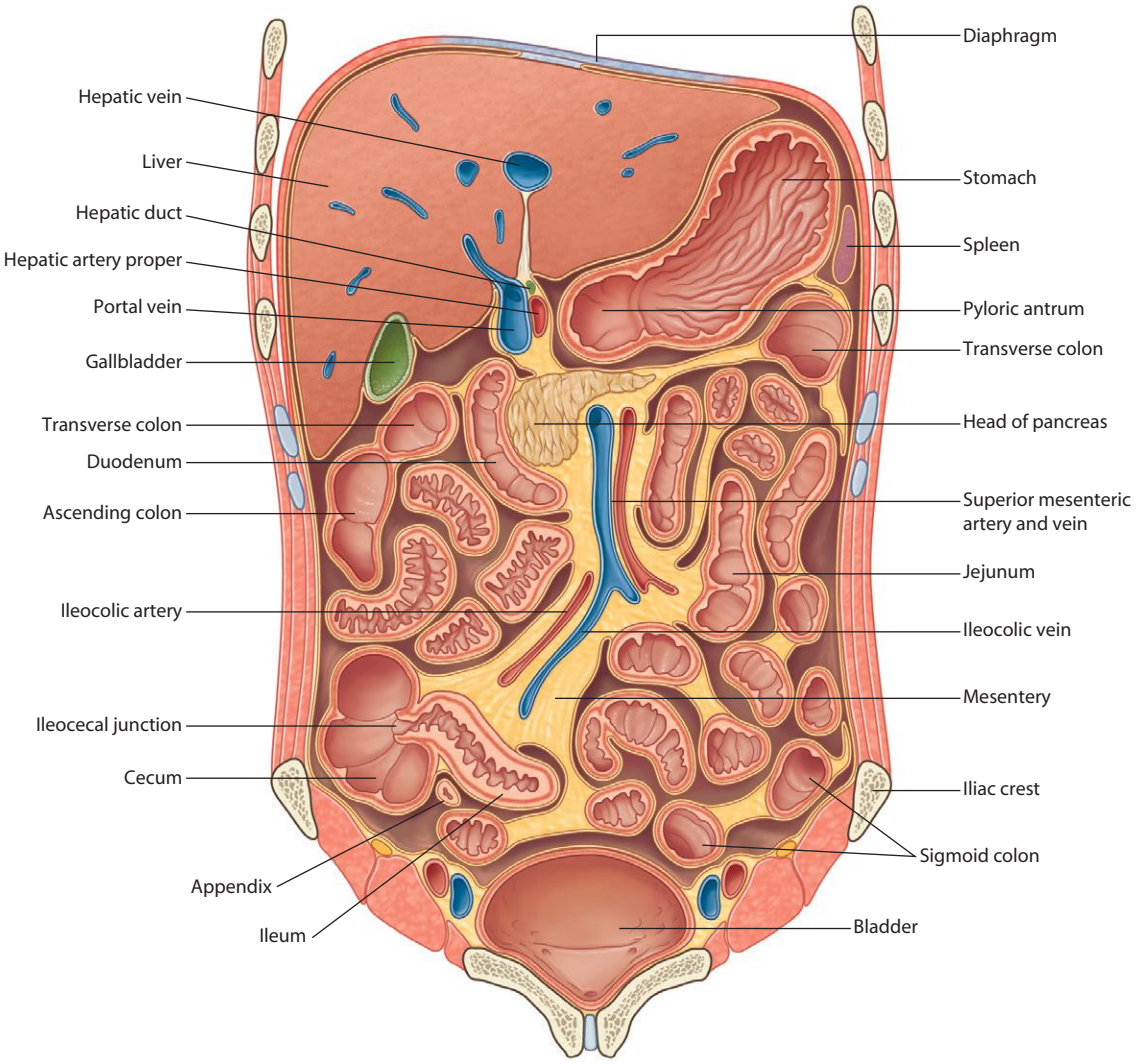

Coronal section

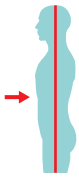

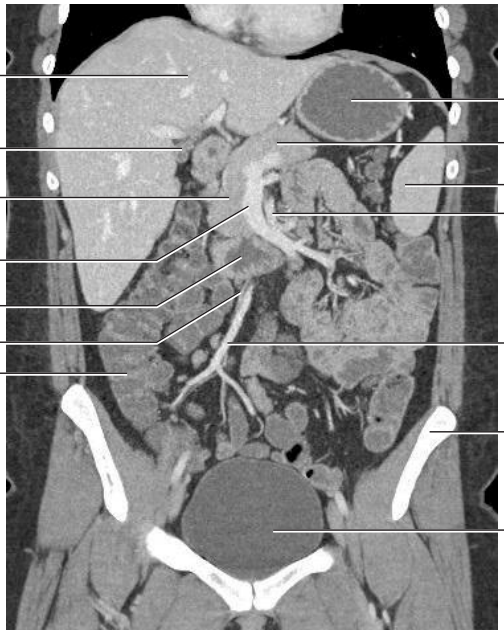

Coronal section.
CT image, with contrast, in coronal plane

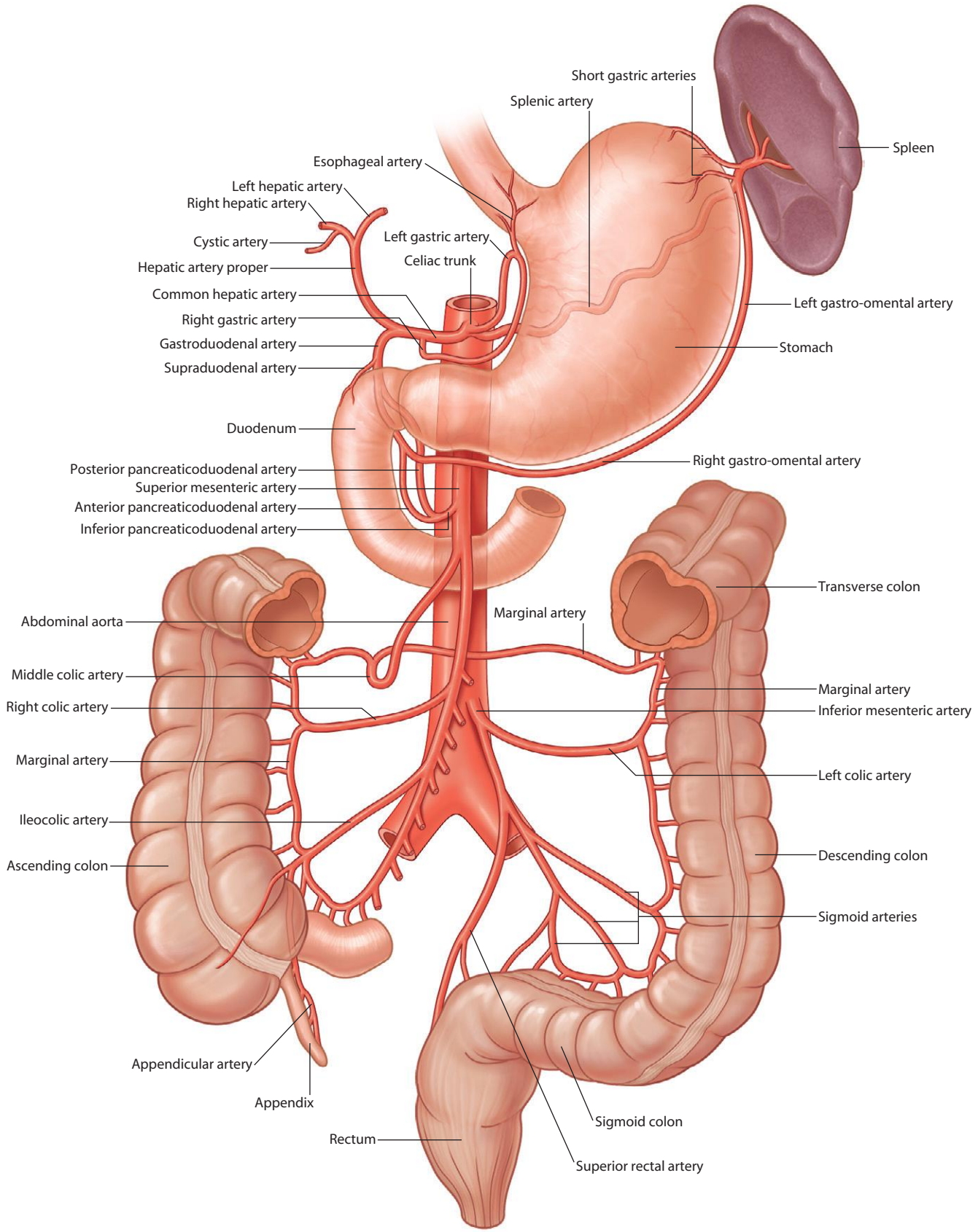
Short gastric arteries
Splenic artery
Spleen
Esophageal artery
Left hepatic artery
Right hepatic artery
Cystic artery
Left gastric artery
Celiac trunk
Hepatic artery proper
Common hepatic artery
Right gastric artery
Gastroduodenal artery
Supraduodenal artery
Left gastro-omental artery
Stomach
Duodenum
Right gastro-omental artery
Posterior pancreaticoduodenal artery
Superior mesenteric artery
Anterior pancreaticoduodenal artery
Inferior pancreaticoduodenal artery
Transverse colon
Abdominal aorta
Marginal artery
Middle colic artery
Marginal artery
Right colic artery
Inferior mesenteric artery
Marginal artery
Left colic artery
Ileocolic artery
Descending colon
Ascending colon
Sigmoid arteries
Appendicular artery
Appendix
Sigmoid colon
Rectum
Superior rectal artery

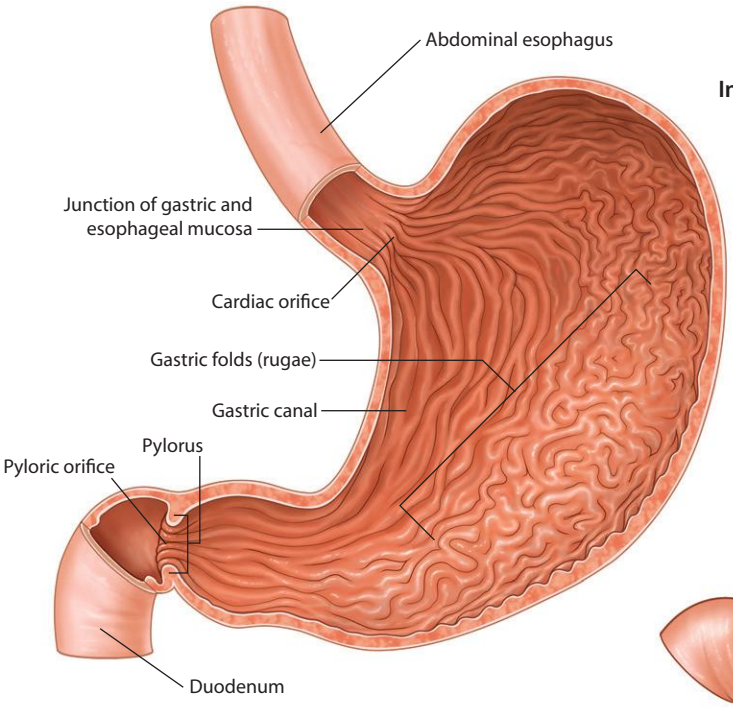

Internal and external features of the stomach

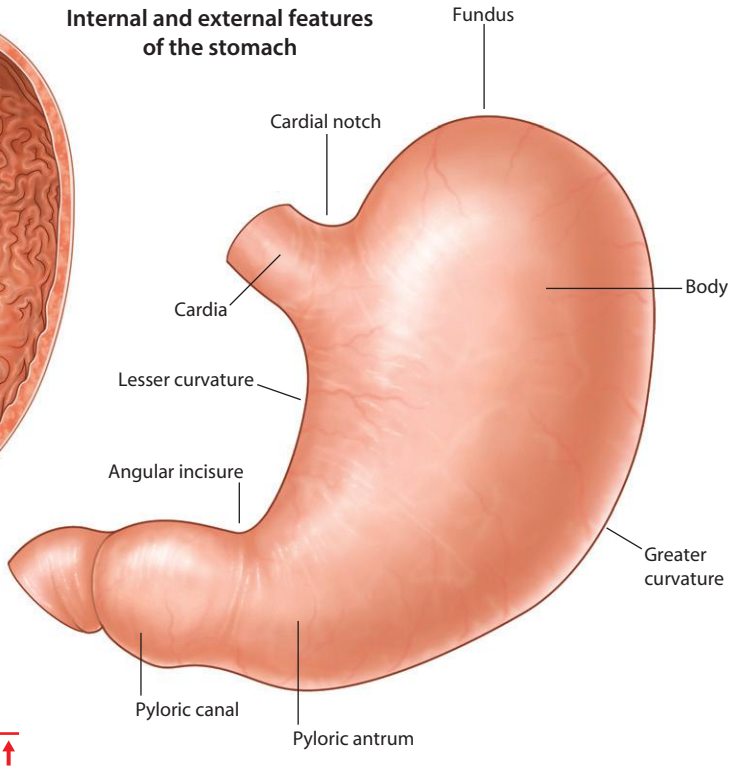

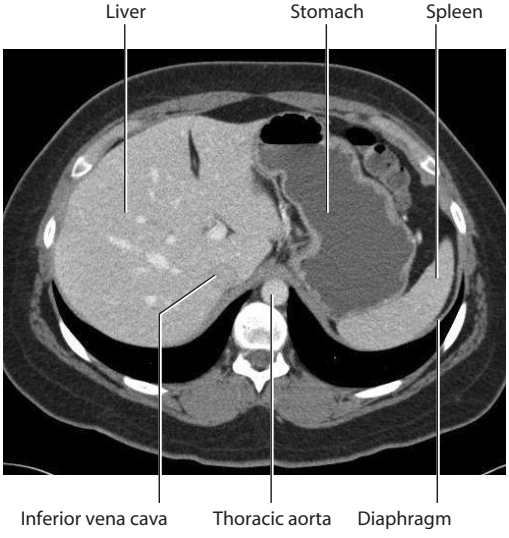

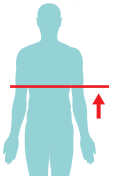

Positioning of the stomach.
CT image, with contrast, in axial plane

Surface projection of the stomach

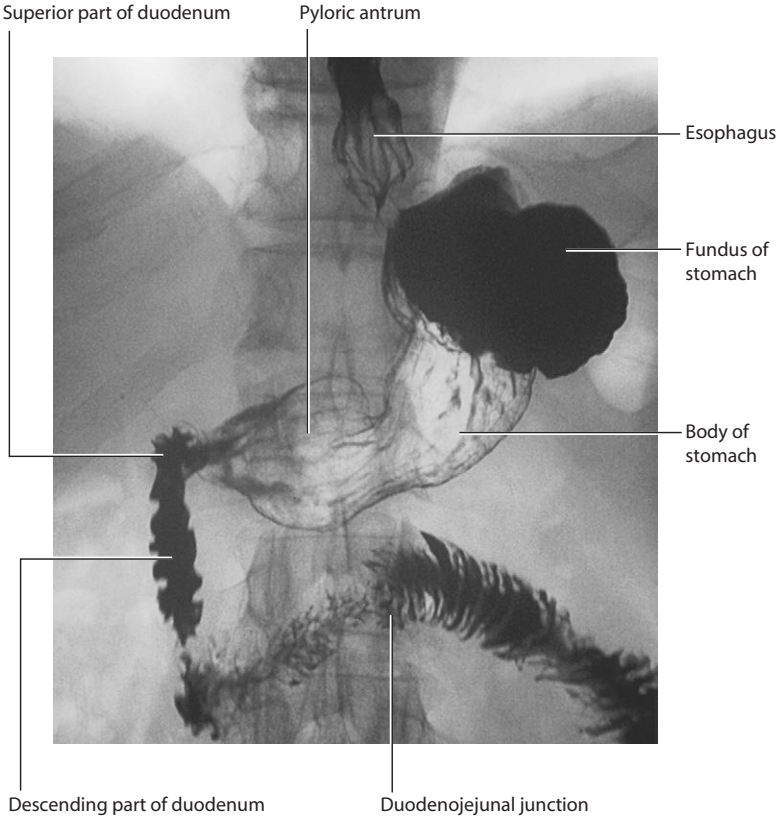

Stomach. Double-contrast radiograph using barium

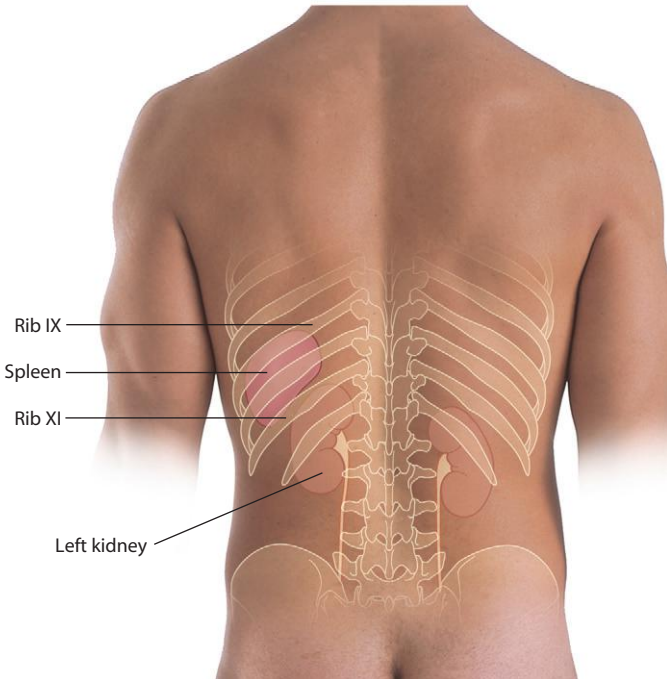

Surface projection of the spleen (posterior view)

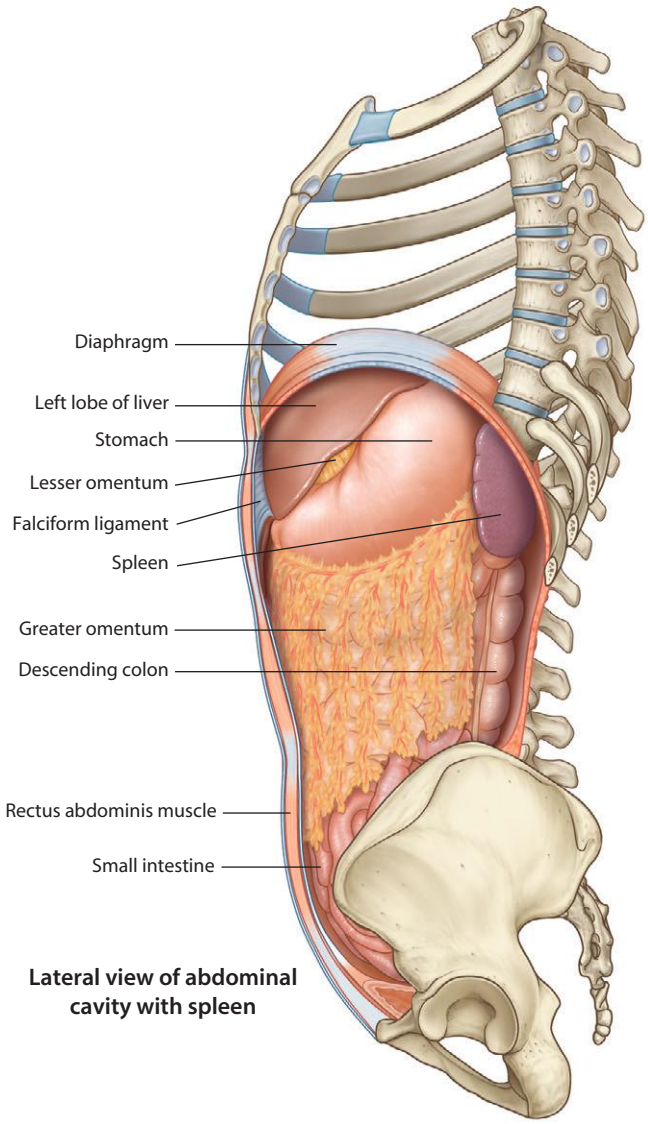

Lateral view of abdominal cavity with spleen

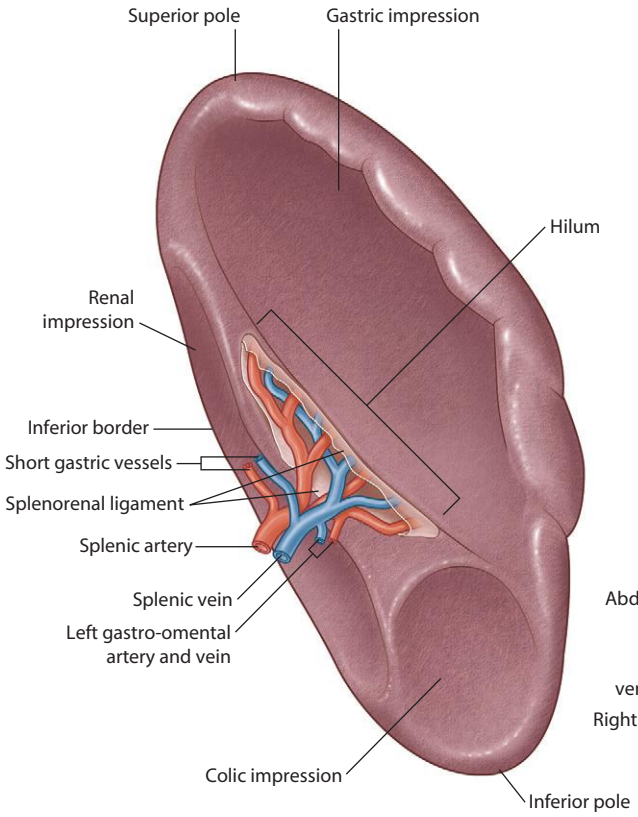

Surfaces and hilum of the spleen

Location of the spleen.
CT image, with contrast, in coronal plane

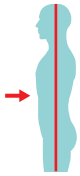

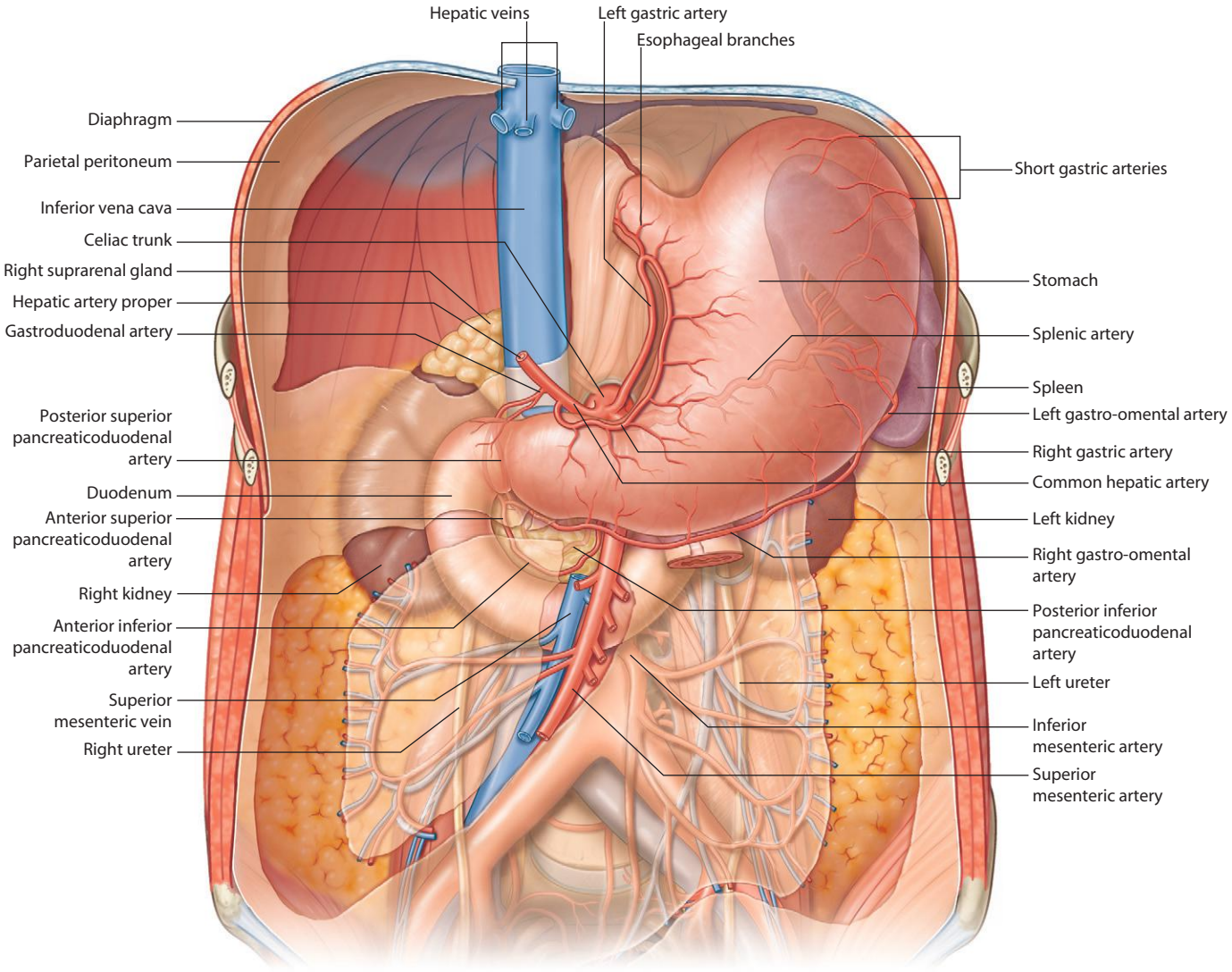

Distribution of the celiac trunk

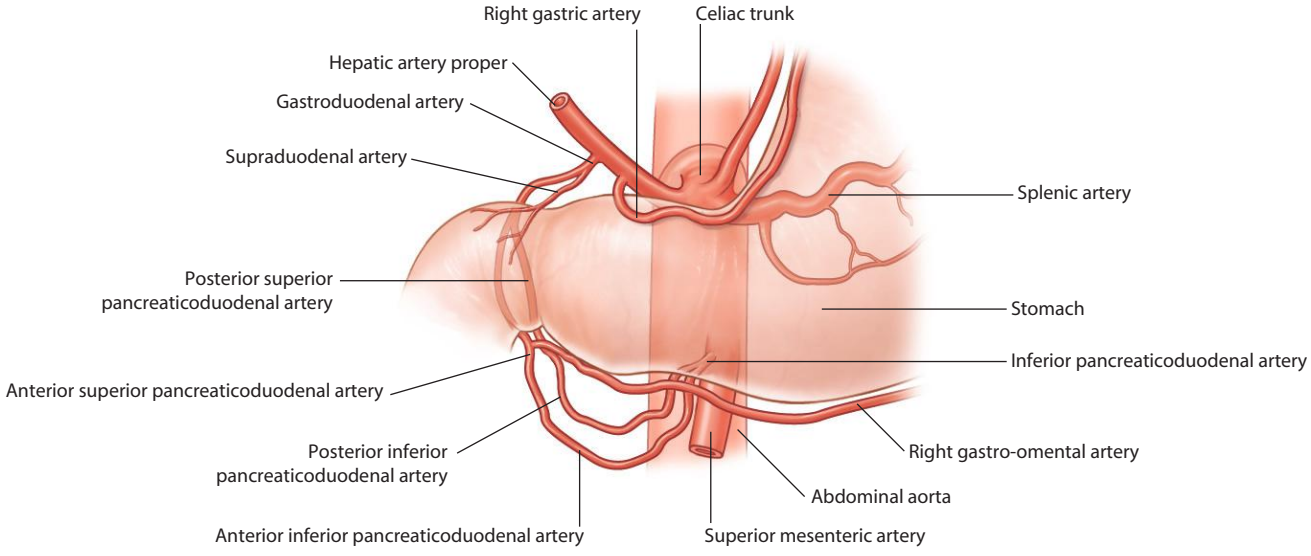

Branches of the gastroduodenal artery

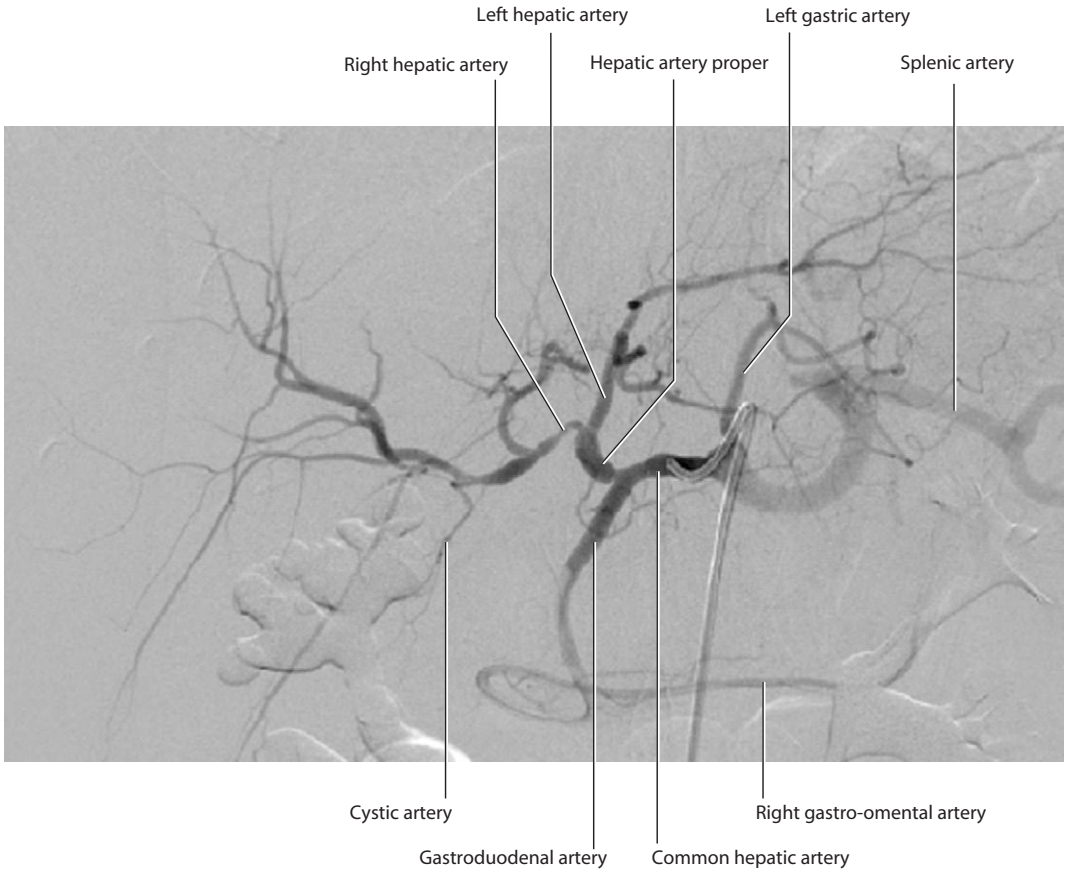

Digital subtraction angiography of the celiac trunk and its branches

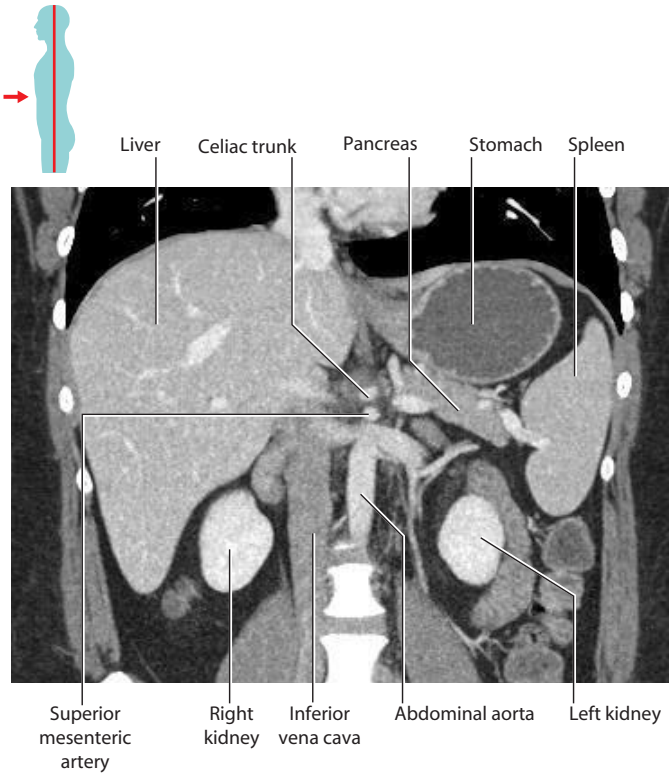

Positioning of the celiac trunk in relation to other structures.
CT image, with contrast, in coronal plane

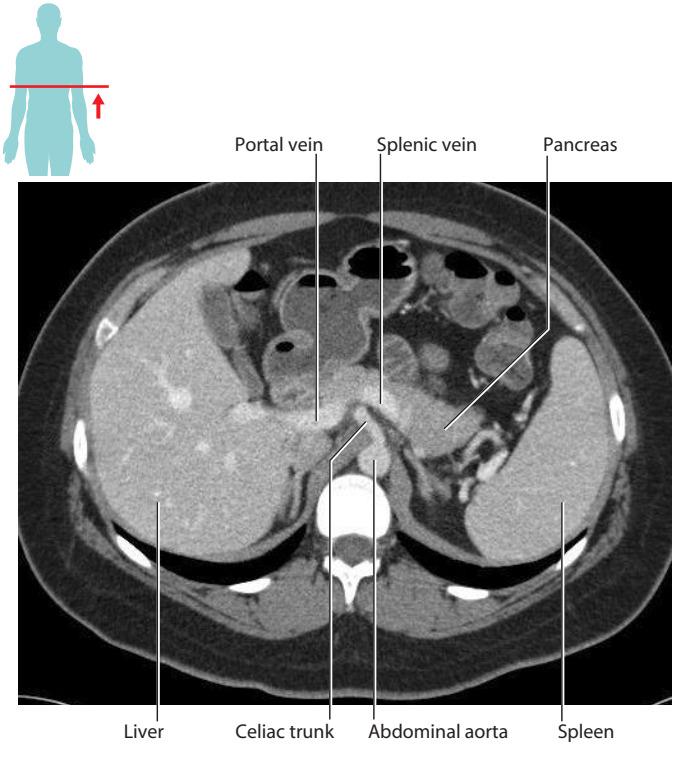

Branching of the celiac trunk from the abdominal aorta.
CT image, with contrast, in axial plane

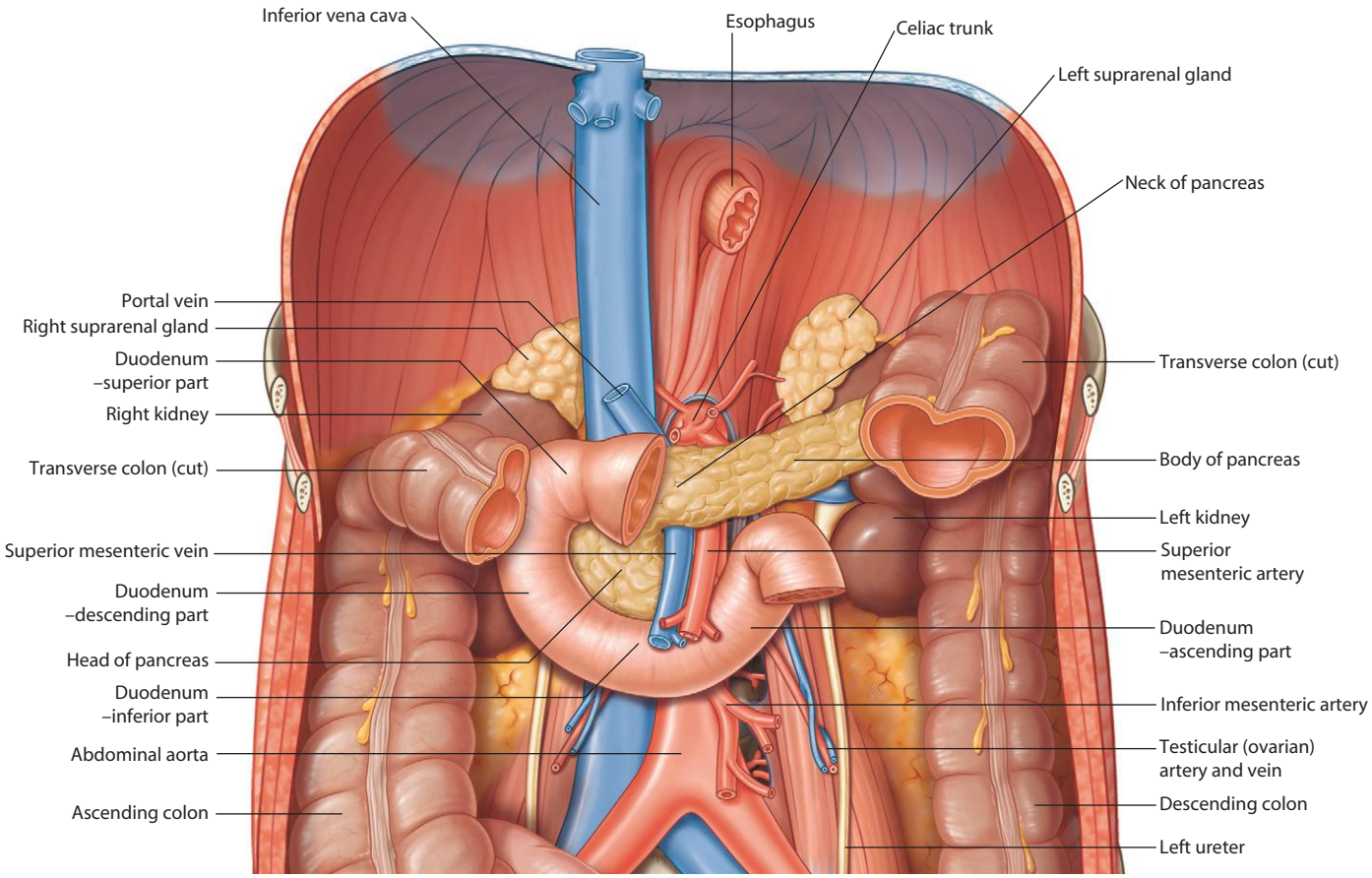

Duodenum in situ

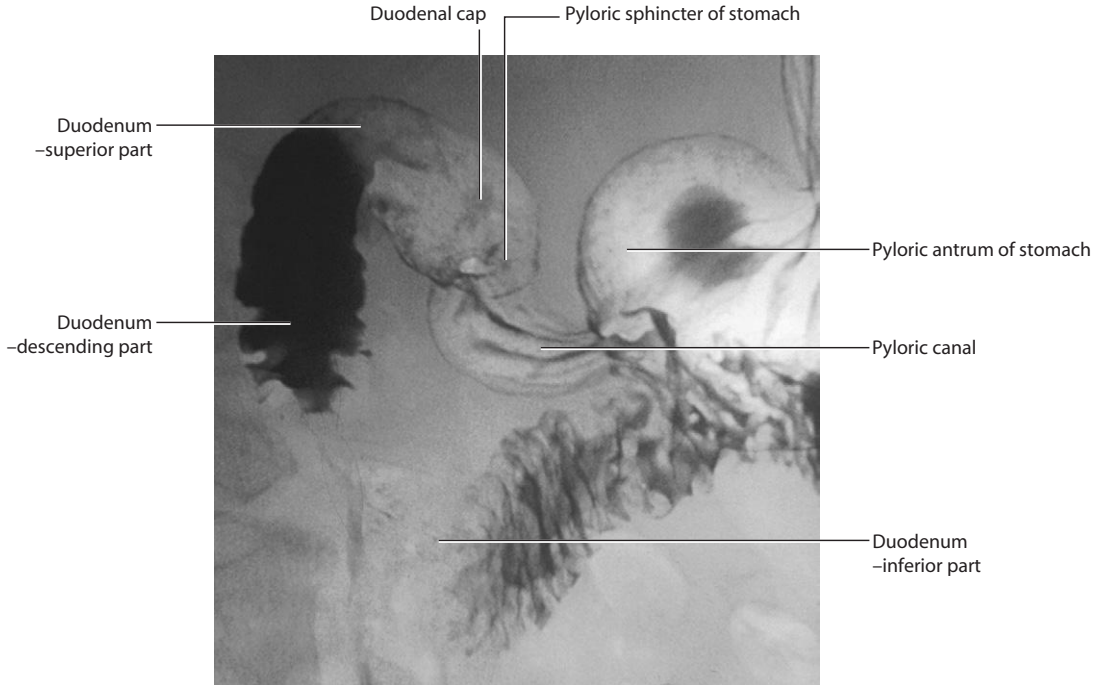

Double-contrast radiograph showing the duodenal cap

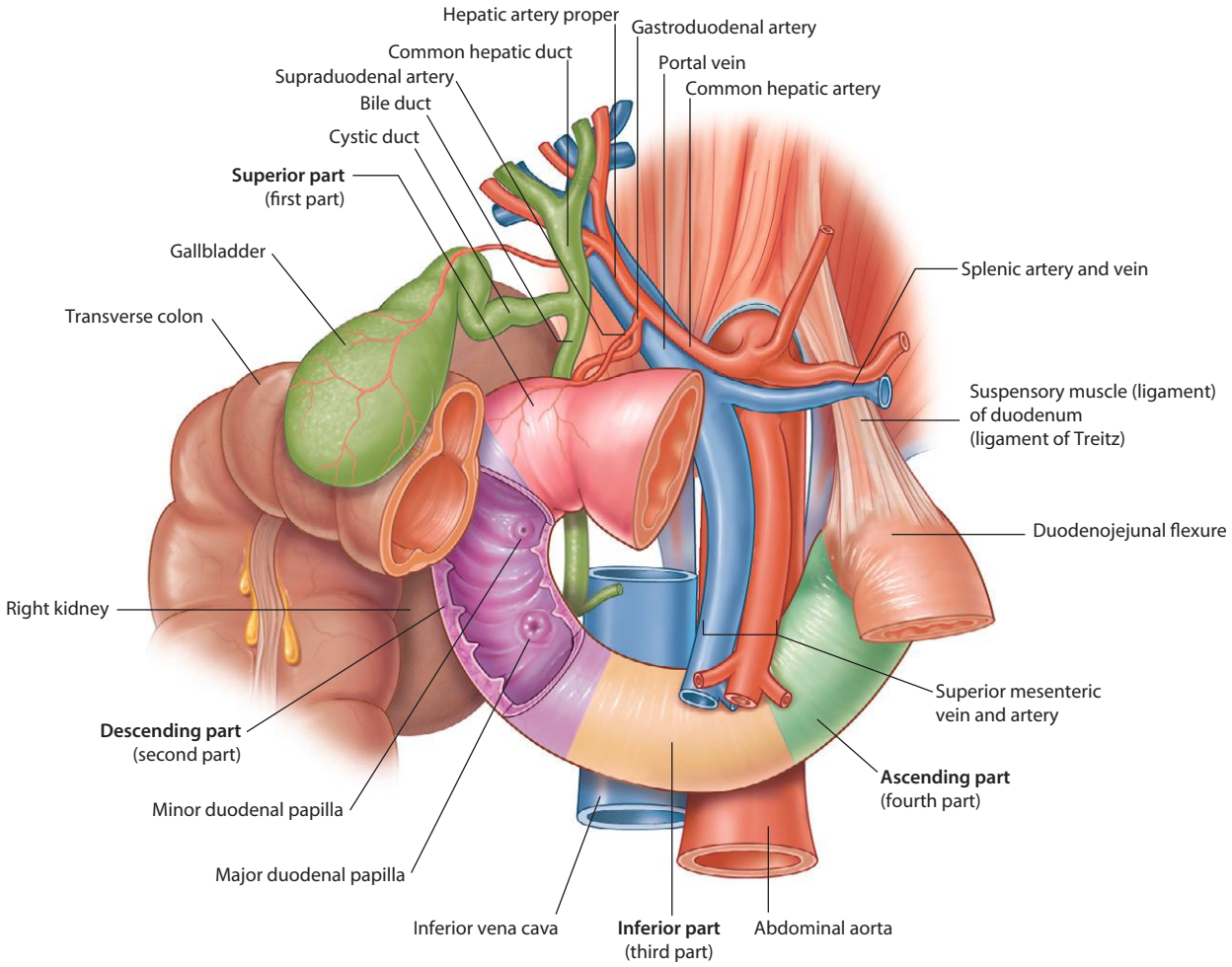

Parts of the duodenum and related structures

Relationship of duodenum to structures in the vicinity.
CT image, with contrast, in coronal plane

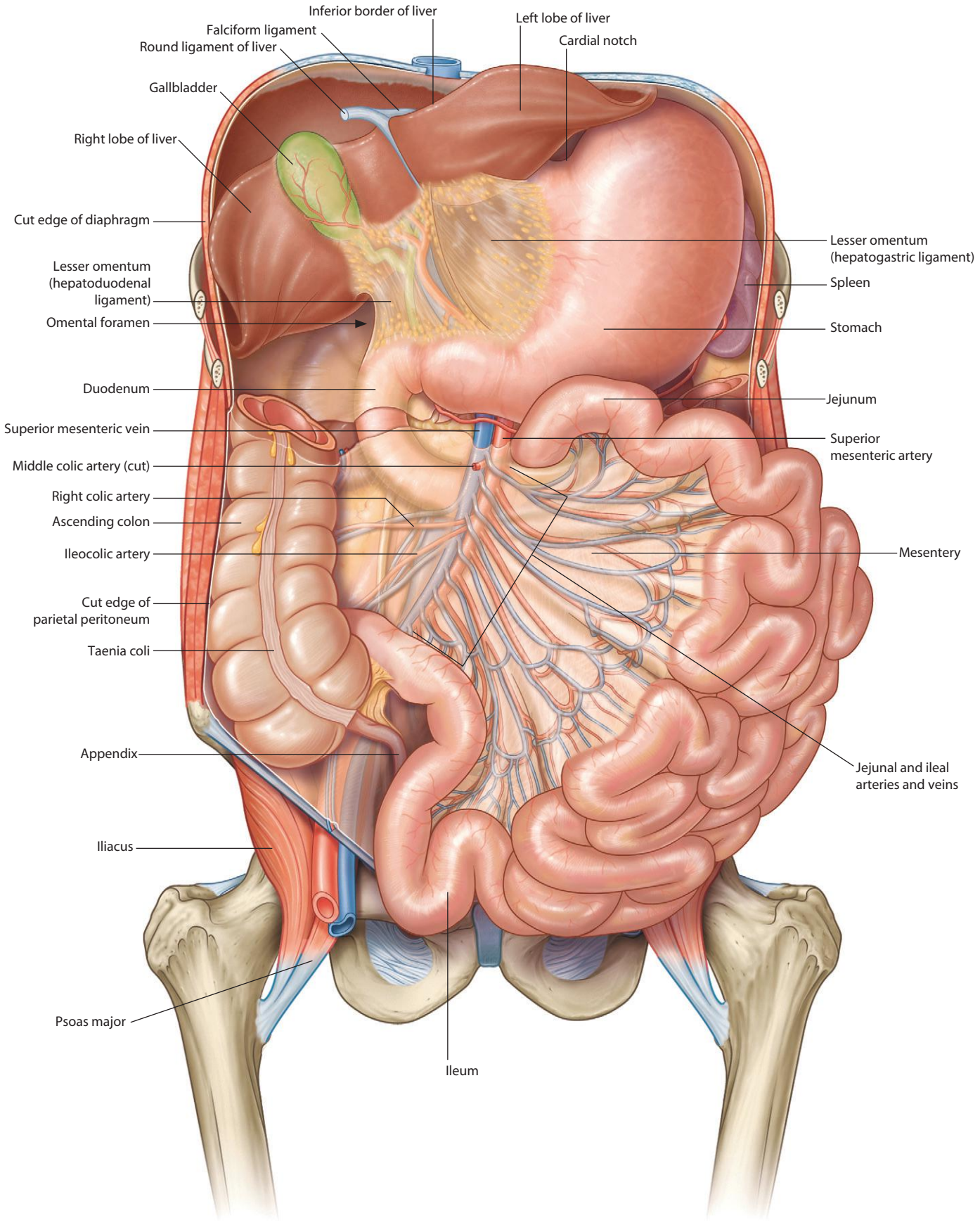

Small intestine displaced to show superior mesenteric vessels

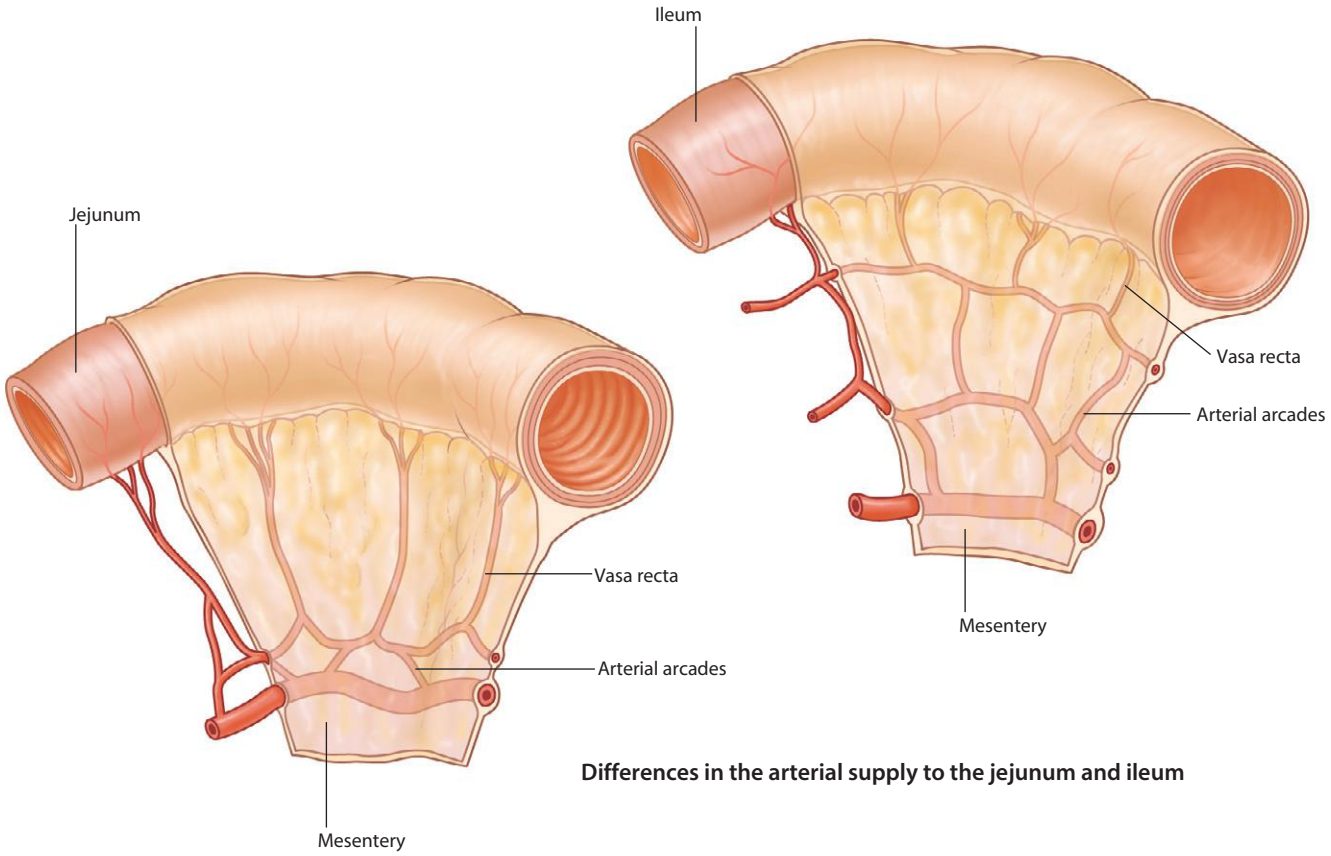

Differences in the arterial supply to the jejunum and ileum

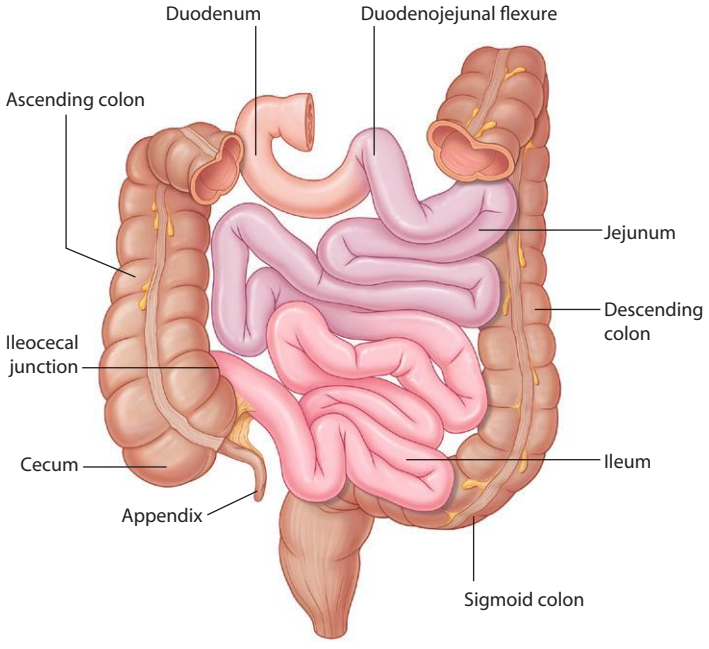

Jejunum and ileum

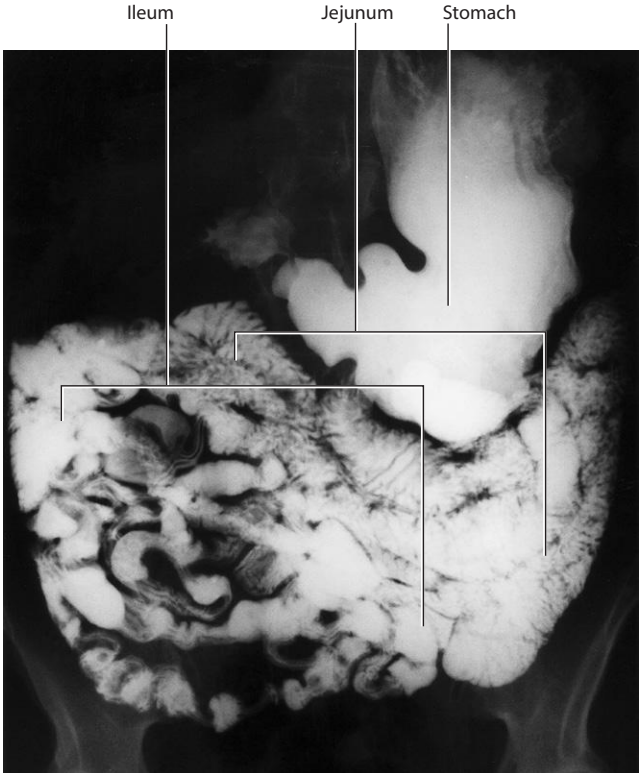

Radiograph using barium, showing jejunum and ileum

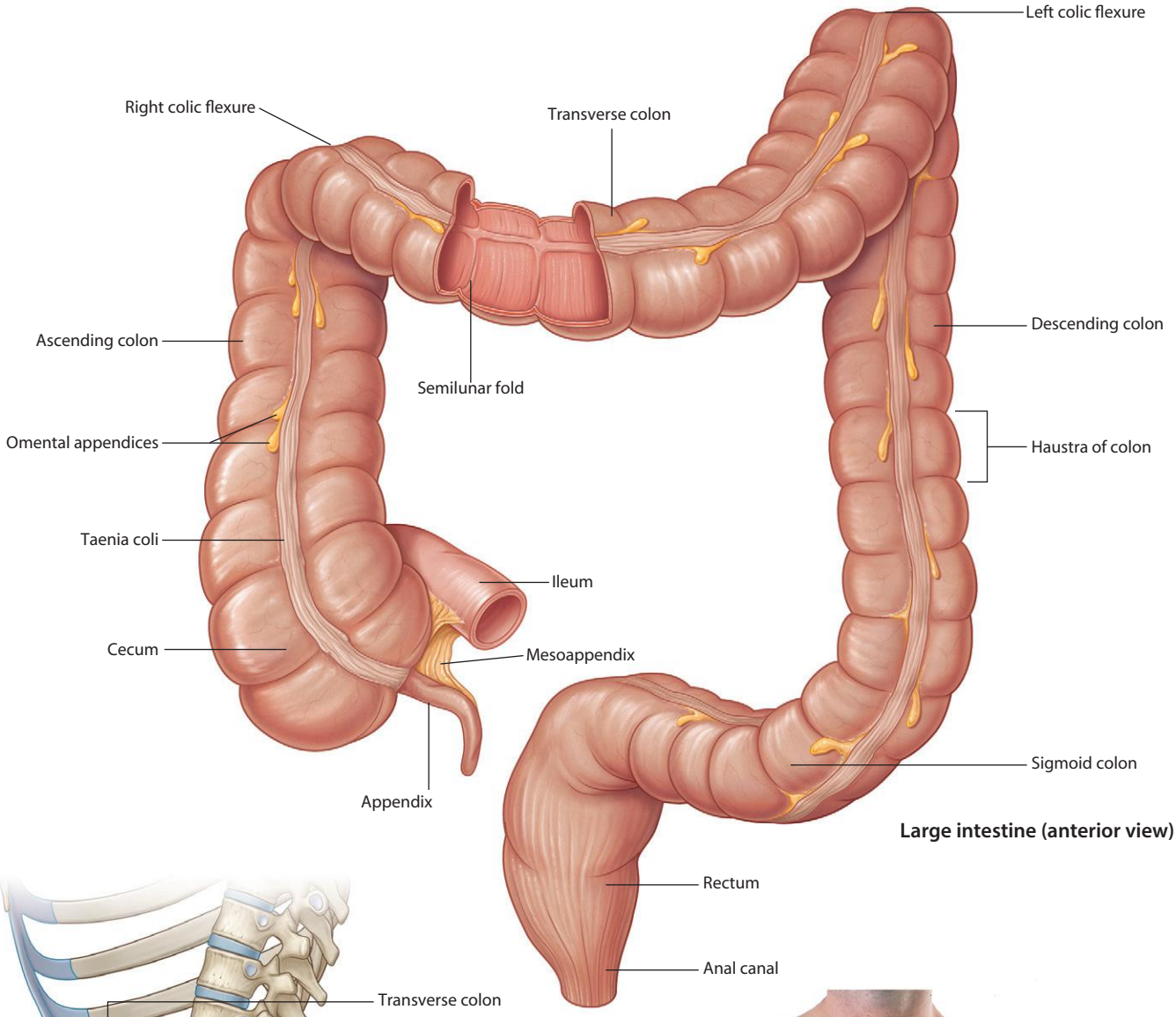

Large intestine (anterior view)

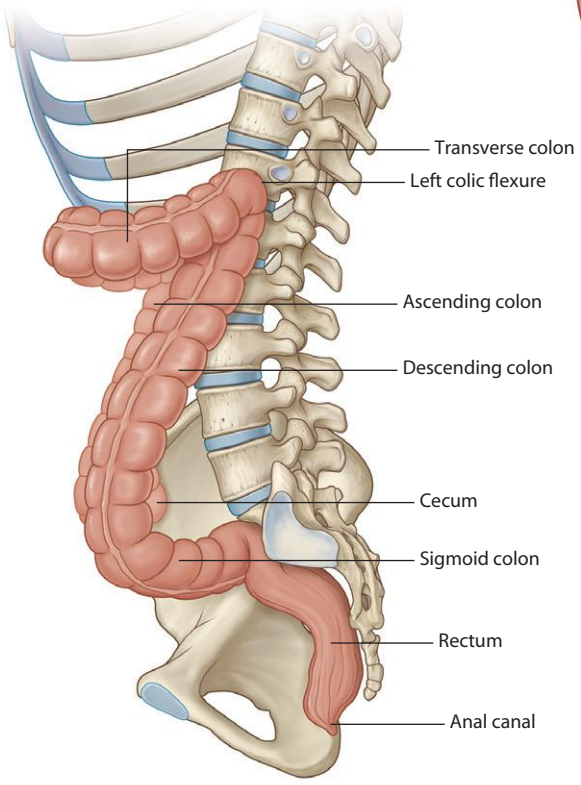

Large intestine (left lateral view)

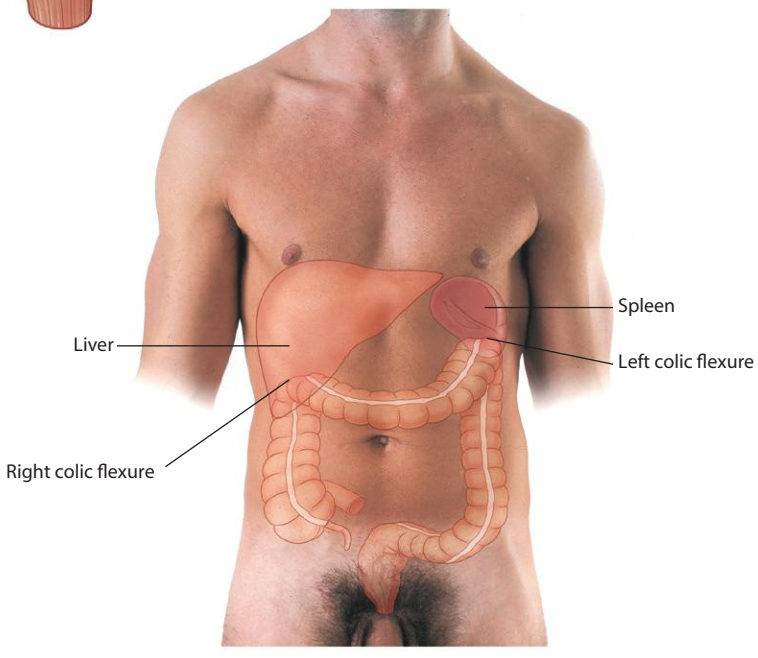

Surface projection of the large intestine

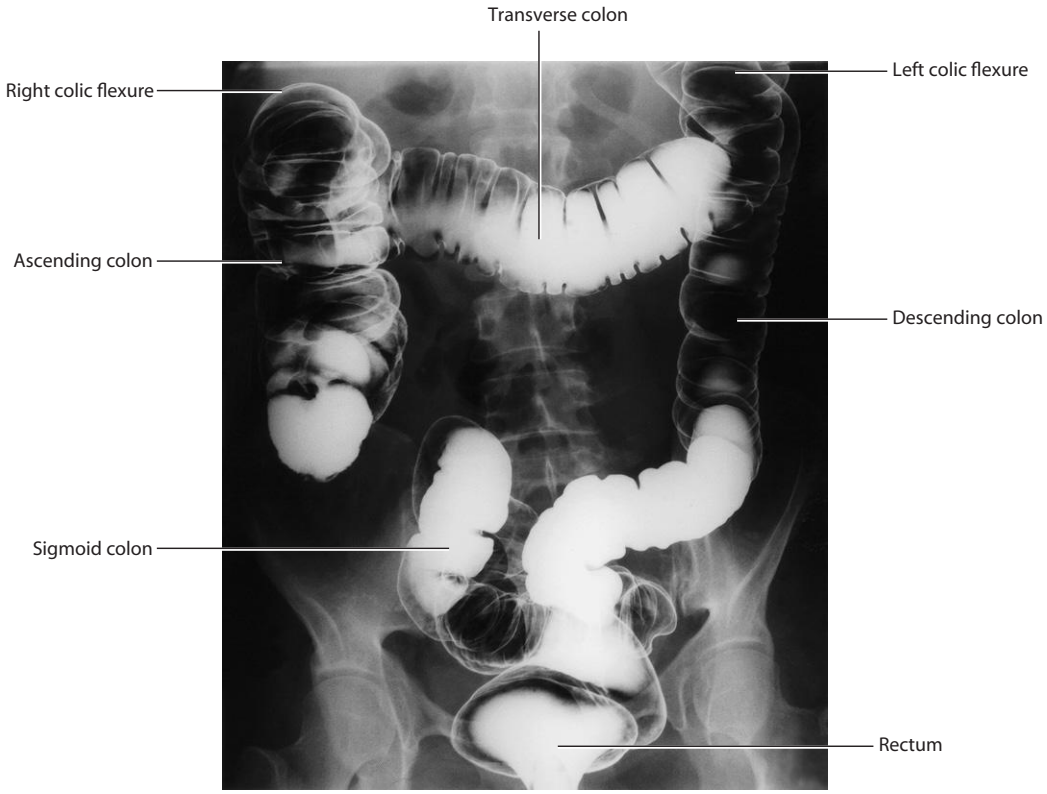

Radiograph using barium, showing the large intestine

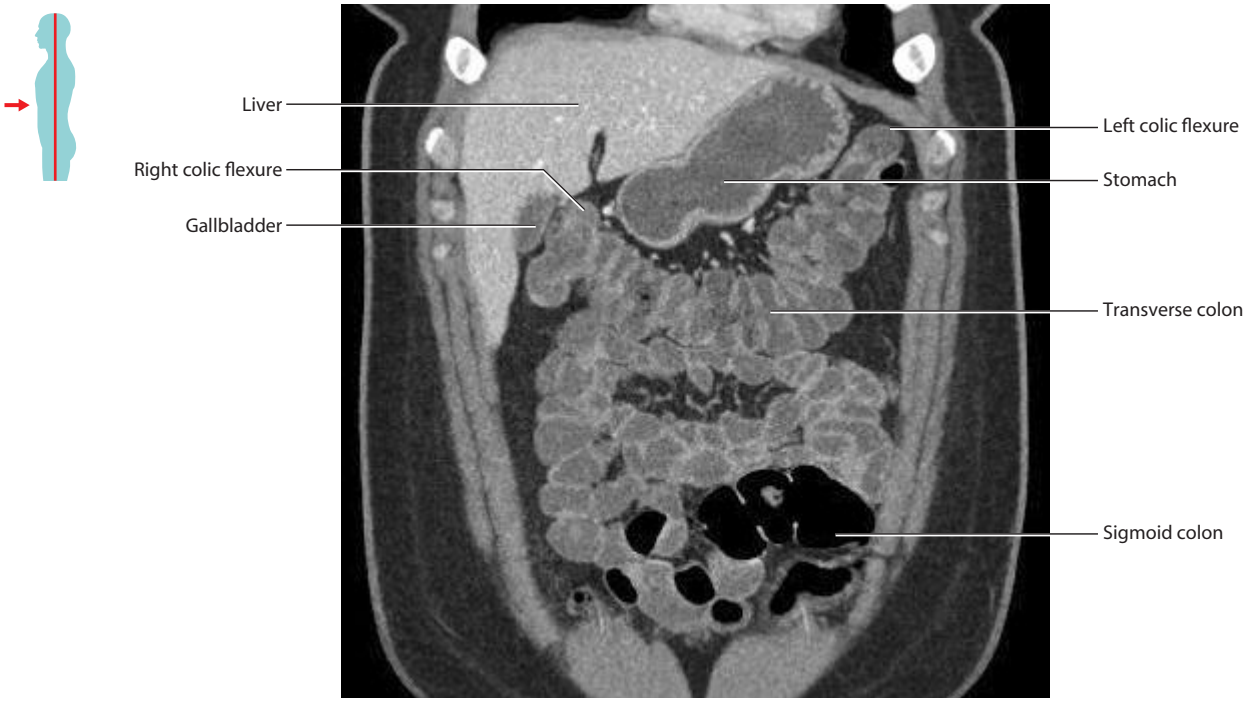

Transverse colon showing right and left colic flexures.
CT image, with contrast, in coronal plane

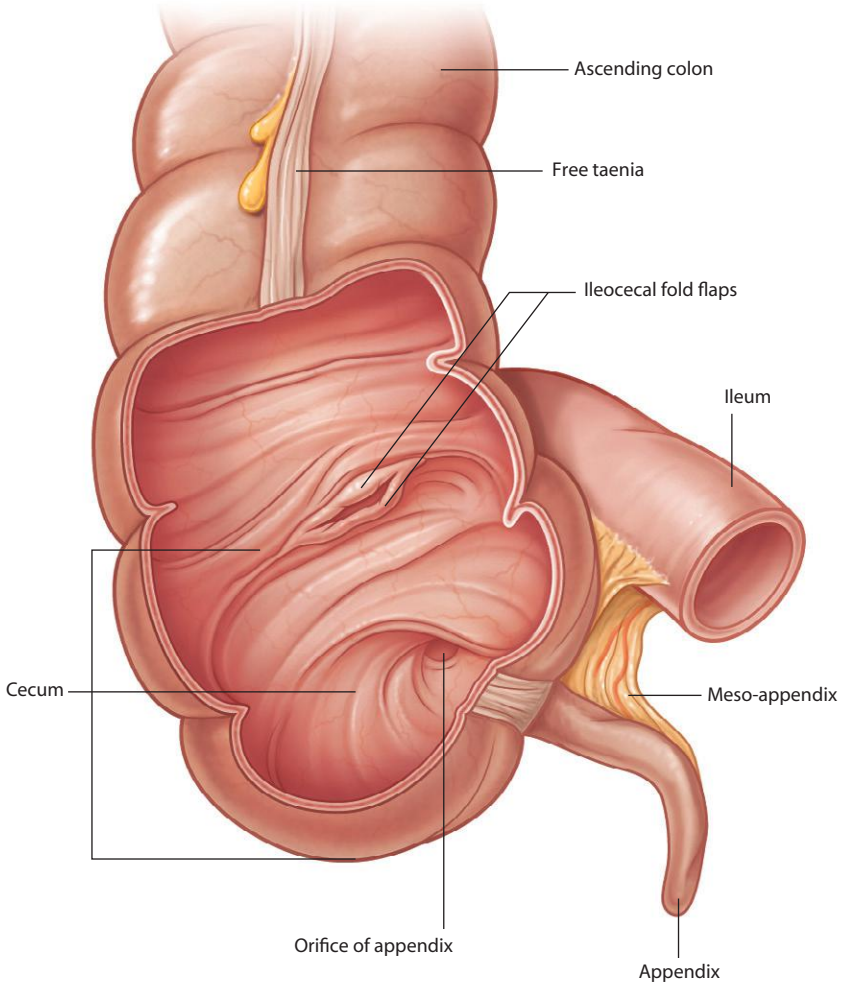

Ileocecal junction

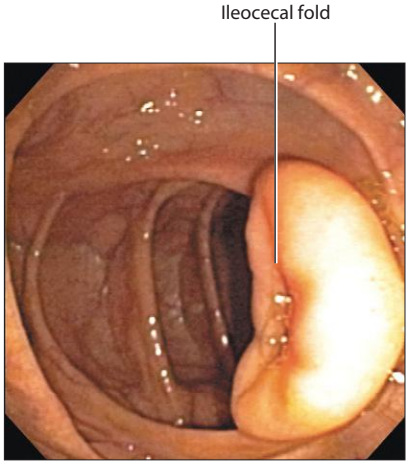

Colonoscopy showing ileocecal fold

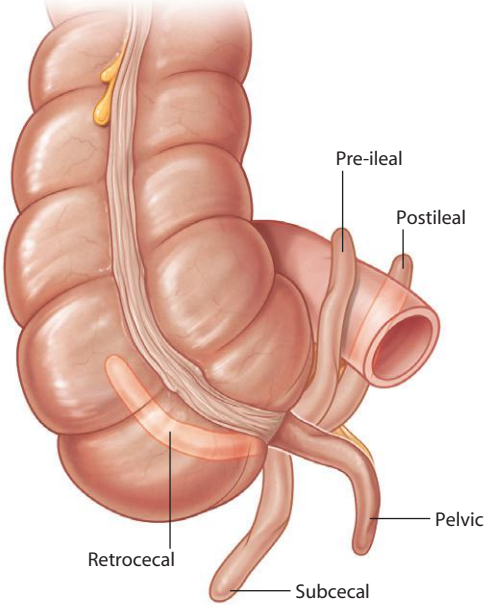

Positions of the appendix

A

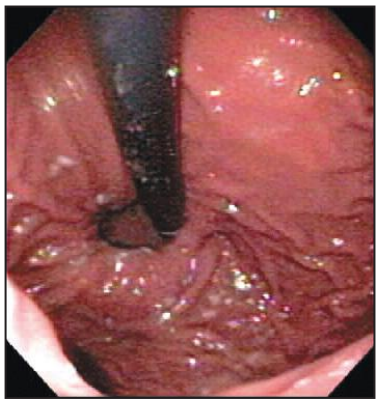

B

C

D

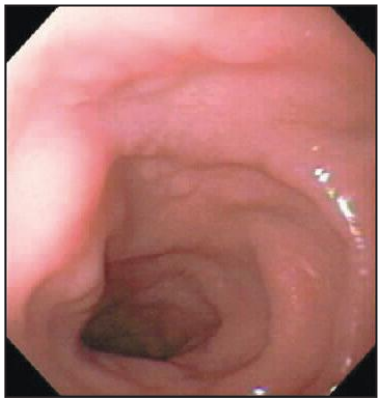

E

F

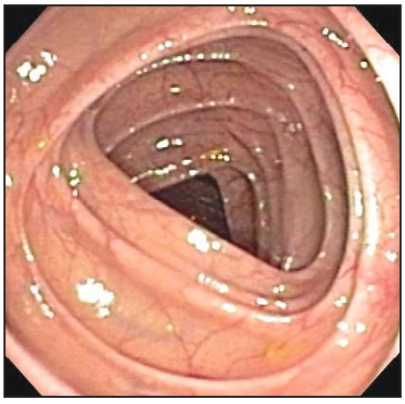

G

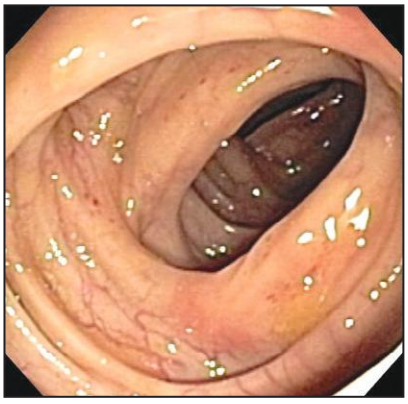

H

I

J

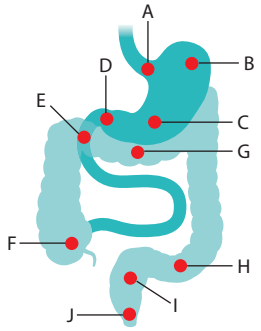

Endoscopy and colonoscopy showing different parts of the gastrointestinal tract.

A. Gastroesophageal junction
B. Cardiac orifice and fundus of stomach-retroflexed view
C. Body of stomach
D. Pylorus of stomach and pyloric sphincter
E. Duodenum
F. Cecum showing appendiceal opening
G. Transverse colon
H. Sigmoid colon
I. Rectum-retroflexed view
J. Pectinate line

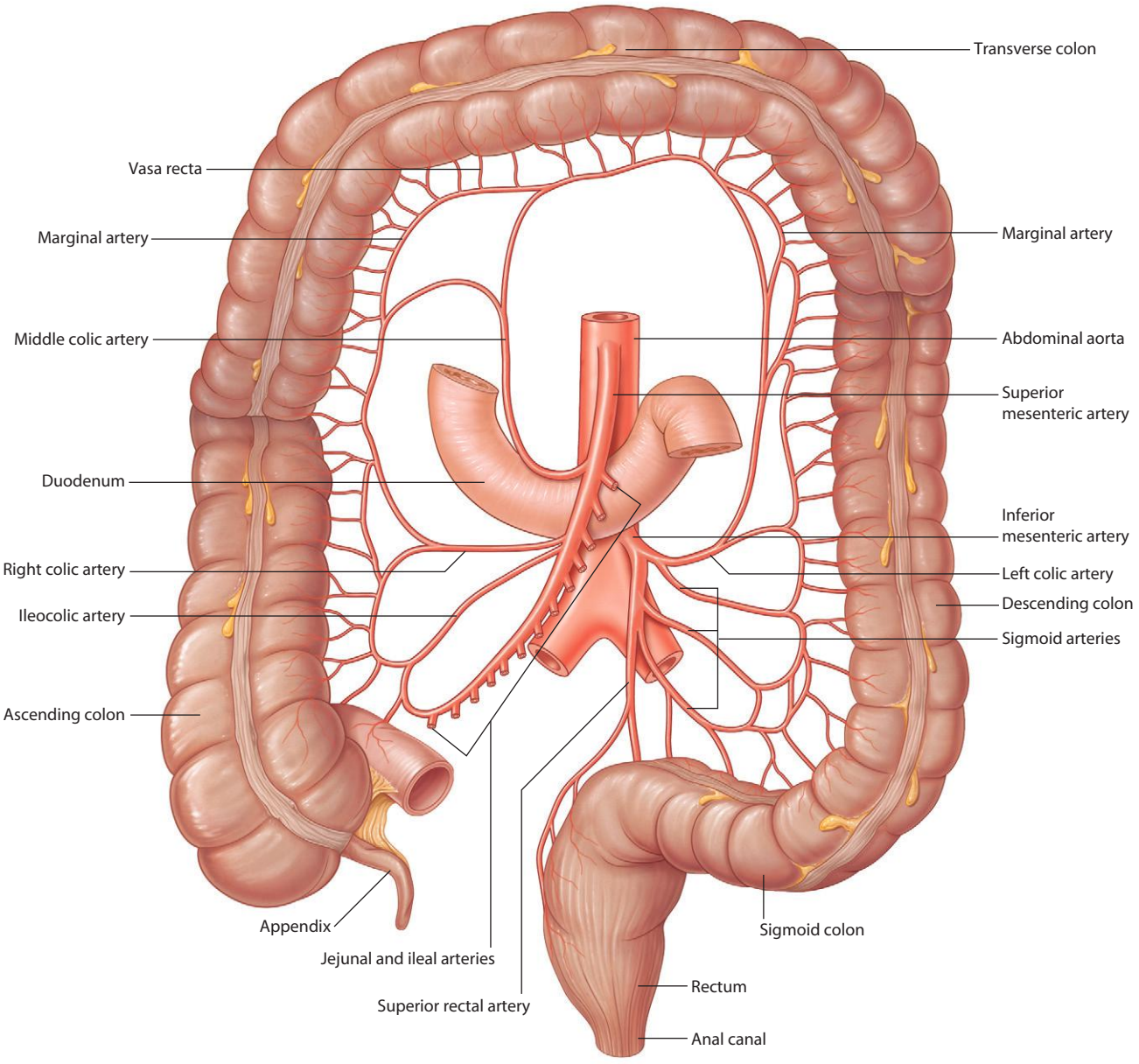

Superior and inferior mesenteric arteries

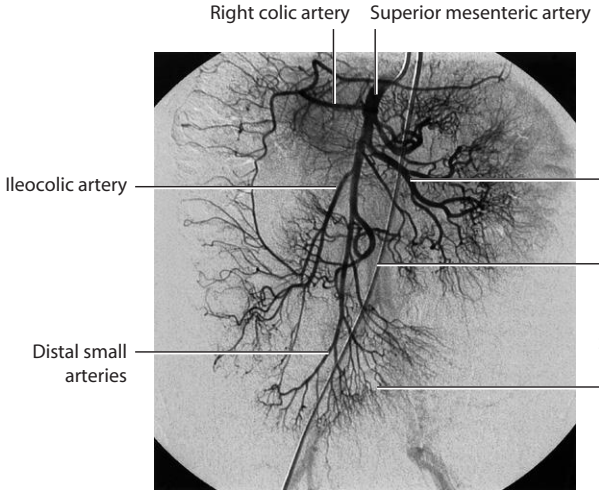

Digital subtraction angiography of the superior mesenteric artery and its branches

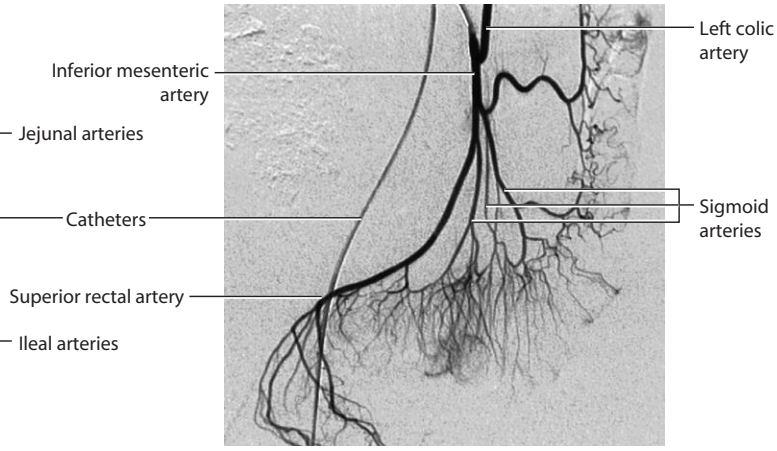

Digital subtraction angiography of the inferior mesenteric artery and its branches

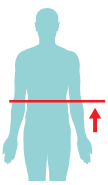

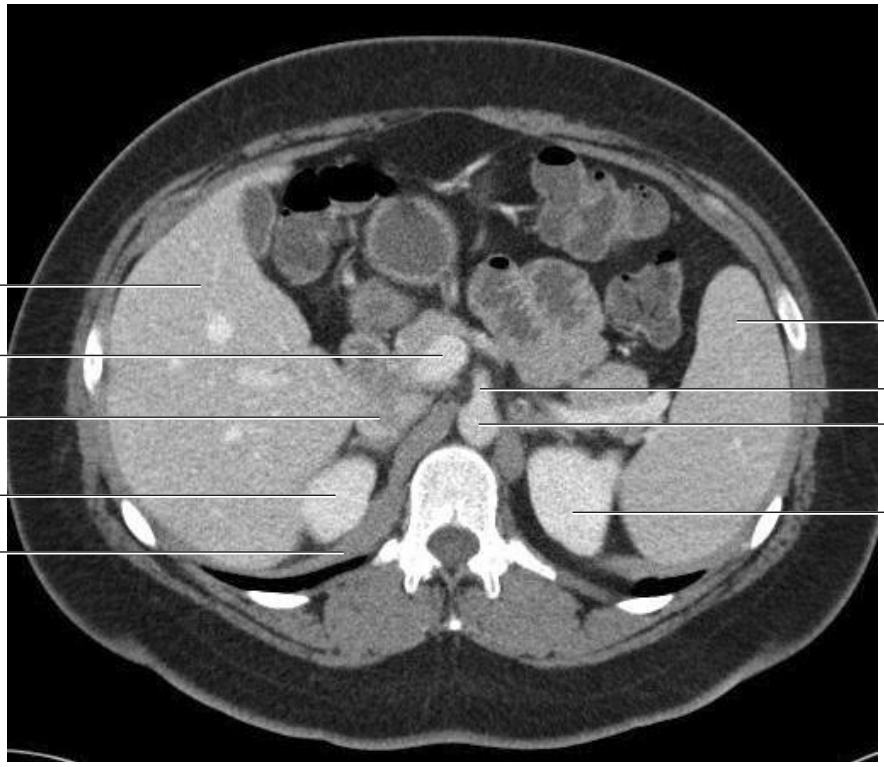

Branching of the superior mesenteric artery from the abdominal aorta.
CT image, with contrast, in axial plane

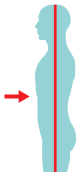

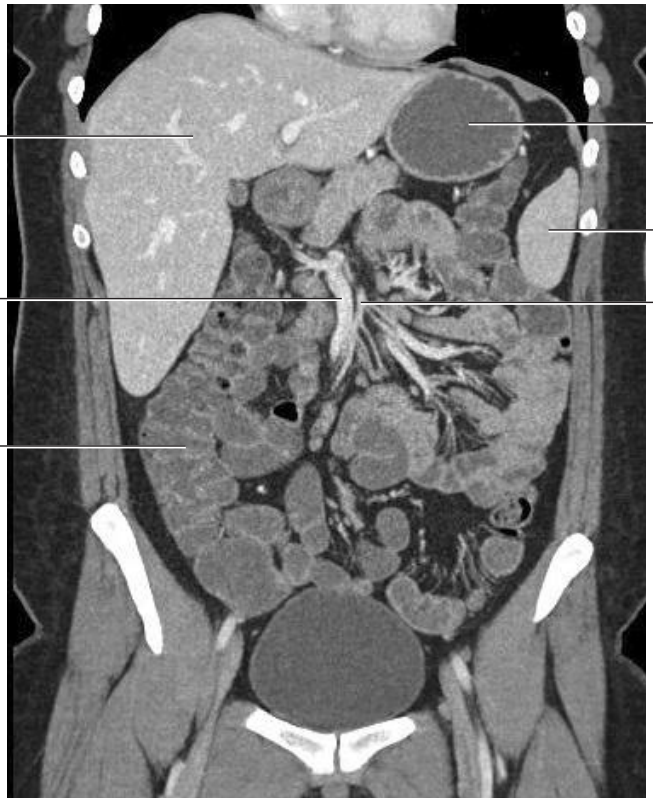

Positioning of the superior mesenteric artery in relation to other structures.
CT image, with contrast, in coronal plane

Surface projection of the liver (anterior view)

Location of the liver.
CT image, with contrast, in coronal plane

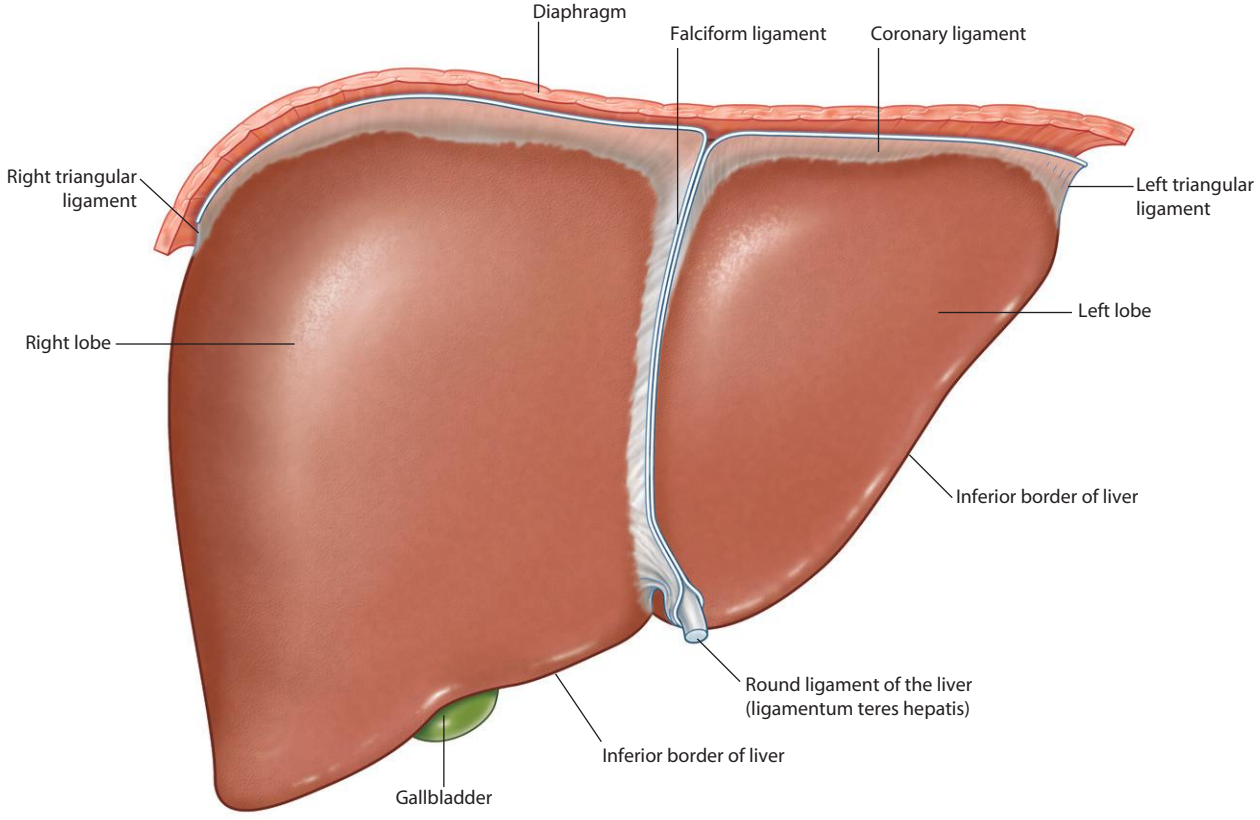

Anterior surface of liver

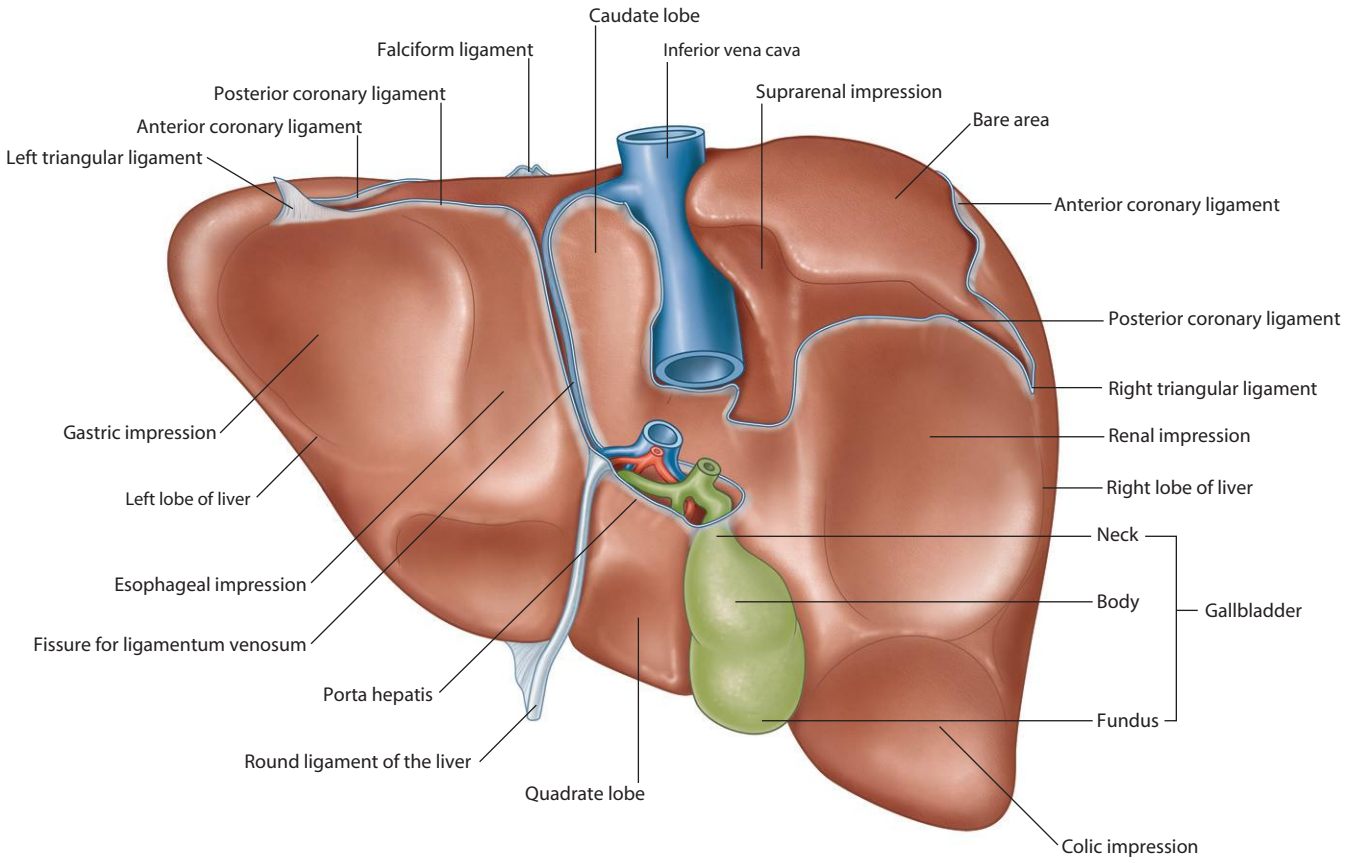

Posterior surface of liver

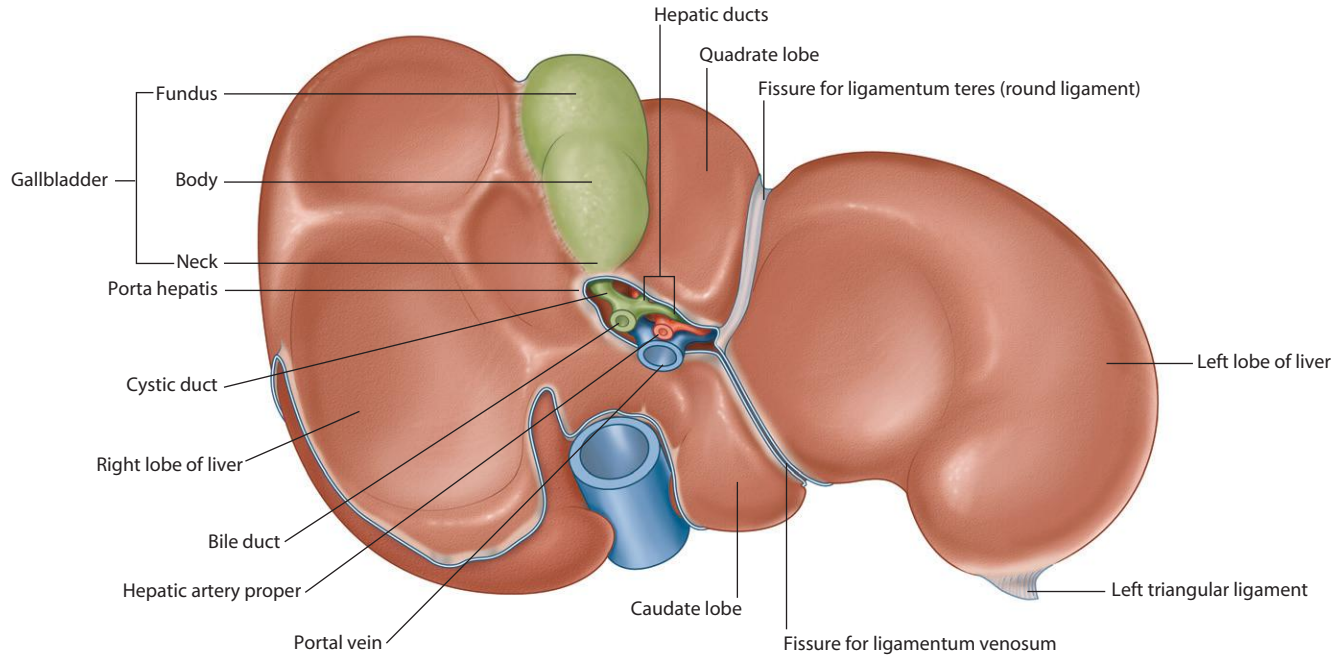

Visceral surface of liver

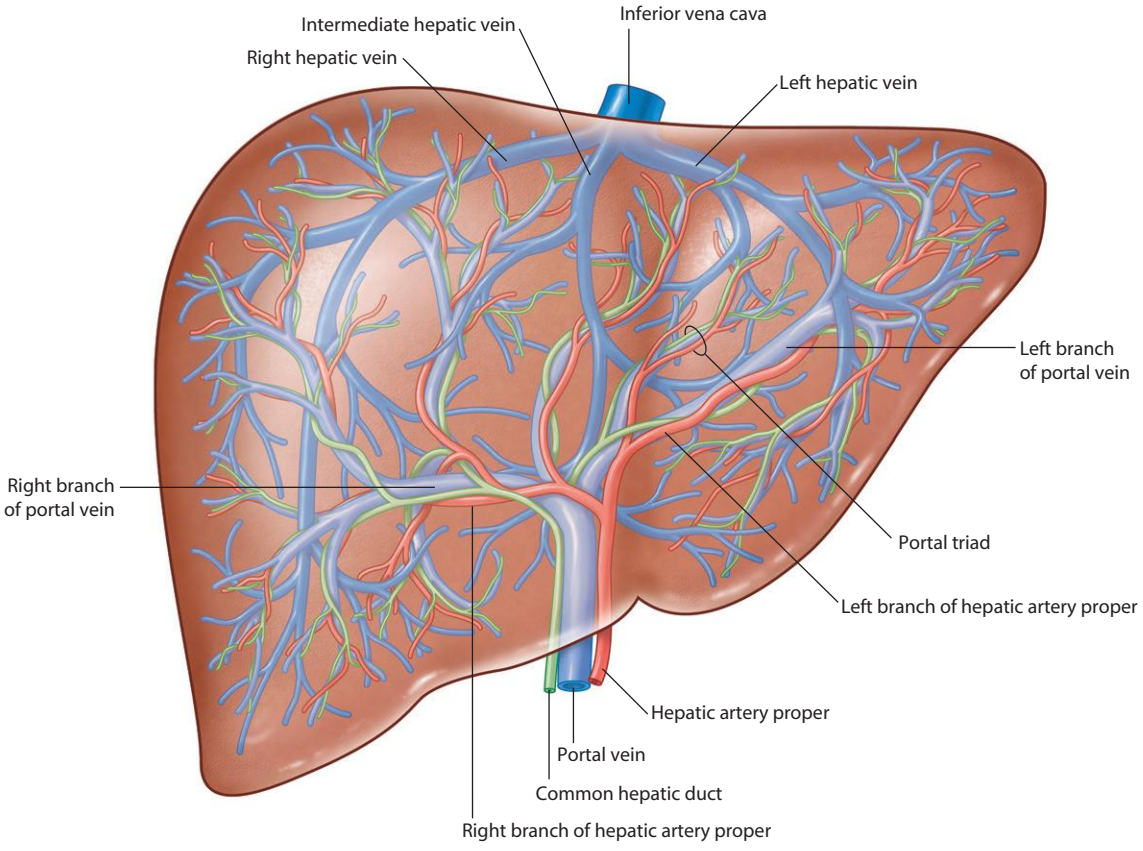

Anterior surface of liver with hepatic veins, portal vein, and associated vessels

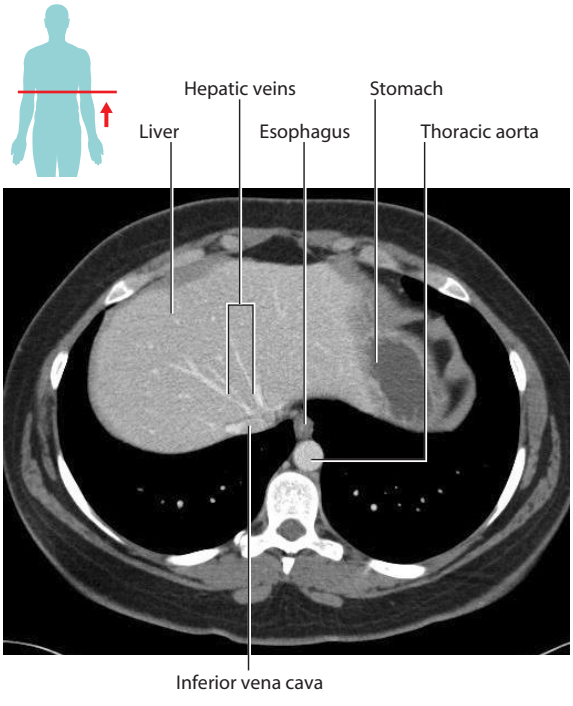

Hepatic veins entering the inferior vena cava in the substance of the liver.
CT image, with contrast, in axial plane

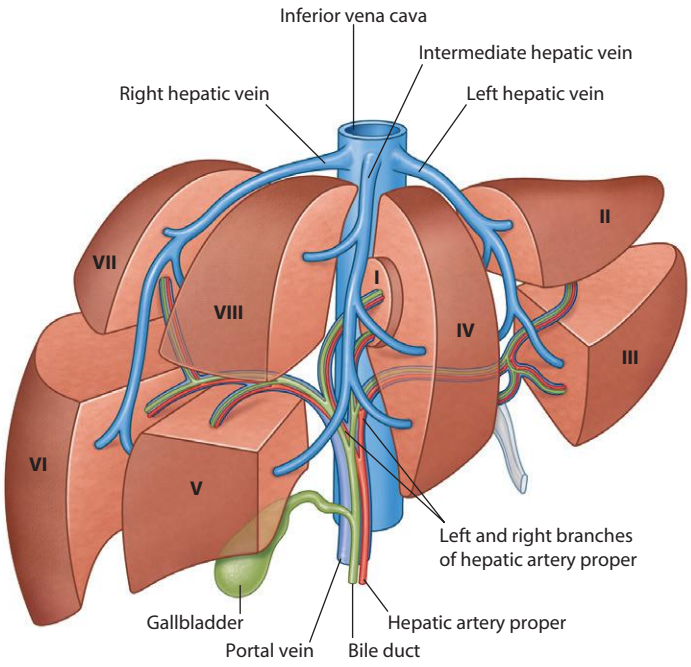

Arrangement of the hepatic venous segments

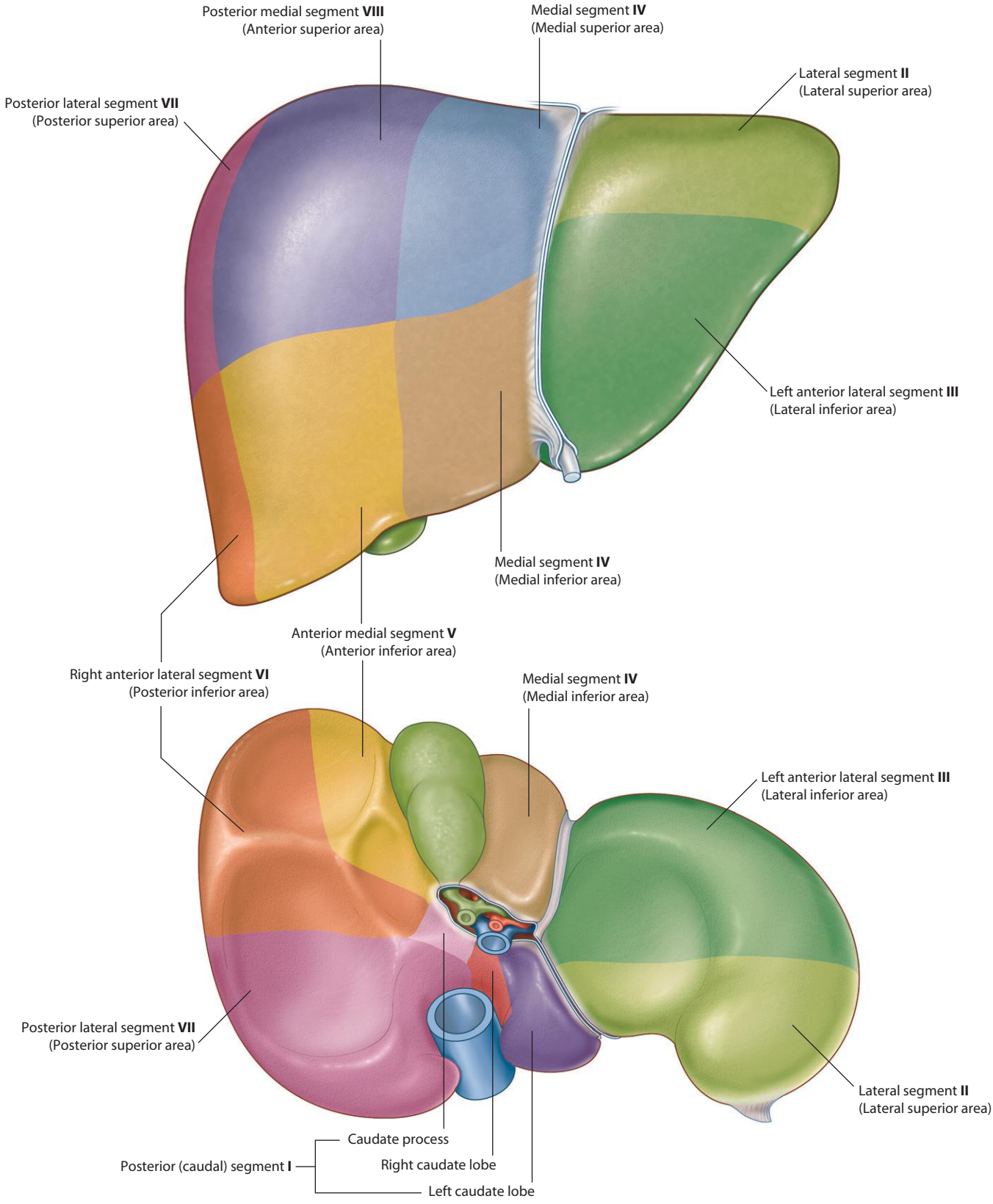

Segments of the liver shown on anterior and visceral surfaces

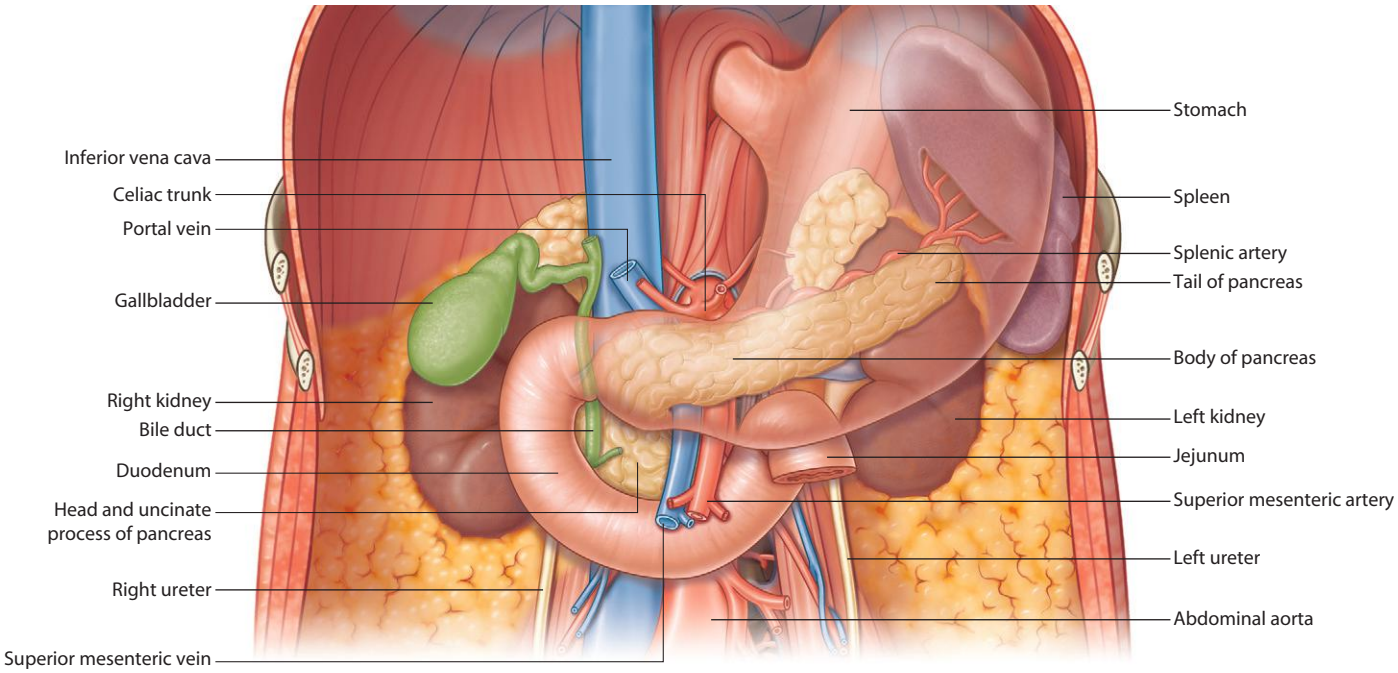

Pancreas with related structures

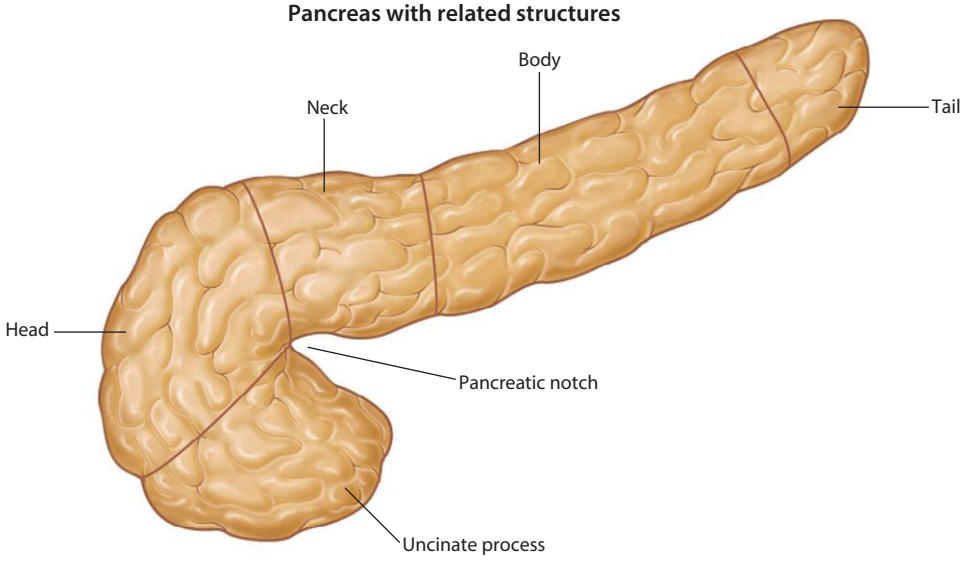

Anterior surface of the pancreas

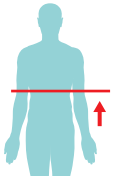

Pancreas.
CT image, with contrast, in axial plane

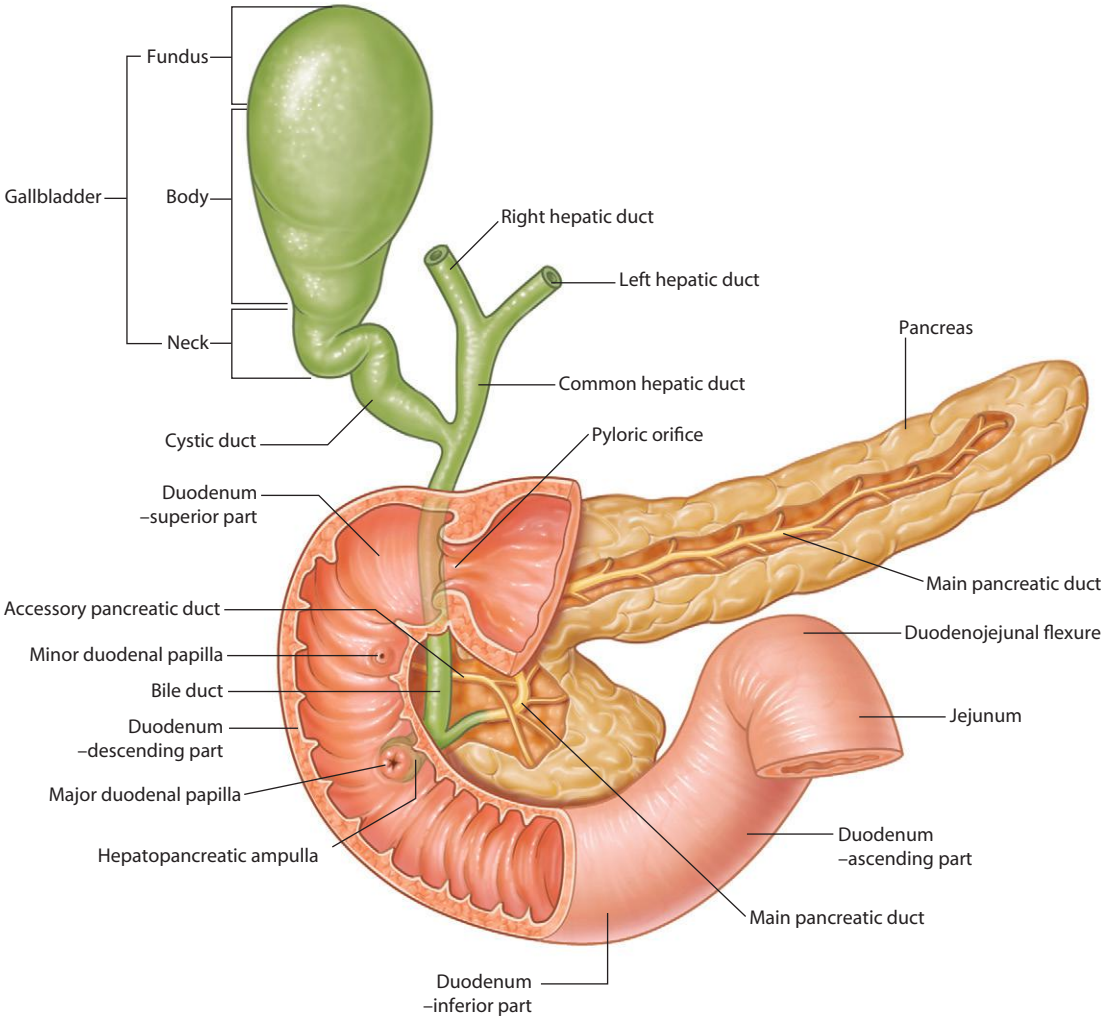

Bile and pancreatic ducts

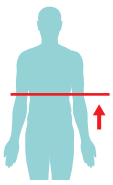

Positioning of the gallbladder in relation to other structures.
CT image, with contrast, in axial plane

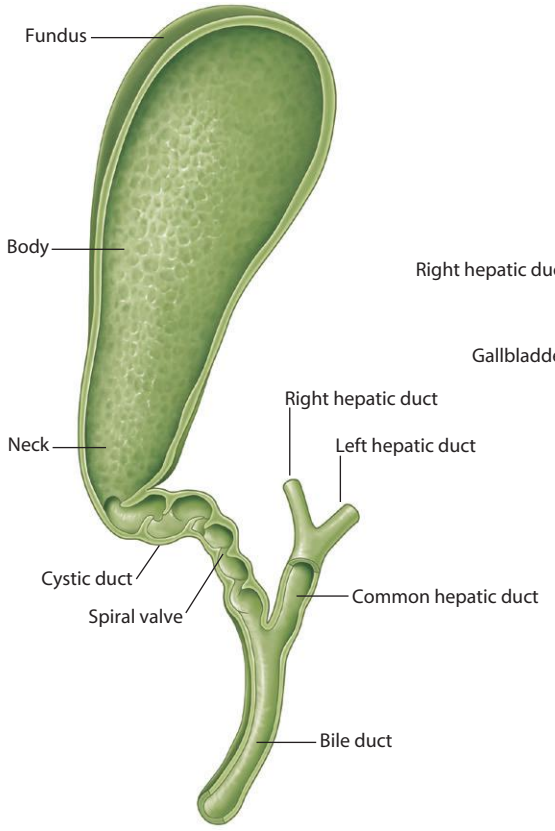

Section through gallbladder and bile ducts

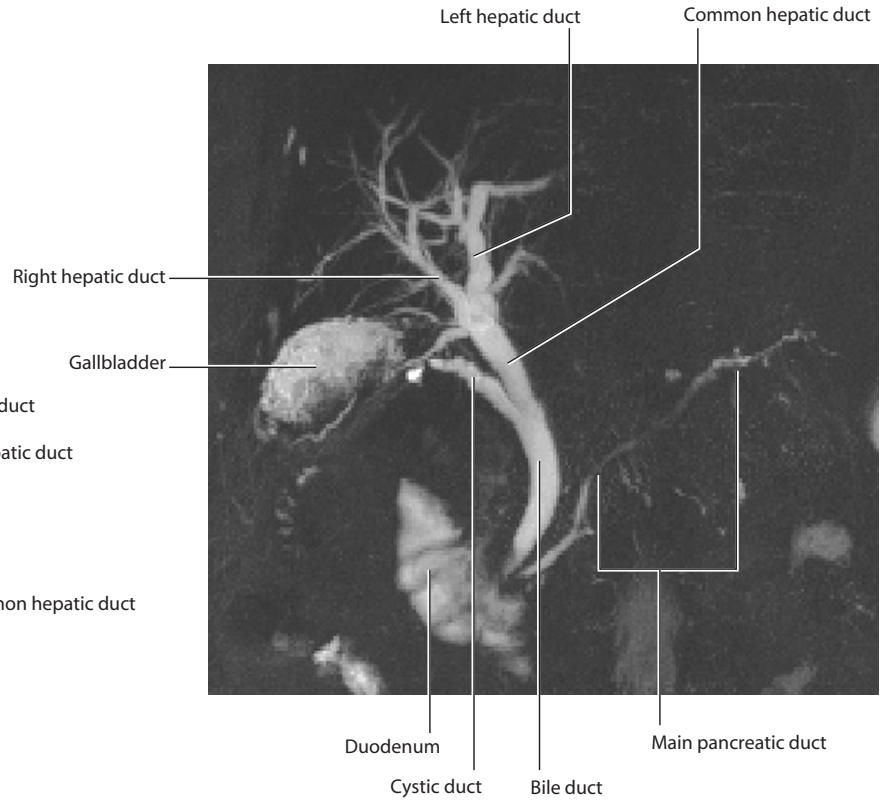

Bile duct system.
Magnetic resonance cholecystopancreatogram

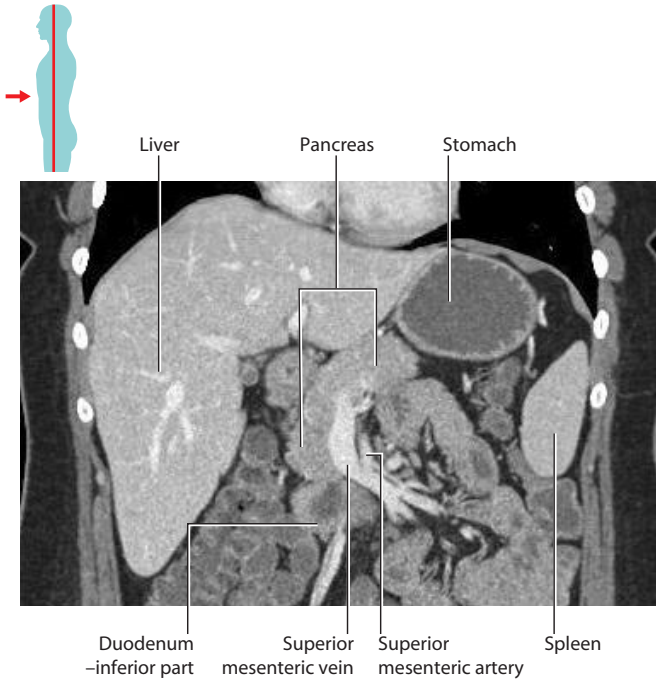

Positioning of the pancreas in relation to other structures.
CT image, with contrast, in coronal plane

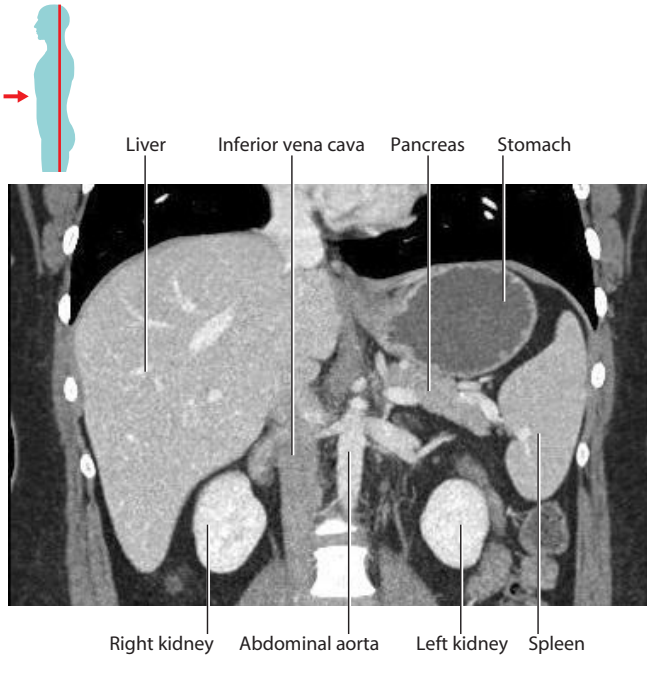

Relationship of pancreas to the stomach and spleen.
CT image, with contrast, in coronal plane

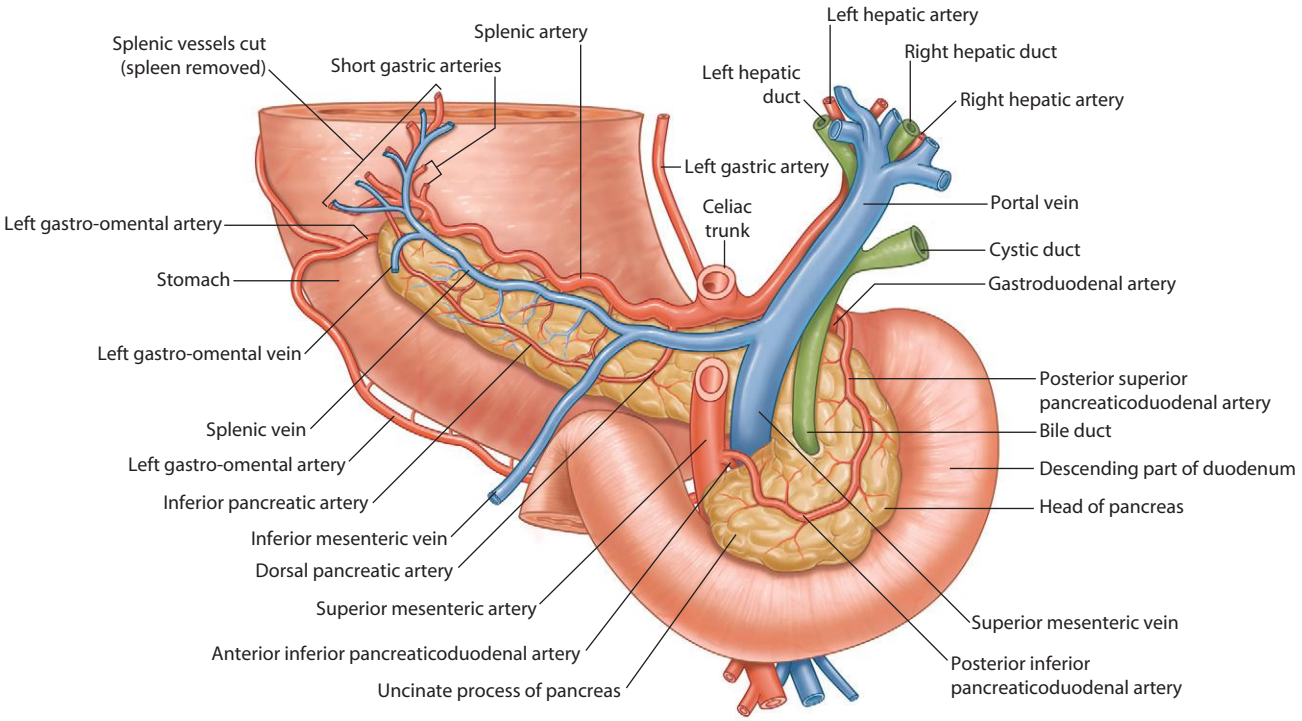

Vasculature of the pancreas (posterior view)

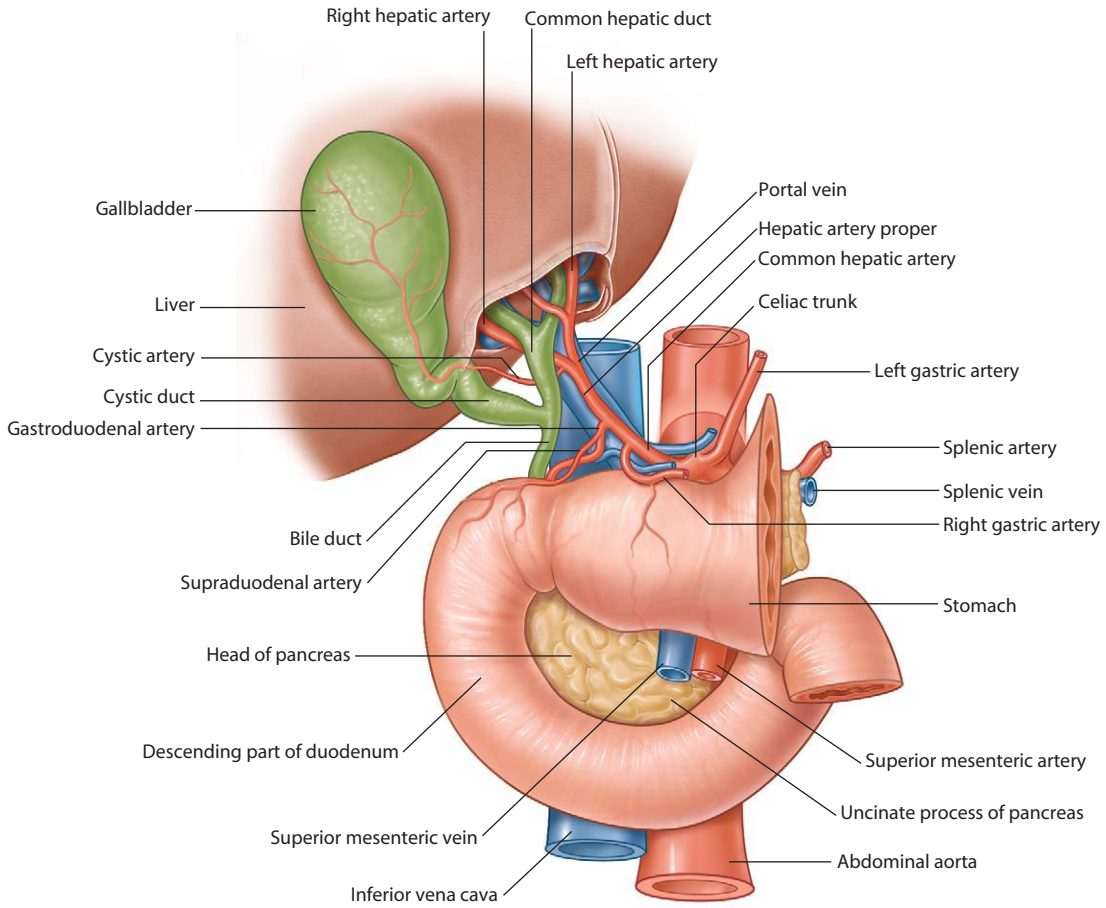

Distribution of the common hepatic artery

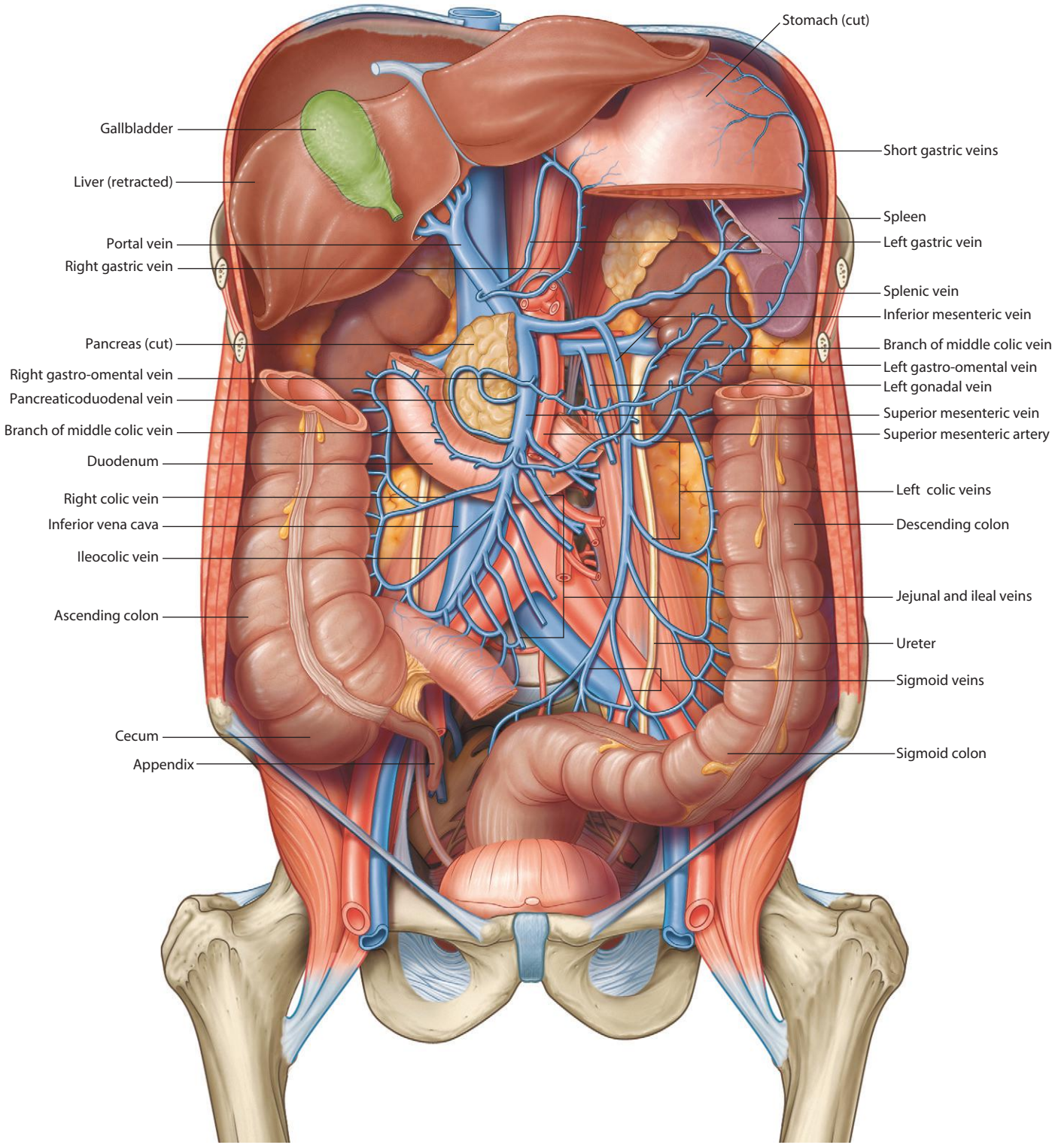

Venous drainage of the abdominal portion of the gastrointestinal tract in situ

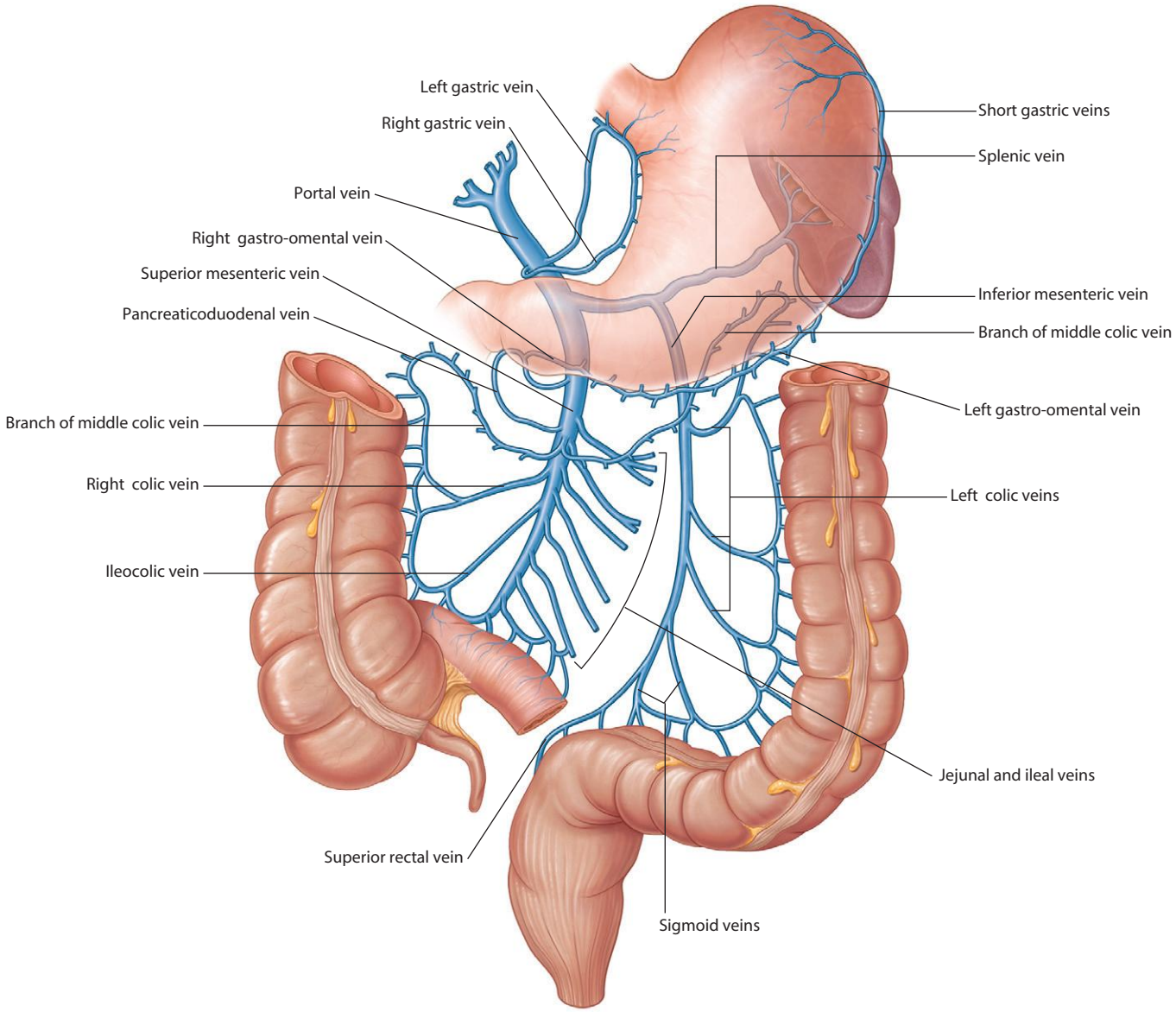

Venous drainage of the abdominal portion of the gastrointestinal tract

Formation of the portal vein.
CT image, with contrast, in coronal plane

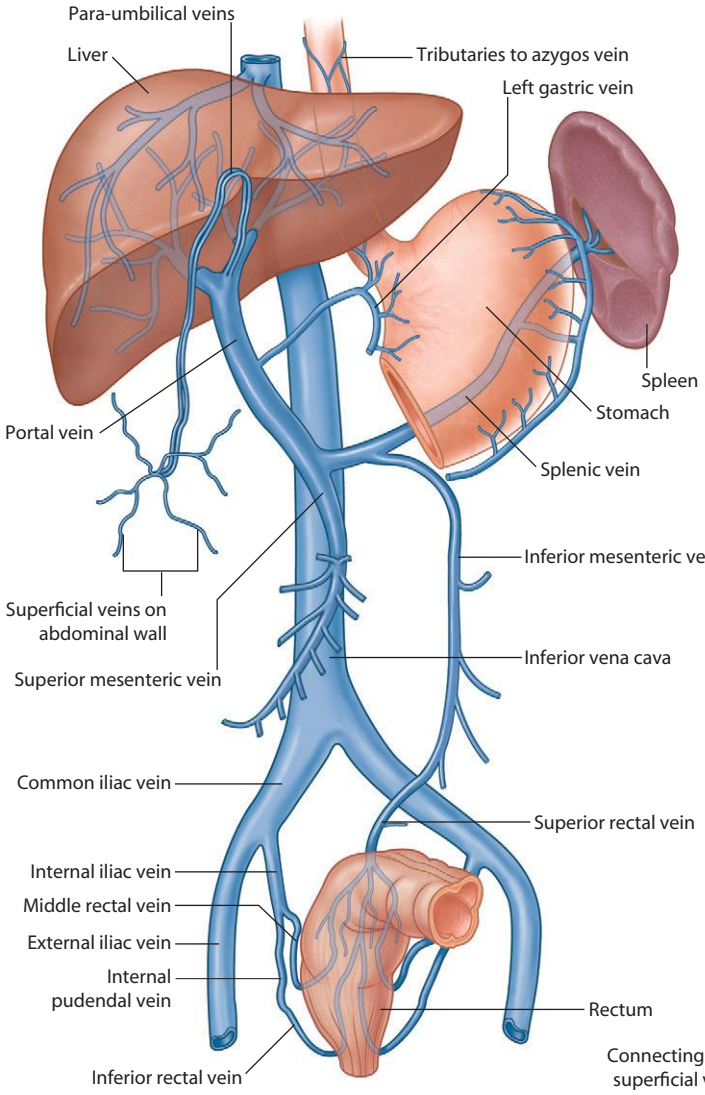

Portosystemic anastomoses

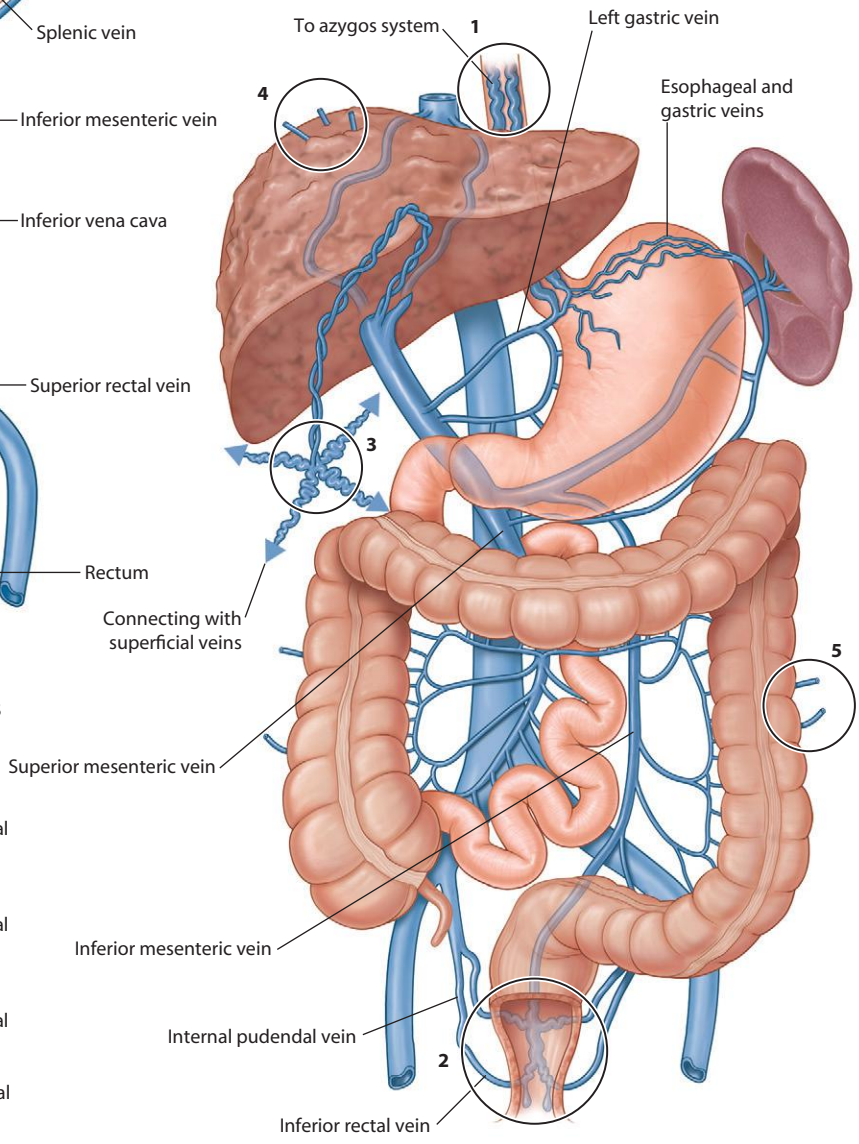

Venous enlargement in portal hypertension (varices)

1 Esophageal varices:
swollen connections between systemic and portal systems at inferior end of esophagus

2 Varices at the anorectal junction:
swollen connections between systemic and portal systems at inferior end of rectum and anal canal

3 Caput medusae:
swollen connections between systemic and portal systems around umbilicus

4 Swollen connections between systemic and portal systems at bare area of liver

5 Swollen connections between veins associated with retroperitoneal parts of the gastrointestinal tract and the body wall

tahir99-VRG & vip.persianss.ir

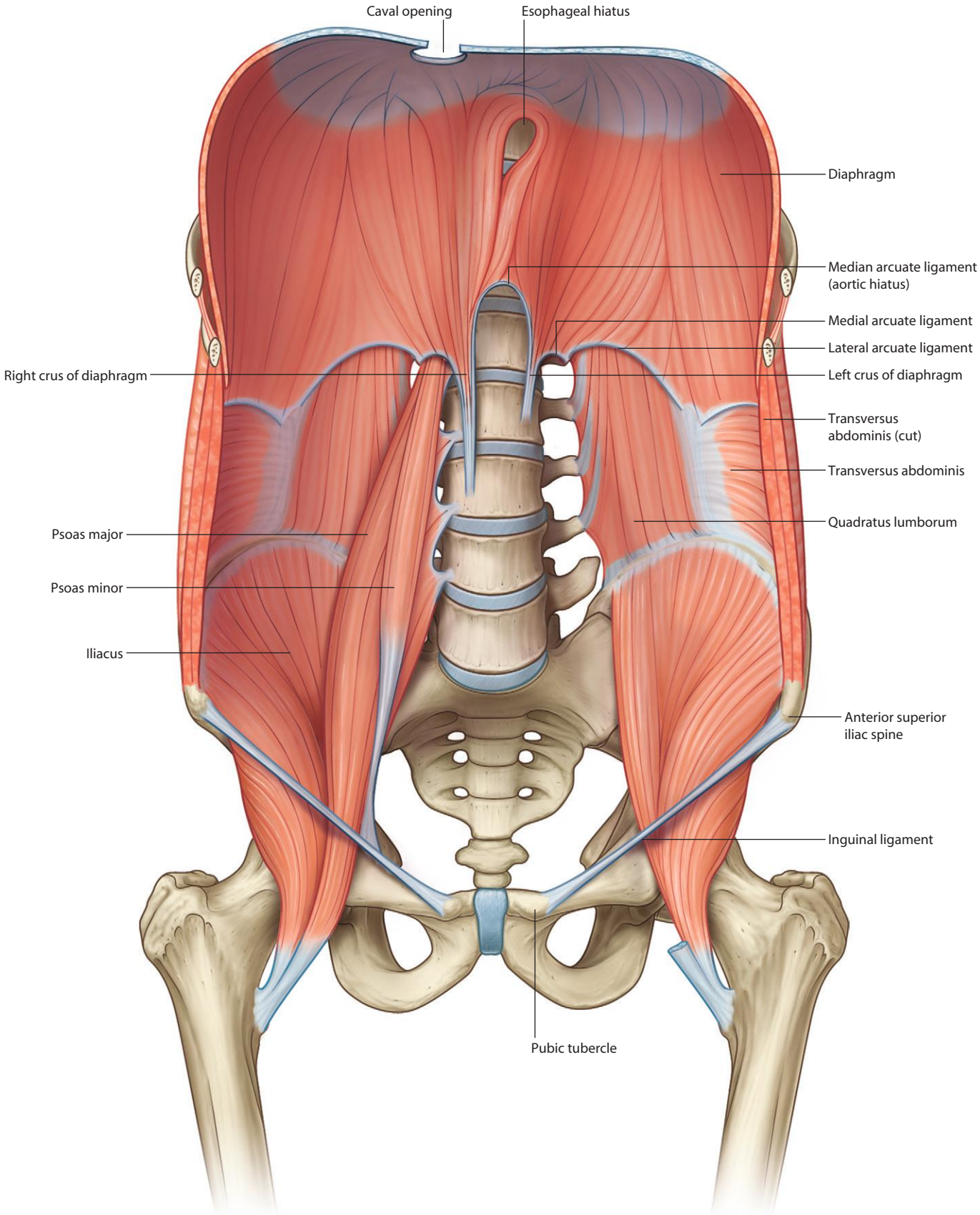

Muscles of the posterior abdominal wall

tahir99-VRG & vip.persianss.ir

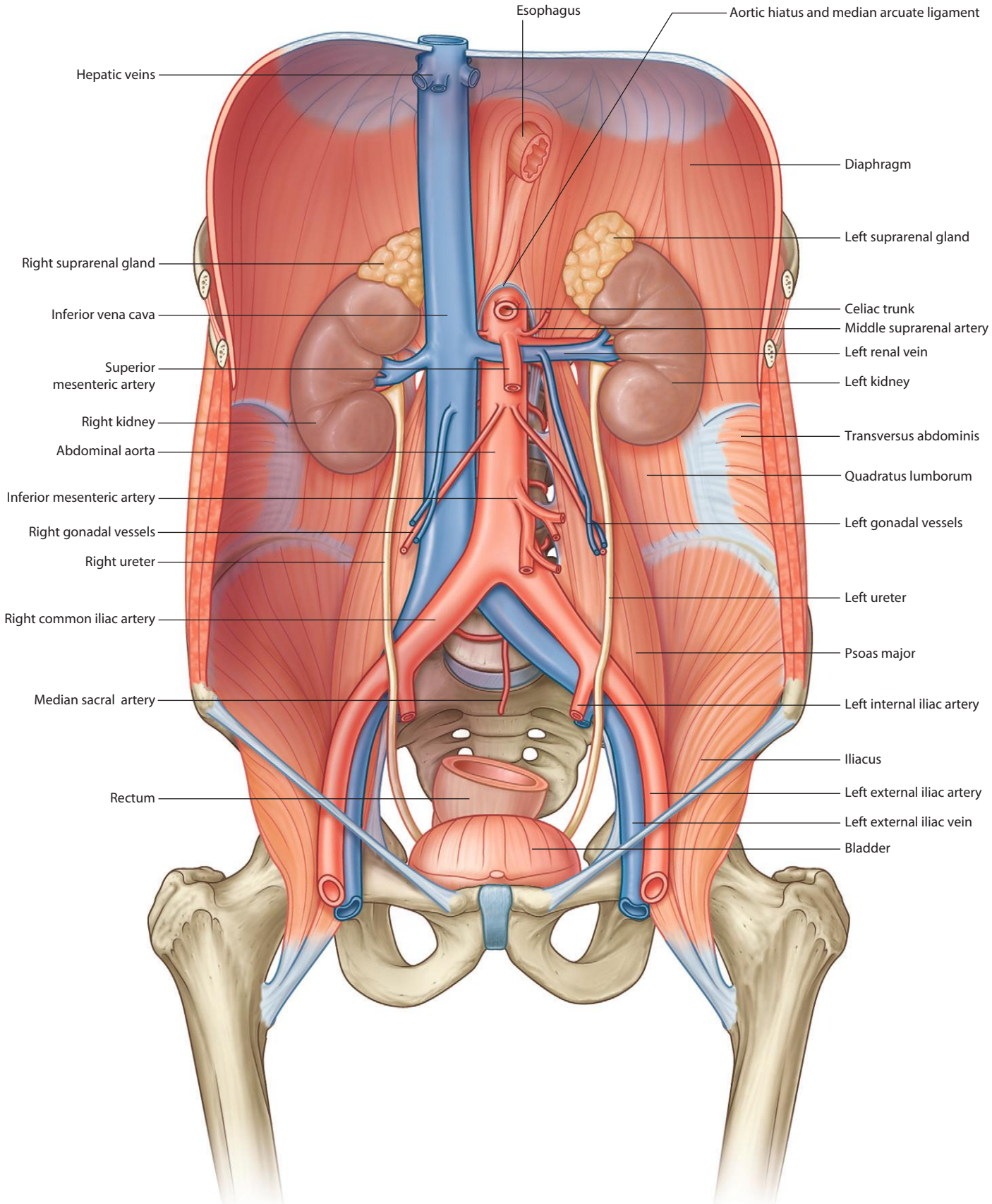

Vessels and their relationship to the posterior abdominal wall

tahir99-VRG & vip.persianss.ir

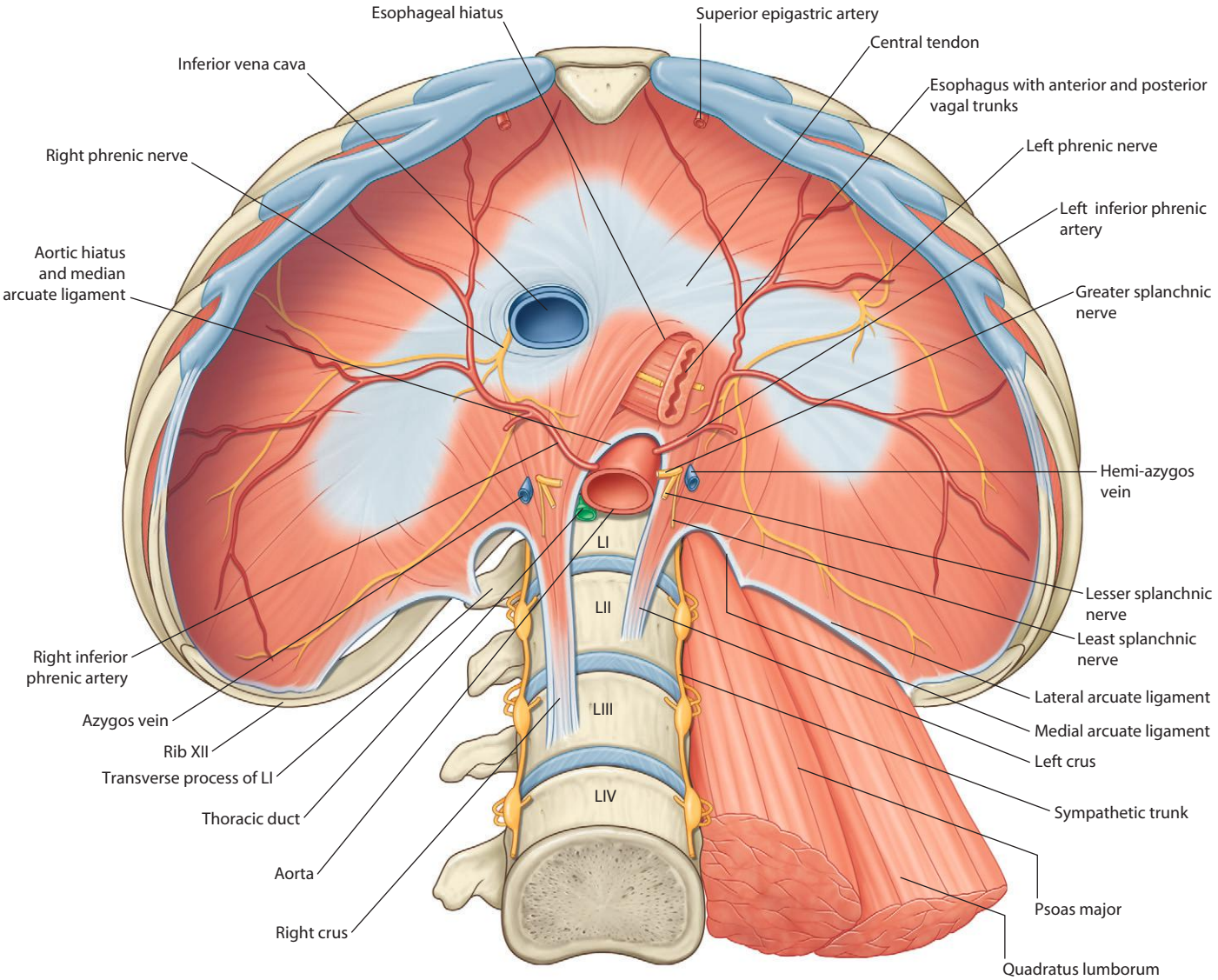

Inferior view of diaphragm

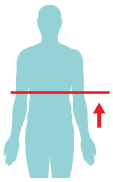

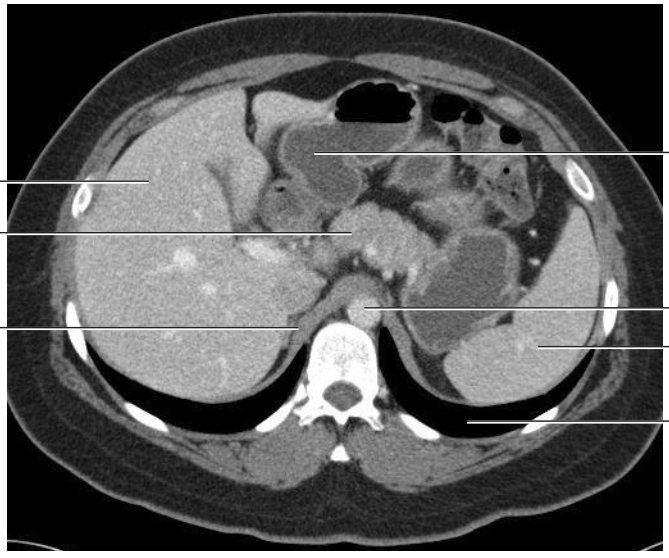

Positioning of the diaphragm in relation to other structures.
CT image, with contrast, in axial plane

tahir99-VRG & vip.persianss.ir

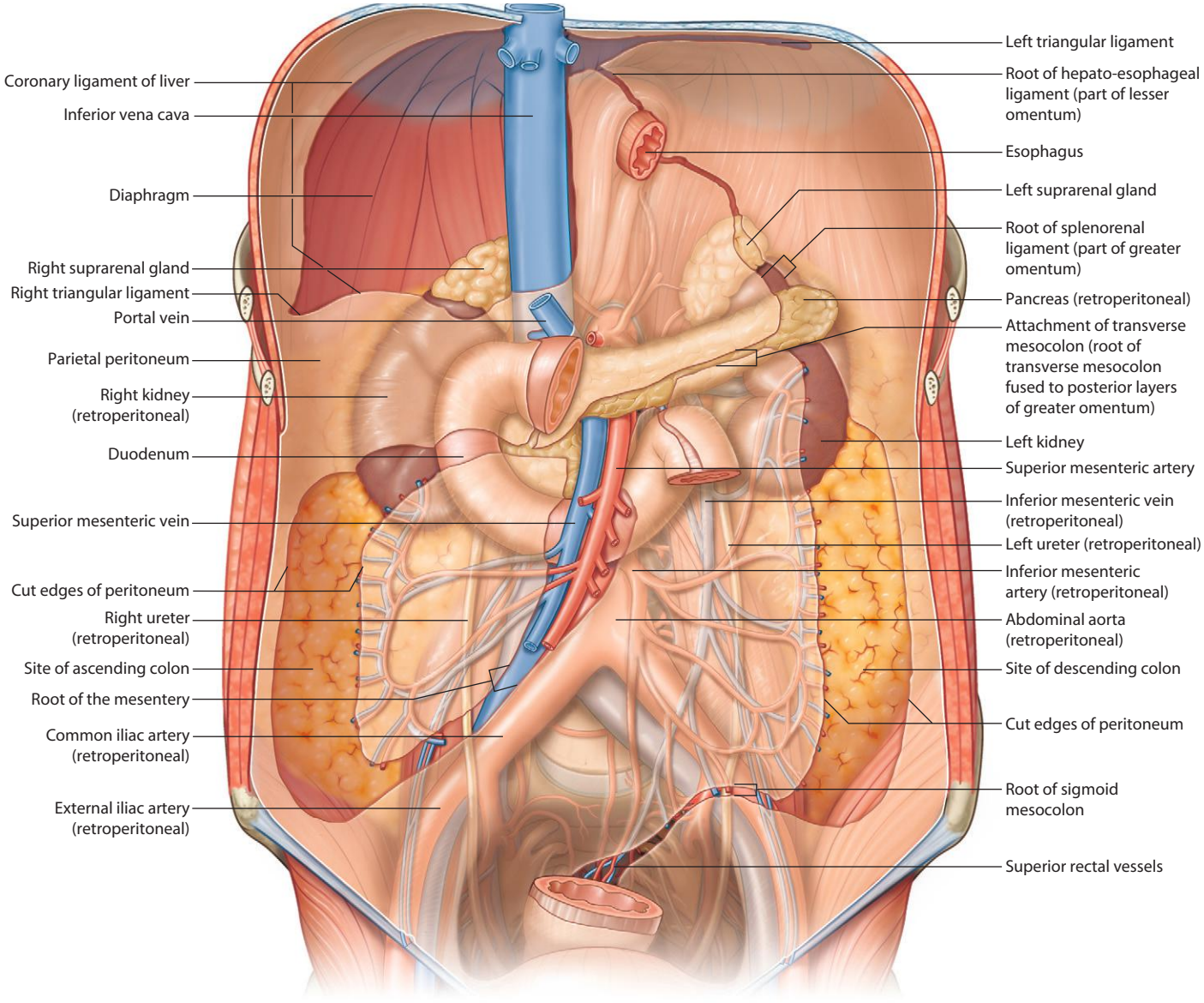

Peritoneum and the retroperitoneal position of the kidneys

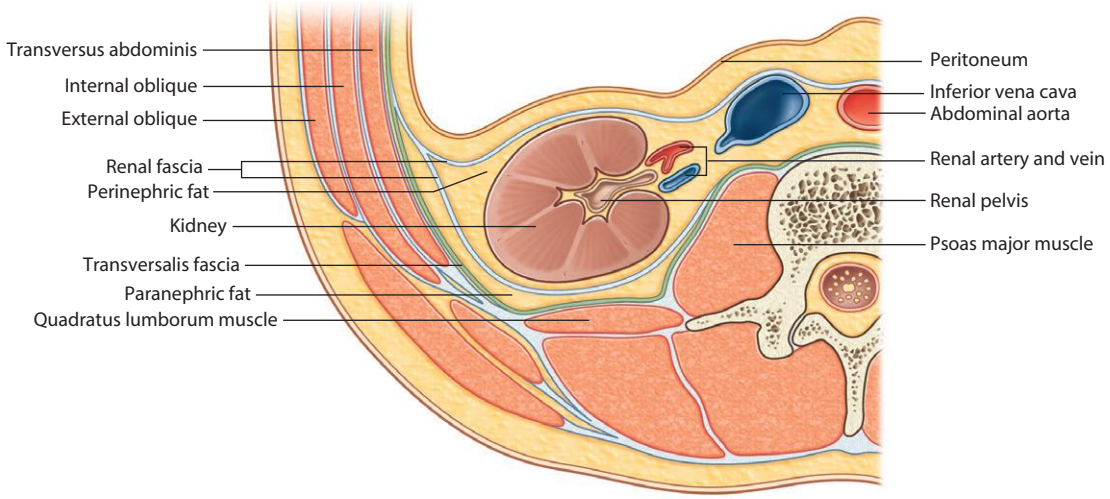

Organization of fat and fascia surrounding the kidneys

tahir99-VRG & vip.persianss.ir

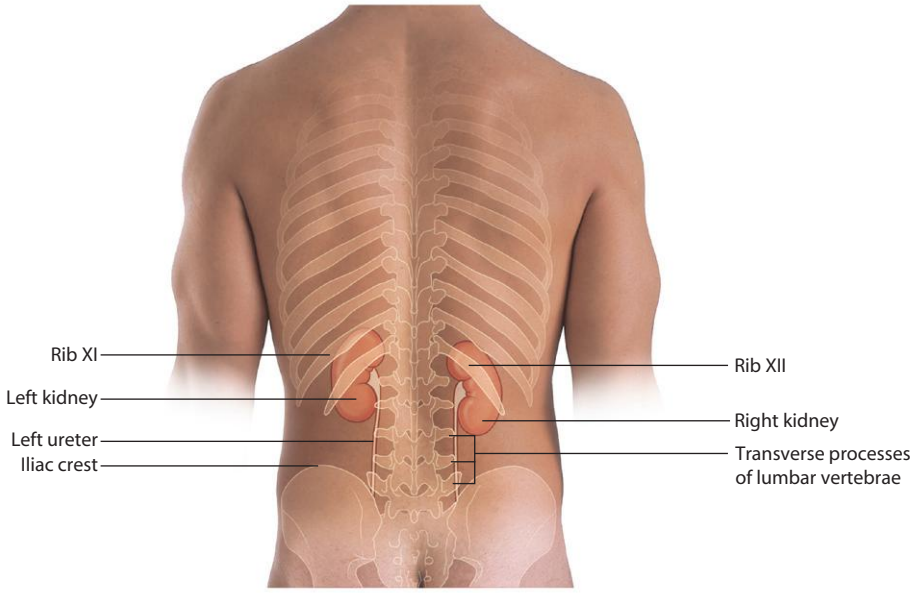

Surface projection of the kidneys and ureters (posterior view)

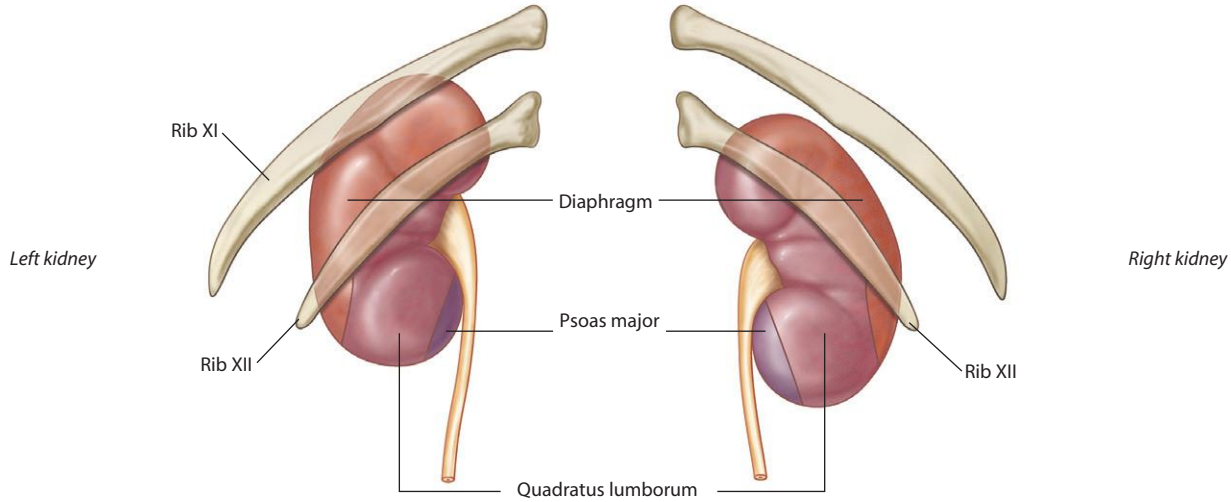

Structures related to the posterior surface of each kidney

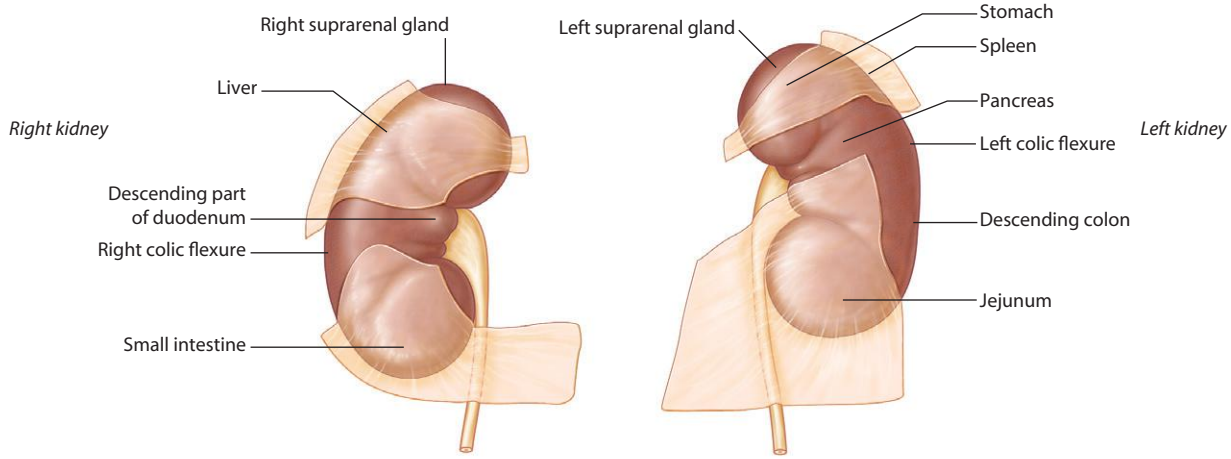

Structures related to the anterior surface of each kidney

tahir99-VRG & vip.persianss.ir

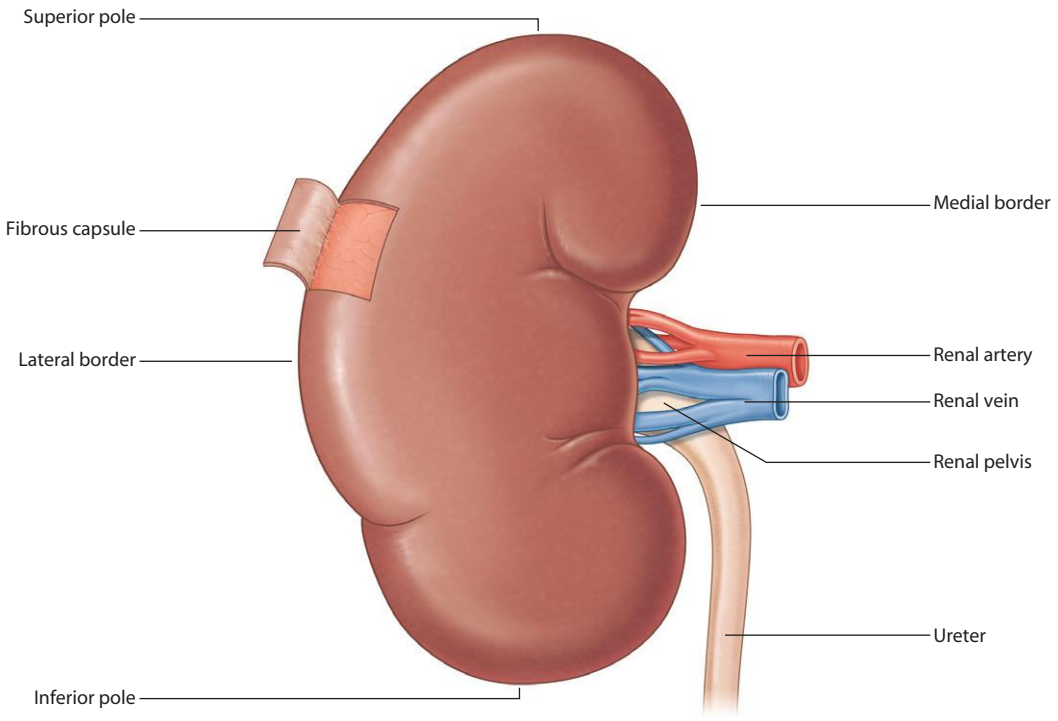

Anterior surface of right kidney

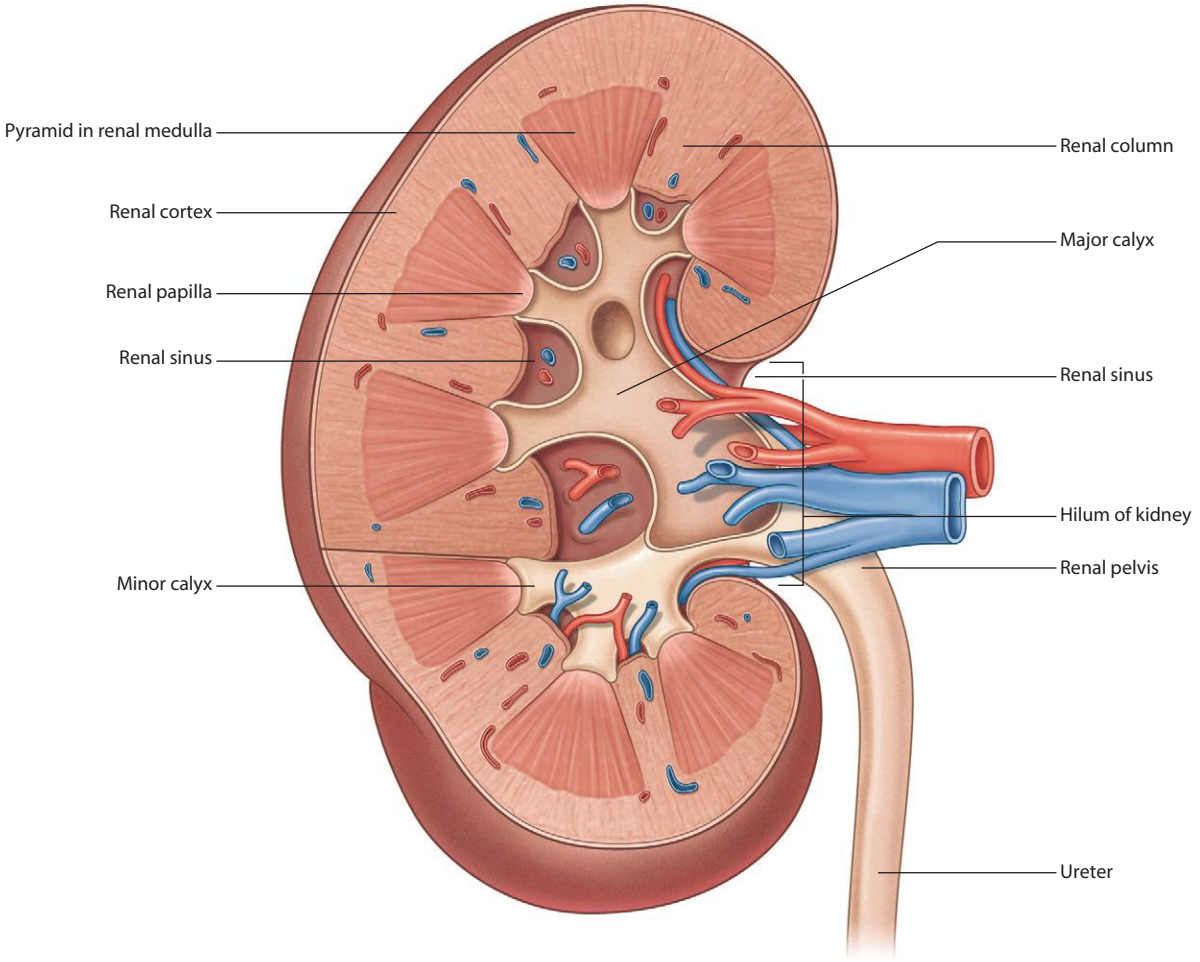

Internal structure of the right kidney

tahir99-VRG & vip.persianss.ir

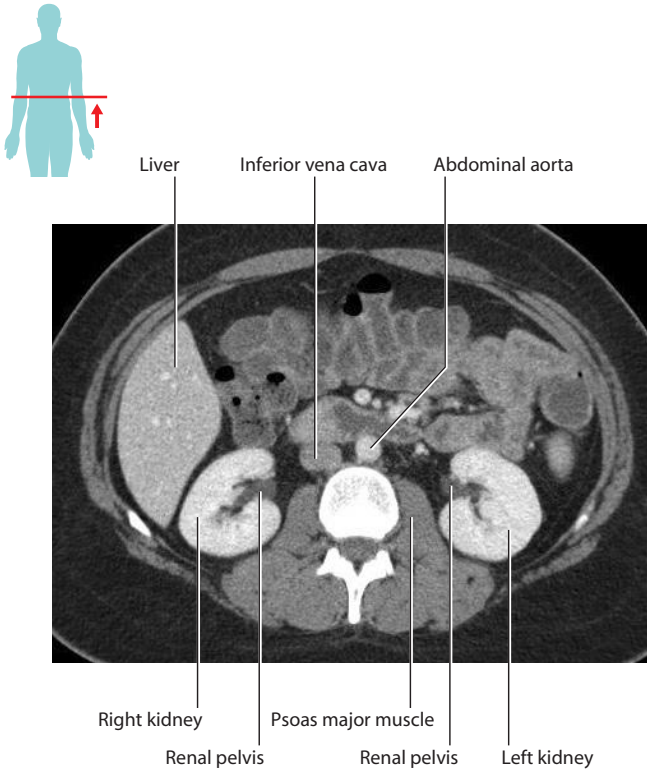

Renal pelvis.
CT image, with contrast, in axial plane

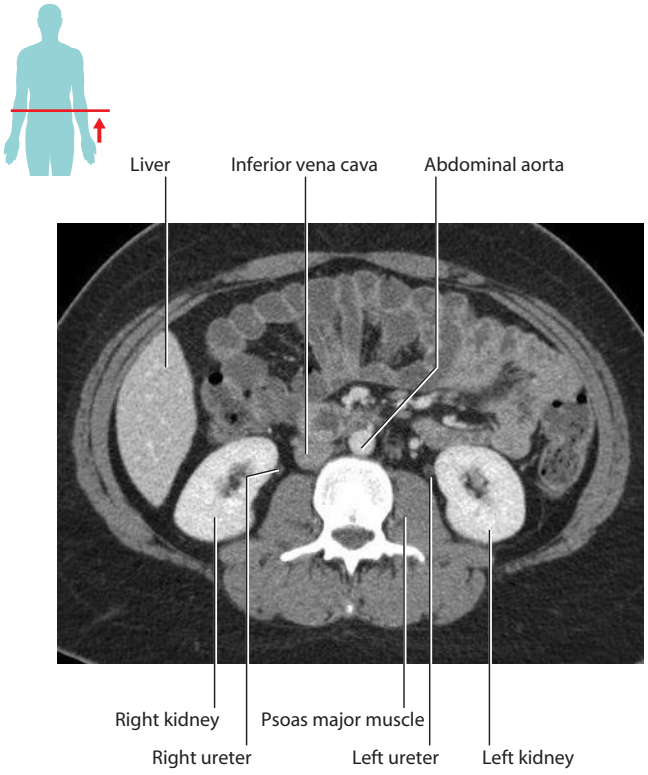

Location of ureters.
CT image, with contrast, in axial plane

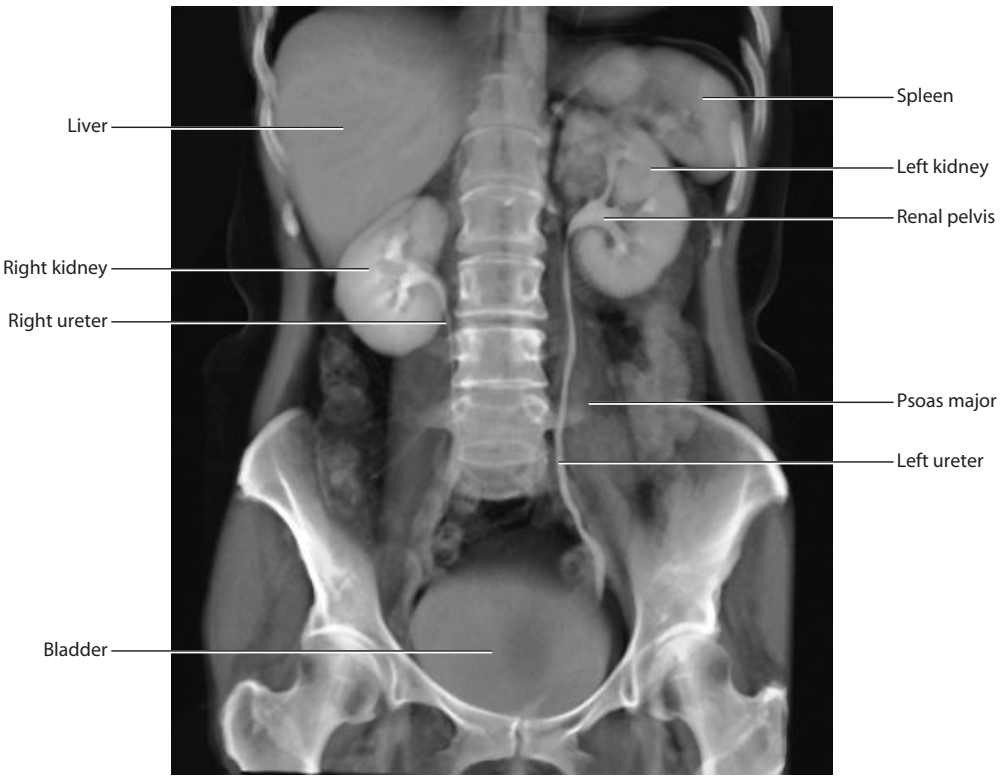

Pathway of ureter in relation to other structures.
Coronal view of 3-D urogram using multidetector computed tomography

tahir99-VRG & vip.persianss.ir

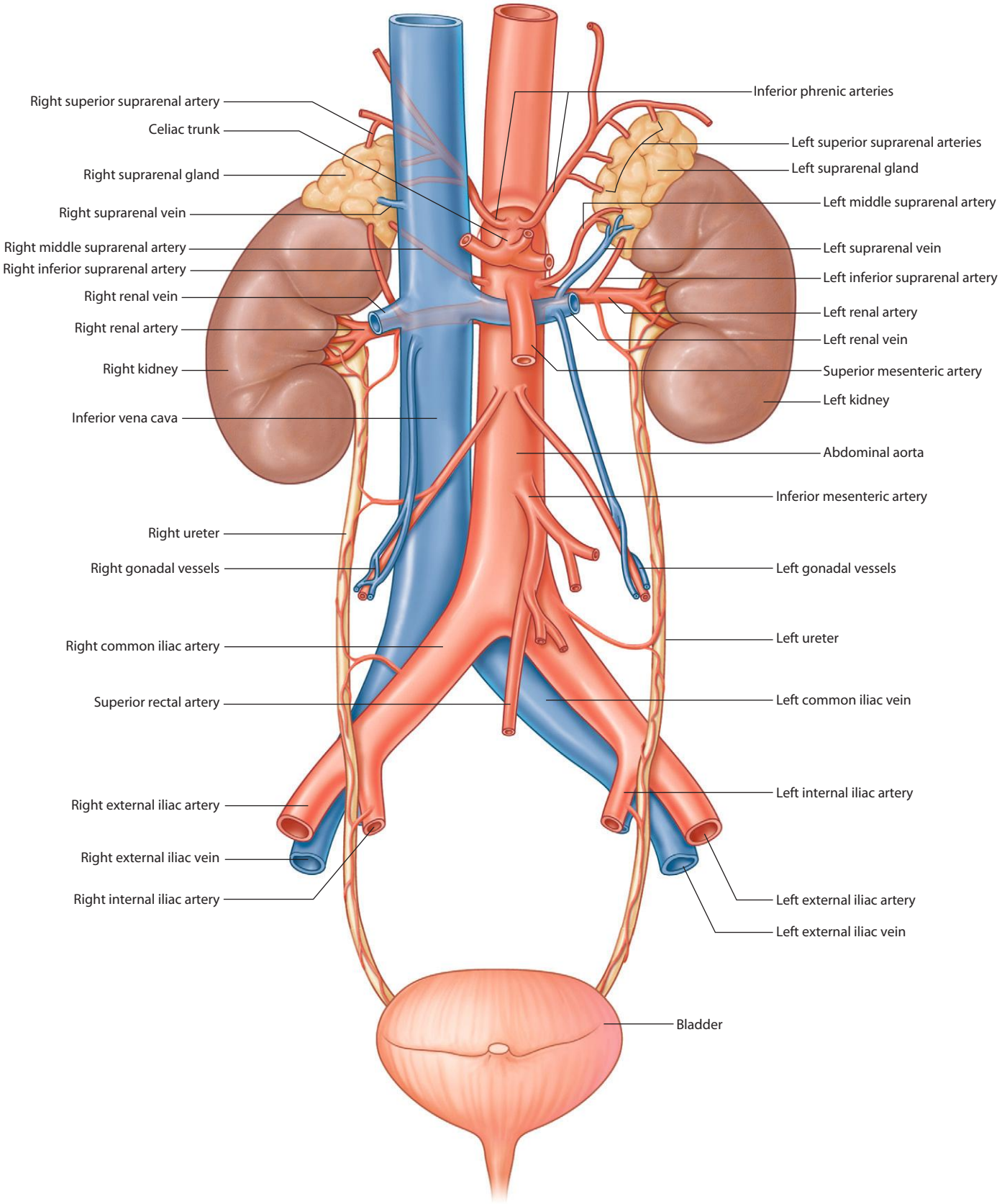

Vasculature relating to kidneys, suprarenal glands, and ureters

tahir99-VRG & vip.persianss.ir

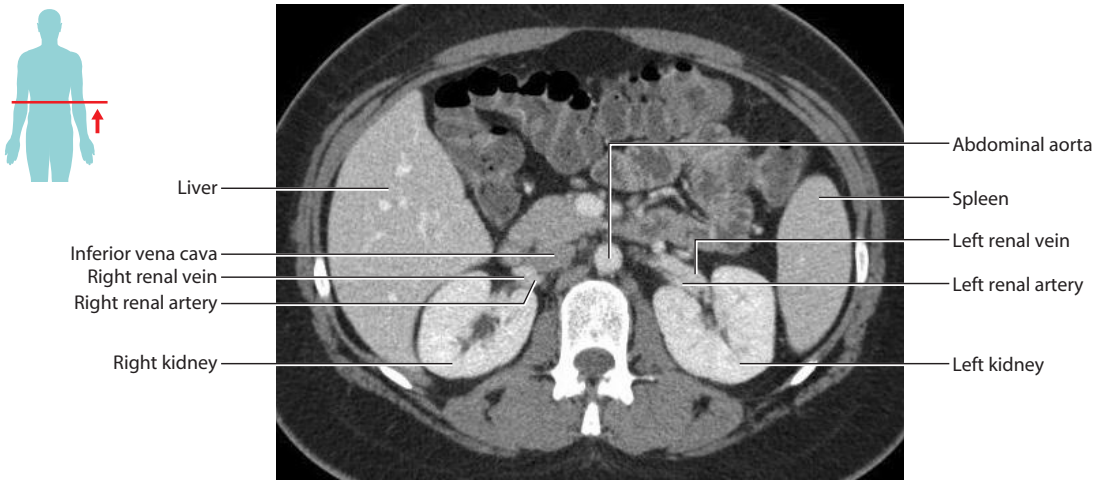

Renal vasculature.
CT image, with contrast, in axial plane

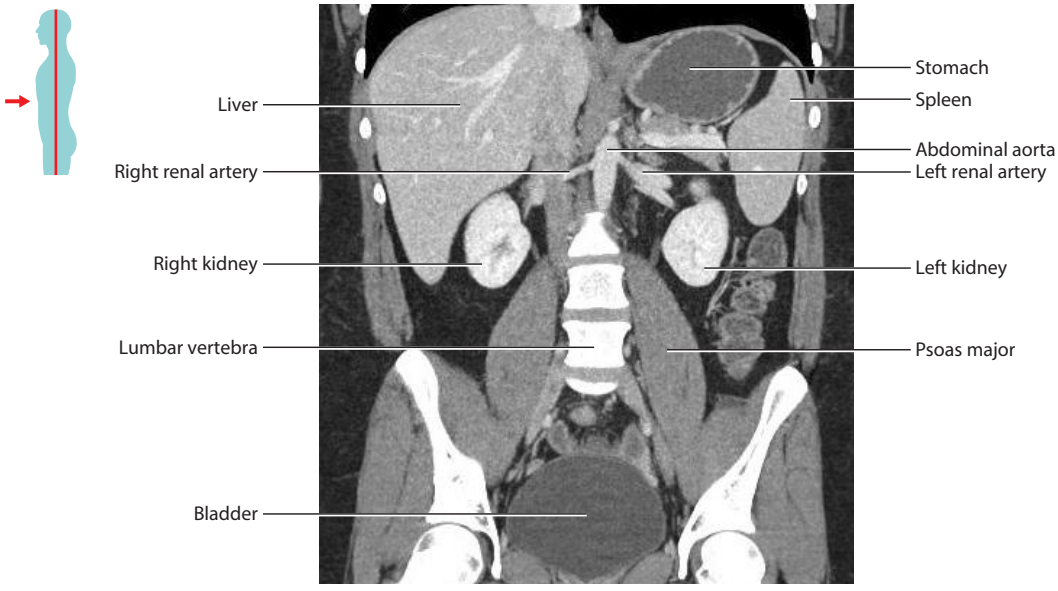

Renal arteries.
CT image, with contrast, in coronal plane

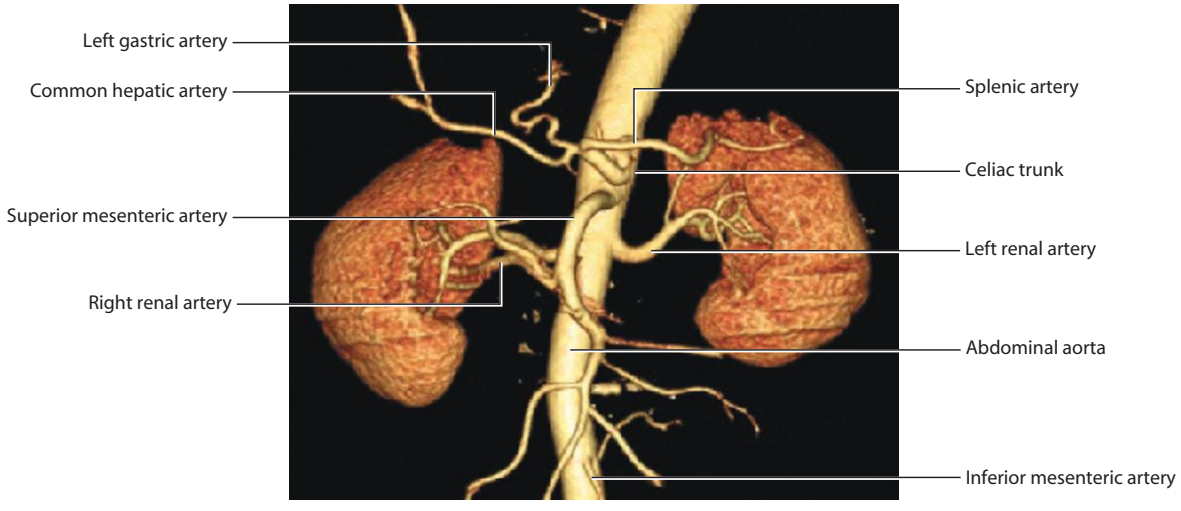

Renal arteries.
Volume-rendered anterior view using multidetector computer tomography

tahir99-VRG & vip.persianss.ir

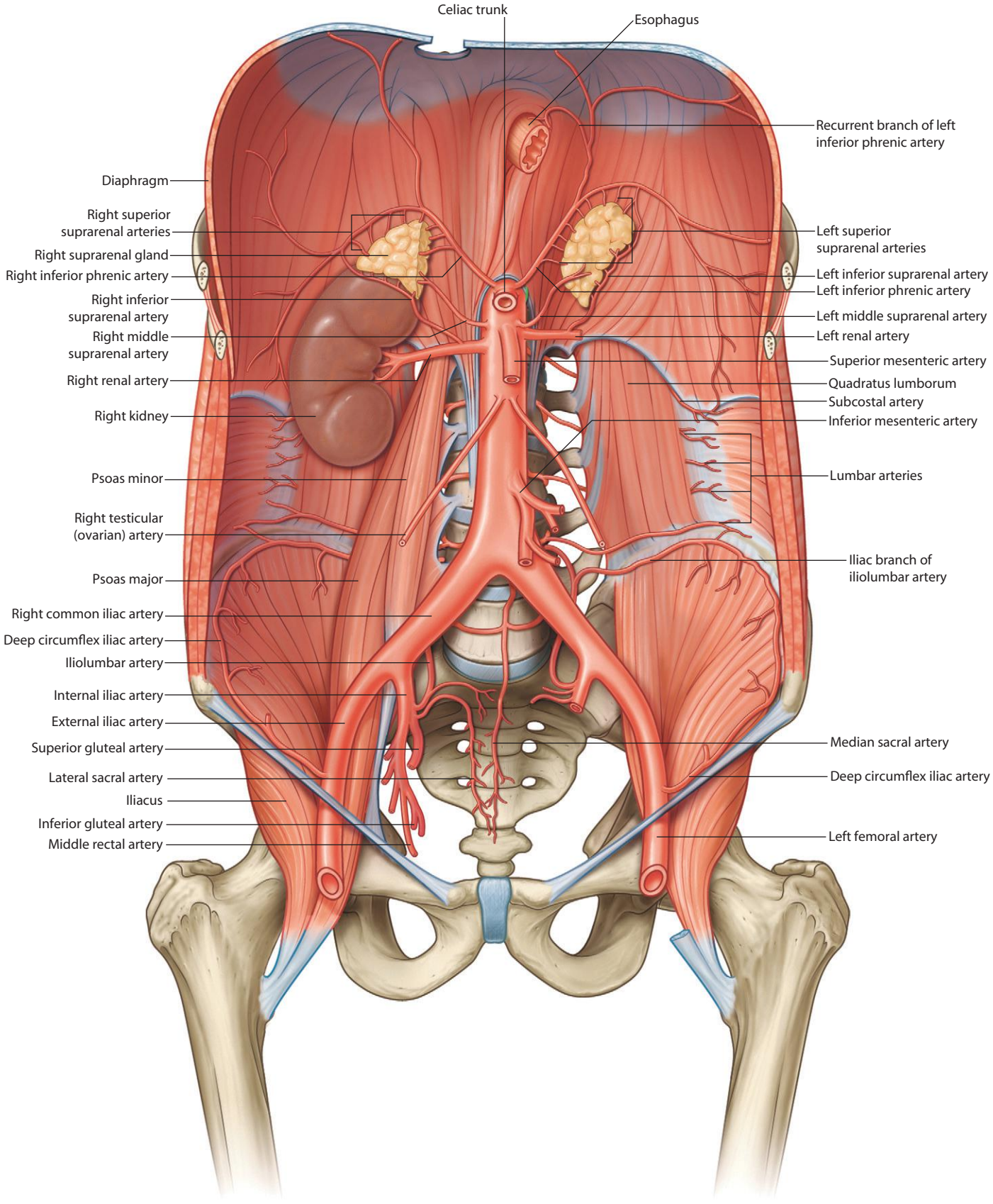

Abdominal aorta and branches

tahir99-VRG & vip.persianss.ir

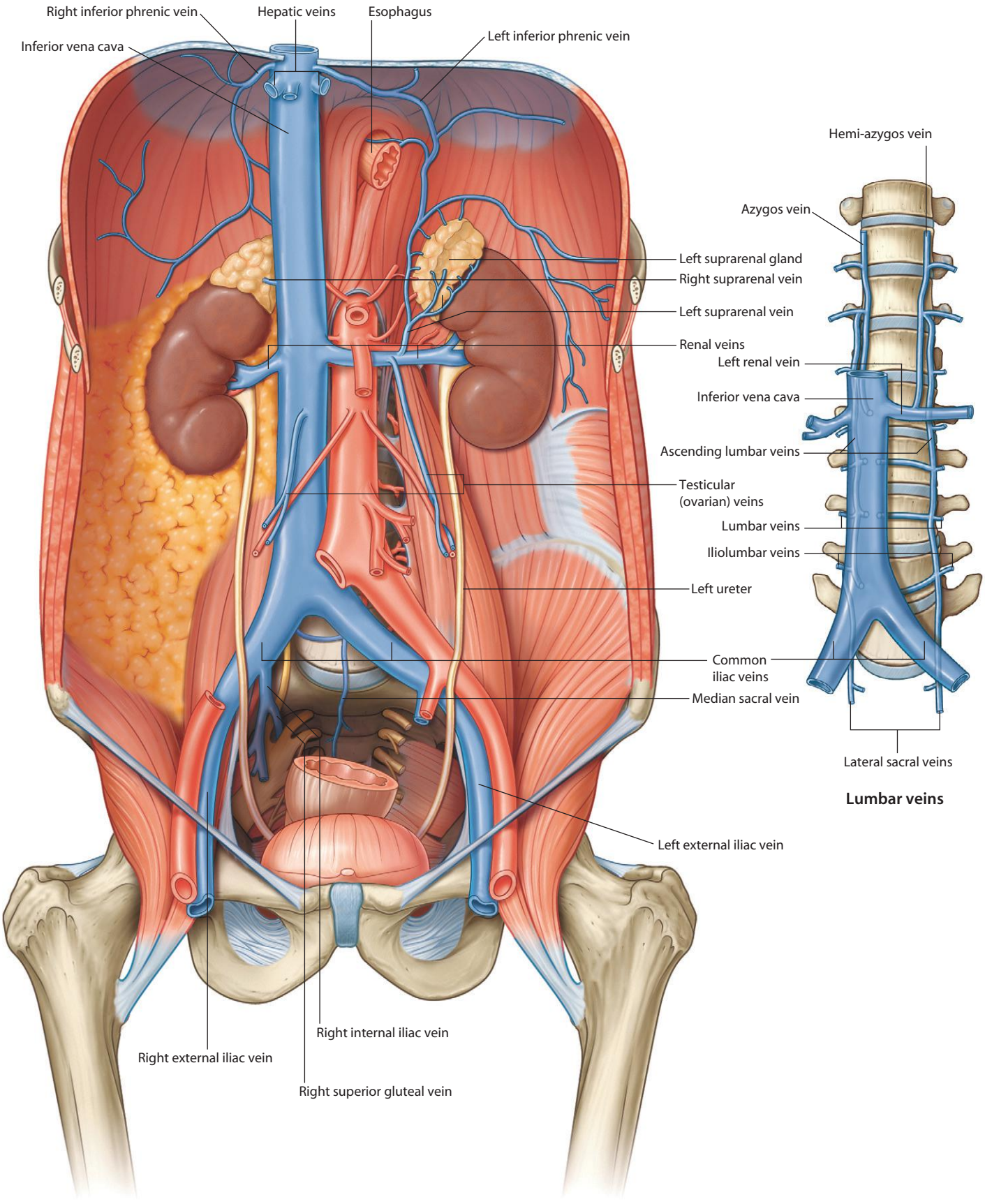

Lumbar veins

Inferior vena cava and tributaries

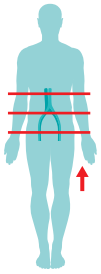

Abdominal aorta and inferior vena cava.
CT images, with contrast, in axial plane

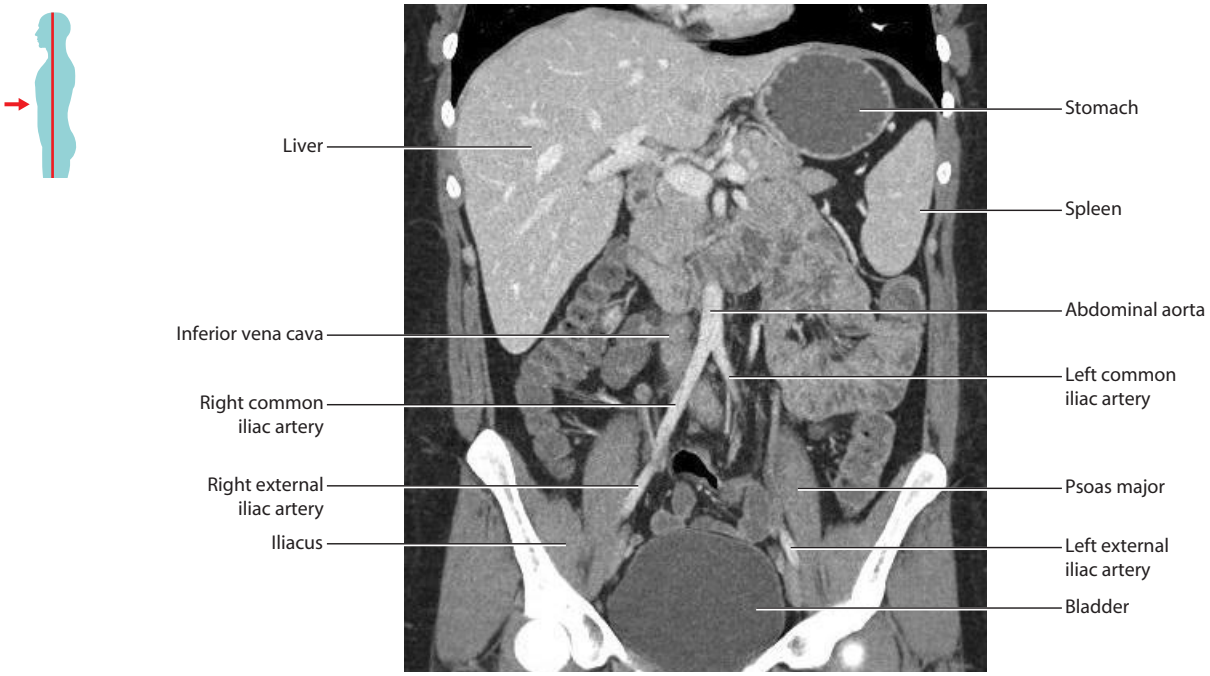

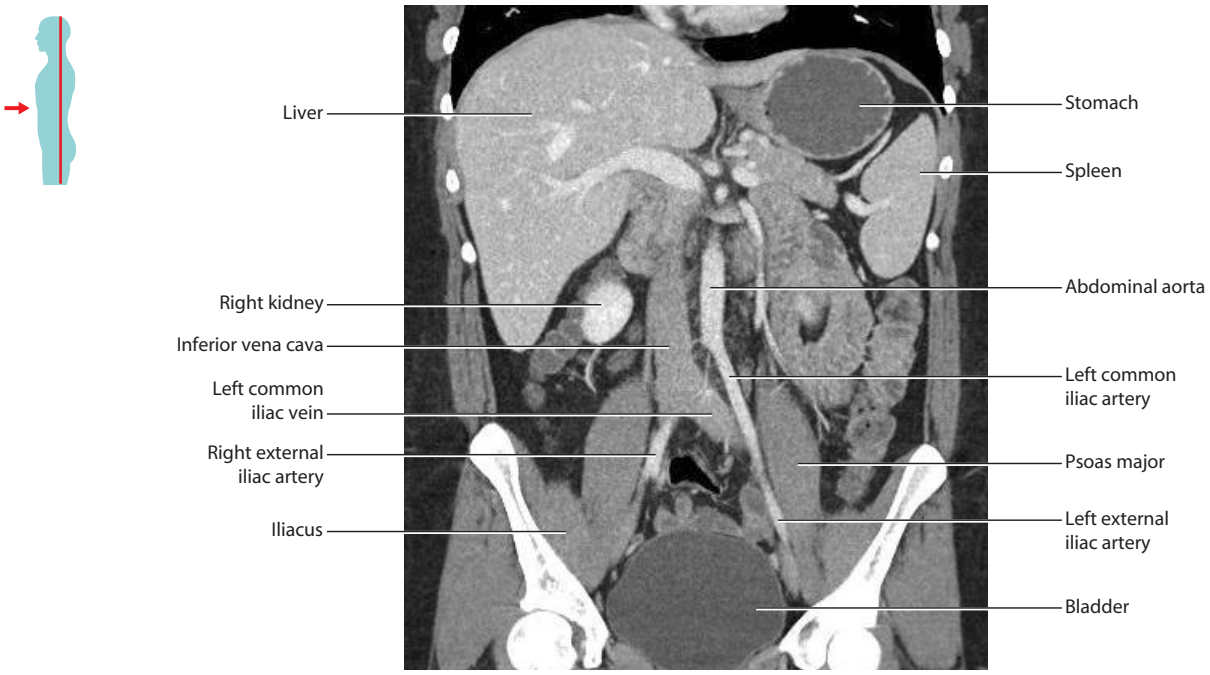

Positioning of the abdominal aorta and inferior vena cava in relation to other structures.
CT images, with contrast, in coronal plane

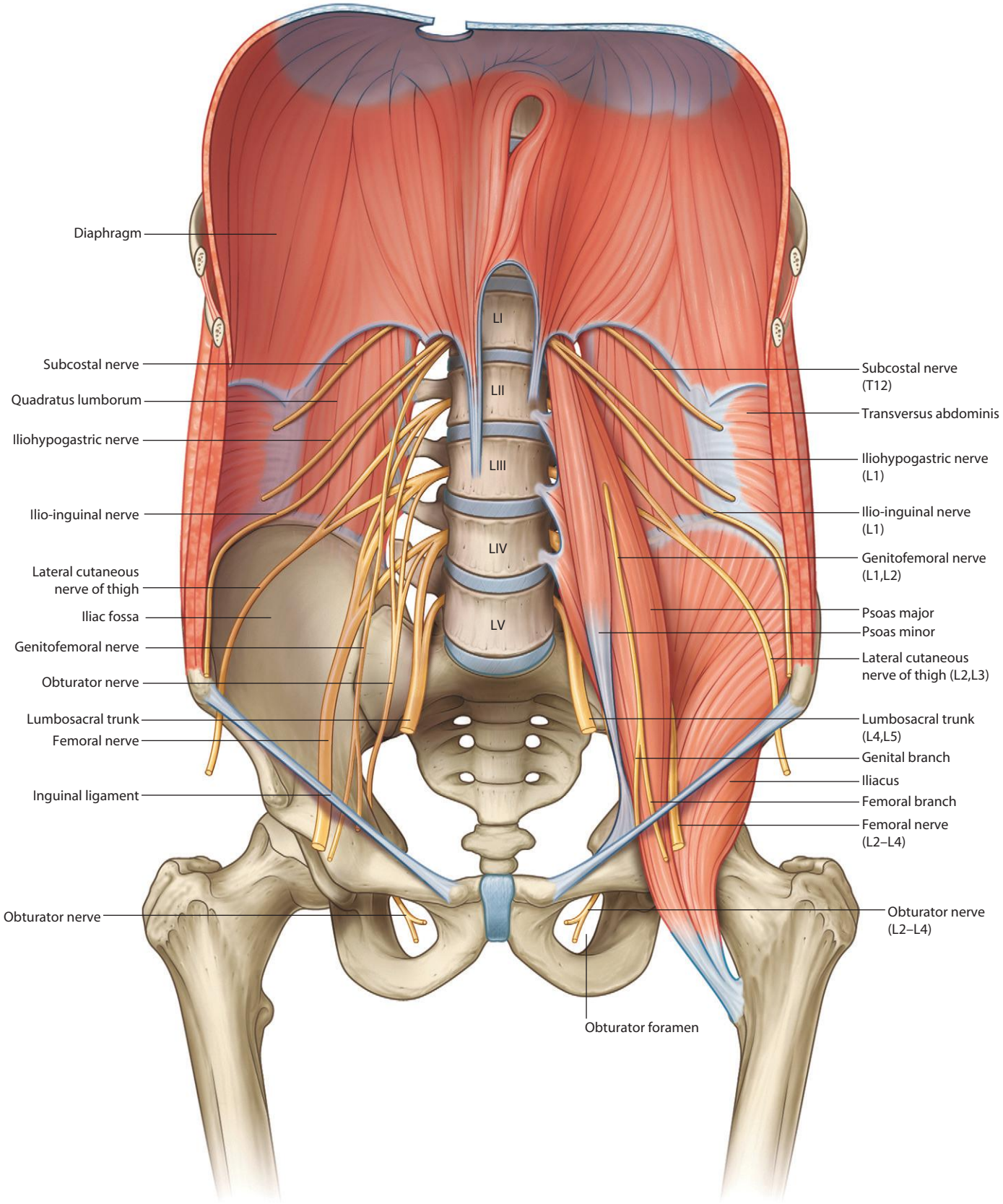

Lumbar plexus

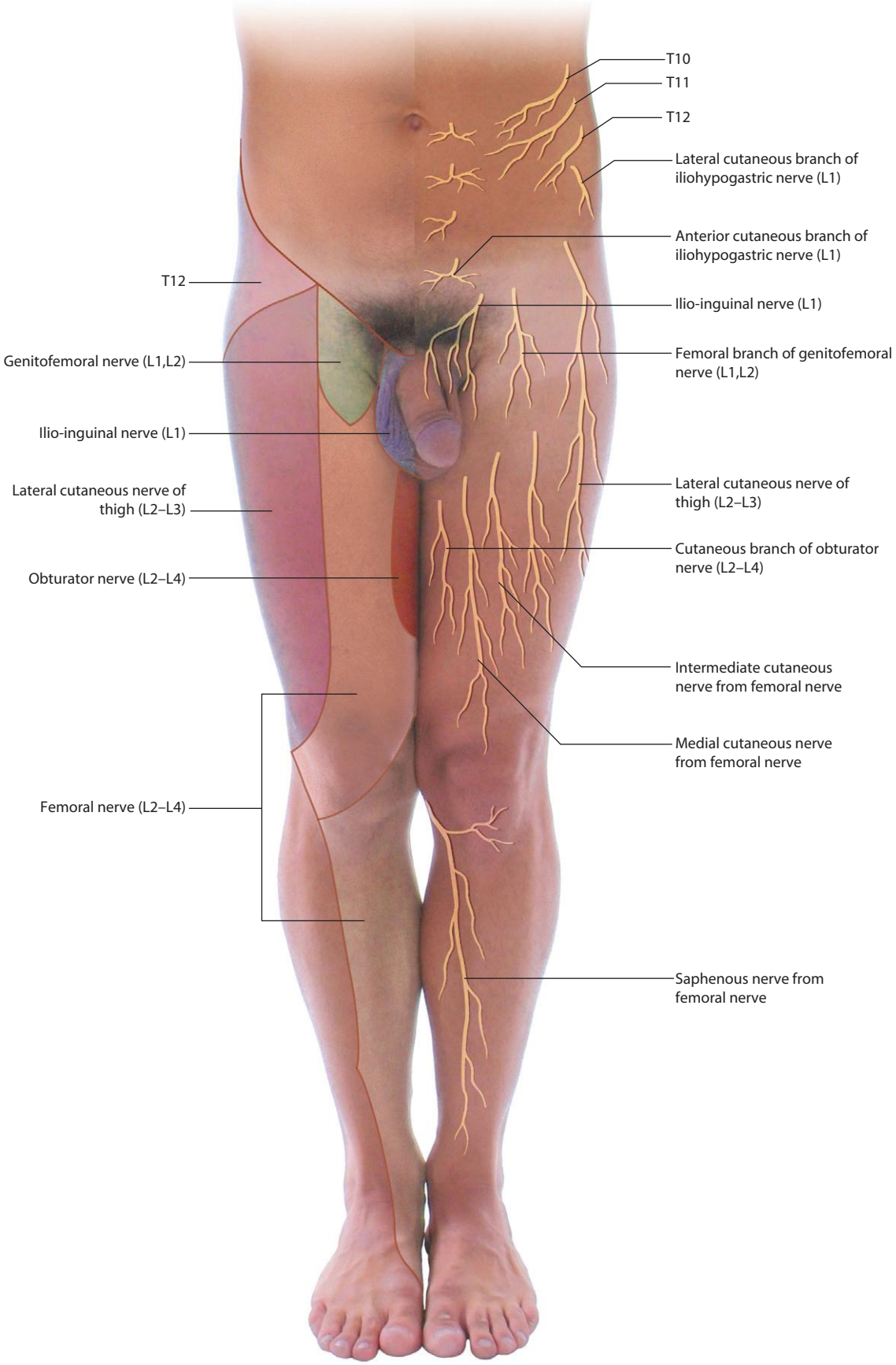

Cutaneous distribution of the nerves from the lumbar plexus

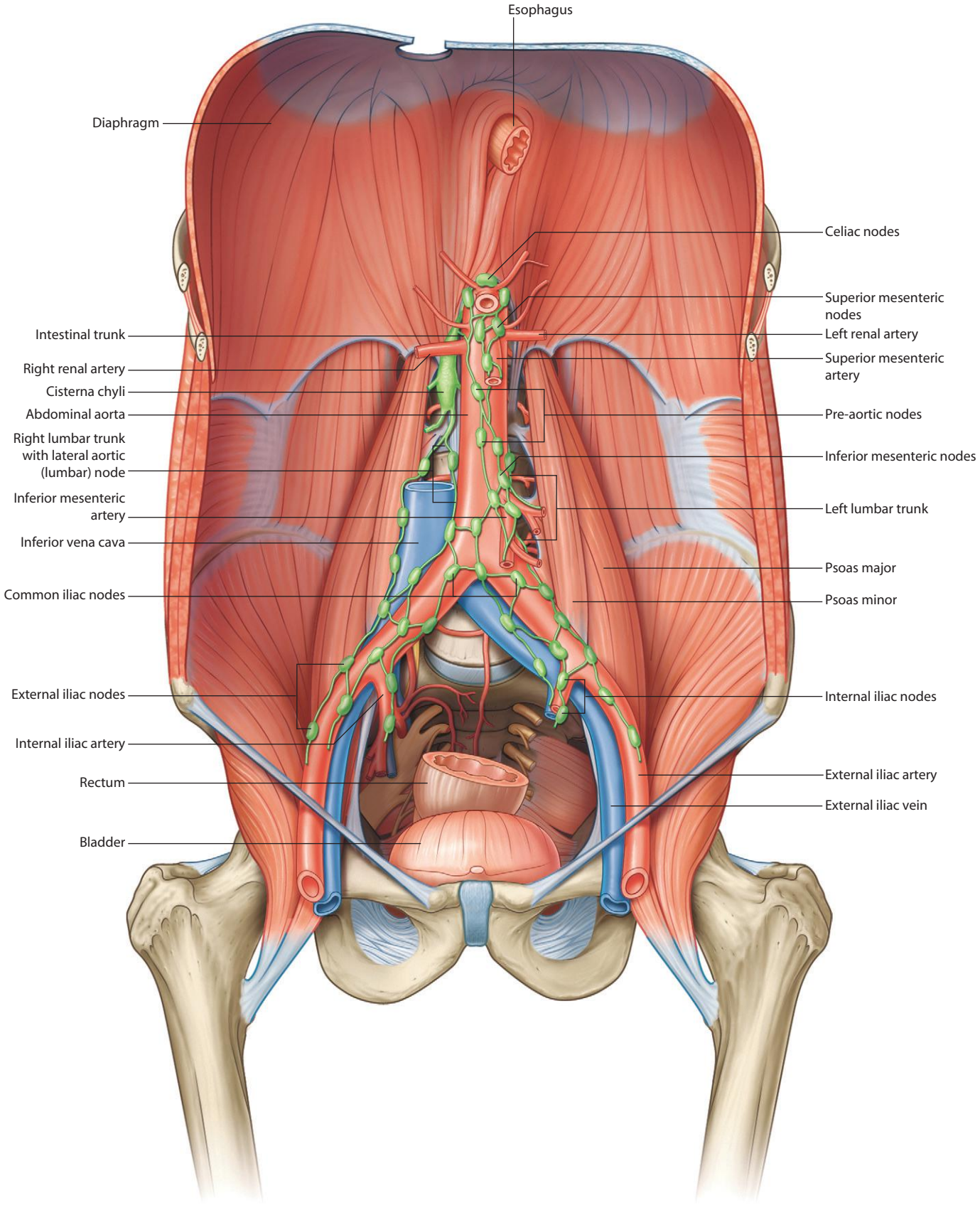

Abdominal lymphatics

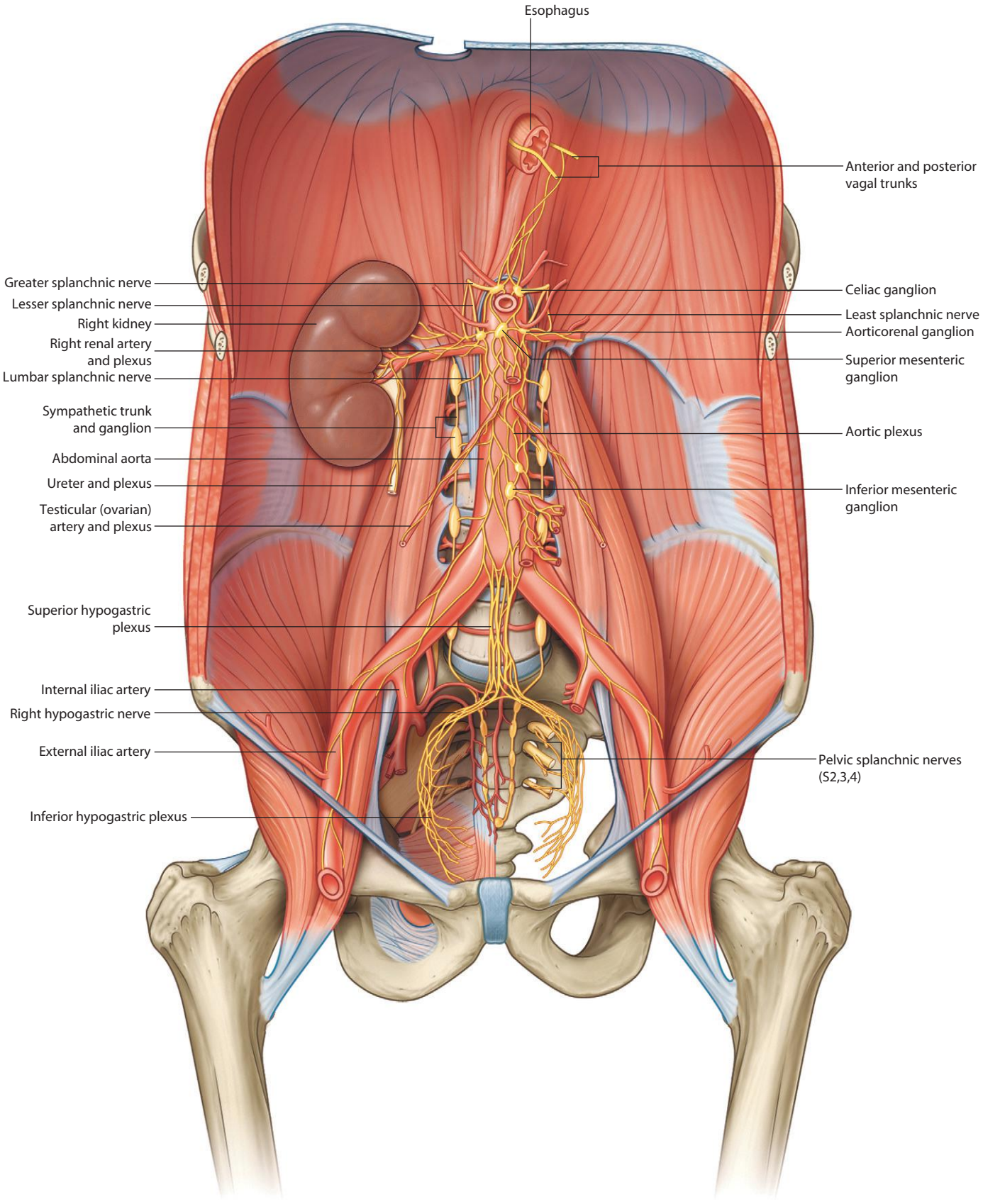

Prevertebral plexuses and ganglia with sympathetic trunks

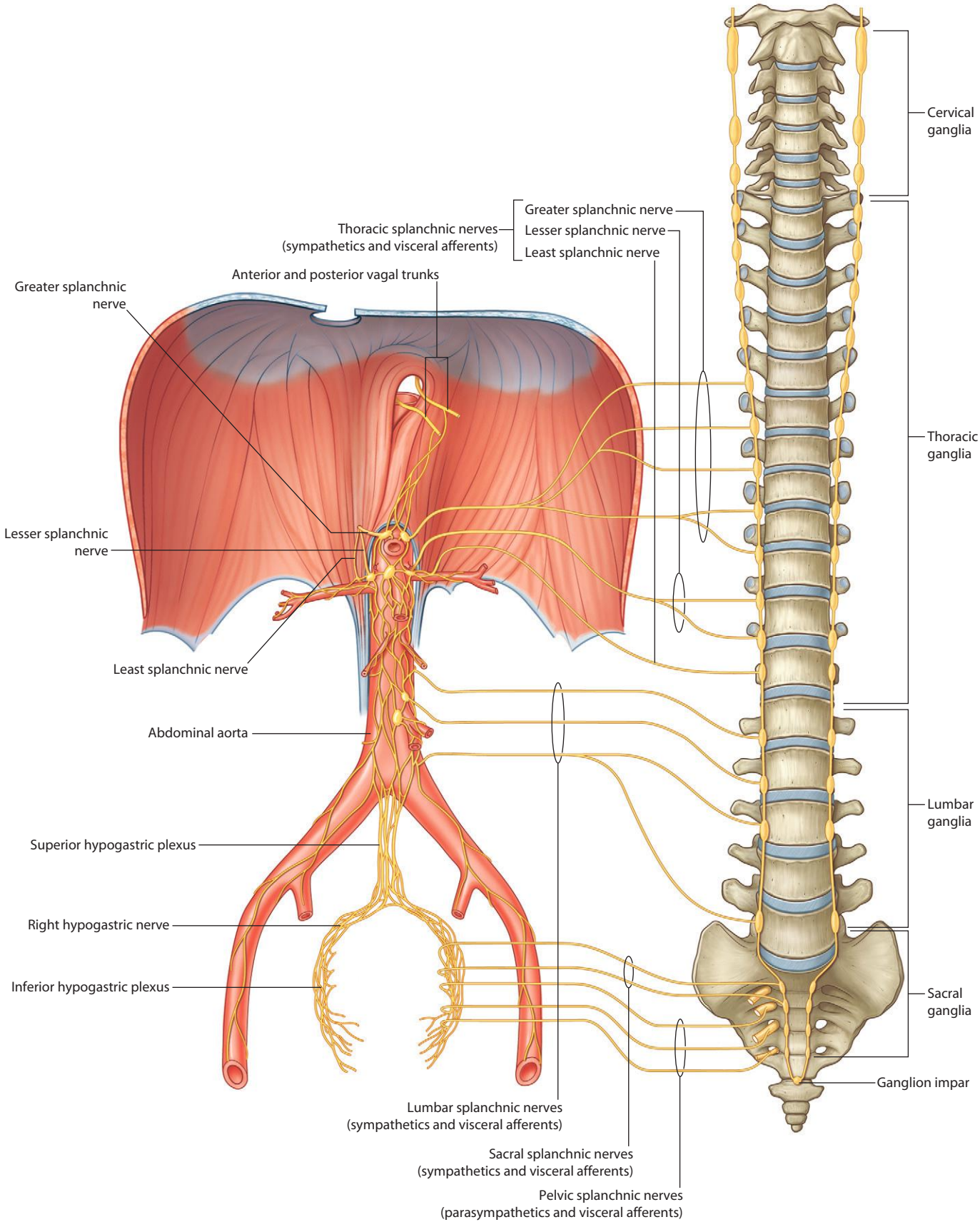

Splanchnic nerves

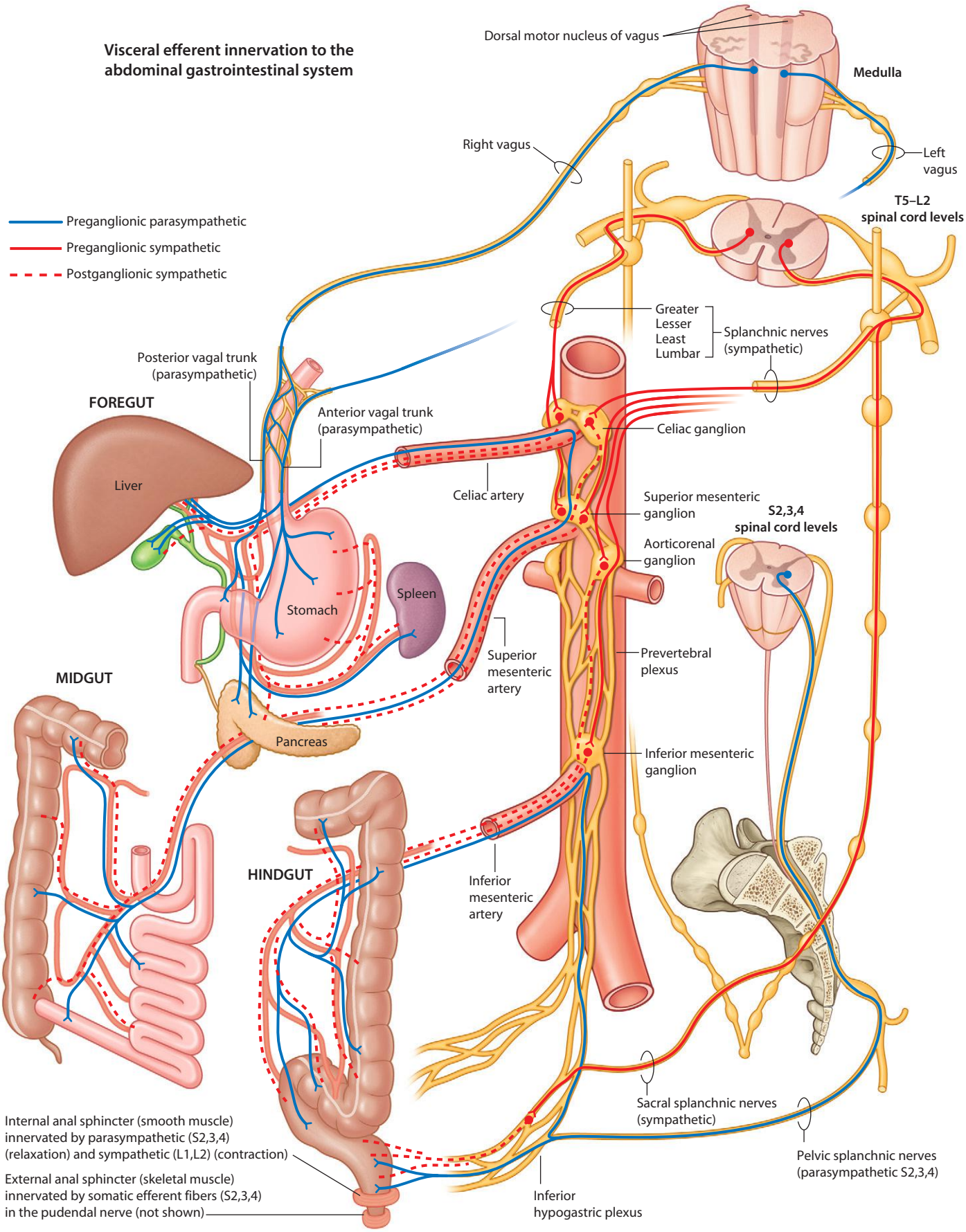
Visceral efferent innervation to the abdominal gastrointestinal system
Preganglionic parasympathetic
Preganglionic sympathetic
Postganglionic sympathetic
Dorsal motor nucleus of vagus
Medulla
Right vagus
Left vagus
T5–L2 spinal cord levels
Greater
Lesser
Least
Lumbar
Splanchnic nerves (sympathetic)
Posterior vagal trunk (parasympathetic)
Anterior vagal trunk (parasympathetic)
FOREGUT
Liver
Celiac ganglion
Celiac artery
Superior mesenteric ganglion
S2,3,4 spinal cord levels
Aorticorenal ganglion
Stomach
Spleen
Superior mesenteric artery
Prevertebral plexus
MIDGUT
Pancreas
Inferior mesenteric ganglion
HINDGUT
Inferior mesenteric artery
Sacral splanchnic nerves (sympathetic)
Pelvic splanchnic nerves (parasympathetic S2,3,4)
Internal anal sphincter (smooth muscle) innervated by parasympathetic (S2,3,4) (relaxation) and sympathetic (L1,L2) (contraction)
External anal sphincter (skeletal muscle) innervated by somatic efferent fibers (S2,3,4) in the pudendal nerve (not shown)
Inferior hypogastric plexus

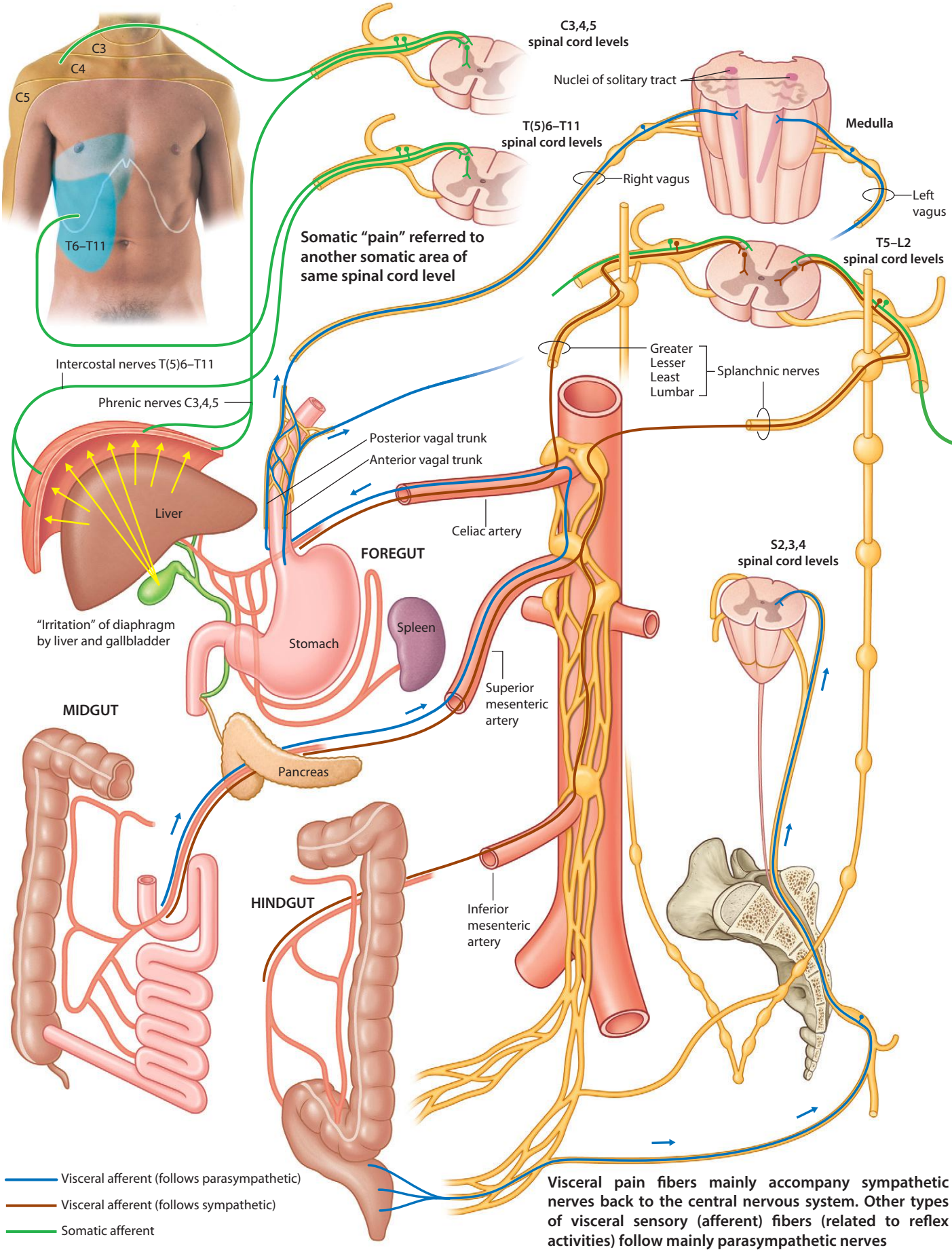

Visceral pain fibers mainly accompany sympathetic nerves back to the central nervous system. Other types of visceral sensory (afferent) fibers (related to reflex activities) follow mainly parasympathetic nerves

Visceral "pain" referred to somatic area innervated by same spinal cord level

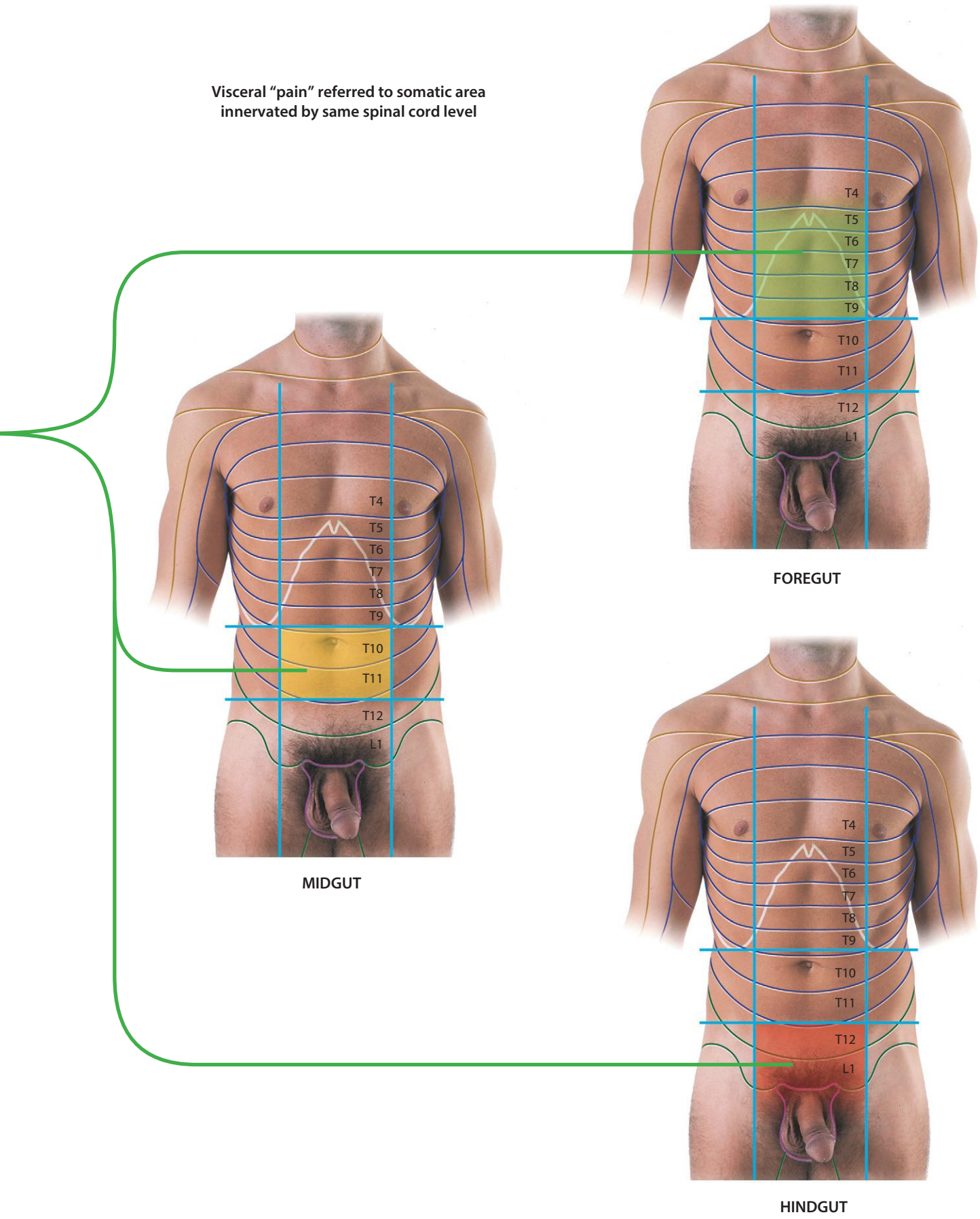

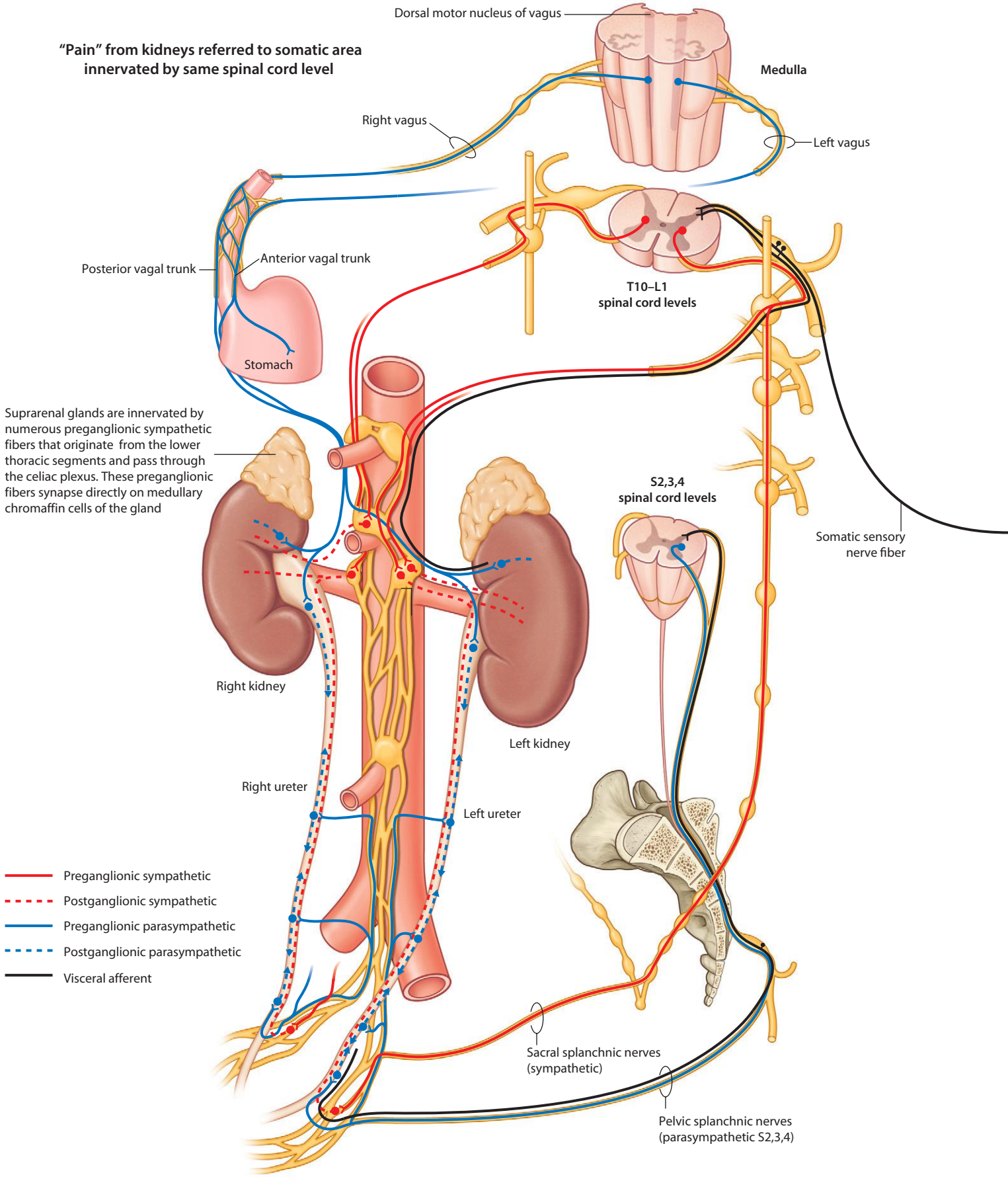
"Pain" from kidneys referred to somatic area innervated by same spinal cord level
Dorsal motor nucleus of vagus
Medulla
Right vagus
Left vagus
Posterior vagal trunk
Anterior vagal trunk
Stomach
T10–L1 spinal cord levels
Suprarenal glands are innervated by numerous preganglionic sympathetic fibers that originate from the lower thoracic segments and pass through the celiac plexus. These preganglionic fibers synapse directly on medullary chromaffin cells of the gland
S2,3,4 spinal cord levels
Somatic sensory nerve fiber
Right kidney
Left kidney
Right ureter
Left ureter
Preganglionic sympathetic
Postganglionic sympathetic
Preganglionic parasympathetic
Postganglionic parasympathetic
Visceral afferent
Sacral splanchnic nerves (sympathetic)
Pelvic splanchnic nerves (parasympathetic S2,3,4)

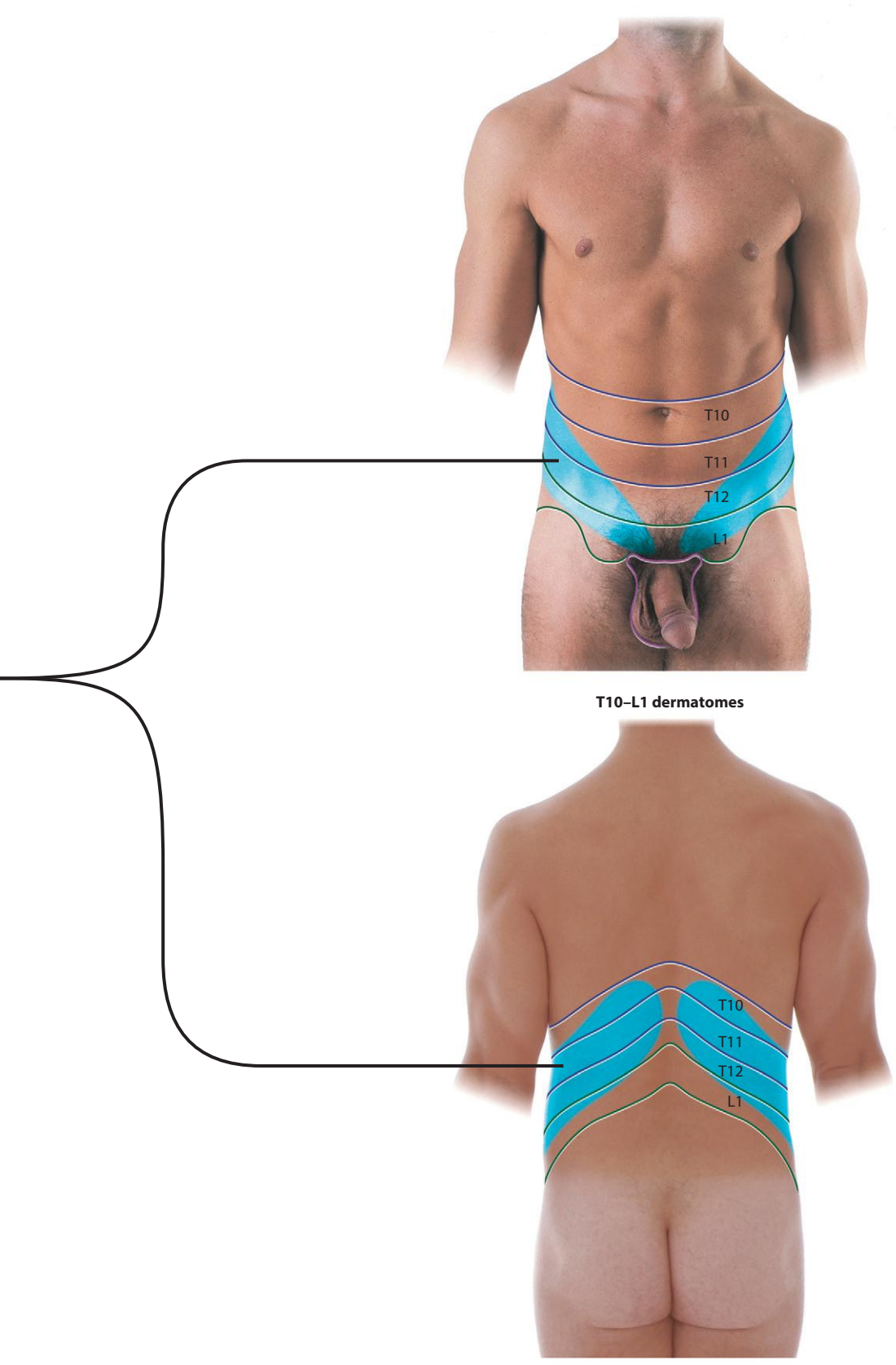

T10–L1 dermatomes

Pain fibers mainly follow sympathetic nerves to the central nervous system (CNS). This pain is 'referred' by the CNS to the somatic area innervated by the same spinal levels. Other types of visceral afferent (sensory) fibers (related to reflex activities) follow mainly parasympathetic nerves

Abdominal wall muscles

Muscle		Origin	Insertion	Innervation	Function
External oblique	1	Muscular slips from the outer surfaces of the lower eight ribs (ribs V to XII)	Lateral lip of iliac crest; aponeurosis ending in midline raphe (linea alba)	Anterior rami of lower six thoracic spinal nerves (T7 to T12)	Compress abdominal contents; both muscles flex trunk; each muscle bends trunk to same side, turning anterior part of abdomen to opposite side
Internal oblique	2	Thoracolumbar fascia; iliac crest between origins of external and transversus; lateral two thirds of inguinal ligament	Inferior border of the lower three or four ribs; aponeurosis ending in linea alba; pubic crest and pectineal line	Anterior rami of lower six thoracic spinal nerves (T7 to T12) and L1	Compress abdominal contents; both muscles flex trunk; each muscle bends trunk and turns anterior part of abdomen to same side
Transversus abdominis	3	Thoracolumbar fascia; medial lip of iliac crest; lateral one third of inguinal ligament; costal cartilages lower six ribs (ribs VII to XII)	Aponeurosis ending in linea alba; pubic crest and pectineal line	Anterior rami of lower six thoracic spinal nerves (T7 to T12) and L1	Compress abdominal contents
Rectus abdominis	4	Pubic crest, pubic tubercle, and pubic symphysis	Costal cartilages of ribs V to VII; xiphoid process	Anterior rami of lower seven thoracic spinal nerves (T7 to T12)	Compress abdominal contents; flex vertebral column; tense abdominal wall
Pyramidalis	5	Front of pubis and pubic symphysis	Into linea alba	Anterior ramus of T12	Tenses the linea alba

Posterior abdominal wall muscles

Psoas major	6	Lateral surface of bodies of TXII and LI to LV vertebrae, transverse processes of the lumbar vertebrae, and the intervertebral discs between TXII and LI to LV vertebrae	Lesser trochanter of the femur	Anterior rami of L1 to L3	Flexion of thigh at hip joint
Psoas minor	7	Lateral surface of bodies of TXII and LI vertebrae and intervening intervertebral disc	Pectineal line of the pelvic brim and iliopubic eminence	Anterior rami of L1	Weak flexion of lumbar vertebral column
Quadratus lumborum	8	Transverse process of LV vertebra, iliolumbar ligament, and iliac crest	Transverse processes of LI to LIV vertebrae and inferior border of rib XII	Anterior rami of T12 and L1 to L4	Depress and stabilize rib XII and some lateral bending of trunk
Iliacus	9	Upper two thirds of iliac fossa, anterior sacro-iliac and iliolumbar ligaments, and upper lateral surface of sacrum	Lesser trochanter of femur	Femoral nerve (L2 to L4)	Flexion of thigh at hip joint

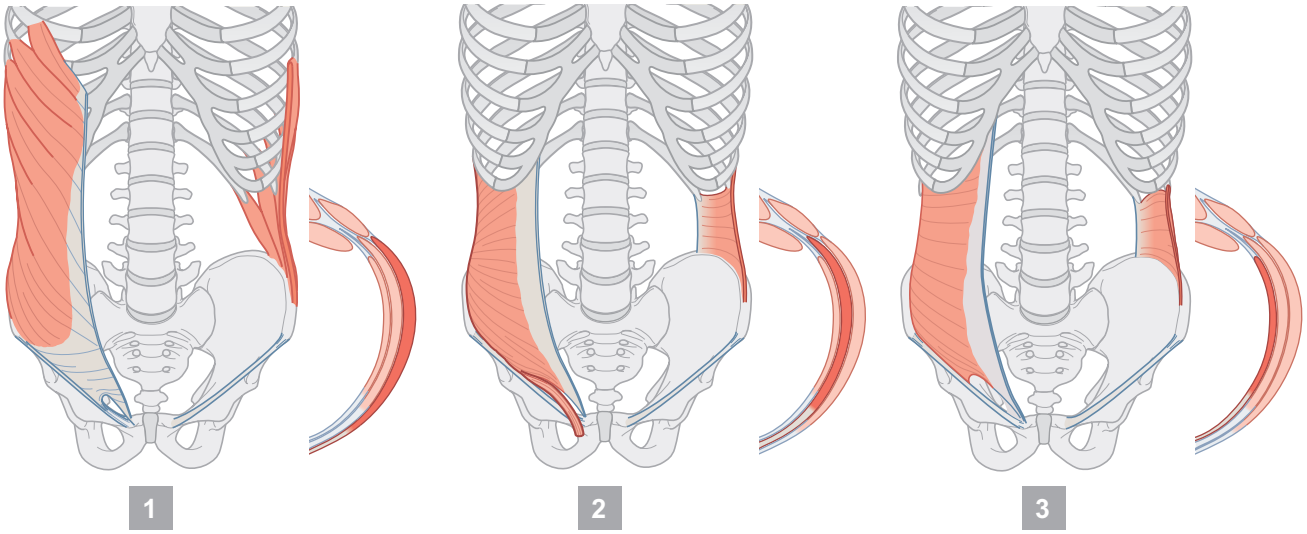
1
2
3

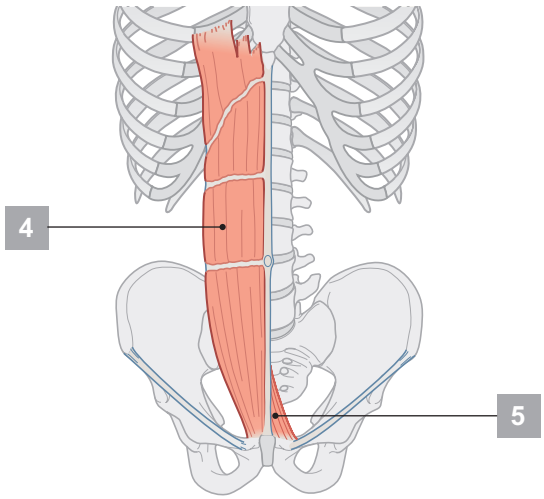
4
5

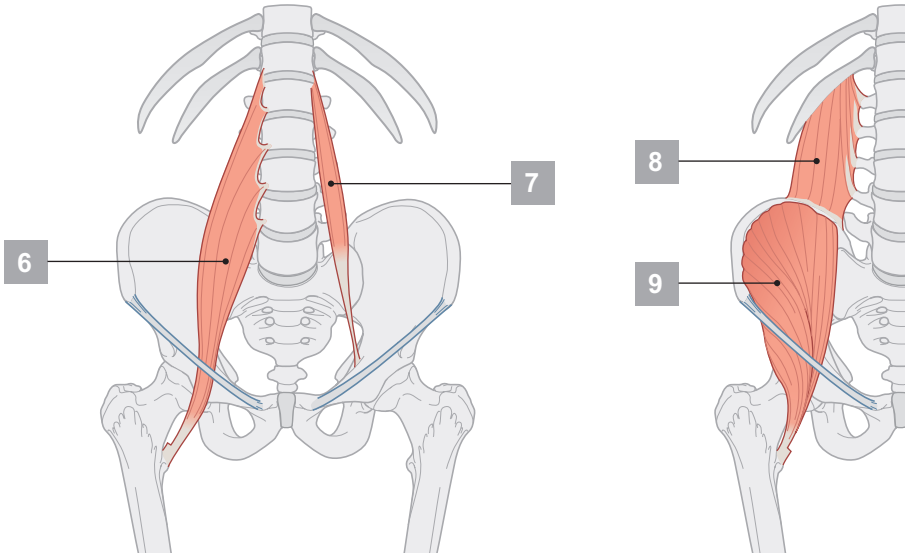
6
7
8
9

Branches of the abdominal aorta

Artery		Branch	Origin	Parts supplied
Celiac trunk	1	Anterior	Immediately inferior to the aortic hiatus of the diaphragm	Abdominal foregut
Superior mesenteric artery	2	Anterior	Immediately inferior to the celiac trunk	Abdominal midgut
Inferior mesenteric artery	3	Anterior	Inferior to the renal arteries	Abdominal hindgut
Middle suprarenal arteries	4	Lateral	Immediately superior to the renal arteries	Suprarenal glands
Renal arteries	5	Lateral	Immediately inferior to the superior mesenteric artery	Kidneys
Testicular or ovarian arteries	6	Paired anterior	Inferior to the renal arteries	Testes in male and ovaries in female
Inferior phrenic arteries	7	Lateral	Immediately inferior to the aortic hiatus	Diaphragm
Lumbar arteries	8	Posterior	Usually four pairs	Posterior abdominal wall and spinal cord
Median sacral artery	9	Posterior	Just superior to the aortic bifurcation, passes inferiorly across lumbar vertebrae, sacrum, and coccyx	
Common iliac arteries	10	Terminal	Bifurcation usually occurs at the level of LIV vertebra	

Branches of the lumbar plexus

Branch		Origin	Spinal segments	Function: motor	Function: sensory
Iliohypogastric	1	Anterior ramus L1	L1	Internal oblique and transversus abdominis	Posterolateral gluteal skin and skin in pubic region
Ilio-inguinal	2	Anterior ramus L1	L1	Internal oblique and transversus abdominis	Skin in the upper medial thigh, and either the skin over the root of the penis and anterior scrotum or the mons pubis and labium majus
Genitofemoral	3	Anterior rami L1 and L2	L1, L2	Genital branch—male cremasteric muscle	Genital branch—skin of anterior scrotum or skin of mons pubis and labium majus; femoral branch—skin of upper anterior thigh
Lateral cutaneous nerve of thigh	4	Anterior rami L2 and L3	L2, L3		Skin on anterior and lateral thigh to the knee
Obturator	5	Anterior rami L2 to L4	L2 to L4	Obturator externus, pectineus, and muscles in medial compartment of thigh	Skin on medial aspect of the thigh
Femoral	6	Anterior rami L2 to L4	L2 to L4	Iliacus, pectineus, and muscles in anterior compartment of thigh	Skin on anterior thigh and medial surface of leg

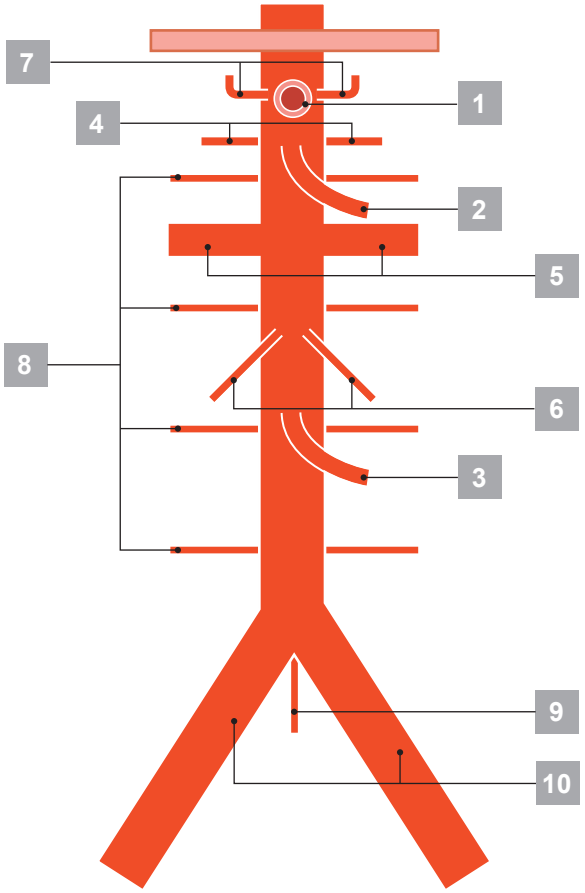
7
4
1
2
5
8
6
3
9
10

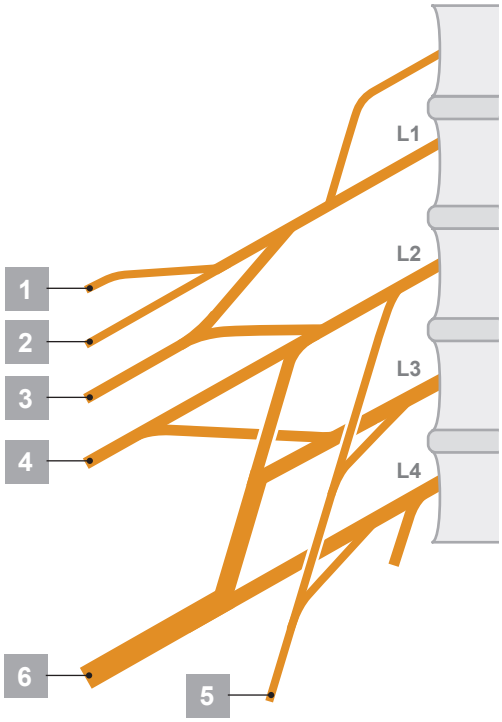
L1
L2
L3
L4
1
2
3
4
6
5

This page intentionally left blank

5

CONTENTS

PELVIS AND PERINEUM

Surface anatomy and articulated pelvis in men **212**
Surface anatomy and articulated pelvis in women **214**
Pelvic girdle **216**
Pelvic girdle: imaging **217**
Lumbosacral joint **218**
Sacro-iliac joint **219**
Pelvic inlet and outlet **220**
Orientation of pelvic girdle and pelvic brim **221**
Pelvic viscera and perineum in men **222**
Pelvic viscera and perineum in men: imaging **223**
Pelvic viscera and perineum in women **224**
Pelvic viscera and perineum in women: imaging **225**
Lateral wall of pelvic cavity **226**
Floor of pelvic cavity: pelvic diaphragm **227**
Rectum and bladder in situ **230**
Rectum **231**
Bladder in men **232**
Bladder in women **233**
Reproductive system in men **234**
Prostate **235**
Prostate and seminal vesicles **237**
Scrotum **238**
Testes **239**
Penis **240**
Reproductive system in women **241**
Uterus and ovaries **242**
Uterus **243**
Uterus: imaging **244**
Pelvic fascia **245**
Arterial supply of pelvis **246**
Venous drainage of pelvis **247**
Vasculature of the pelvic viscera **248**
Vasculature of uterus **249**
Venous drainage of prostate and penis **250**
Venous drainage of rectum **251**
Sacral and coccygeal nerve plexuses **252**
Pelvic nerve plexus **253**
Hypogastric plexus **254**
Surface anatomy of the perineum **255**
Borders and ceiling of the perineum **258**
Deep pouch and perineal membrane **259**
Muscles and erectile tissues in men **260**
Erectile tissue in men: imaging **261**
Muscles and erectile tissues in women **262**
Erectile tissue in women: imaging **263**
Internal pudendal artery and vein **264**
Pudendal nerve **265**
Vasculature of perineum **266**
Nerves of perineum **267**
Lymphatics of pelvis and perineum in men **268**
Lymphatics of pelvis and perineum in women **269**
Lymphatics **270**
Dermatomes **271**
Innervation of reproductive system in men **272**
Innervation of reproductive system in women **273**
Innervation of bladder **274**
Pelvic cavity imaging in men **275**
Pelvic cavity imaging in women **278**
Tables **284**

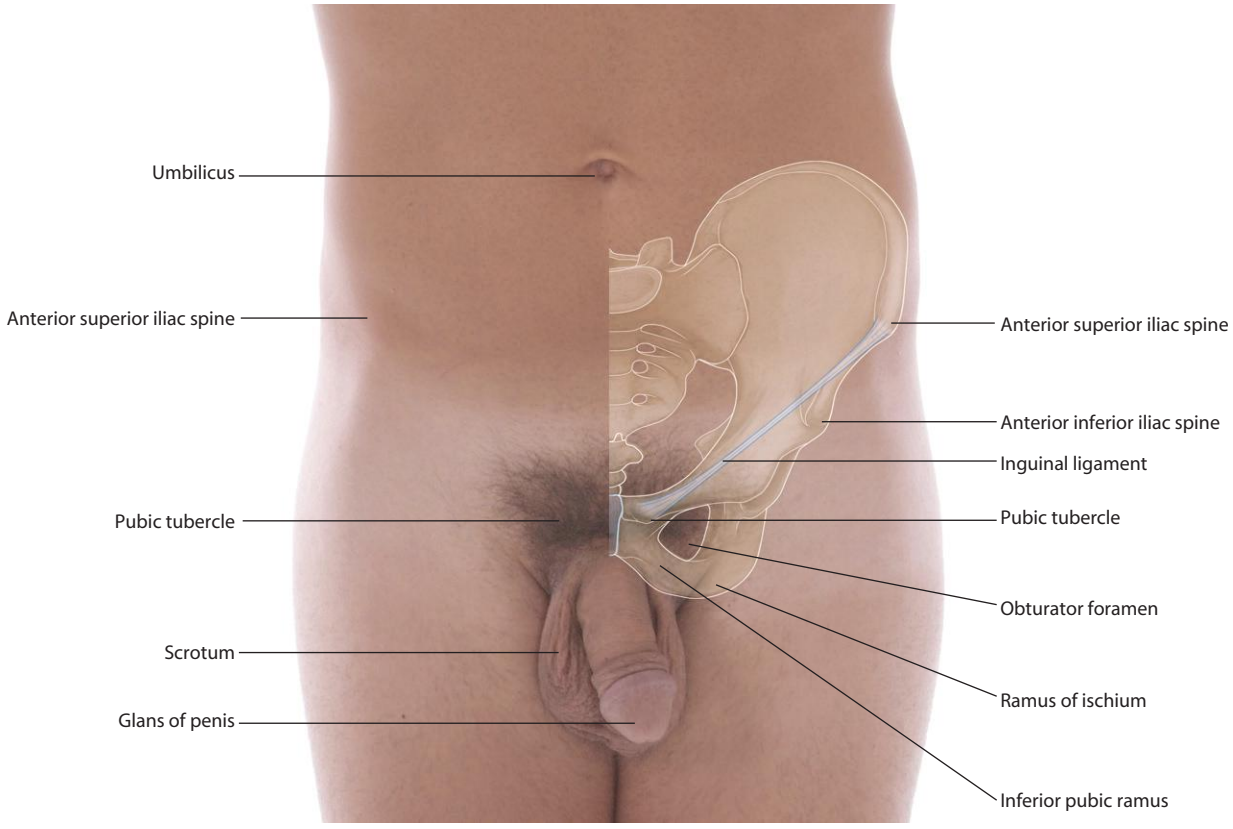

Surface anatomy with bones (anterior view)

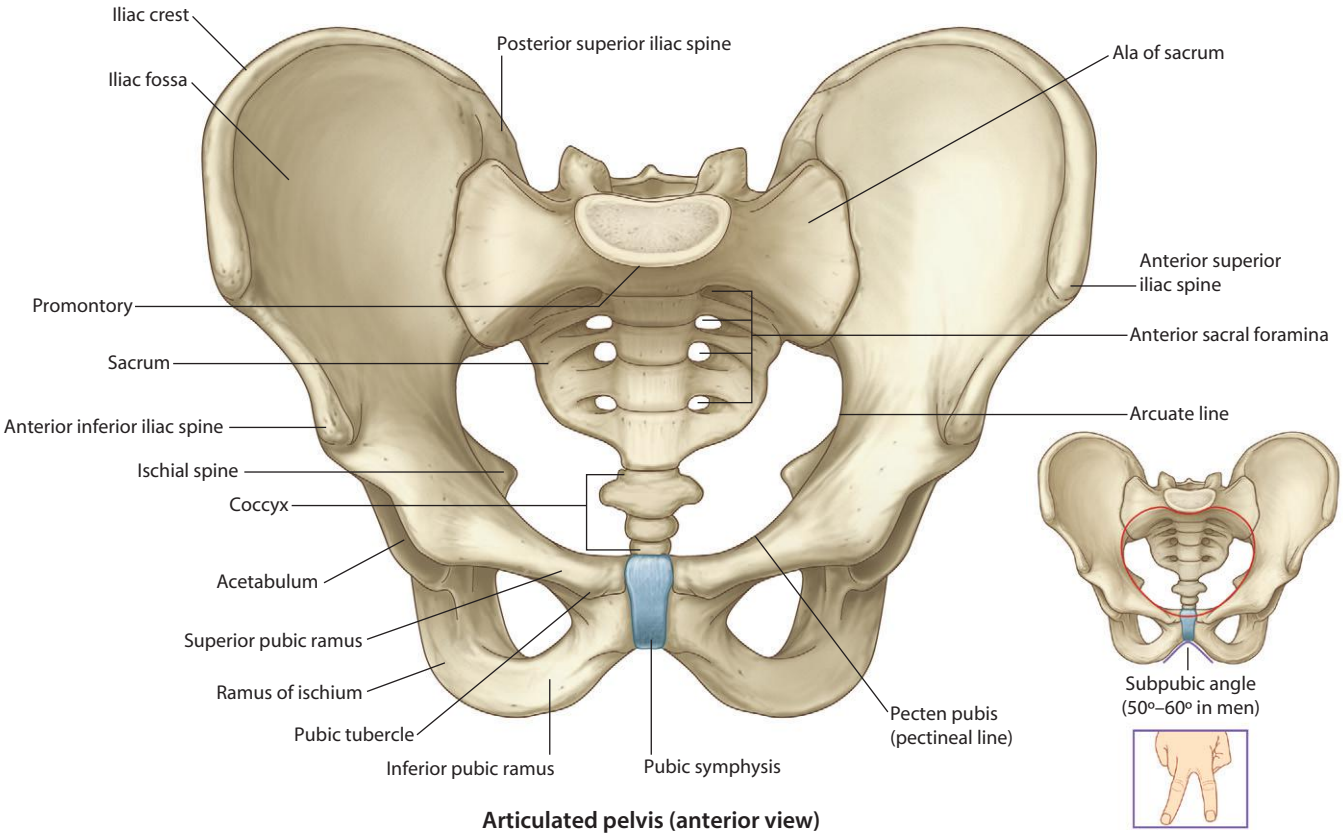

Articulated pelvis (anterior view)

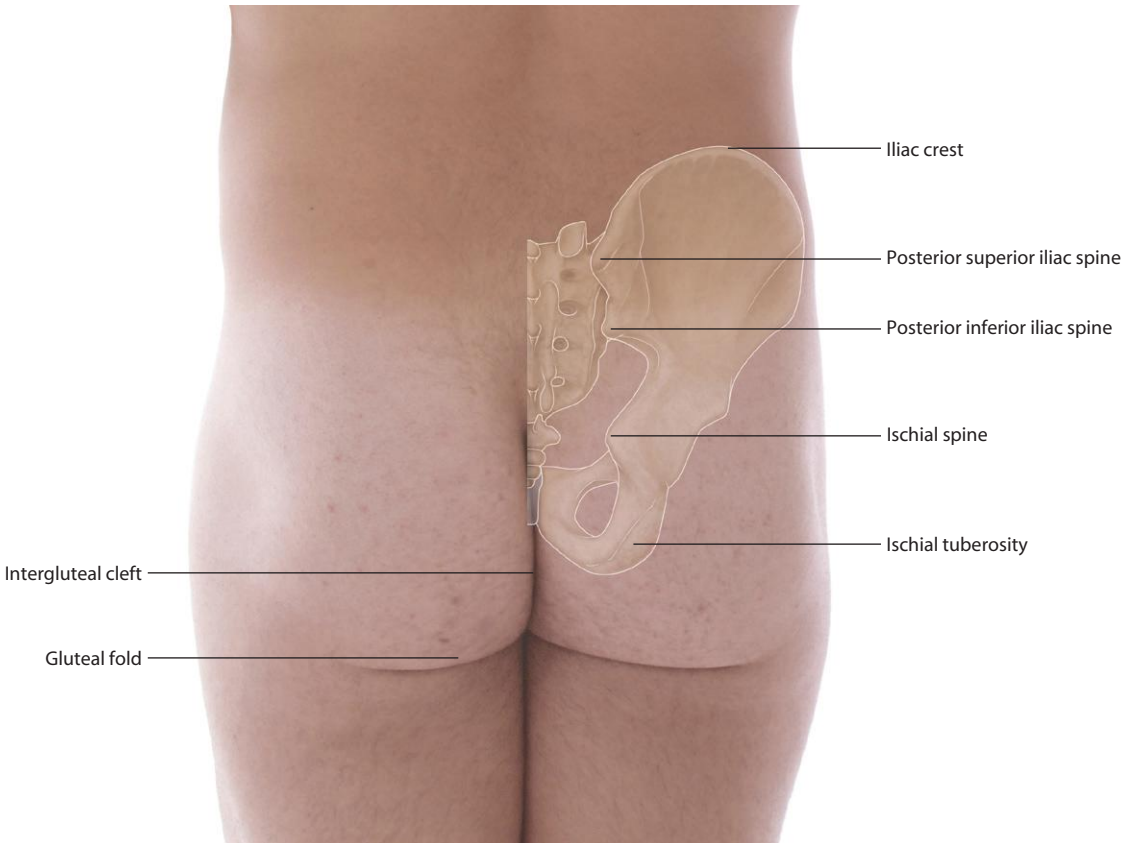

Surface anatomy with bones (posterior view)

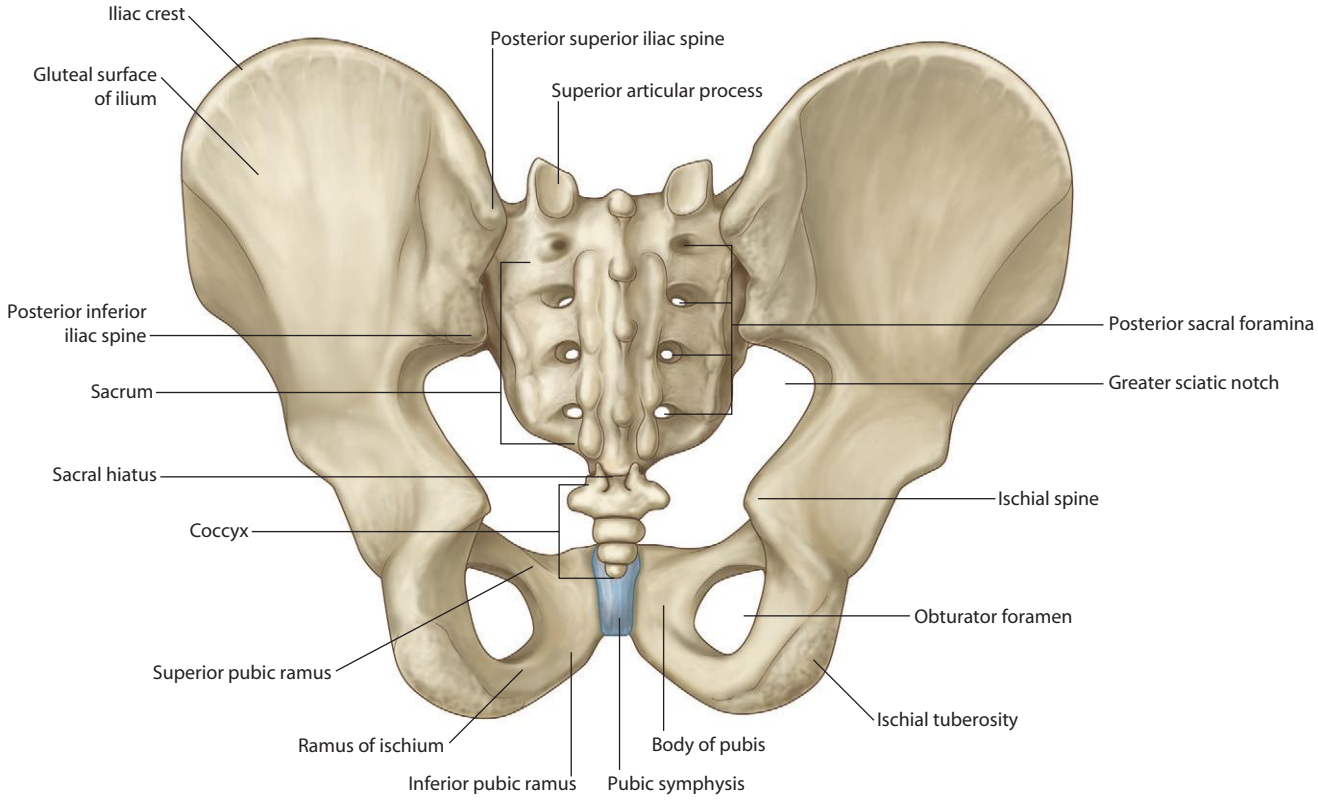

Articulated pelvis (posterior view)

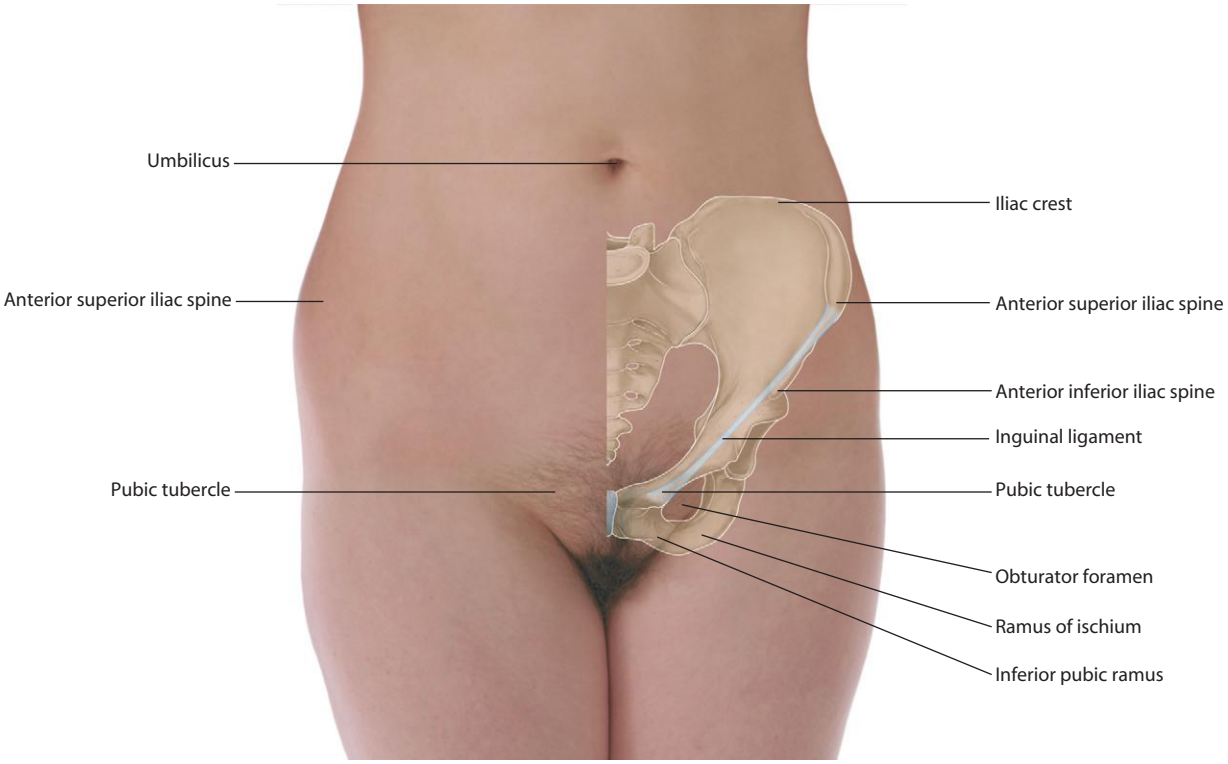

Surface anatomy with bones (anterior view)

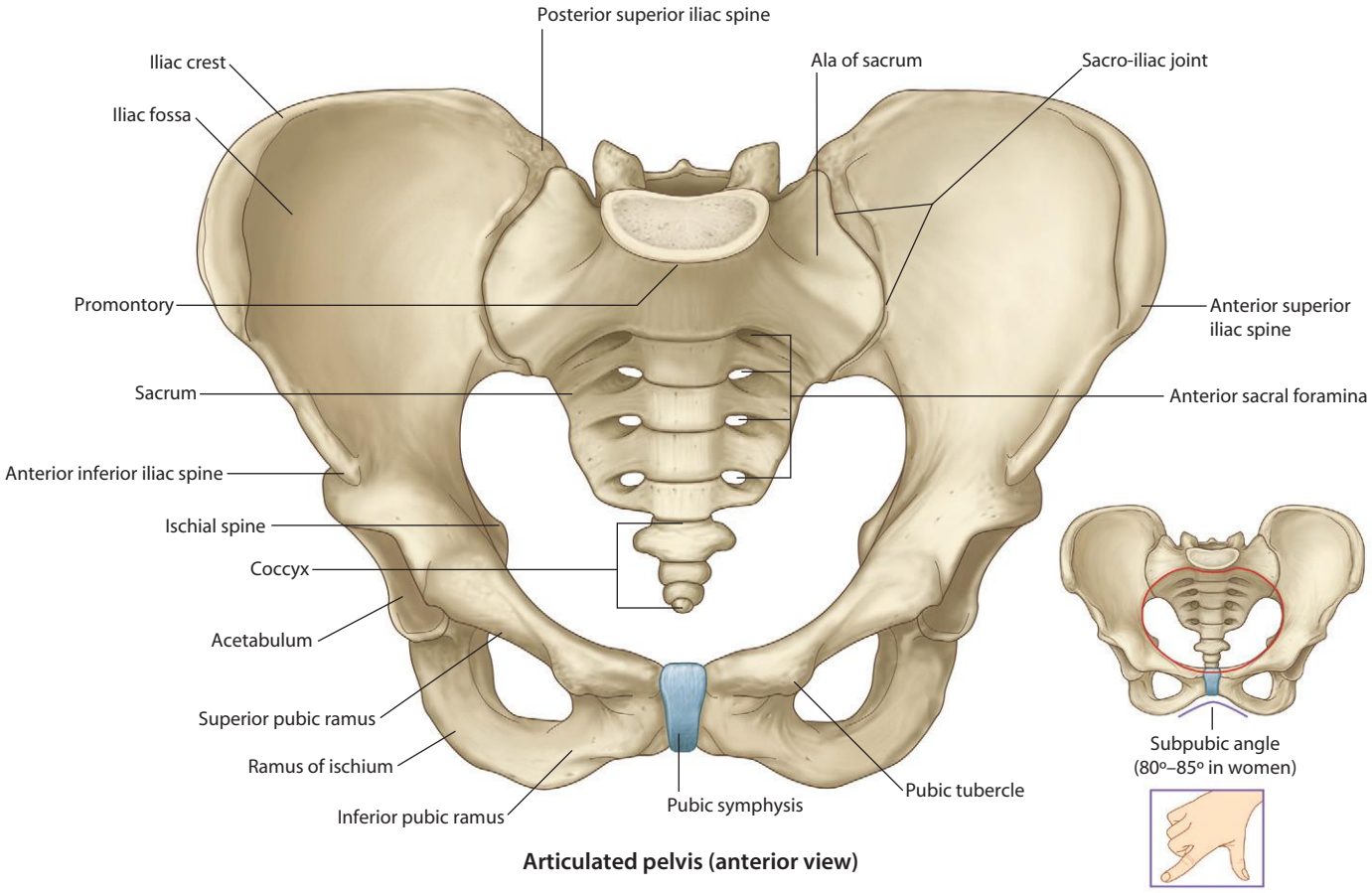

Articulated pelvis (anterior view)

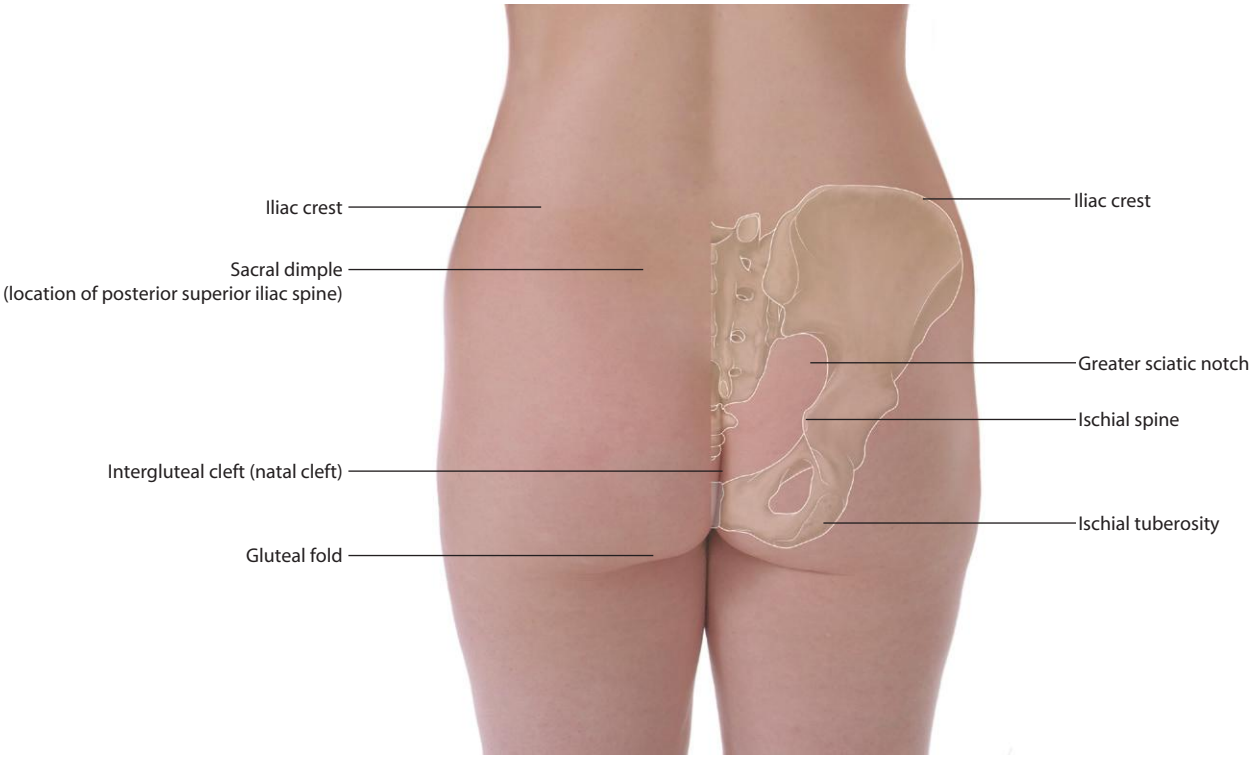

Surface anatomy with bones (posterior view)

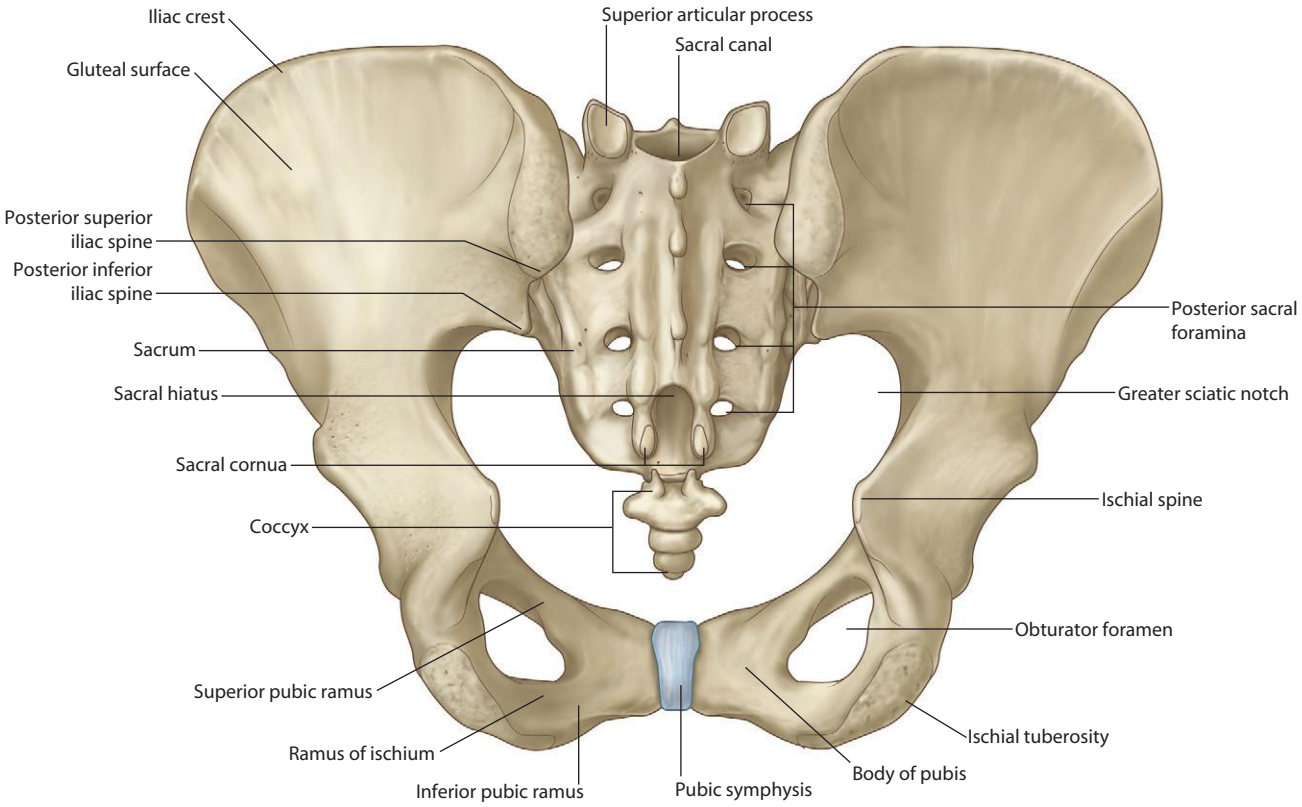

Articulated pelvis (posterior view)

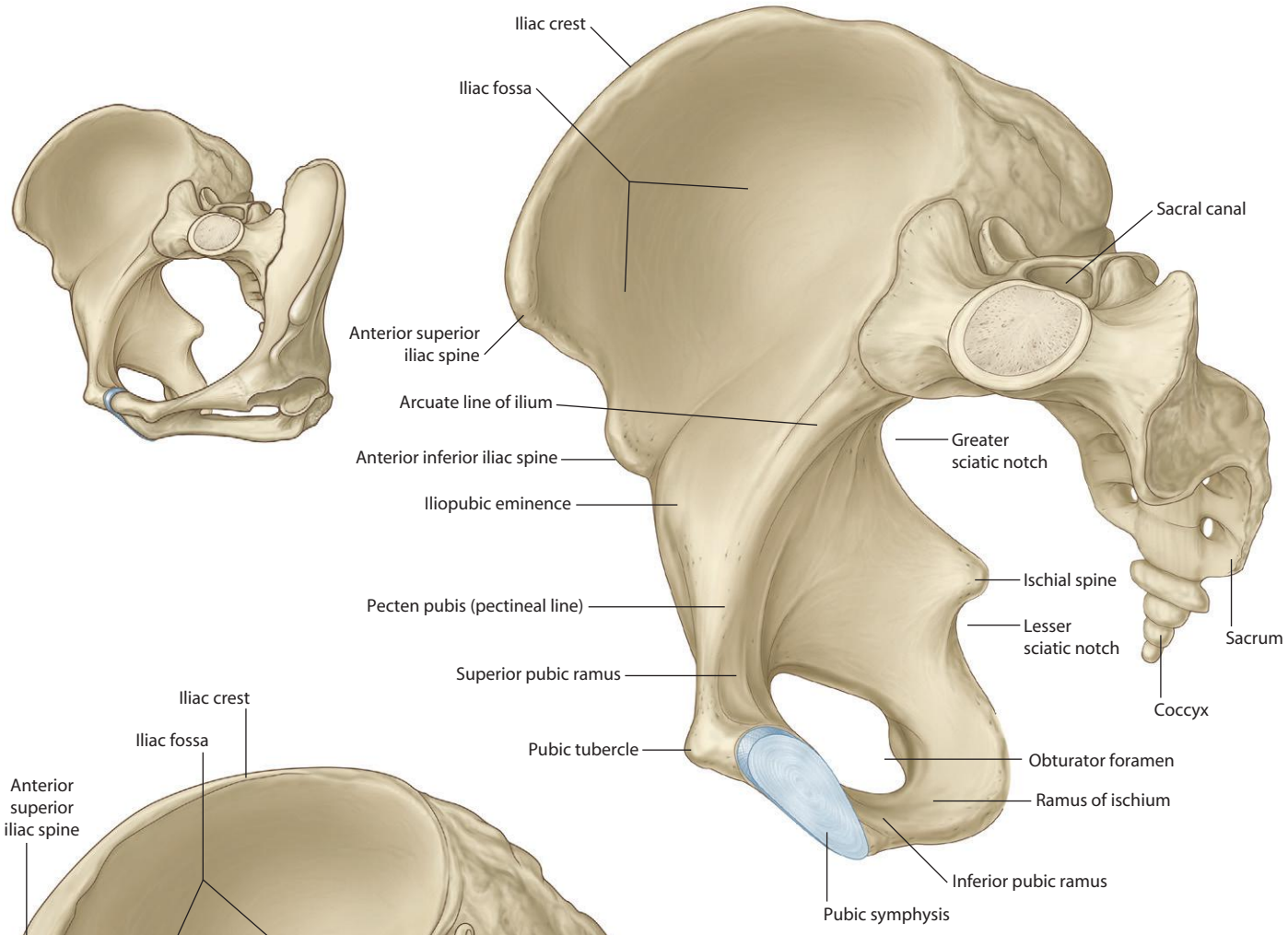

Pelvic girdle in men with left pelvic bone removed (anterolateral superior view)

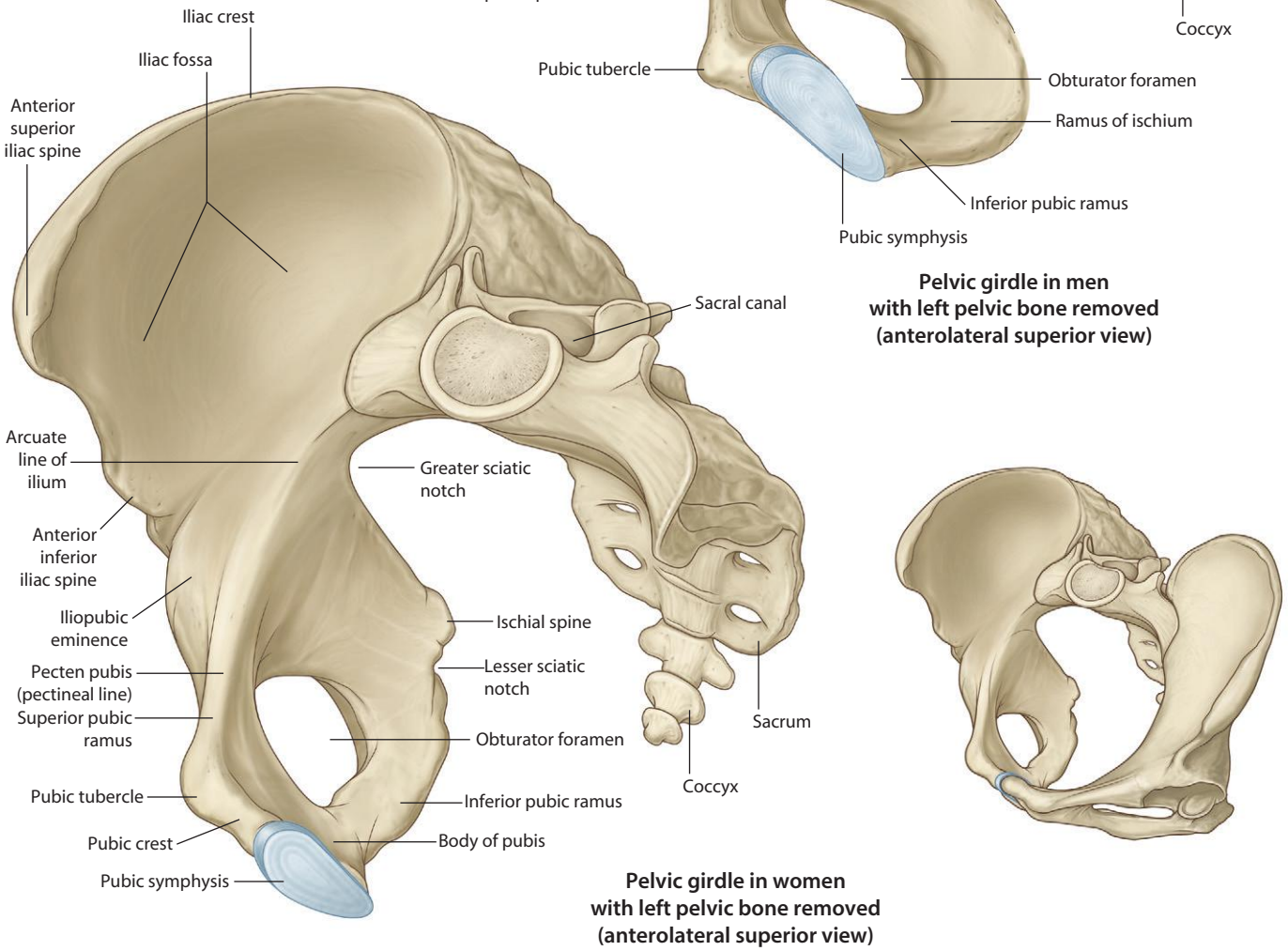

Pelvic girdle in women with left pelvic bone removed (anterolateral superior view)

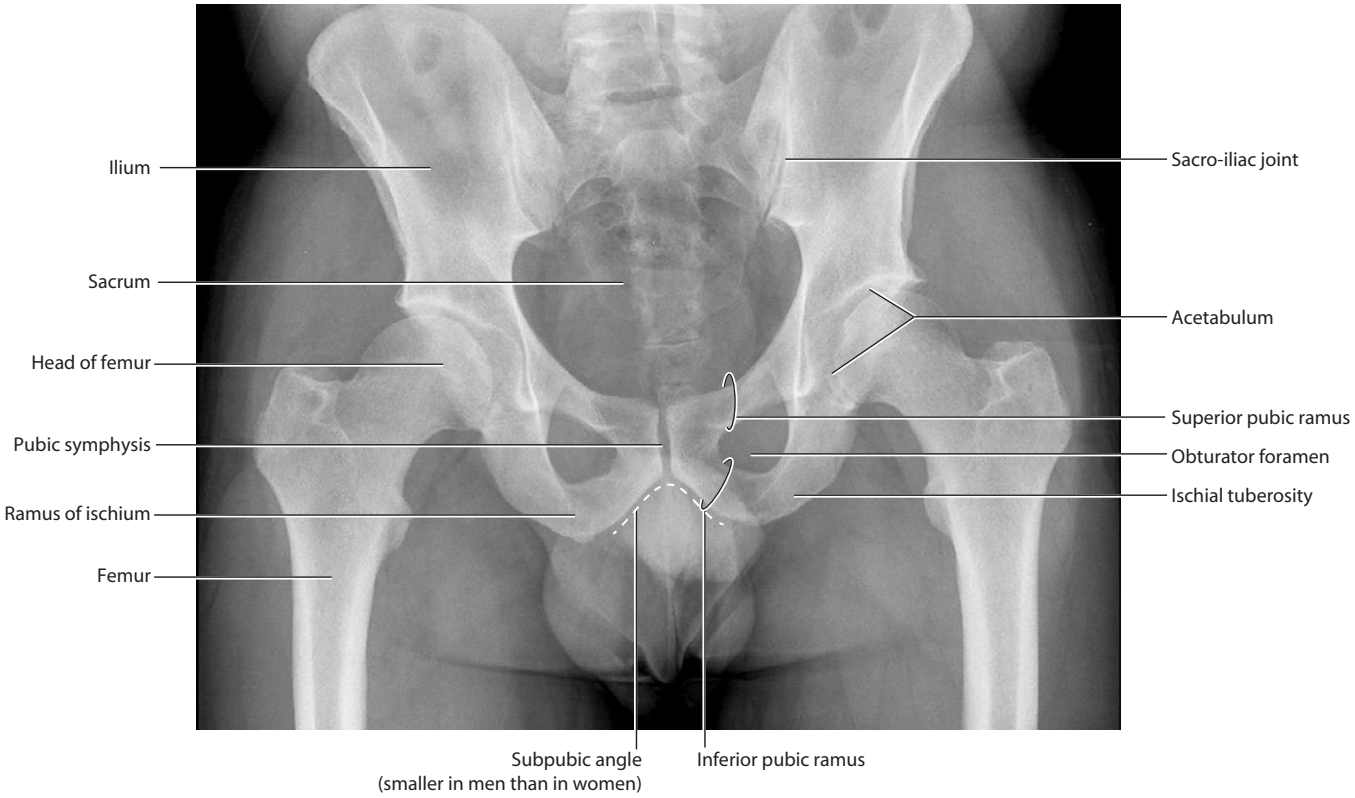

Male bony pelvis.
Radiograph, AP view

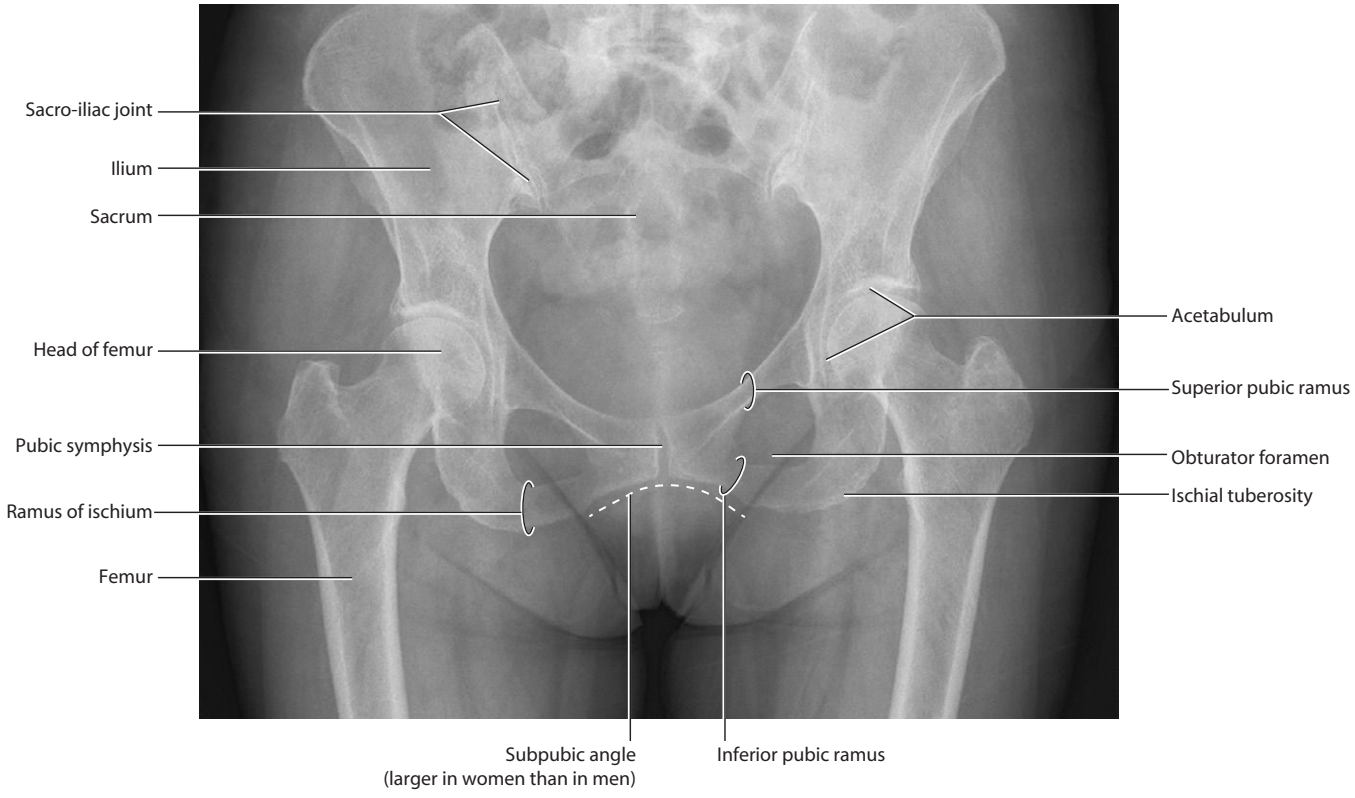

Female bony pelvis.
Radiograph, AP view

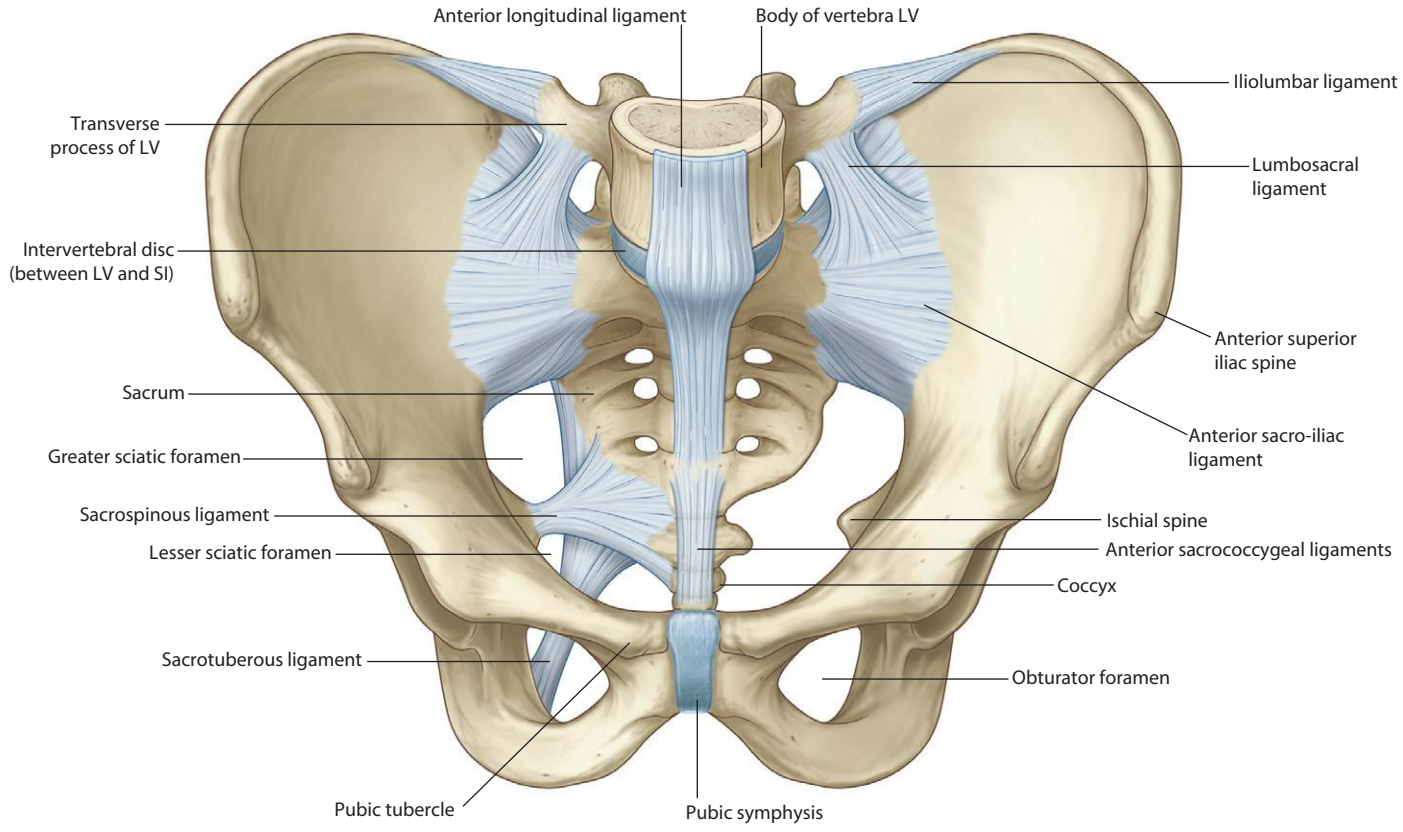

Lumbosacral joints and associated ligaments (anterior view)

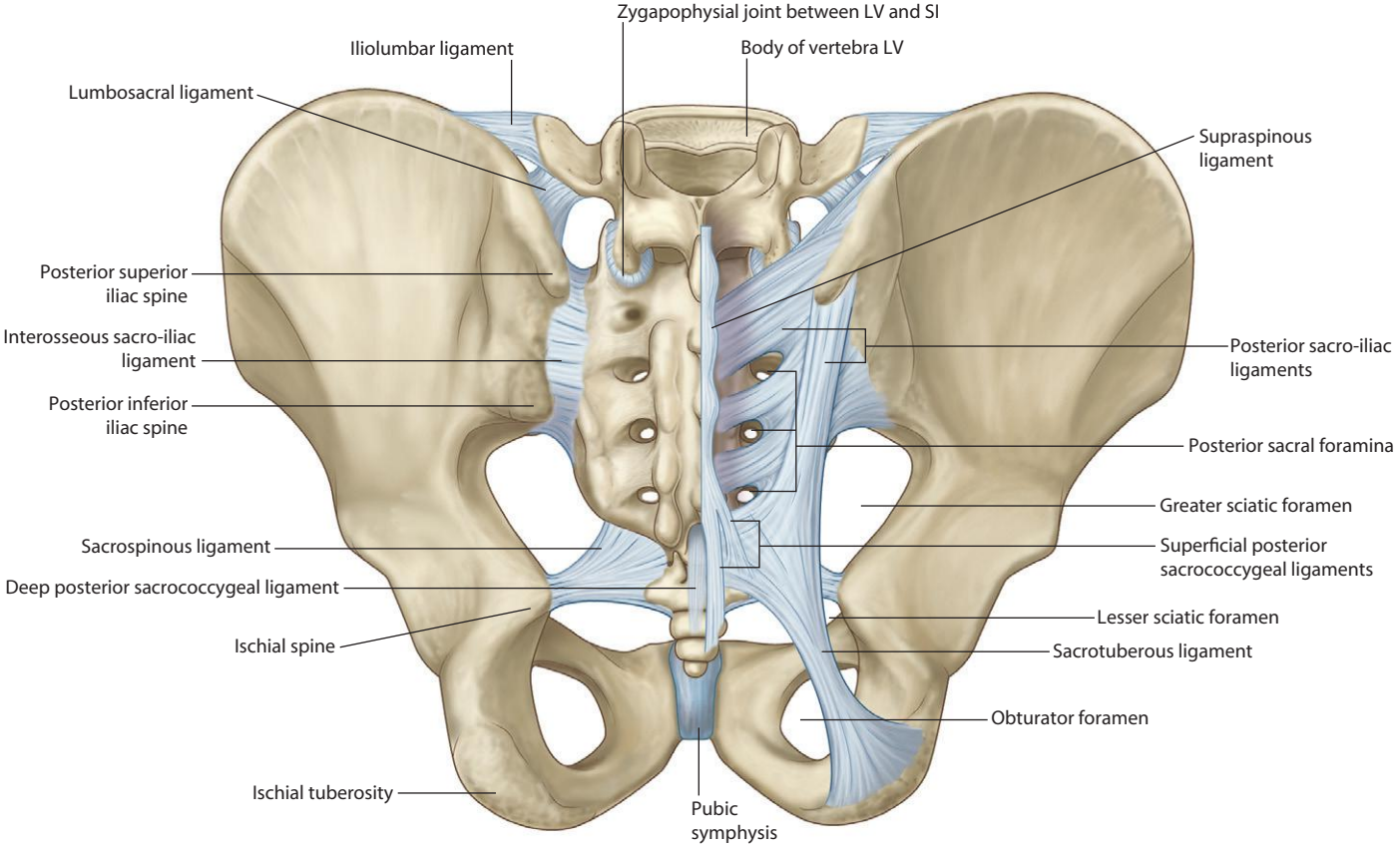

Lumbosacral joints and associated ligaments (posterior view)

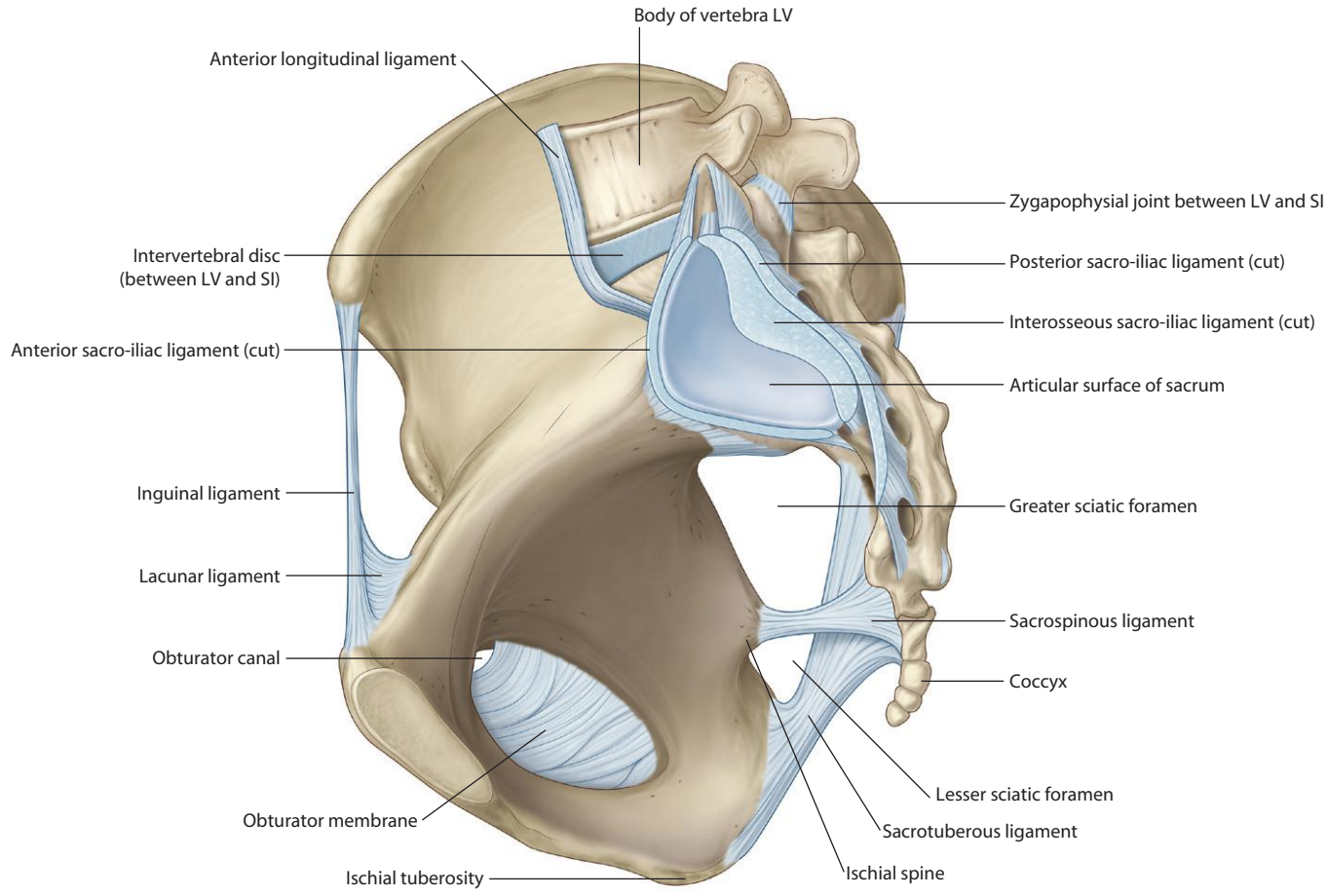

Sacro-iliac joints and associated ligaments (lateral view with left pelvic bone removed)

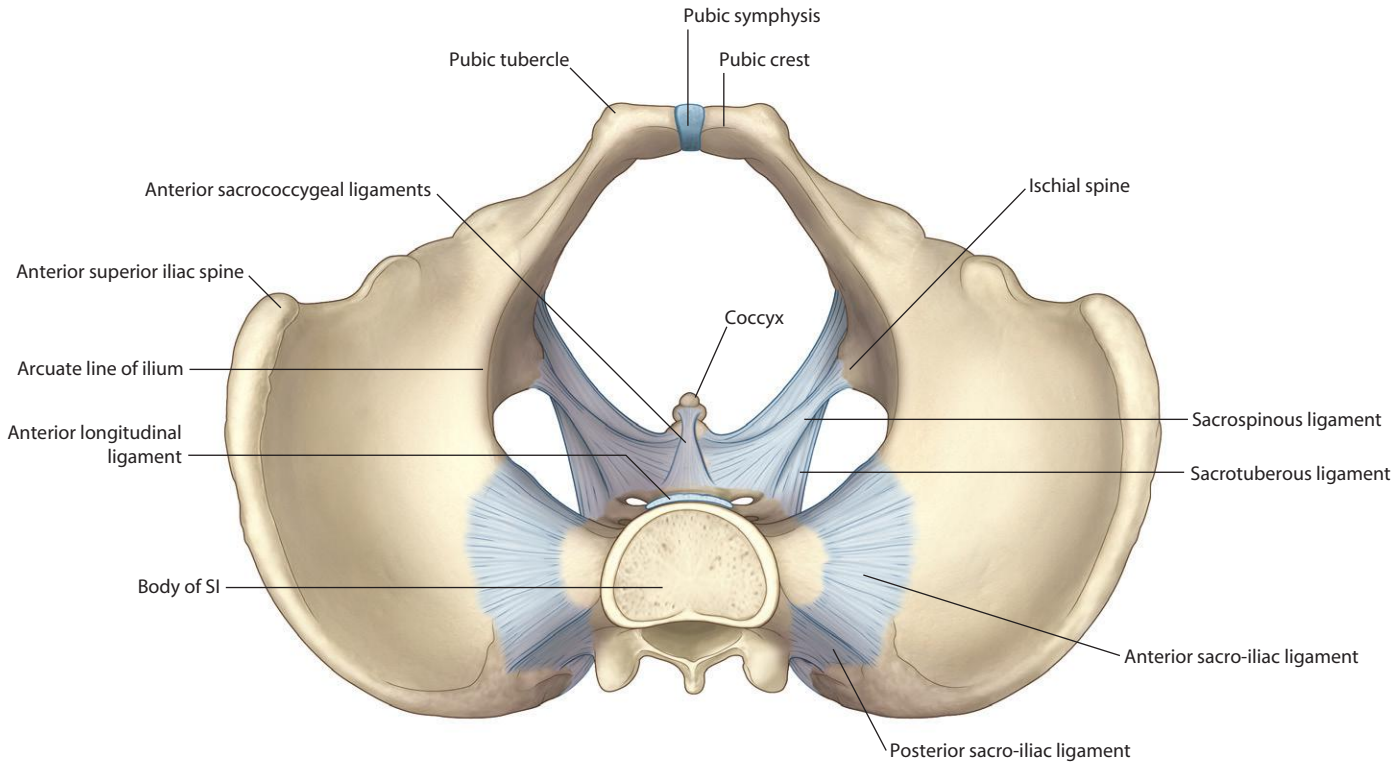

Sacro-iliac joints (anterosuperior view)

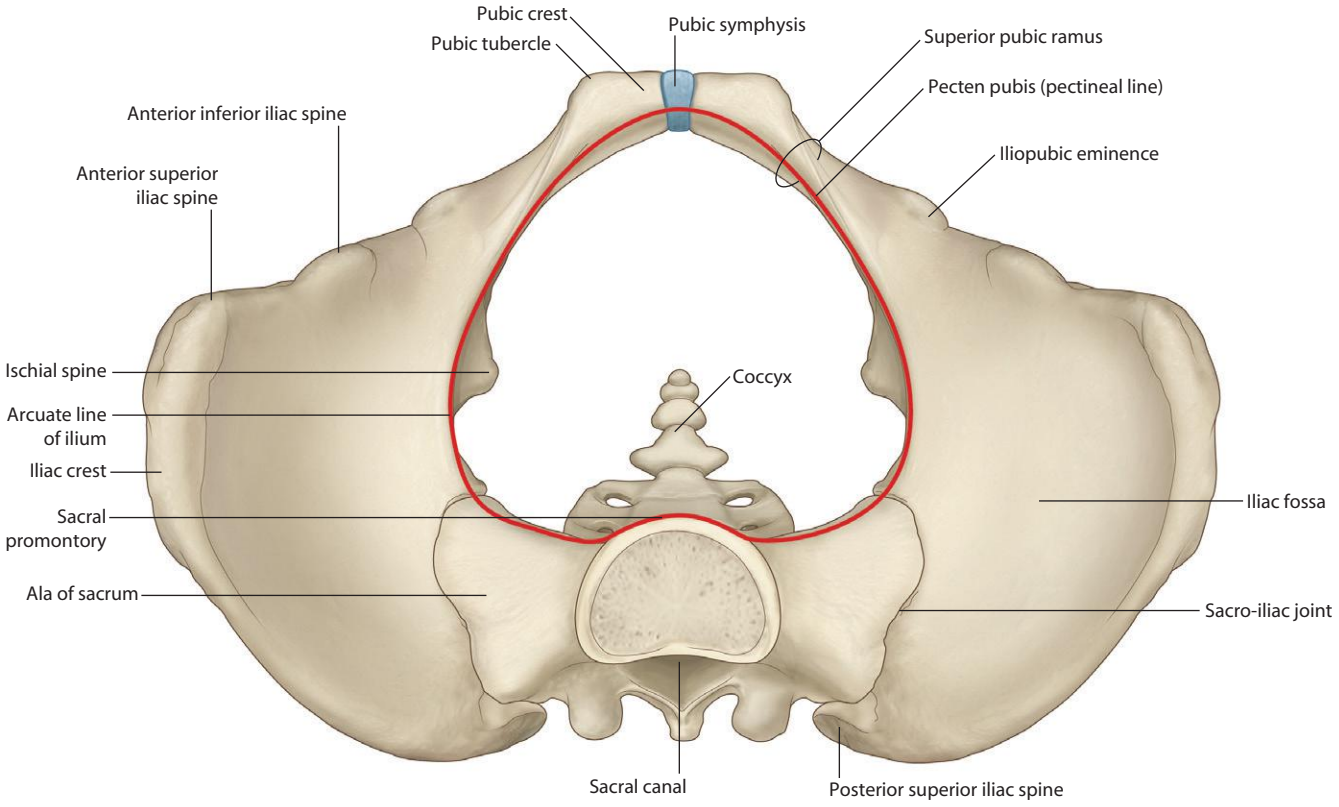

Pelvic inlet (shown in red; anterosuperior view)

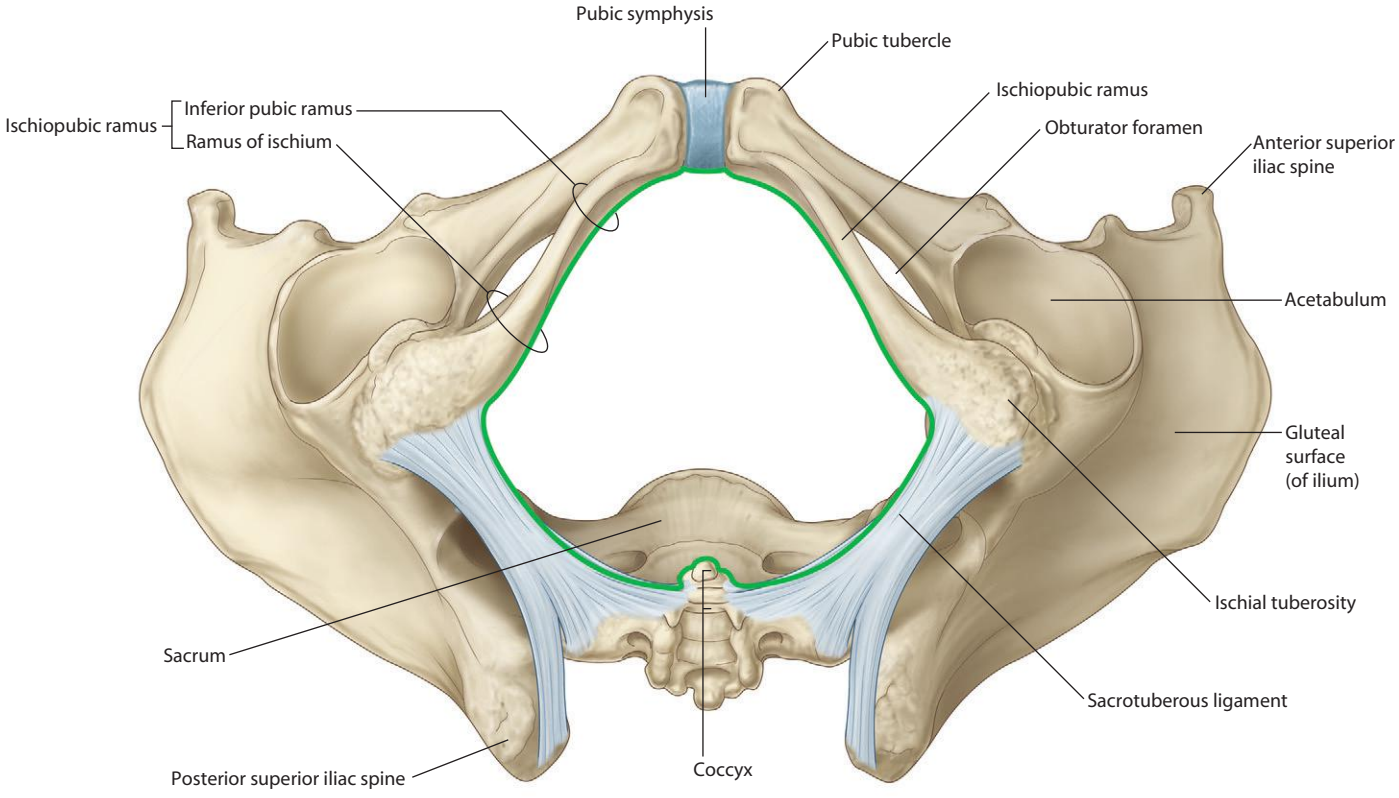

Pelvic outlet (shown in green; anteroinferior view)

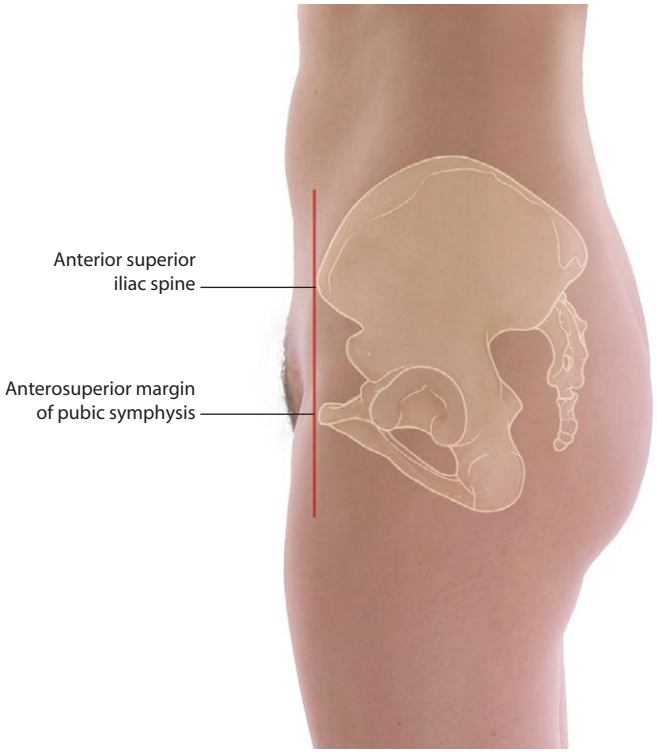

Pelvic orientation in anatomical position (lateral view)

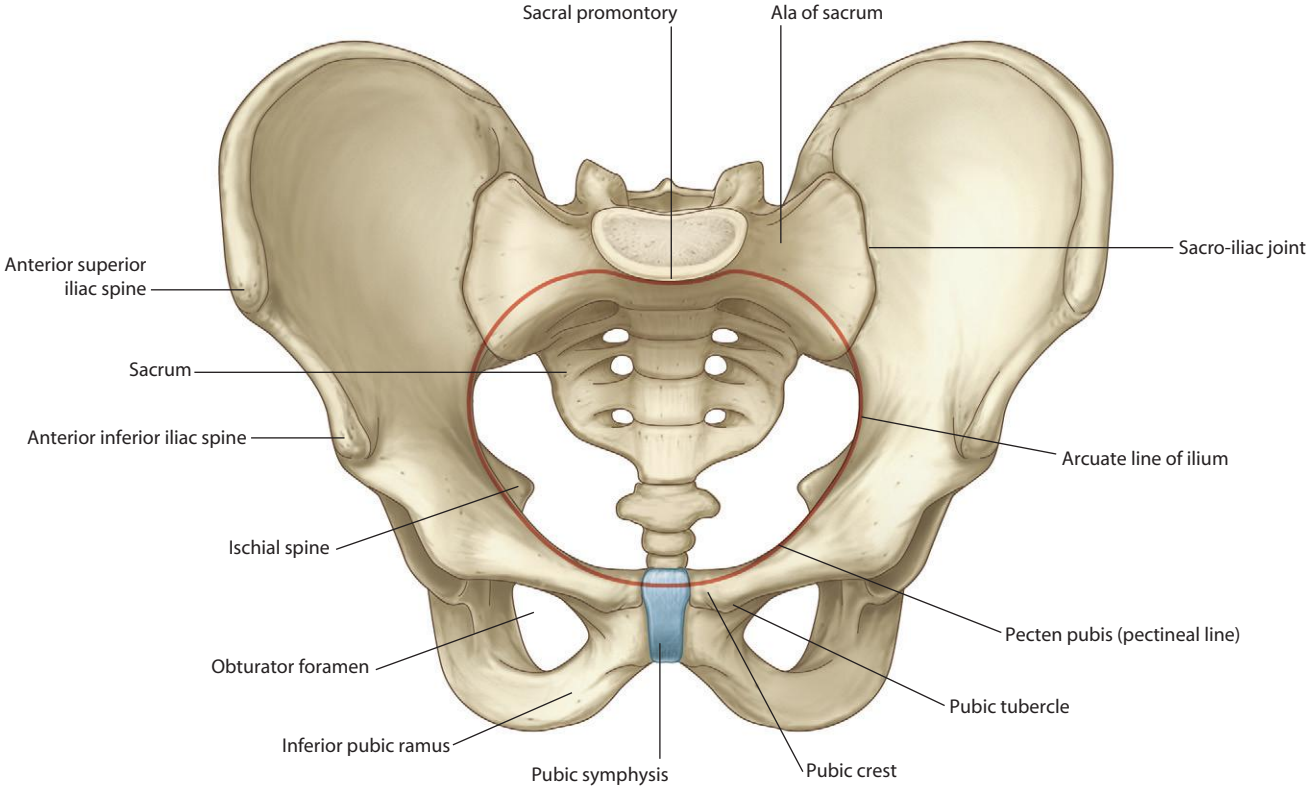

Pelvic inlet (shown in red; anterior view)

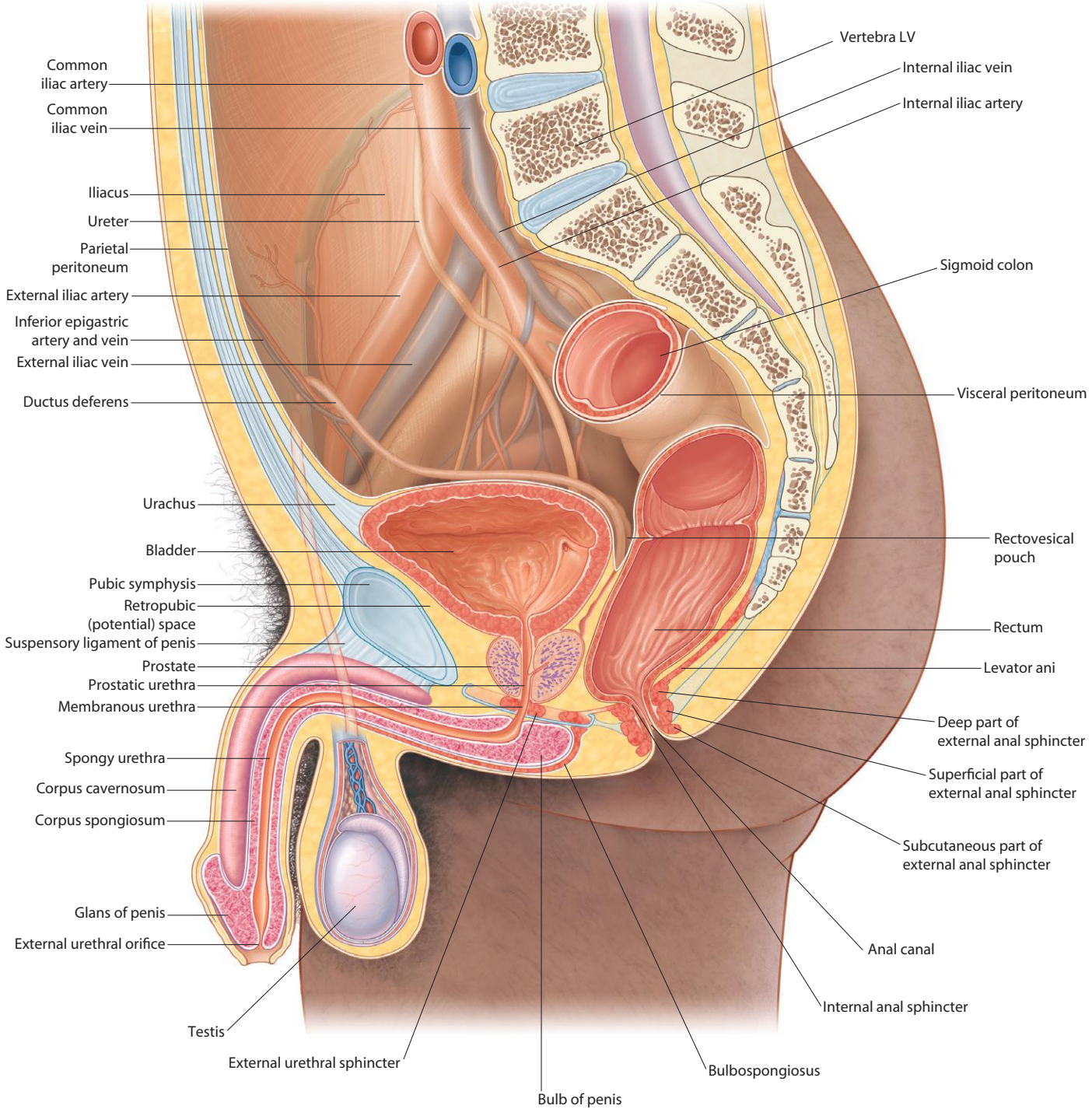

Pelvic viscera and perineum in men *in situ* (sagittal section)

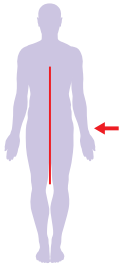

Pelvic viscera in men.
Fat-saturated T2-weighted MR image in sagittal plane

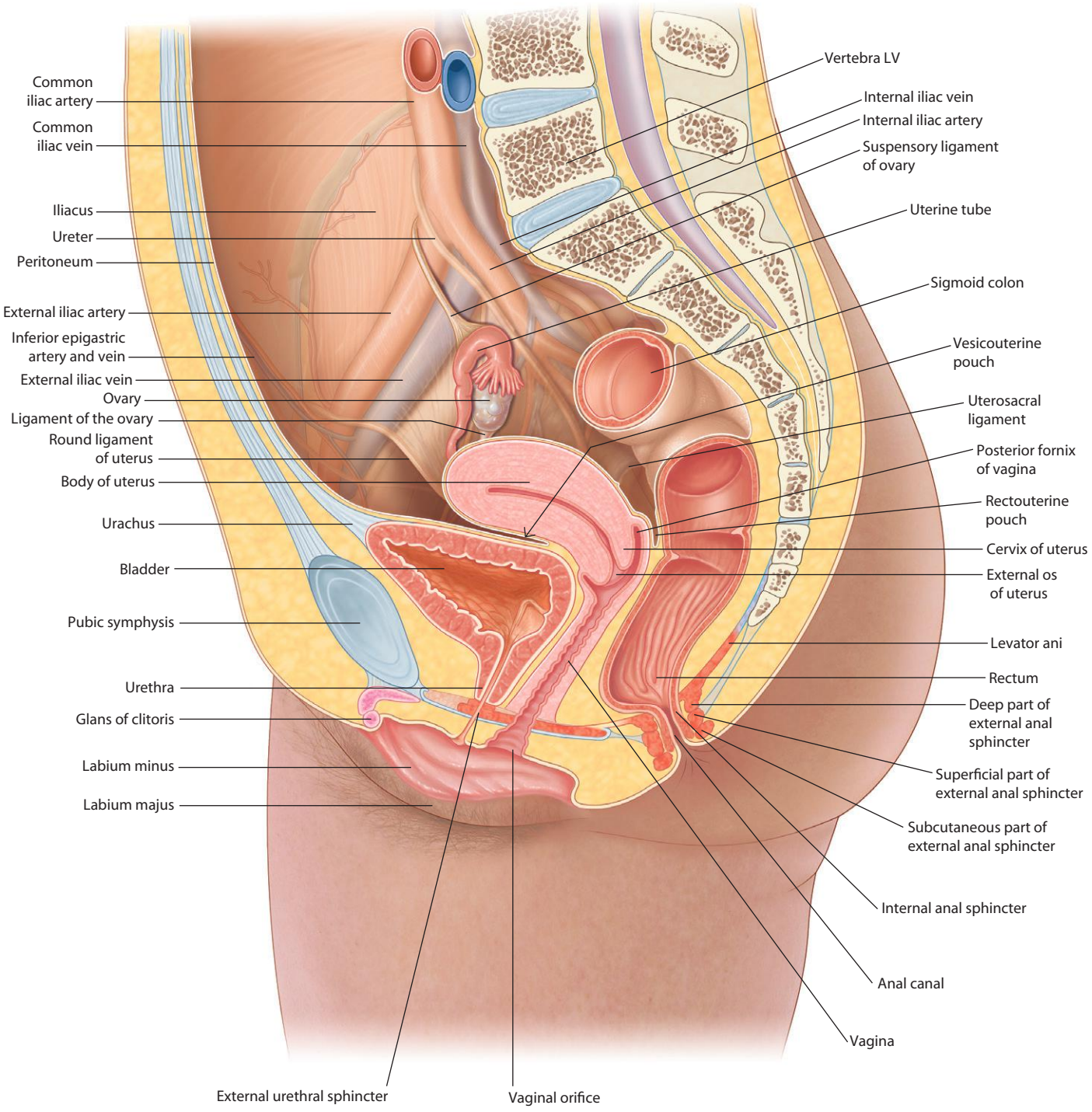

Pelvic viscera and perineum in women *in situ* (sagittal section)

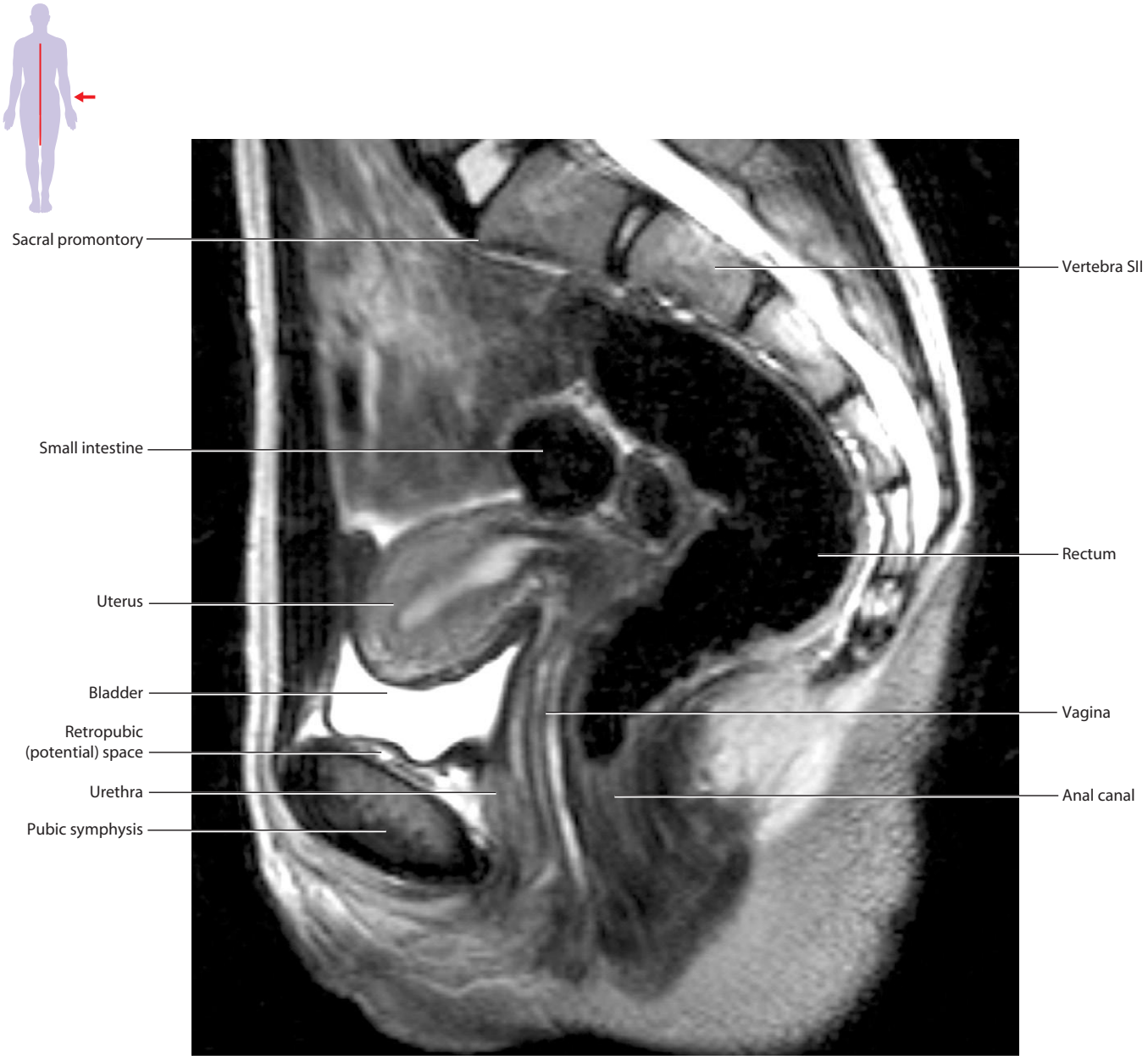

Pelvic viscera in women.
T2-weighted MR image in sagittal plane

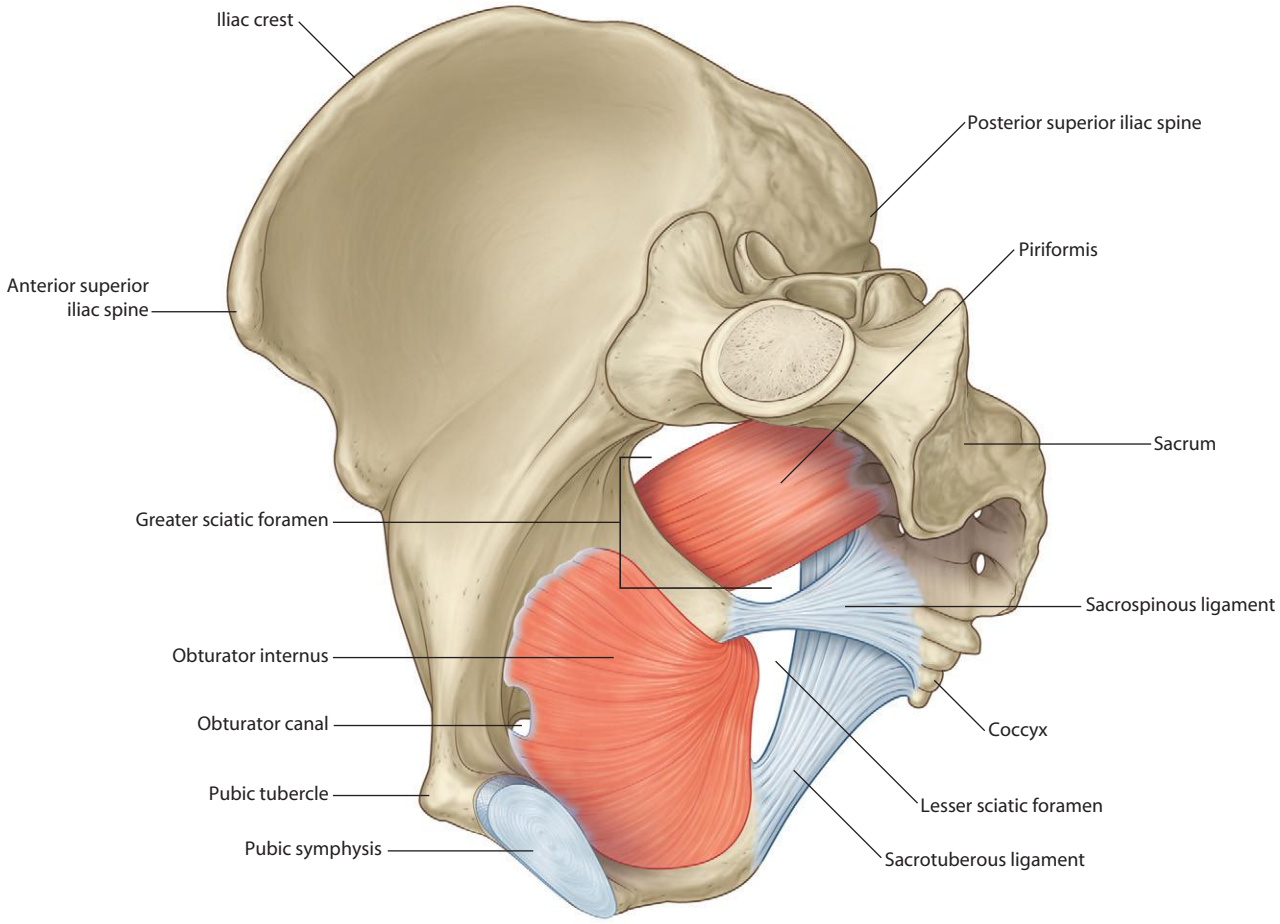

Obturator internus and piriformis muscles (oblique medial view)

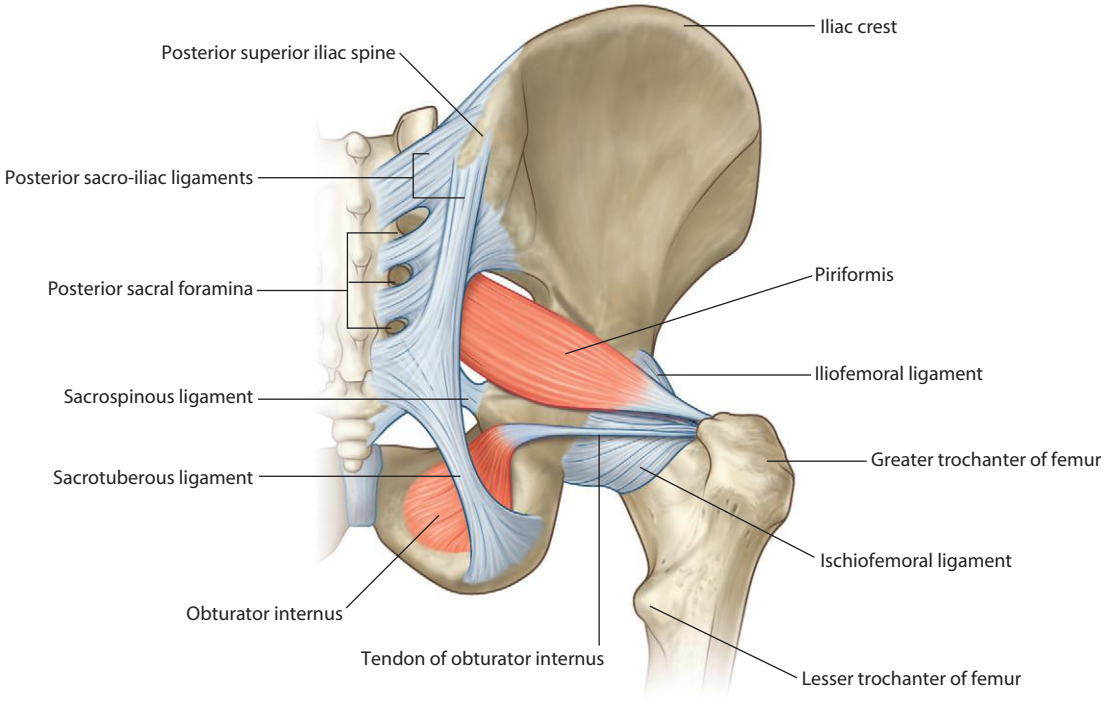

Obturator internus and piriformis muscles (posterior view)

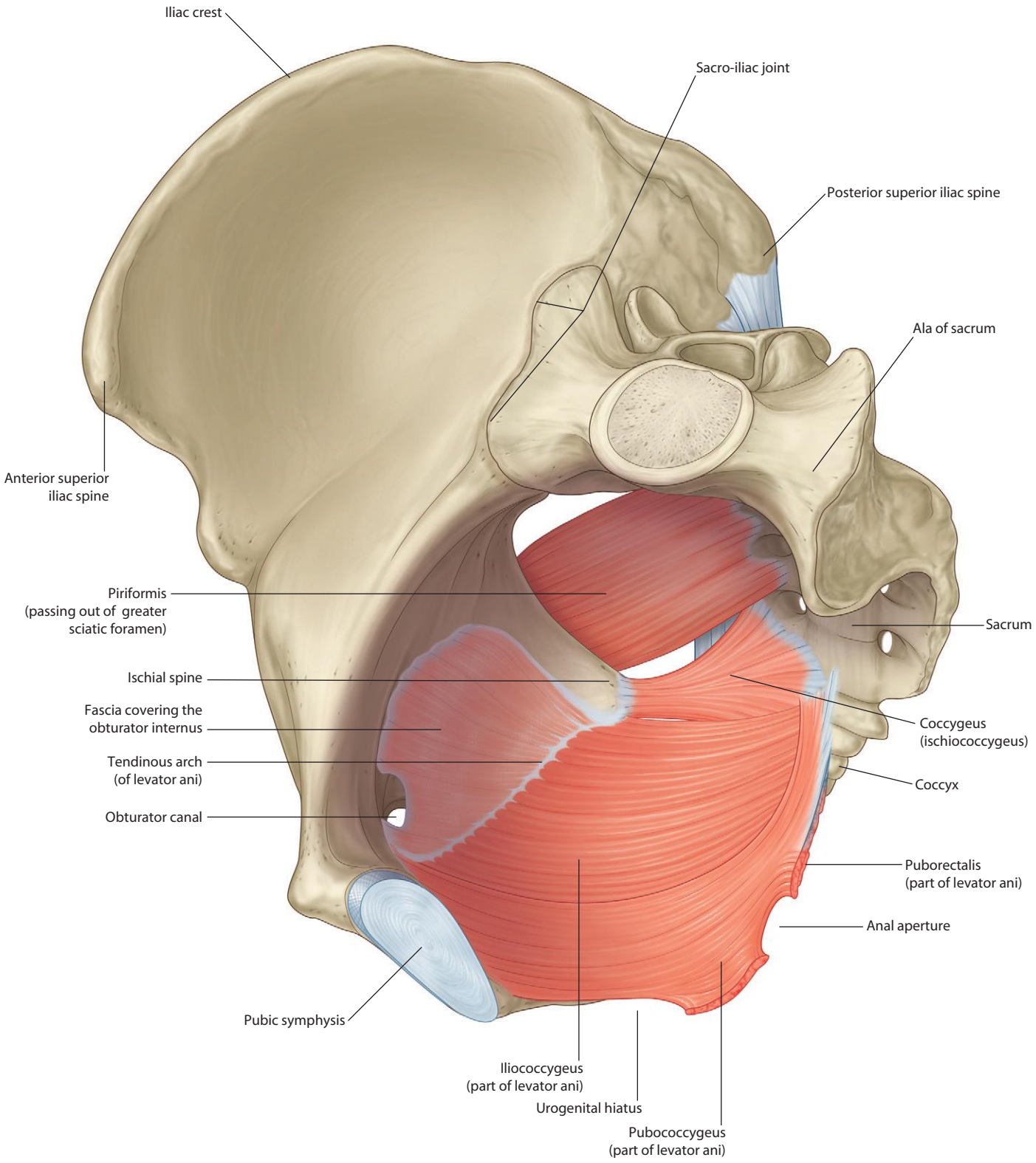

Levator ani and coccygeus (ischiococcygeus) muscles (oblique sagittal view)

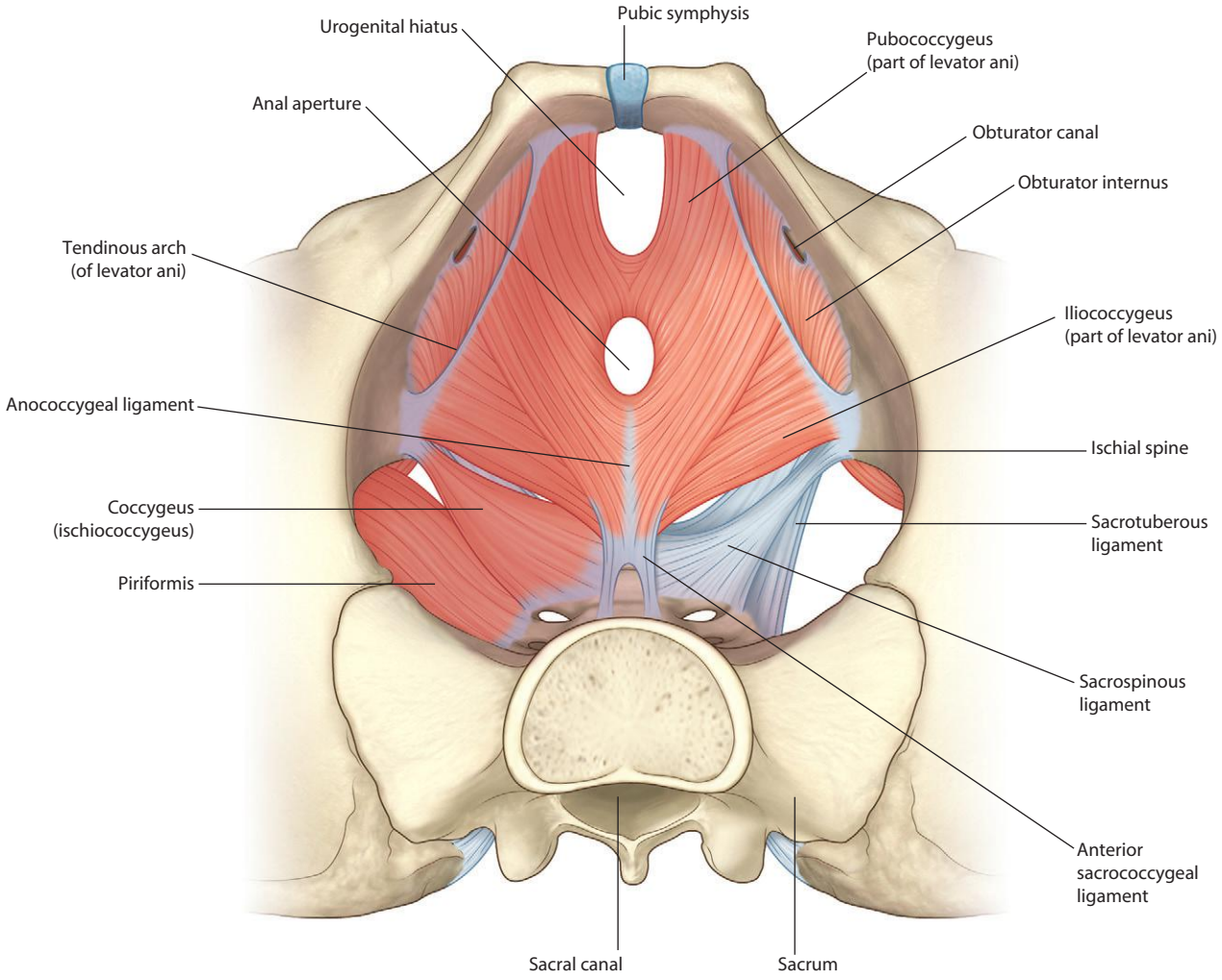

Levator ani and coccygeus (ischiococcygeus) muscles (anterosuperior view)

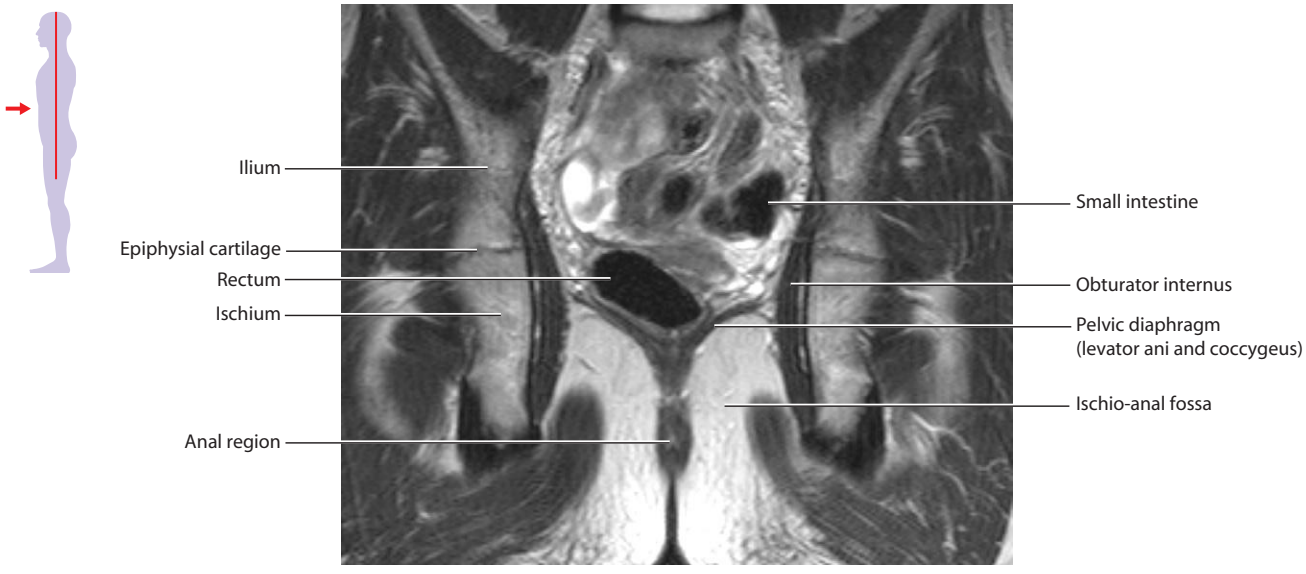

Pelvic diaphragm in relation to other structures in the pelvic cavity and perineum.
T2-weighted MR image in coronal plane

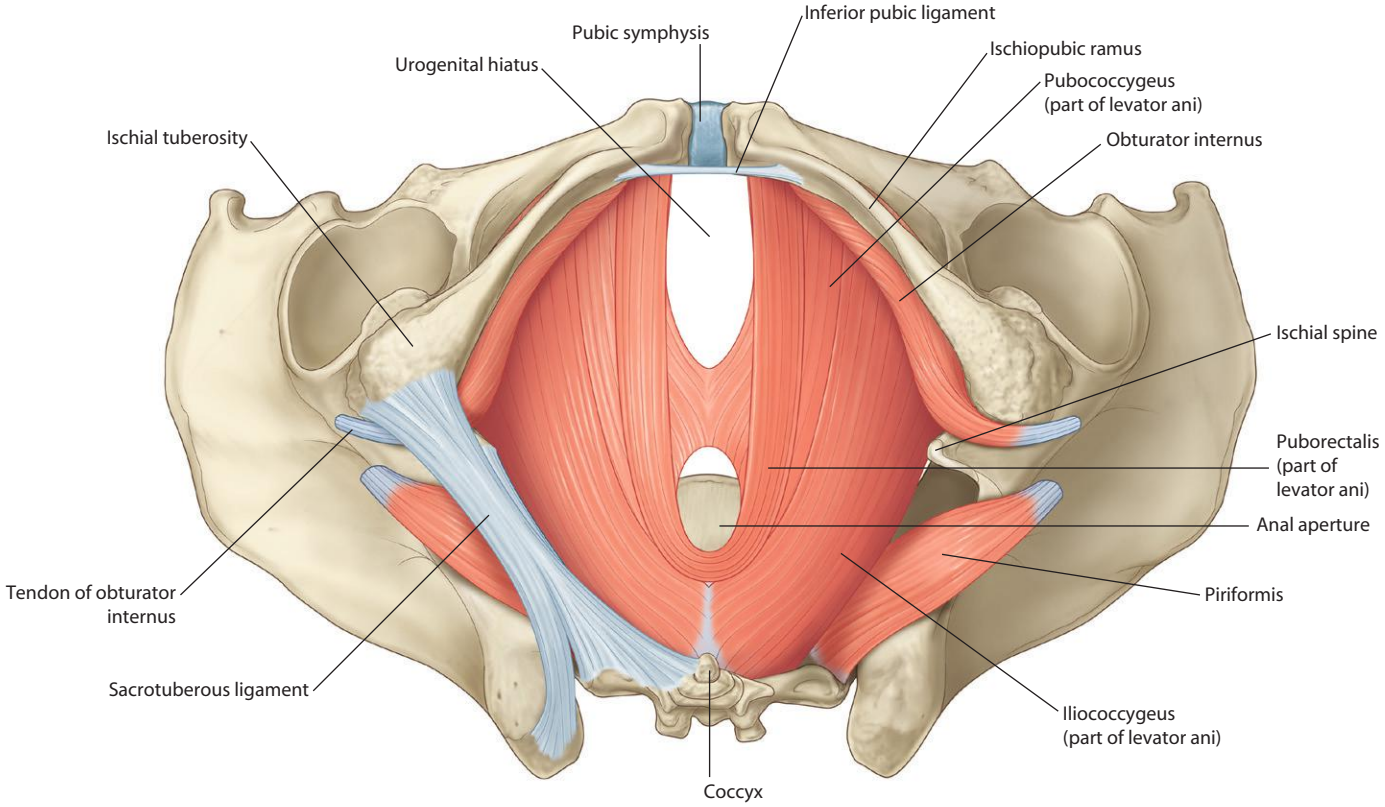

Levator ani muscle (inferior view)

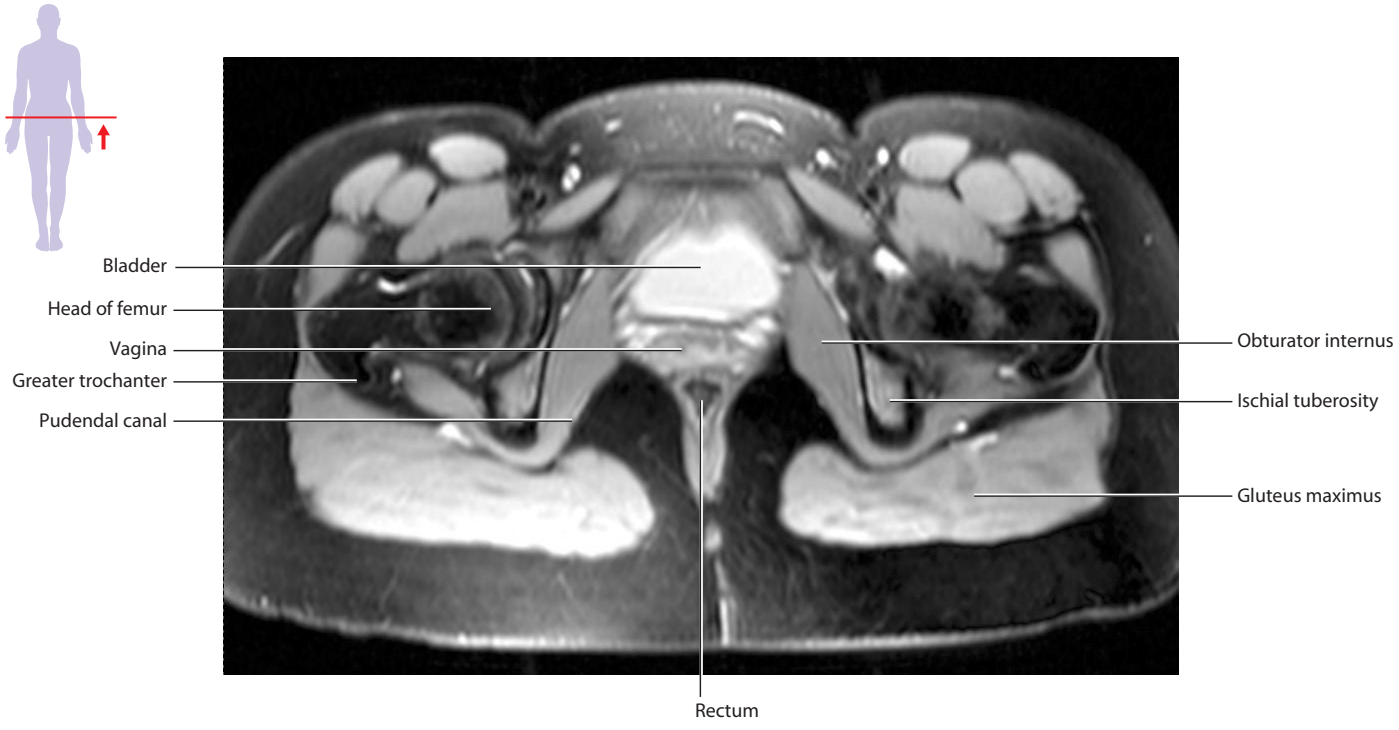

Obturator internus muscle and its relationship to other pelvic structures.
Fat-saturated T2-weighted MR image in axial plane

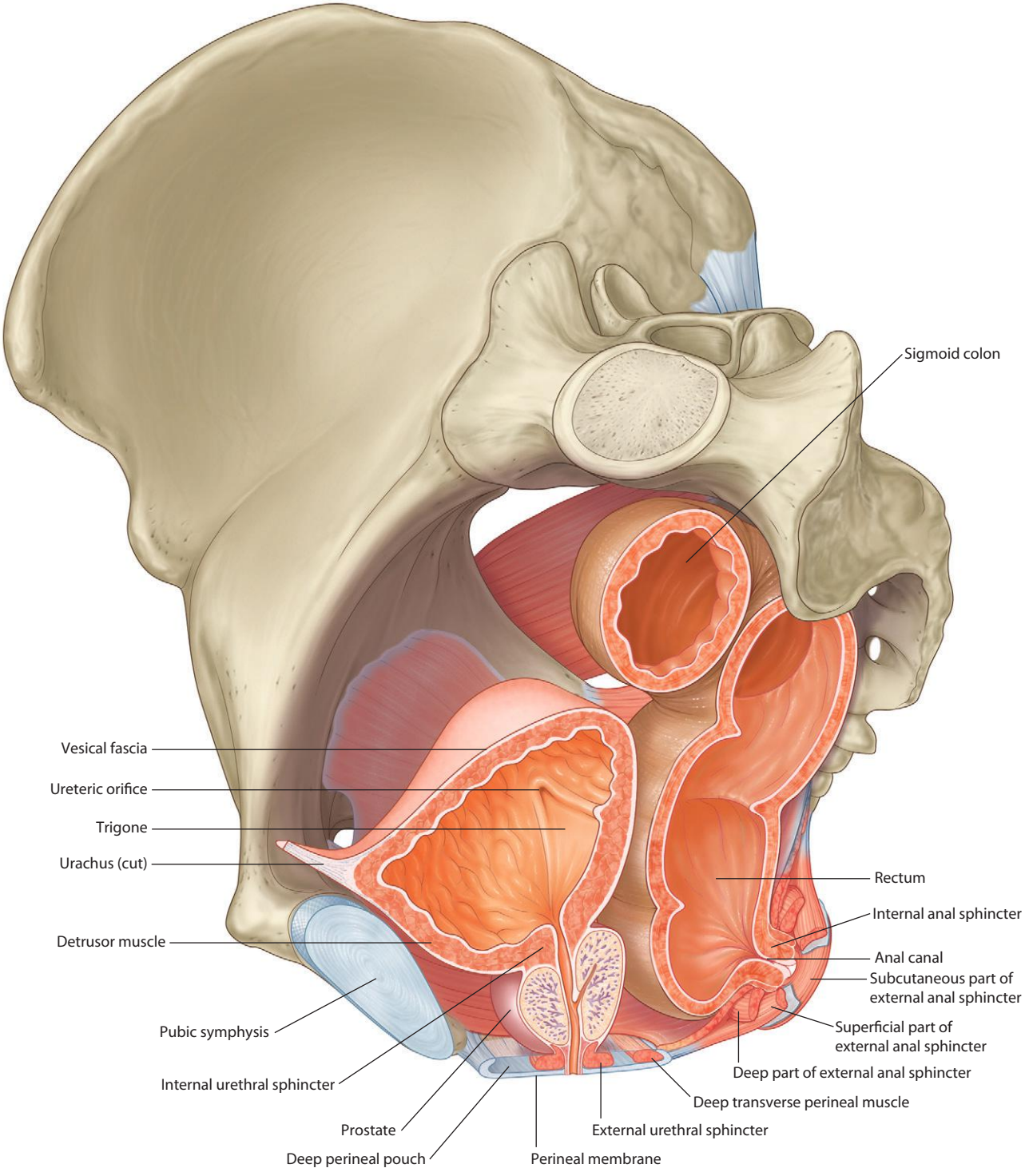

Bladder, prostate, and rectum within pelvic cavity in men (oblique sagittal view)

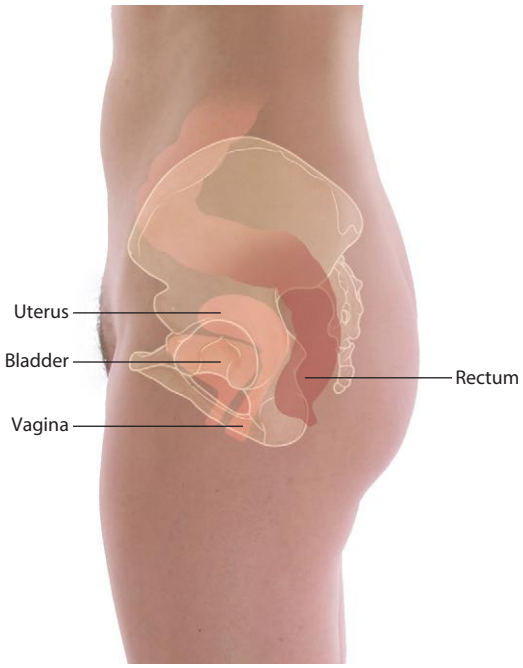

Surface projection of the rectum in women

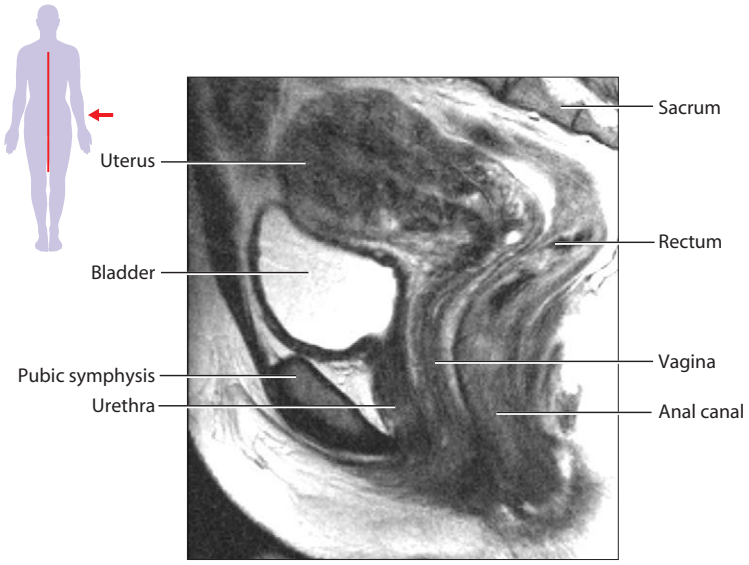

Positioning of the rectum and anal canal in relation to the other female pelvic viscera.
T2-weighted MR image in sagittal plane

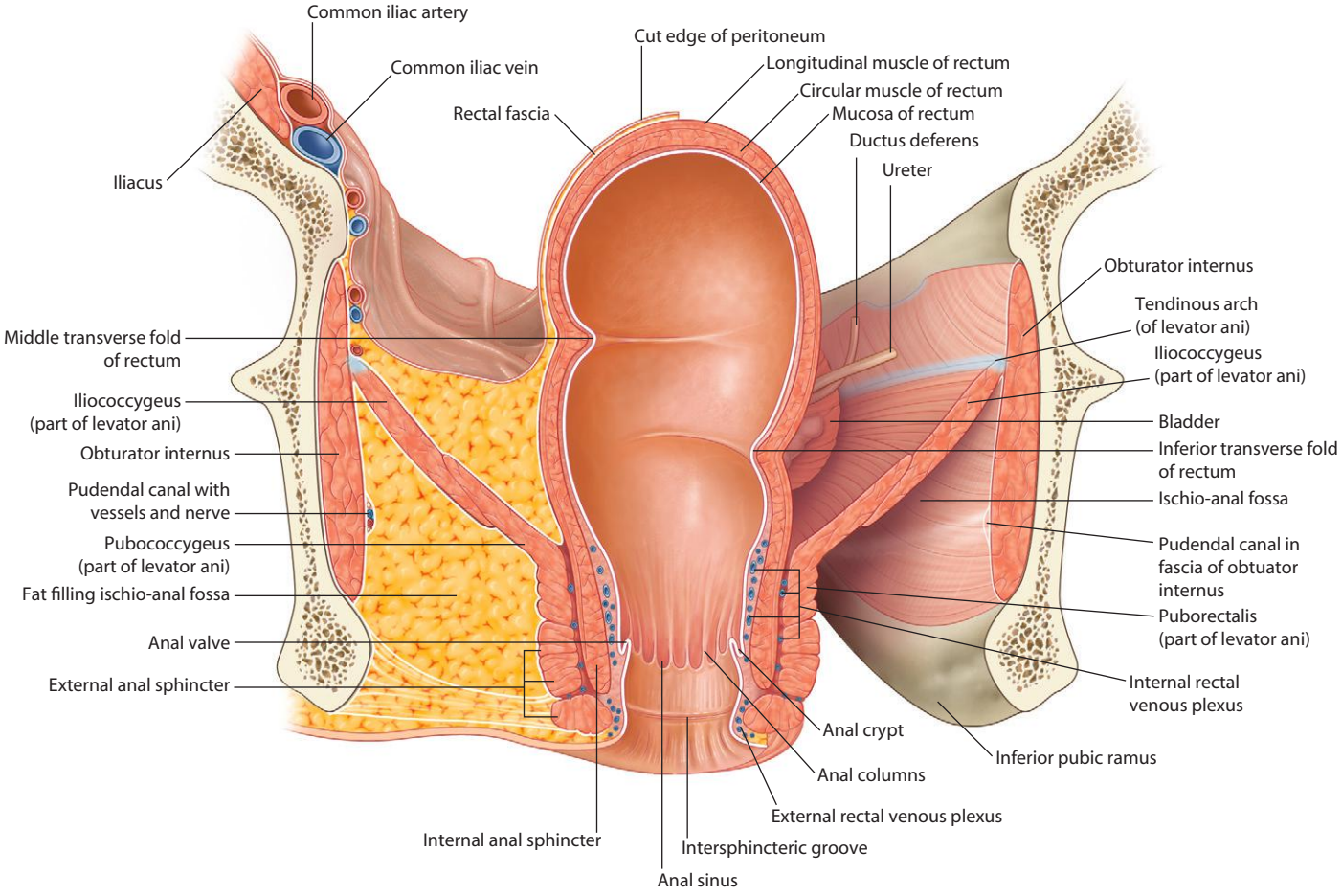

Coronal section through rectum and anal canal (posterior view)

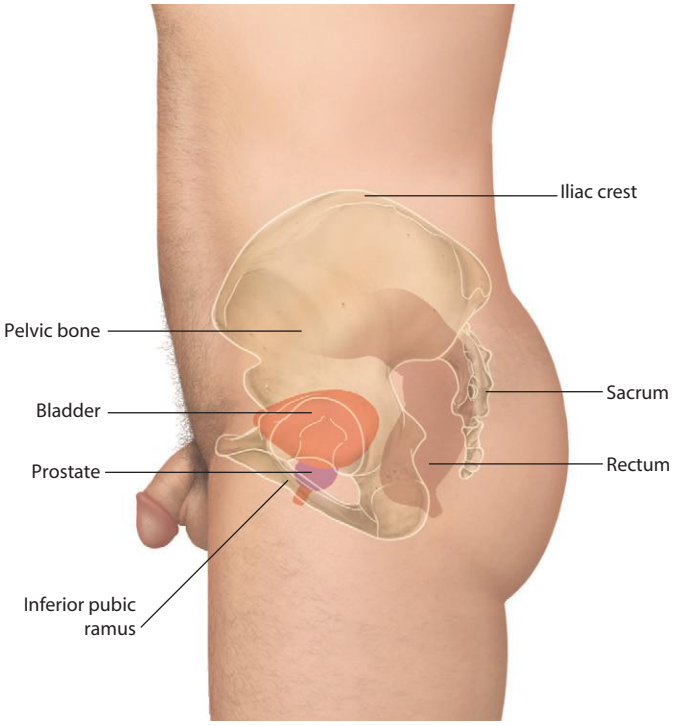

Surface projection of the bladder in men (lateral view)

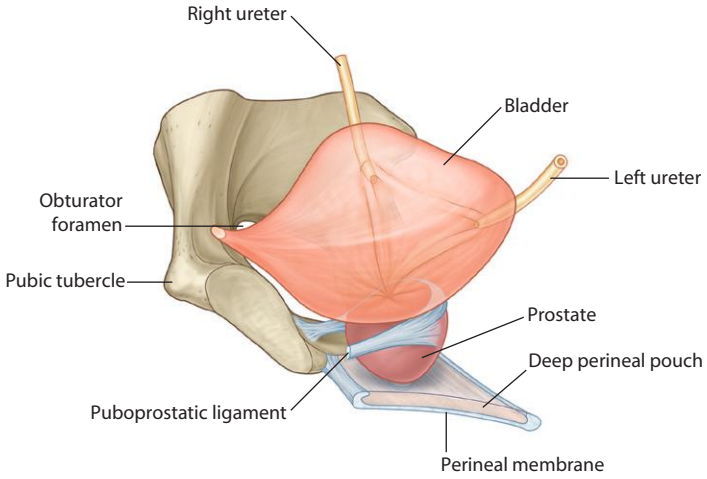

Puboprostatic ligament

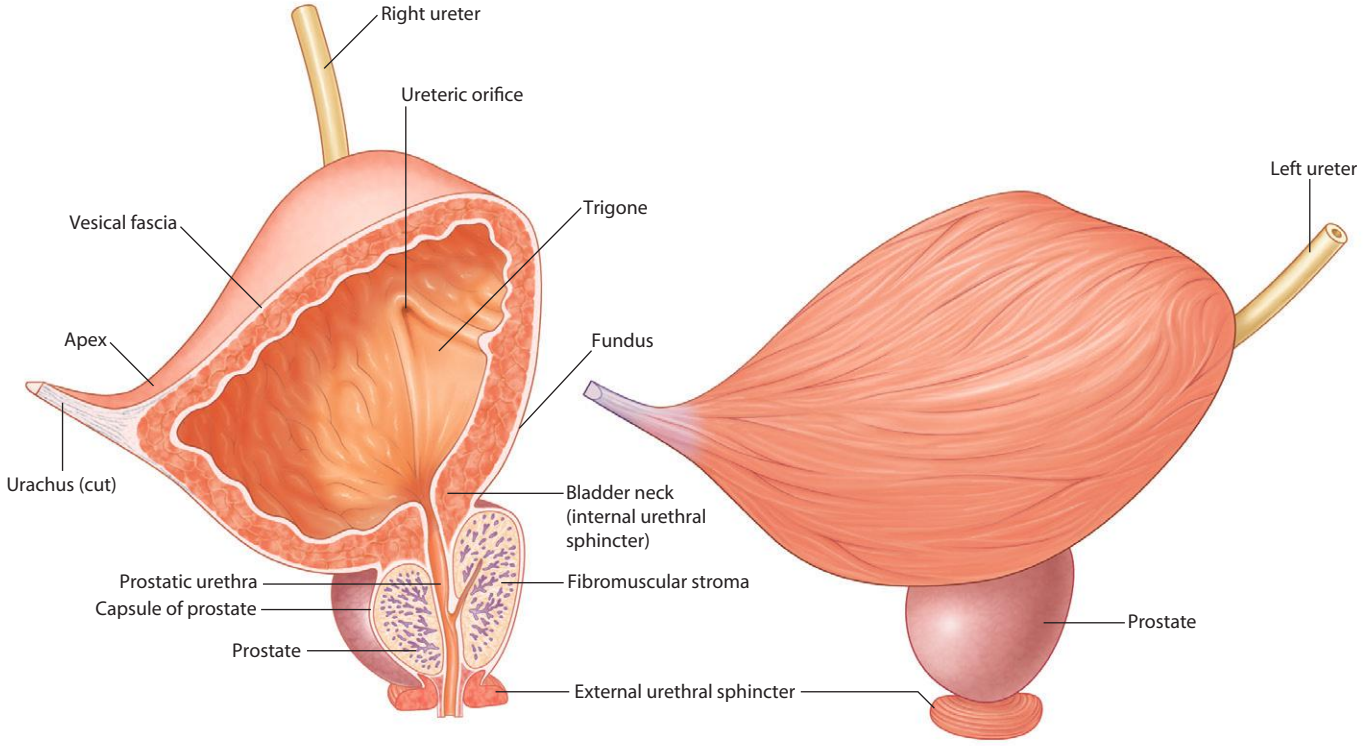

Urinary bladder in men

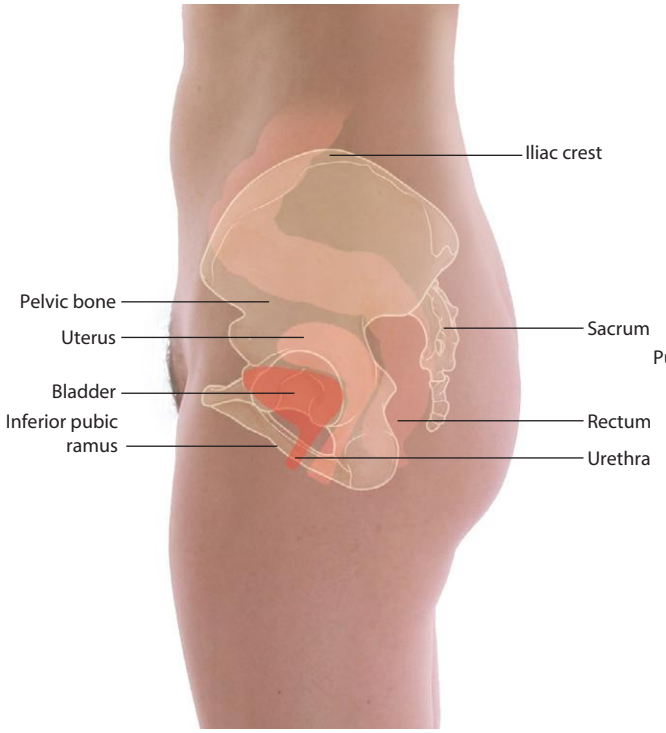

Surface projection of the bladder in women (lateral view)

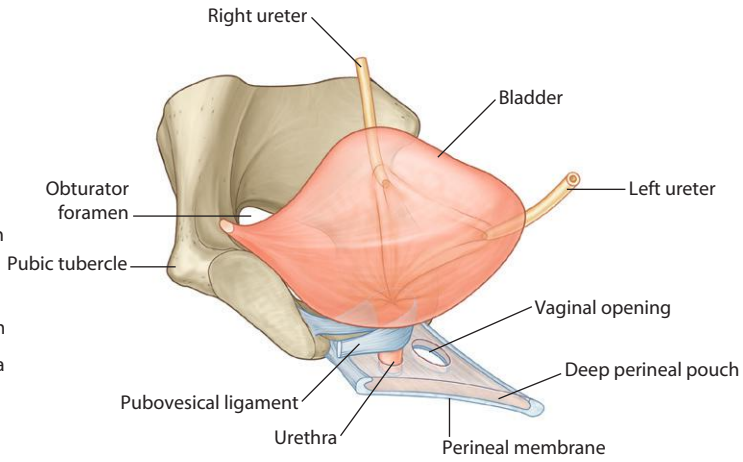

Pubovesical ligament

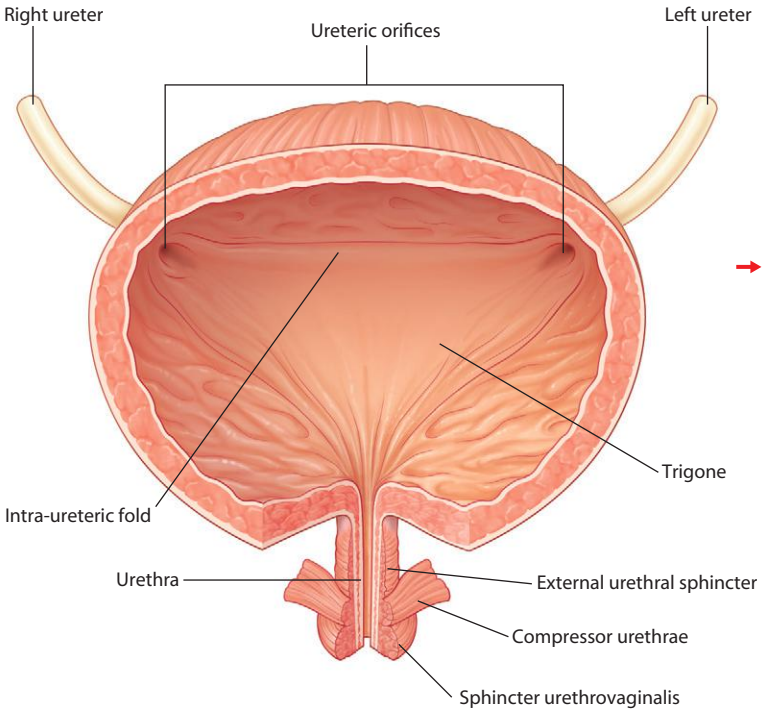

Urinary bladder and urethral sphincter muscles in women (anterior view of posterior wall)

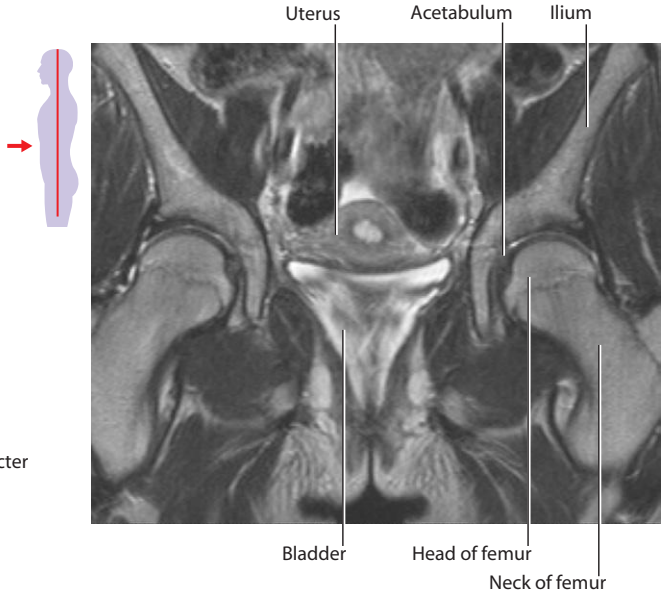

Appearance and positioning of the bladder in relation to other structures in the female pelvic cavity.
T2-weighted MR image in coronal plane

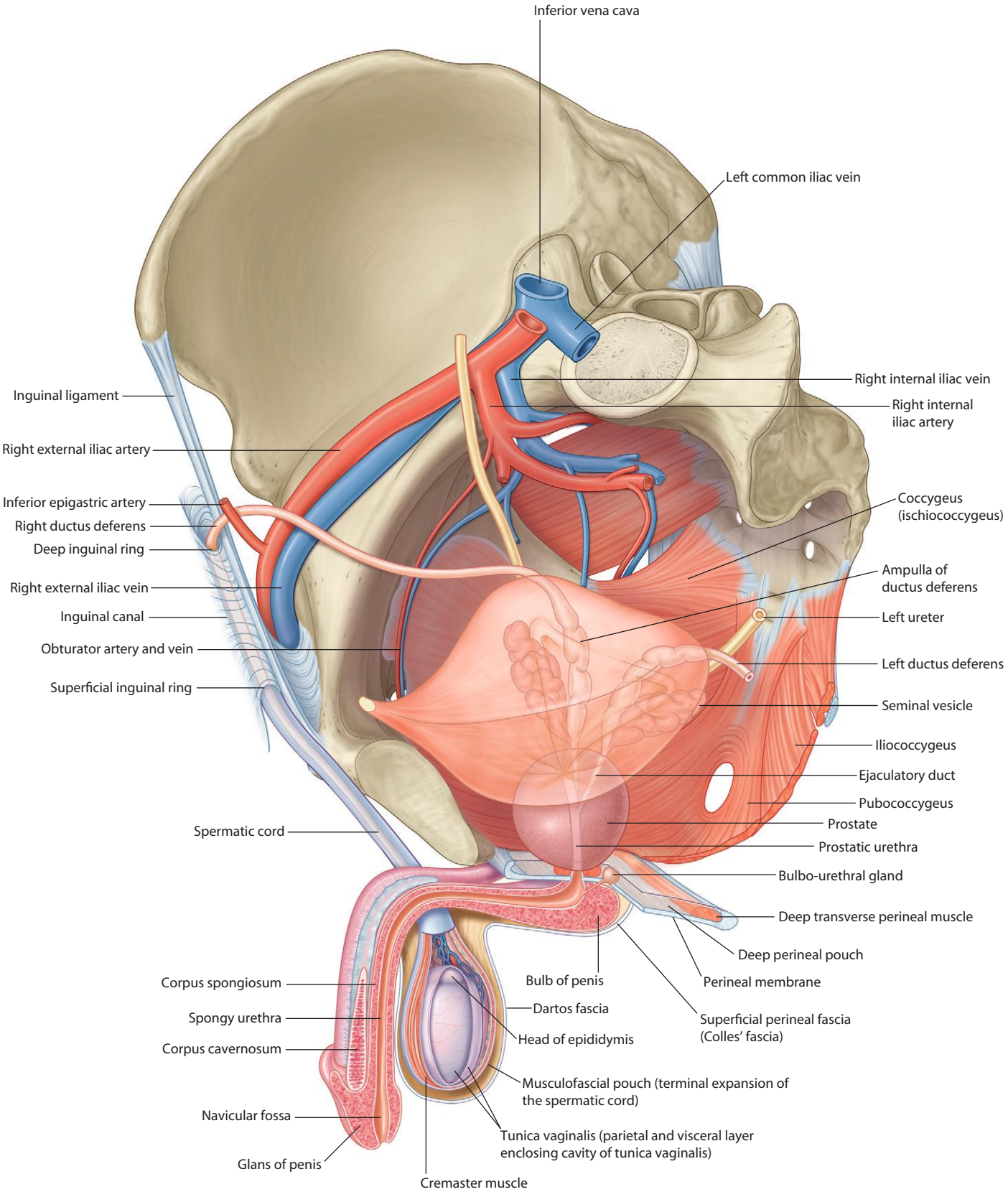

Reproductive system in men (oblique sagittal view)

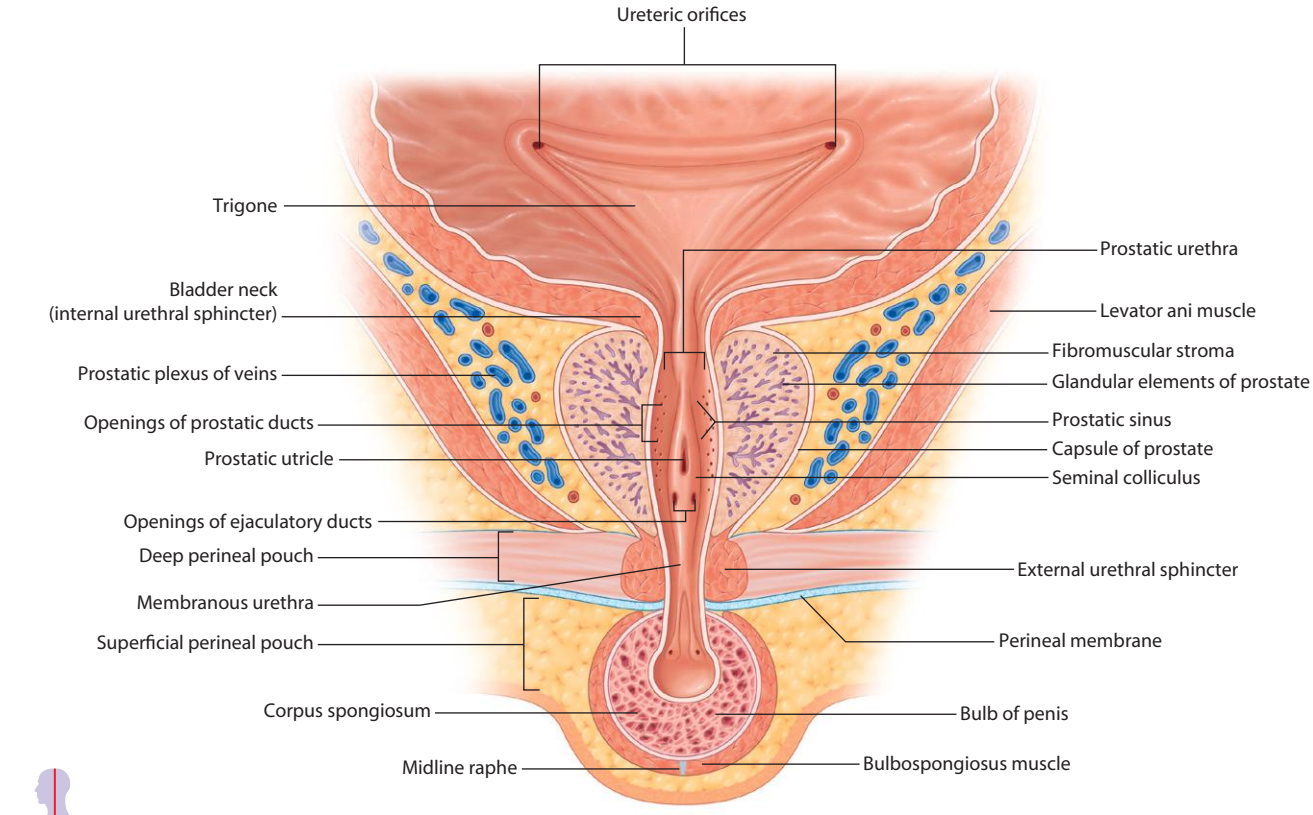

Coronal secion through bladder and prostate (anterior view)

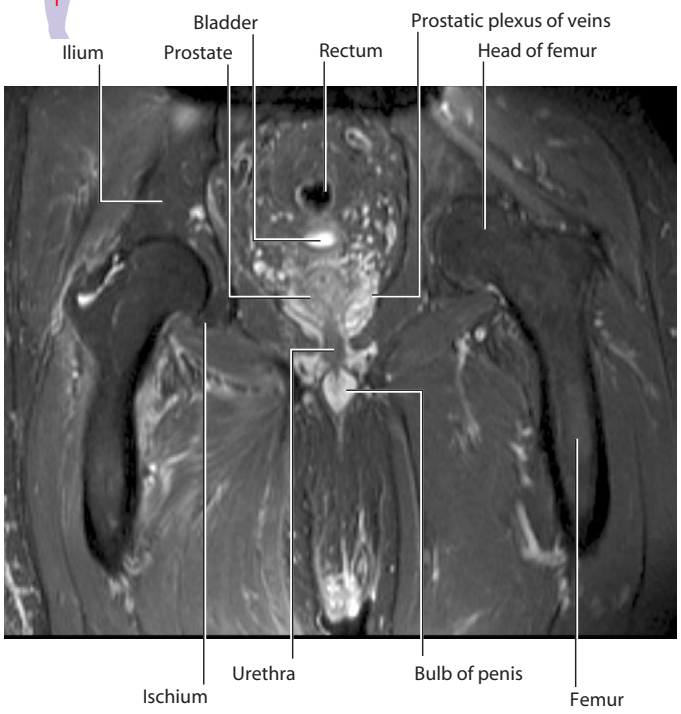

Appearance and positioning of bladder and prostate in relation to other structures in the male pelvis and perineum.
Fat-saturated T2-weighted MR image in coronal plane

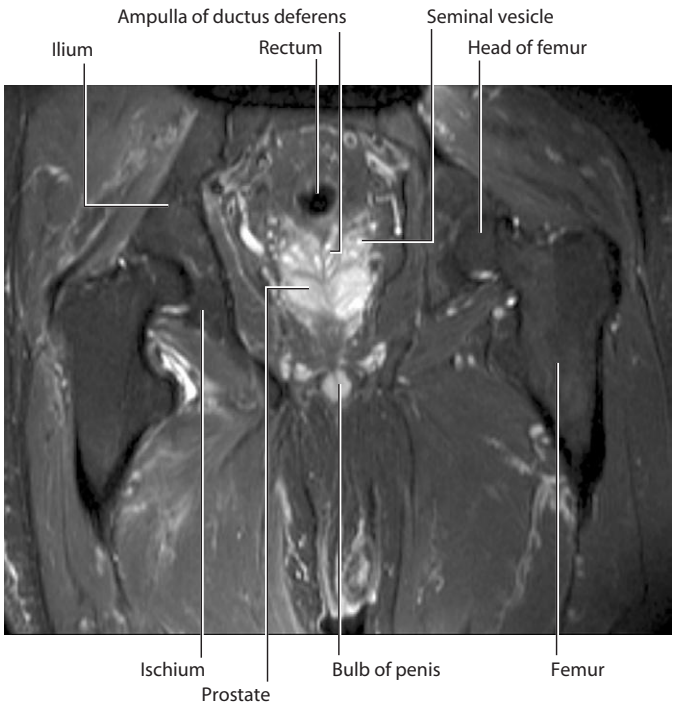

Appearance and positioning of ductus deferens and seminal vesicles in relation to other structures in the male pelvis and perineum.
Fat-saturated T2-weighted MR image in coronal plane

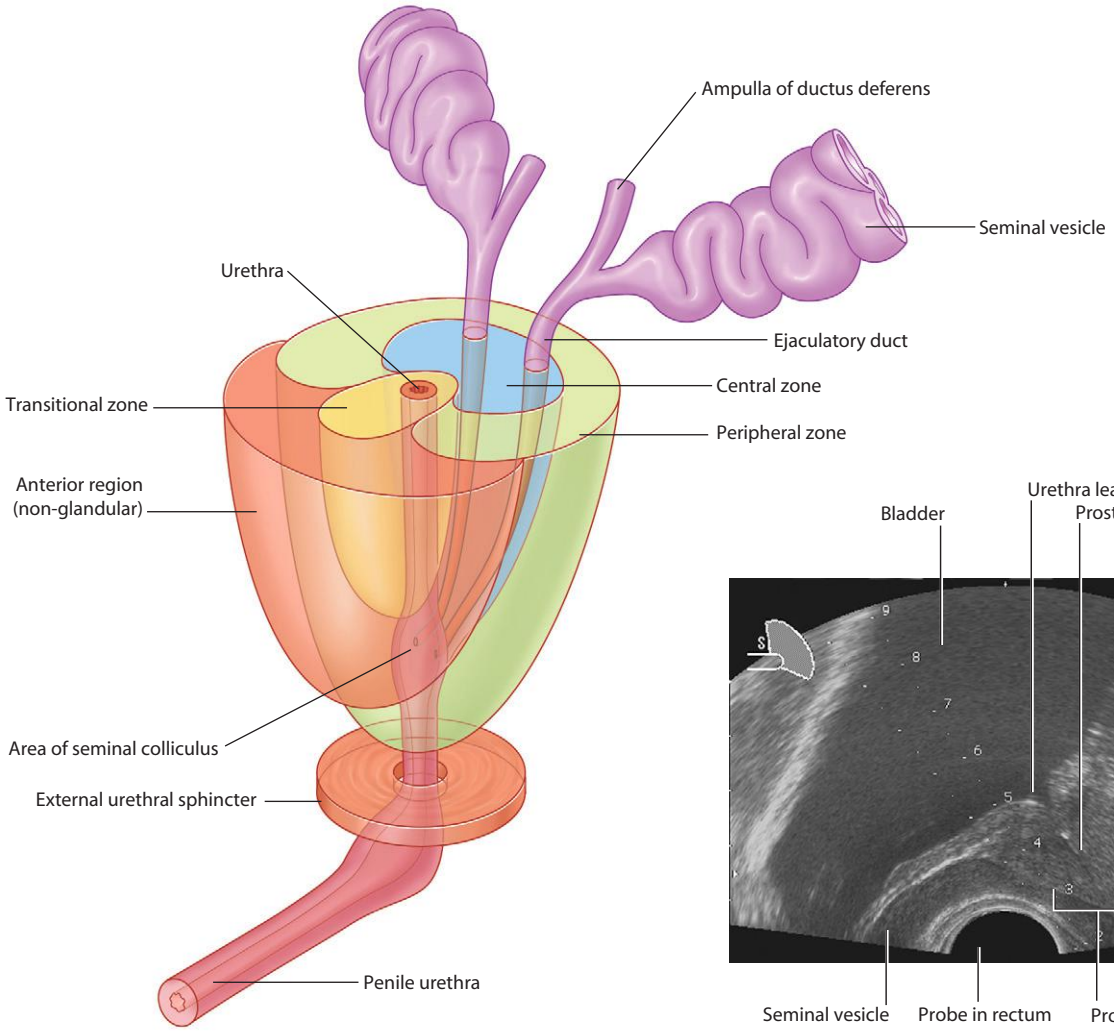

**Zonal anatomy of the prostate gland.
Most carcinomas originate in the peripheral zone.
Benign prostatic hypertrophy (BPH)
affects mainly the transitional zone**

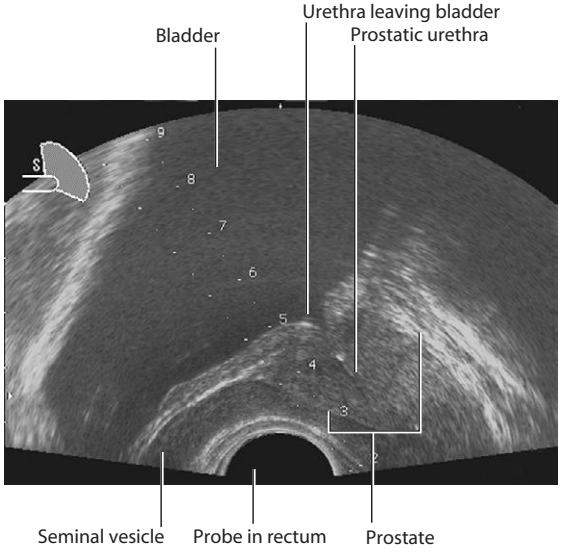

Rectal ultrasound imaging of the prostate, bladder, and seminal vesicle. Sagittal view also showing the urethra

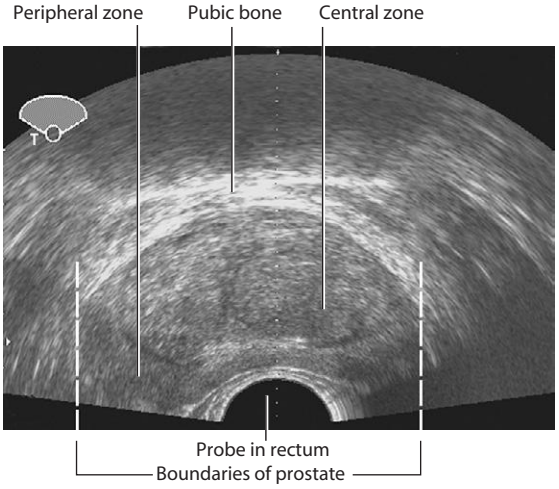

**Rectal ultrasound imaging of the prostate.
Axial view showing the central and peripheral zones**

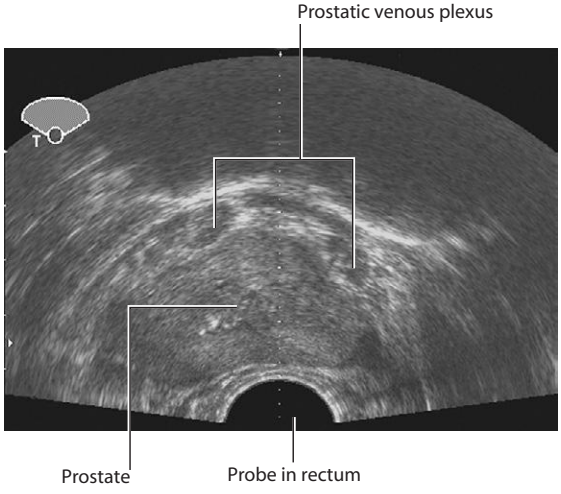

**Rectal ultrasound imaging of the prostate.
Axial view showing the surrounding plexus of veins**

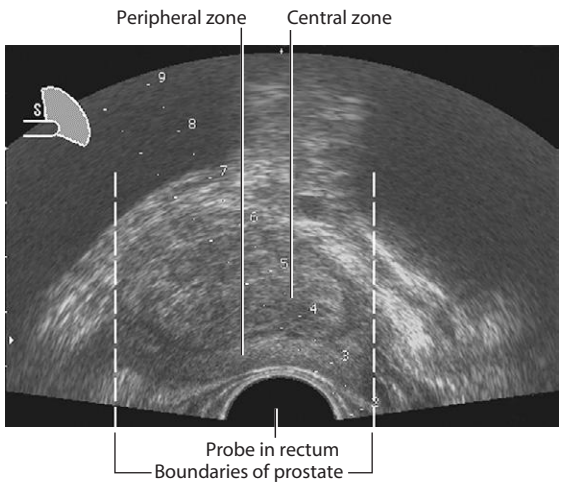

Rectal ultrasound imaging of the prostate.
Sagittal view showing the central and peripheral zones

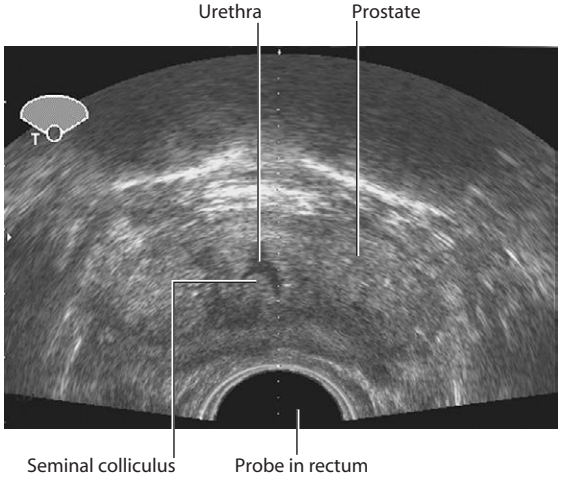

Rectal ultrasound imaging of the prostate.
Axial view showing the urethra and seminal colliculus

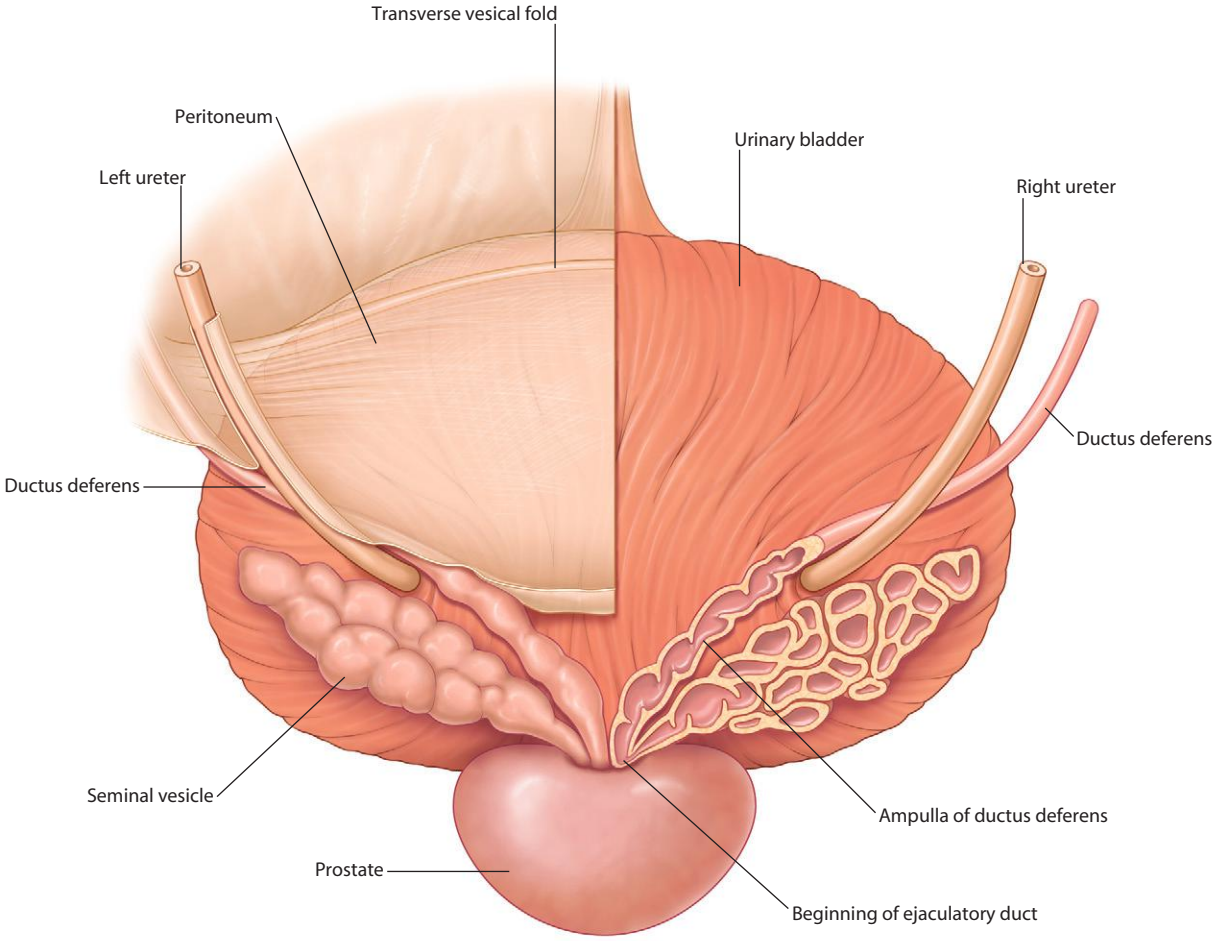

Bladder and prostate (posterior view)

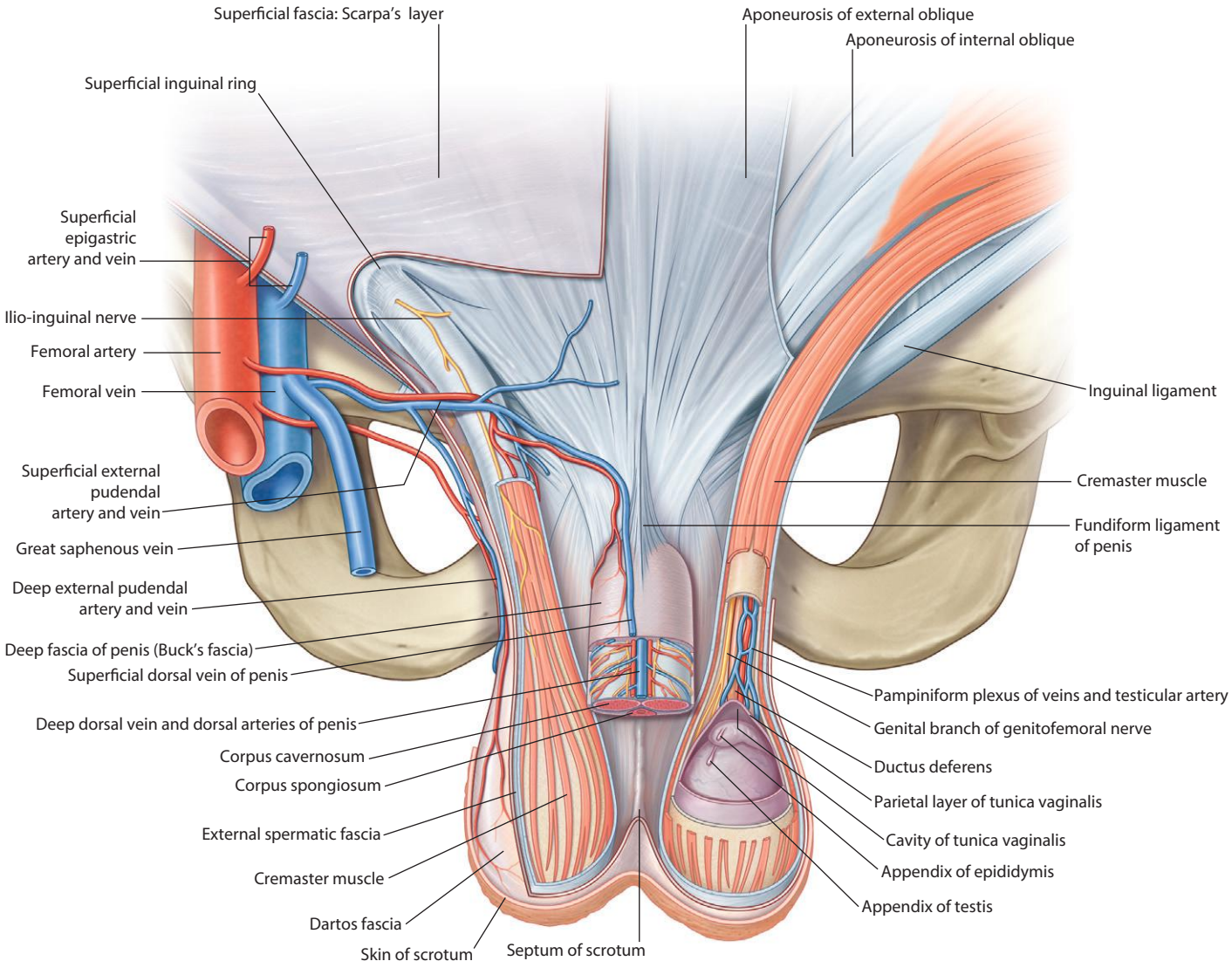

Contents of the scrotum (anterior view)

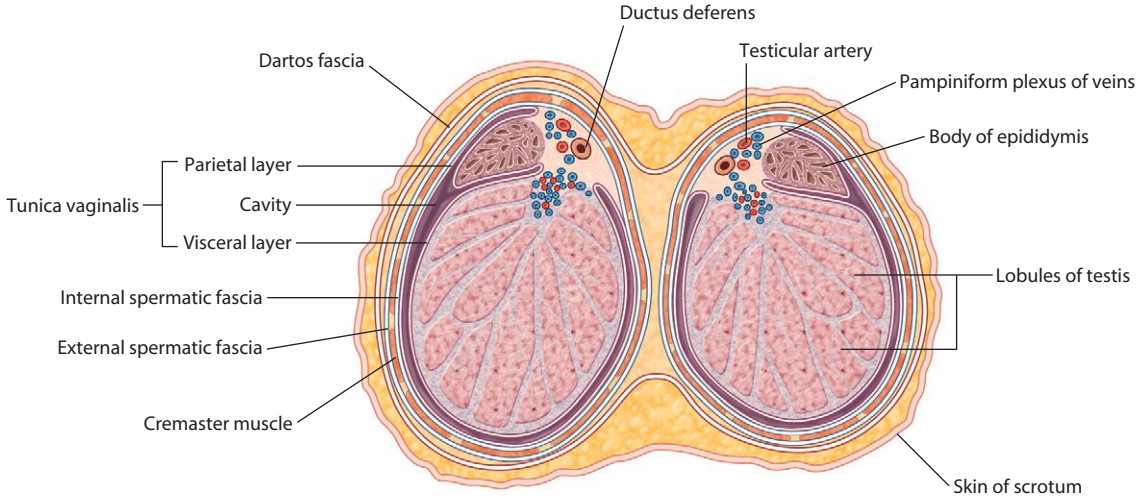

Transverse section through the scrotum and testes

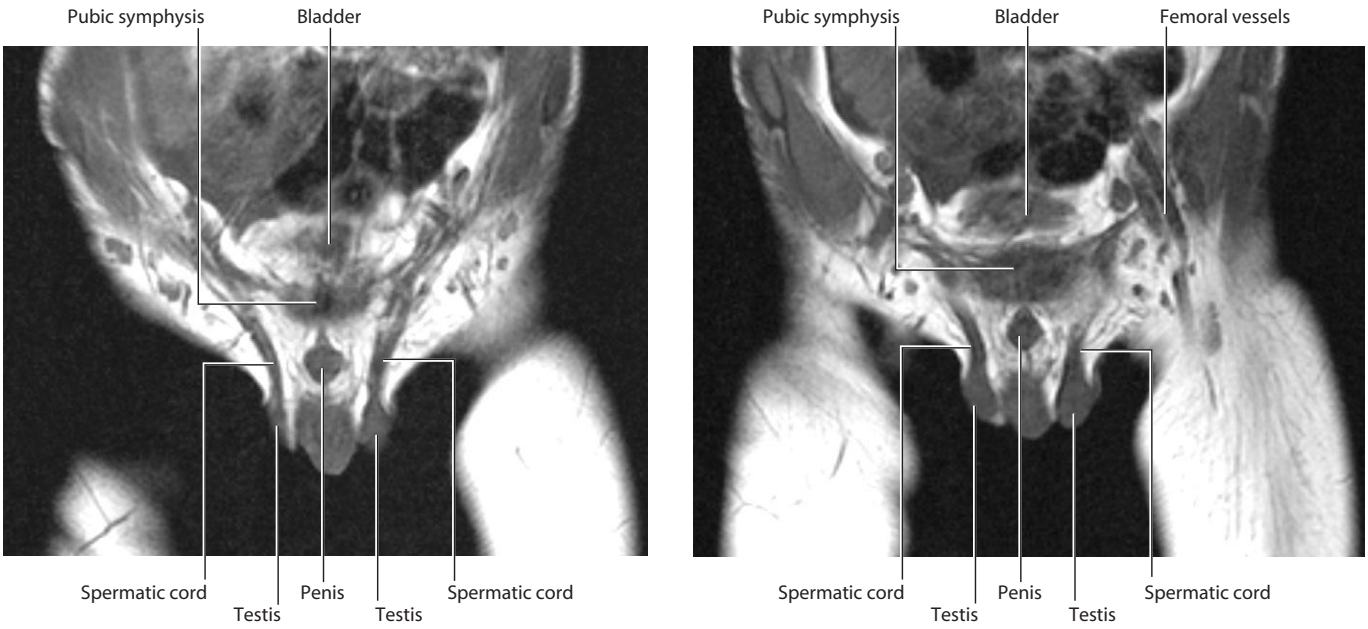

Spermatic cord appearance and positioning in a young male.
T1-weighted MR images in coronal plane

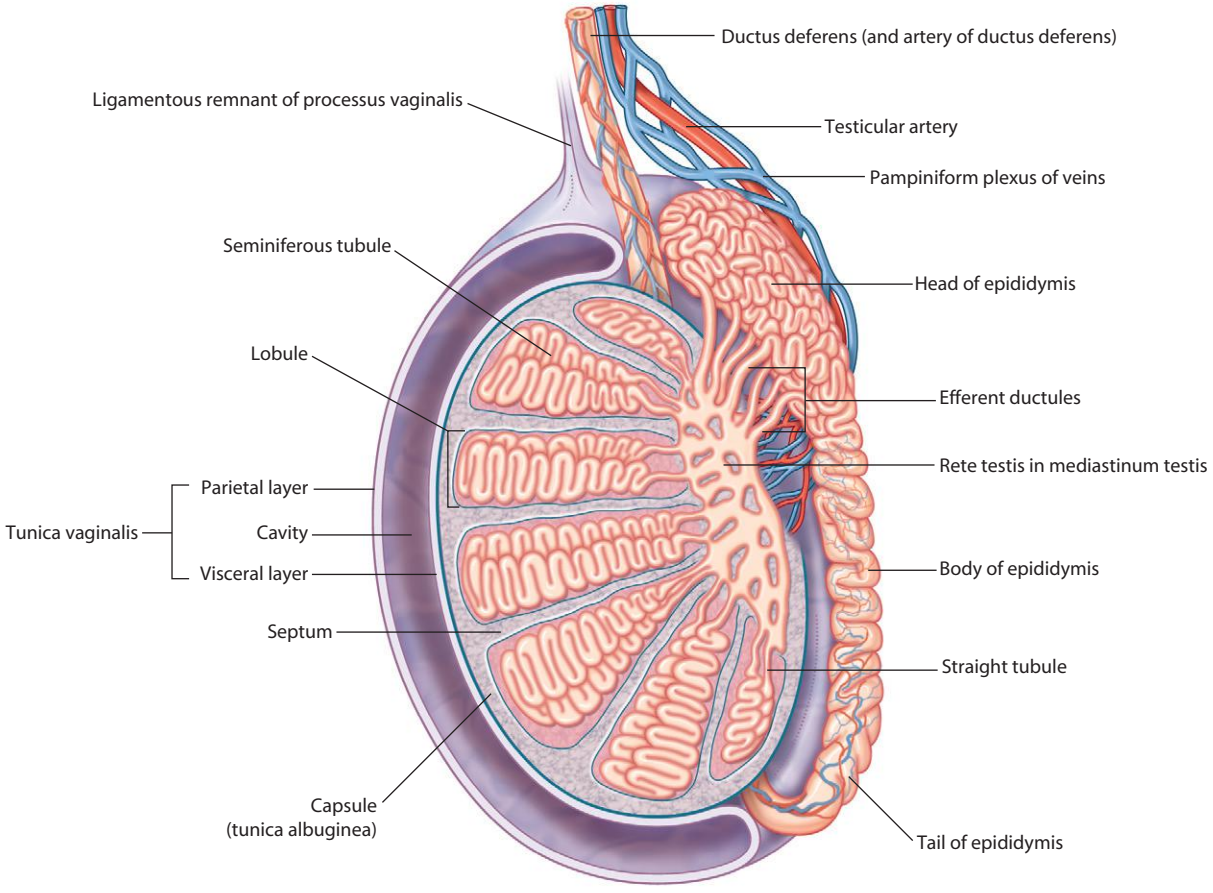

Testis and surrounding structures

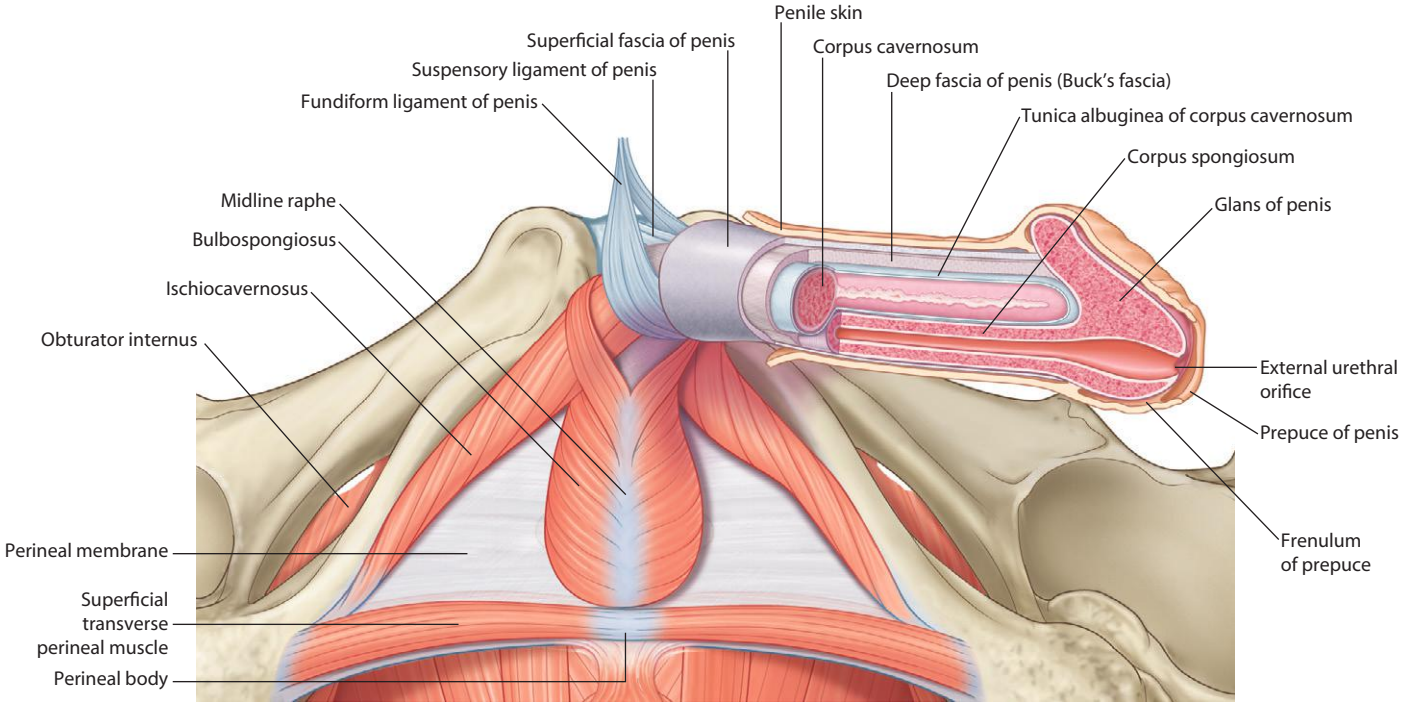

Structure of the penis

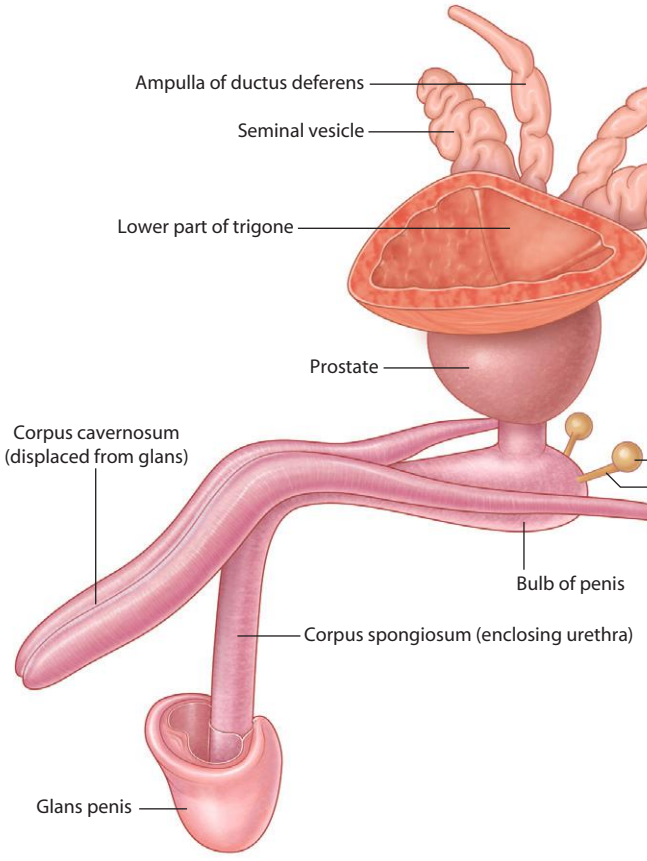

Structure of the penis

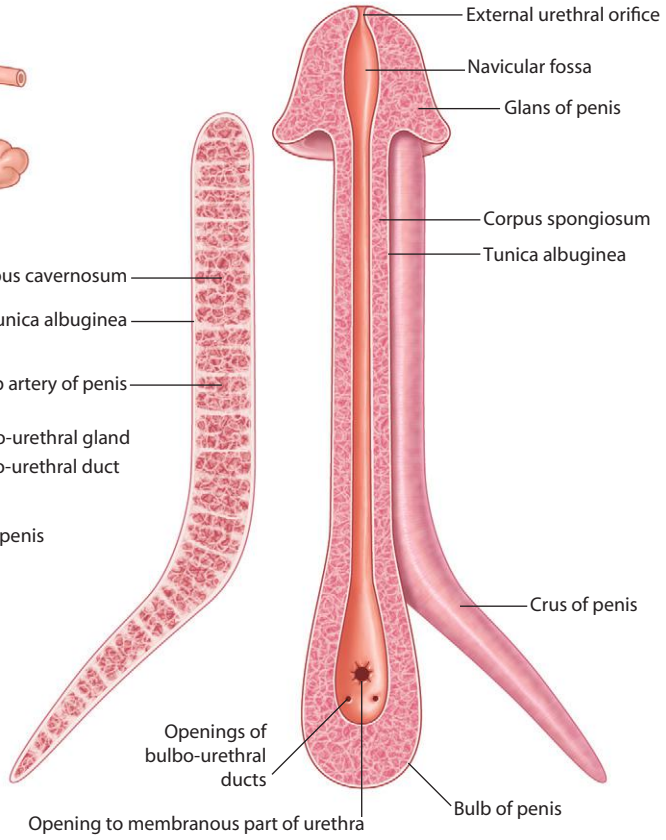

Roof of spongy urethra (inferior view)

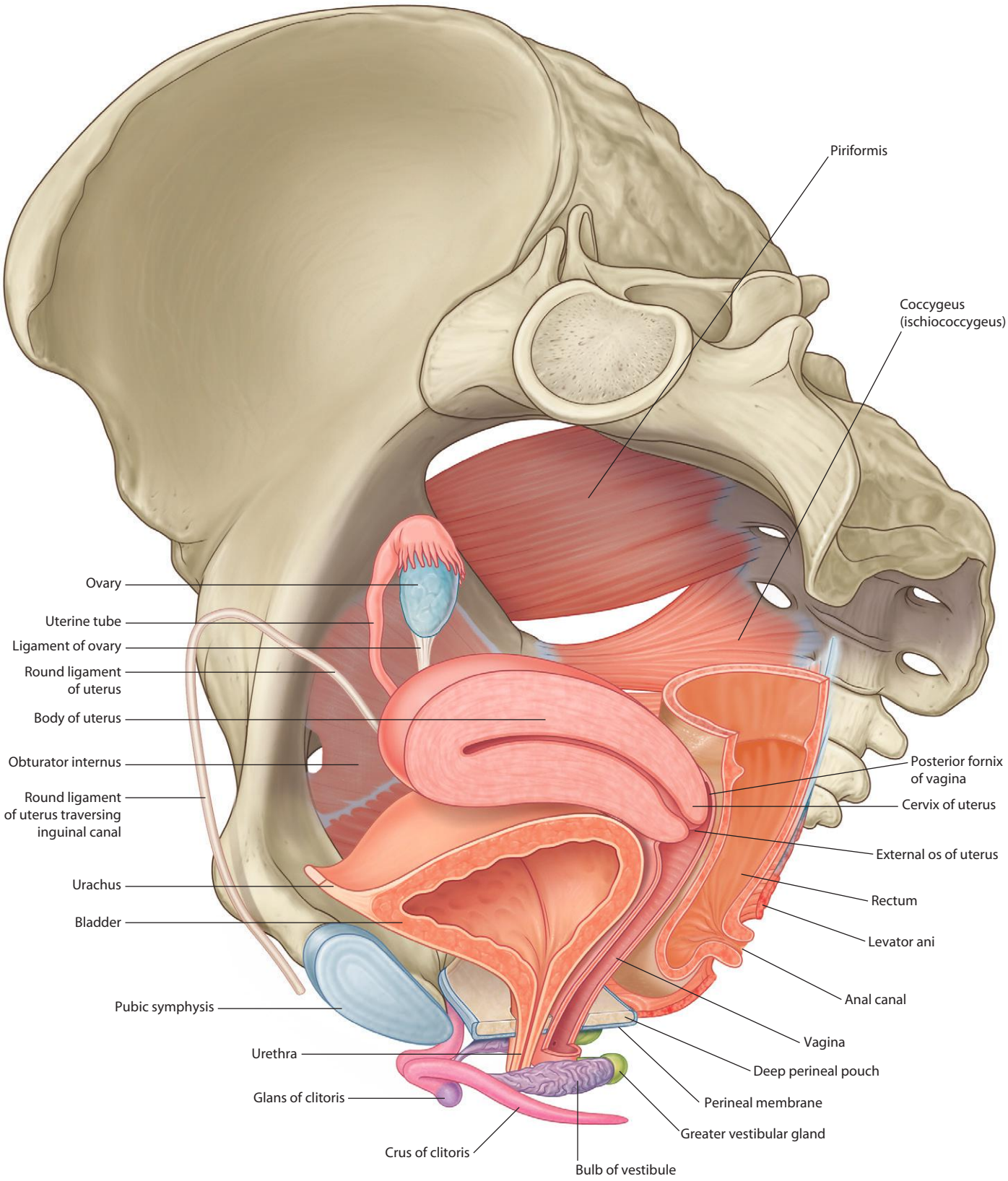

Reproductive system in women (oblique sagittal view)

Surface projection of the uterus

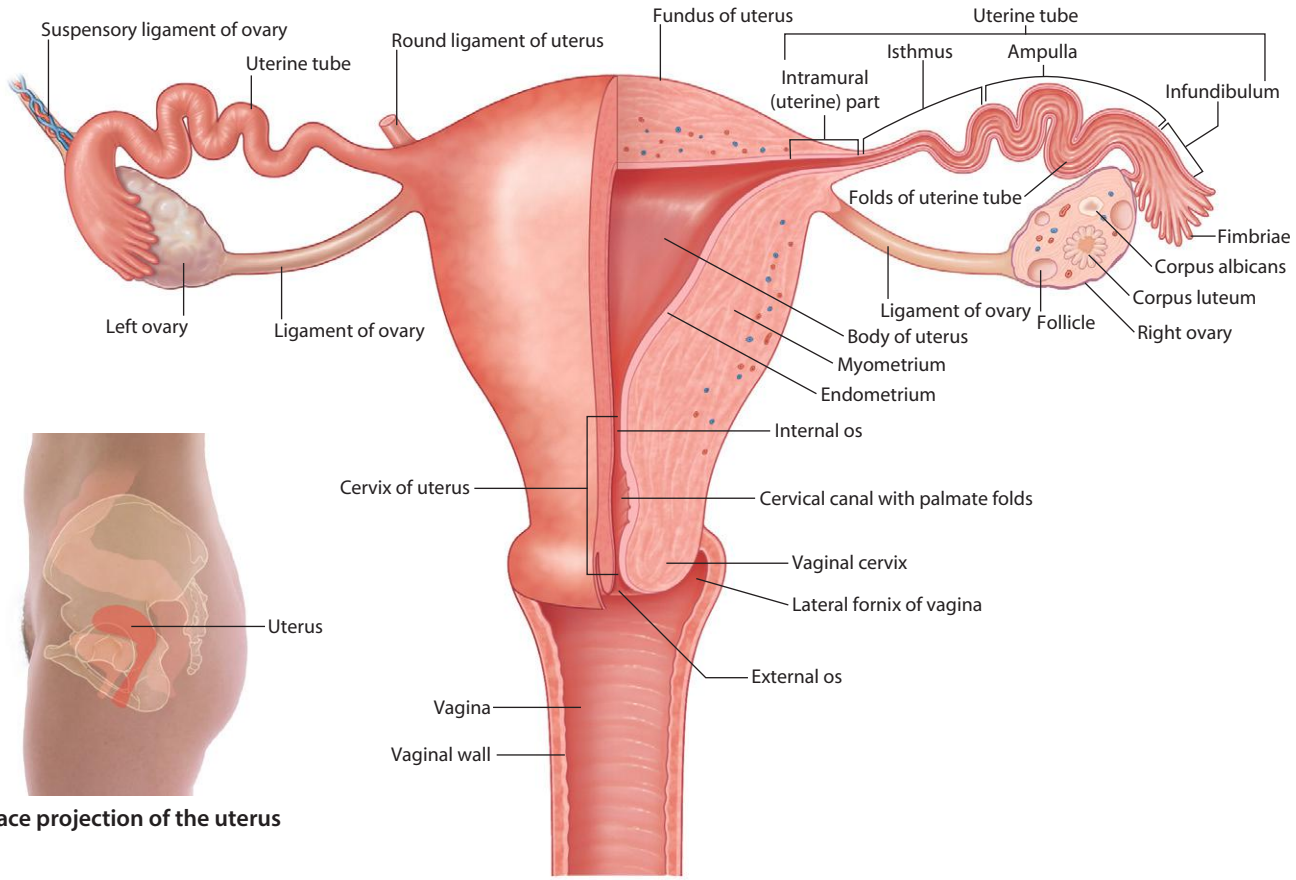

Structure of the uterus and ovaries (posterior view)

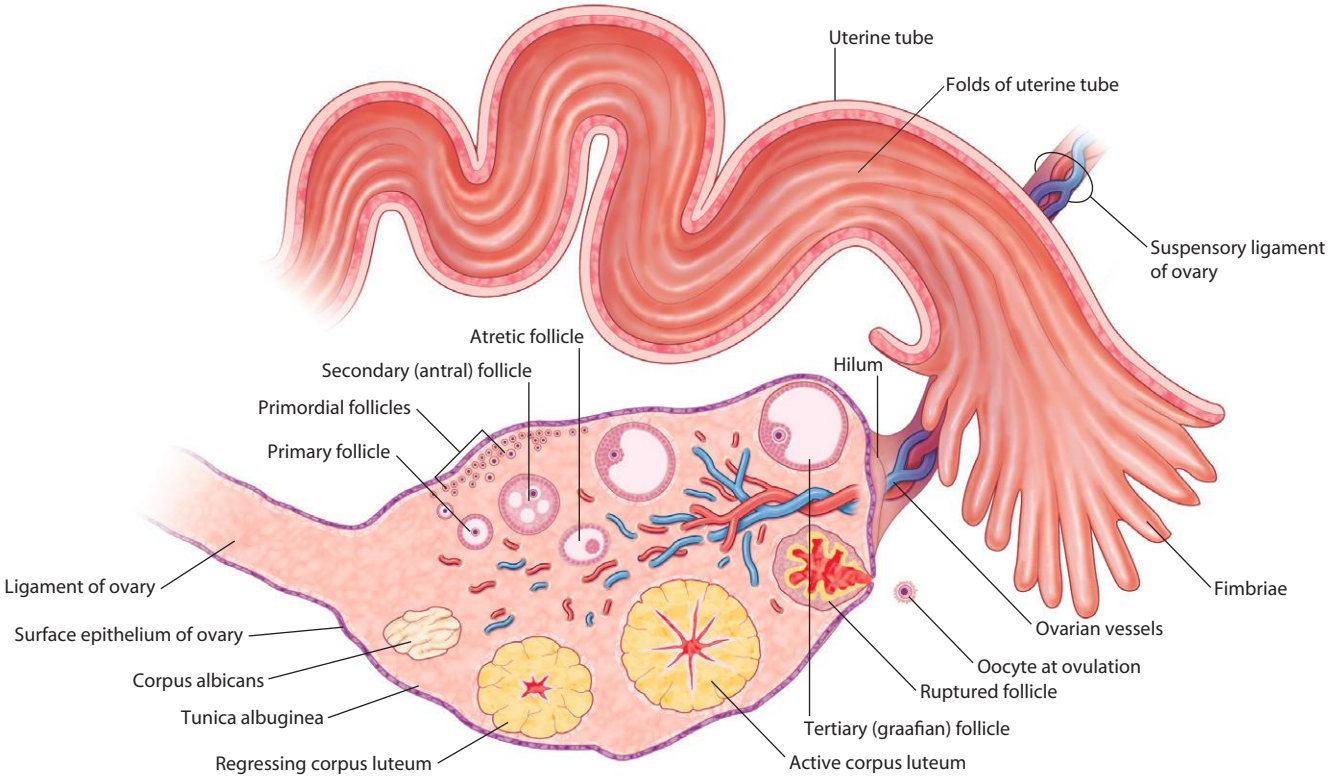

Structure of the uterine tube and ovary (posterior view)

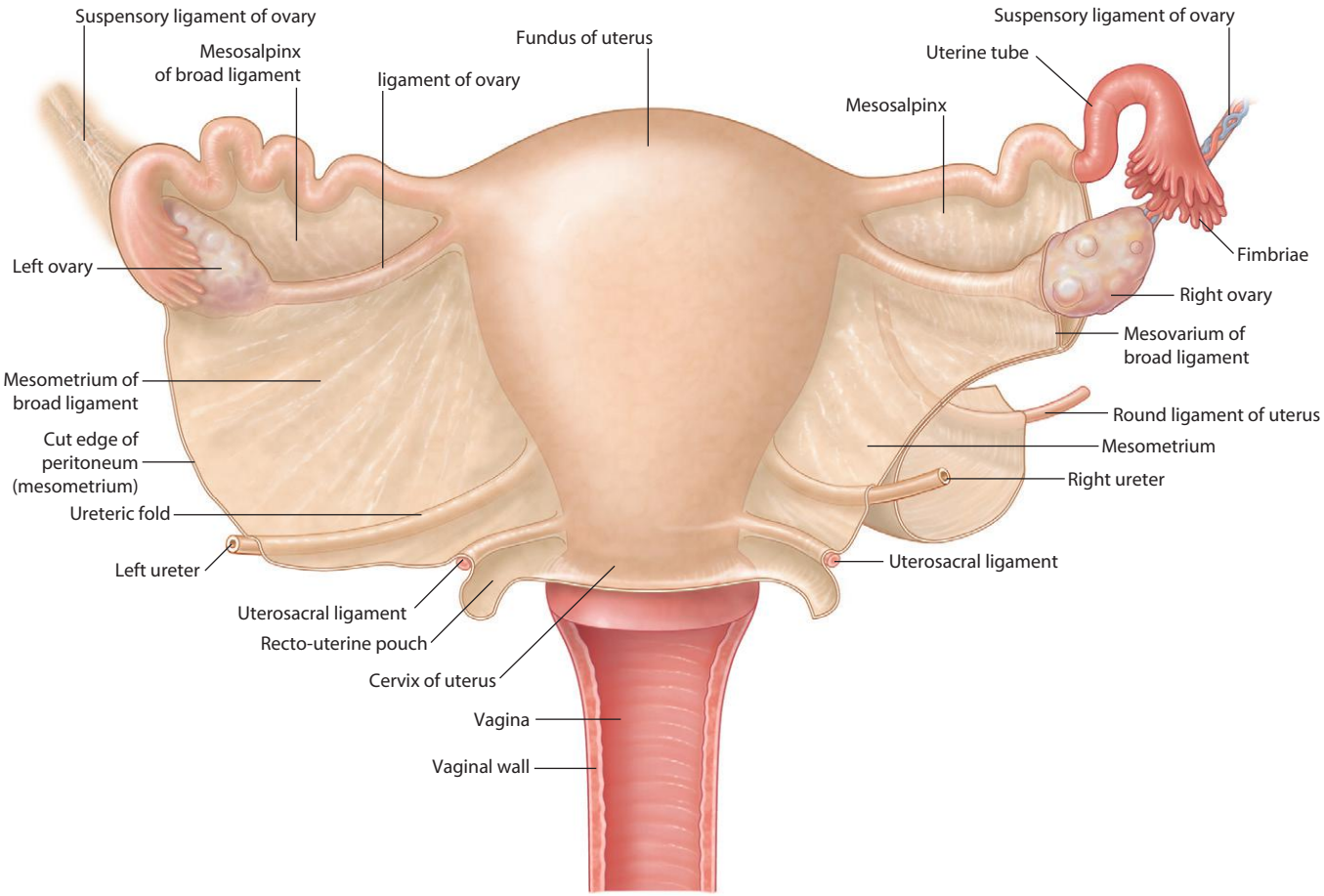

Uterus and broad ligament (posterior view)

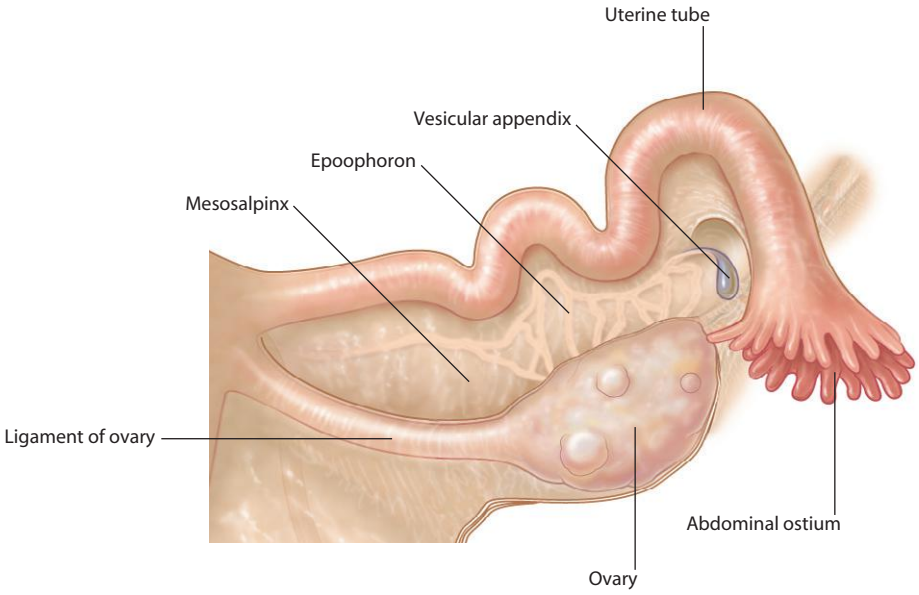

Uterine tube and ovary (posterior view)

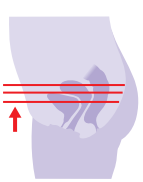

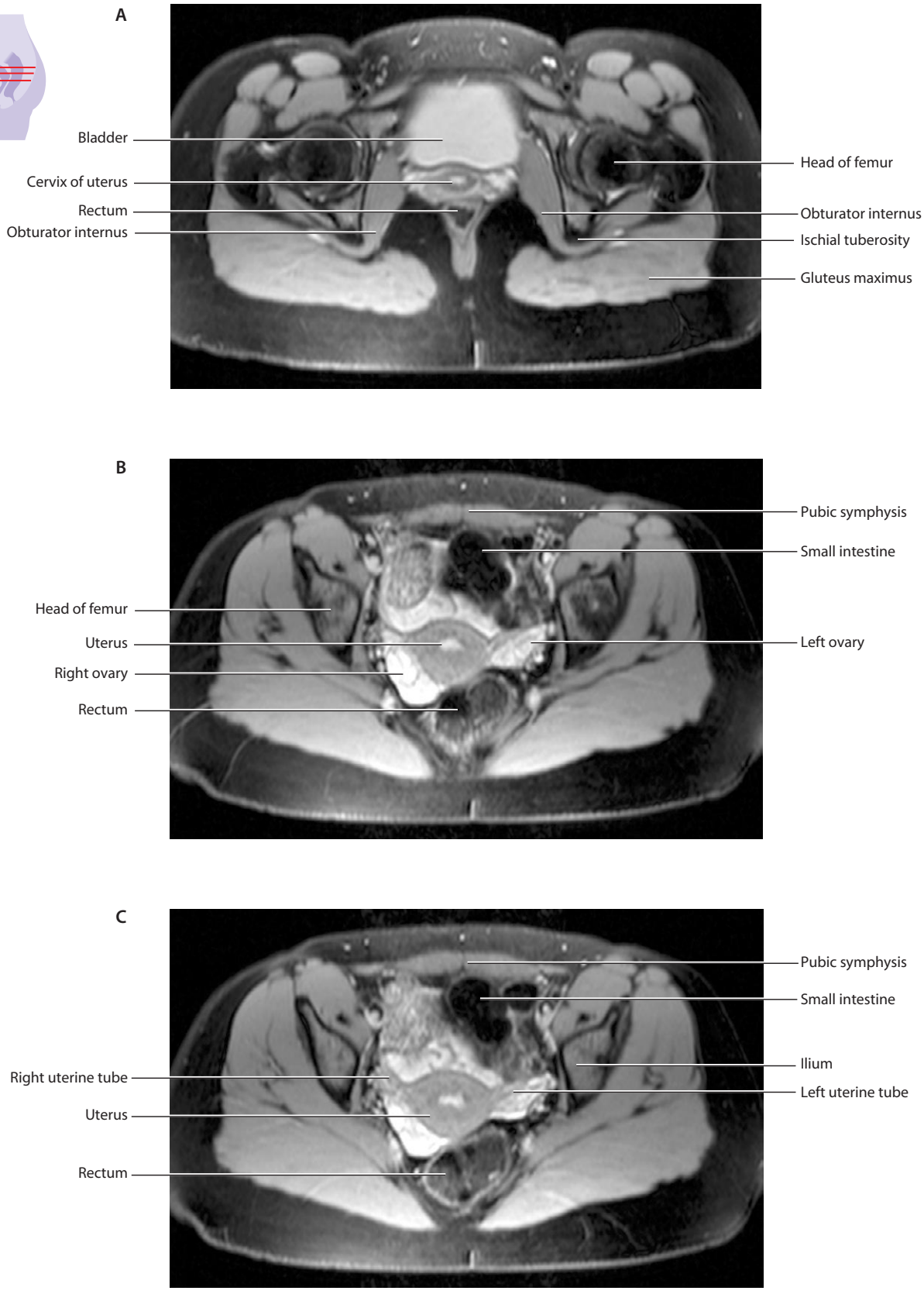

Appearance of cervix of uterus, uterus, ovaries, and uterine tubes in relation to other pelvic structures.
Fat-saturated T2-weighted MR images in axial plane

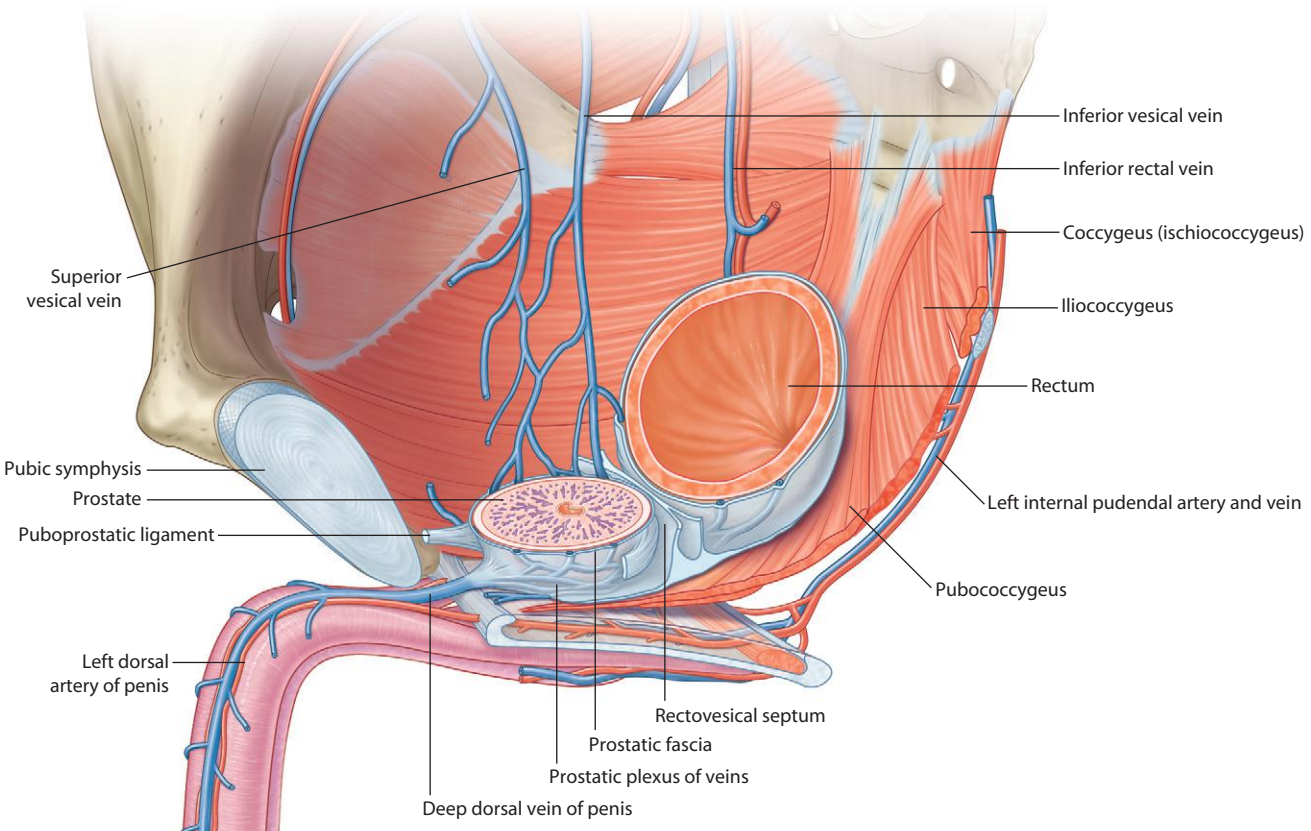

Pelvic fascia and related structures in men

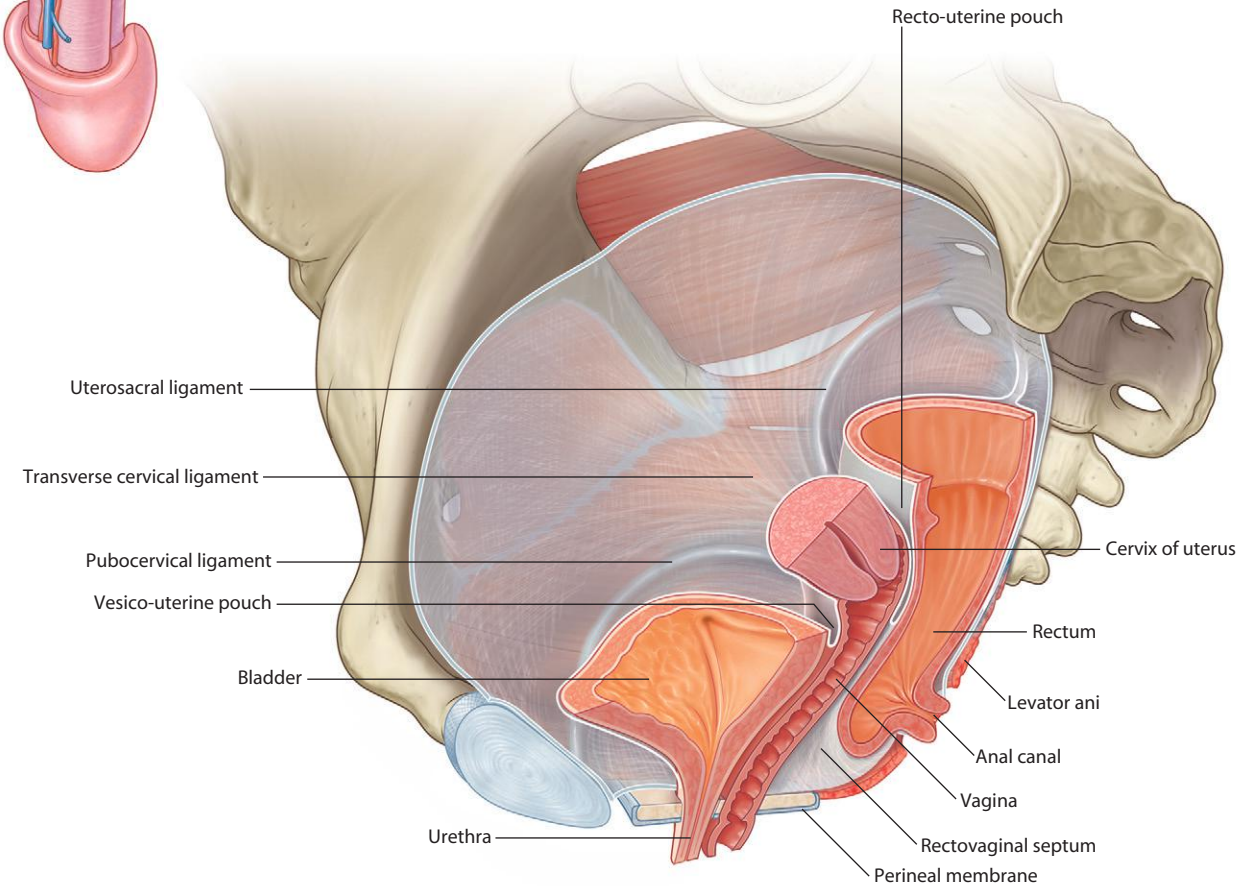

Pelvic fascia and related structures in women

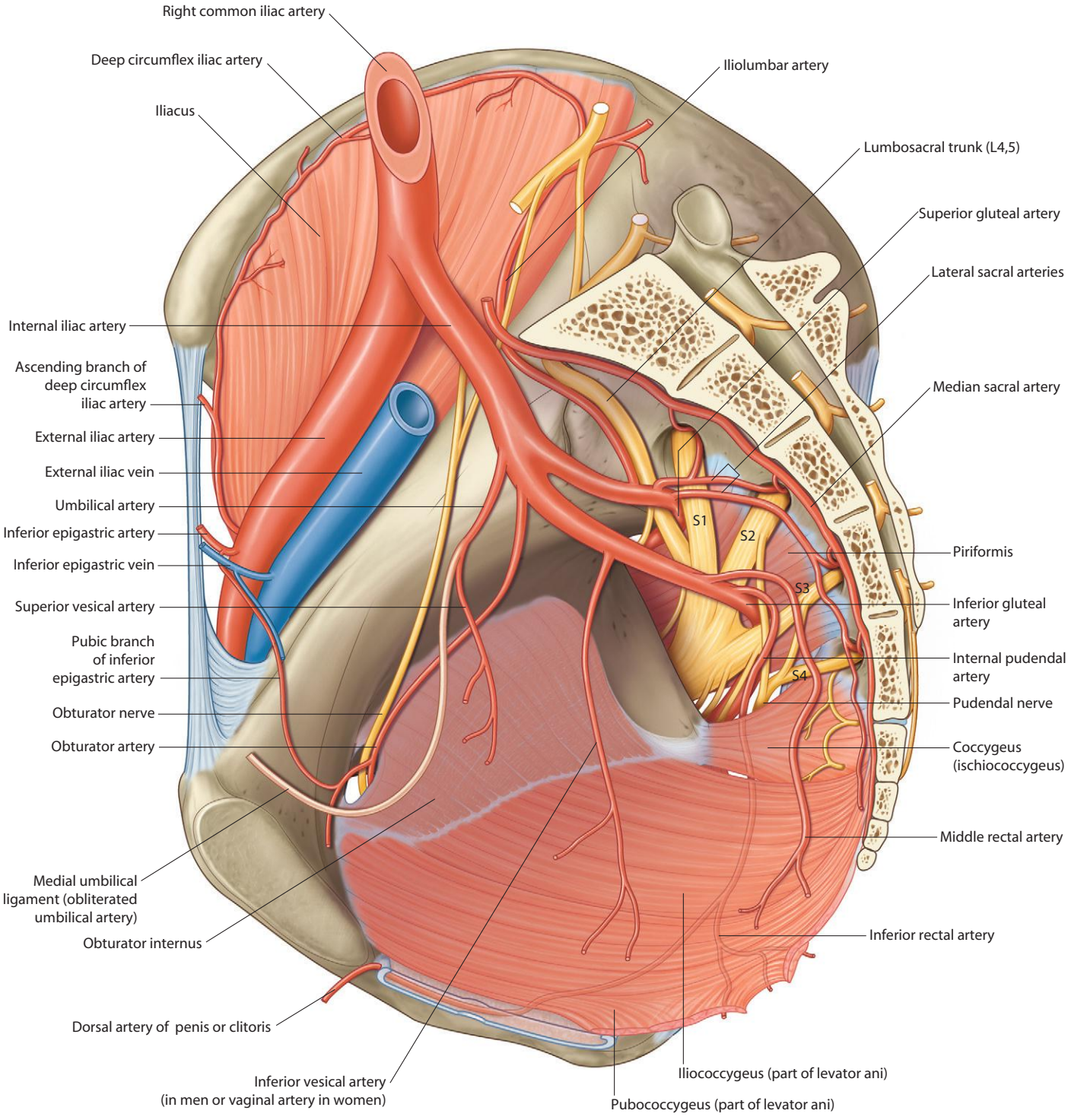

Arterial supply to the pelvis (right side sagittal view)

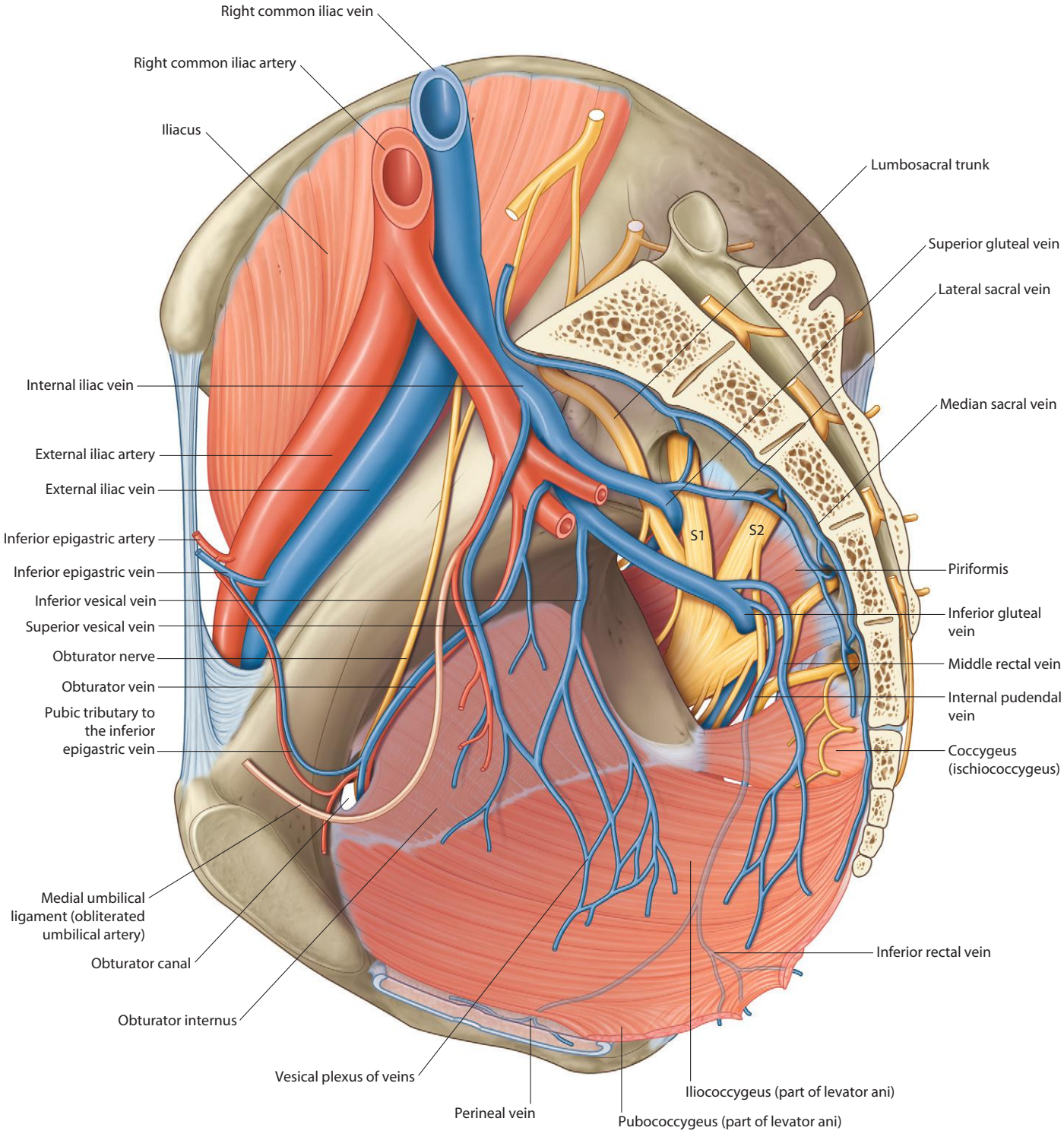

Veins of the pelvis
(right side sagittal view)

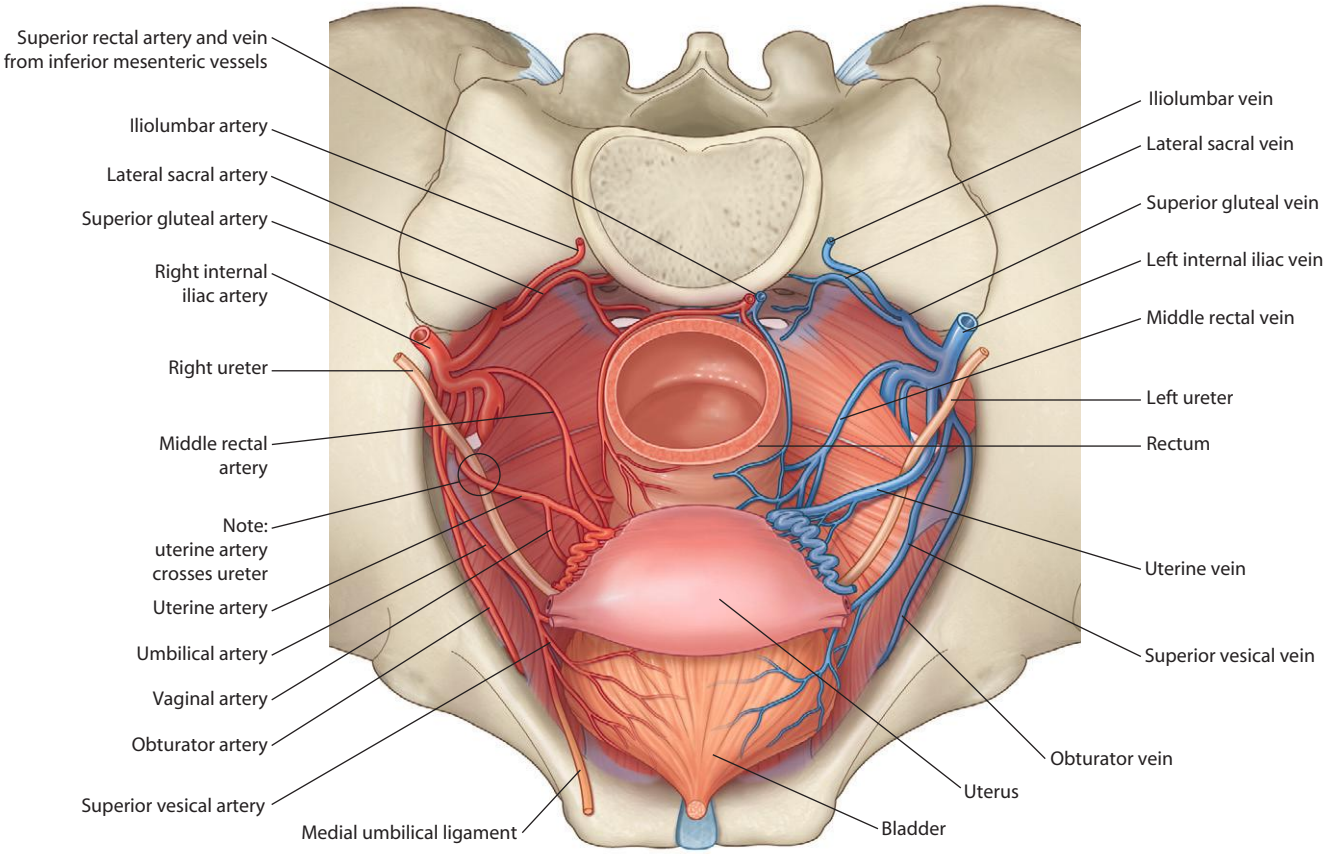

Vasculature of the pelvic viscera in women (superior view)

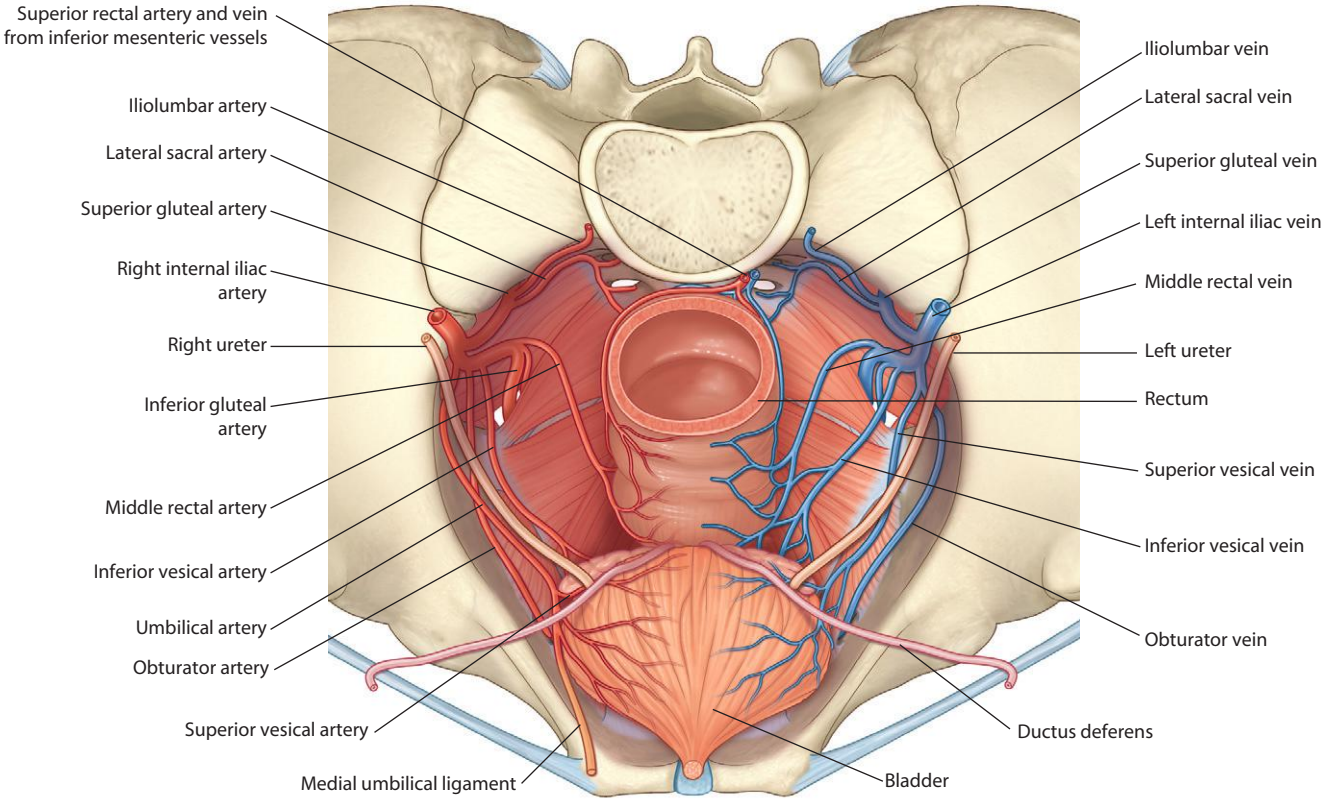

Vasculature of the pelvic viscera in men (superior view)

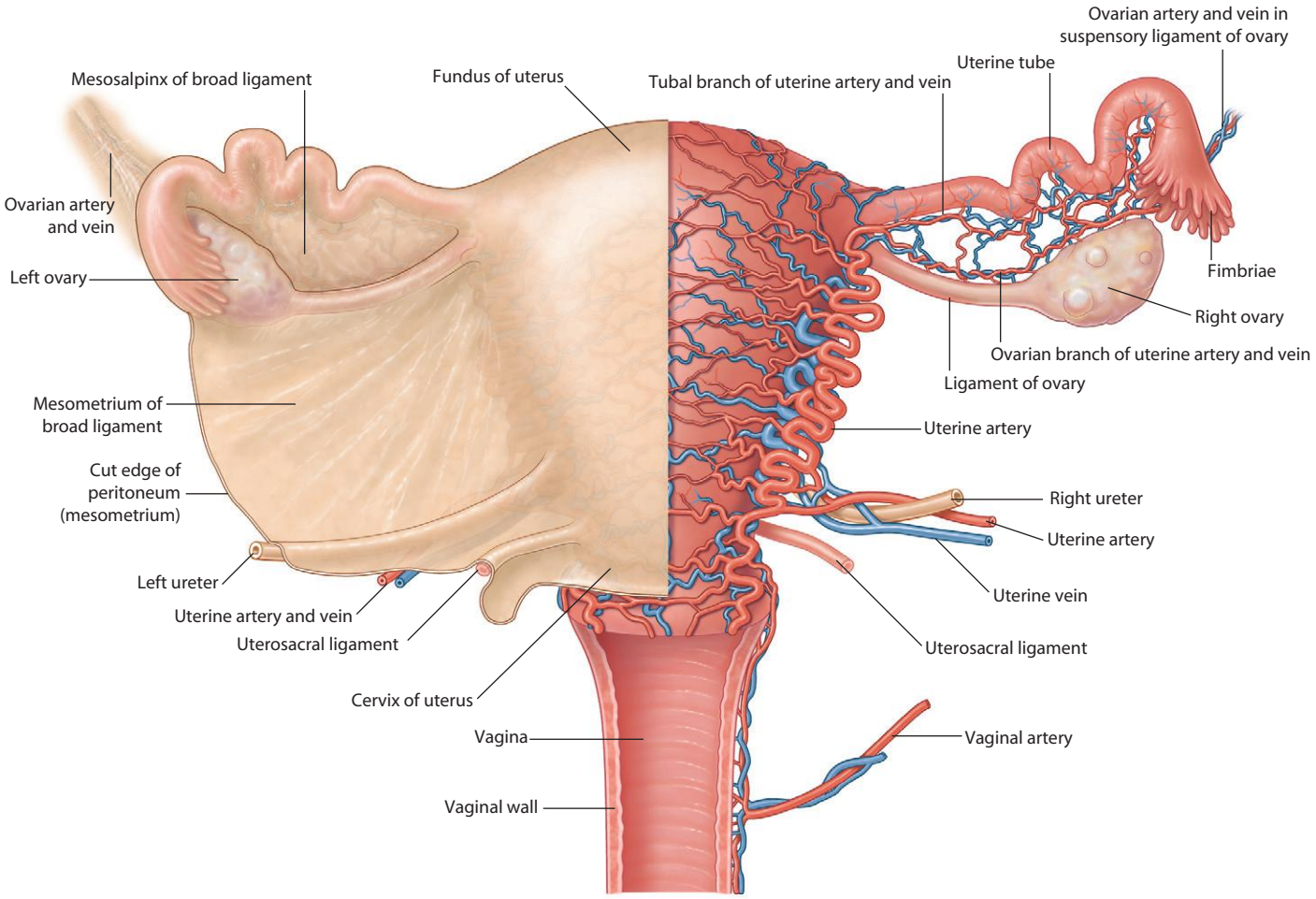

Vascular supply to uterus (posterior view)

Vascular supply to uterus.
Angiogram

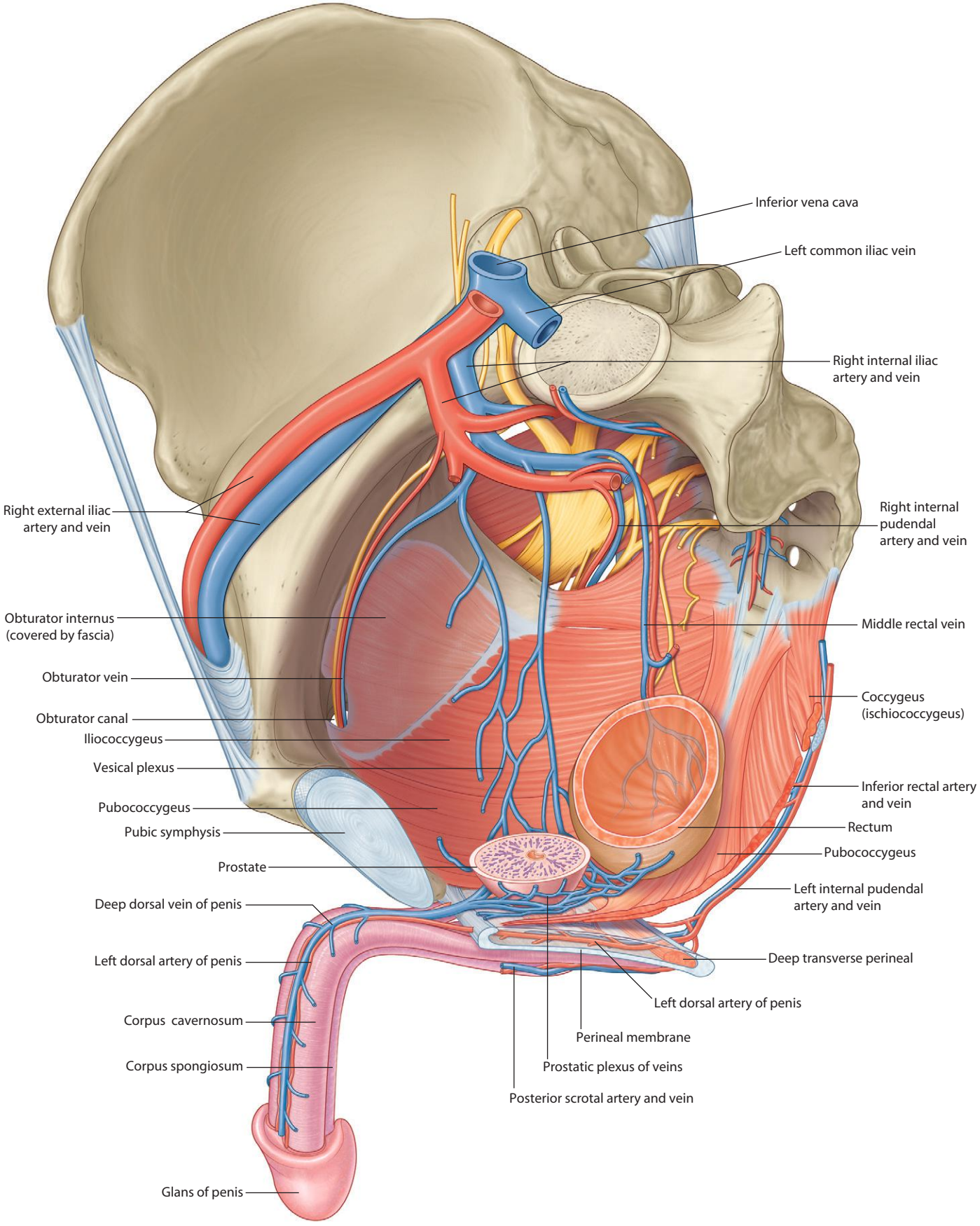

Venous drainage of pelvic viscera in men (oblique sagittal view)

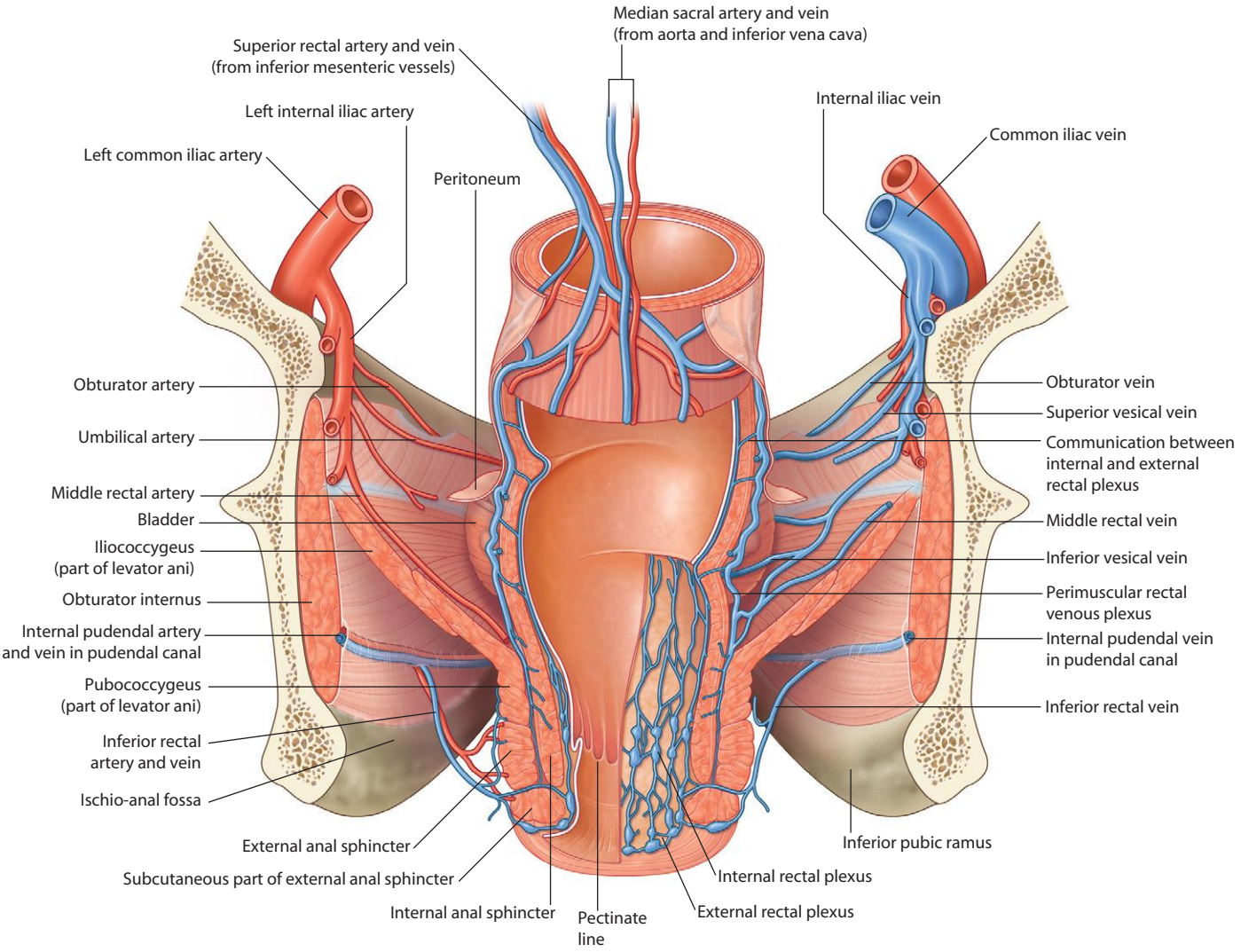

Vasculature of the rectum (posterior view)

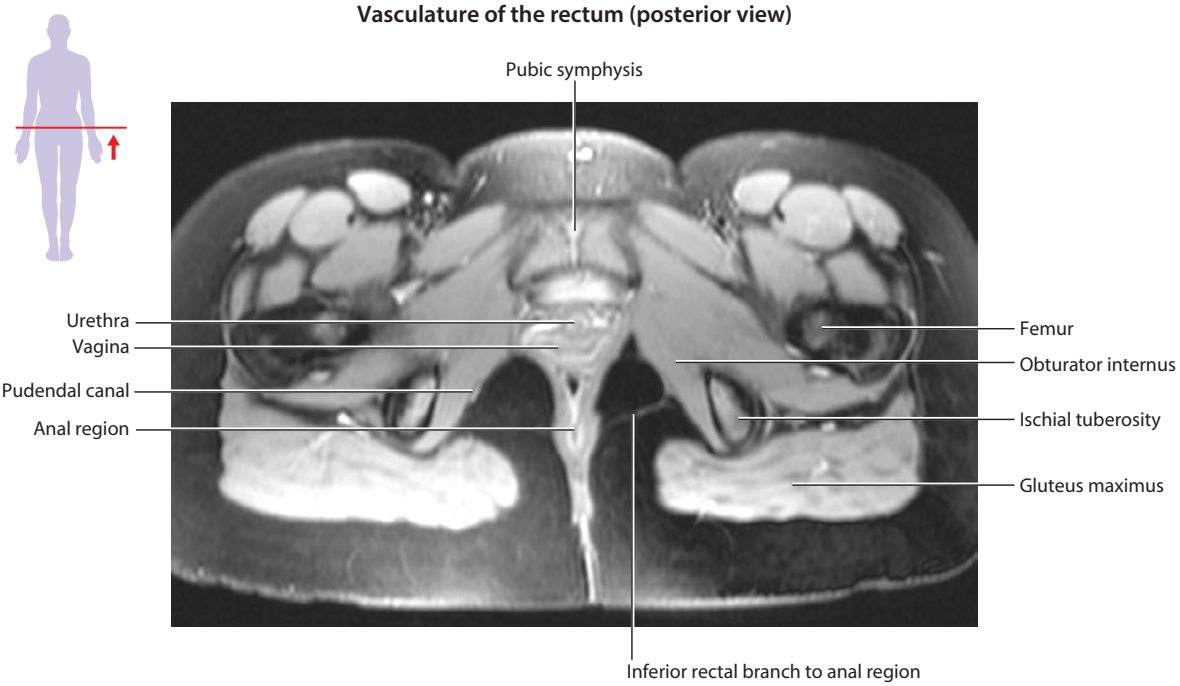

Inferior rectal neurovascular bundle crossing the ischio-anal fossa.
T2-weighted MR image in axial plane

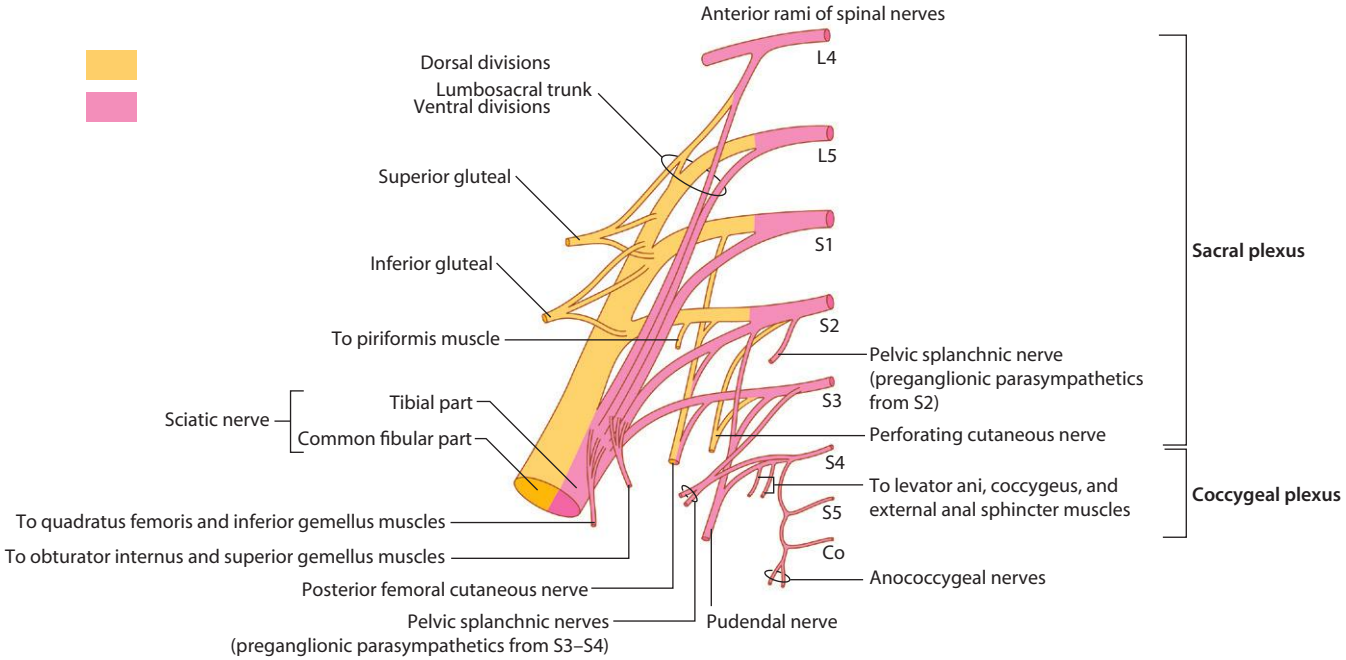

Components and branches of the sacral and coccygeal nerve plexuses

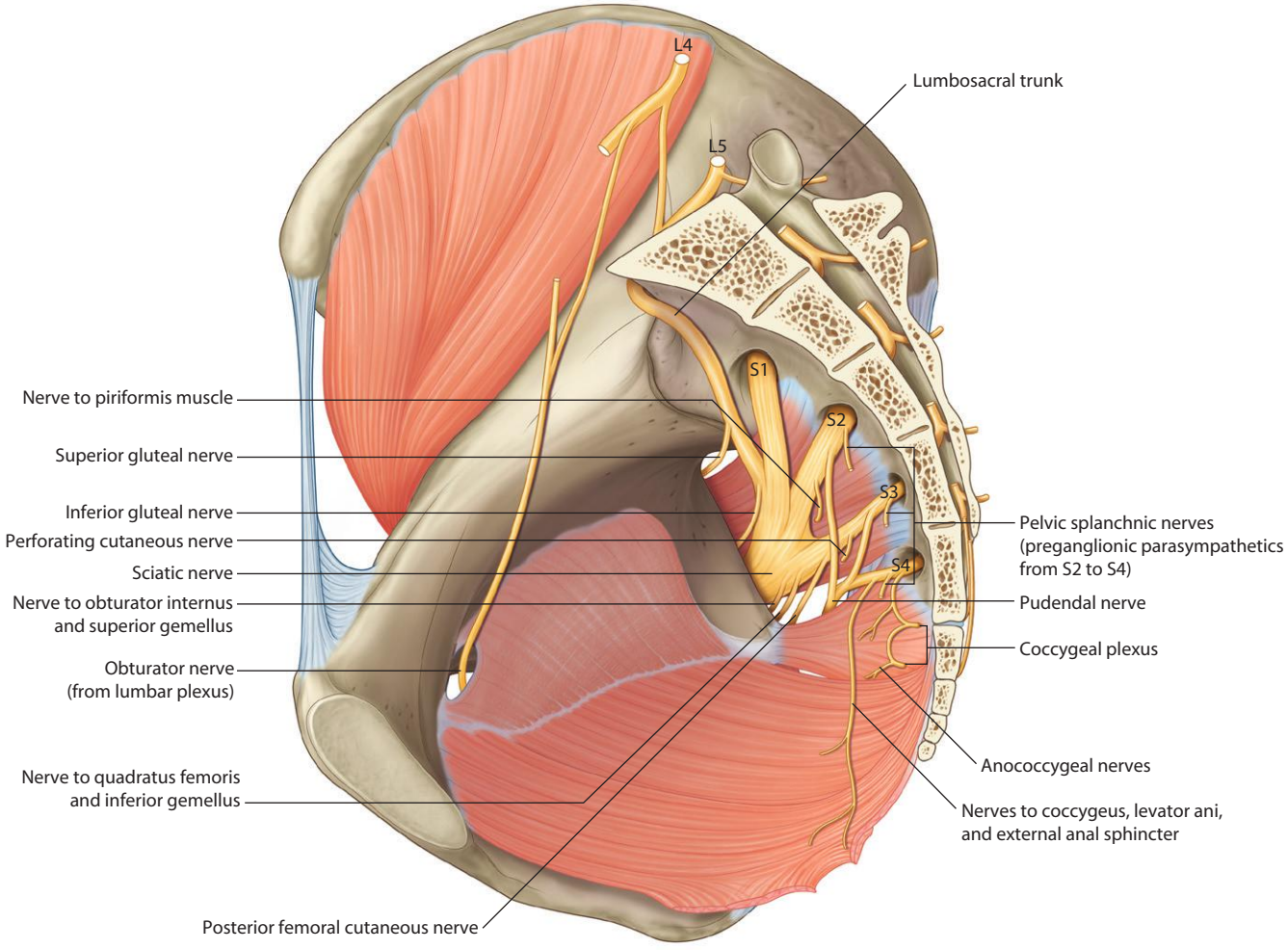

Sacral and coccygeal nerve plexuses within the pelvic cavity (sagittal view)

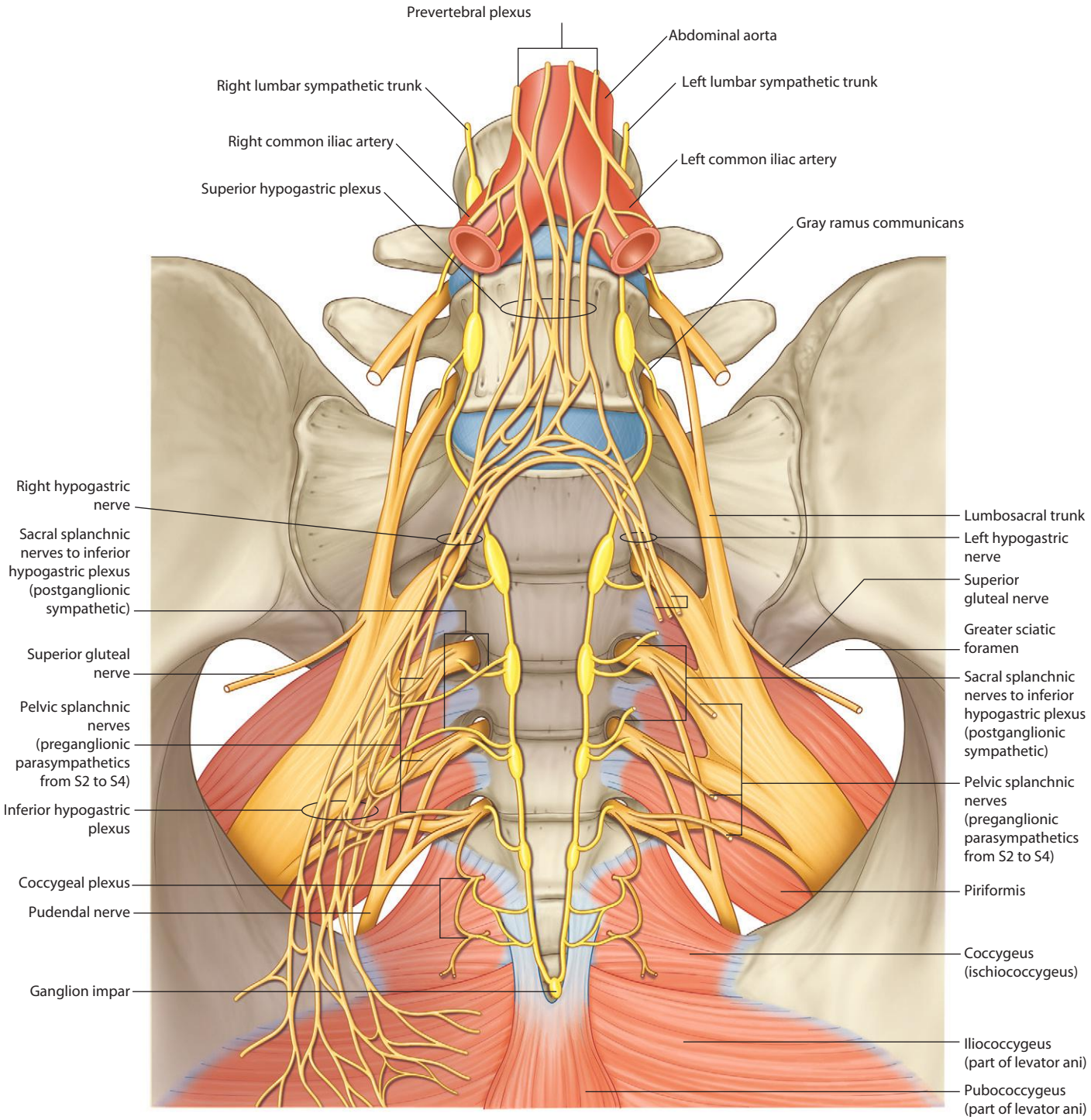

Pelvic extensions of the prevertebral nerve plexus (anterior view)

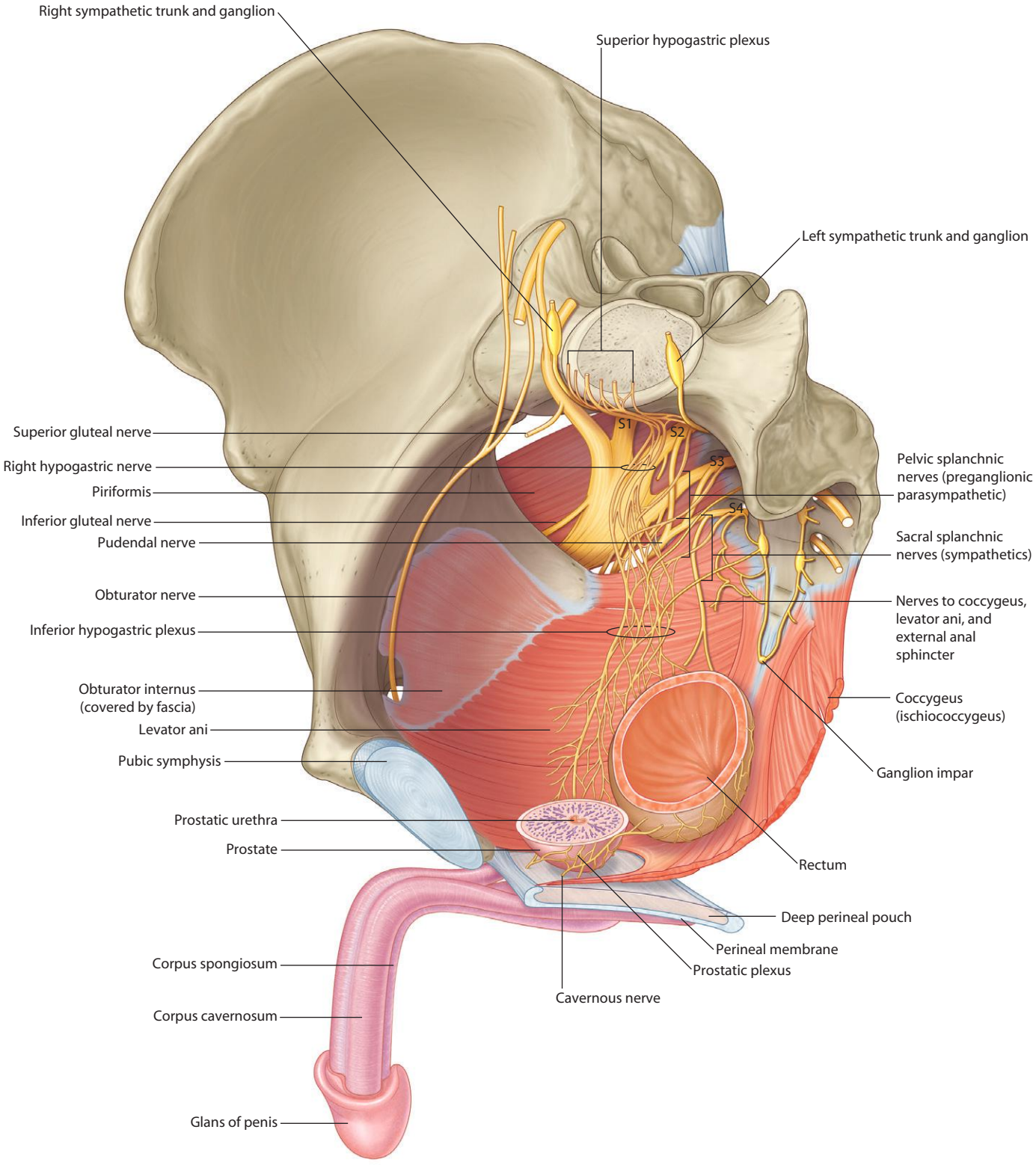

Hypogastric nerve plexuses (oblique sagittal view)

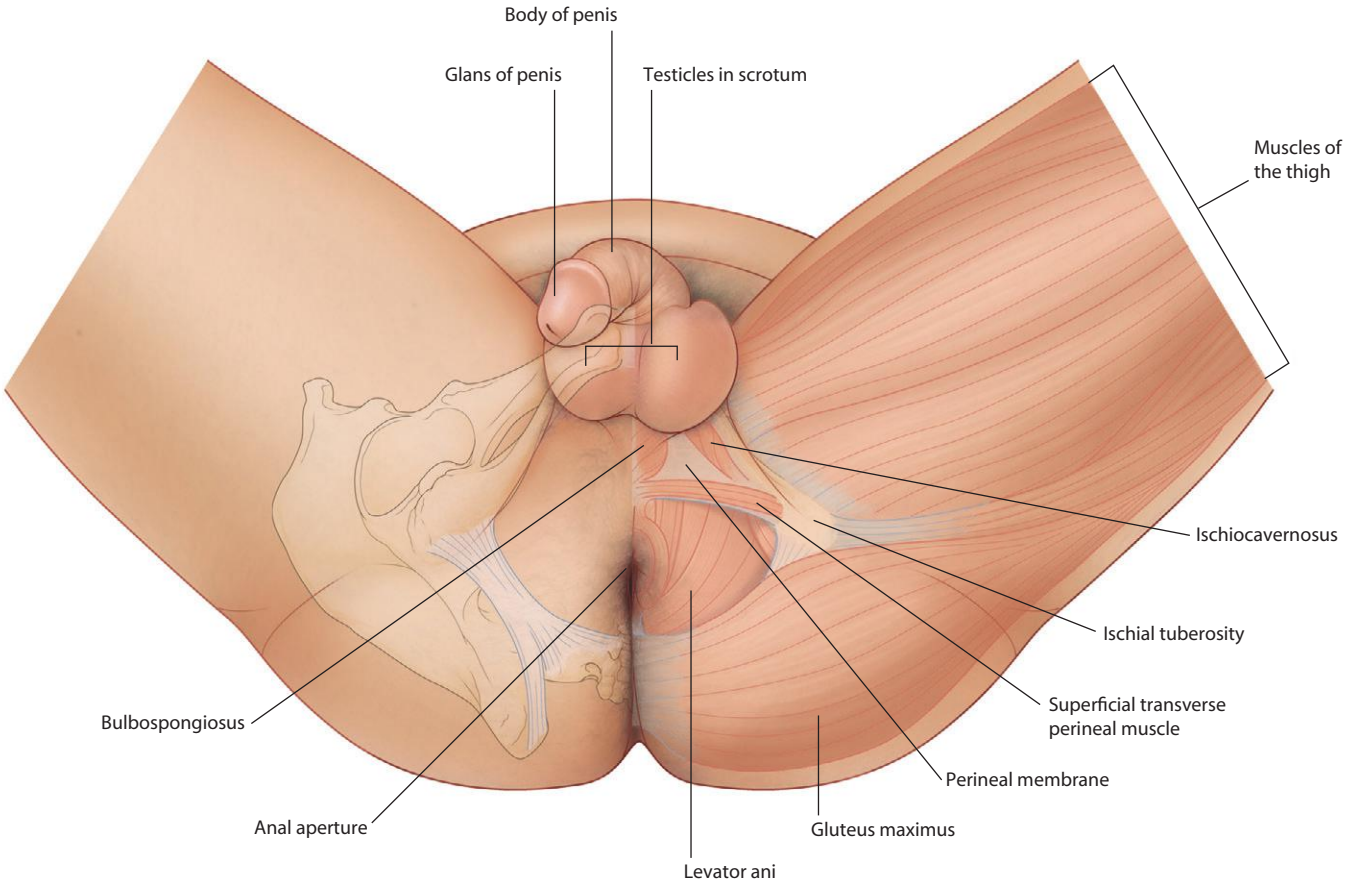

Structures of the perineum in men

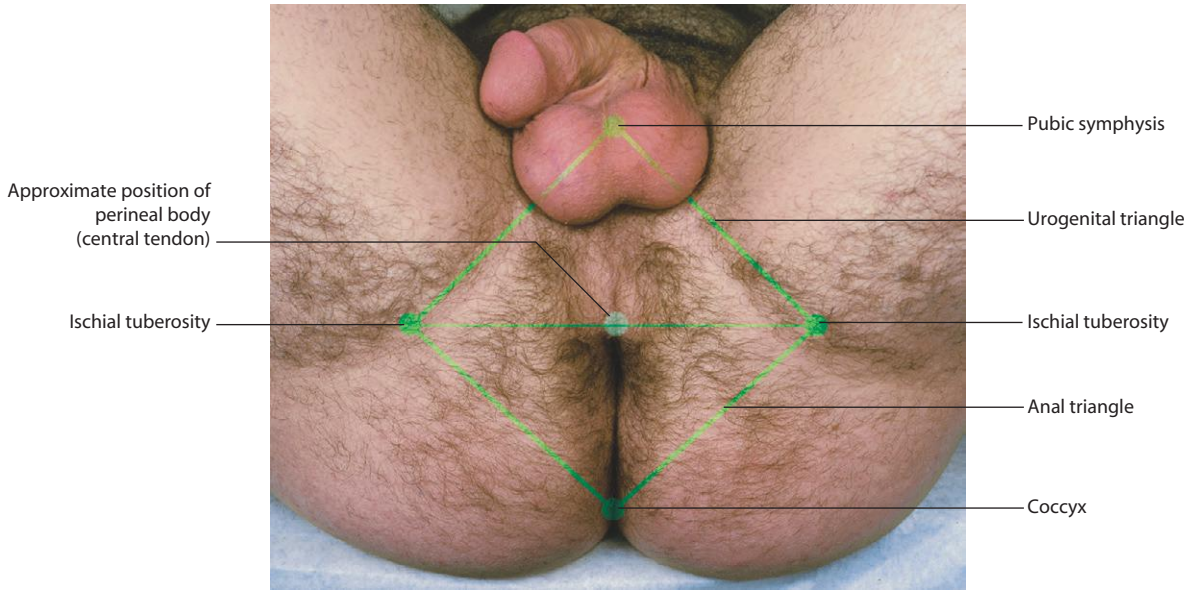

Surface anatomy of the perineum in men

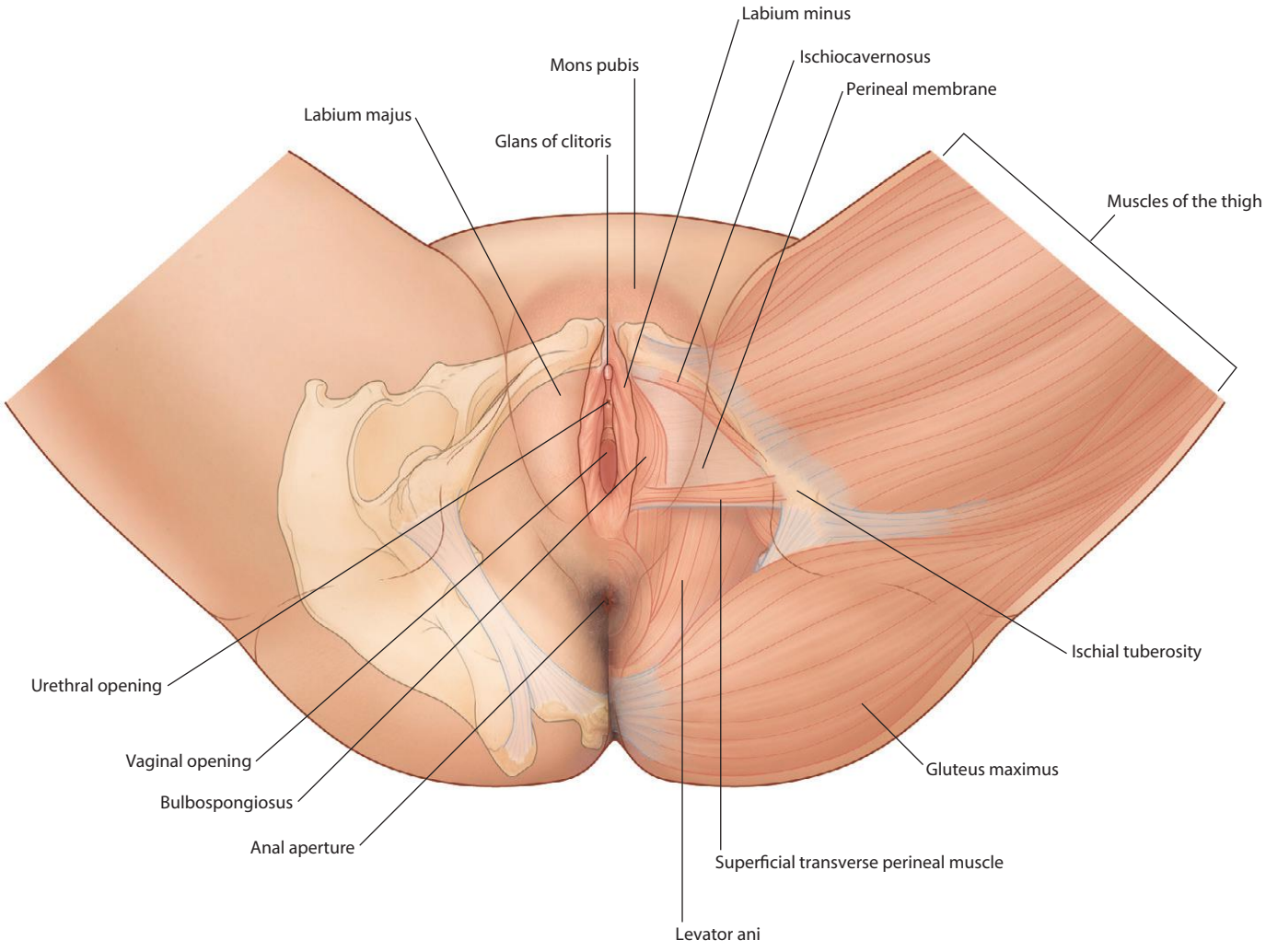

Structures of the perineum in women

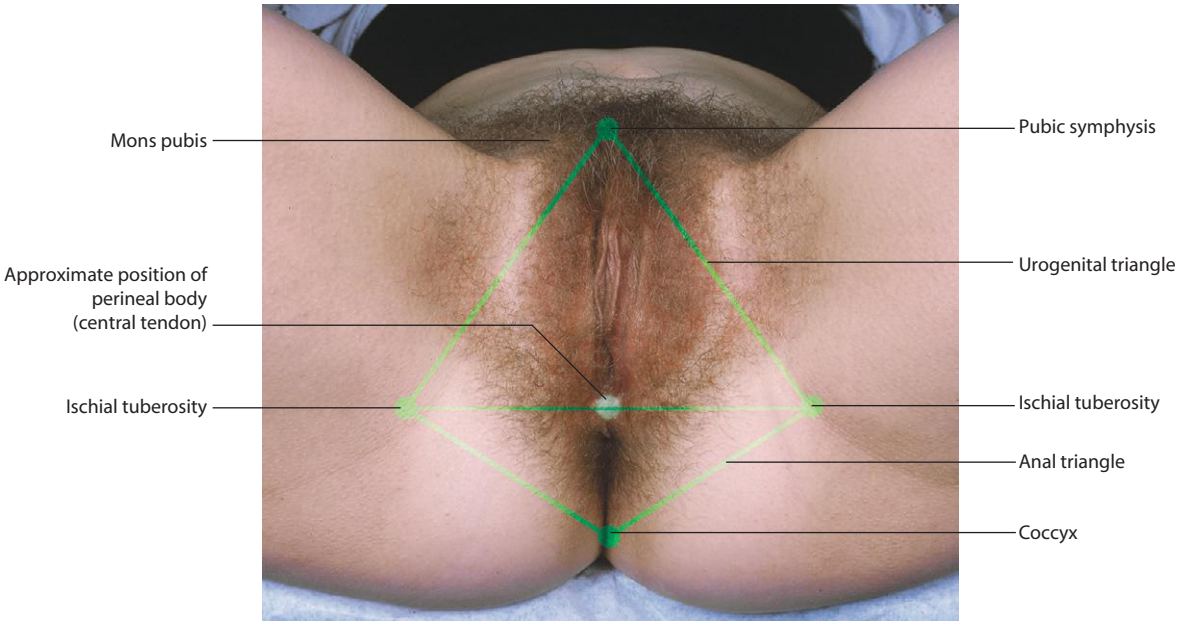

Surface anatomy of the perineum in women

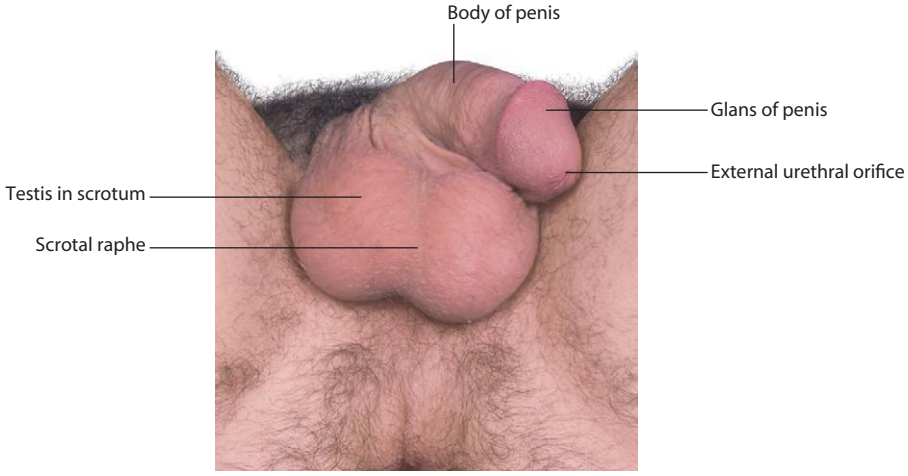

Superficial features of the perineum in men

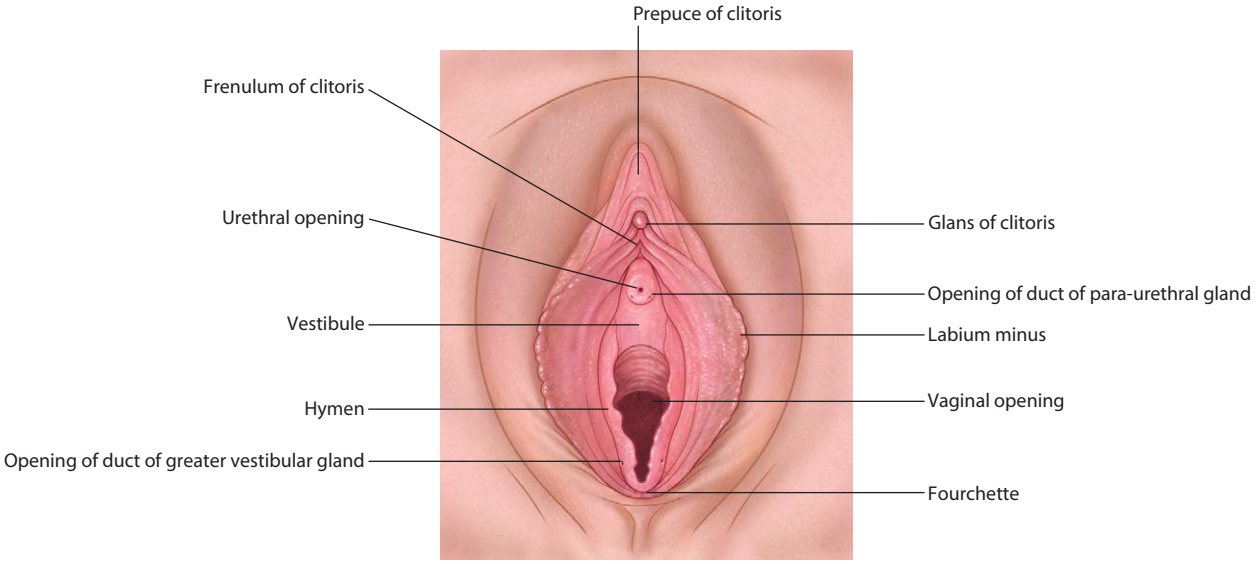

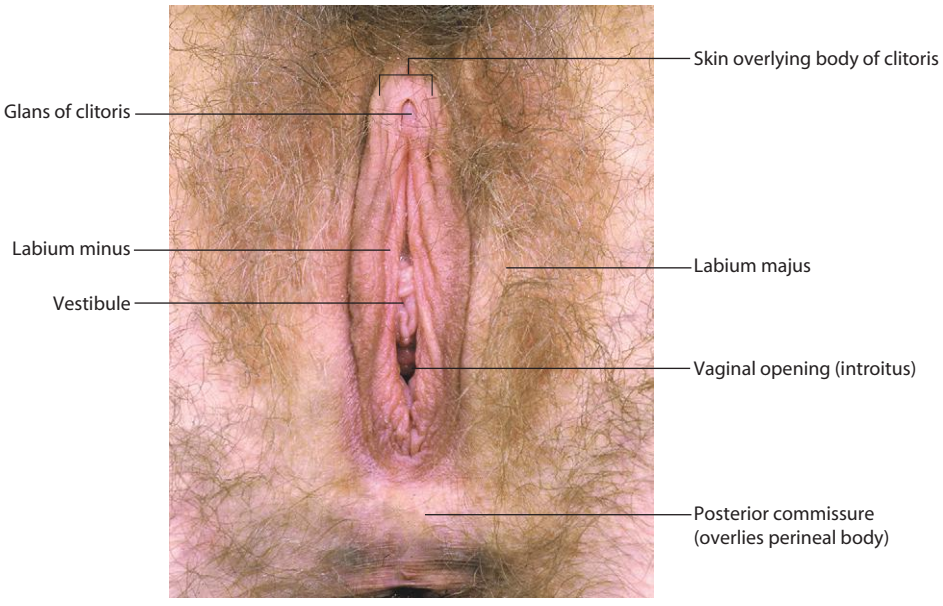

Superficial features of the perineum in women

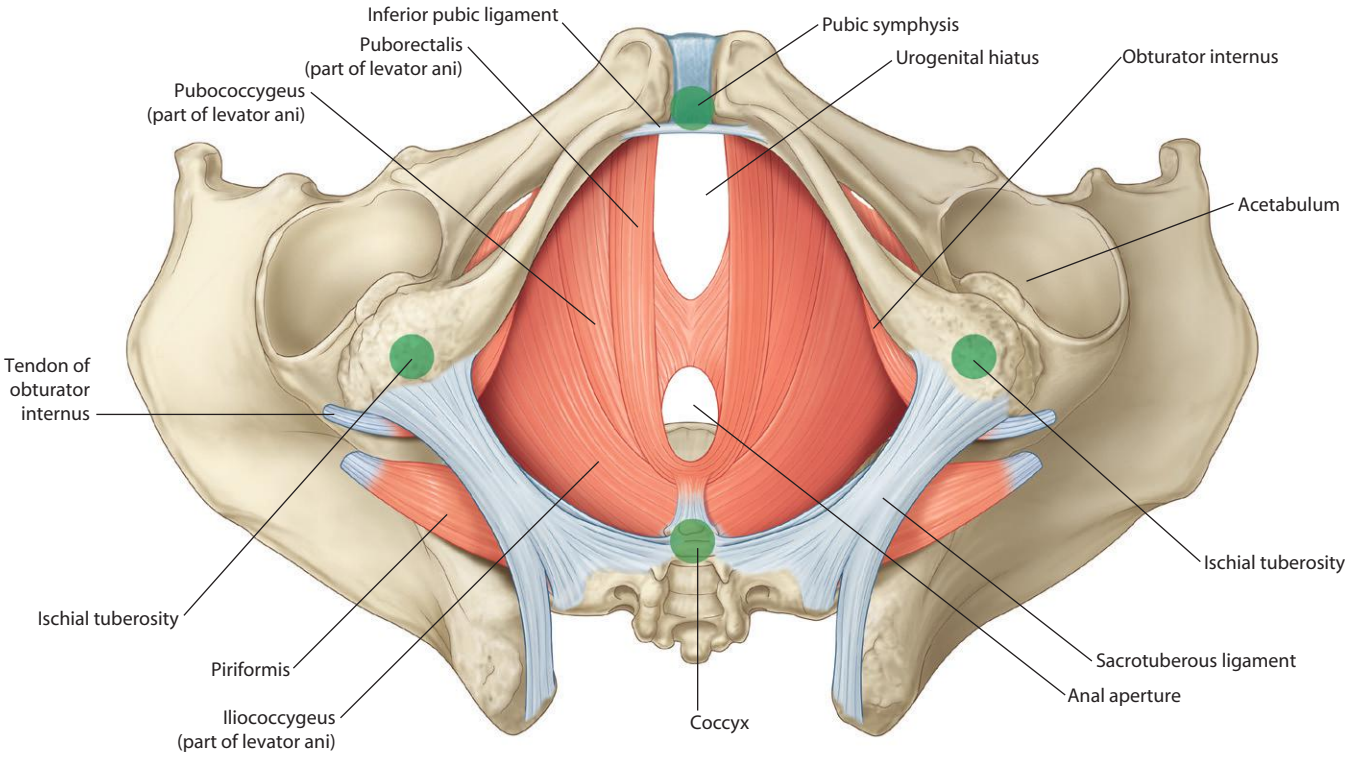

Borders and ceiling of the perineum in men

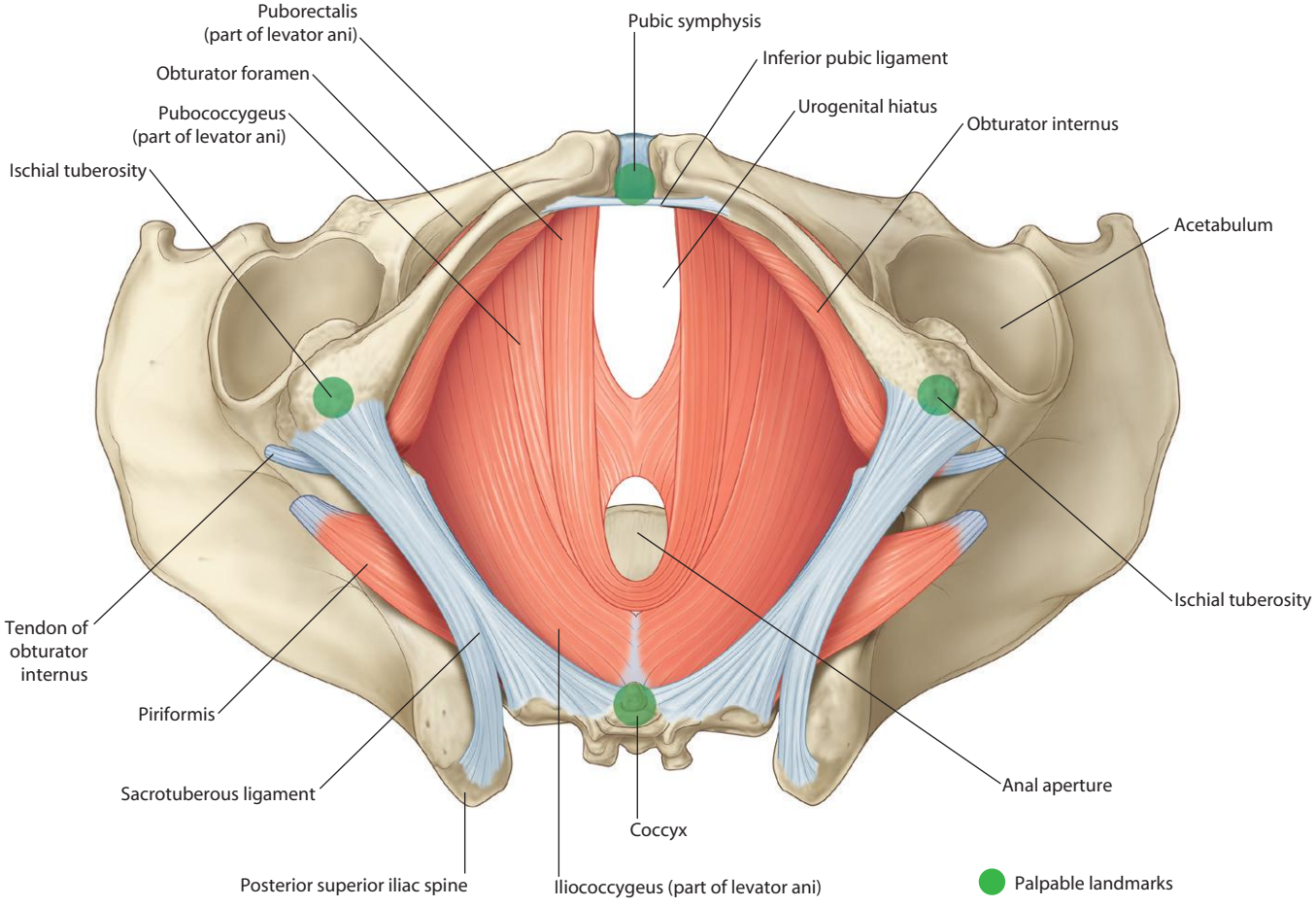

Borders and ceiling of the perineum in women

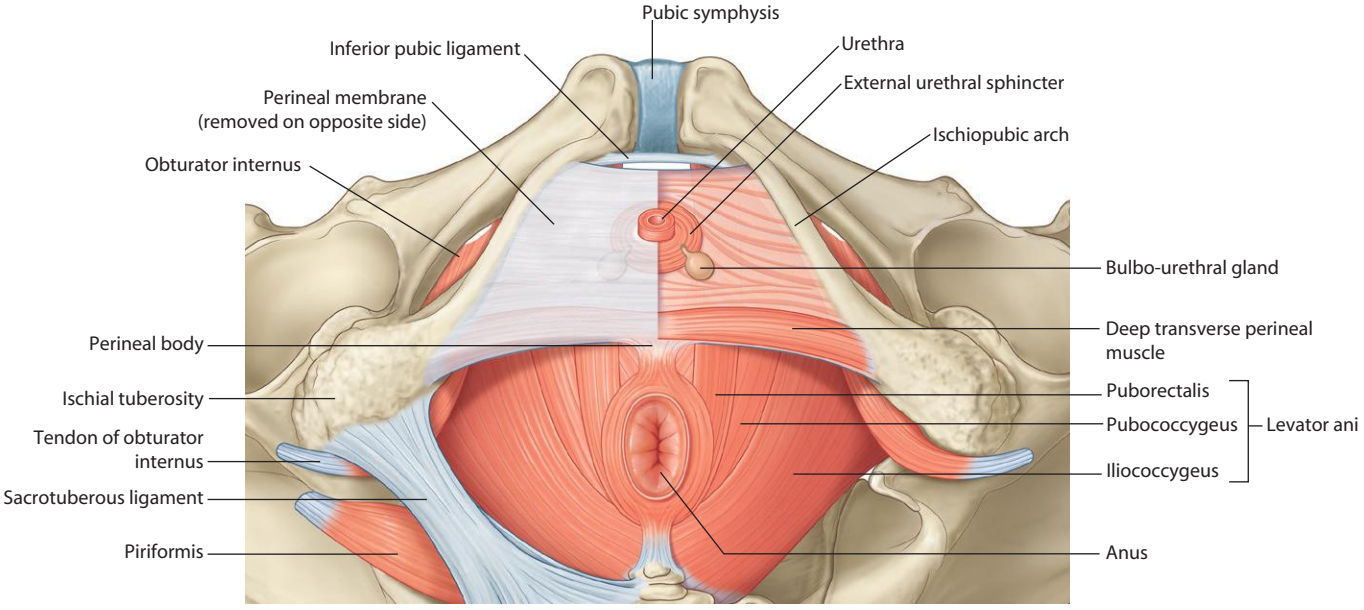

Muscles of deep perineal pouch in men
(perineal membrane removed on left side to expose deep perineal pouch)

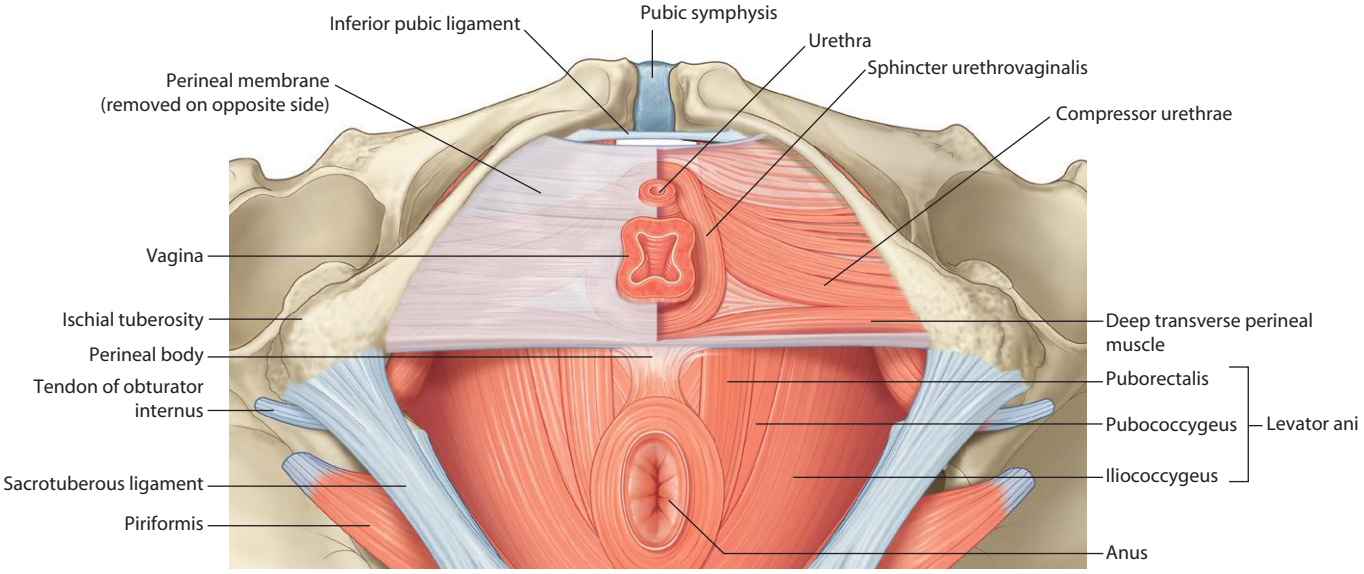

Muscles of deep perineal pouch in women
(perineal membrane removed on left side to expose deep perineal pouch)

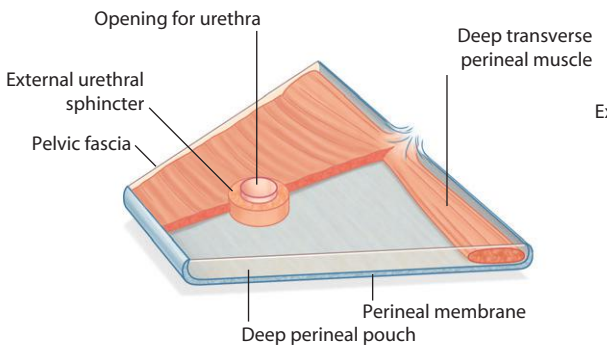

Muscles of deep perineal pouch in men

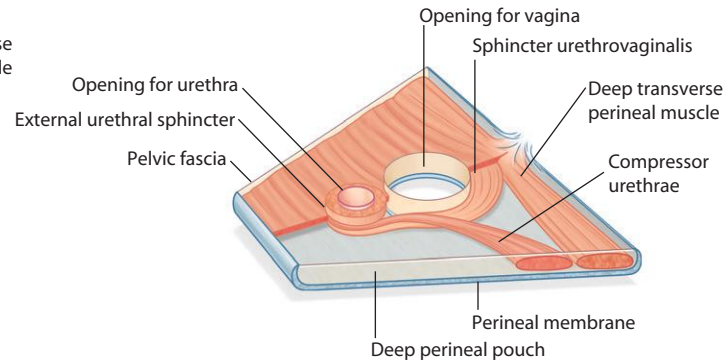

Muscles of deep perineal pouch in women

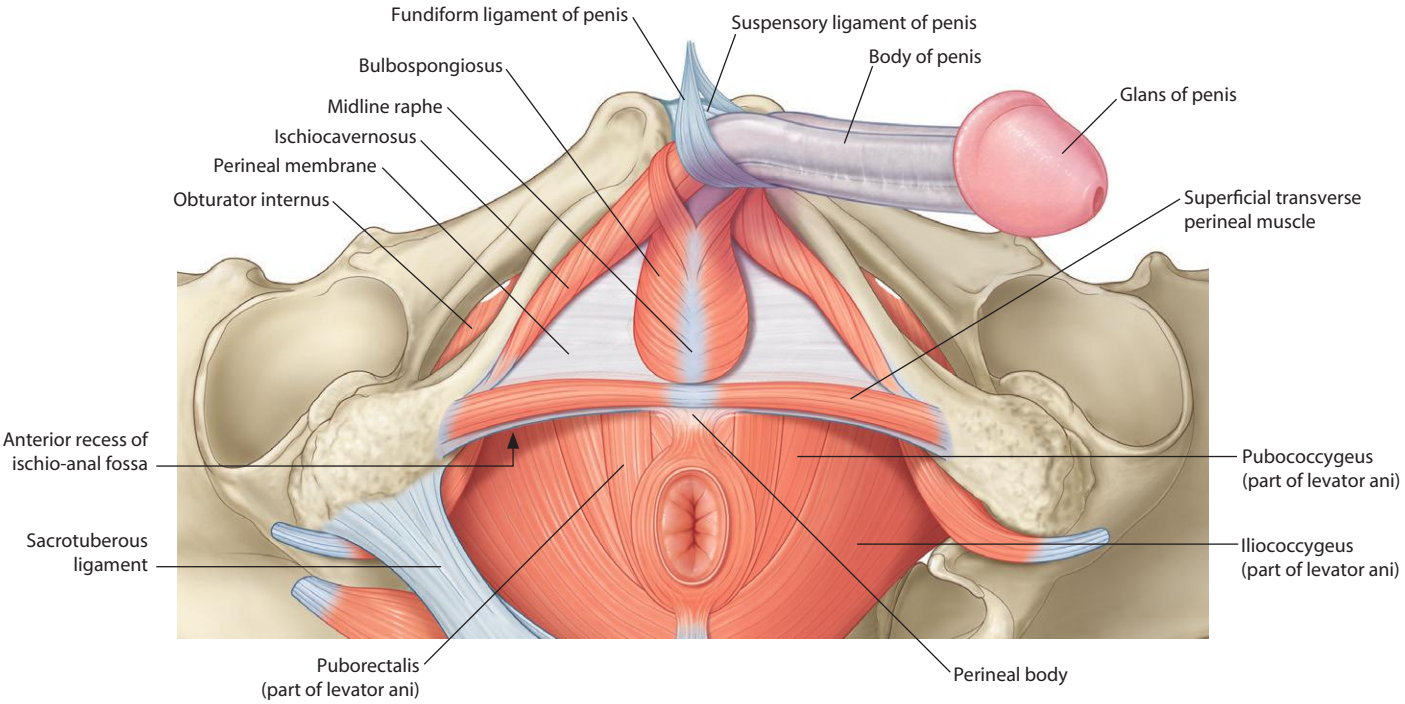

Muscles of the superficial perineal pouch in men

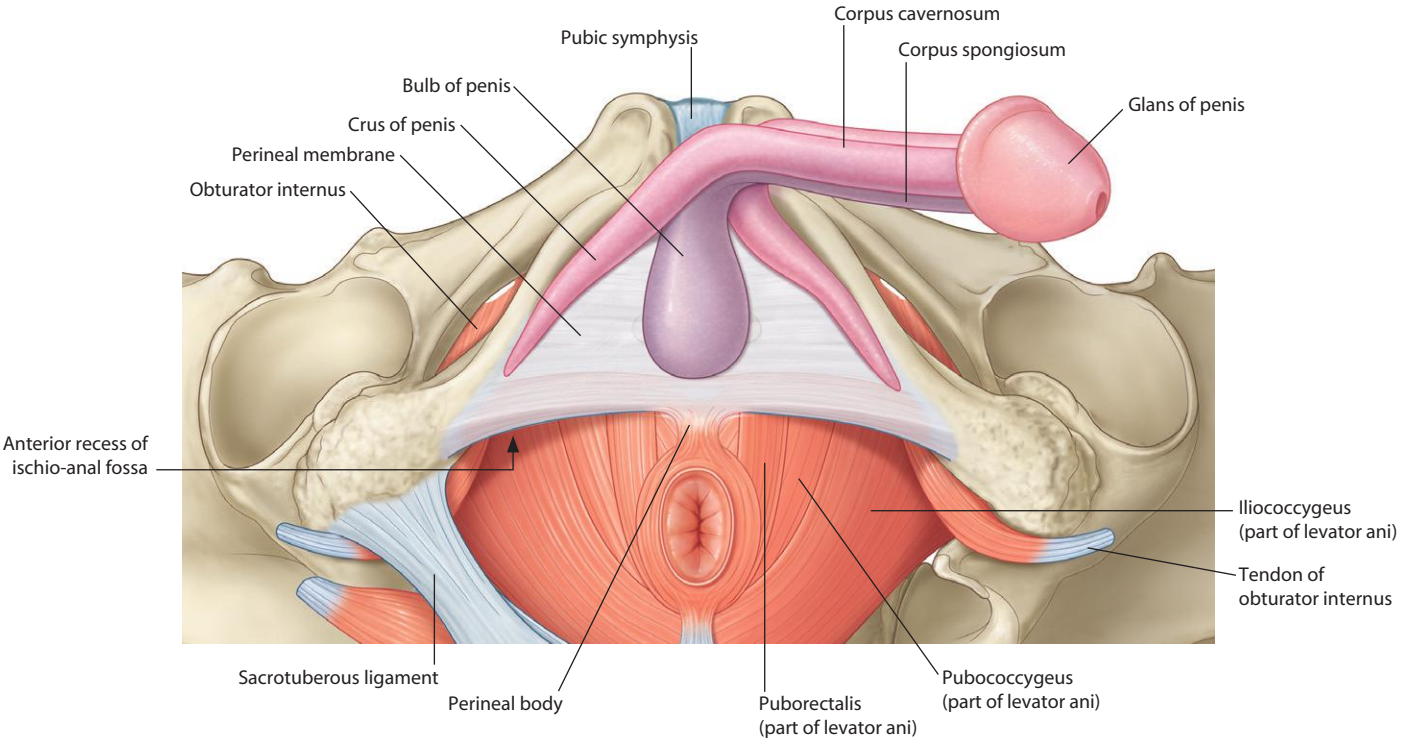

Erectile tissues of the superficial perineal pouch in men

Erectile tissues in relation to other structures in the male perineum.
Fat-saturated T2-weighted MR image in axial plane

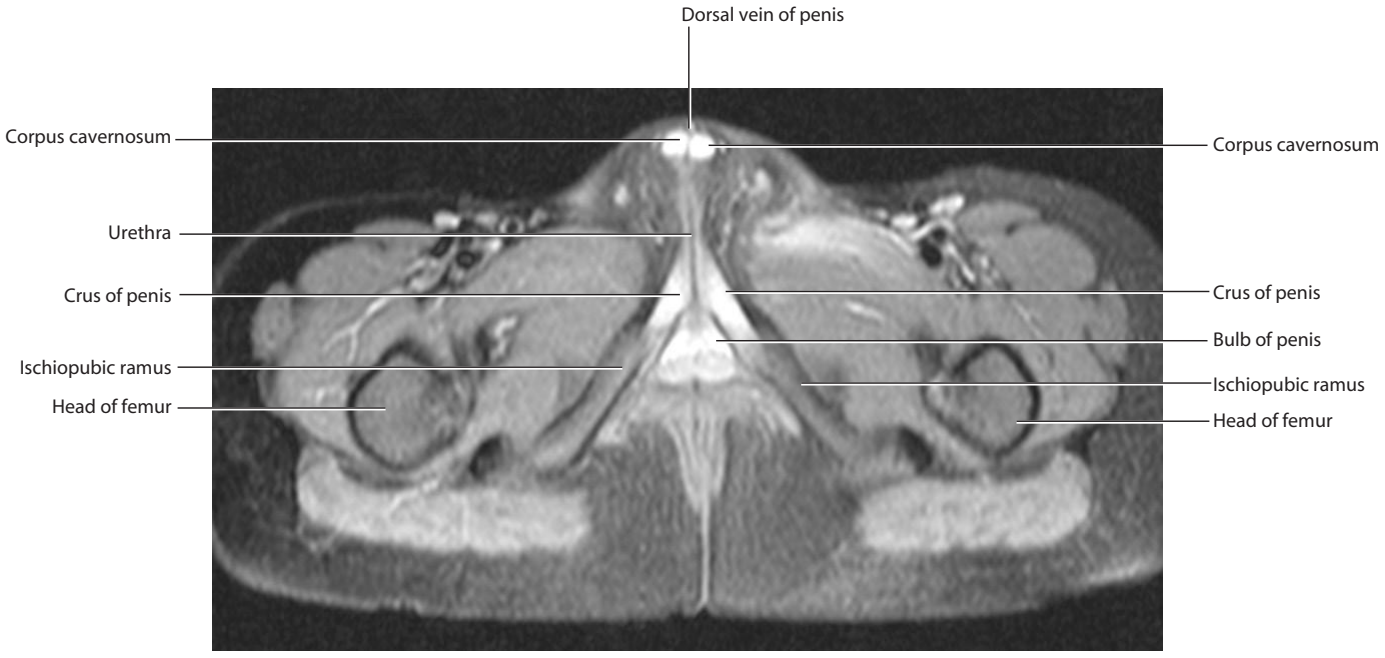

Erectile tissues in relation to other structures in the male perineum.
Fat-saturated T2-weighted MR image in axial plane

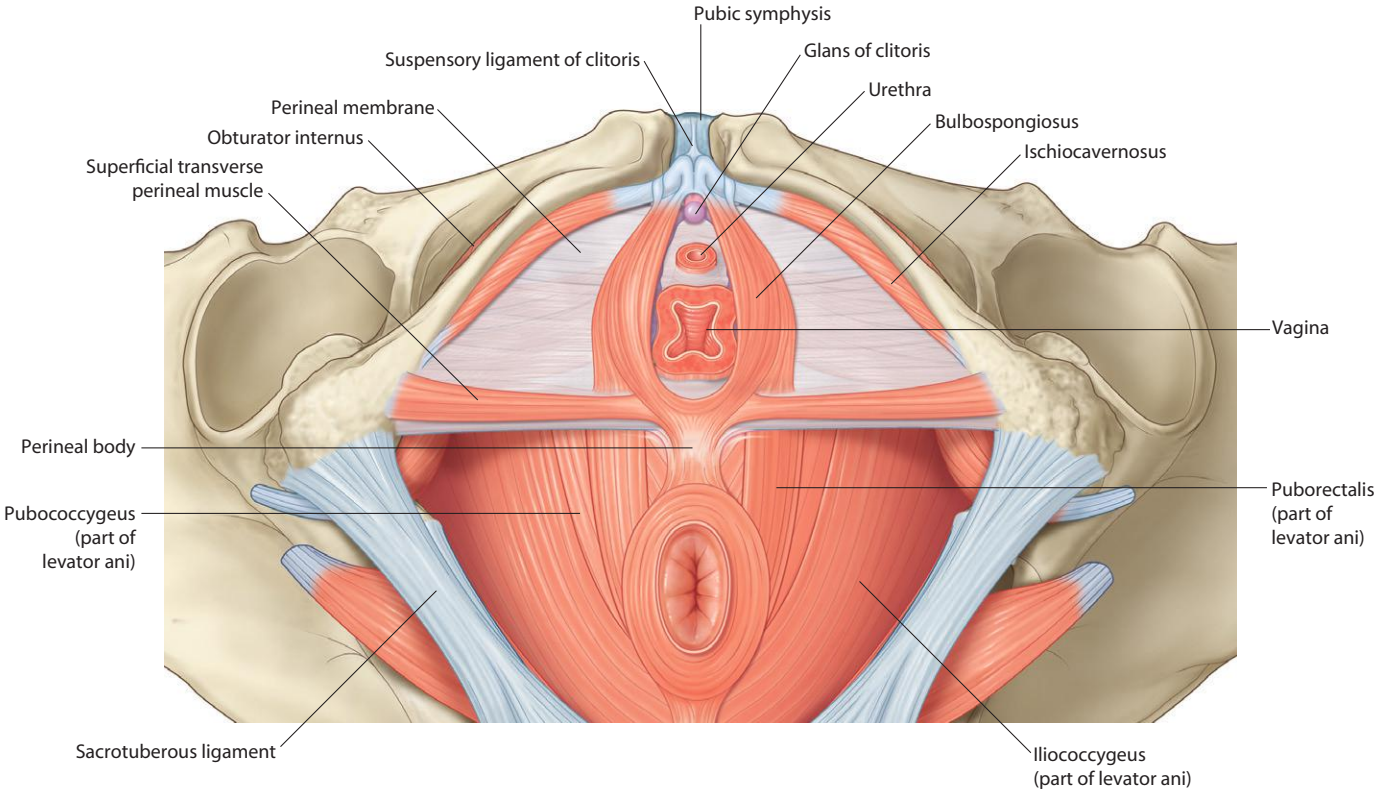

Muscles of the superficial perineal pouch in women

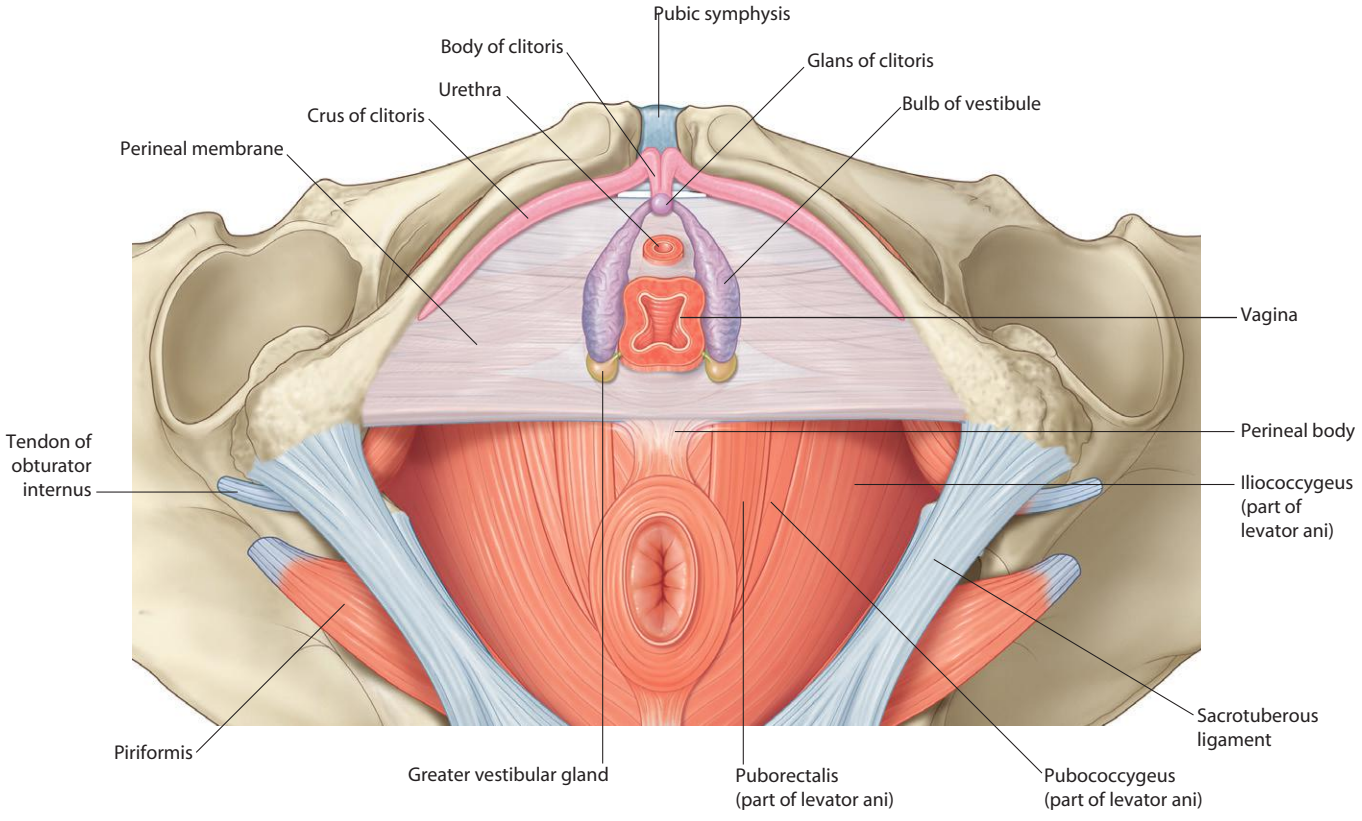

Erectile tissues of the superficial perineal pouch in women

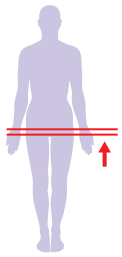

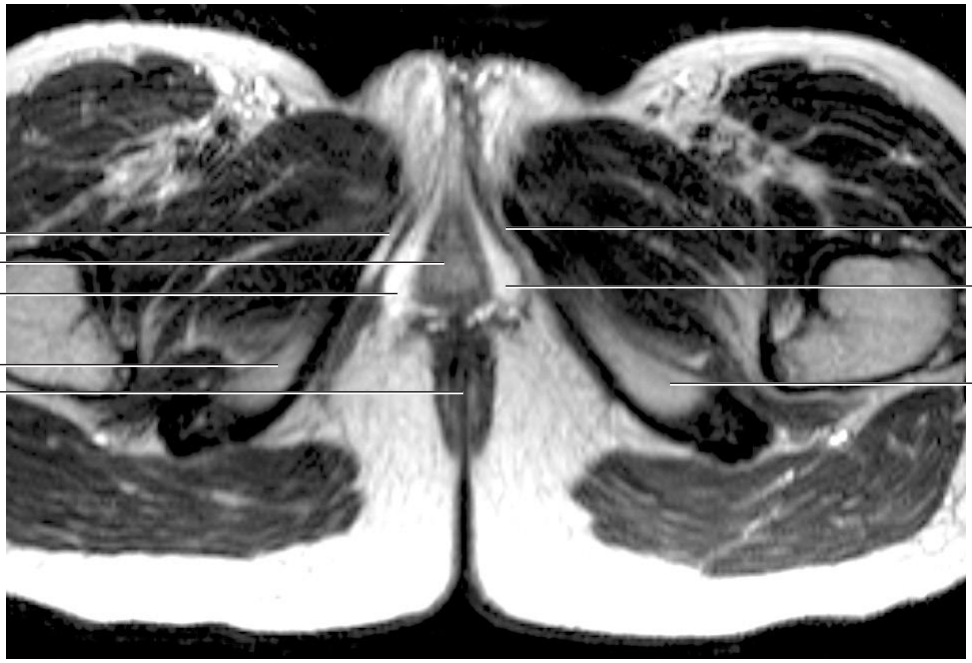

Erectile tissues in relation to other structures in the female perineum.
T2-weighted MR image in axial plane

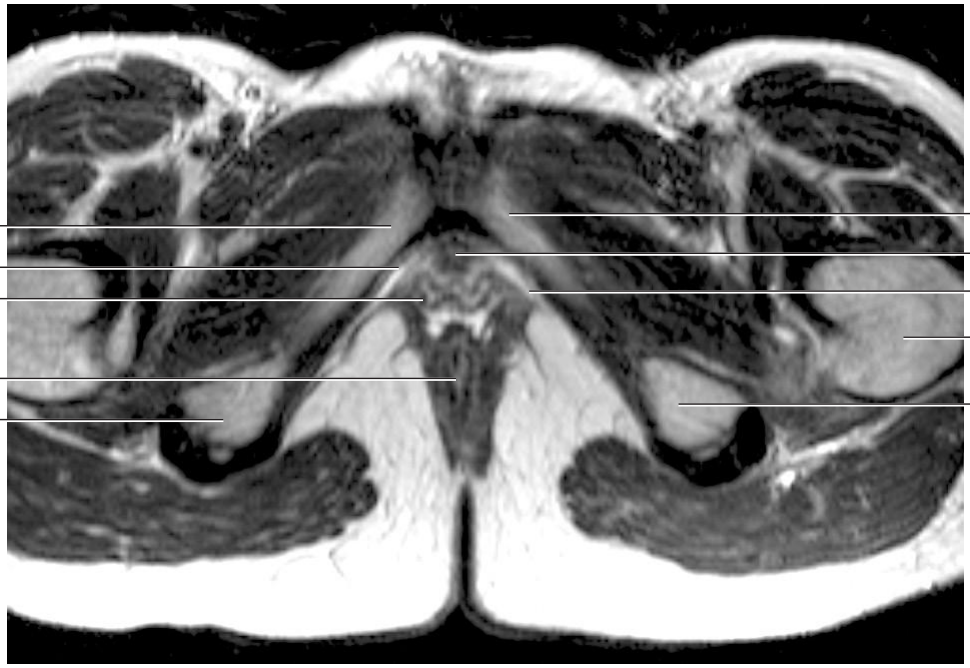

Erectile tissues in relation to other structures in the female perineum.
T2-weighted MR image in axial plane

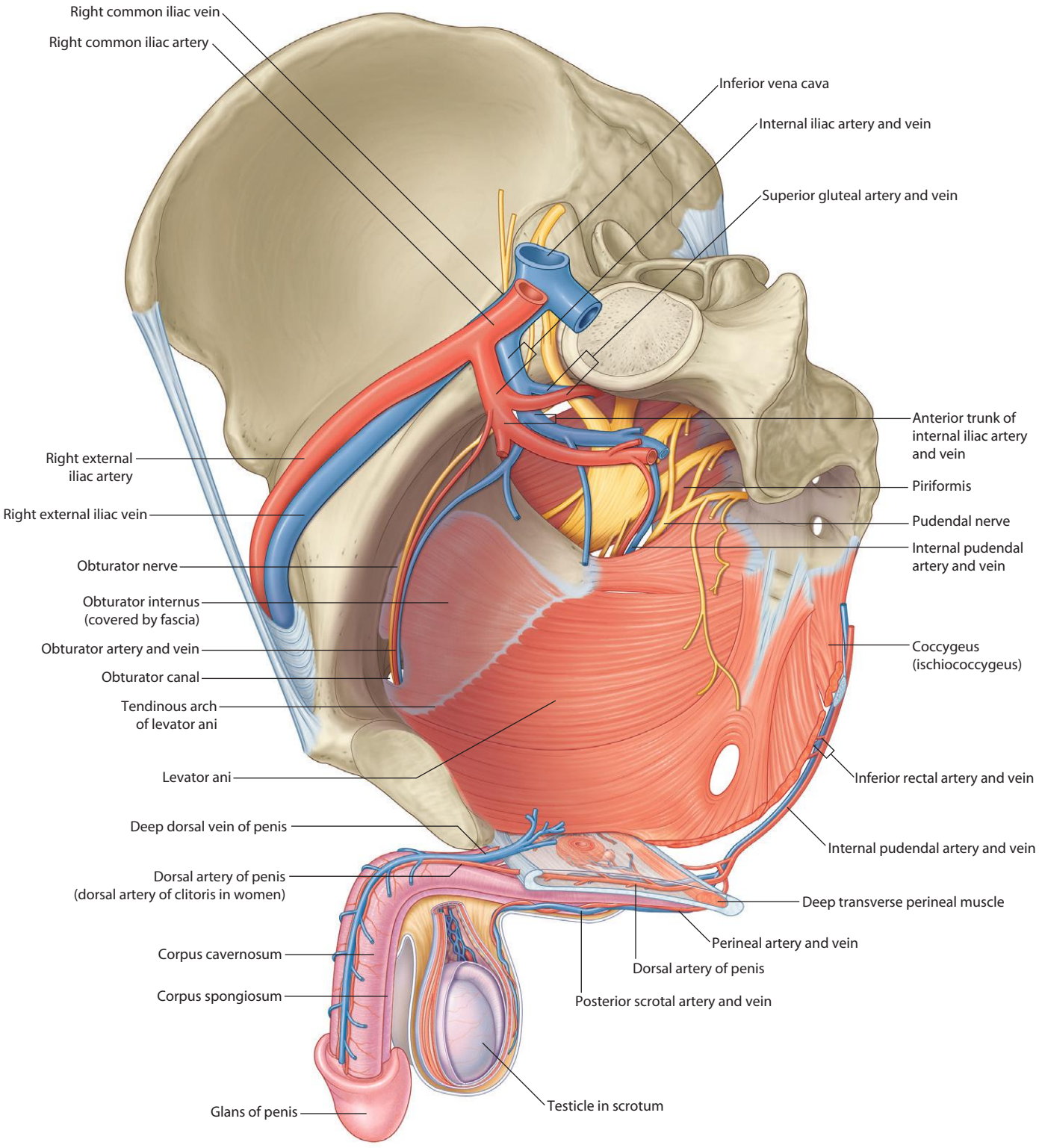

Course of internal pudendal artery and vein in men (oblique sagittal view)

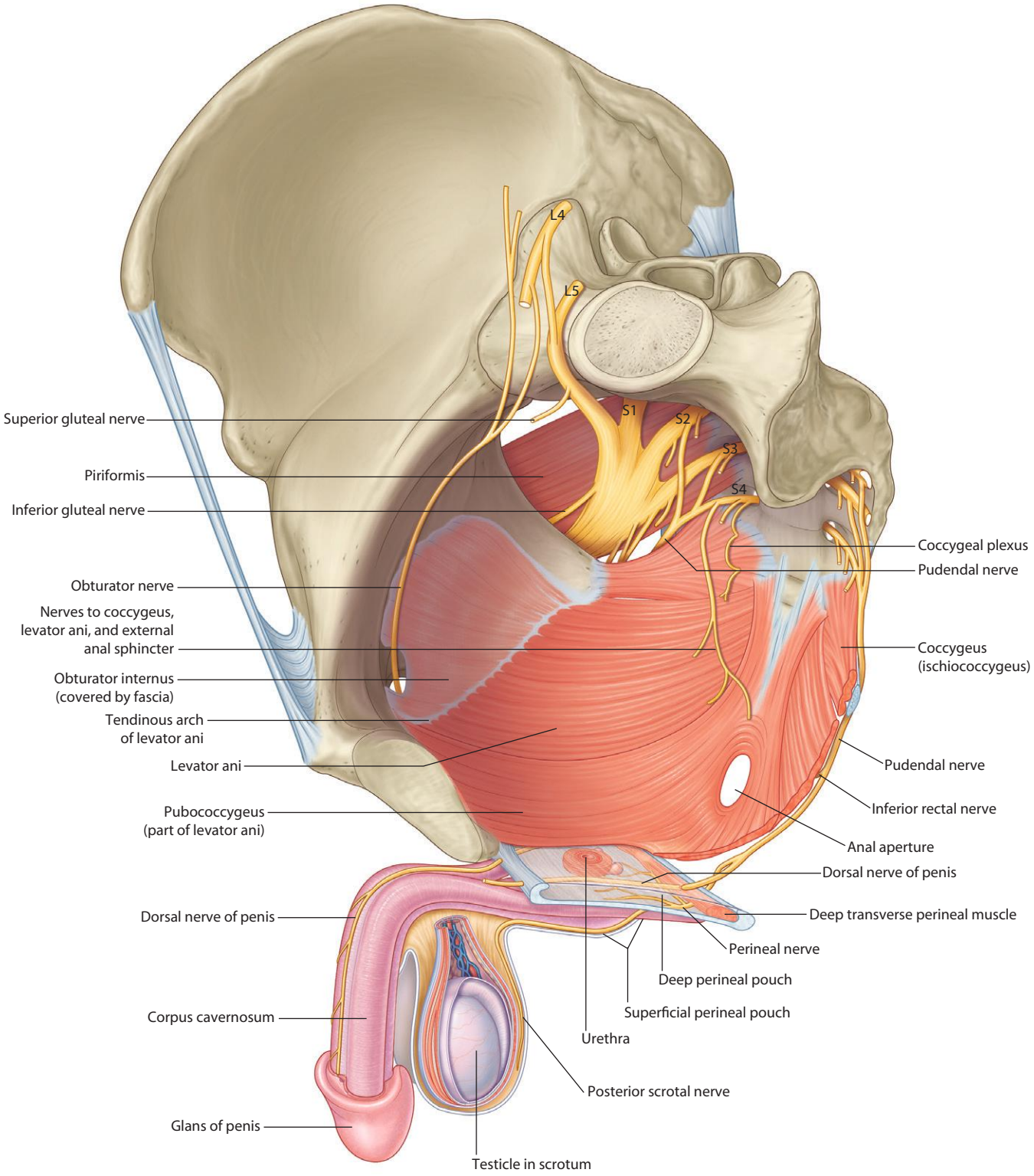

Course of pudendal nerve in men (oblique sagittal view)

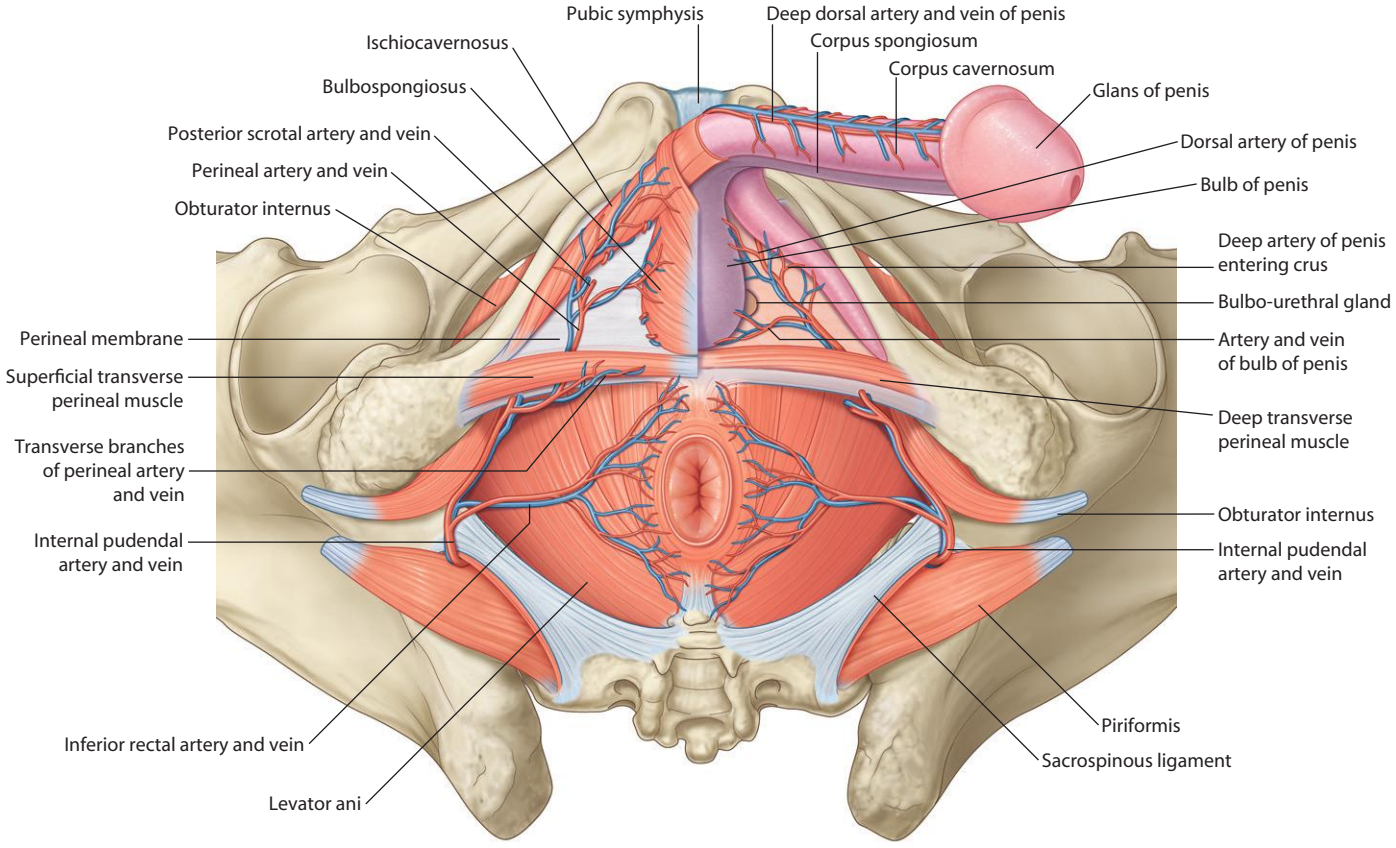

Arteries and veins of perineum in men
(perineal membrane removed on left side to expose deep perineal pouch; inferior view)

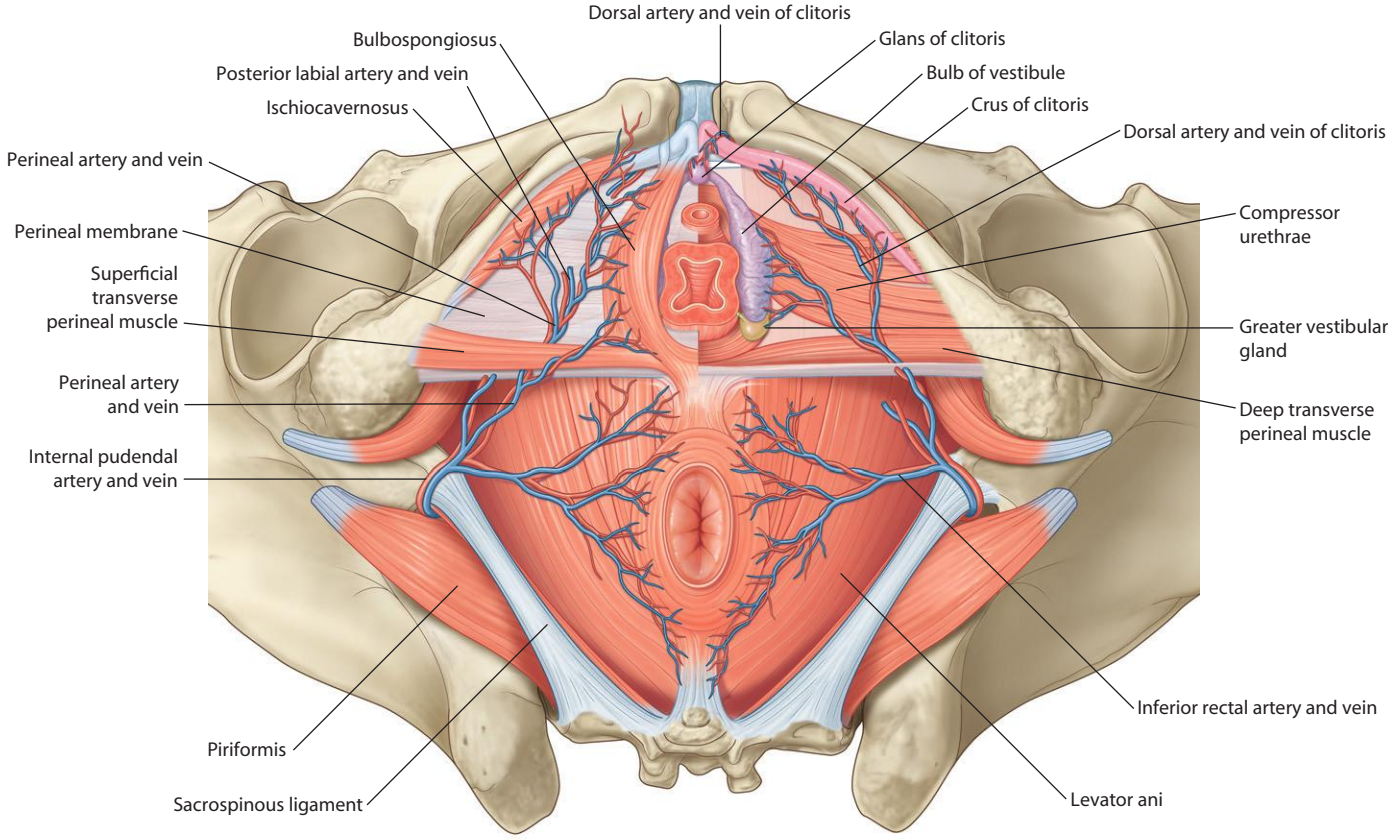

Arteries and veins of perineum in women
(perineal membrane removed on left side to expose deep perineal pouch; inferior view)

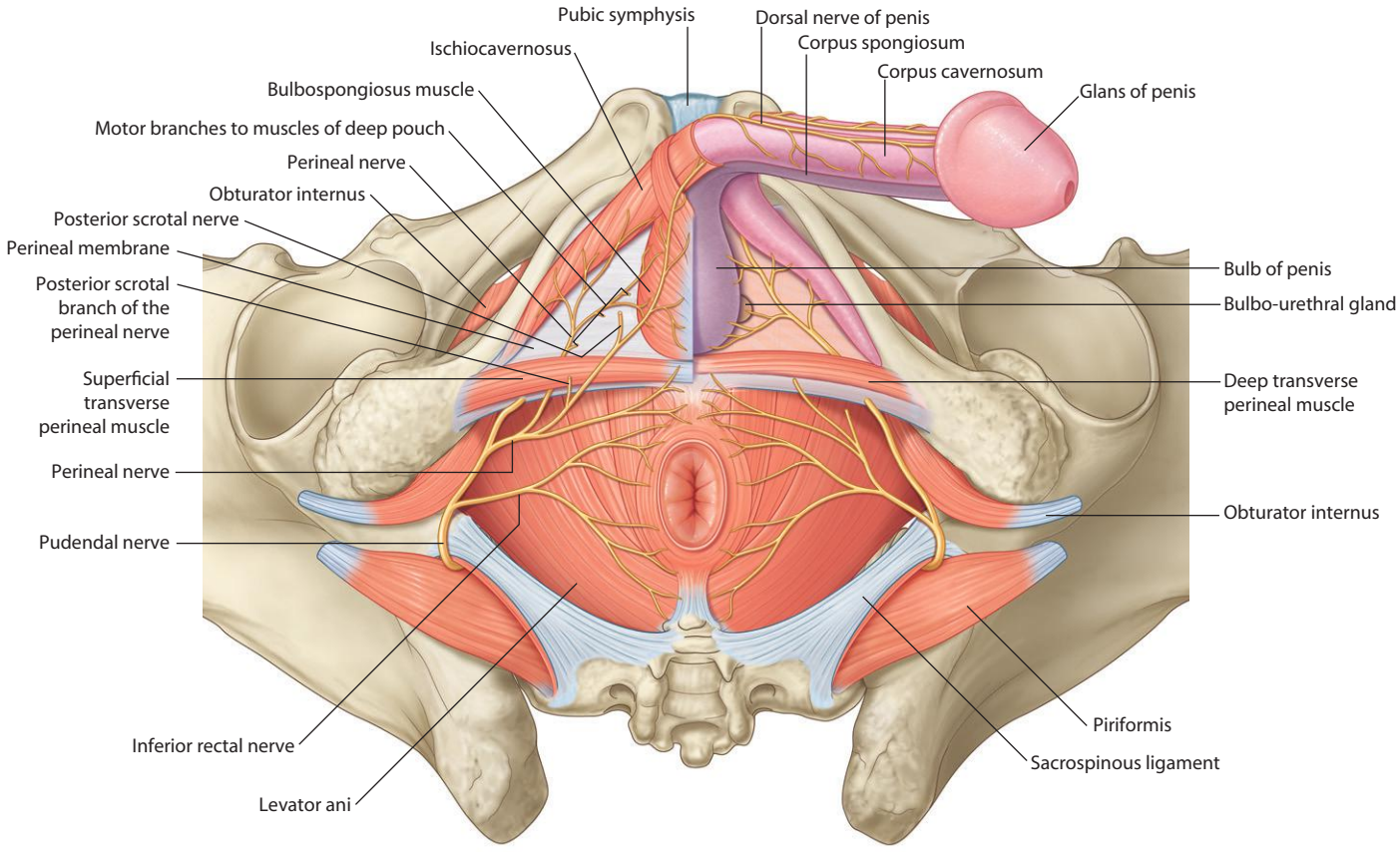

Nerves of the perineum in men
(perineal membrane removed on left side to expose deep perineal pouch; inferior view)

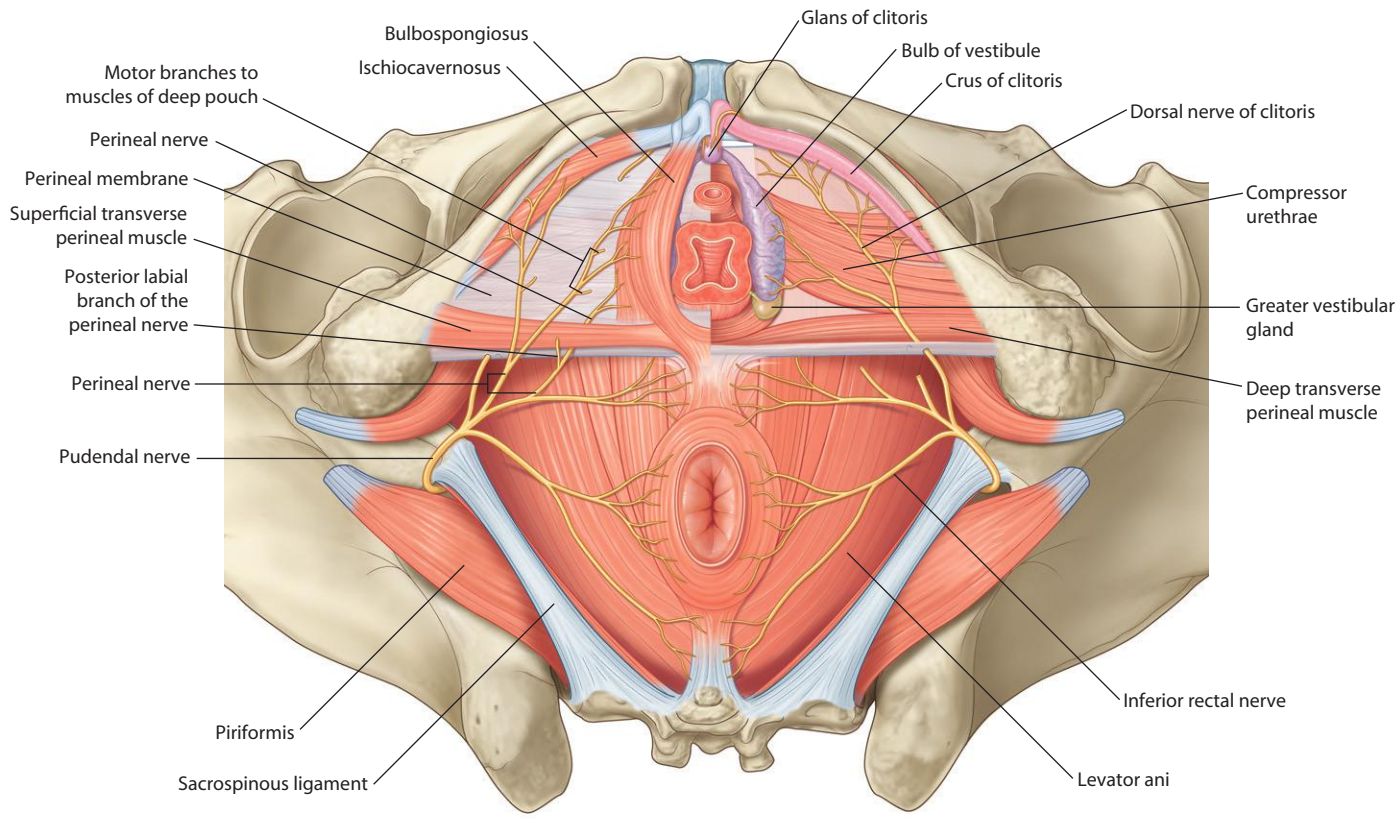

Nerves of the perineum in women
(perineal membrane removed on left side to expose deep perineal pouch; inferior view)

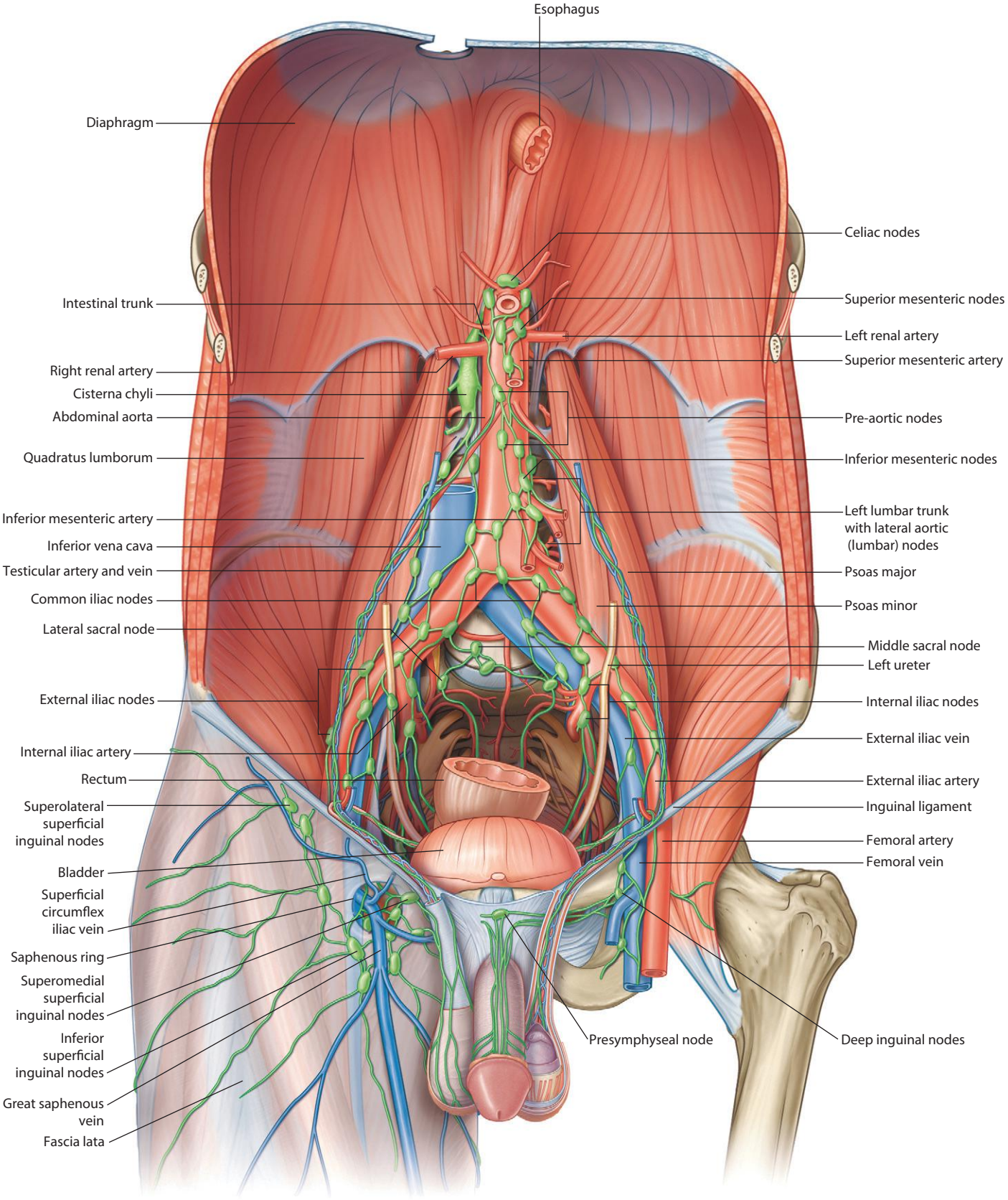

Lymphatics of pelvis and perineum in men

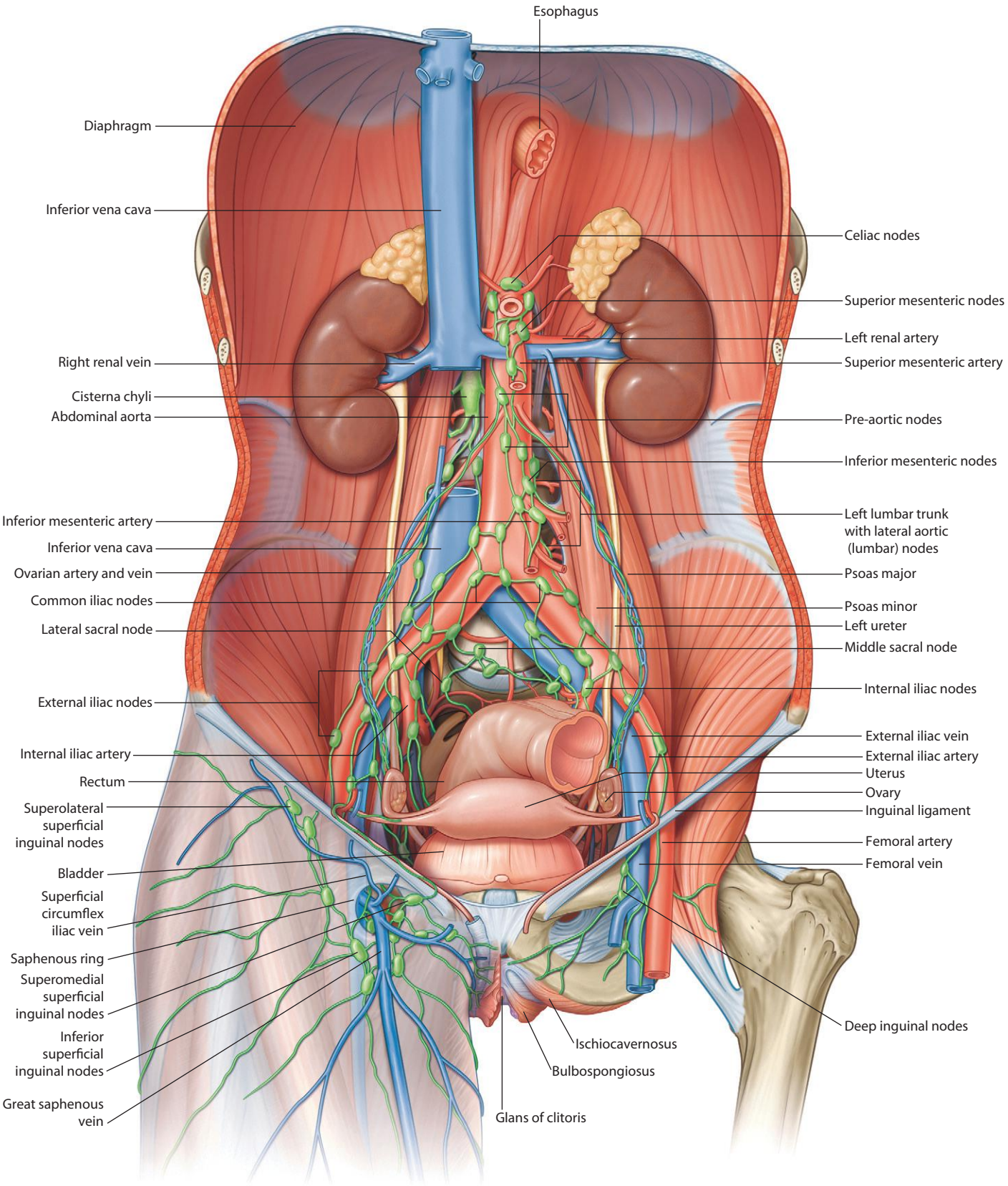

Lymphatics of pelvis and perineum in women

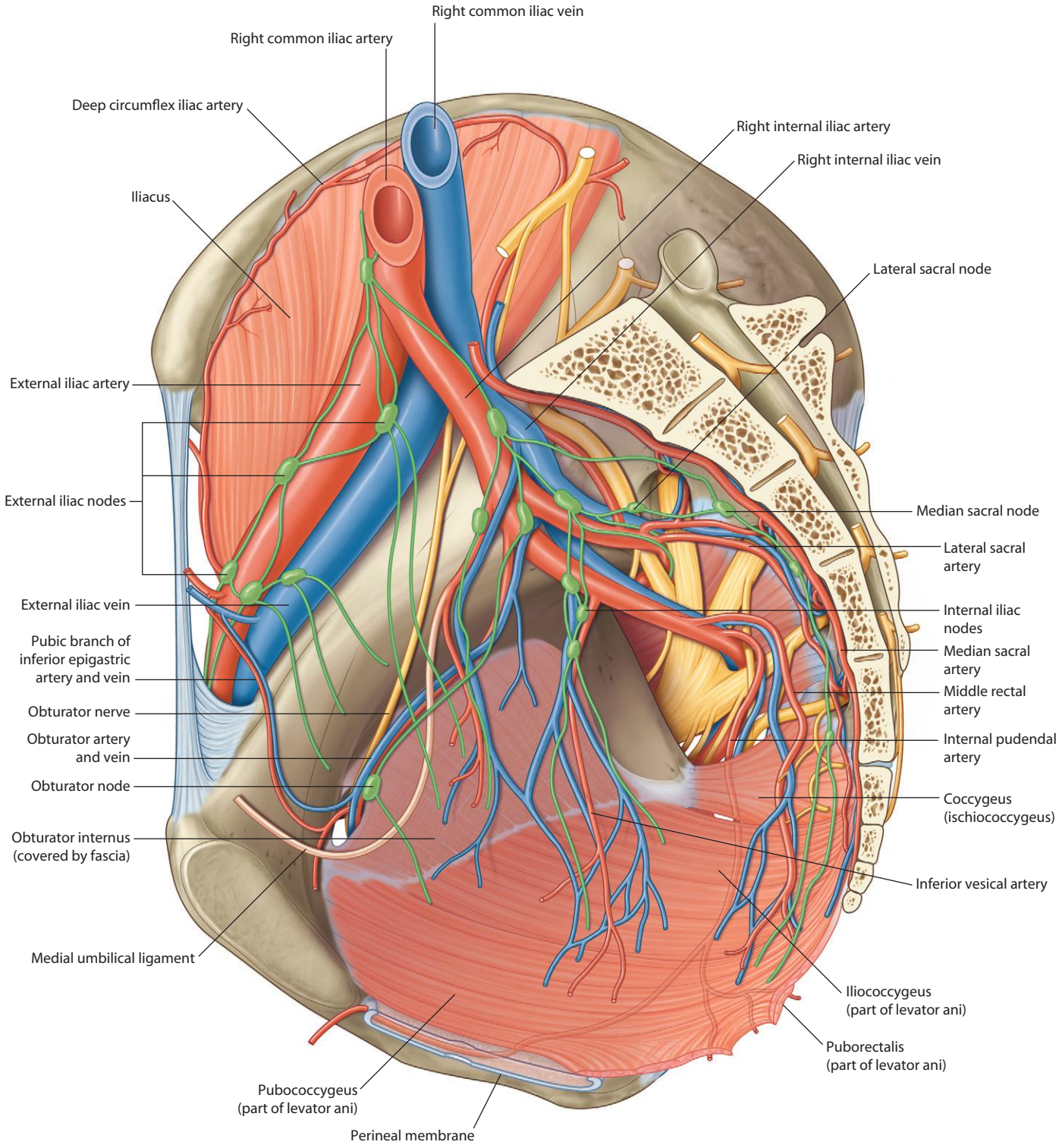

Lymphatics of pelvic cavity (sagittal view)

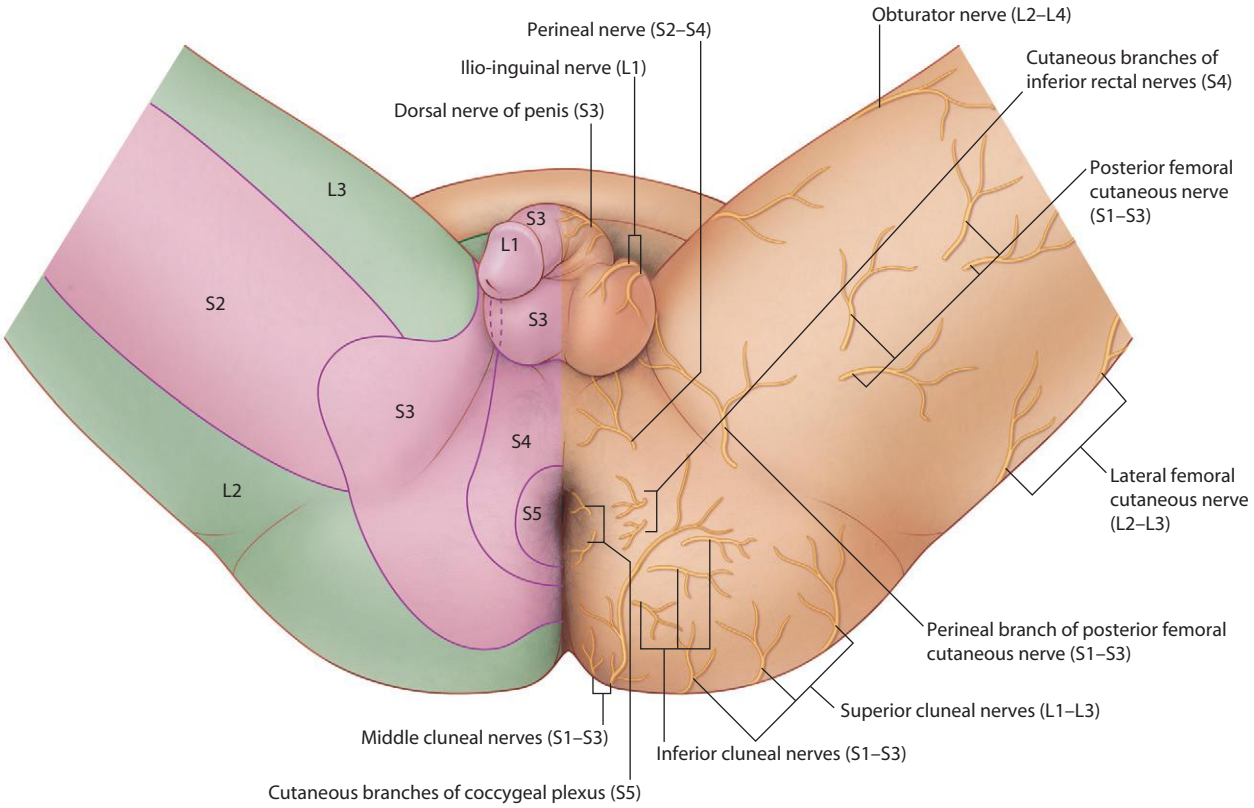

Dermatomes and cutaneous nerves of perineum in men

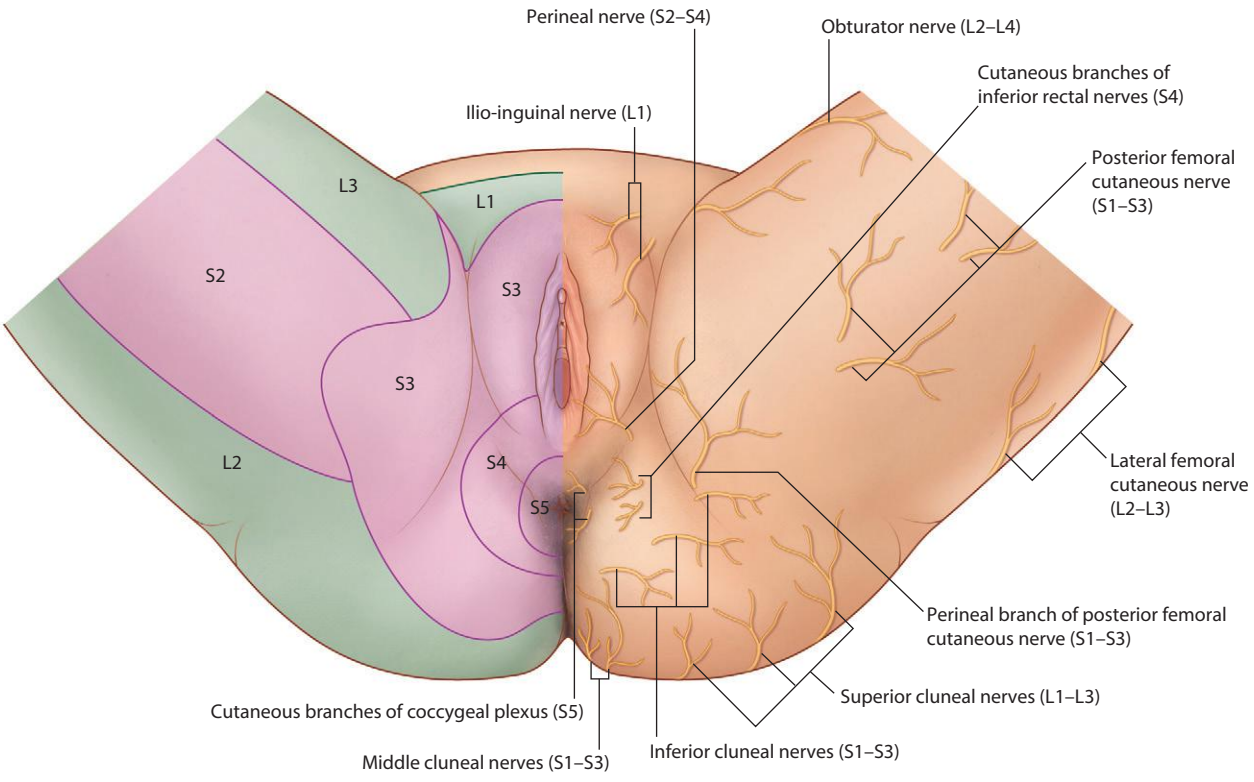

Dermatomes and cutaneous nerves of perineum in women

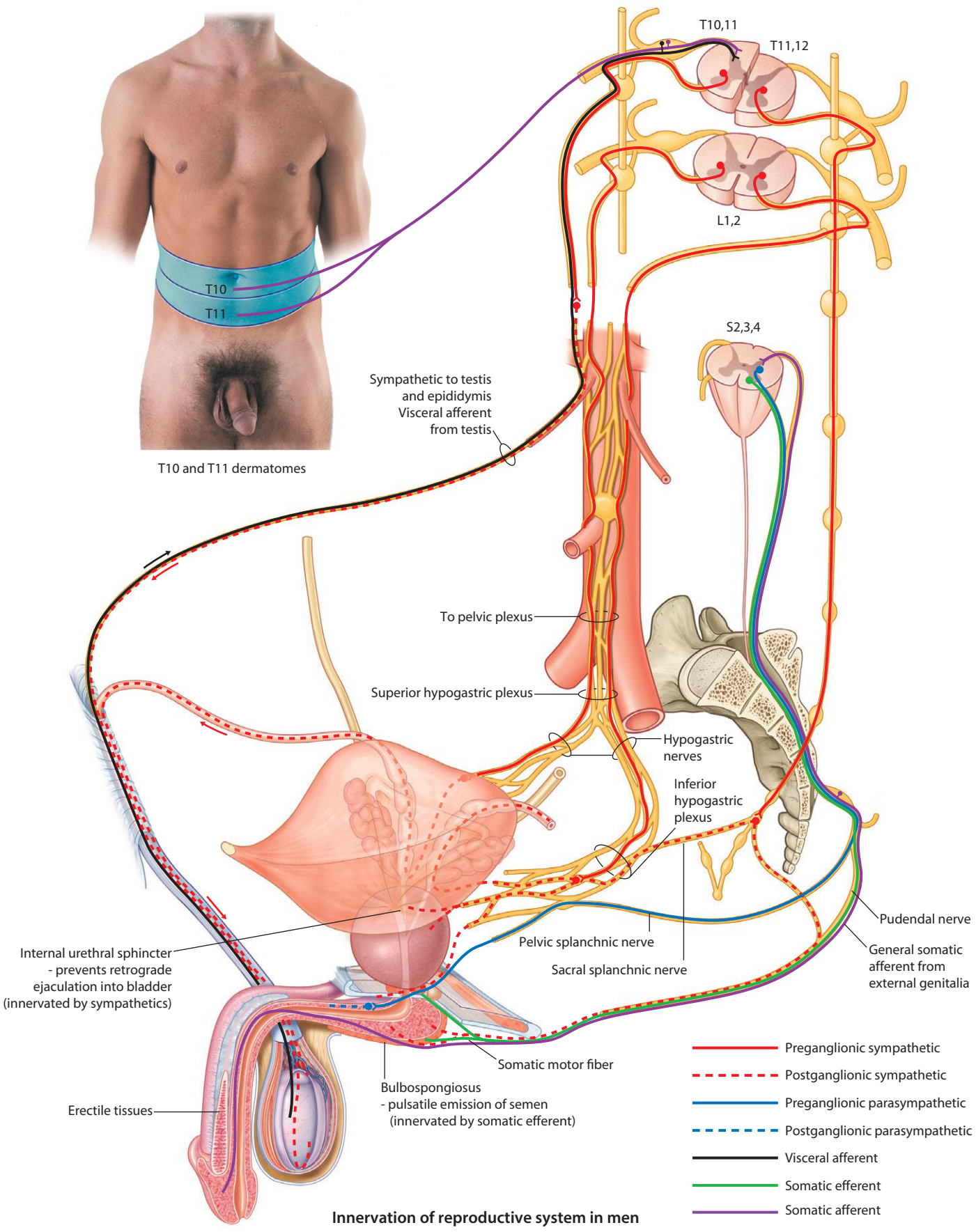

Innervation of reproductive system in men

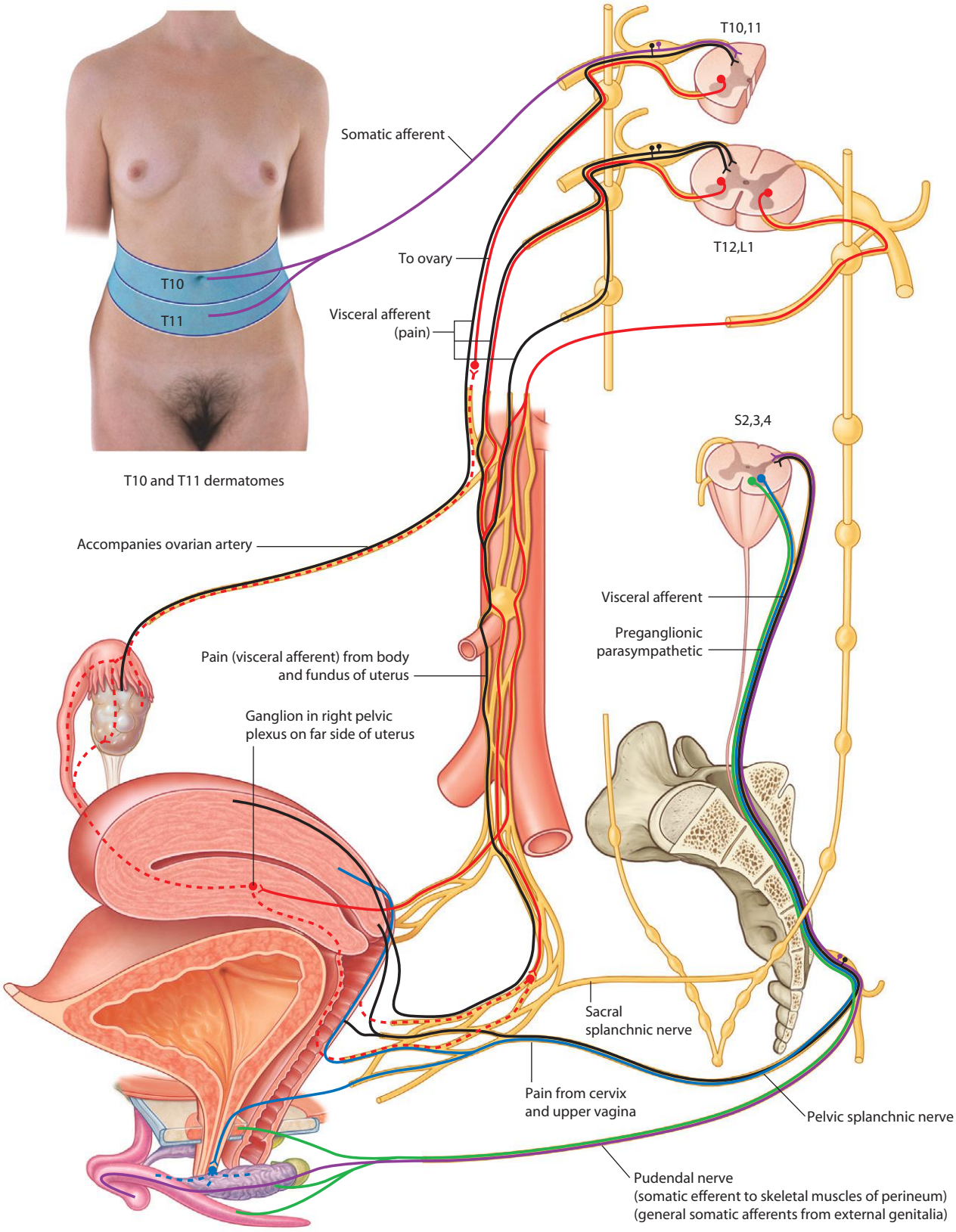

Innervation of reproductive system in women

Visceral efferent (parasympathetic and sympathetic) innervation of bladder and visceral afferent nerves

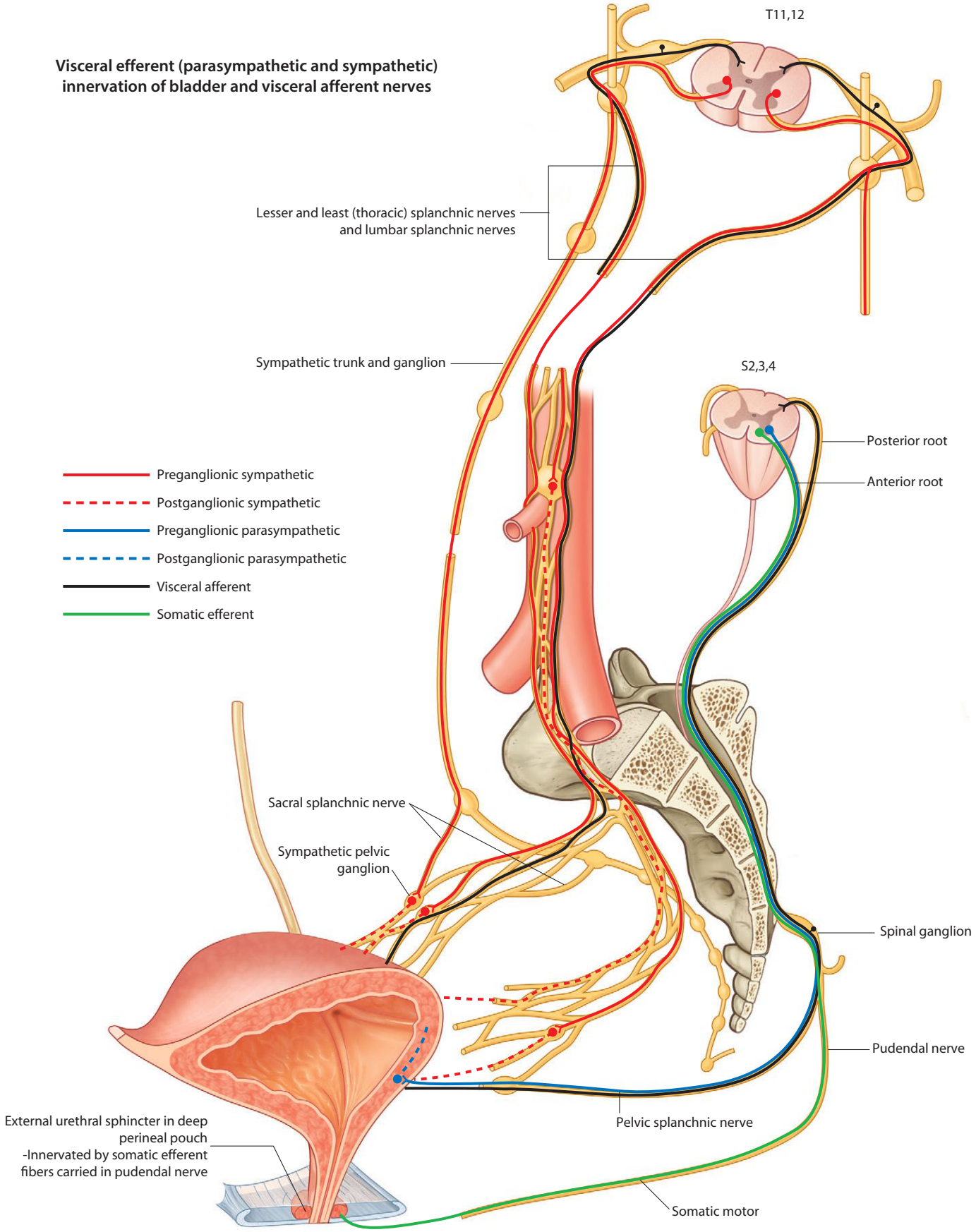

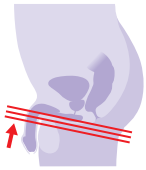

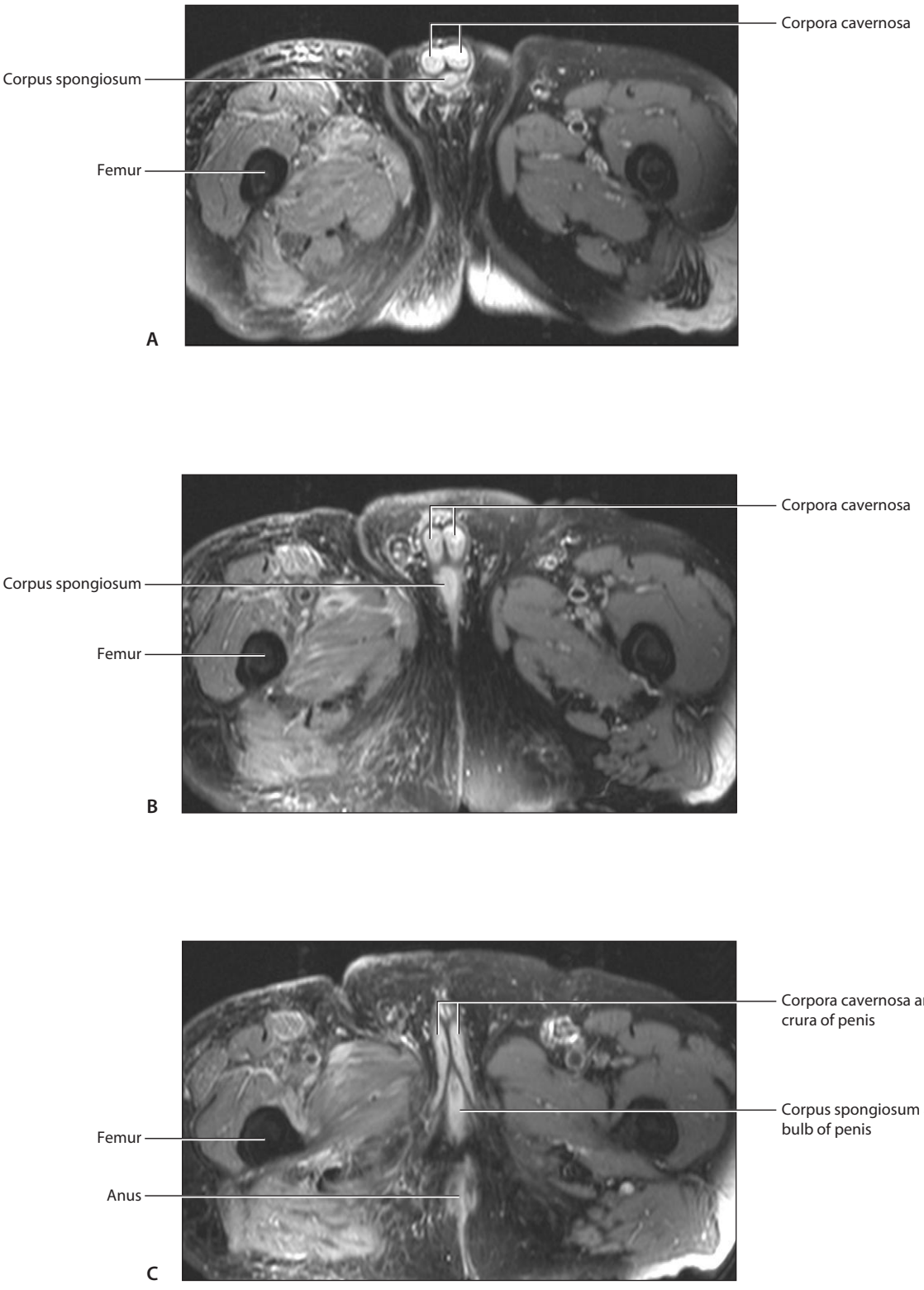

A through C – Series of axial images that pass through the pelvic cavity and perineum from inferior to superior showing the various structures and their relationships with each other.
Fat-saturated T2-weighted MR images in axial plane

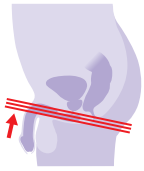

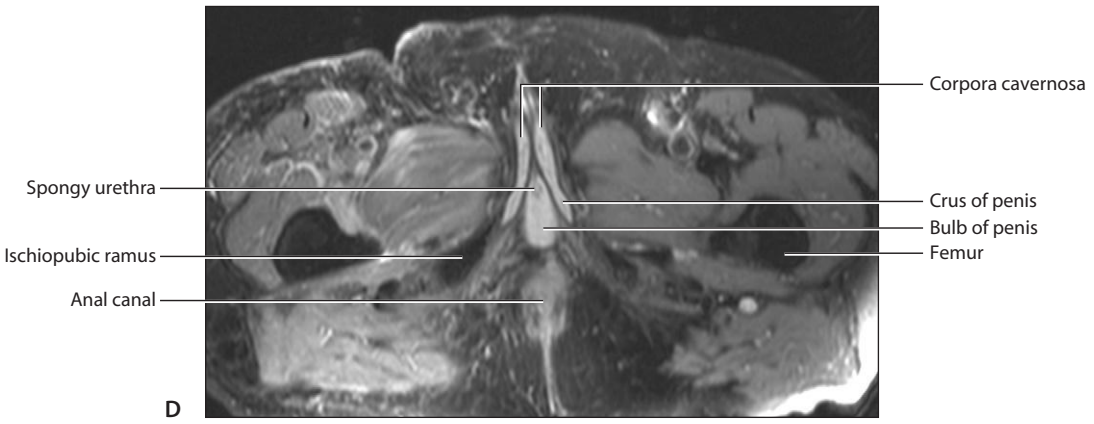

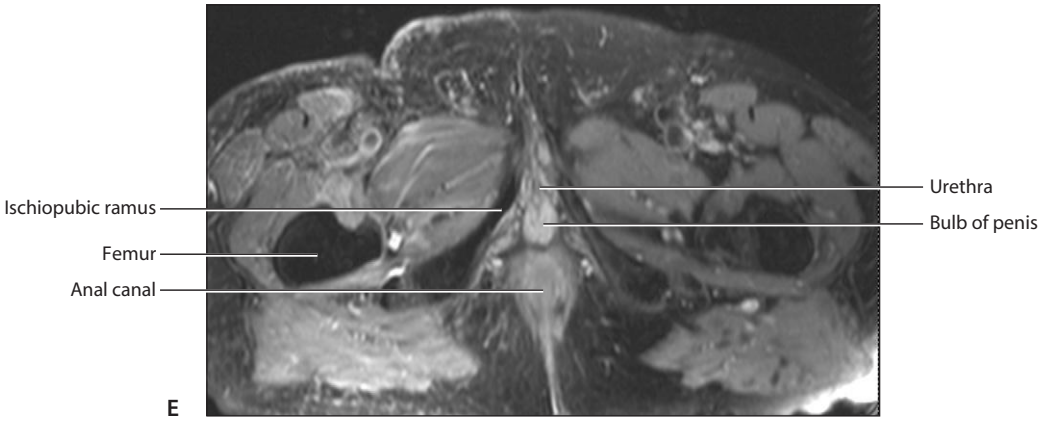

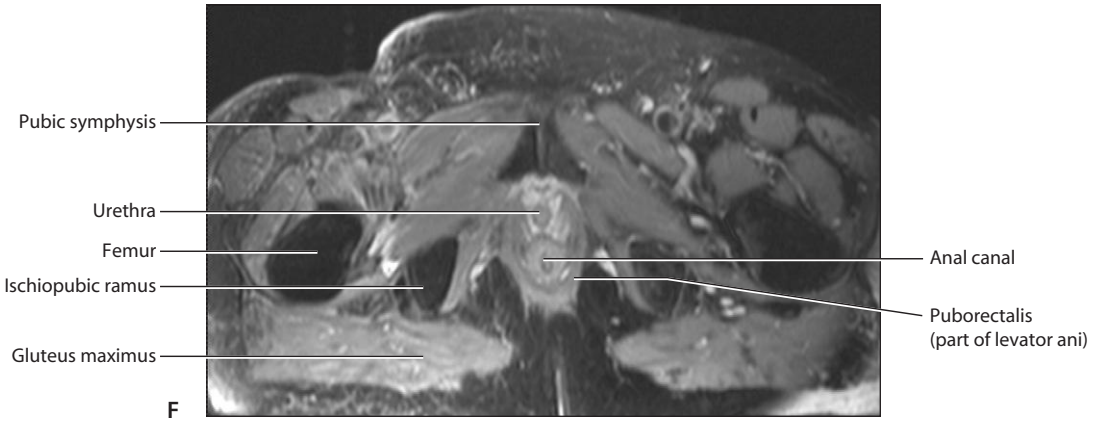

D through J – Series of axial images that pass through the pelvic cavity and perineum from inferior to superior showing the various structures and their relationships with each other.
Fat-saturated T2-weighted MR images in axial plane

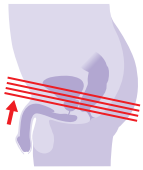

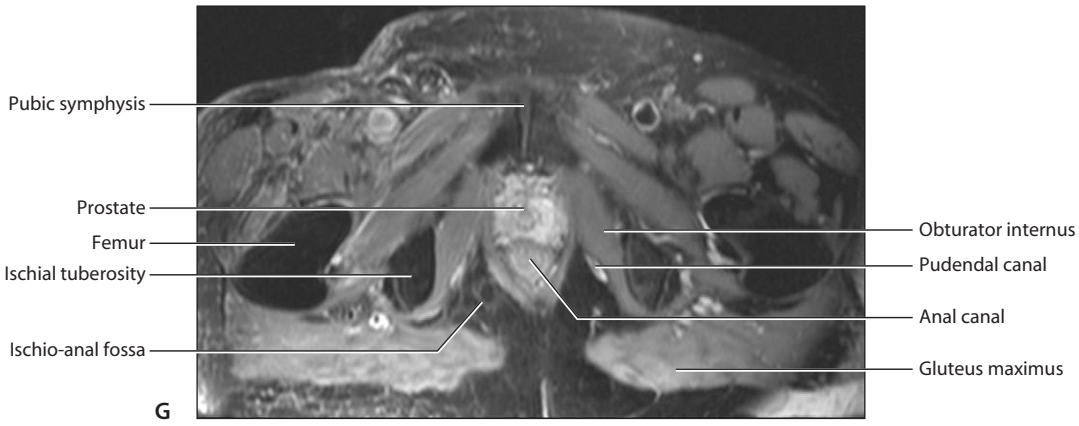
Pubic symphysis
Prostate
Femur
Ischial tuberosity
Ischio-anal fossa
Obturator internus
Pudendal canal
Anal canal
Gluteus maximus

G

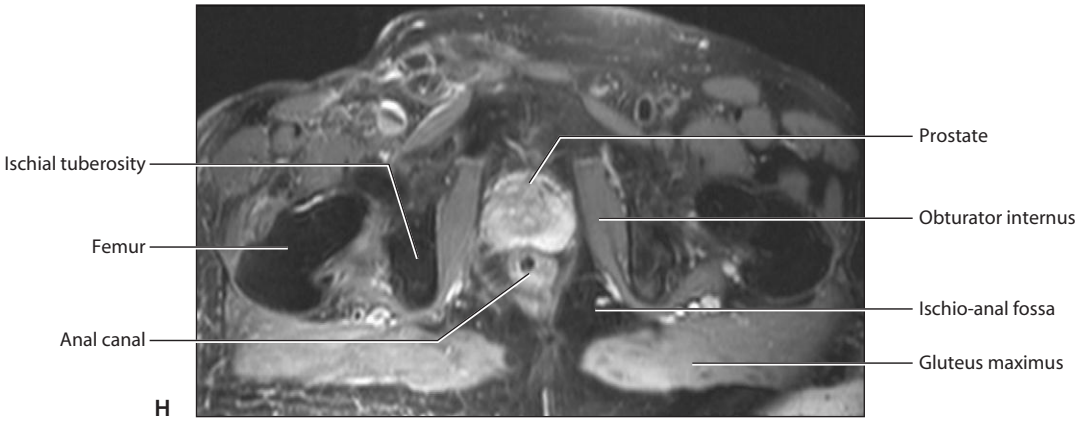
Ischial tuberosity
Femur
Anal canal
Prostate
Obturator internus
Ischio-anal fossa
Gluteus maximus

H

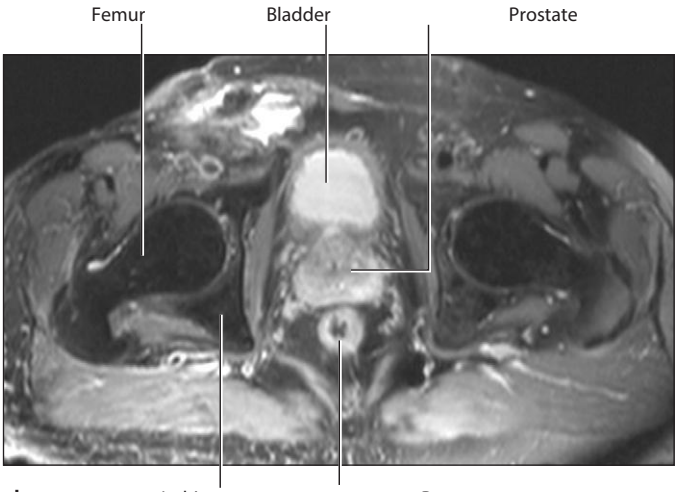
Femur
Bladder
Prostate
Ischium
Rectum

I

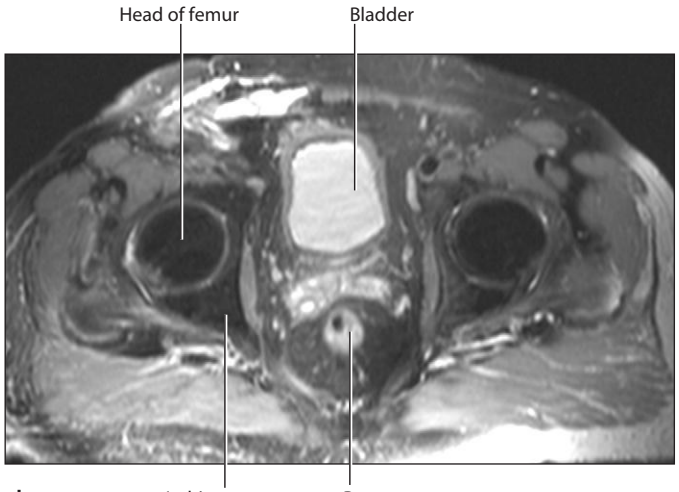
Head of femur
Bladder
Ischium
Rectum

J

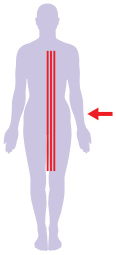

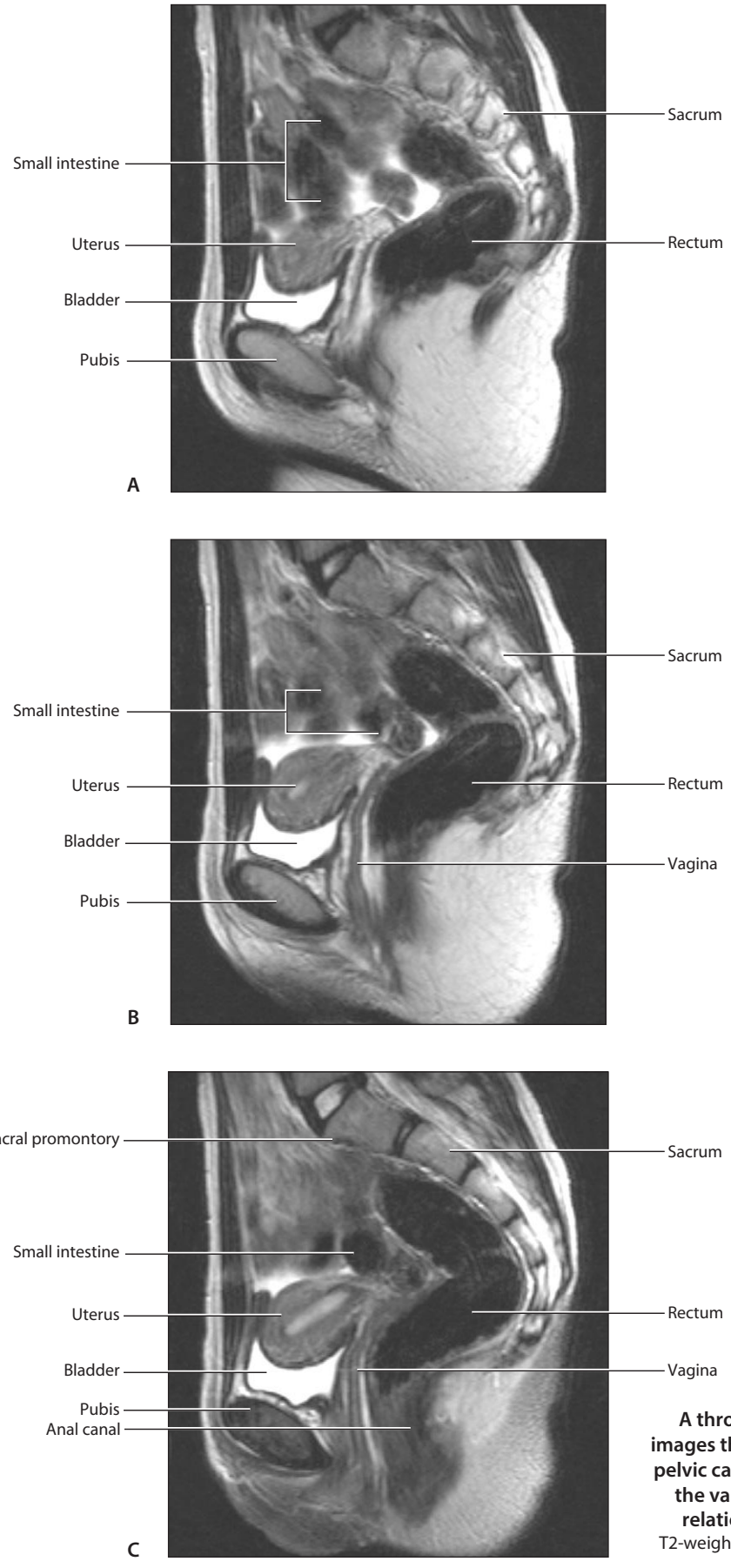

A through F – Series of sagittal images that pass through the female pelvic cavity and perineum showing the various structures and their relationships with each other.
T2-weighted MR images in sagittal plane

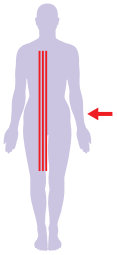

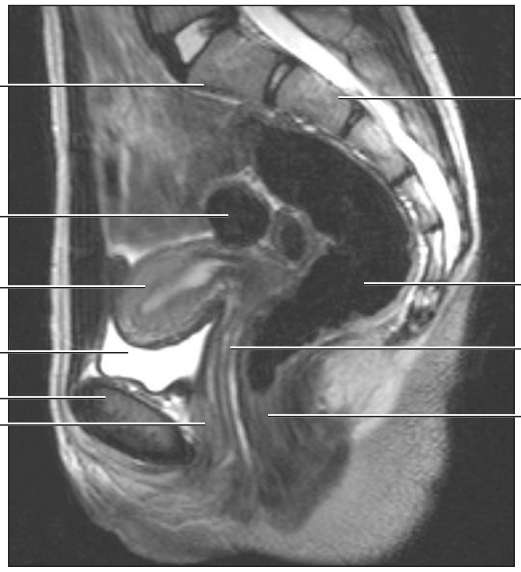
Sacral promontory
Small intestine
Uterus
Bladder
Pubic symphysis
Urethra
Sacrum
Rectum
Vagina
Anal canal

D

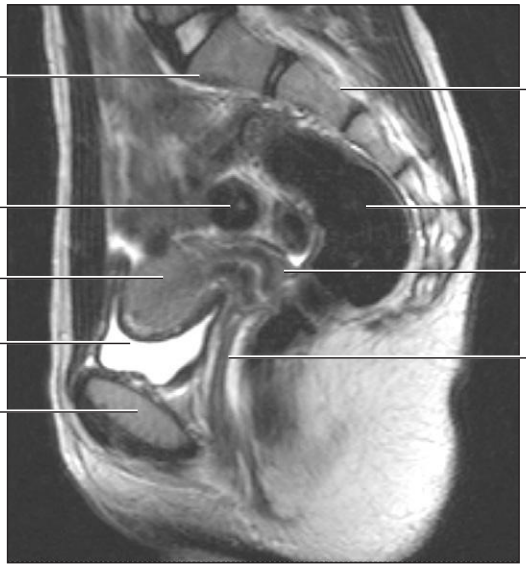
Sacral promontory
Small intestine
Uterus
Bladder
Pubis
Sacrum
Rectum
Cervix
Vagina

E

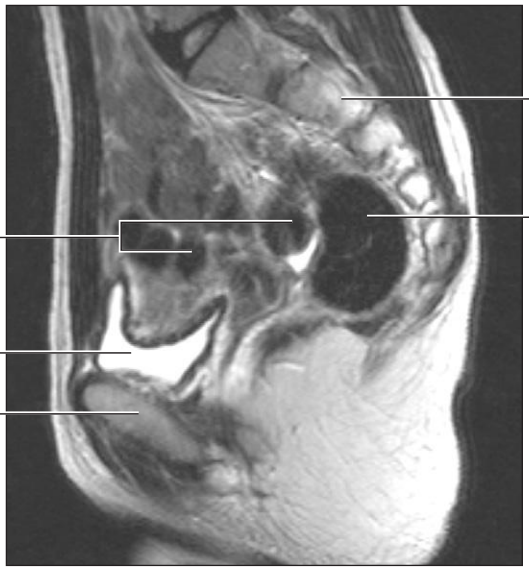
Small intestine
Bladder
Pubis
Sacrum
Rectum

F

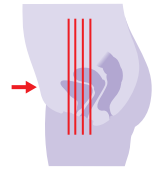

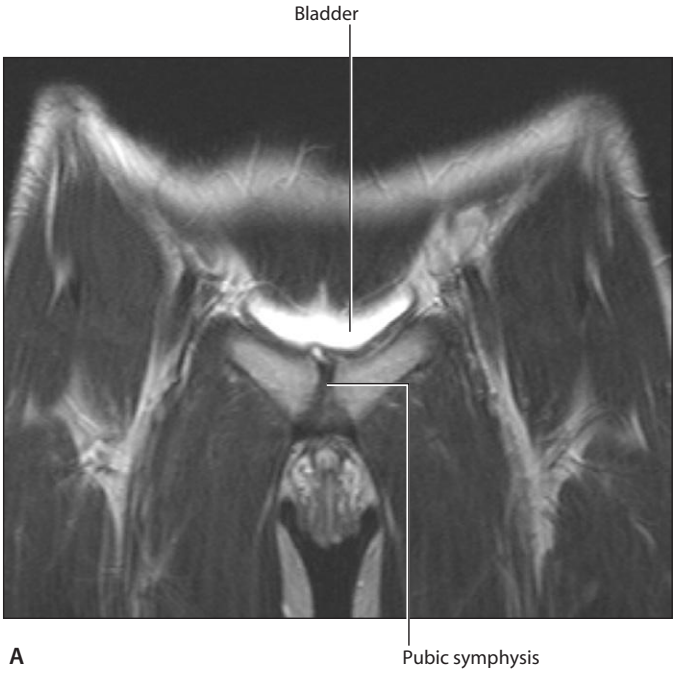

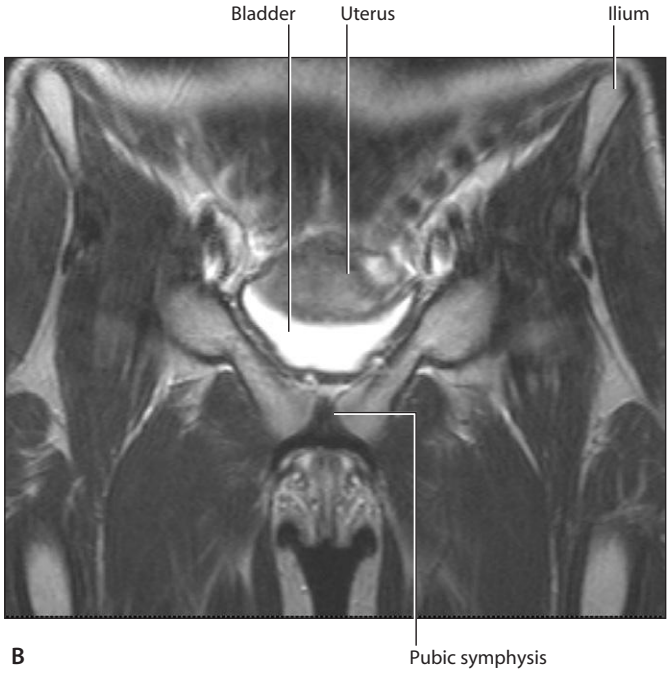

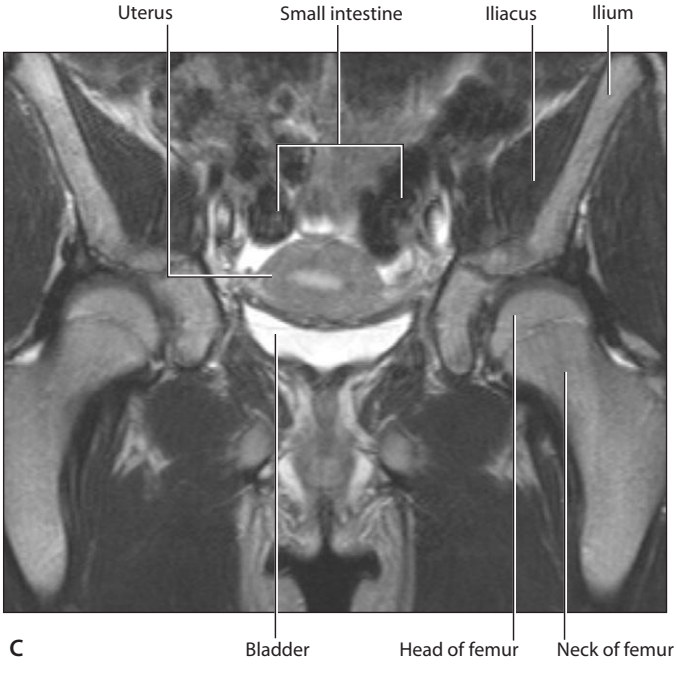

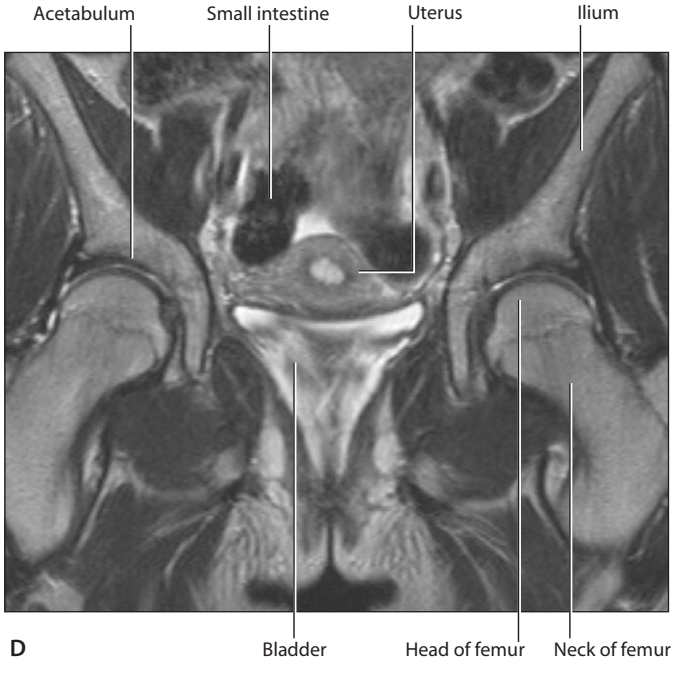

A through G – Series of coronal images that pass through the pelvic cavity and perineum from anterior to posterior showing the various structures and their relationships with each other.
T2-weighted MR images in coronal plane

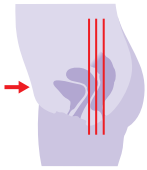

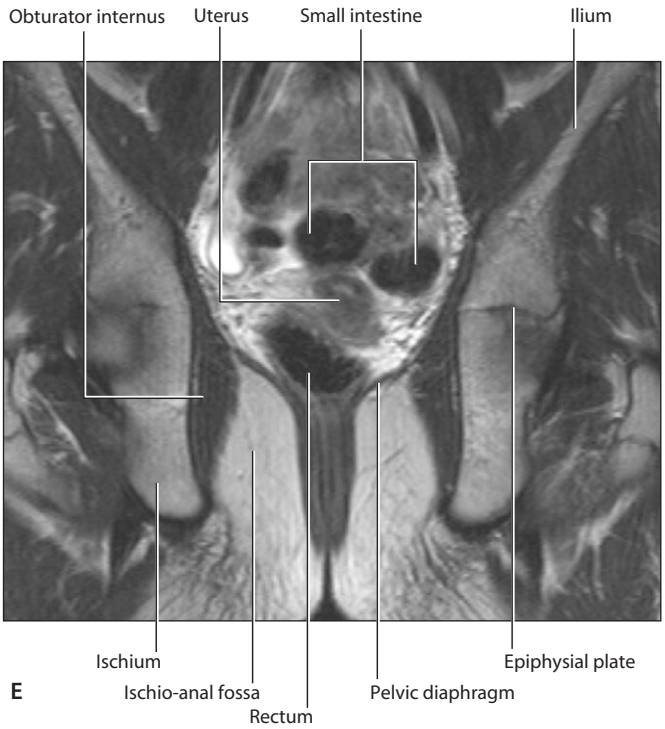
Obturator internus
Uterus
Small intestine
Ilium
Ischium
Ischio-anal fossa
Rectum
Pelvic diaphragm
Epiphysial plate

E

Small intestine
Vertebral column
Ilium
Obturator internus
Rectum
Pelvic diaphragm
Ischium

F

Sacrum
Ilium
Sacro-iliac joint
Rectum

G

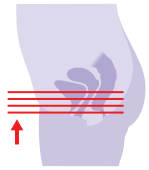

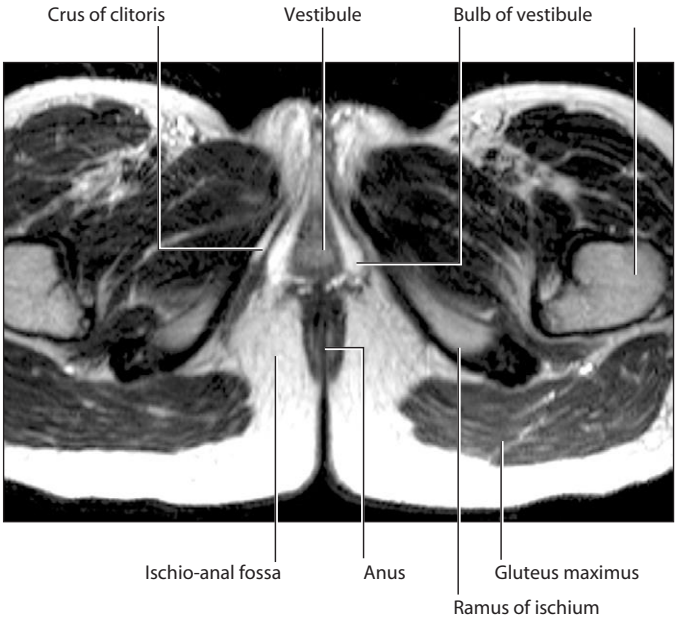

A

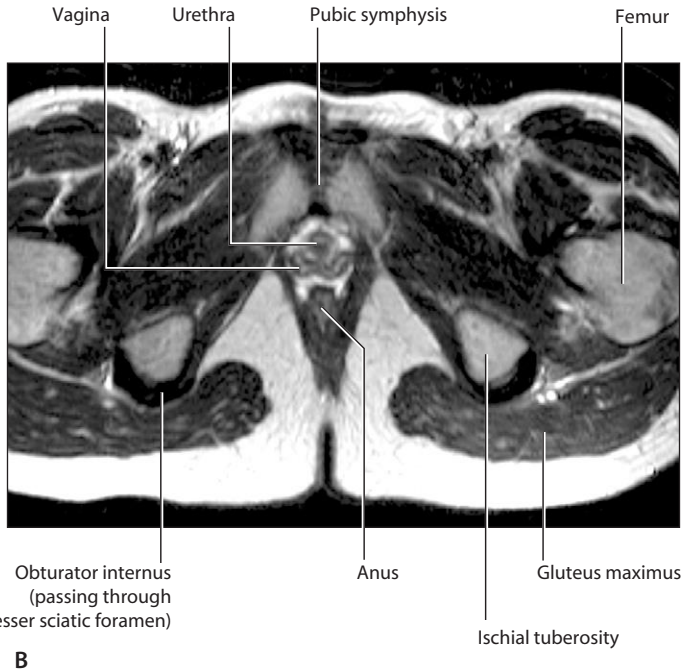

B

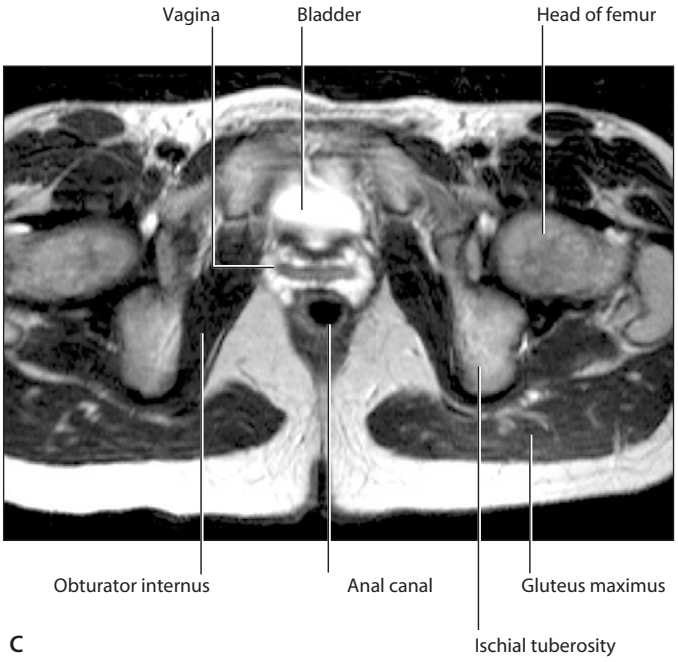

C

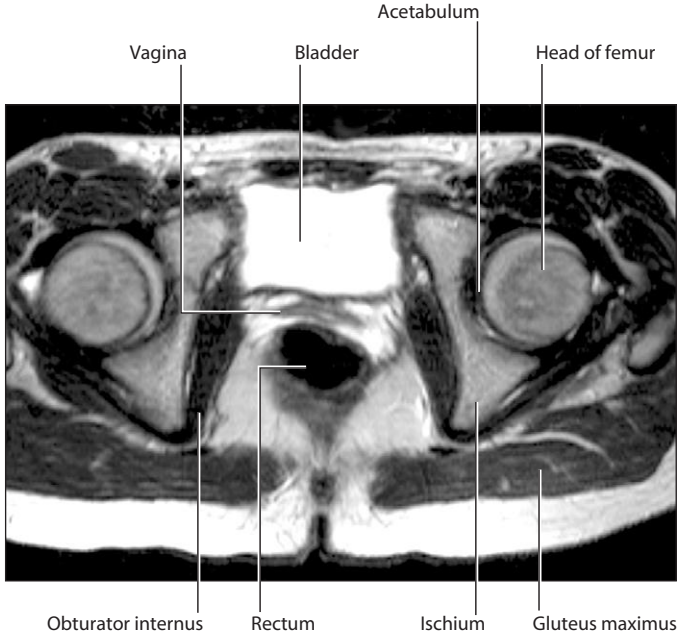

D

A through H – Series of axial images that pass through the pelvic cavity and perineum from inferior to superior showing the various structures and their relationships with each other.
T2-weighted MR images in axial plane

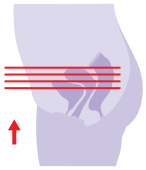

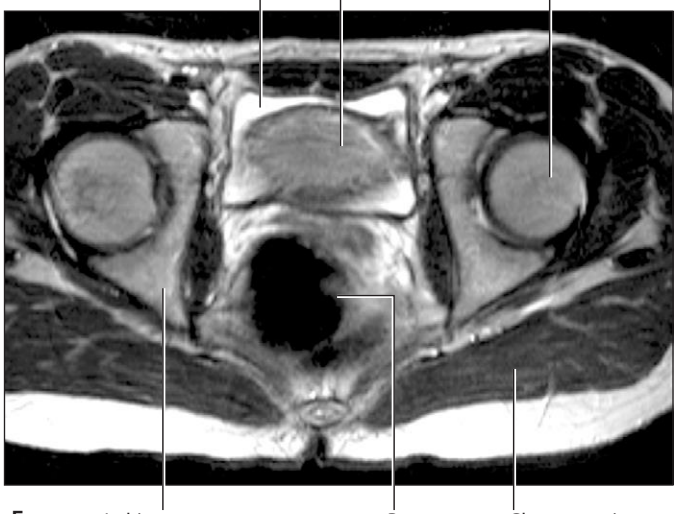
Bladder
Uterus
Head of femur
Ischium
Rectum
Gluteus maximus

E

Acetabulum
Uterus
Cervix
Head of femur
Ischium
Rectum
Gluteus maximus

F

Uterus
Cervix
Rectum
Ilium

G

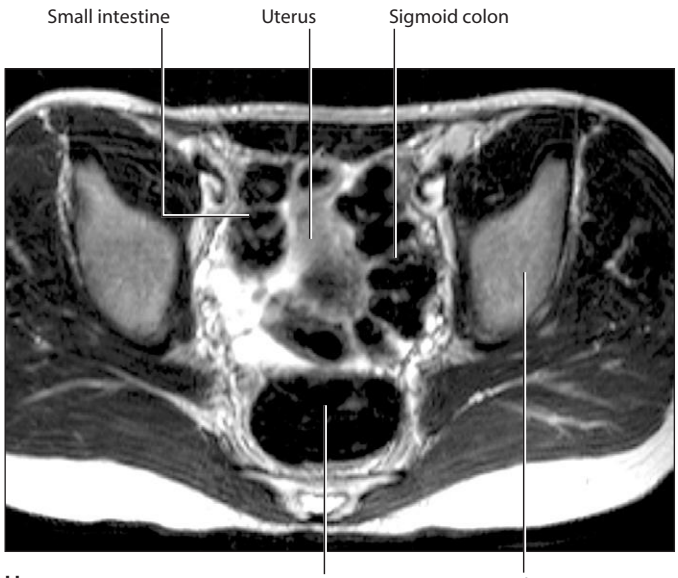
Small intestine
Uterus
Sigmoid colon
Rectum
Ilium

H

Branches of the sacral plexus

(spinal segments in parentheses do not consistently participate)

Branch		Spinal segments	Motor function	Sensory (cutaneous) function
Tibial part	1	L4 to S3	All muscles in the posterior or hamstring compartment of the thigh (including the hamstring part of the adductor magnus) except for the short head of the biceps All muscles in the posterior compartment of the leg All muscles in the sole of the foot	Skin on posterolateral and lateral surfaces of foot and sole of foot
Common fibular part	2	L4 to S2	Short head of biceps in the posterior compartment of the thigh All muscles in the anterior and lateral compartments of the leg Extensor digitorum brevis in the foot (also contributes to the supply of the first dorsal interosseous muscle)	Skin on the anterolateral surface of the leg and dorsal surface of the foot
Pudendal	3	S2 to S4	Skeletal muscles in the perineum including the external urethral and anal sphincters and levator ani (overlaps in supply of the levator ani and external sphincter with branches directly from ventral division of S4)	Most skin of the perineum, penis and clitoris
Superior gluteal	4	L4 to S1	Gluteus medius, gluteus minimus, and tensor fasciae latae	
Inferior gluteal	5	L5 to S2	Gluteus maximus	
Nerve to obturator internus and superior gemellus	6	L5 to S2	Obturator internus and superior gemellus	
Nerve to quadratus femoris and inferior gemellus	7	L4 to S1	Quadratus femoris and inferior gemellus	
Posterior femoral cutaneous (posterior cutaneous nerve of thigh)	8	S1, S3		Skin on the posterior aspect of the thigh
Perforating cutaneous	9	S2, S3		Skin over gluteal fold (overlaps with posterior femoral cutaneous)
Nerve to piriformis	10	(L5), S1, S2	Piriformis muscle	
Nerves to levator ani, coccygeus, and external anal sphincter	11	S4	Levator ani, coccygeus, and external anal sphincter (overlaps with pudendal nerve)	Small patch of skin between anus and coccyx

Branch		Spinal segments	Motor function	Sensory (cutaneous) function
Pelvic splanchnic nerves	12	S2, S3 (S4)	Visceral motor (preganglionic parasympathetic) to pelvic part of prevertebral plexus Stimulate erection, modulate mobility in gastrointestinal system distal to the left colic flexure, inhibitory to internal urethral sphincter	Visceral afferents from pelvic viscera and distal parts of colon. Pain from cervix and possibly from bladder and proximal urethra

Branches of the coccygeal plexus

Anococcygeal nerves	13	S4 to Co	Peri-anal skin	

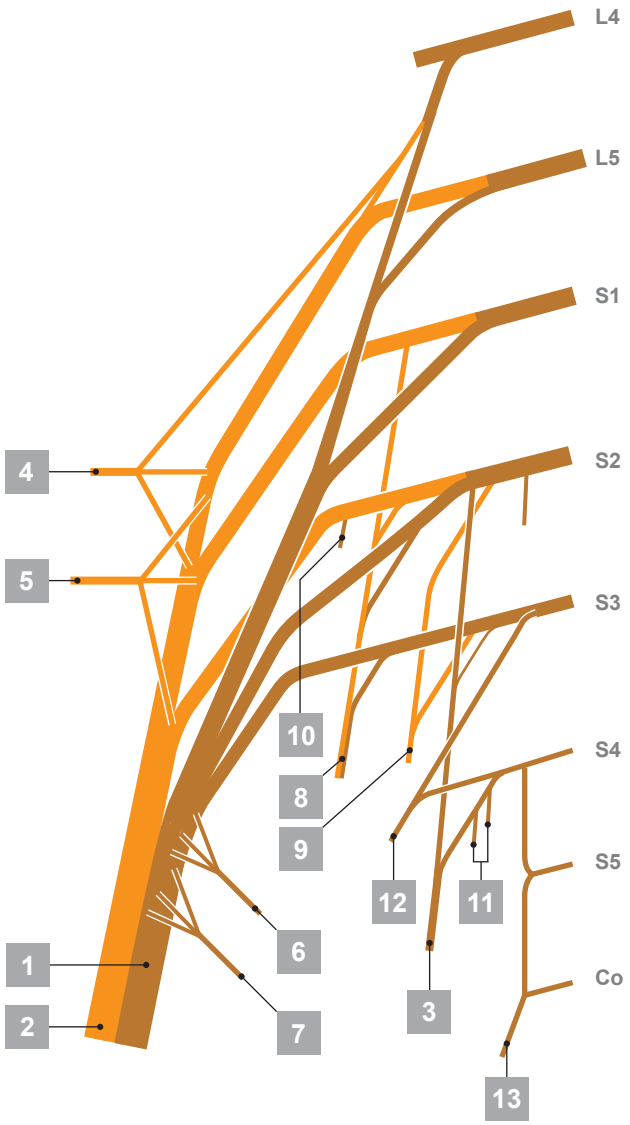

Muscles of the pelvic walls

(spinal segments in bold are the major segments innervating the muscle)

Muscle		Origin	Insertion	Innervation	Function
Obturator internus	1	Anterolateral wall of true pelvis (deep surface of obturator membrane and surrounding bone)	Medial surface of greater trochanter of femur	Nerve to obturator internus **L5**, **SI**	Lateral rotation of the extended hip joint; abduction of flexed hip
Piriformis	2	Anterior surface of sacrum between anterior sacral foramina	Medial side of superior border of greater trochanter of femur	Branches from L5, **SI**, and **S2**	Lateral rotation of the extended hip joint; abduction of flexed hip

Muscles of the pelvic diaphragm

Levator ani	3	In a line around the pelvic wall beginning on the posterior aspect of the pubic bone and extending across the obturator internus muscle as a tendinous arch (thickening of the obturator internus fascia) to the ischial spine	The anterior part is attached to the superior surface of the perineal membrane; the posterior part meets its partner on the other side at the perineal body, around the anal canal, and along the anococcygeal ligament	Branches direct from the anterior ramus of S4, and by the inferior rectal branch of the pudendal nerve (S2 to S4)	Contributes to the formation of the pelvic floor, which supports the pelvic viscera; maintains an angle between the rectum and anal canal. Reinforces the external anal sphincter and, in women, functions as a vaginal sphincter
Coccygeus	4	Ischial spine and pelvic surface of the sacrospinous ligament	Lateral margin of coccyx and related border of sacrum	Branches from the anterior rami of S3 and S4	Contributes to the formation of the pelvic floor, which supports the pelvic viscera; pulls coccyx forward after defecation

Muscles within the deep perineal pouch

External urethral sphincter	5	From the inferior ramus of the pubis on each side and adjacent walls of the deep perineal pouch	Surrounds membranous part of urethra	Perineal branches of the pudendal nerve (S2 to S4)	Compresses the membranous urethra; relaxes during micturition
Deep transverse perineal	6	Medial aspect of ischial ramus	Perineal body	Perineal branches of the pudendal nerve (S2 to S4)	Stabilizes the position of the perineal body
Compressor urethrae (in women only)	7	Ischiopubic ramus on each side	Blends with partner on other side anterior to the urethra	Perineal branches of the pudendal nerve (S2 to S4)	Functions as an accessory sphincter of the urethra
Sphincter urethrovaginalis (in women only)	8	Perineal body	Passes forward lateral to the vagina to blend with partner on other side anterior to the urethra	Perineal branches of the pudendal nerve (S2 to S4)	Functions as an accessory sphincter of the urethra (also may facilitate closing the vagina)

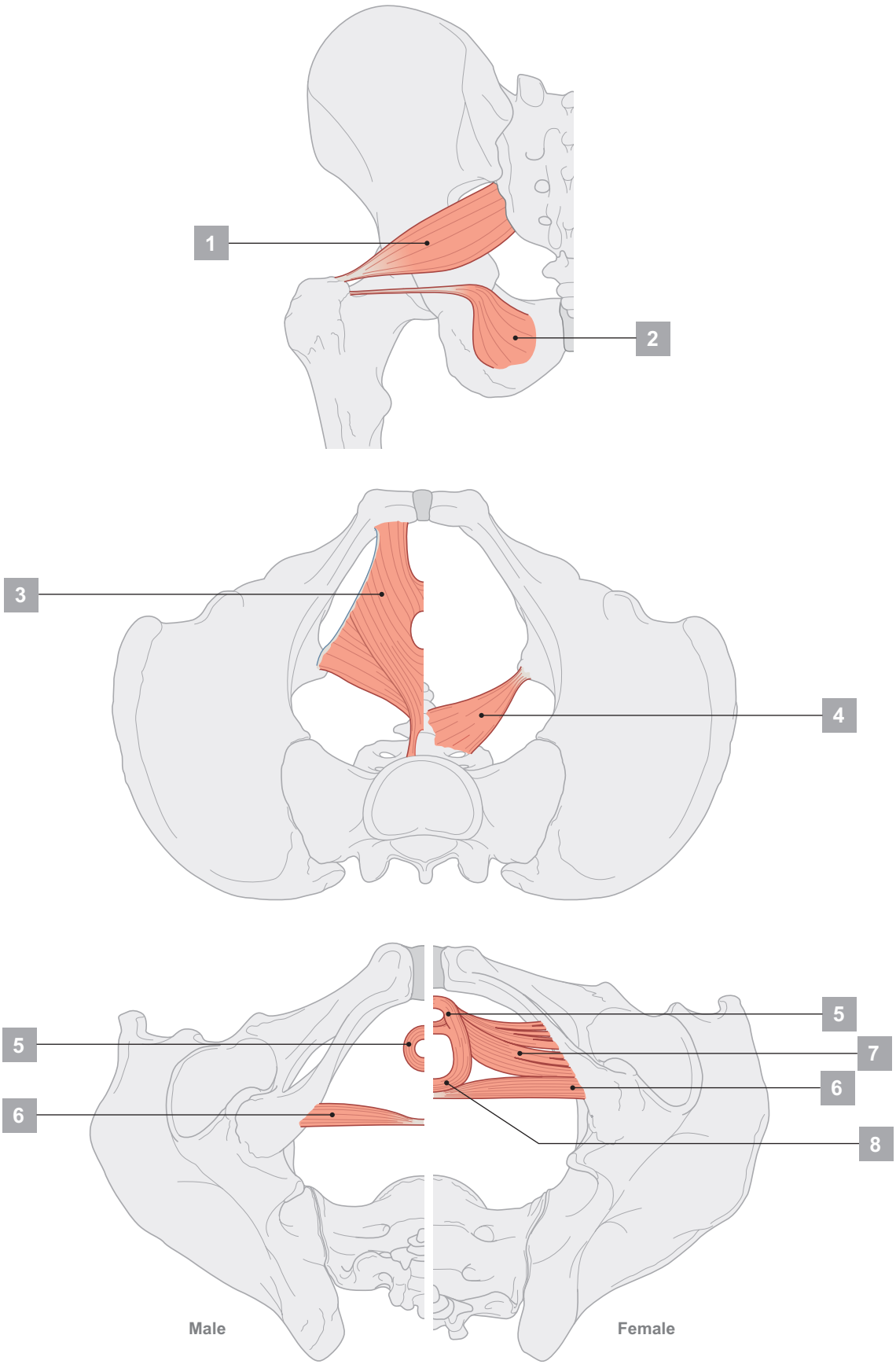
1
2
3
4
5
6
5
7
6
8
Male
Female

Muscles of the anal triangle

Muscle		Origin	Insertion	Innervation	Function
EXTERNAL ANAL SPHINCTER **Deep part**	1	Surrounds superior aspect of anal canal		Pudendal nerve (S2 and S3) and branches directly from S4	Closes anal canal
Superficial part	2	Surrounds lower part of anal canal	Anchored to perineal body and anococcygeal body		
Subcutaneous part	3	Surrounds anal aperture			

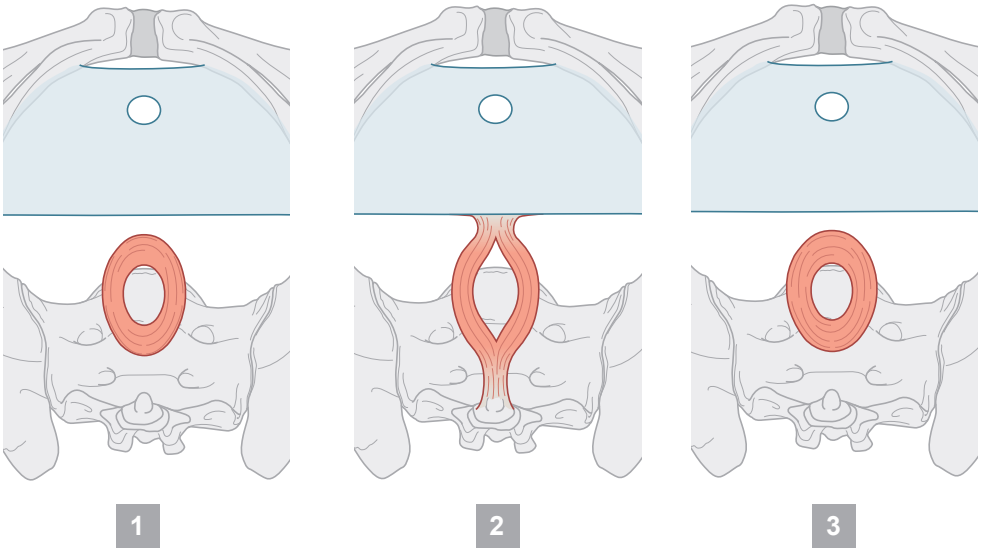

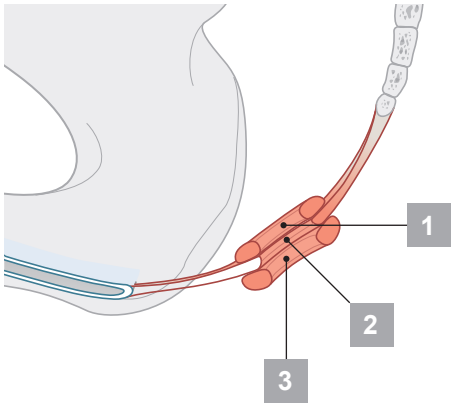

Muscles of the superficial perineal pouch

Muscle		Origin	Insertion	Innervation	Function
Ischiocavernosus	1	Ischial tuberosity and ramus	Crus of penis and clitoris	Pudendal nerve (S2 to S4)	Move blood from crura into the body of the erect penis and clitoris
Bulbospongiosus	2	In women: perineal body In men: perineal body, midline raphe	In women: bulb of vestibule, perineal membrane, body of clitoris, and corpus cavernosum In men: bulbospongiosus, perineal membrane, and corpus cavernosum	Pudendal nerve (S2 to S4)	Move blood from attached parts of the clitoris and penis into the glans In men: removal of residual urine from urethra after urination; pulsatile emission of semen during ejaculation
Superficial transverse perineal	3	Ischial tuberosity and ramus	Perineal body	Pudendal nerve (S2 to S4)	Stabilize the perineal body

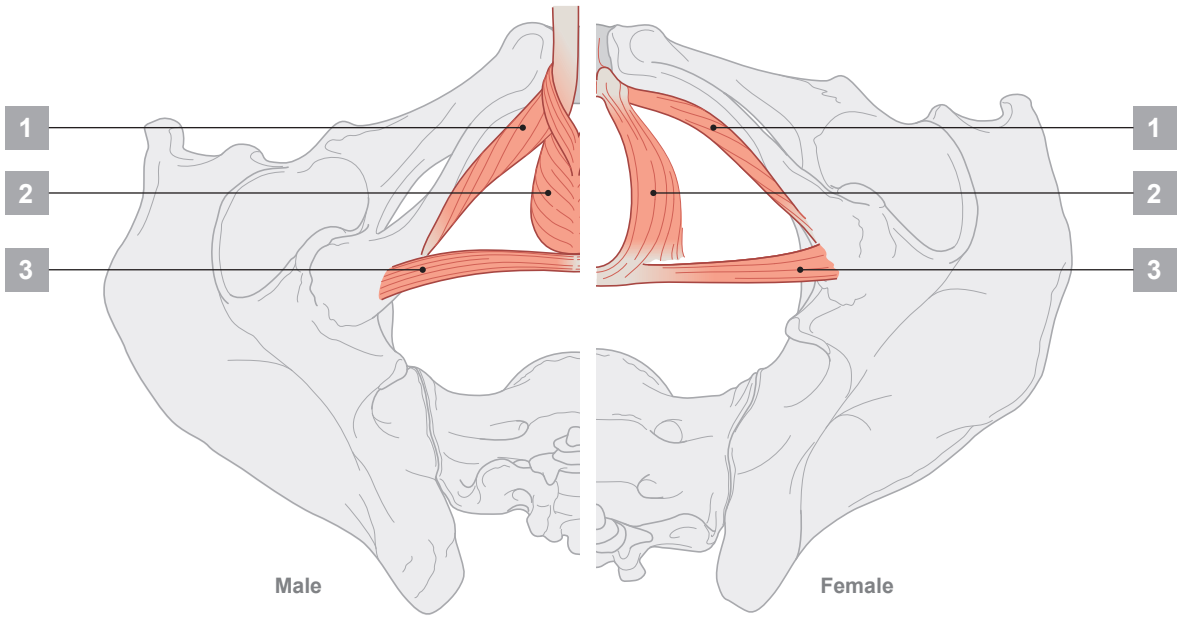

This page intentionally left blank

6

LOWER LIMB

CONTENTS

Surface anatomy **292**
Bones of the lower limb **293**
Pelvic bones and sacrum **294**
Articulated pelvis **295**
Proximal femur **296**
Hip joint **297**
Hip joint: structure and arterial supply **299**
Gluteal region: attachments and superficial musculature **300**
Gluteal region: superficial and deep muscles **301**
Gluteal region: arteries and nerves **302**
Distal femur and proximal tibia and fibula **304**
Thigh: muscle attachments **305**
Thigh: anterior superficial musculature **306**
Thigh: posterior superficial musculature **307**
Thigh: anterior compartment muscles **308**
Thigh: medial compartment muscles **309**
Femoral triangle **310**
Anterior thigh: arteries and nerves **311**
Anterior thigh: arteries **312**
Thigh: posterior compartment muscles **313**
Posterior thigh: arteries and nerves **314**
Transverse sections: thigh **316**
Knee joint **318**
Ligaments of the knee **320**
Menisci and cruciate ligaments **322**
Knee: bursa and capsule **326**
Knee surface: muscles, capsule, and arteries **327**
Popliteal fossa **328**
Tibia and fibula **329**
Bones of the foot **330**
Bones and joints of the foot **333**
Talus and calcaneus **334**
Ankle joint **335**
Ligaments of the ankle joint **336**
Leg: muscle attachments **339**
Posterior leg: superficial muscles **340**
Posterior compartment: deep muscles **341**
Posterior leg: arteries and nerves **342**
Lateral compartment: muscles **343**
Anterior leg: superficial muscles **344**
Anterior compartment: muscles **345**
Anterior leg: arteries and nerves **346**
Leg: cutaneous nerves **347**
Transverse sections: leg **348**
Foot: muscle attachments **350**
Foot: ligaments **351**
Dorsum of foot **353**
Dorsum of foot: arteries and nerves **354**
Plantar aponeurosis **356**
Plantar region (sole) musculature: first layer **357**
Plantar region (sole) musculature: second layer **358**
Plantar region (sole) musculature: third layer **359**
Plantar region (sole) musculature: fourth layer **360**
Plantar region (sole): arteries and nerves **361**
Dorsal hood and tarsal tunnel **363**
Superficial veins of the lower limb **364**
Lymphatics of the lower limb **365**
Anterior cutaneous nerves and dermatomes of the lower limb **366**
Posterior cutaneous nerves and dermatomes of the lower limb **367**
Tables **368**

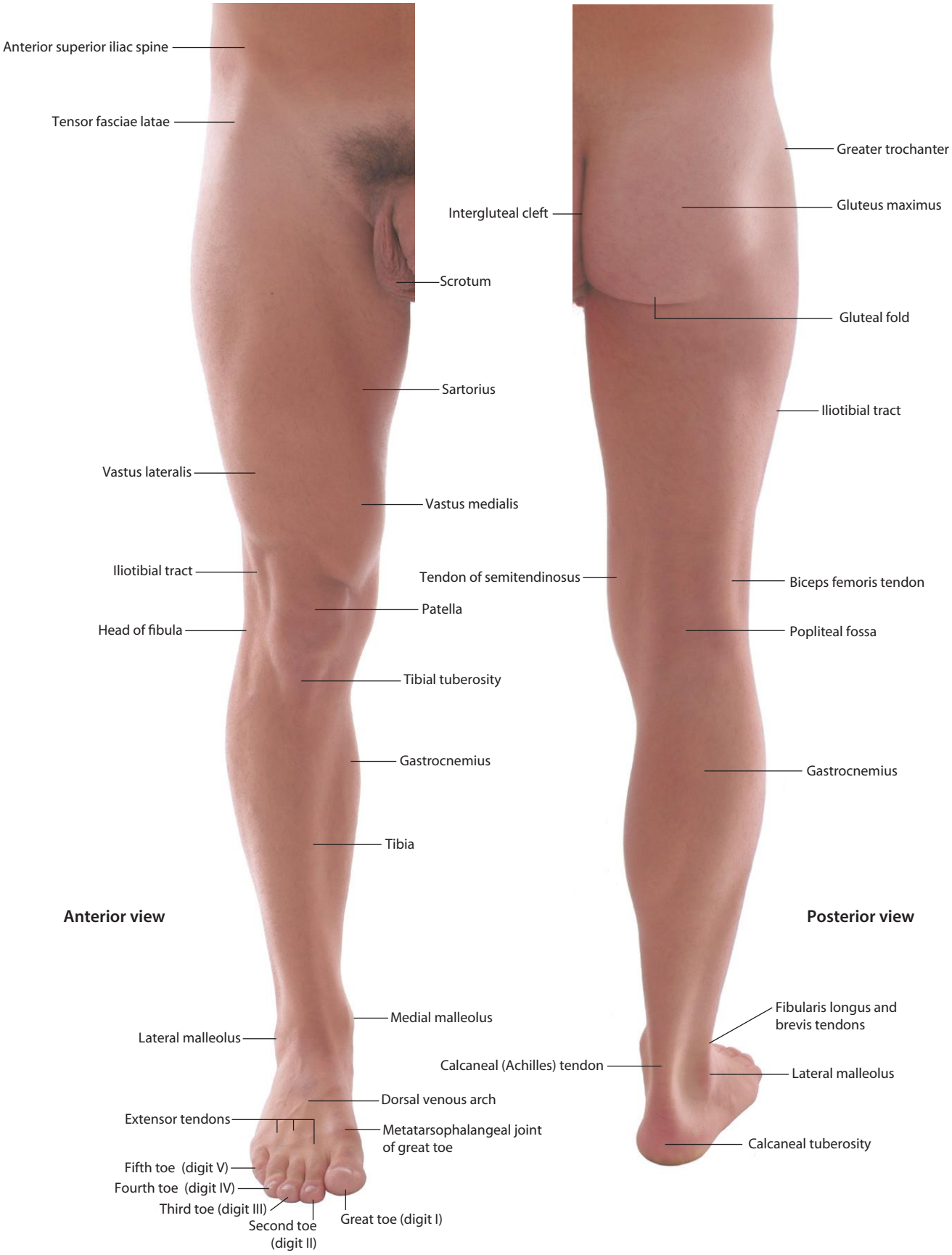

tahir99-VRG & vip.persianss.ir

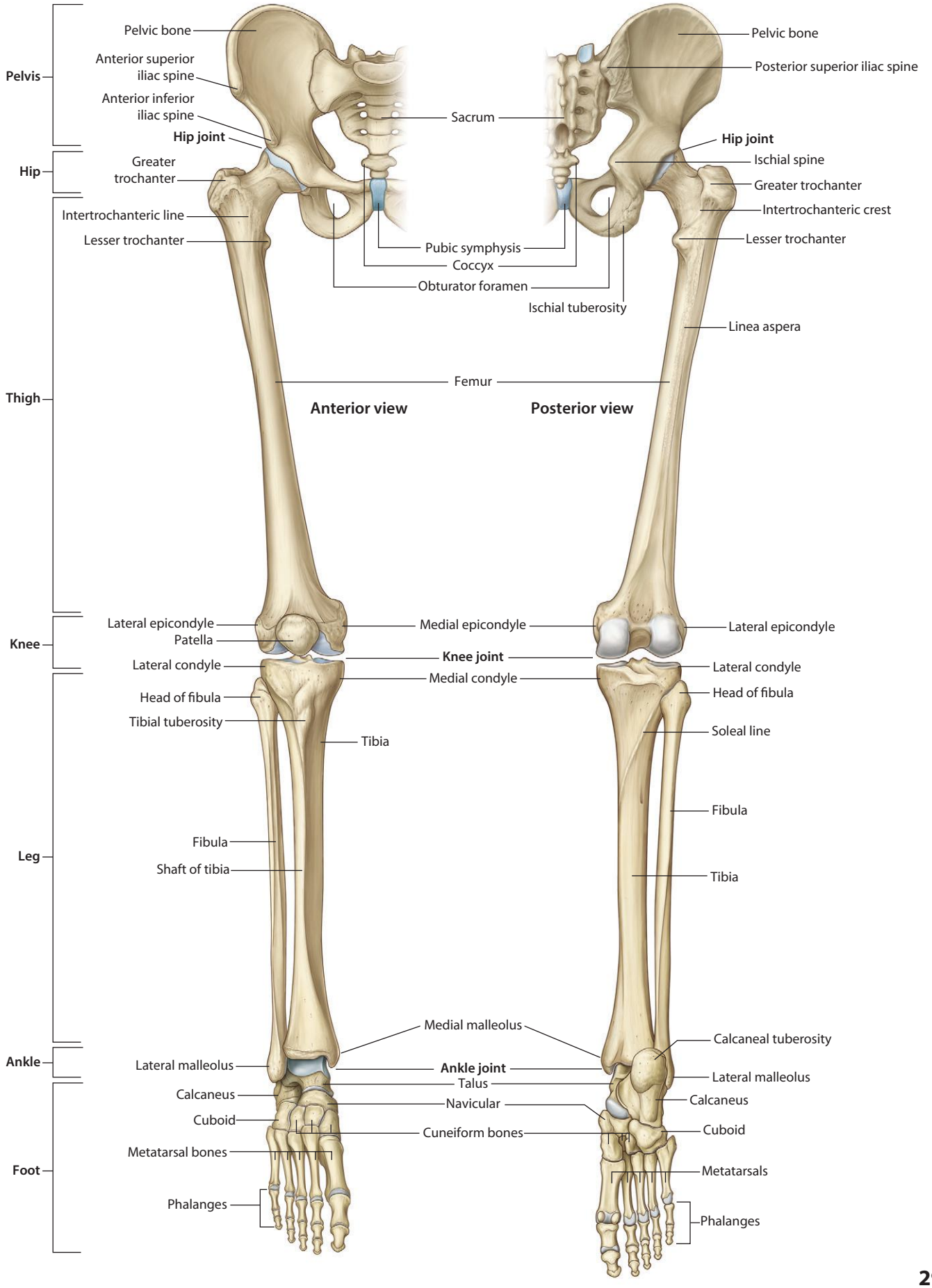

tahir99-VRG & vip.persianss.ir

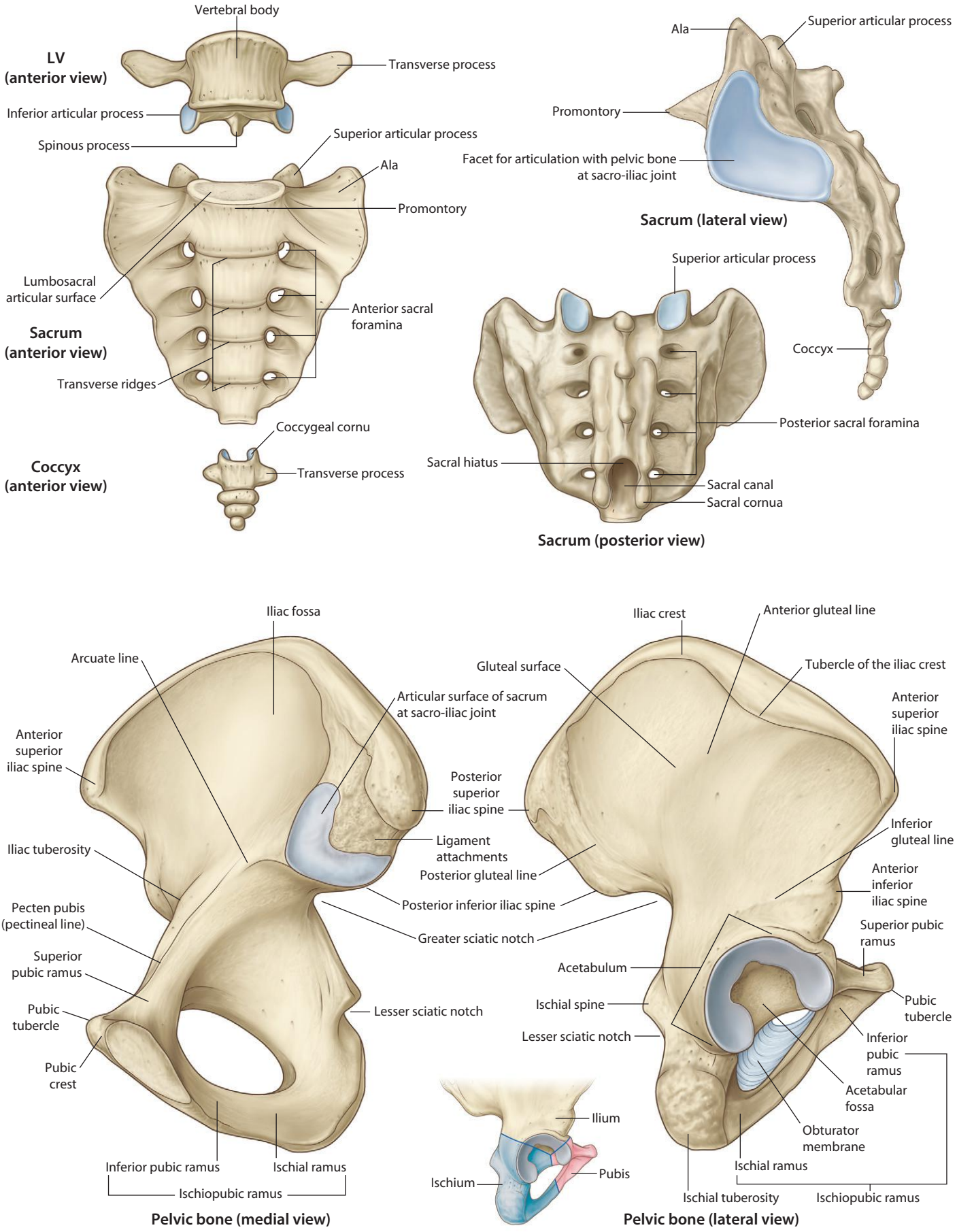

tahir99-VRG & vip.persianss.ir

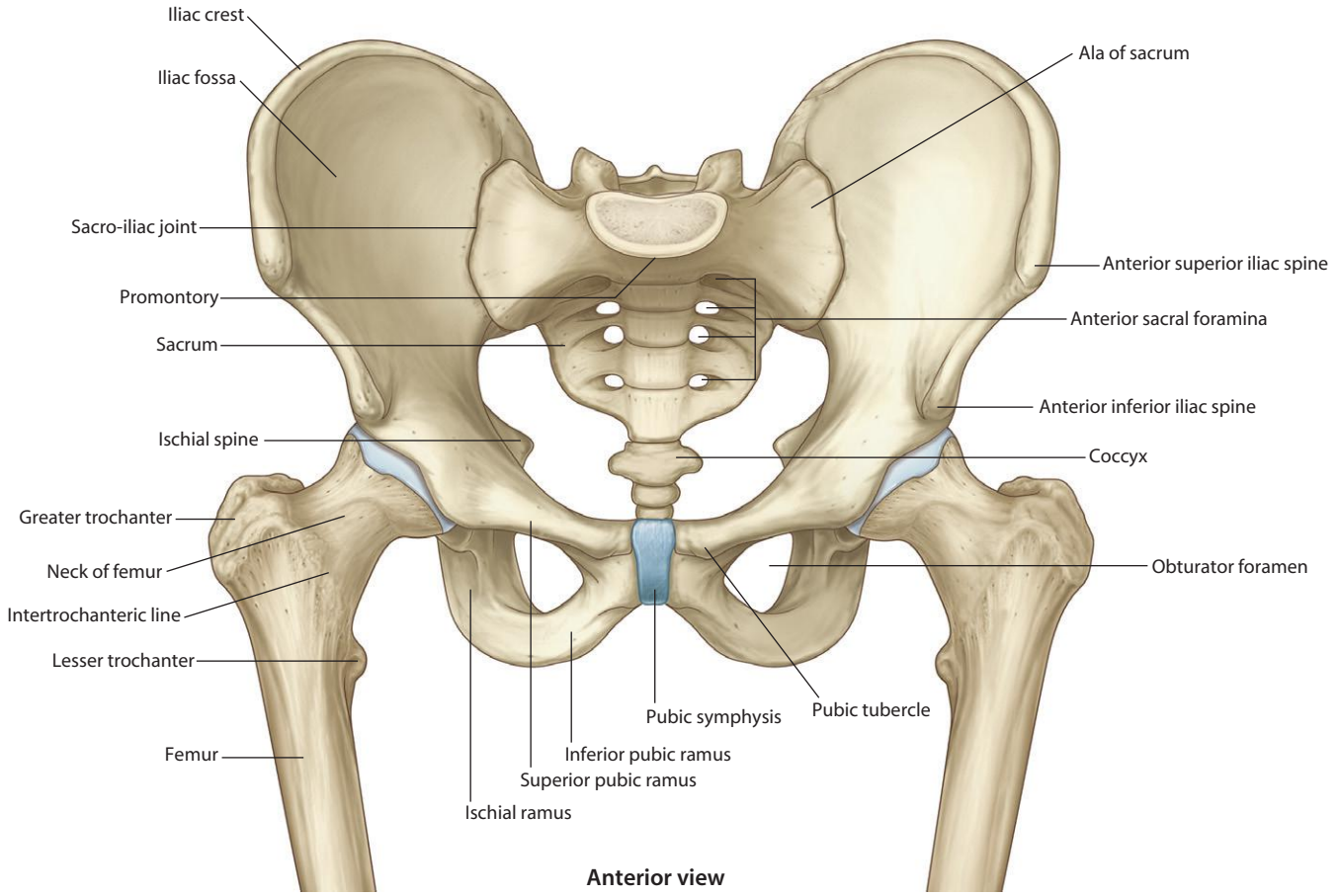

Anterior view

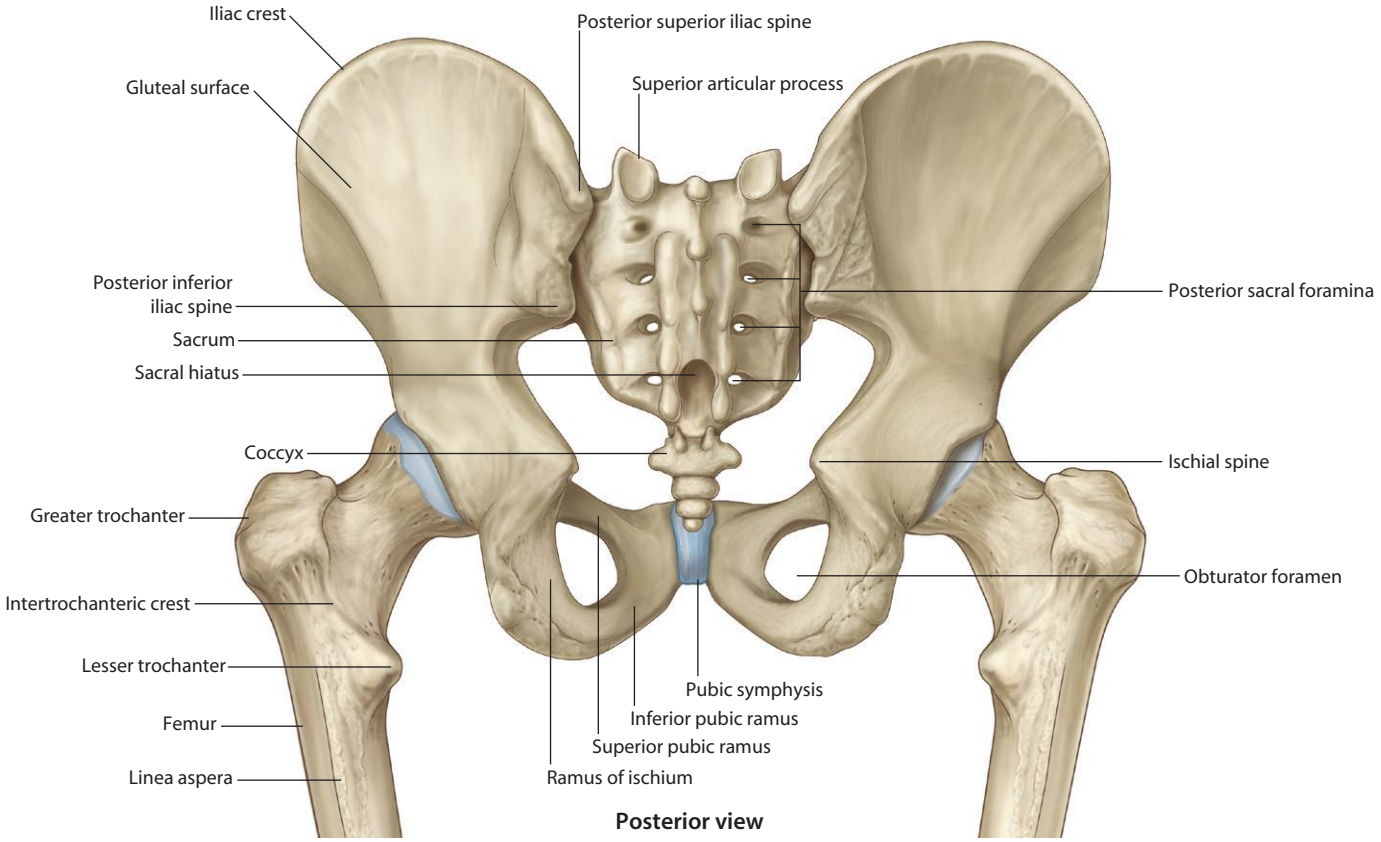

Posterior view

tahir99-VRG & vip.persianss.ir

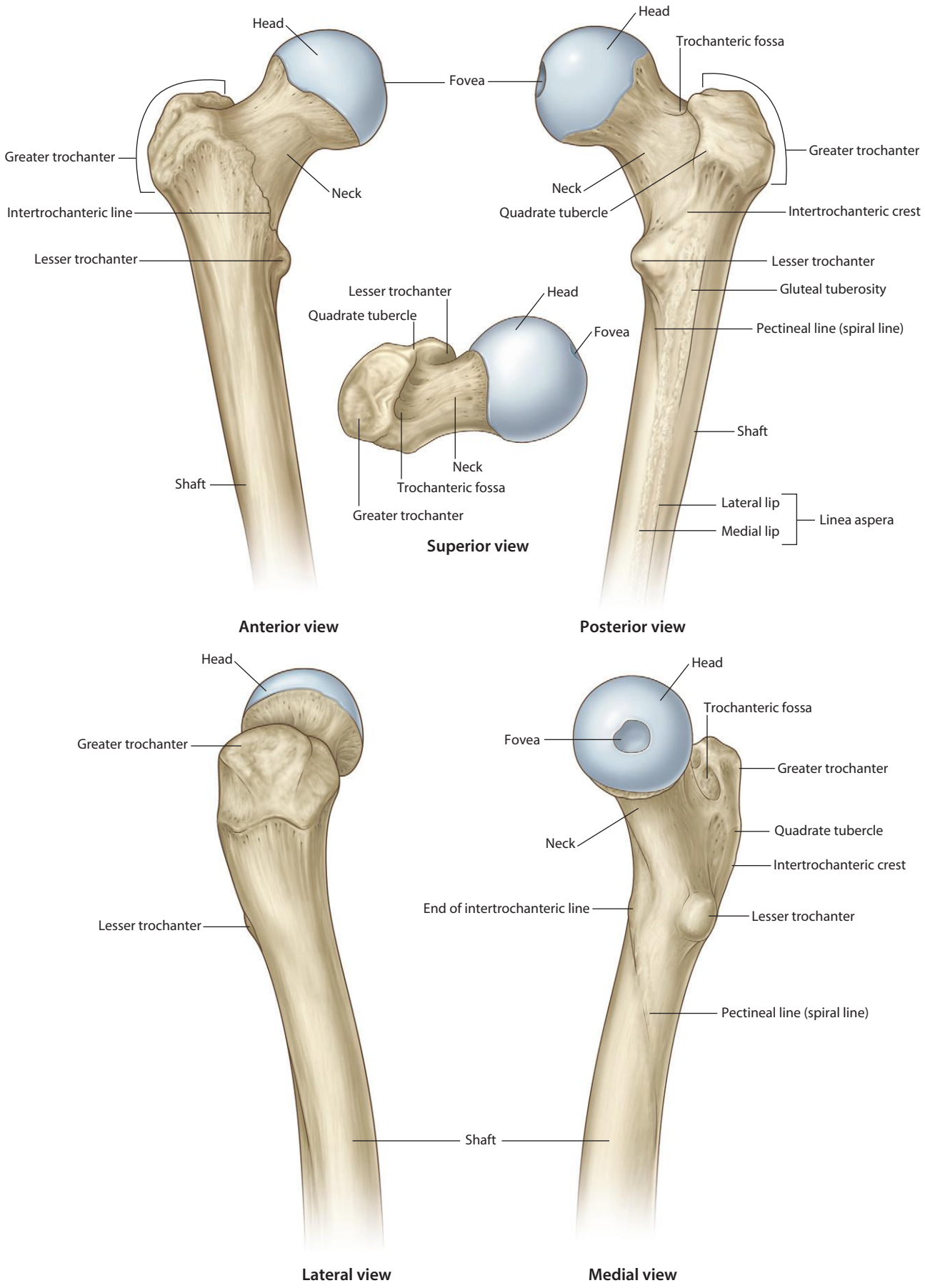

tahir99-VRG & vip.persianss.ir

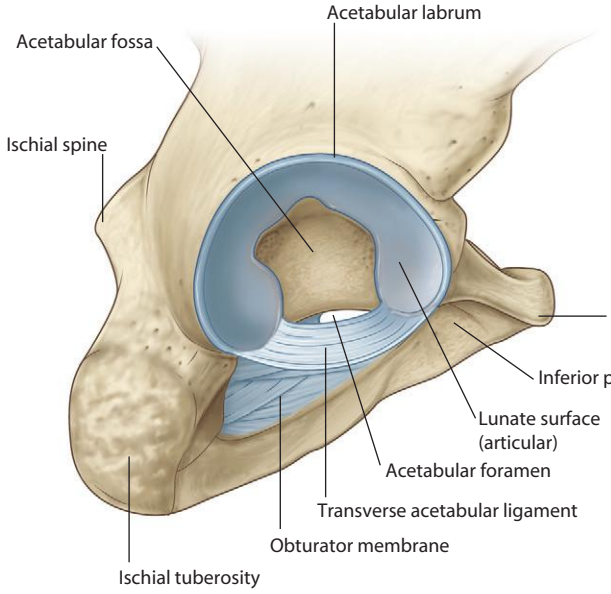

Acetabular fossa and transverse acetabular ligament

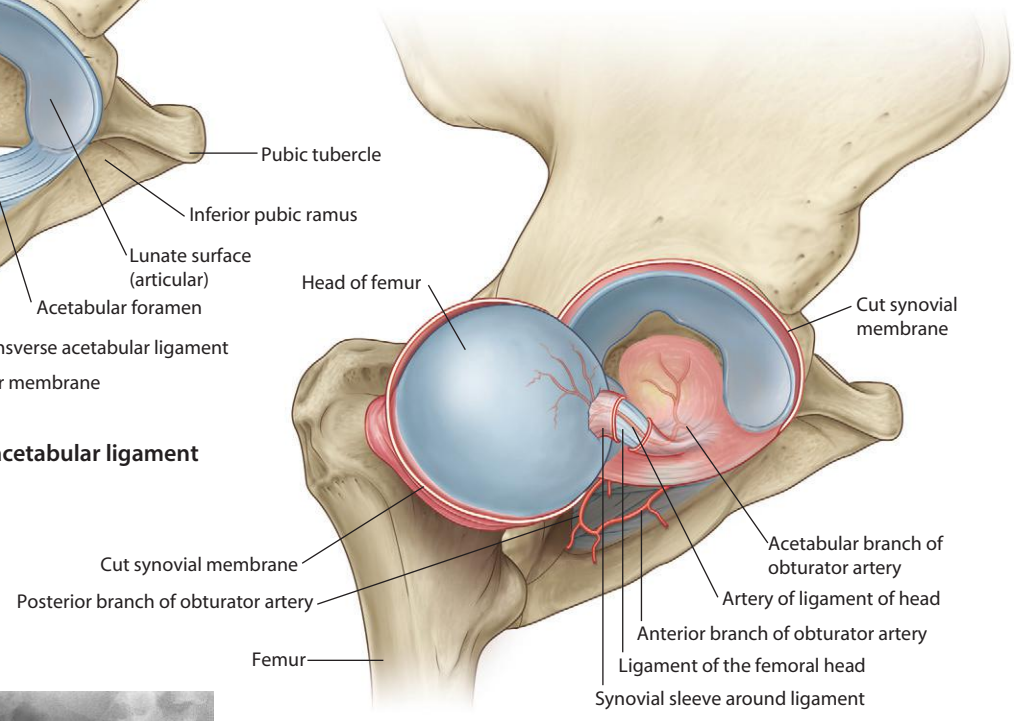

Ligament of head of femur.
The head of the femur has been laterally rotated

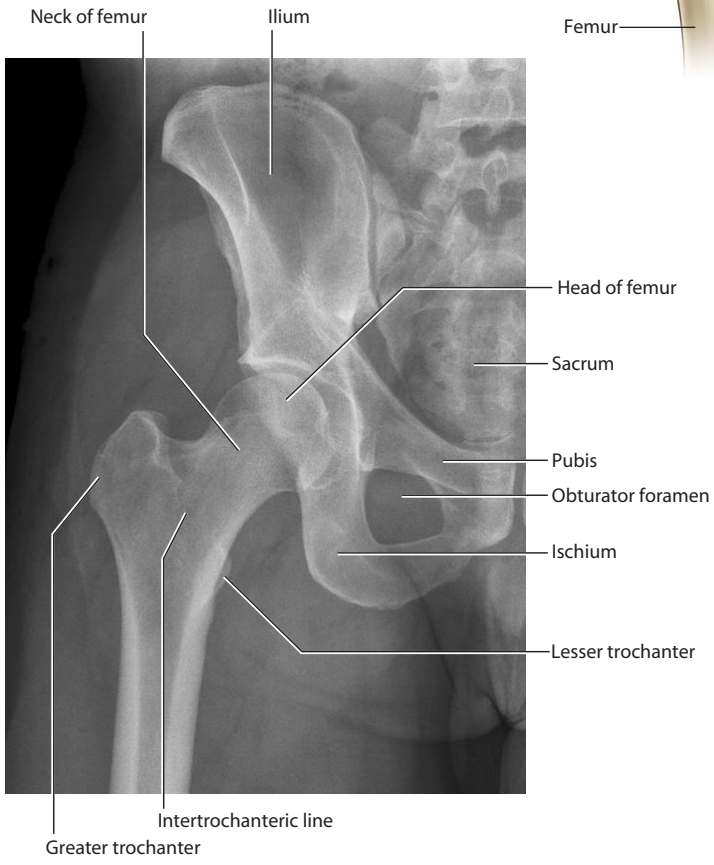

Normal hip joint.
Radiograph, AP view

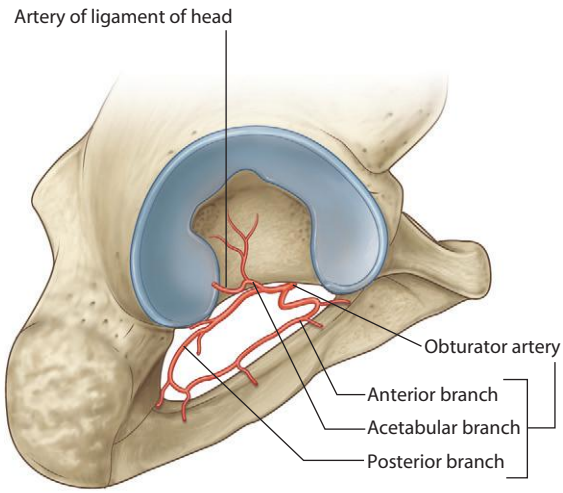

Obturator artery and branches

tahir99-VRG & vip.persianss.ir

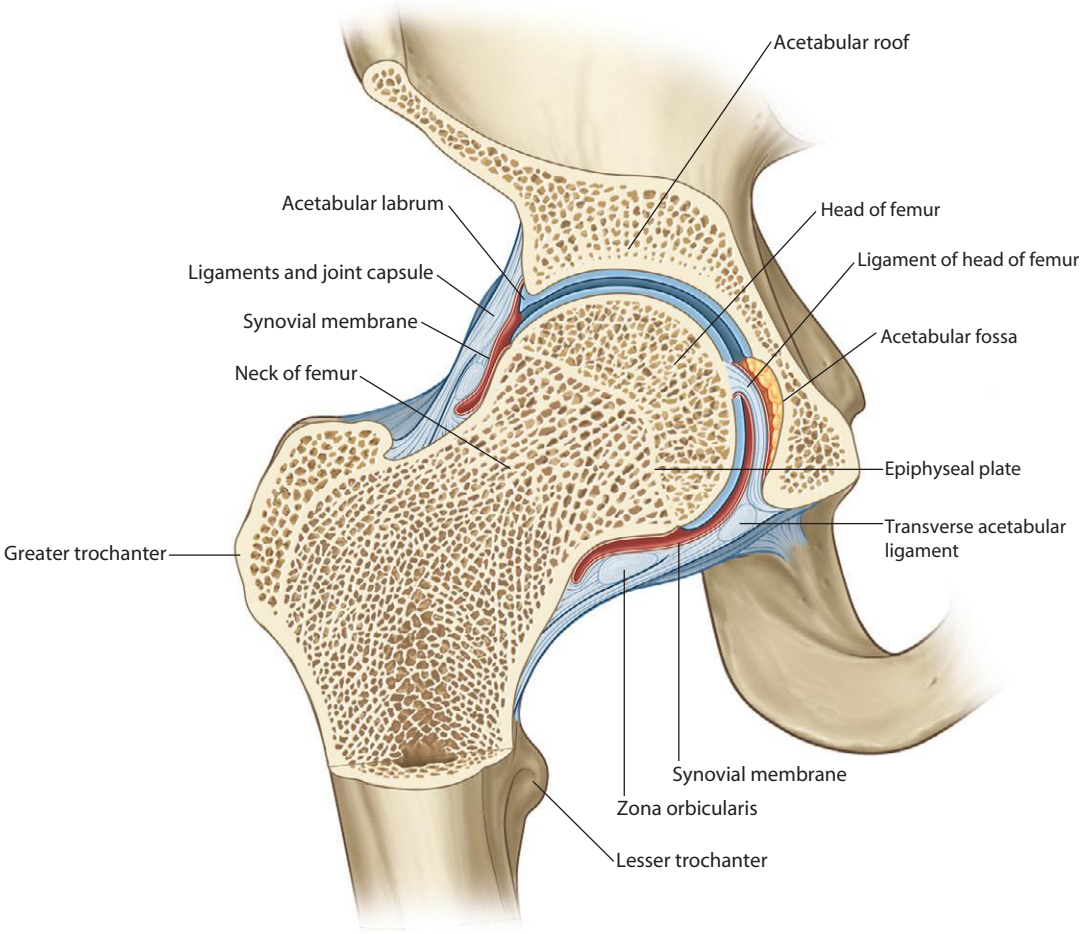

Coronal section through hip joint

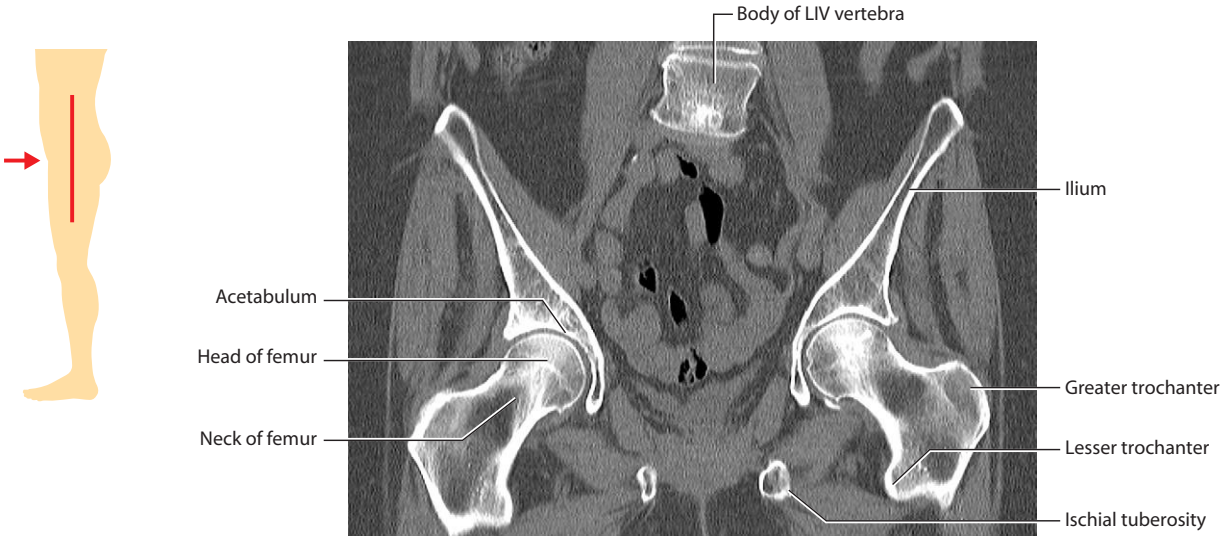

Hip joints.
CT image in coronal plane

tahir99-VRG & vip.persianss.ir

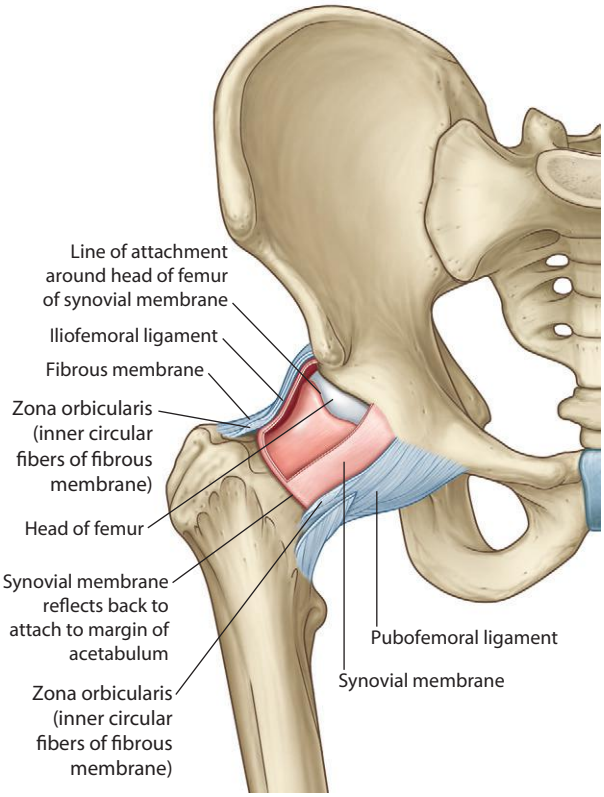

Joint capsule and synovial membrane

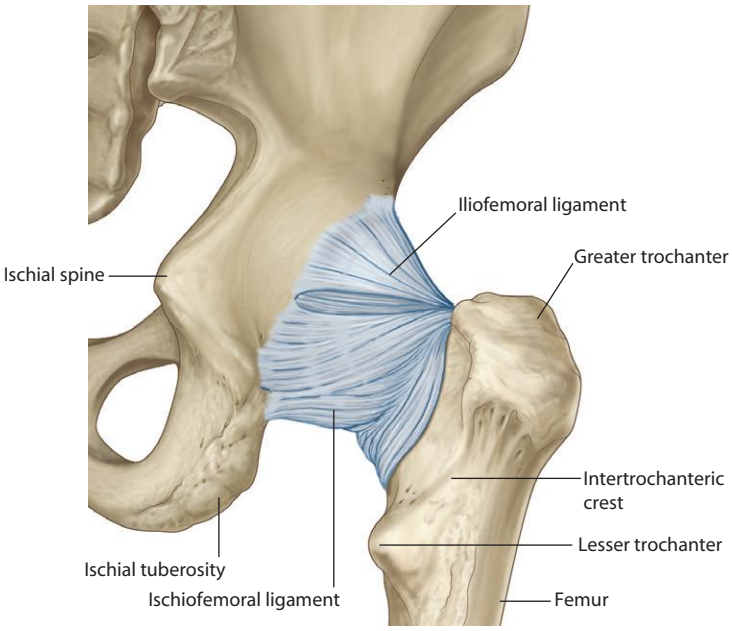

Ischiofemoral ligament (posterior view)

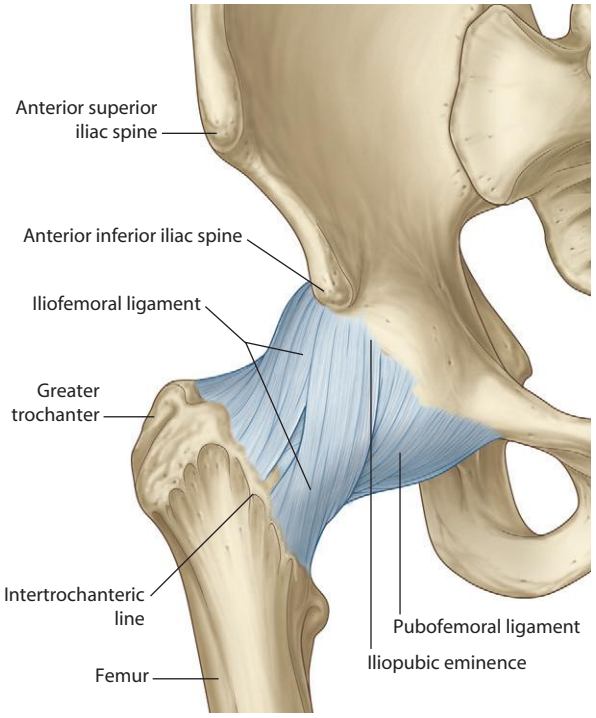

Iliofemoral and pubofemoral ligaments (anterior view)

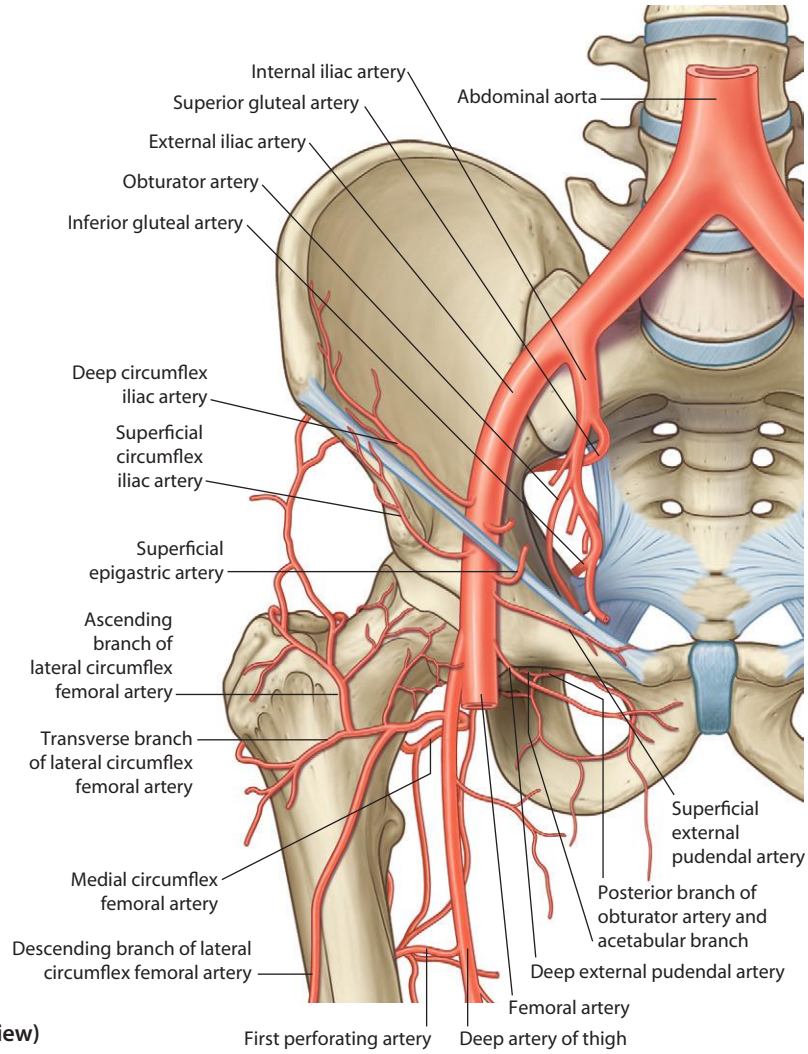

Arterial supply of the hip joint

tahir99-VRG & vip.persianss.ir

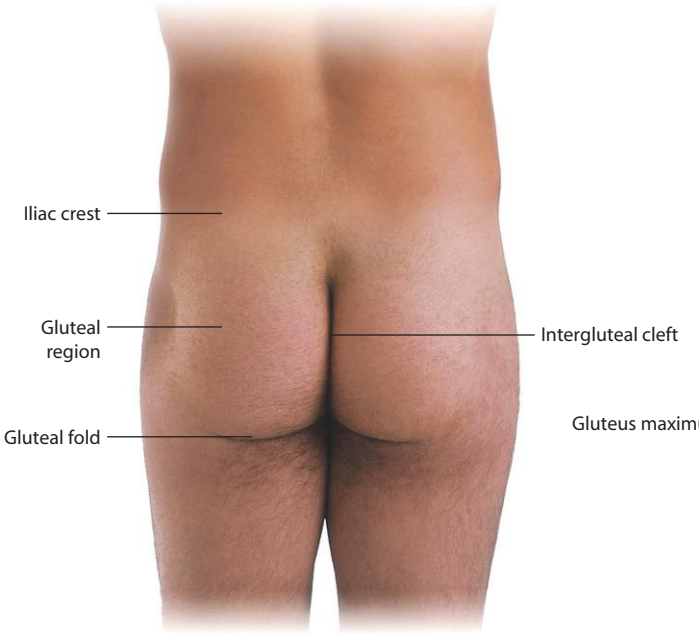

Surface anatomy of the gluteal region

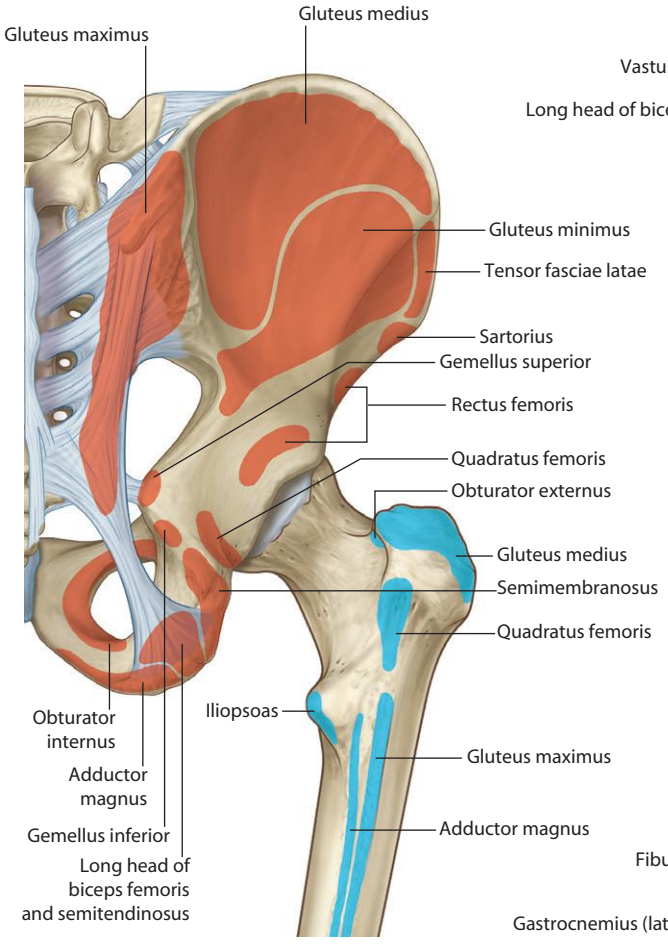

Muscle attachments of the gluteal region

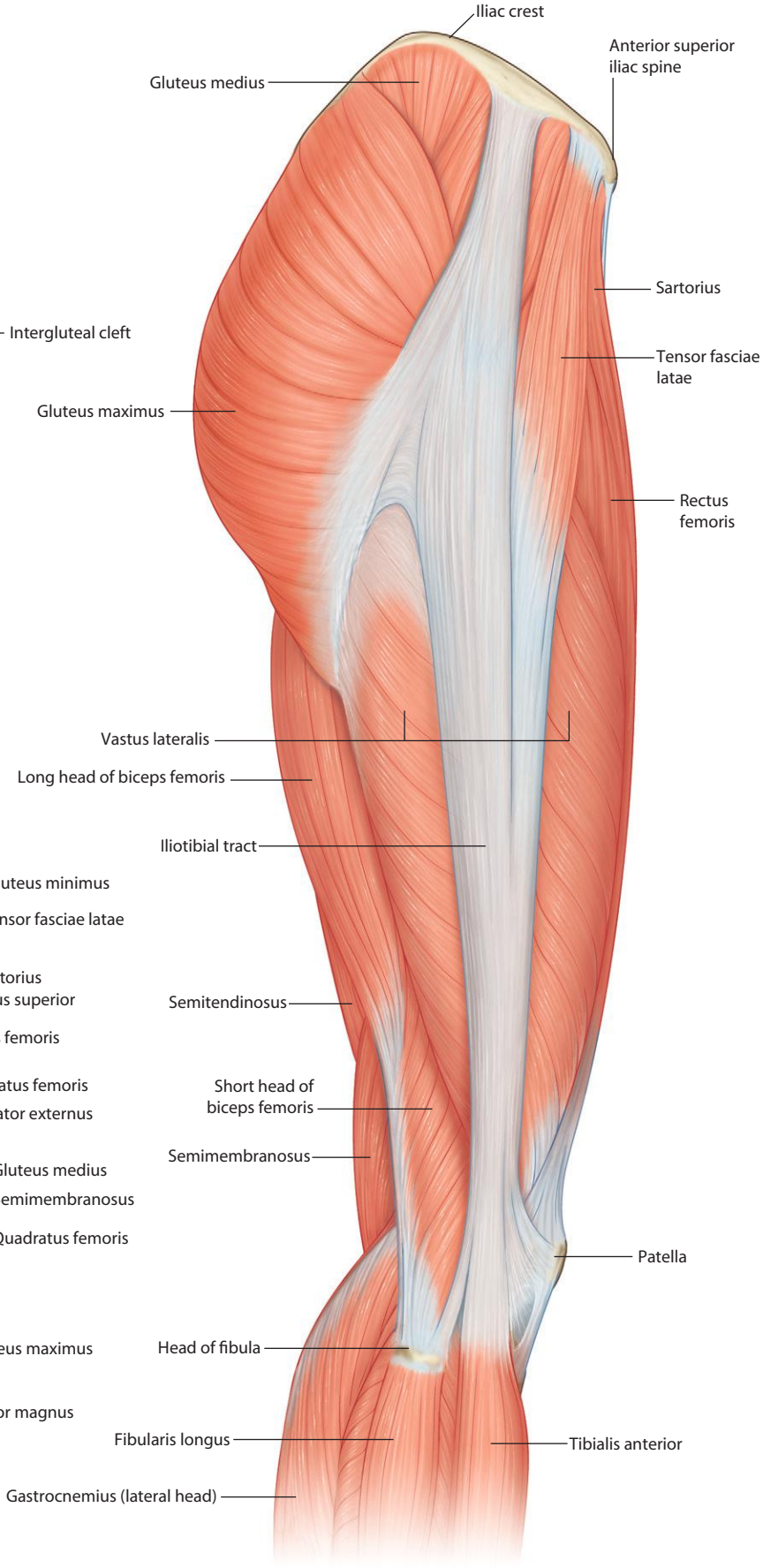

Muscles of the hip and thigh (lateral view)

tahir99-VRG & vip.persianss.ir

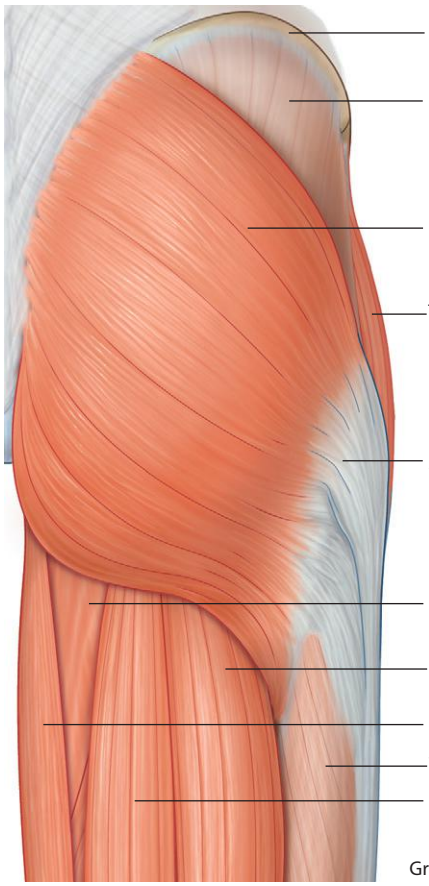

Superficial muscles of the gluteal region (posterior view)

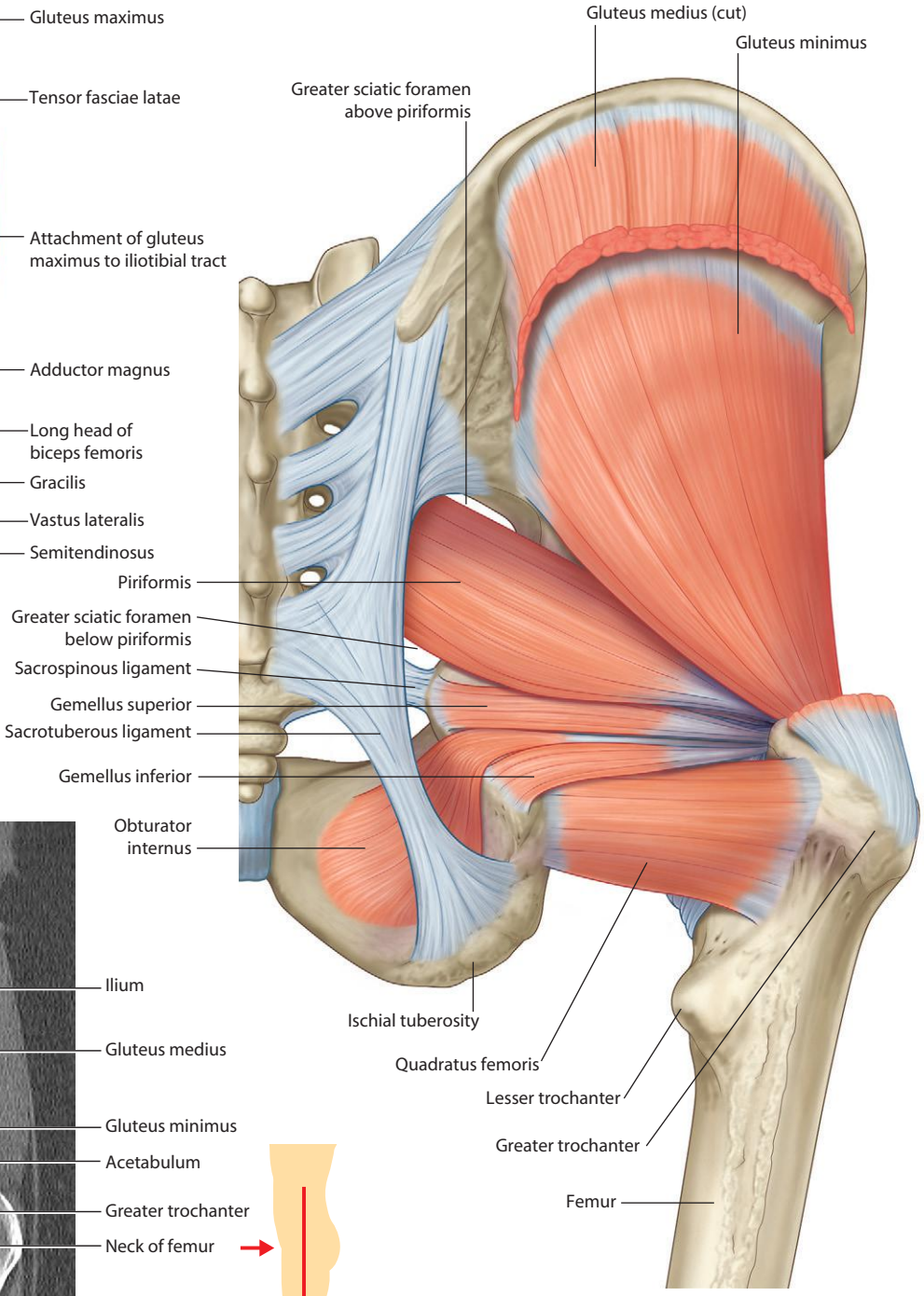

Deep muscles of the gluteal region (posterior view)

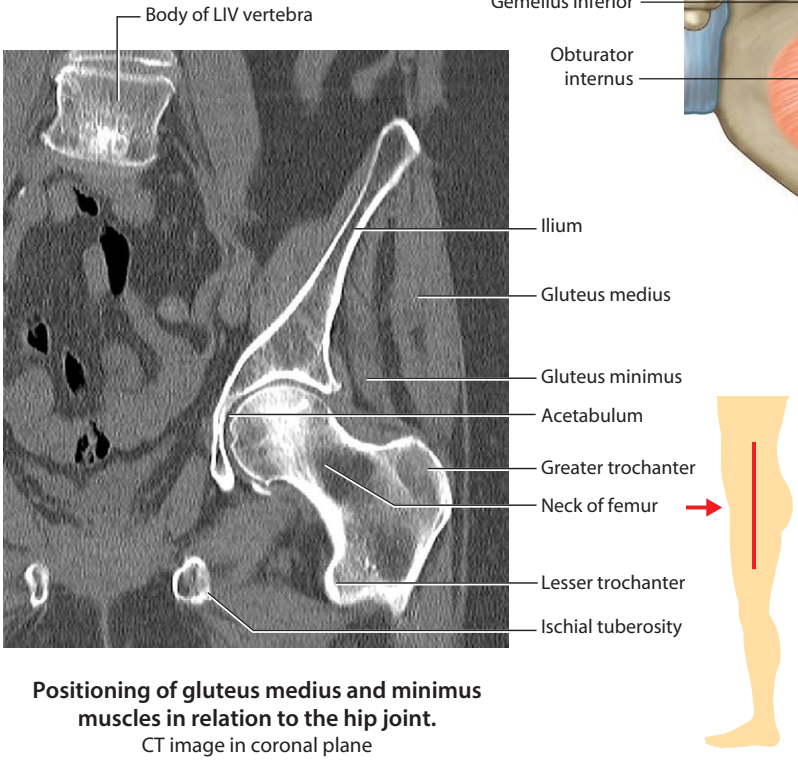

Positioning of gluteus medius and minimus muscles in relation to the hip joint.
CT image in coronal plane

tahir99-VRG & vip.persianss.ir

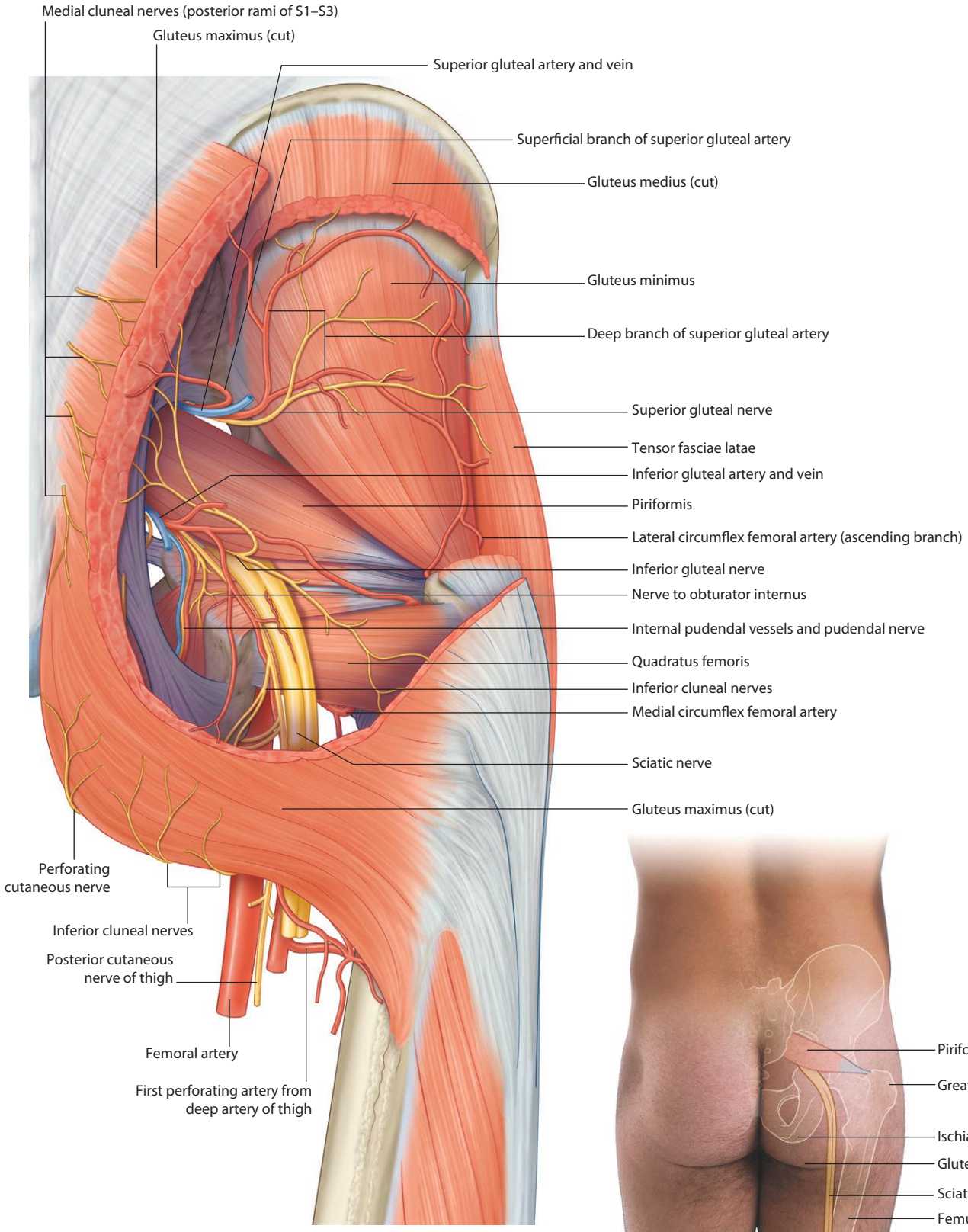

Arteries and nerves of the gluteal region

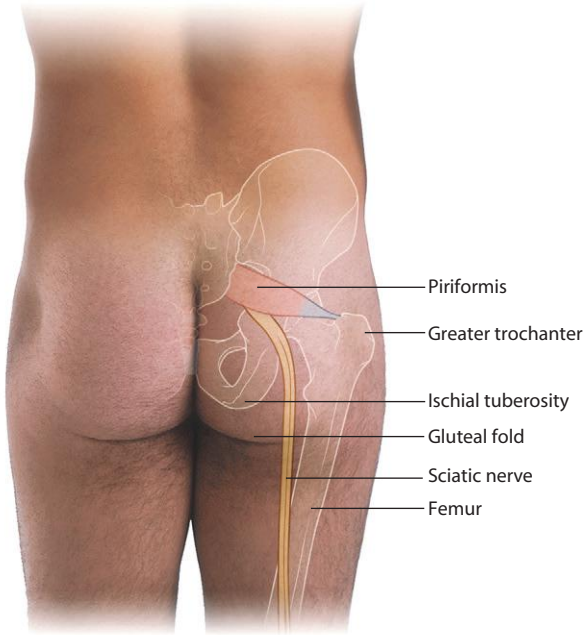

Sciatic nerve in the gluteal region as it relates to the surface (posterior view)

tahir99-VRG & vip.persianss.ir

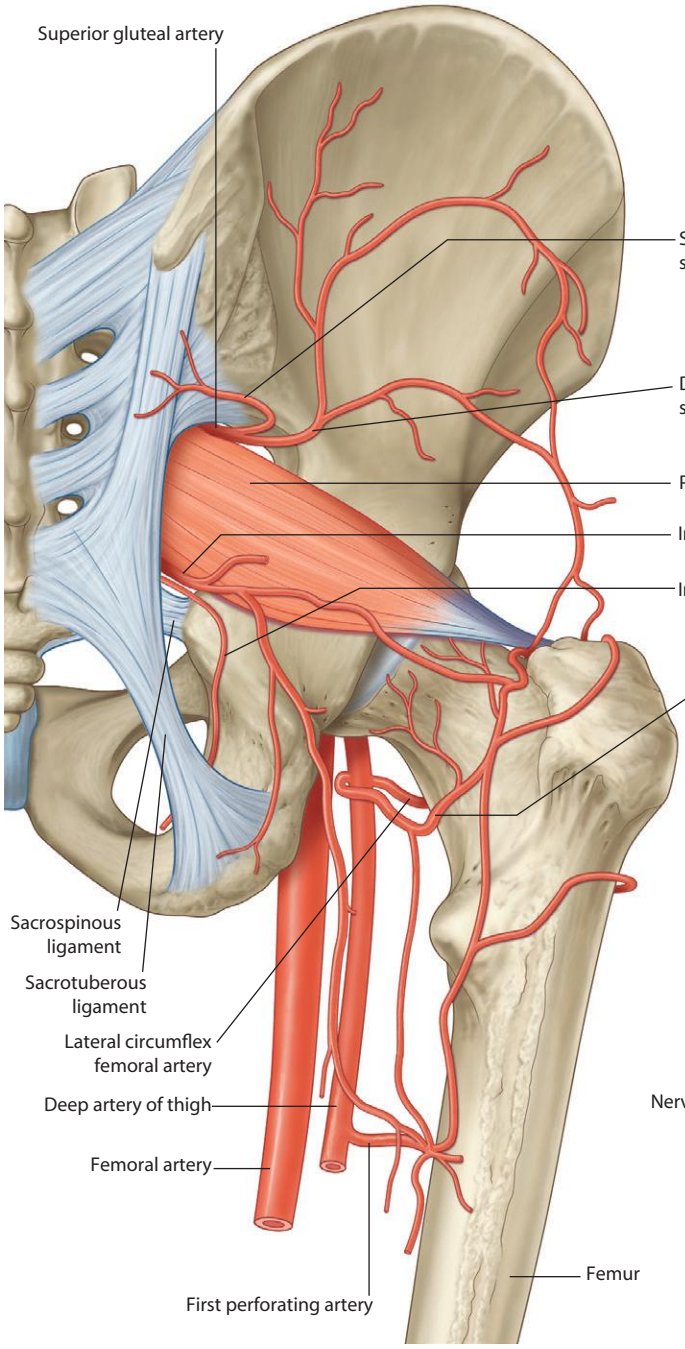

Arteries of the gluteal region

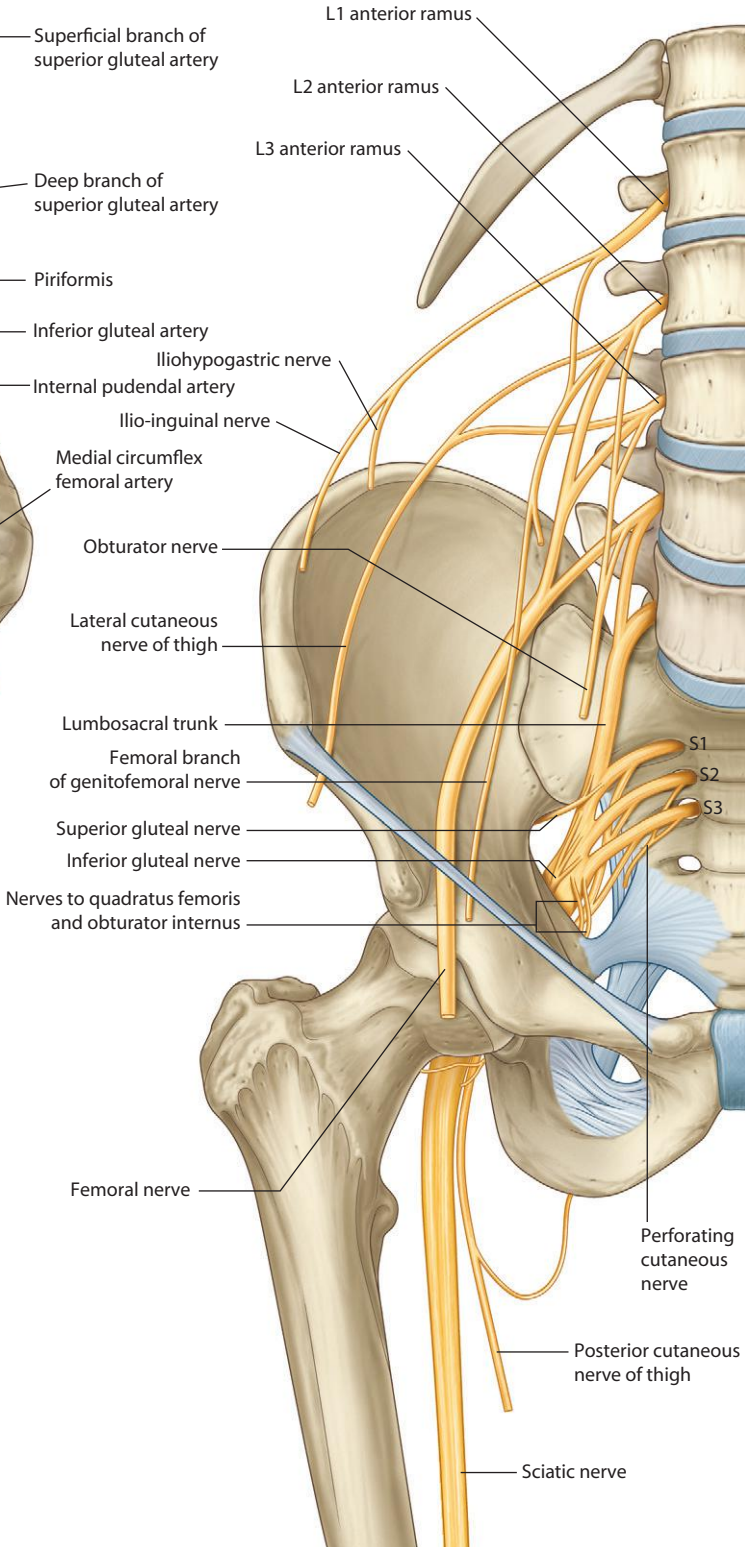

Branches of the lumbosacral plexus related to lower limb

tahir99-VRG & vip.persianss.ir

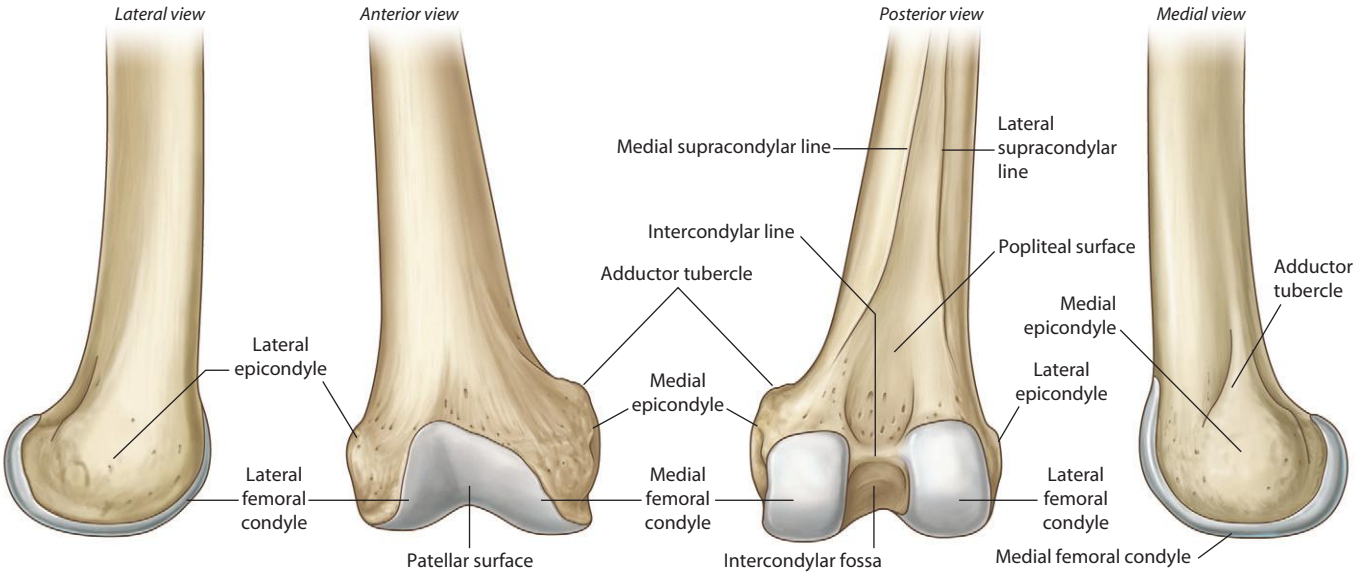

Distal end of (right) femur

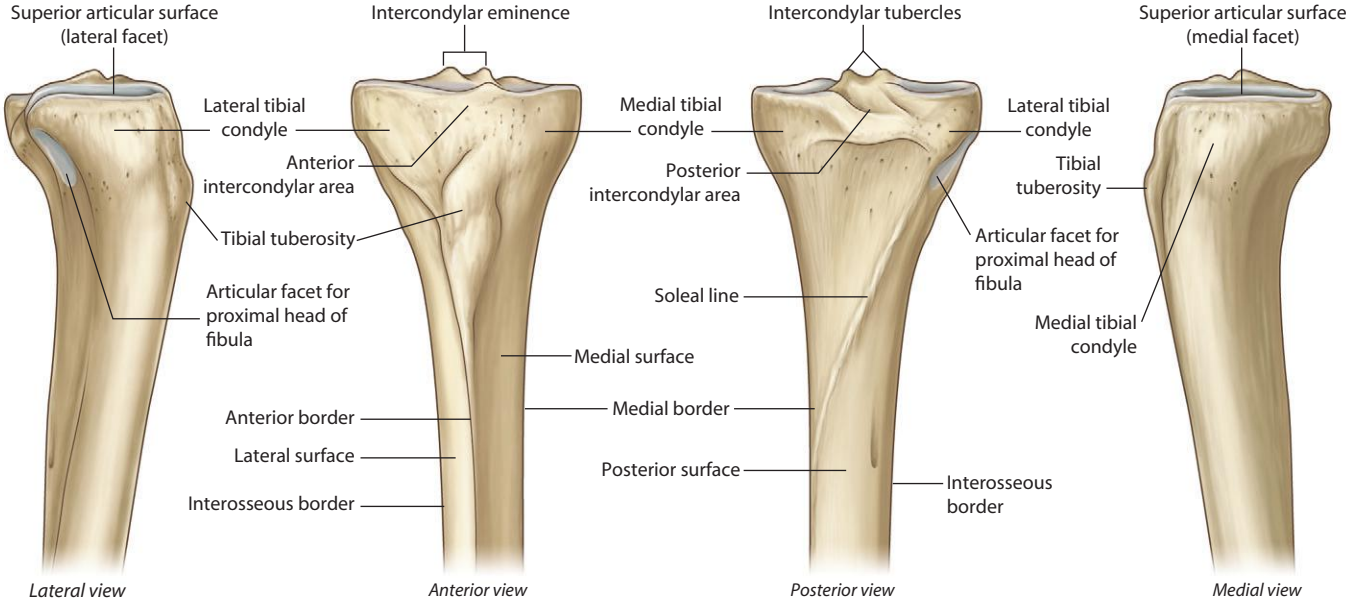

Proximal end of (right) tibia

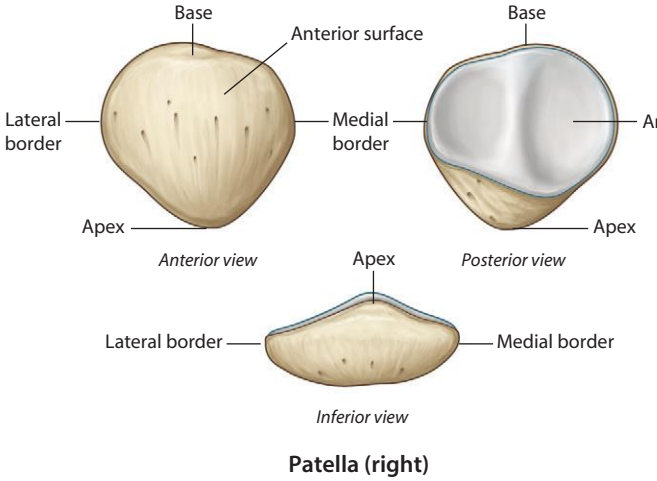

Patella (right)

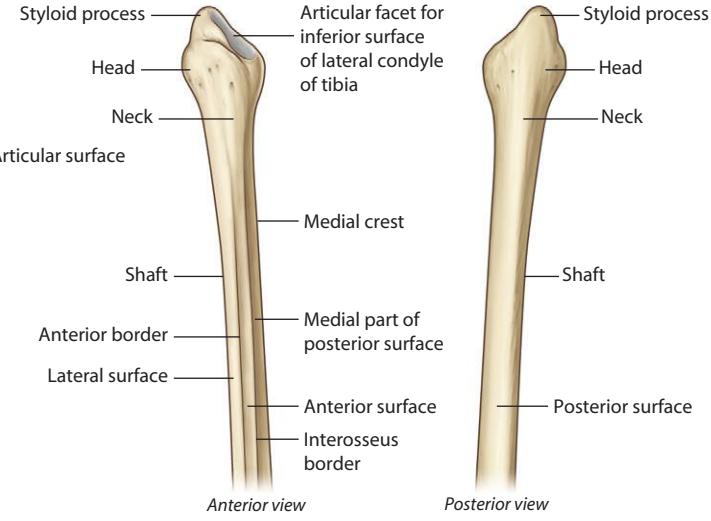

Proximal end of (right) fibula

tahir99-VRG & vip.persianss.ir

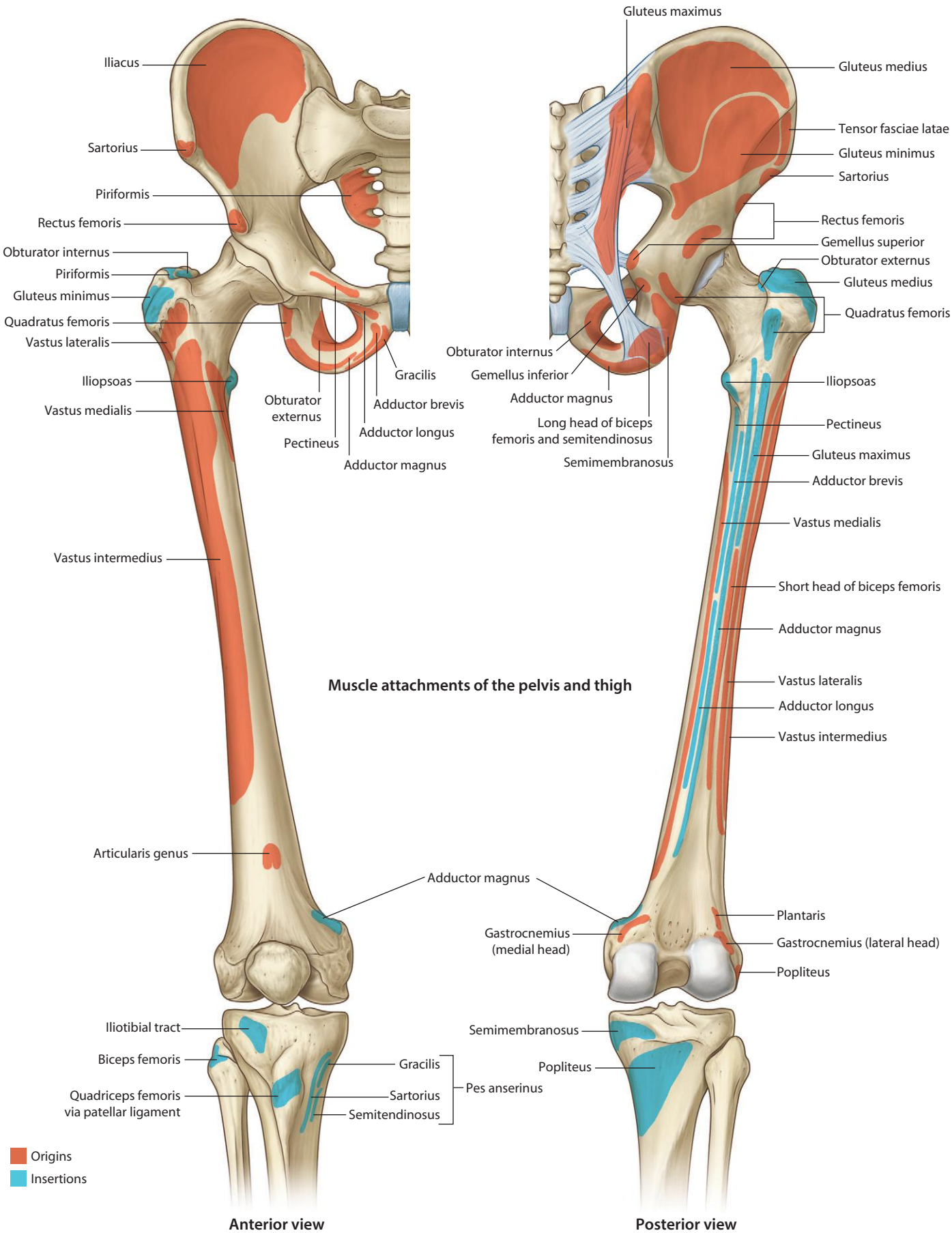

Muscle attachments of the pelvis and thigh

tahir99-VRG & vip.persianss.ir

Surface anatomy of lower limb with overlay of muscles (anterior view)

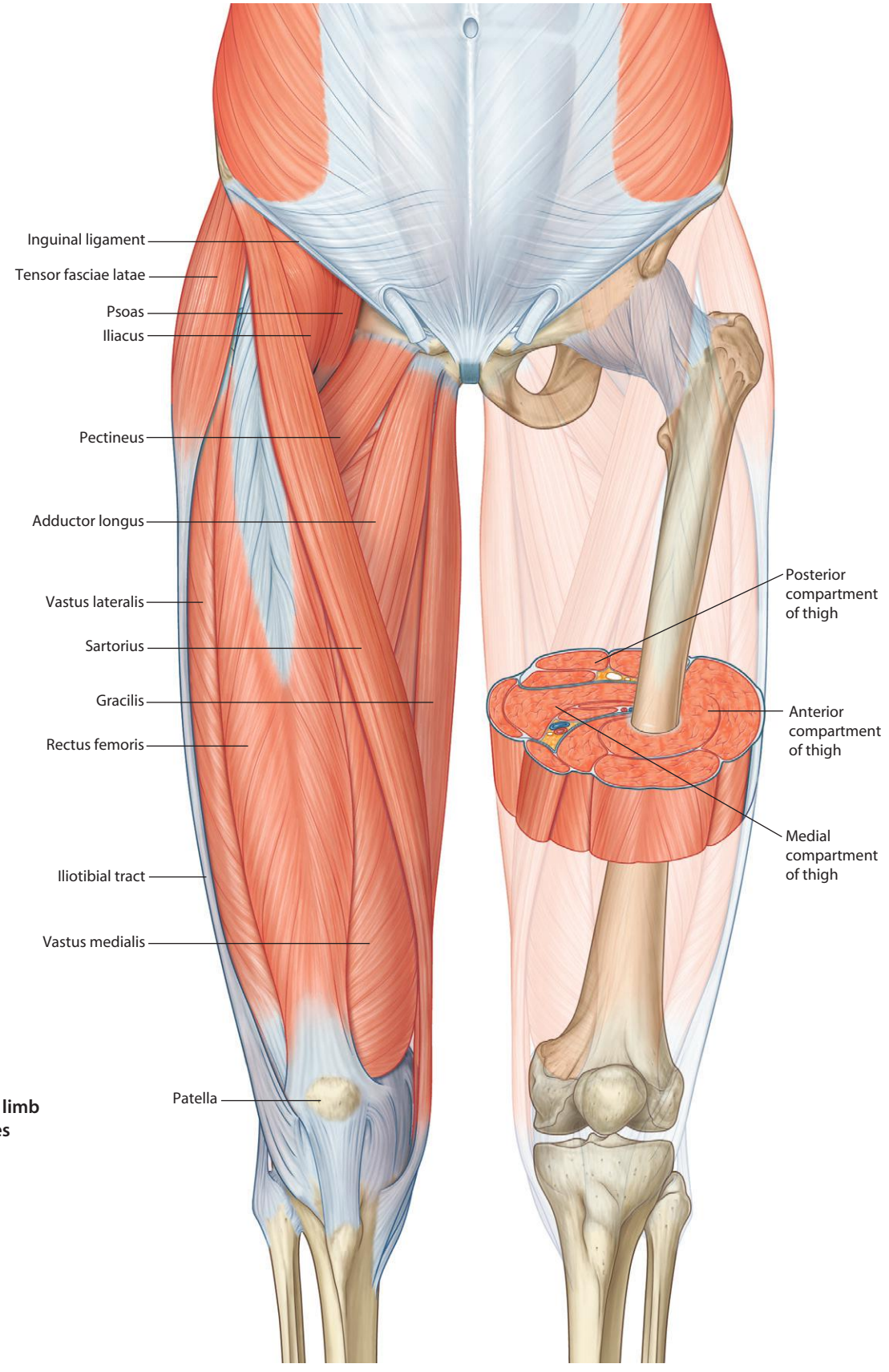

Superficial muscles of the thigh (anterior view)

tahir99-VRG & vip.persianss.ir

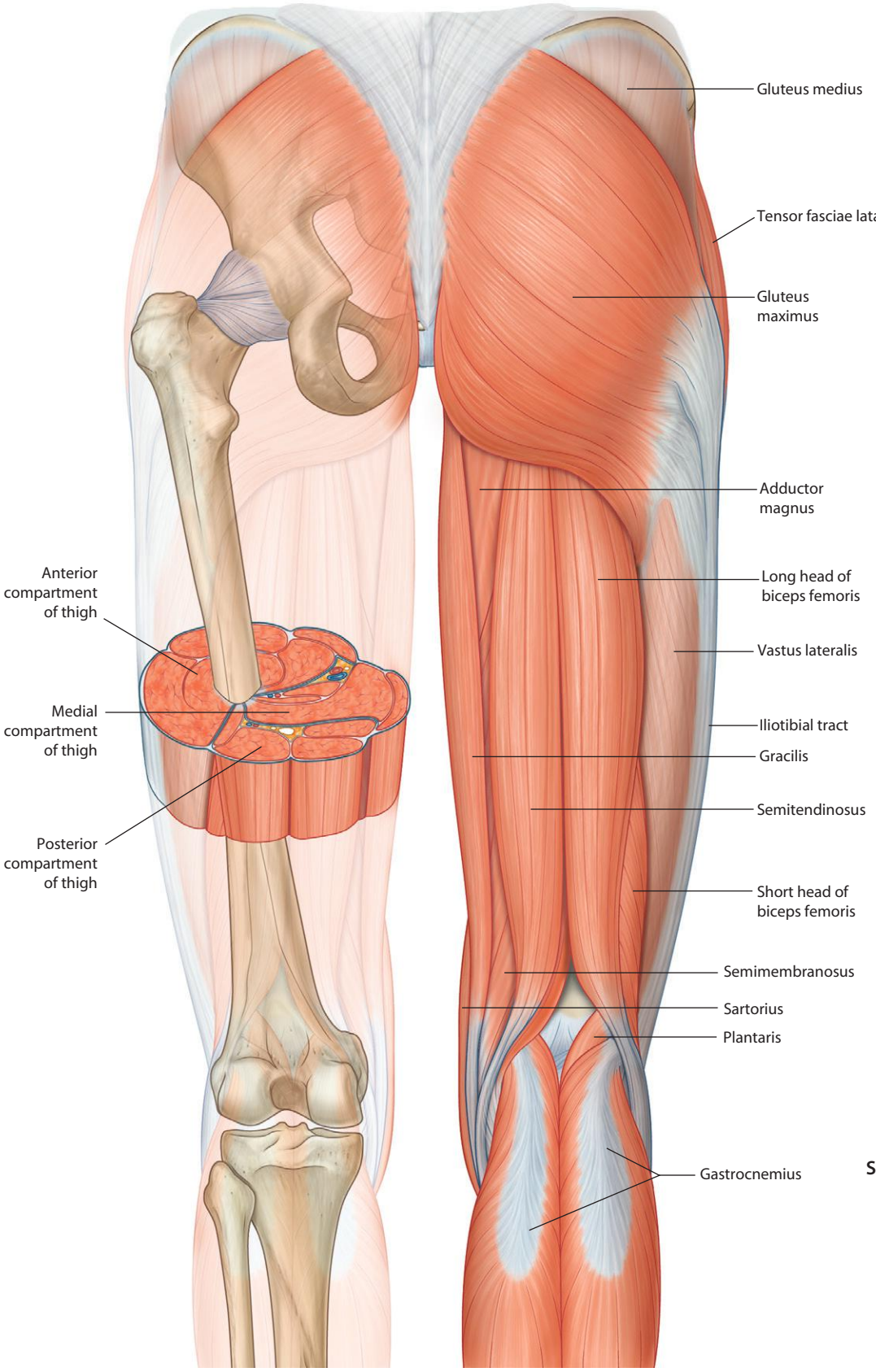

Superficial muscles of the thigh (posterior view)

Surface anatomy of lower limb with overlay of muscles (posterior view)

tahir99-VRG & vip.persianss.ir

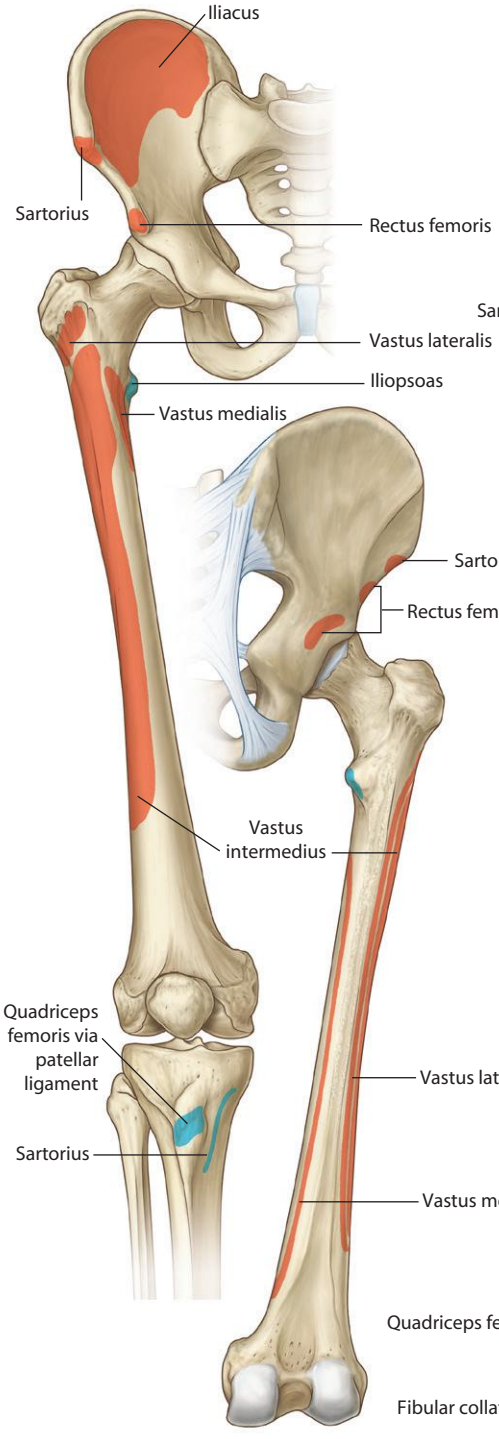

Muscle attachments of the anterior compartment of the thigh

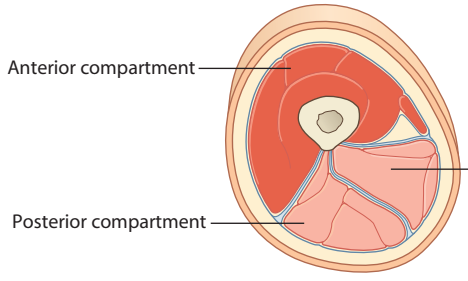

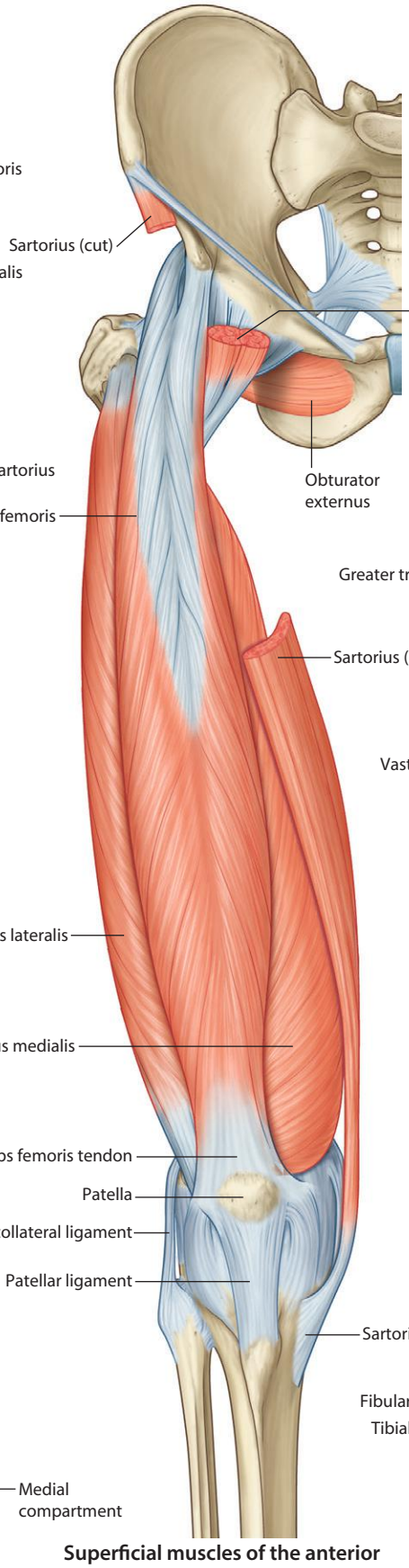

Superficial muscles of the anterior compartment of the thigh

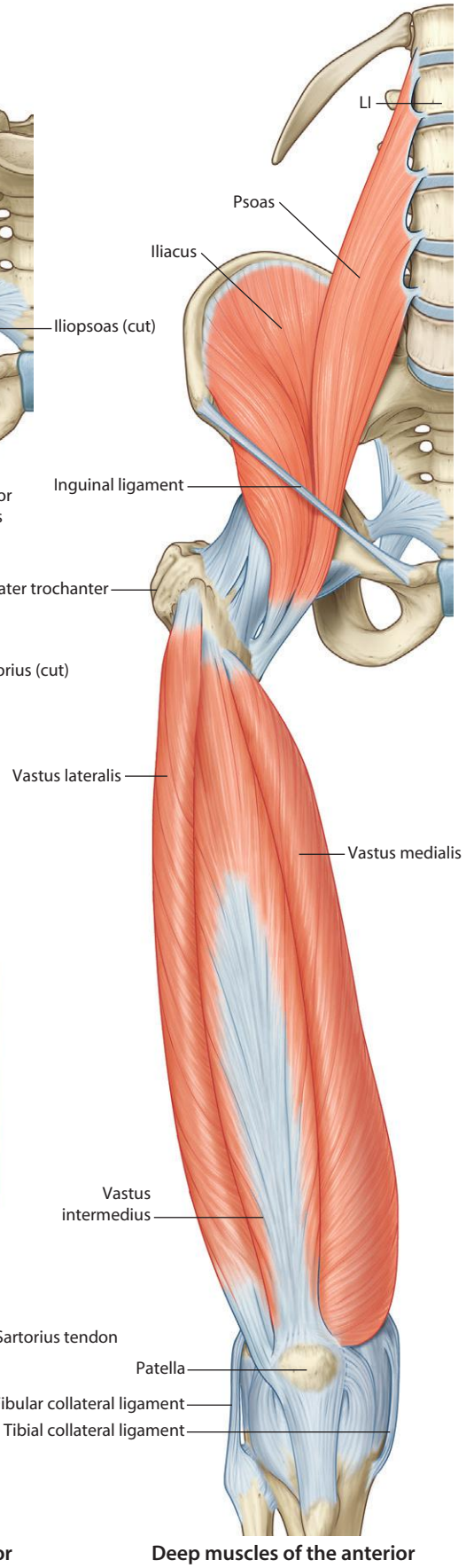

Deep muscles of the anterior compartment of the thigh

tahir99-VRG & vip.persianss.ir

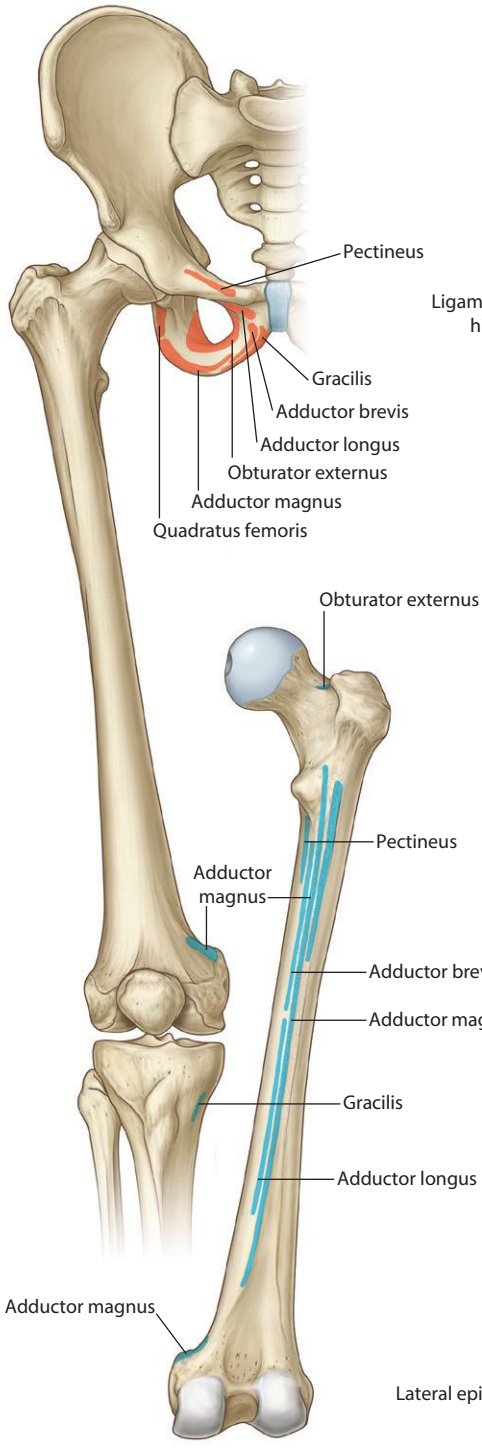

Muscle attachments of the medial compartment of the thigh

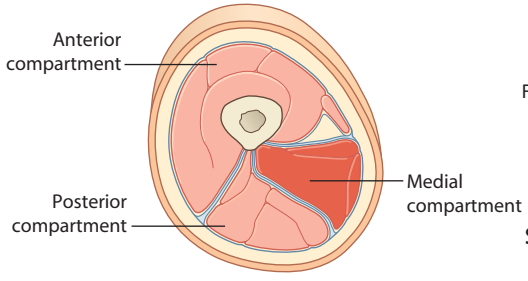

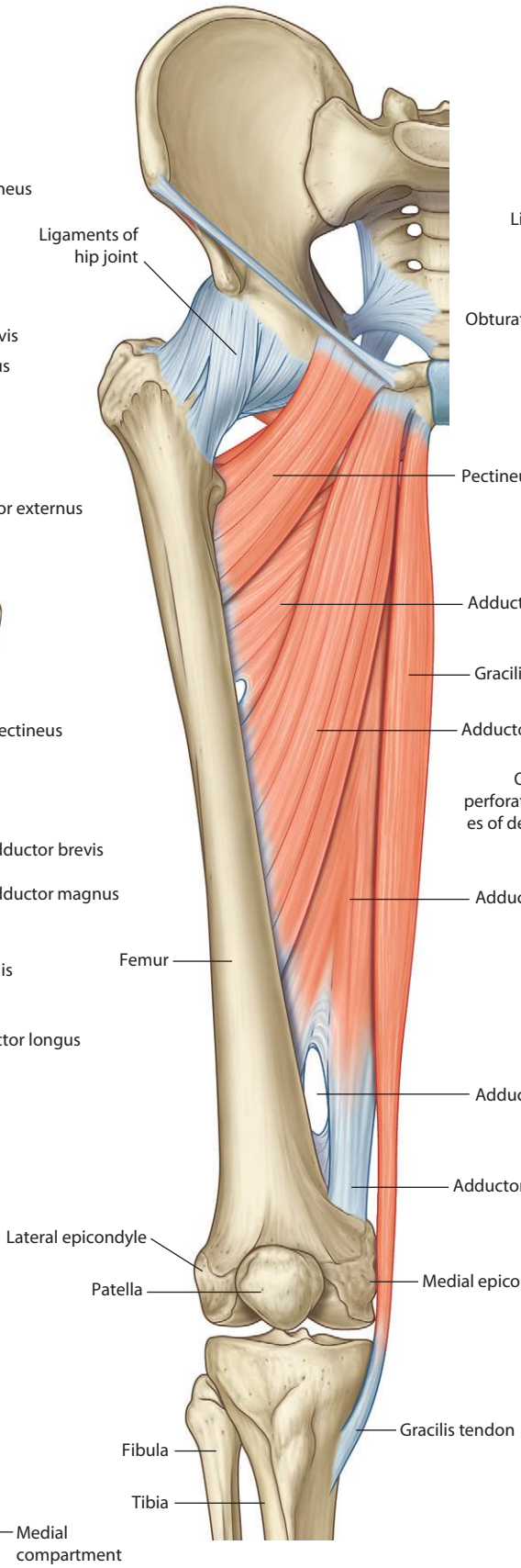

Superficial muscles of the medial compartment of the thigh

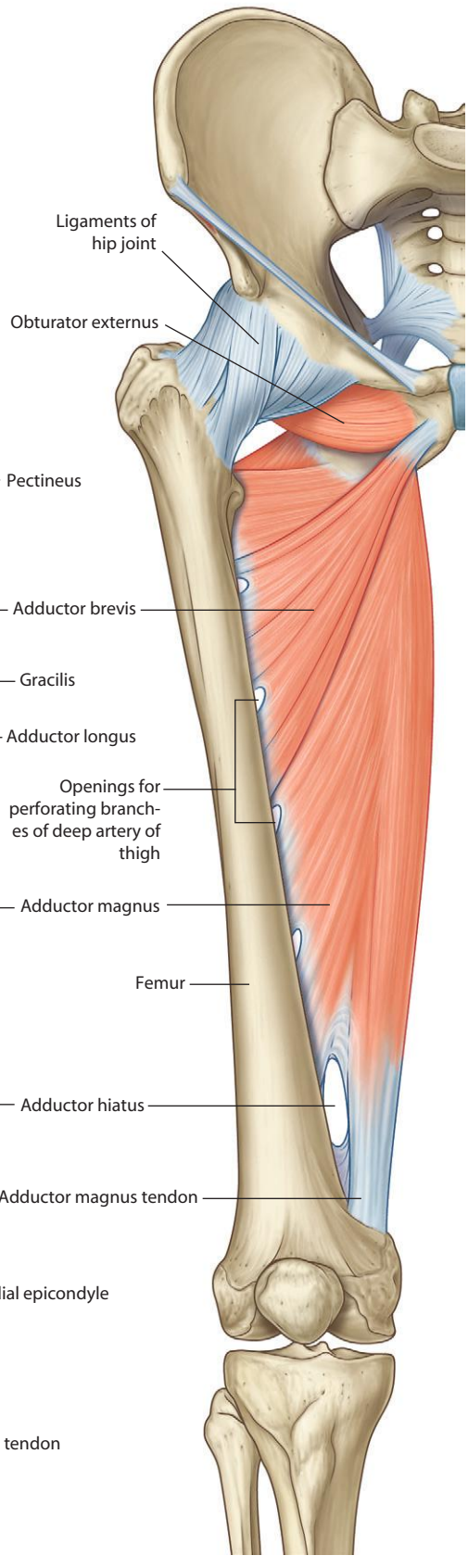

Deep muscles of the medial compartment of the thigh

tahir99-VRG & vip.persianss.ir

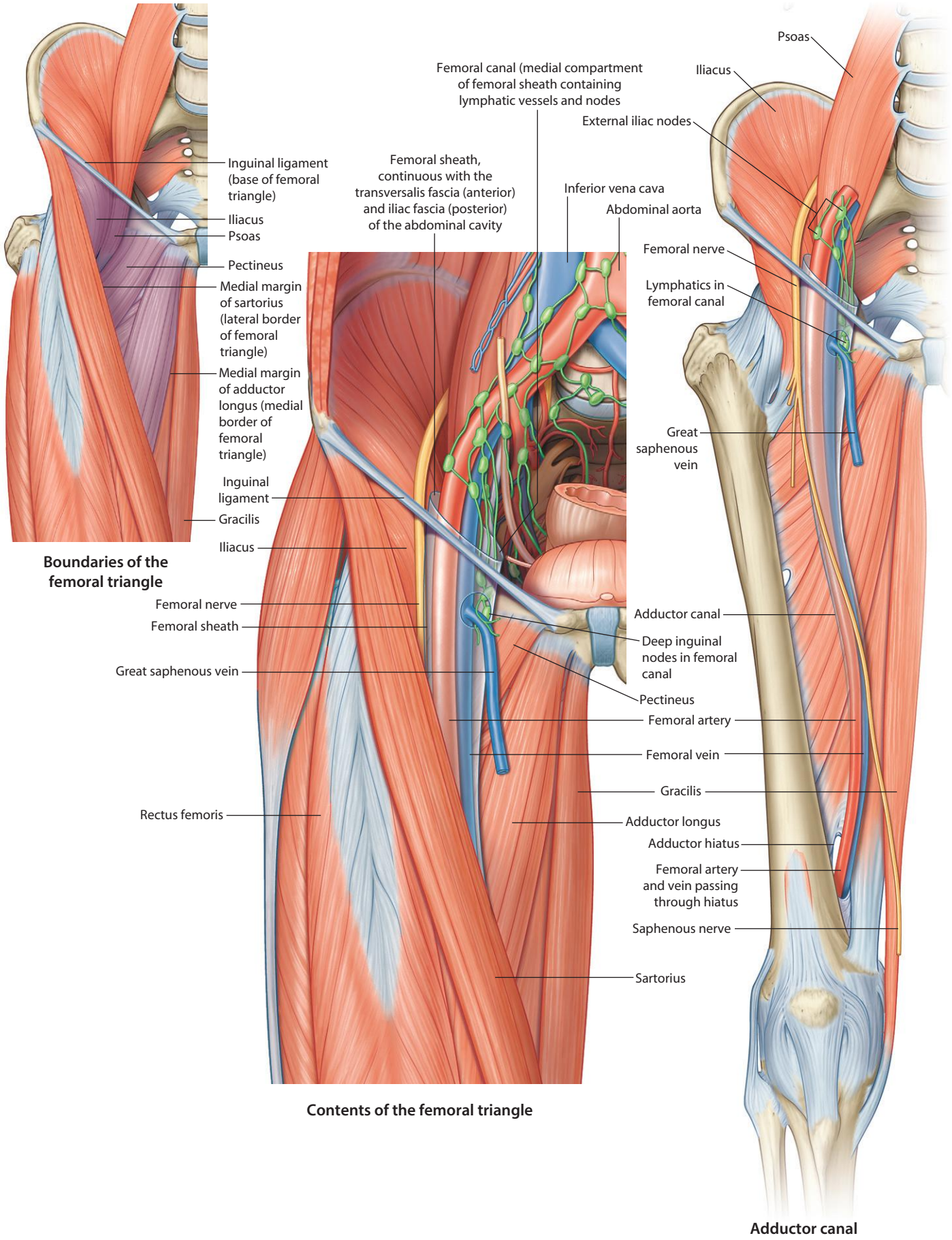
Inguinal ligament (base of femoral triangle)
Iliacus
Psoas
Pectineus
Medial margin of sartorius (lateral border of femoral triangle)
Medial margin of adductor longus (medial border of femoral triangle)
Gracilis
Boundaries of the femoral triangle
Femoral canal (medial compartment of femoral sheath containing lymphatic vessels and nodes
Femoral sheath, continuous with the transversalis fascia (anterior) and iliac fascia (posterior) of the abdominal cavity
Inferior vena cava
Abdominal aorta
Inguinal ligament
Iliacus
Femoral nerve
Femoral sheath
Great saphenous vein
Rectus femoris
Contents of the femoral triangle
Psoas
Iliacus
External iliac nodes
Femoral nerve
Lymphatics in femoral canal
Great saphenous vein
Adductor canal
Deep inguinal nodes in femoral canal
Pectineus
Femoral artery
Femoral vein
Gracilis
Adductor longus
Adductor hiatus
Femoral artery and vein passing through hiatus
Saphenous nerve
Sartorius
Adductor canal

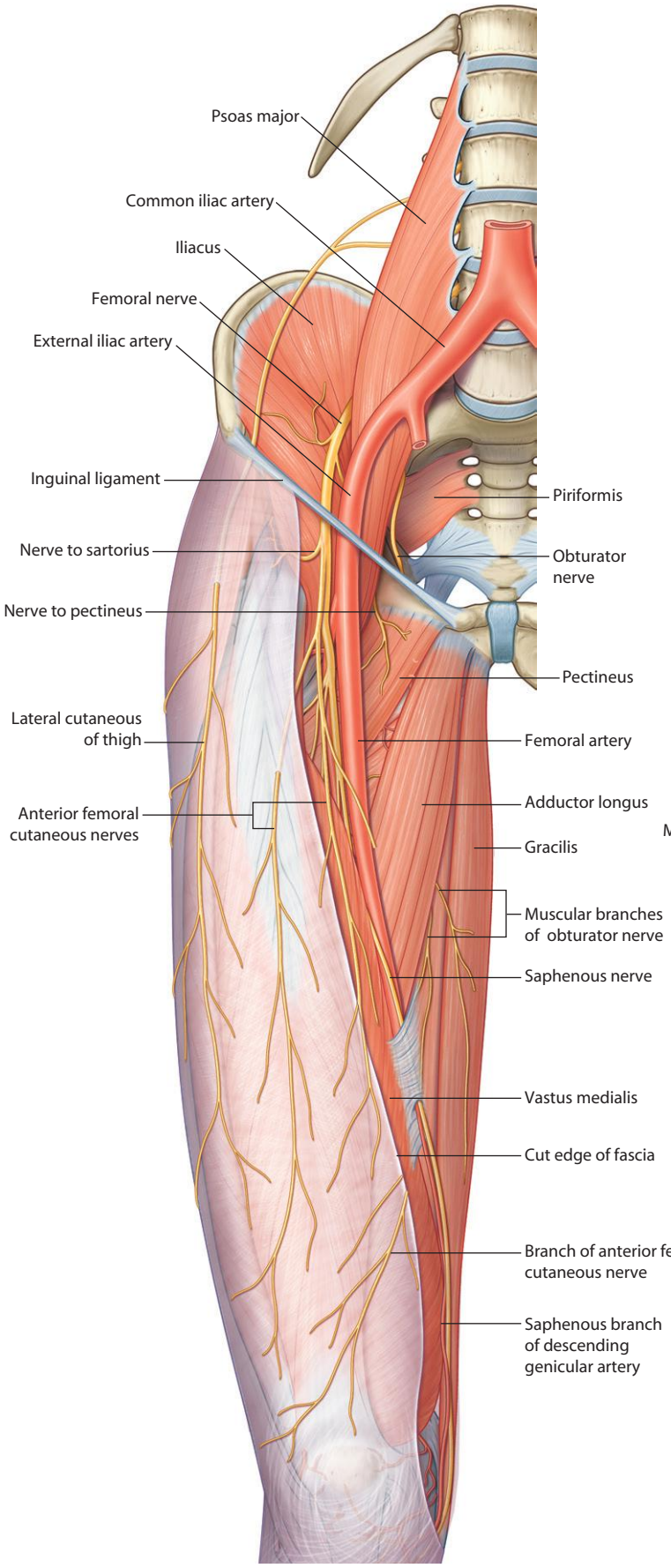

Superficial arteries and nerves of the thigh (anterior view)

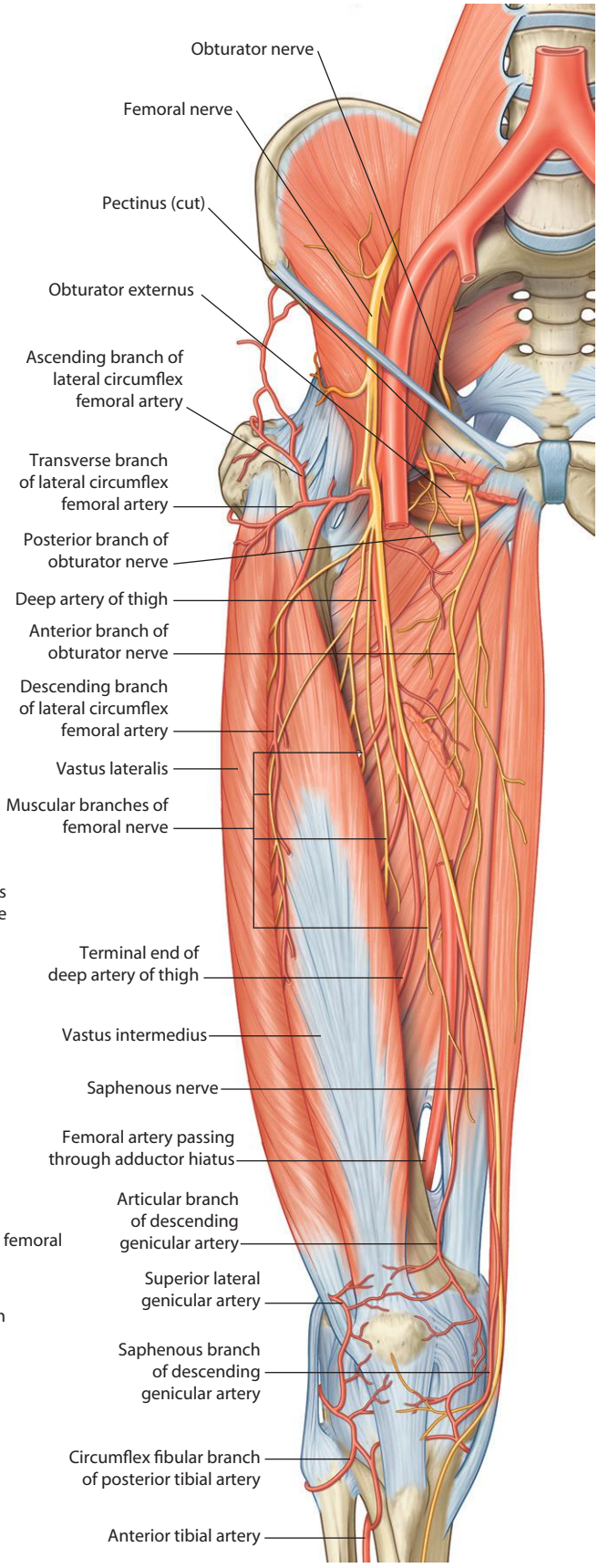

Deep arteries and nerves of the thigh (anterior view)

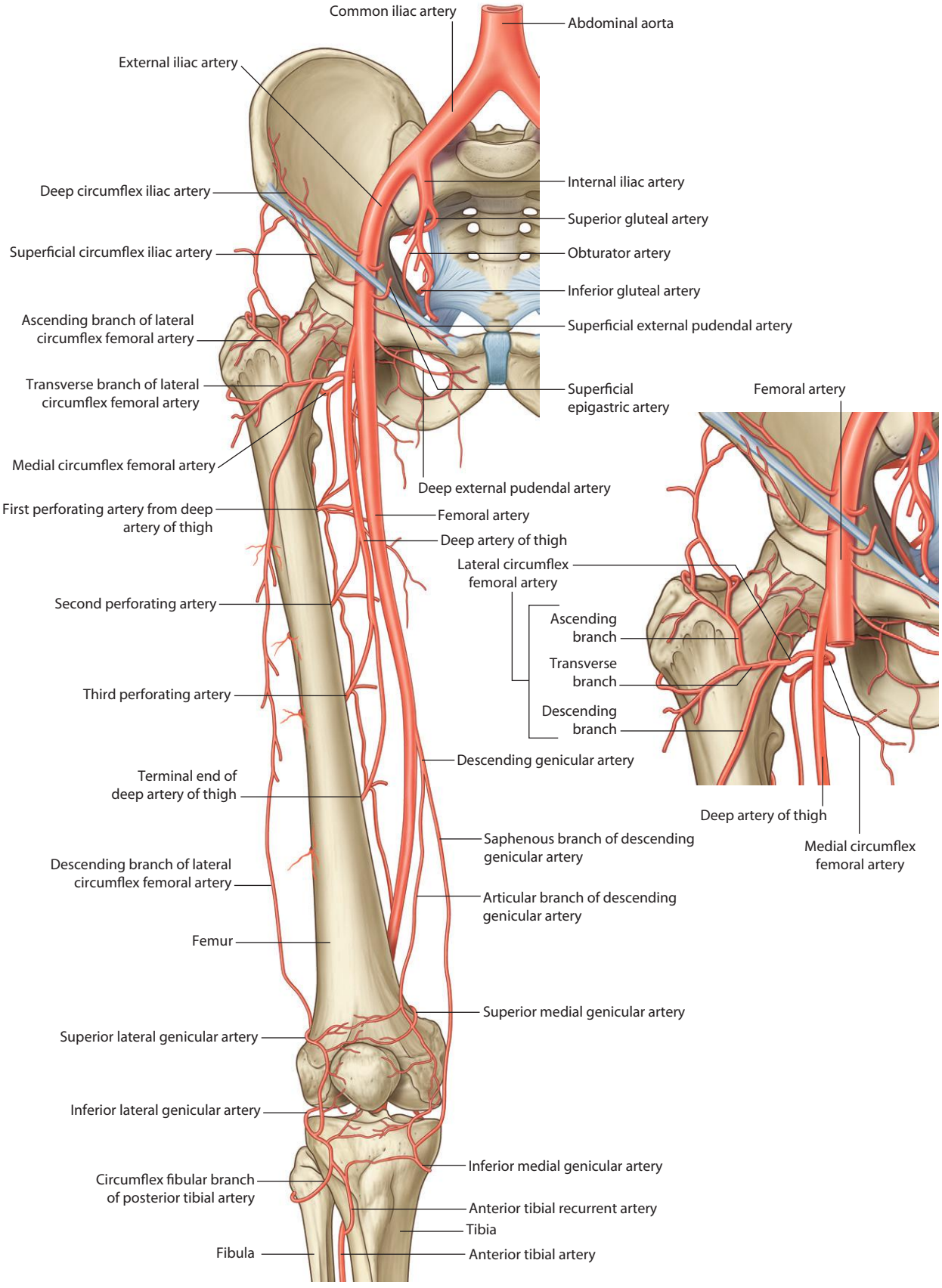

Arteries of the thigh (anterior view)

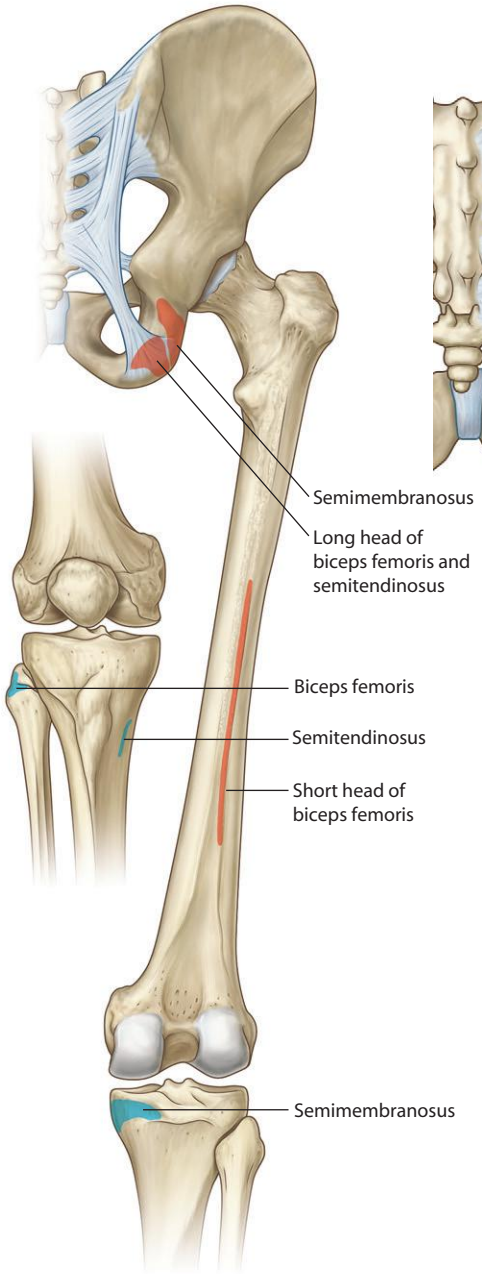

Muscle attachments of the posterior compartment of the thigh

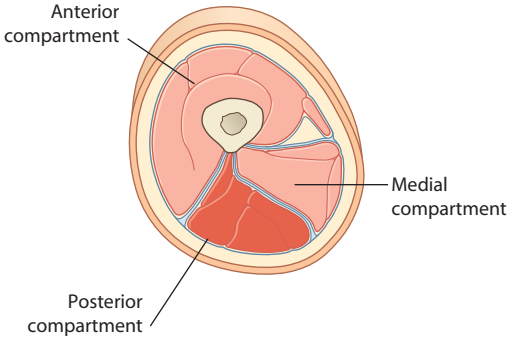

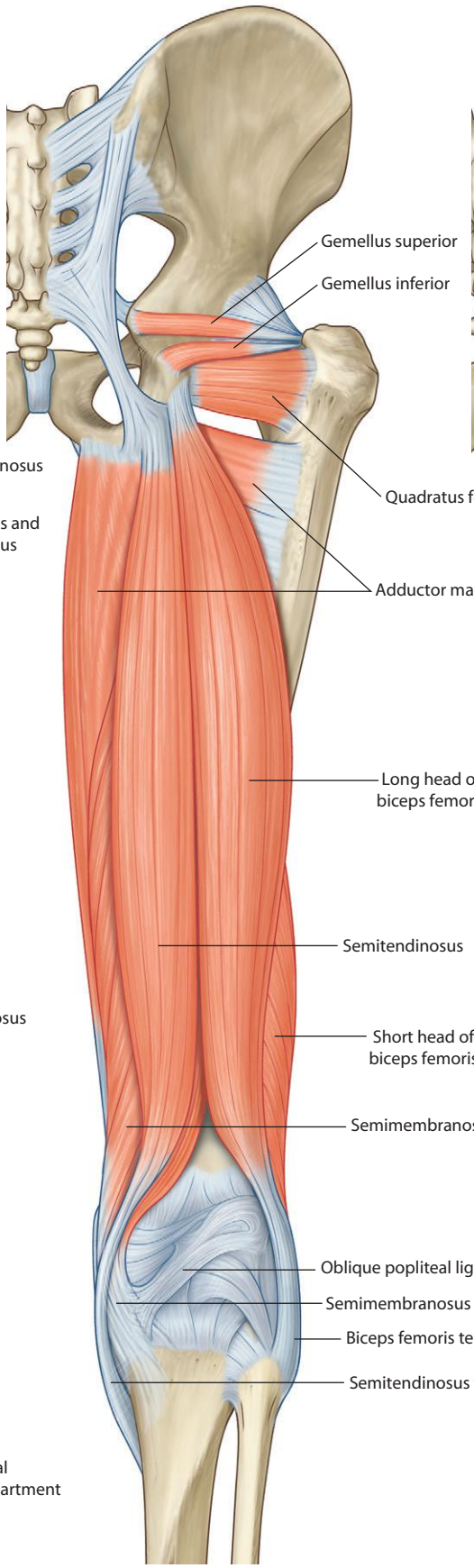

Superficial muscles of the posterior compartment of the thigh

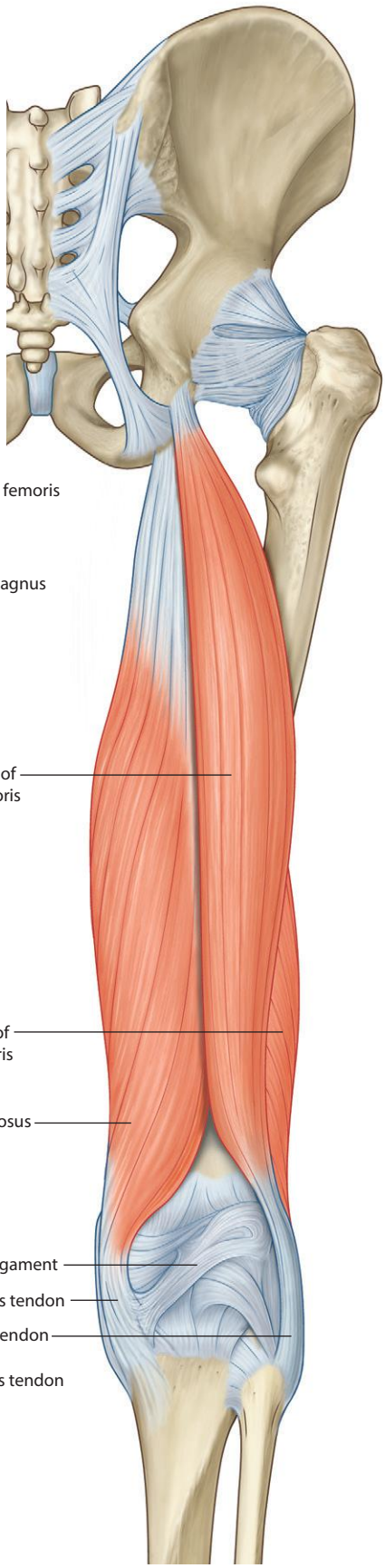

Deep muscles of the posterior compartment of the thigh

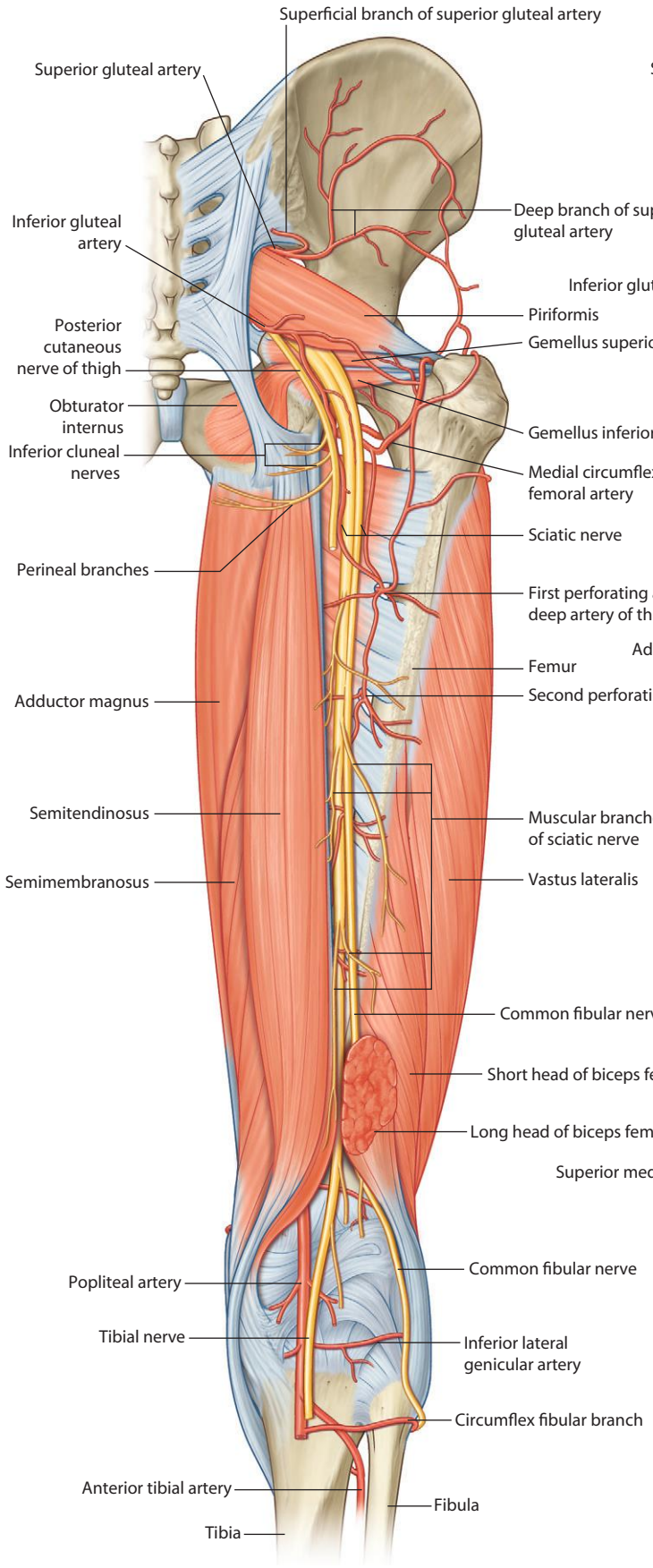

Arteries and nerves of the thigh (posterior view)

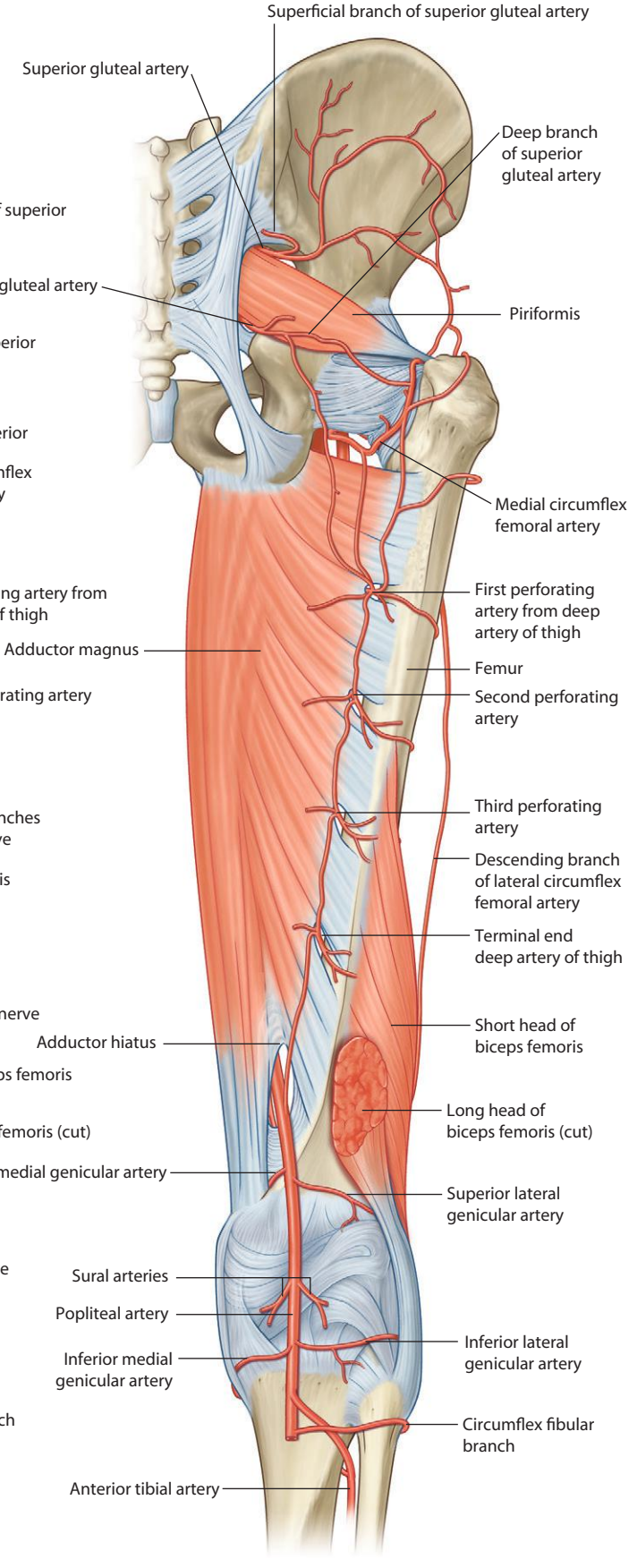

Deep arteries of the thigh (posterior view)

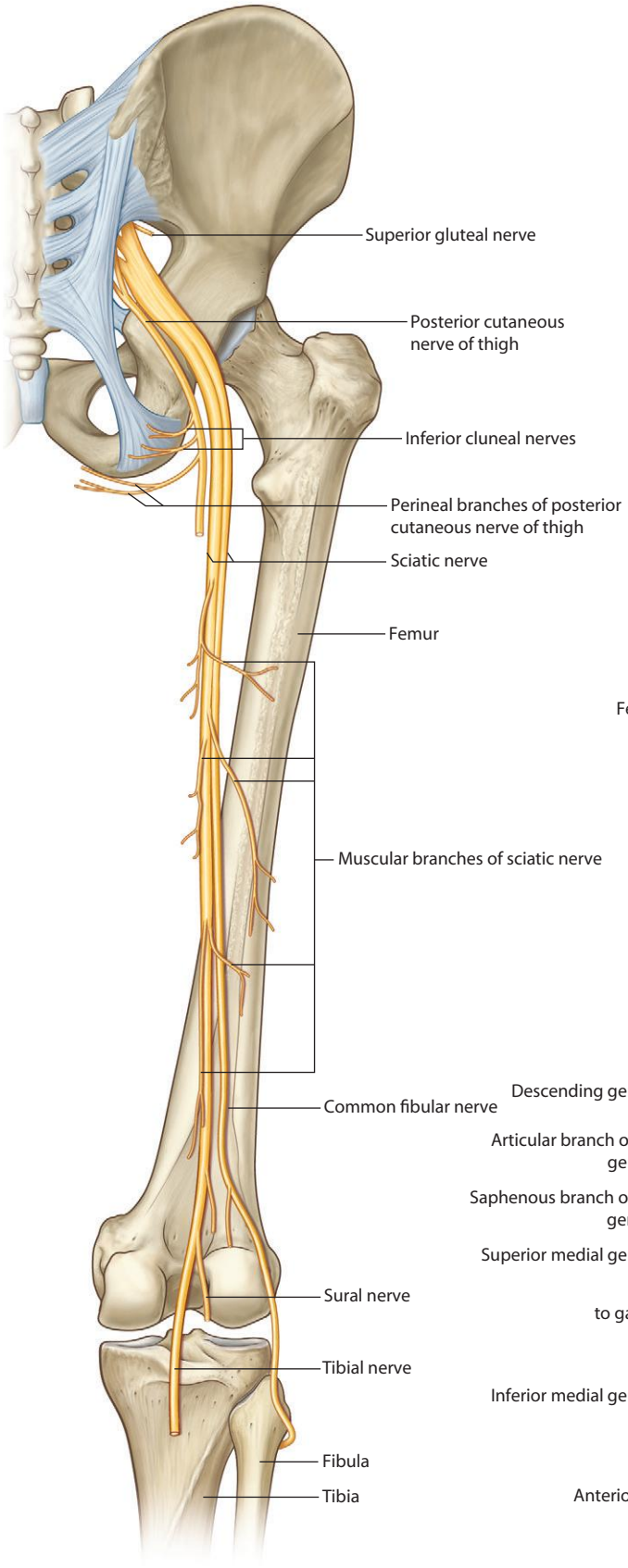

Nerves of the thigh (posterior view)

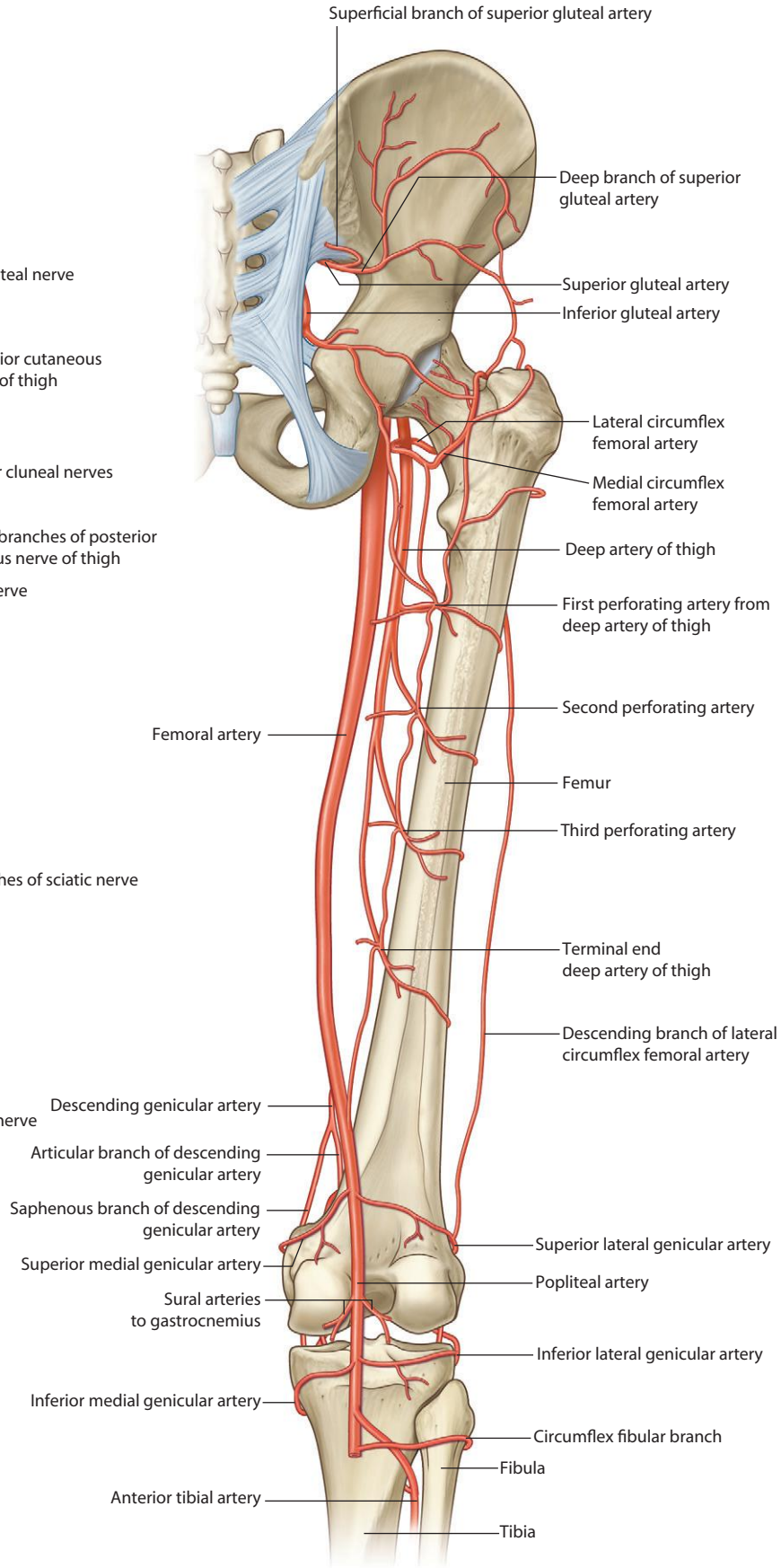

Arteries of the thigh (posterior view)

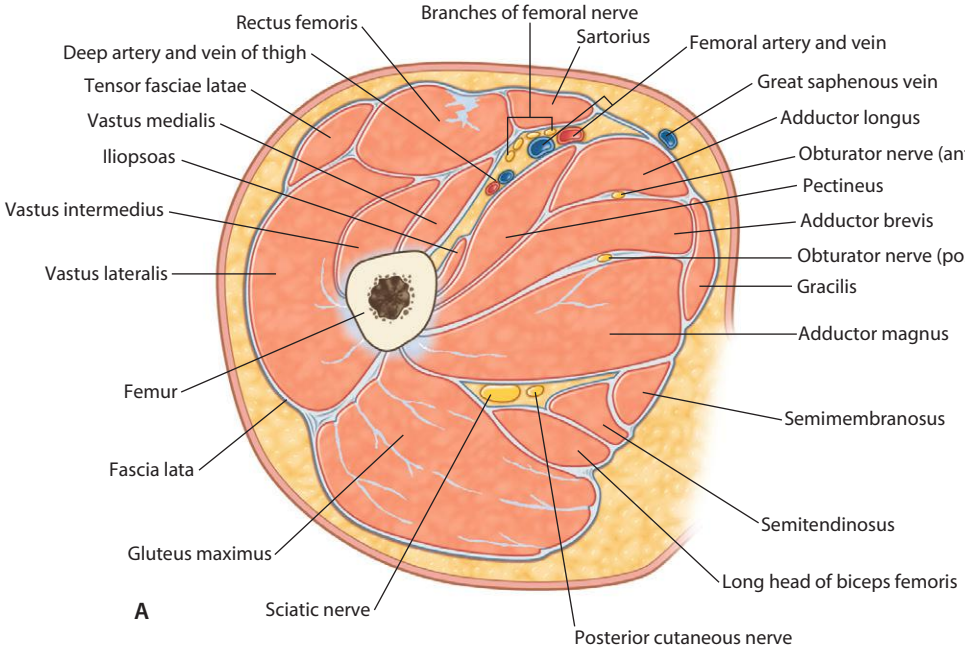

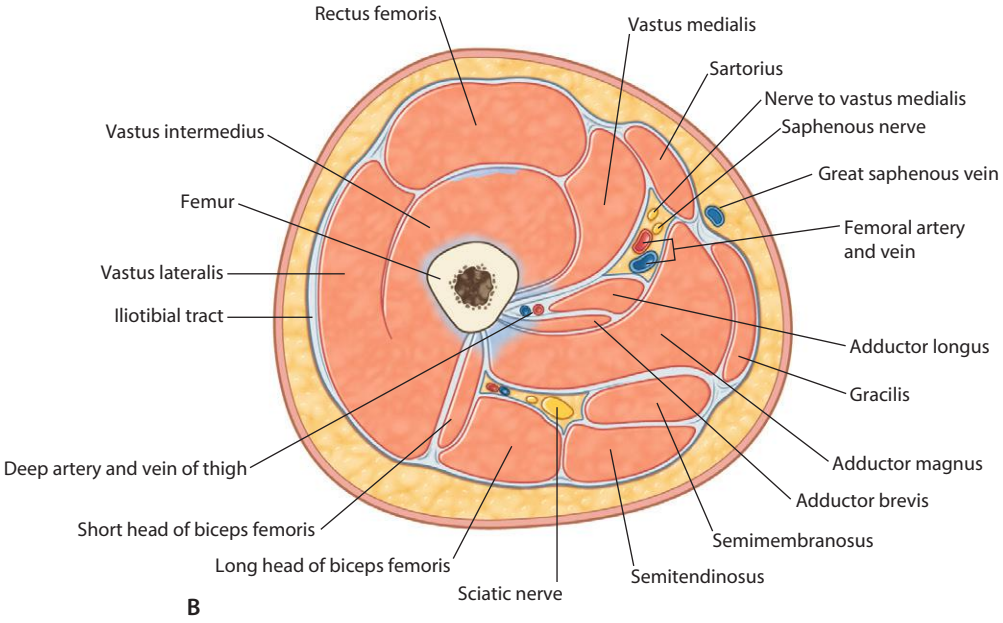

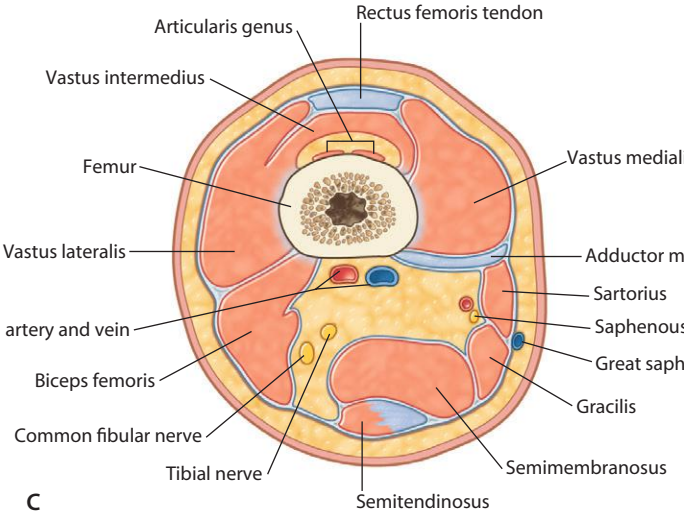

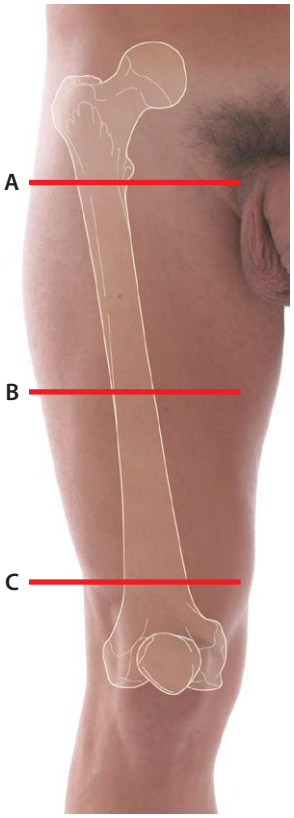

Transverse sections through thigh

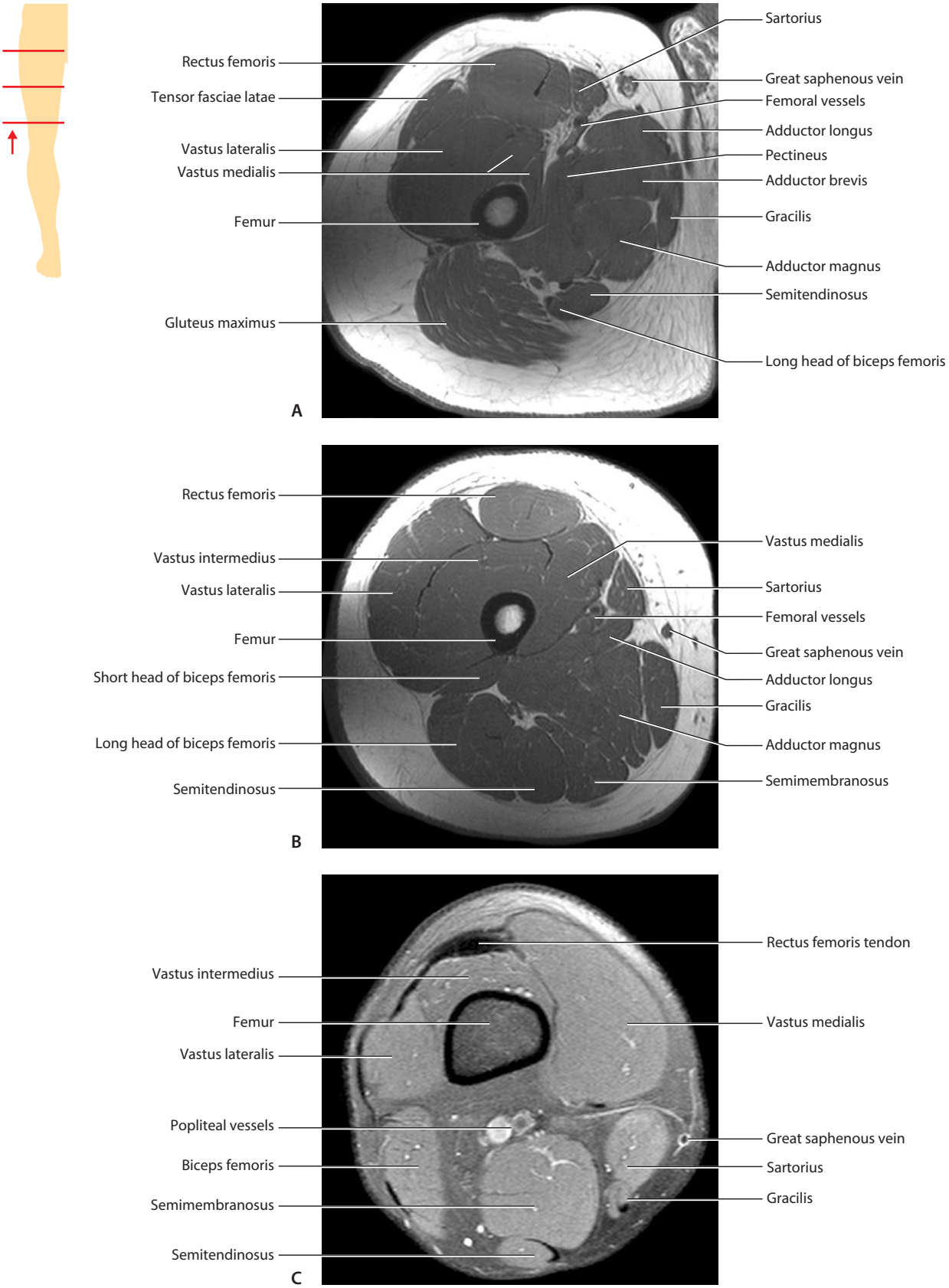

Transverse/axial sections through the thigh.
A. Proximal/upper thigh. T1-weighted MR image in axial plane
B. Middle thigh. T1-weighted MR image in axial plane
C. Distal/lower thigh. Fat-saturated T2-weighted MR image in axial plane

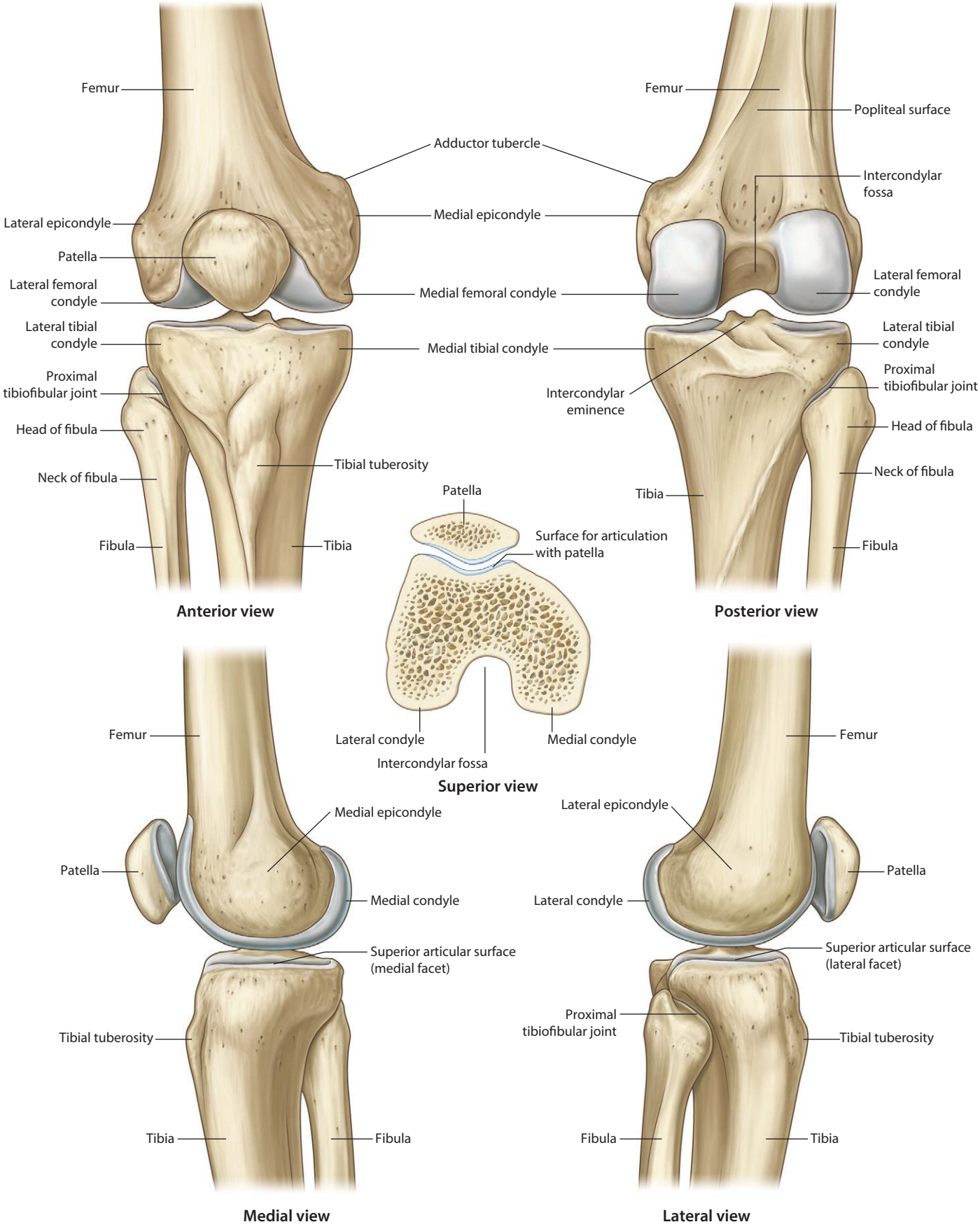
Femur
Adductor tubercle
Lateral epicondyle
Medial epicondyle
Patella
Lateral femoral condyle
Medial femoral condyle
Lateral tibial condyle
Medial tibial condyle
Proximal tibiofibular joint
Head of fibula
Tibial tuberosity
Neck of fibula
Fibula
Tibia
Anterior view
Femur
Popliteal surface
Intercondylar fossa
Lateral femoral condyle
Lateral tibial condyle
Intercondylar eminence
Proximal tibiofibular joint
Head of fibula
Neck of fibula
Tibia
Fibula
Posterior view
Patella
Surface for articulation with patella
Lateral condyle
Medial condyle
Intercondylar fossa
Superior view
Femur
Medial epicondyle
Patella
Medial condyle
Superior articular surface (medial facet)
Tibial tuberosity
Tibia
Fibula
Medial view
Femur
Lateral epicondyle
Patella
Lateral condyle
Superior articular surface (lateral facet)
Proximal tibiofibular joint
Tibial tuberosity
Fibula
Tibia
Lateral view

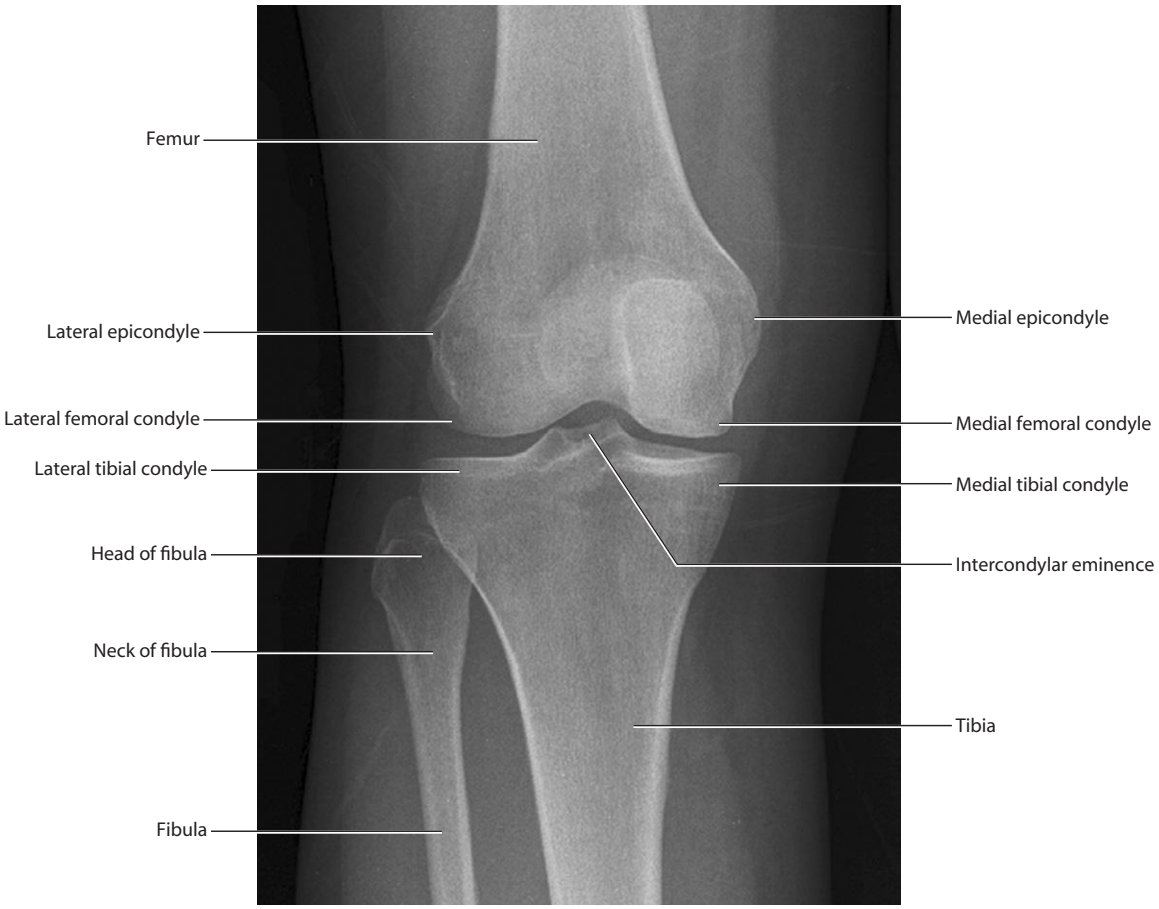

Normal knee joint.
Radiograph, AP view

Normal knee joint.
Radiograph, lateral view

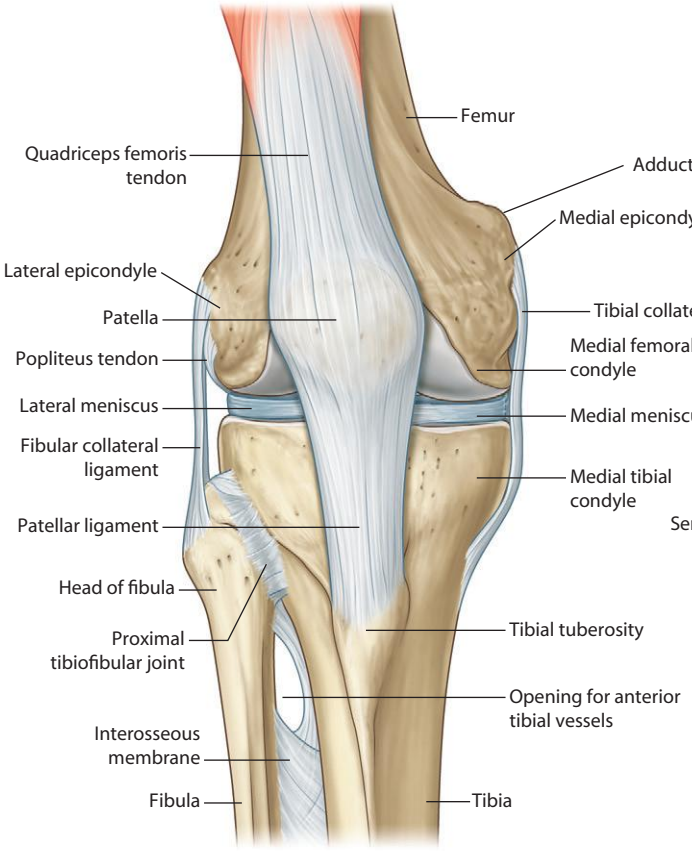

Anterior view

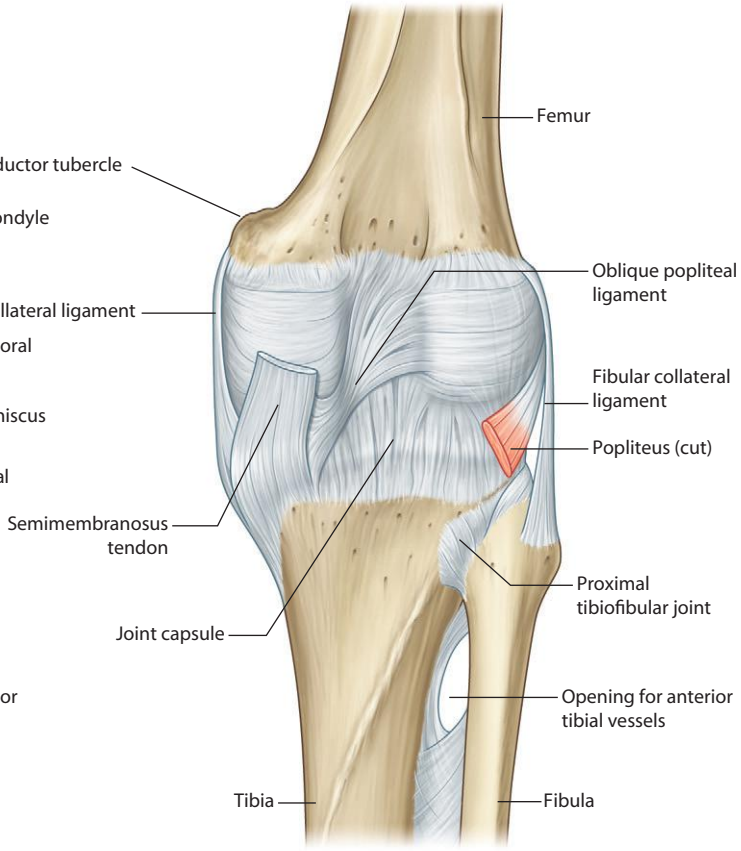

Posterior view

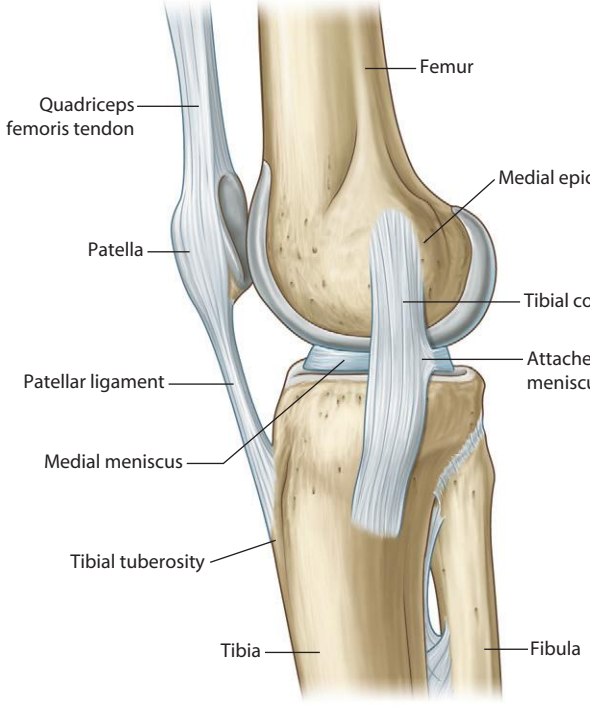

Medial view

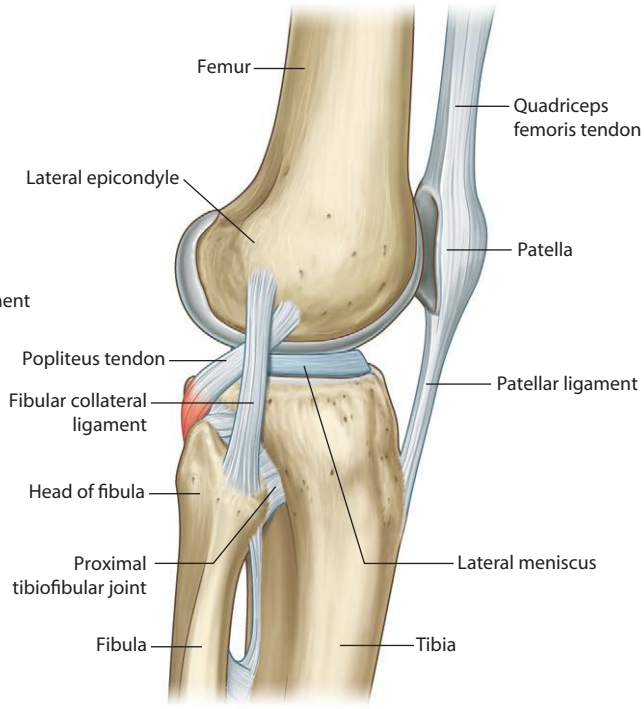

Lateral view

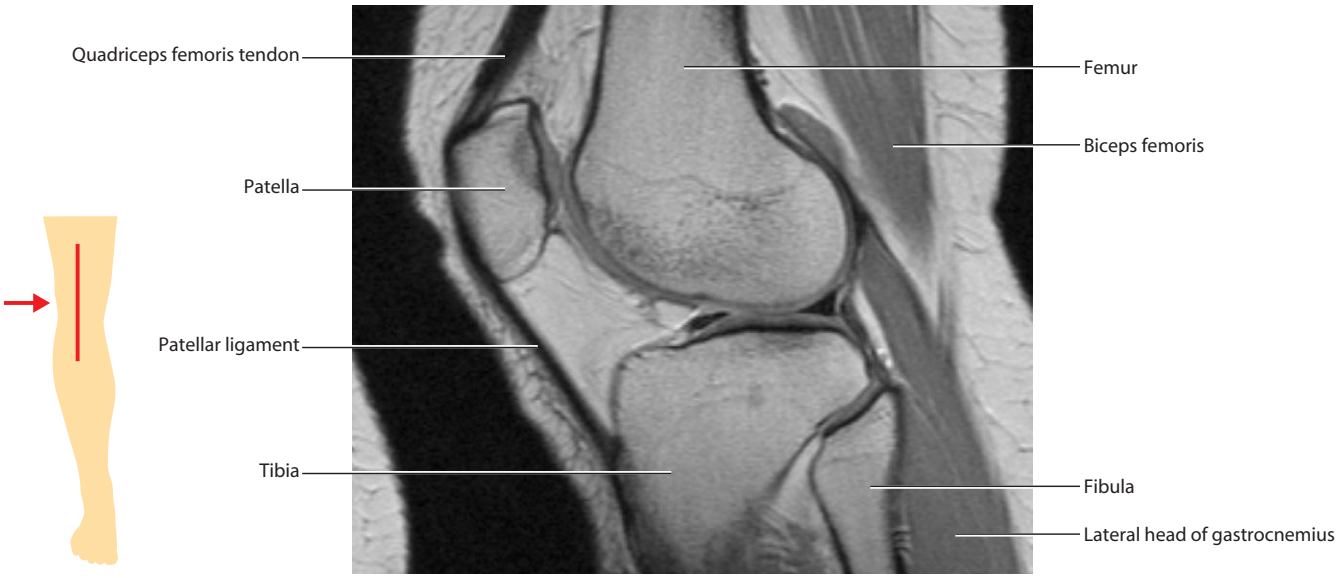

Normal knee joint.
T2-weighted MR image in sagittal plane

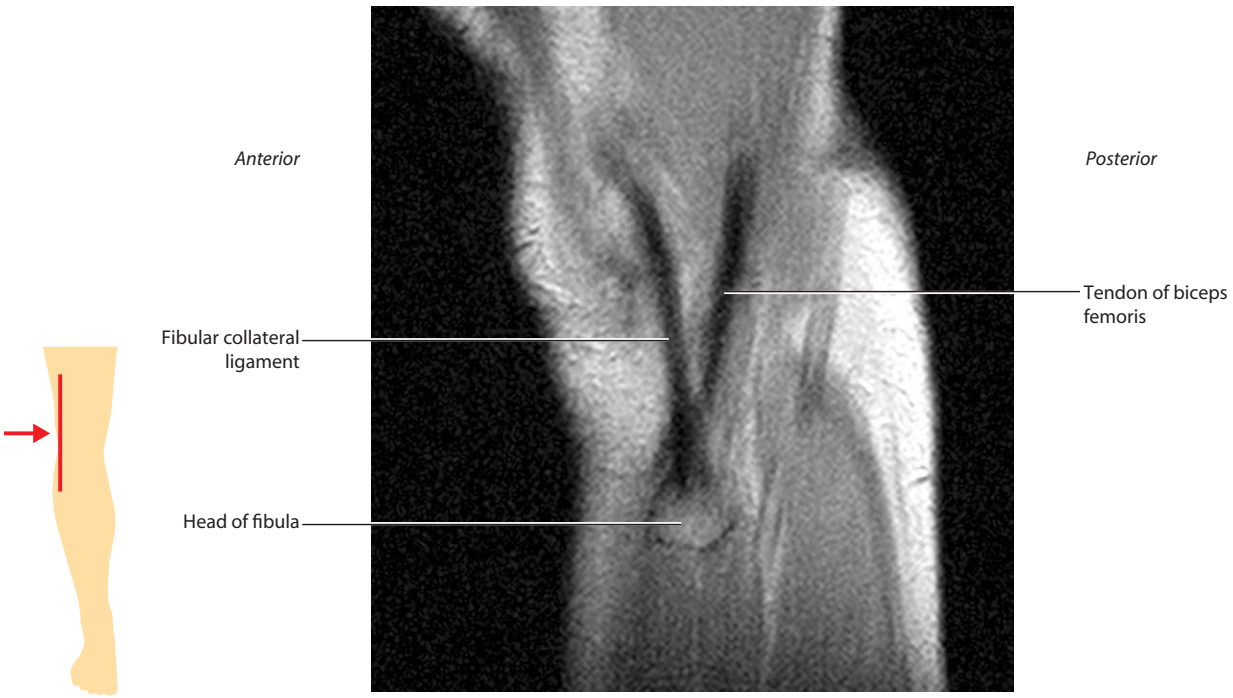

Unique view showing the fibular collateral ligament and the tendon of the biceps femoris muscle attaching to the head of the fibula.
T2-weighted MR image in sagittal plane

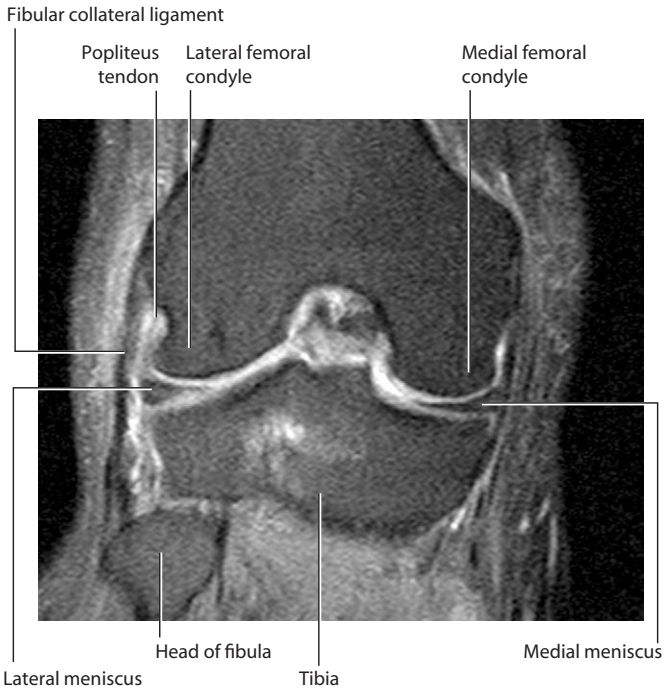

Coronal view of knee joint showing the fibular collateral ligament and its relationship to surrounding structures.
Fat-saturated T2-weighted MR image in coronal plane

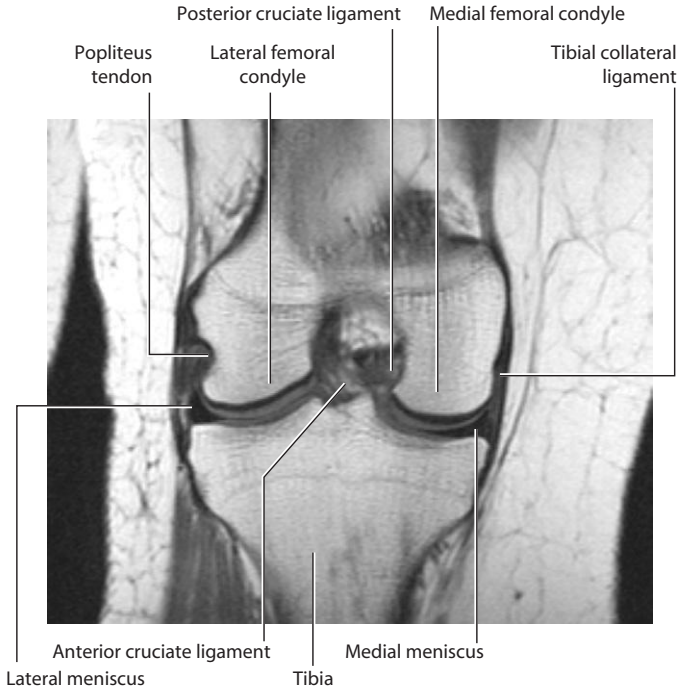

Anterior view of knee joint showing the relationship between the tibial collateral ligament and the medial meniscus.
T1-weighted MR image in coronal plane

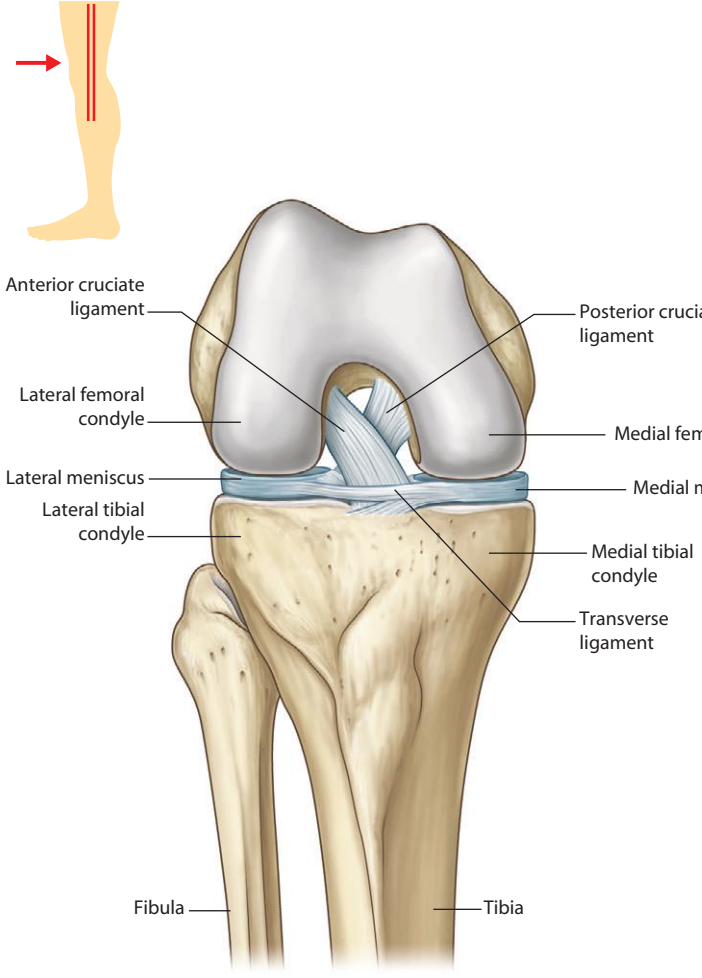

Anterior view (flexed)

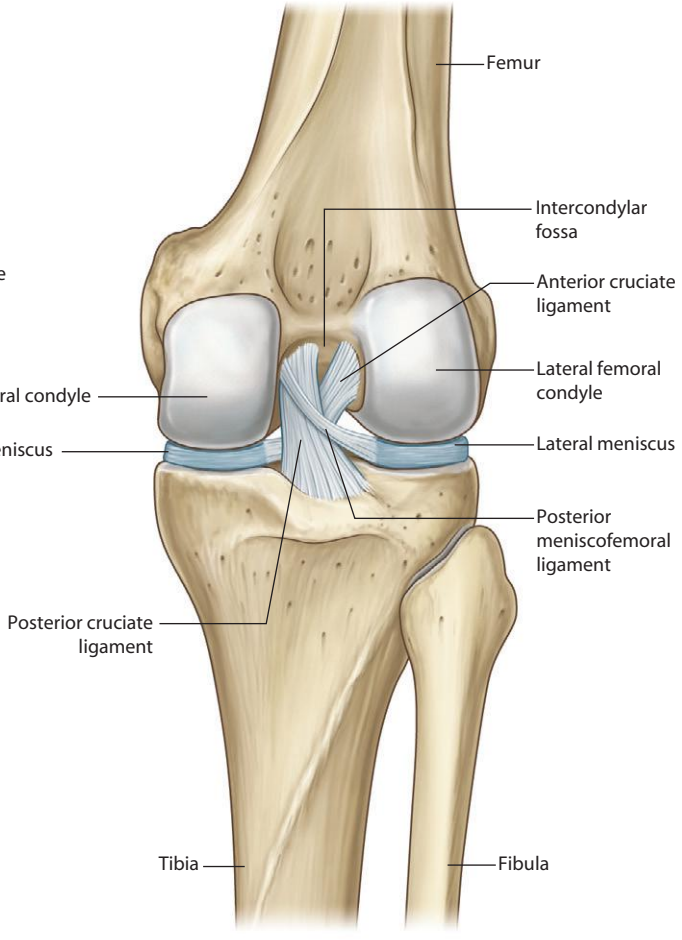

Posterior view

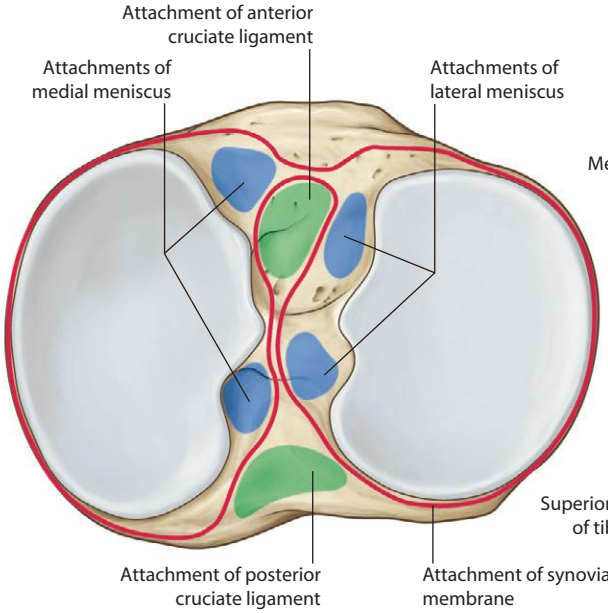

Attachments of menisci, cruciate ligaments, and synovial membrane of the right tibia. (superior view)

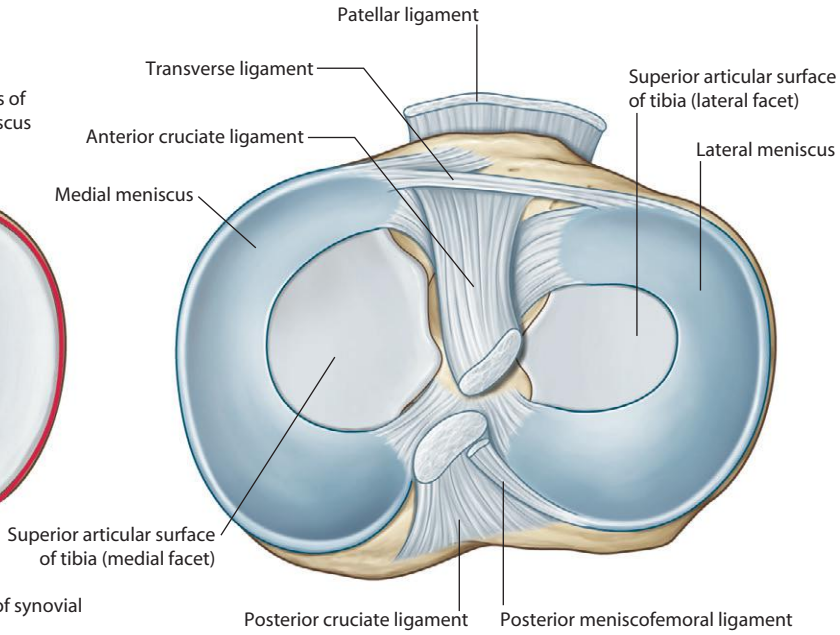

Menisci of the right knee joint. (superior view)

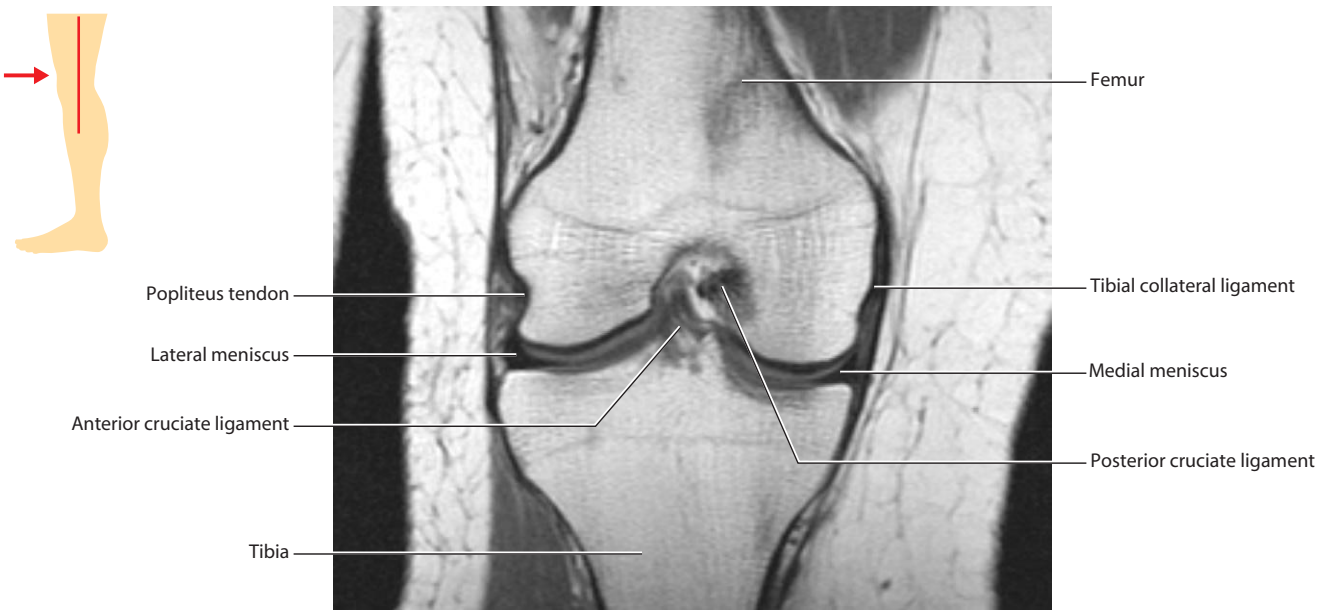

Anterior view of knee joint showing the anterior and posterior cruciate ligaments.
T2-weighted MR image in coronal plane

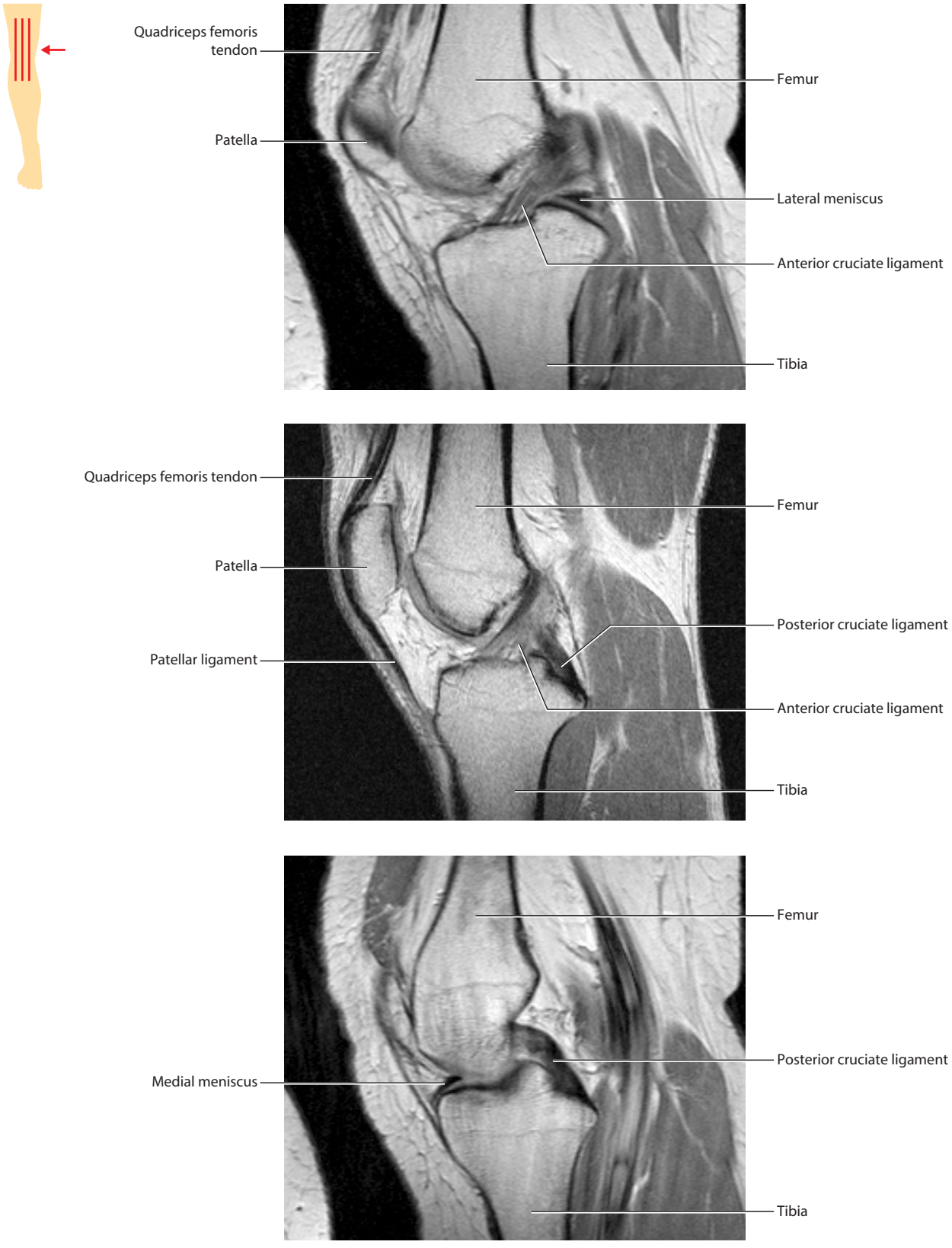

A series of images moving from medial to lateral showing the relationship between anterior and posterior cruciate ligaments.
T2-weighted MR images in sagittal plane

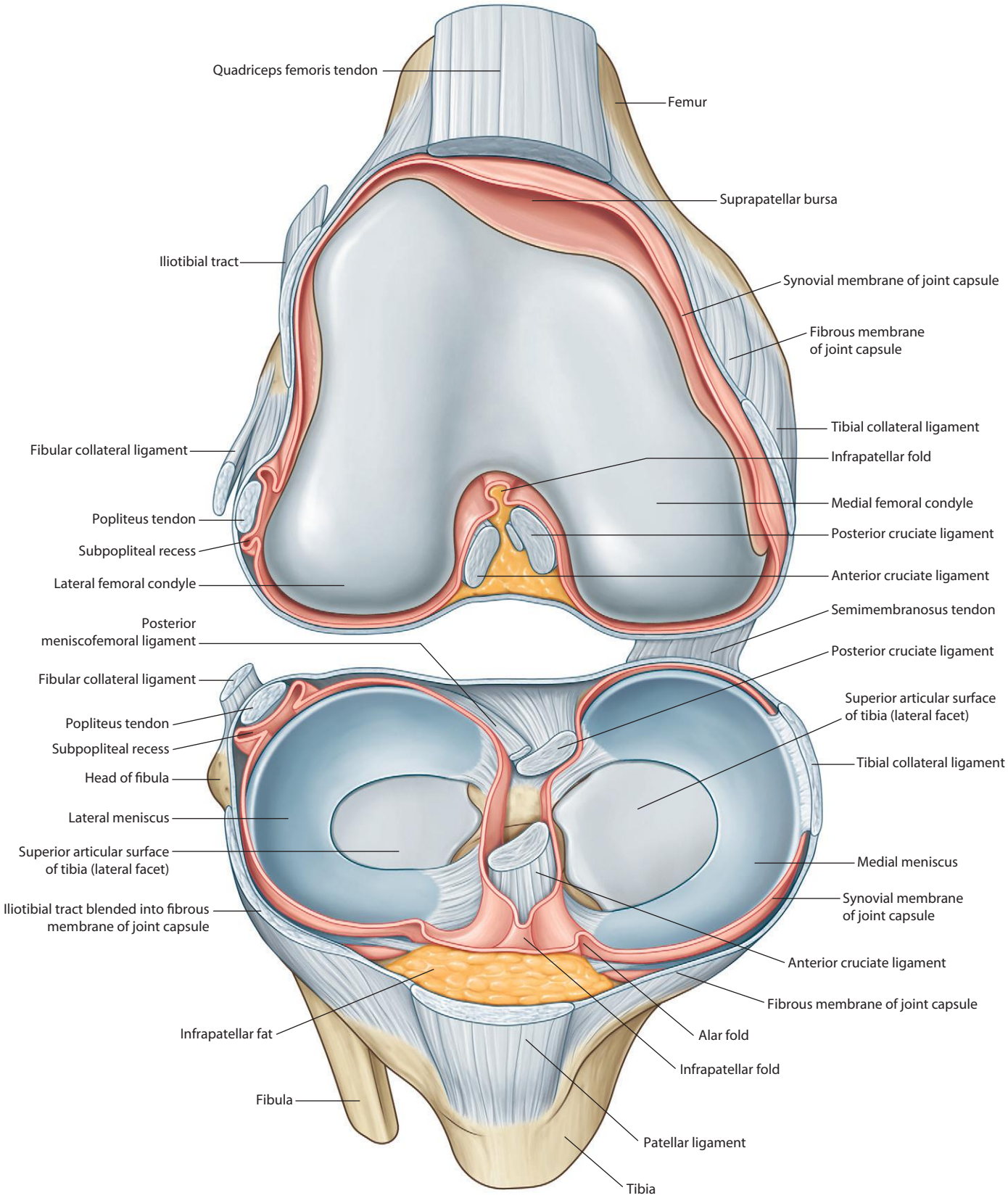

Knee joint (anterosuperior view)

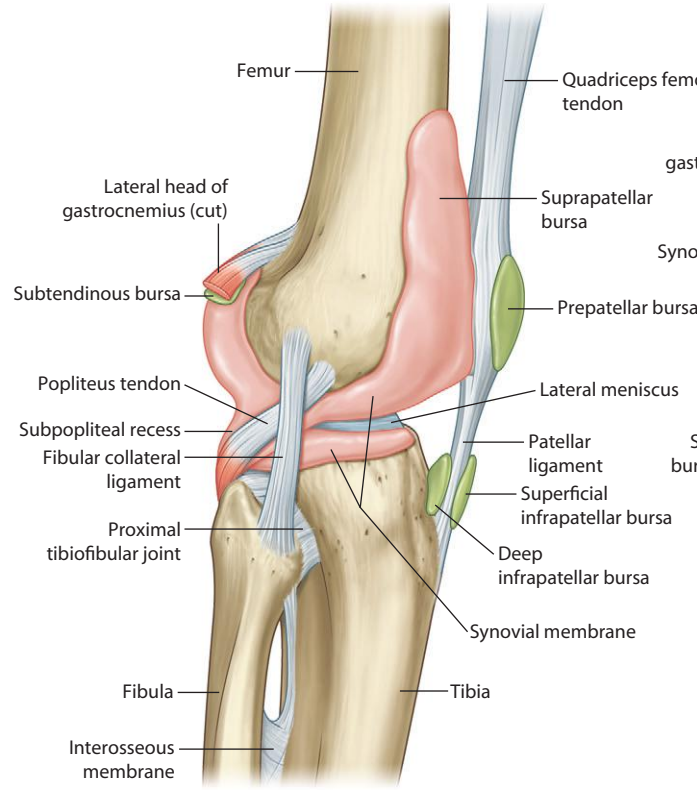

Lateral view

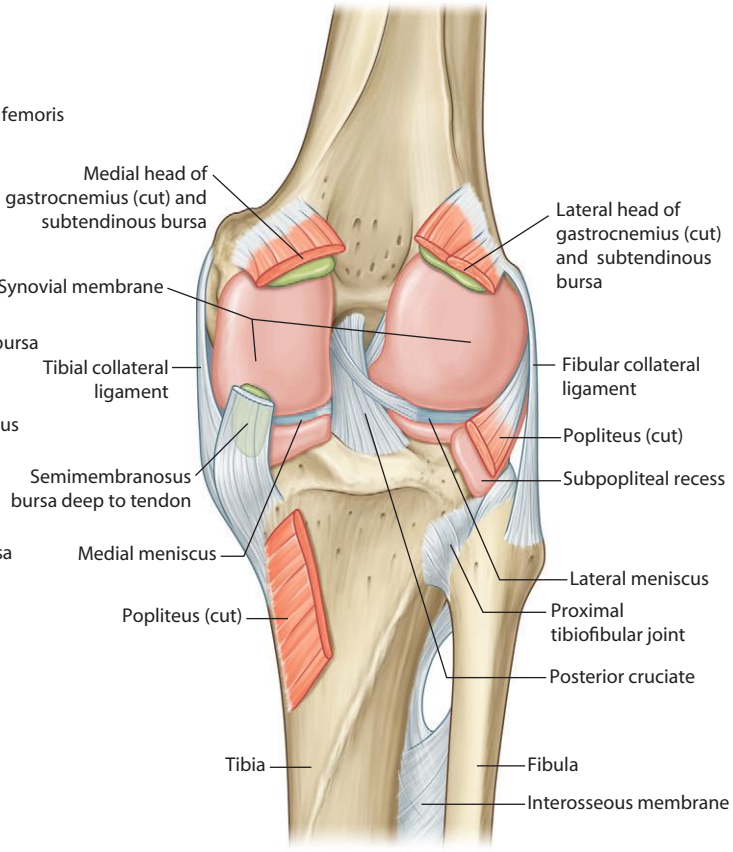

Posterior view

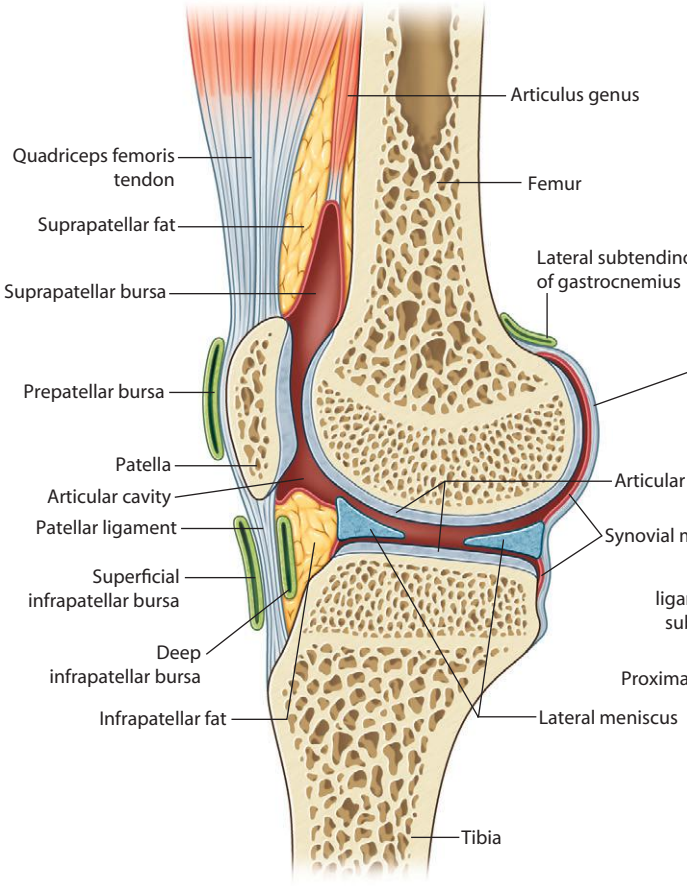

Paramedian section through knee joint

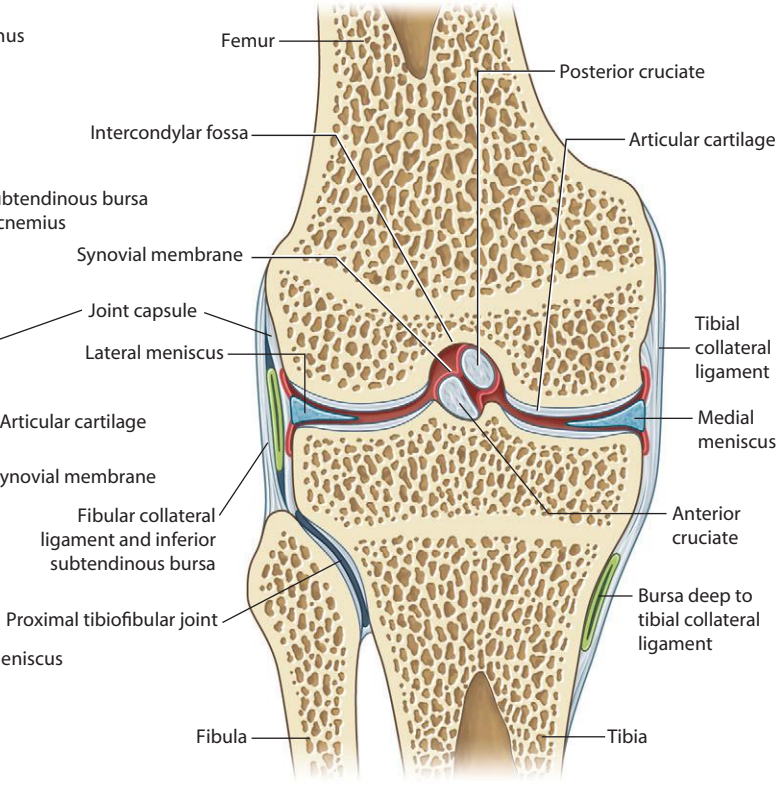

Coronal section through knee joint (anterior view)

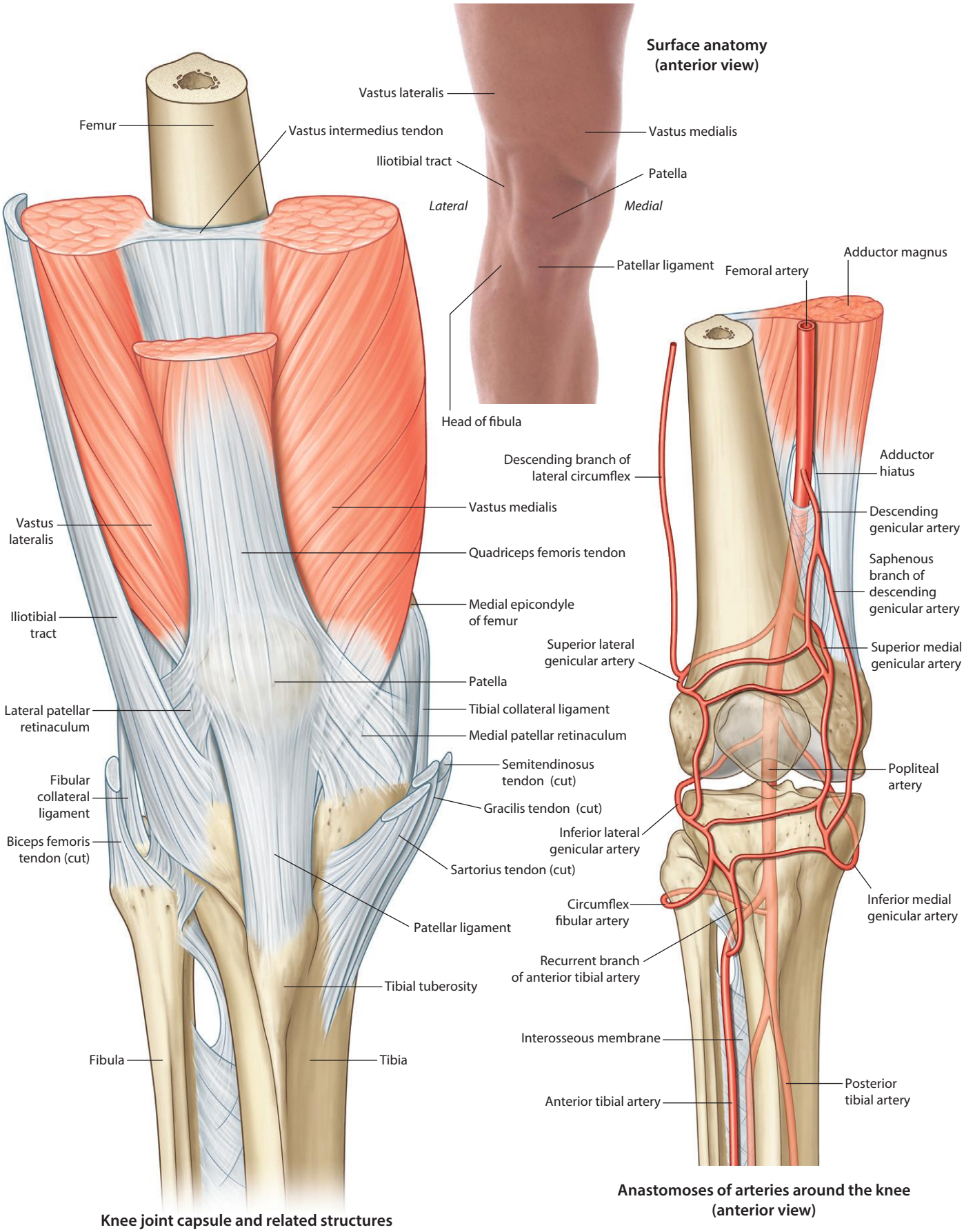
Surface anatomy
(anterior view)
Vastus lateralis
Vastus medialis
Iliotibial tract
Patella
Lateral
Medial
Patellar ligament
Head of fibula
Femur
Vastus intermedius tendon
Vastus lateralis
Vastus medialis
Quadriceps femoris tendon
Iliotibial tract
Medial epicondyle of femur
Patella
Lateral patellar retinaculum
Tibial collateral ligament
Medial patellar retinaculum
Fibular collateral ligament
Semitendinosus tendon (cut)
Biceps femoris tendon (cut)
Gracilis tendon (cut)
Sartorius tendon (cut)
Patellar ligament
Tibial tuberosity
Fibula
Tibia
Knee joint capsule and related structures
(anterior view)
Adductor magnus
Femoral artery
Descending branch of lateral circumflex
Adductor hiatus
Descending genicular artery
Saphenous branch of descending genicular artery
Superior lateral genicular artery
Superior medial genicular artery
Popliteal artery
Inferior lateral genicular artery
Inferior medial genicular artery
Circumflex fibular artery
Recurrent branch of anterior tibial artery
Interosseous membrane
Posterior tibial artery
Anterior tibial artery
Anastomoses of arteries around the knee
(anterior view)

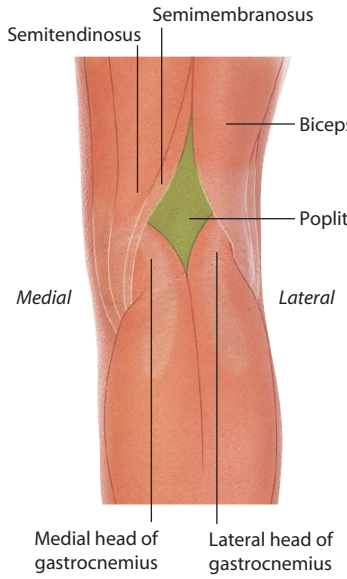

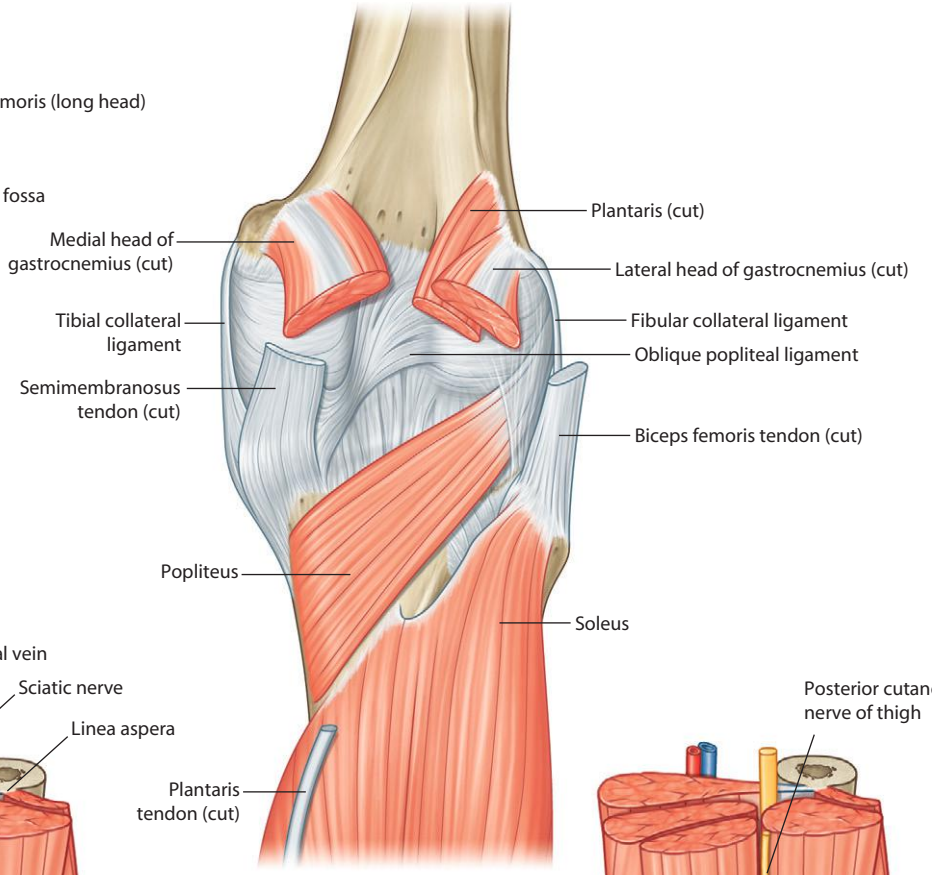

Floor of the popliteal fossa

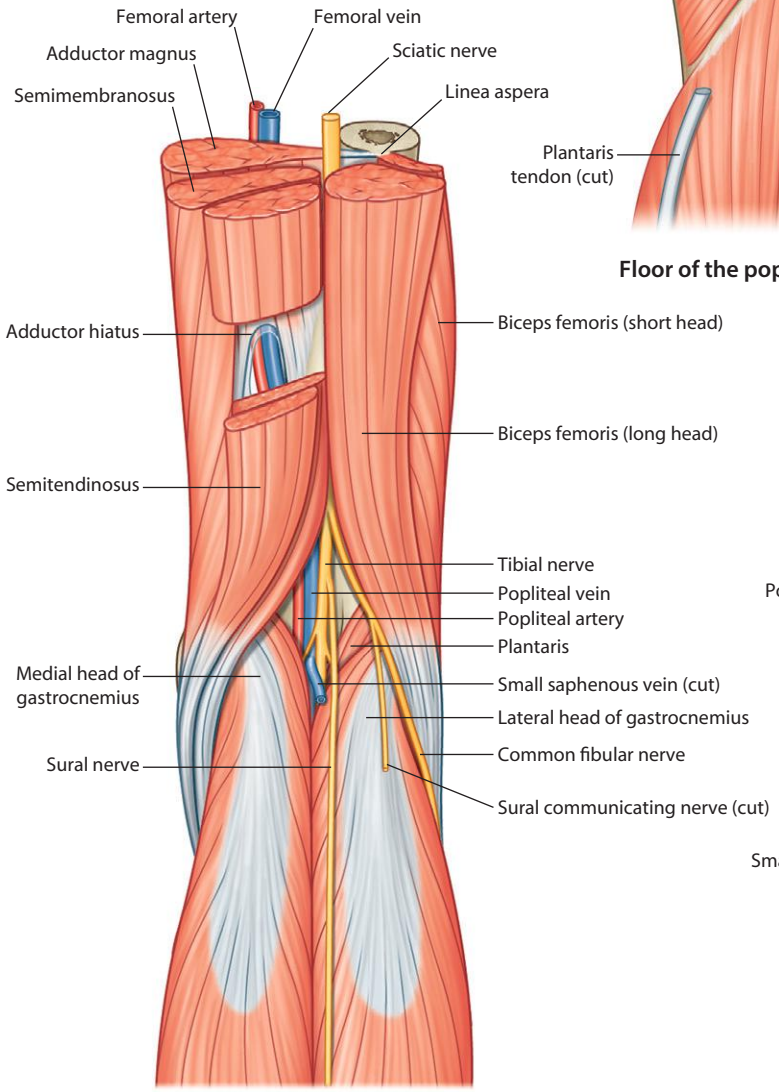

Structures in the popliteal fossa

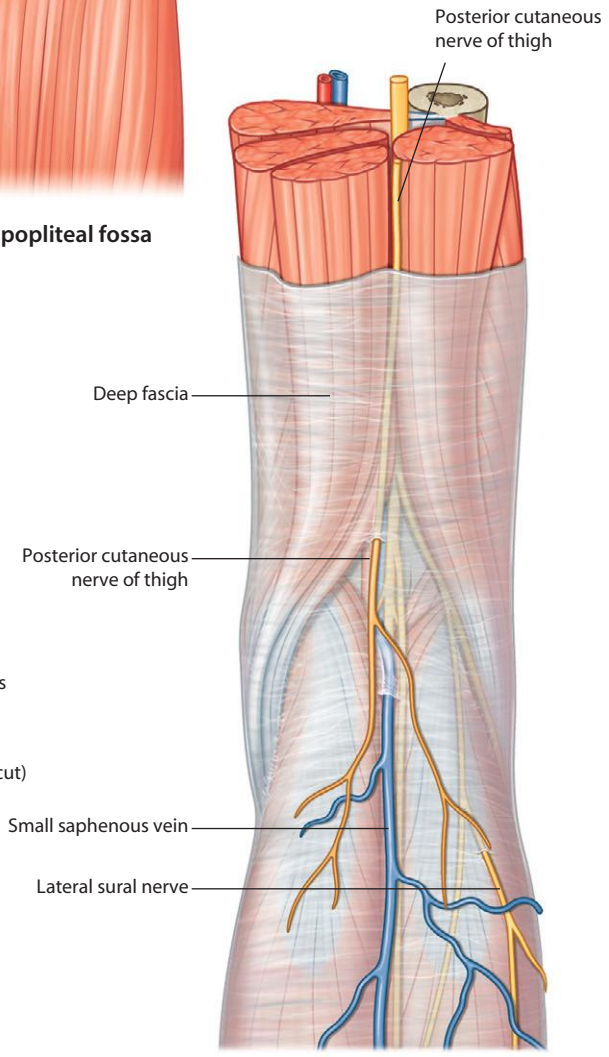

Superficial structures

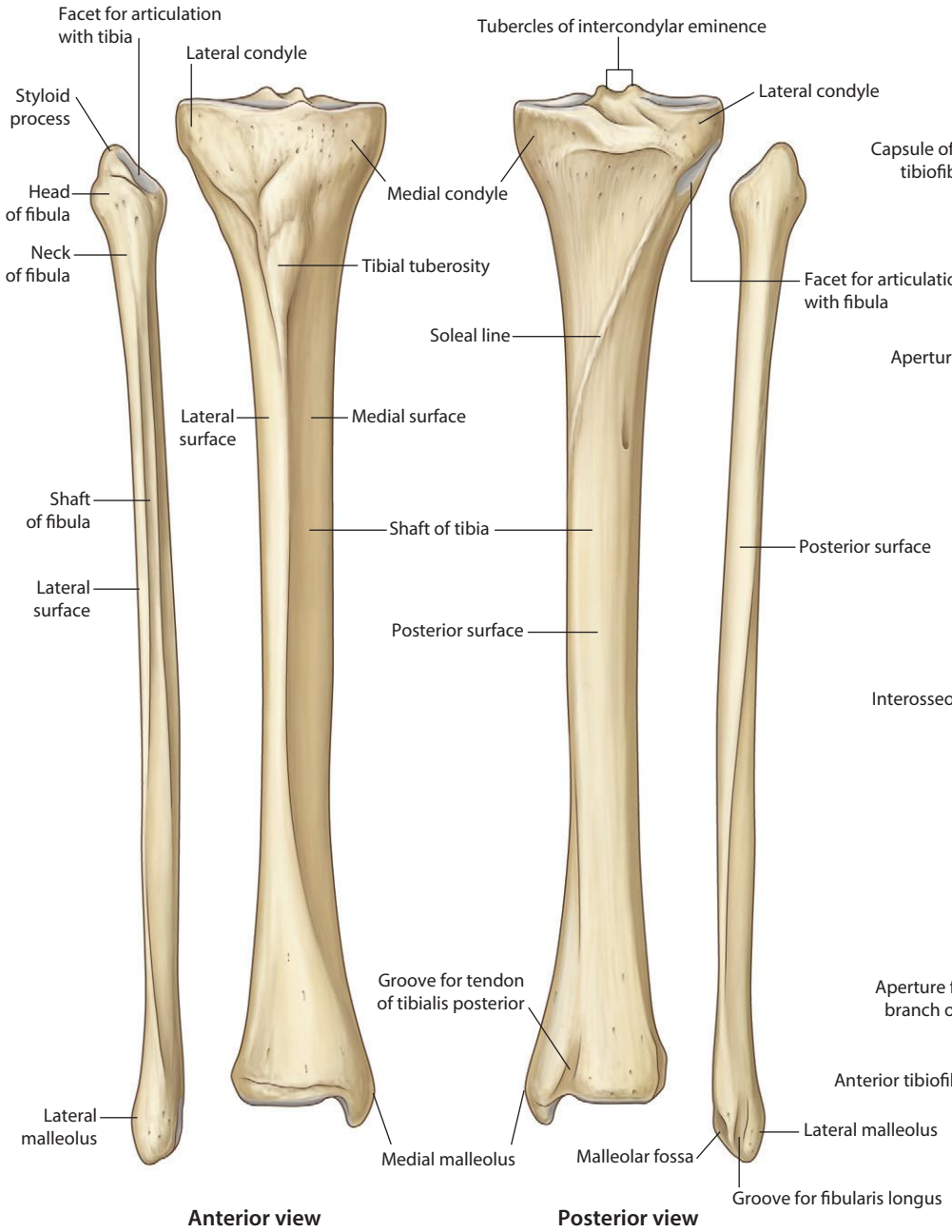

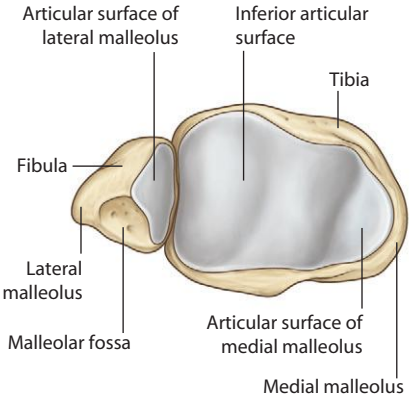

Distal tibia and fibula (inferior view)

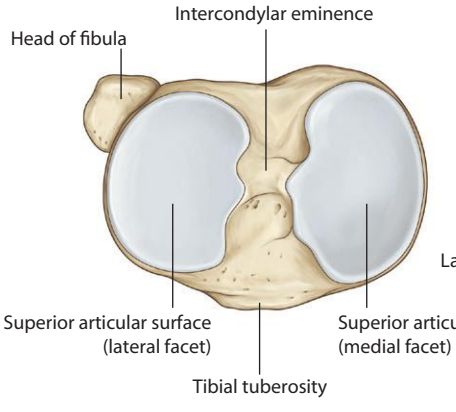

Proximal tibia and fibula (superior view)

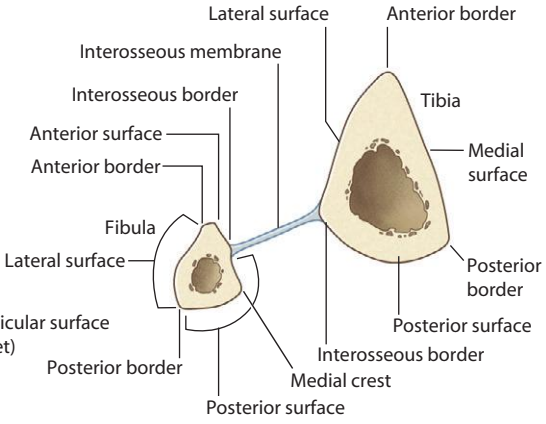

Cross section through shafts

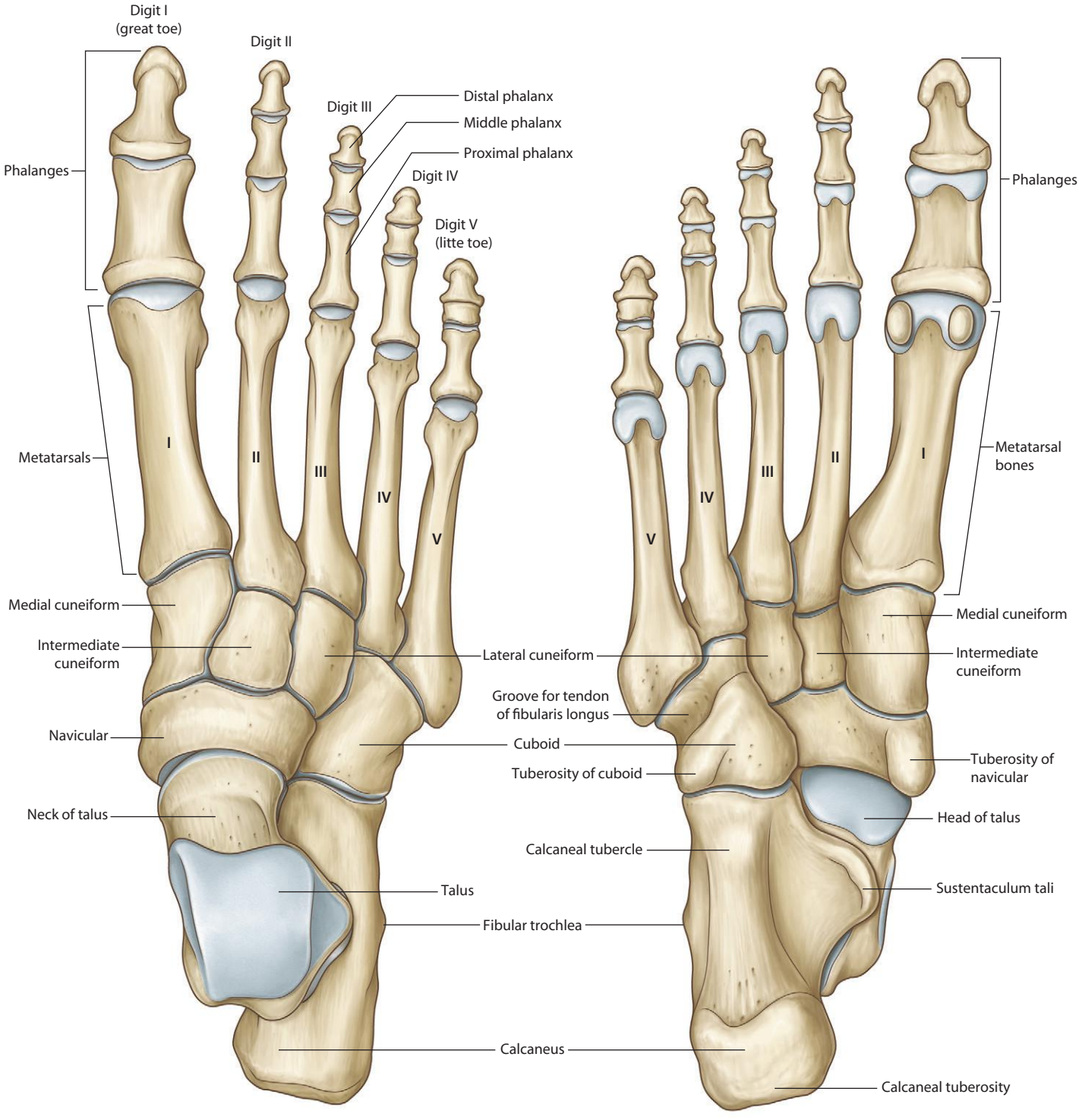
Digit I
(great toe)
Digit II
Digit III
Digit IV
Digit V
(litte toe)
Distal phalanx
Middle phalanx
Proximal phalanx
Phalanges
Metatarsals
I
II
III
IV
V
Medial cuneiform
Intermediate
cuneiform
Lateral cuneiform
Navicular
Cuboid
Neck of talus
Talus
Fibular trochlea
Calcaneus
Dorsal view
Phalanges
Metatarsal
bones
Medial cuneiform
Intermediate
cuneiform
Groove for tendon
of fibularis longus
Tuberosity of
navicular
Tuberosity of cuboid
Head of talus
Calcaneal tubercle
Sustentaculum tali
Calcaneal tuberosity
Plantar view

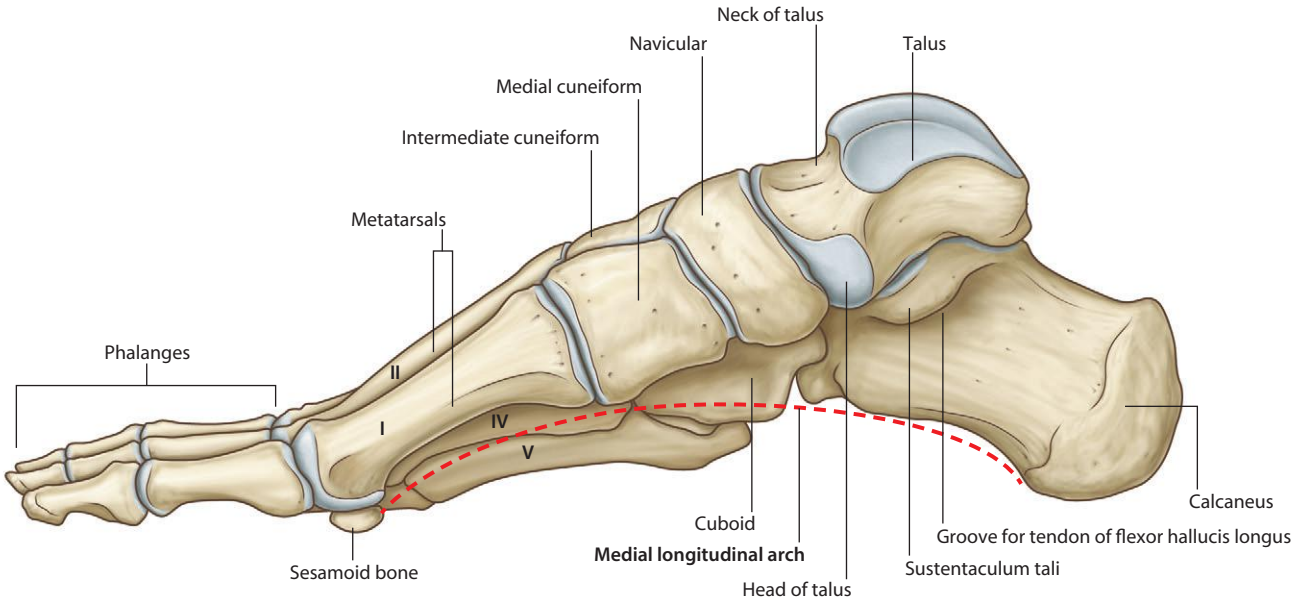

Medial view

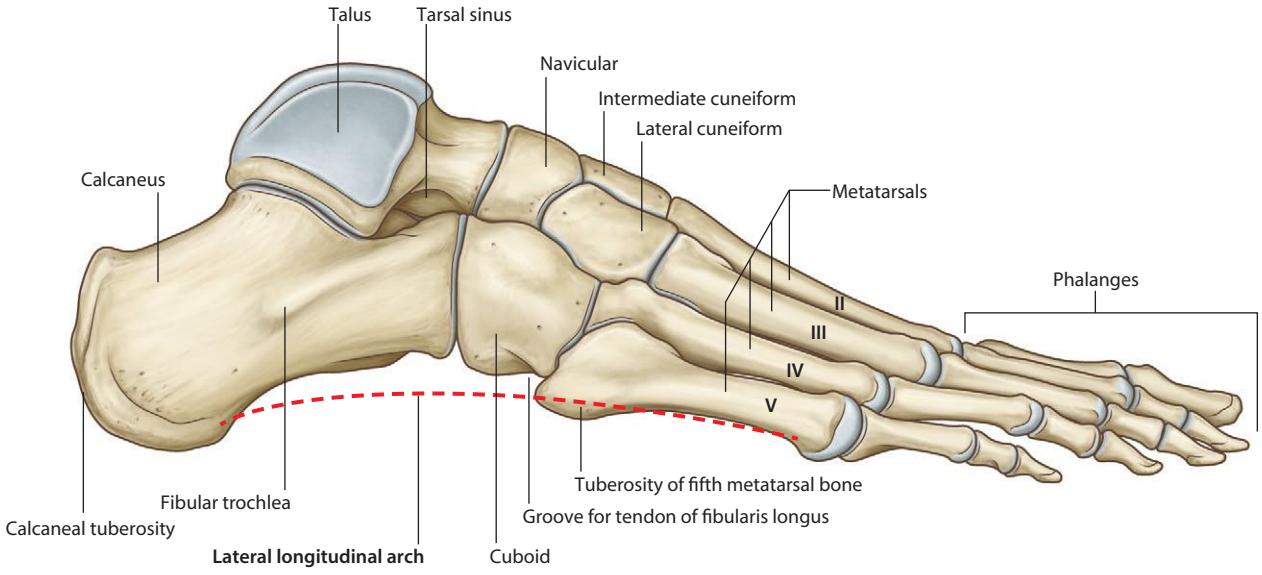

Lateral view

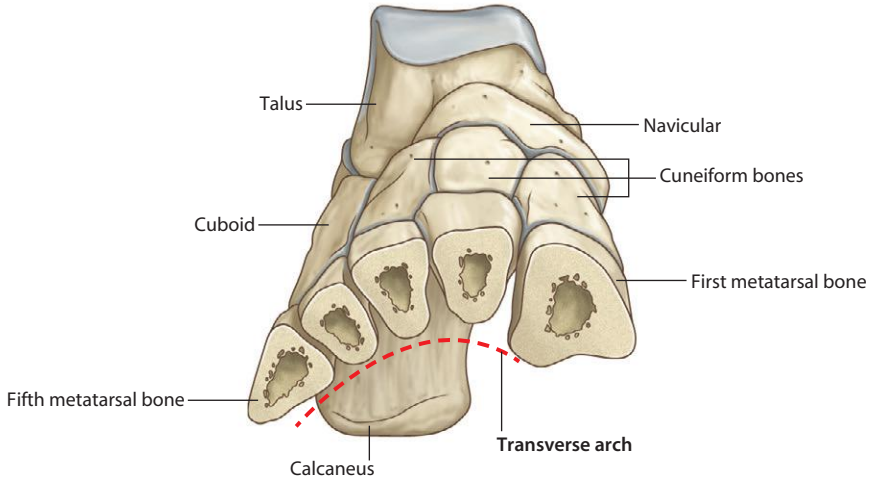

Cross section through the foot bones

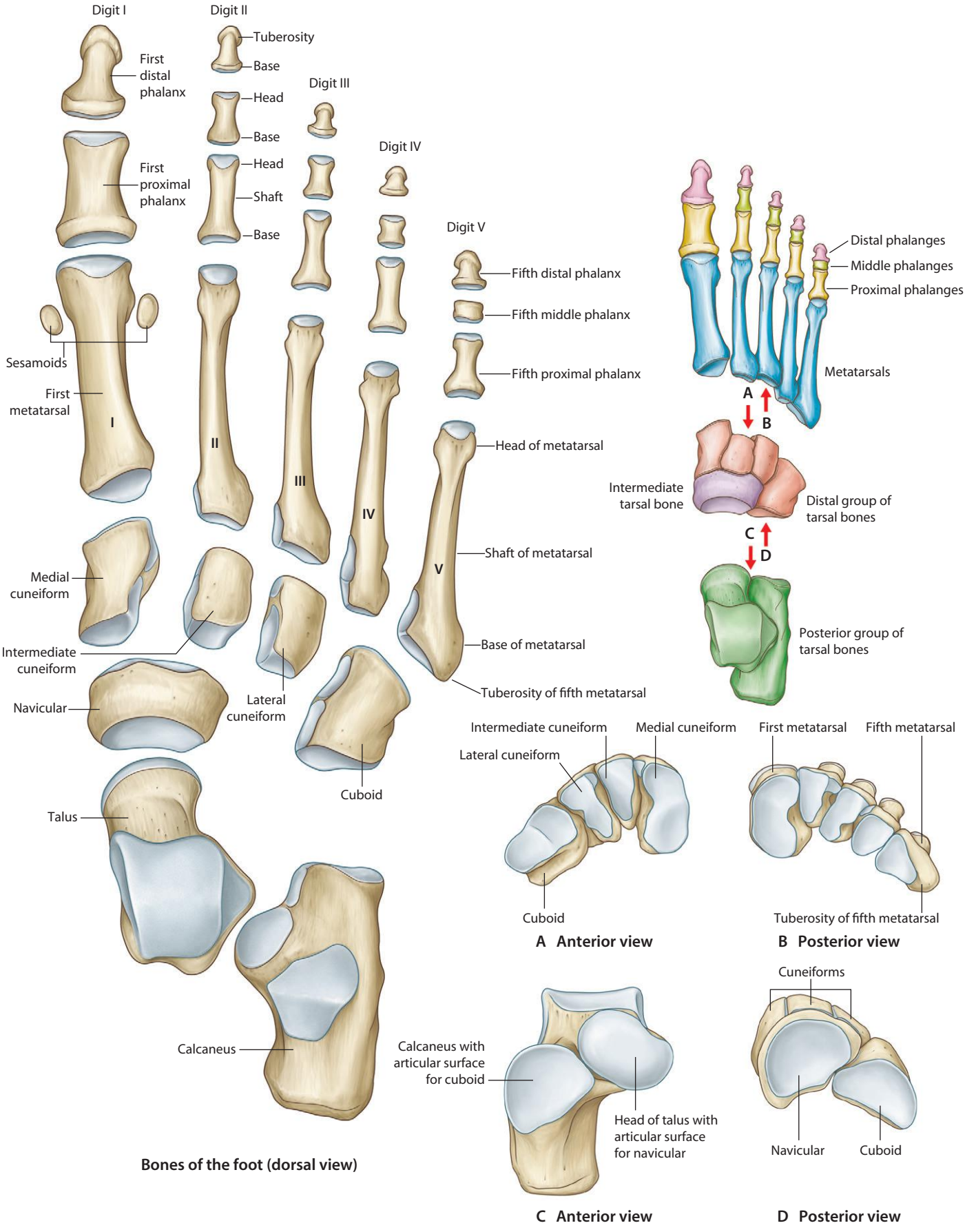

Bones of the foot (dorsal view)

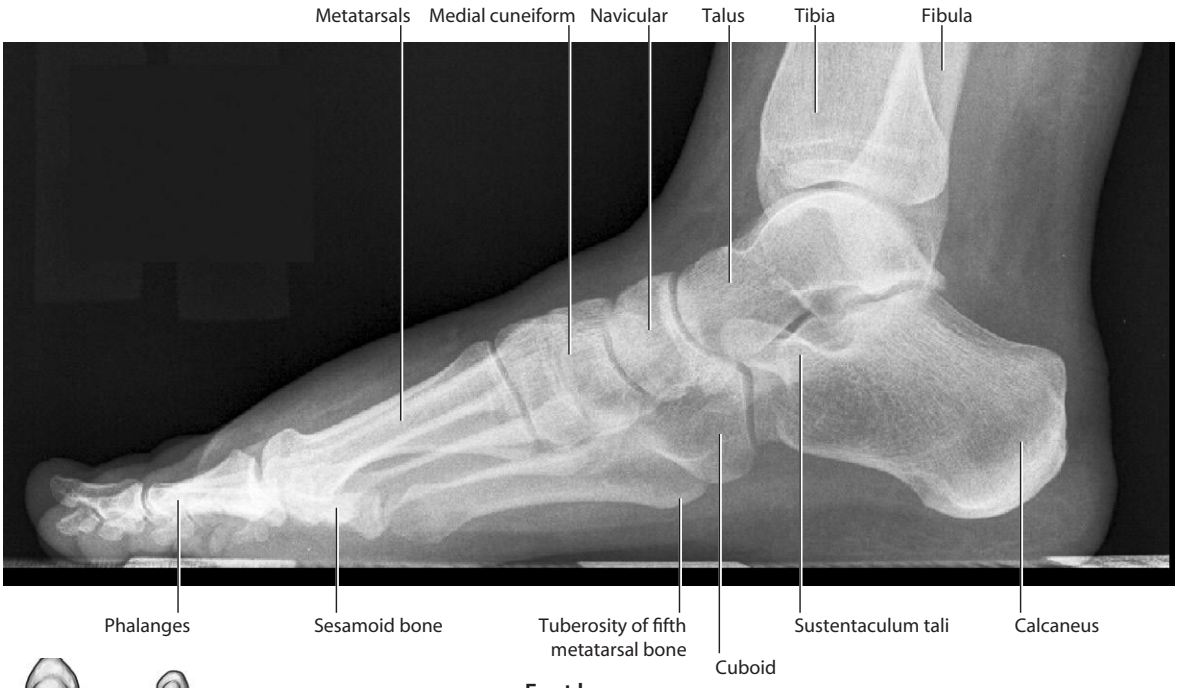

Foot bones.
Radiograph, lateral view

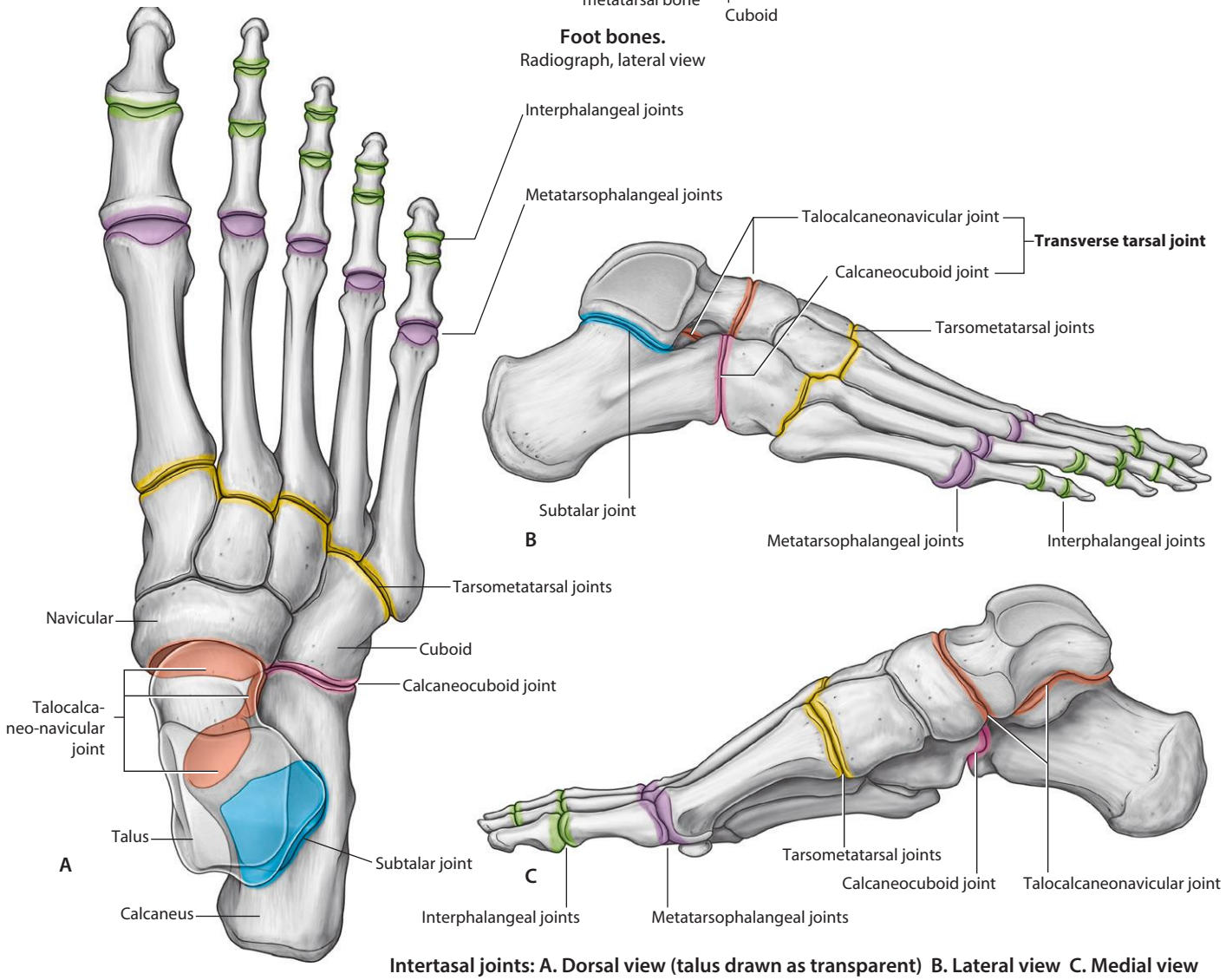

Intertasal joints: A. Dorsal view (talus drawn as transparent) B. Lateral view C. Medial view

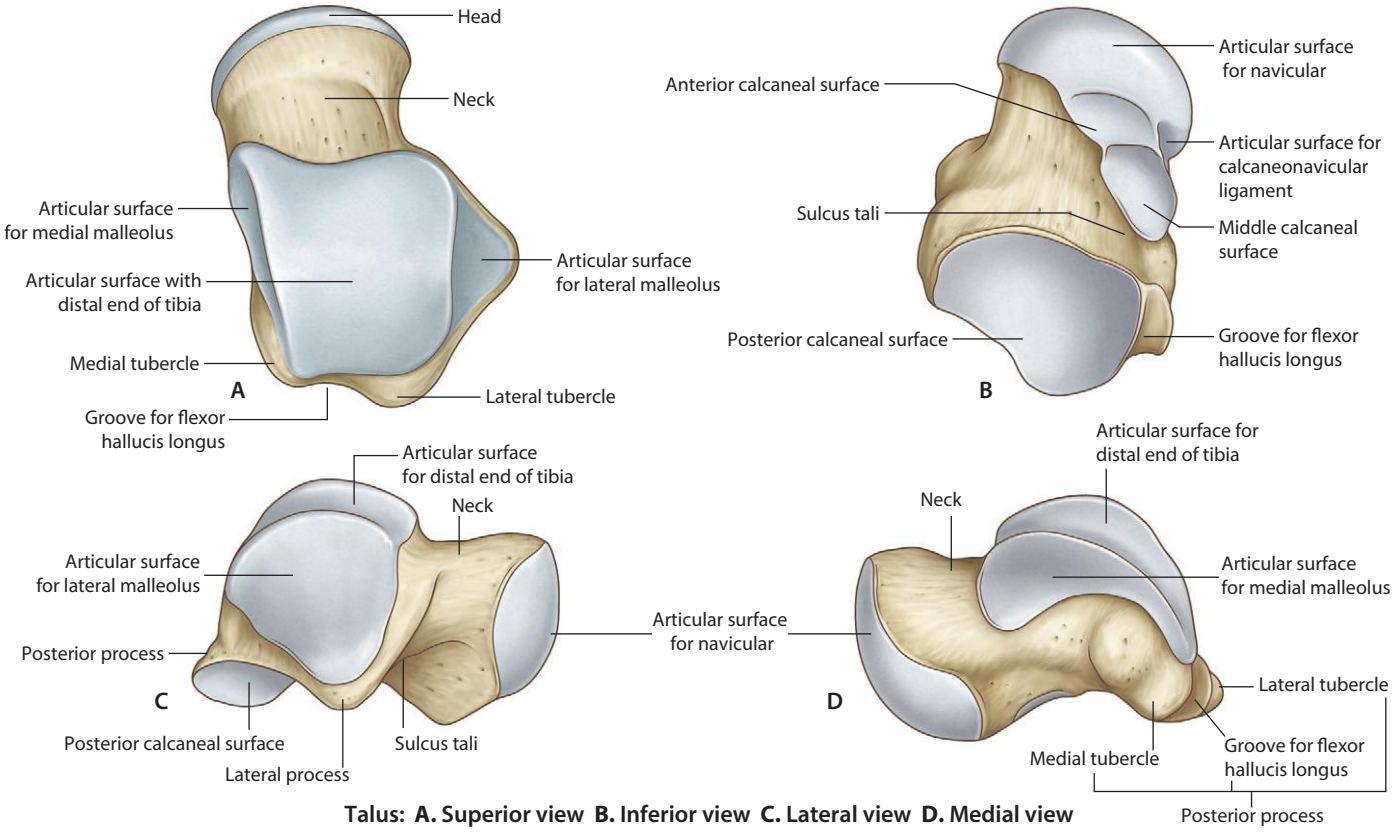

Talus: A. Superior view B. Inferior view C. Lateral view D. Medial view

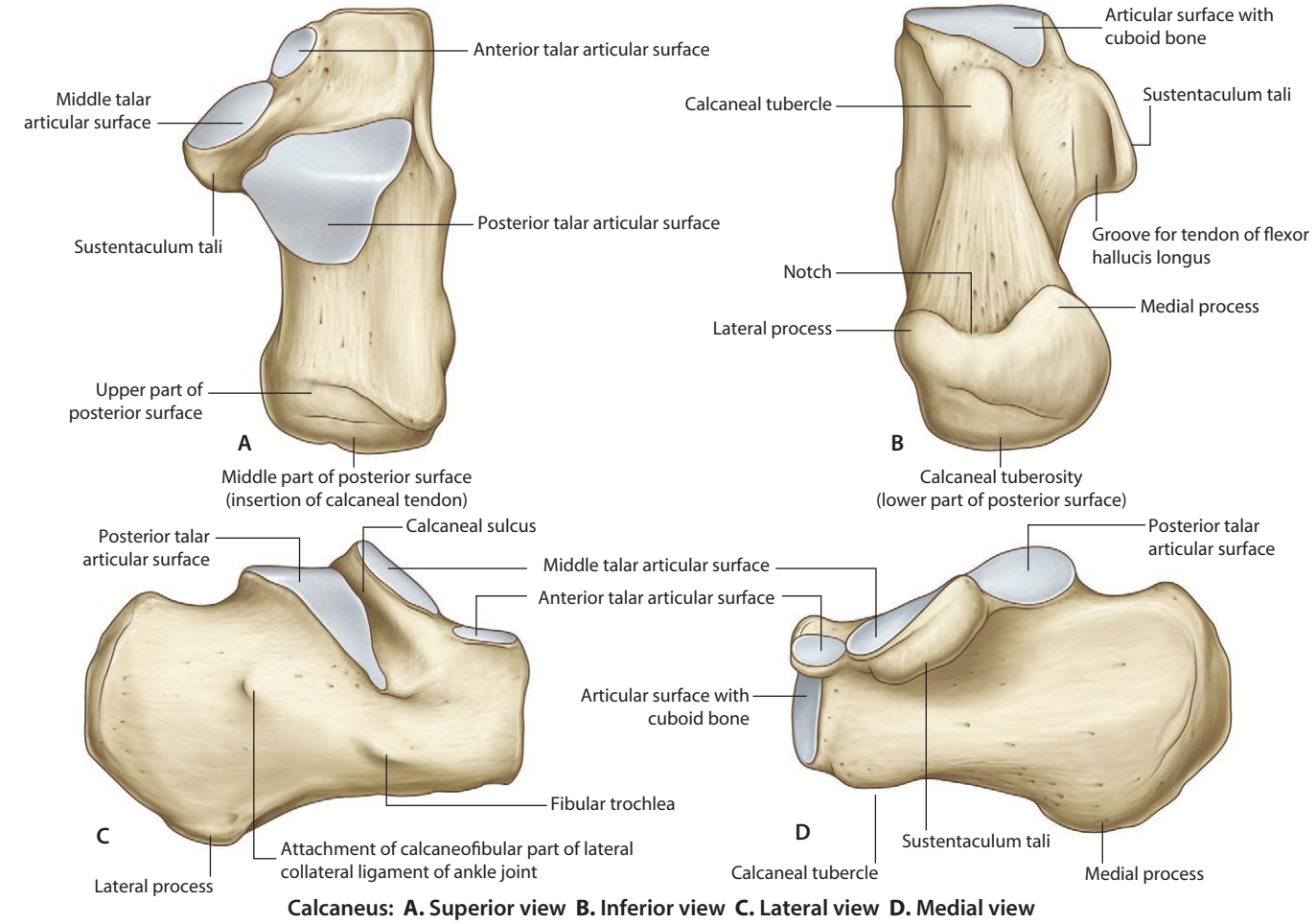

Calcaneus: A. Superior view B. Inferior view C. Lateral view D. Medial view

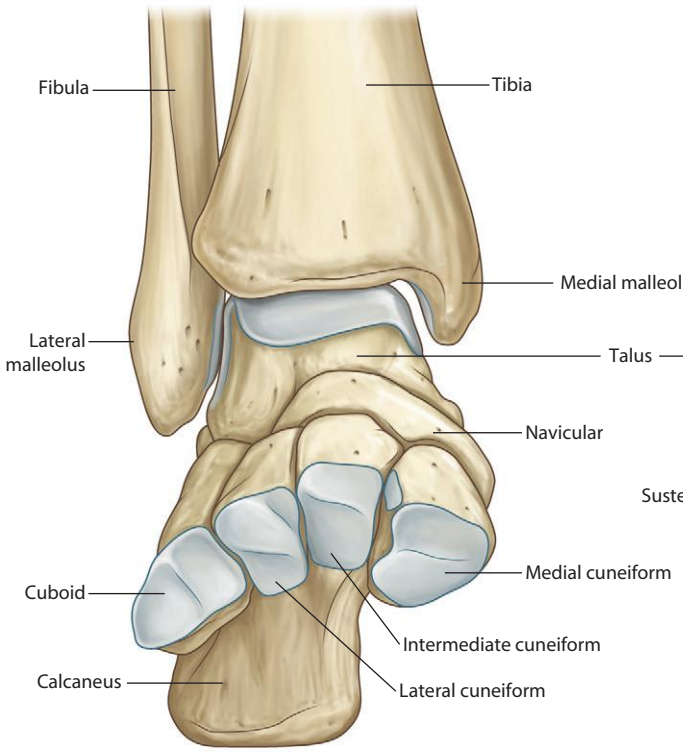

Anterior view
(metatarsals and phalanges removed)

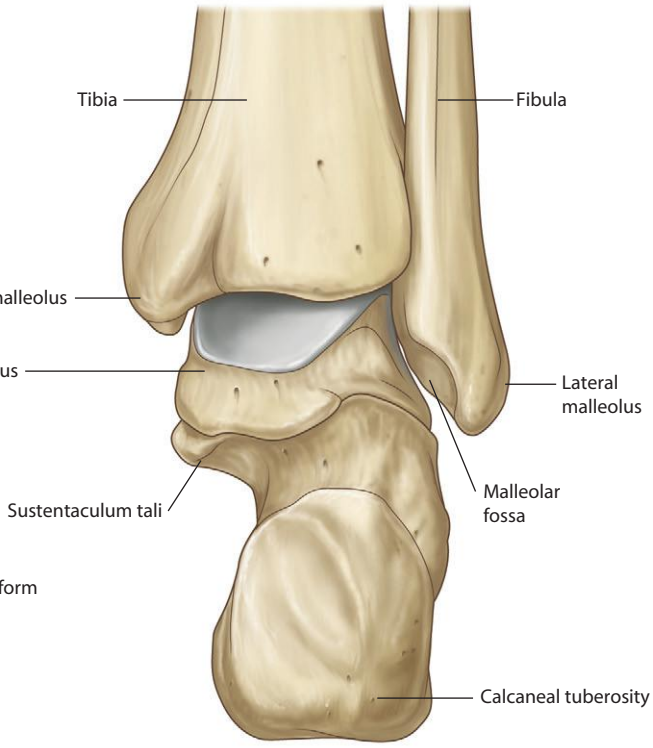

Posterior view

Normal ankle joint.
Radiograph, lateral view

Normal ankle joint.
Radiograph, AP view

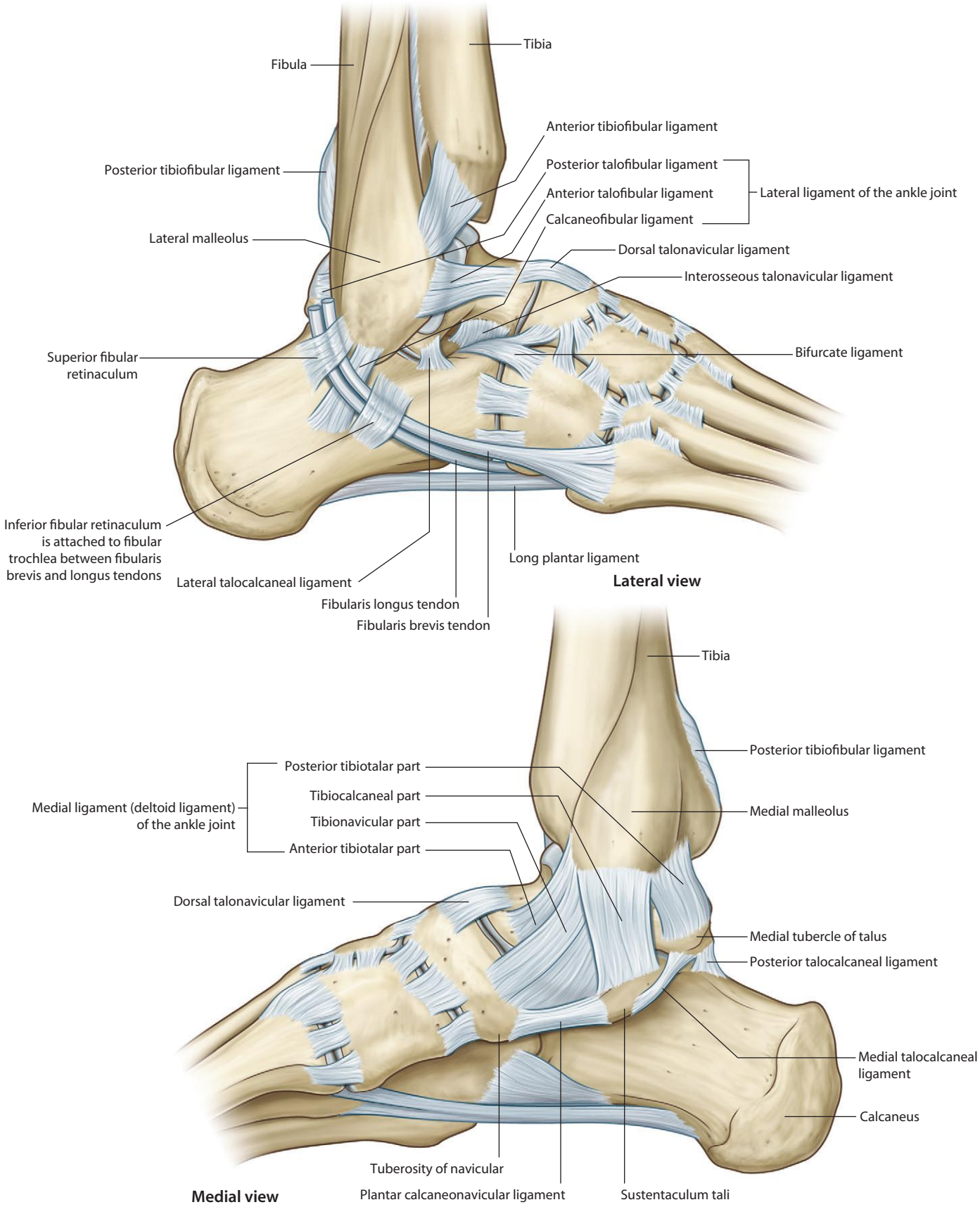
Tibia
Fibula
Anterior tibiofibular ligament
Posterior tibiofibular ligament
Posterior talofibular ligament
Anterior talofibular ligament
Calcaneofibular ligament
Lateral ligament of the ankle joint
Lateral malleolus
Dorsal talonavicular ligament
Interosseous talonavicular ligament
Bifurcate ligament
Superior fibular retinaculum
Inferior fibular retinaculum is attached to fibular trochlea between fibularis brevis and longus tendons
Lateral talocalcaneal ligament
Fibularis longus tendon
Fibularis brevis tendon
Long plantar ligament
Lateral view
Tibia
Posterior tibiofibular ligament
Posterior tibiotalar part
Tibiocalcaneal part
Tibionavicular part
Anterior tibiotalar part
Medial ligament (deltoid ligament) of the ankle joint
Medial malleolus
Dorsal talonavicular ligament
Medial tubercle of talus
Posterior talocalcaneal ligament
Medial talocalcaneal ligament
Calcaneus
Tuberosity of navicular
Plantar calcaneonavicular ligament
Sustentaculum tali
Medial view

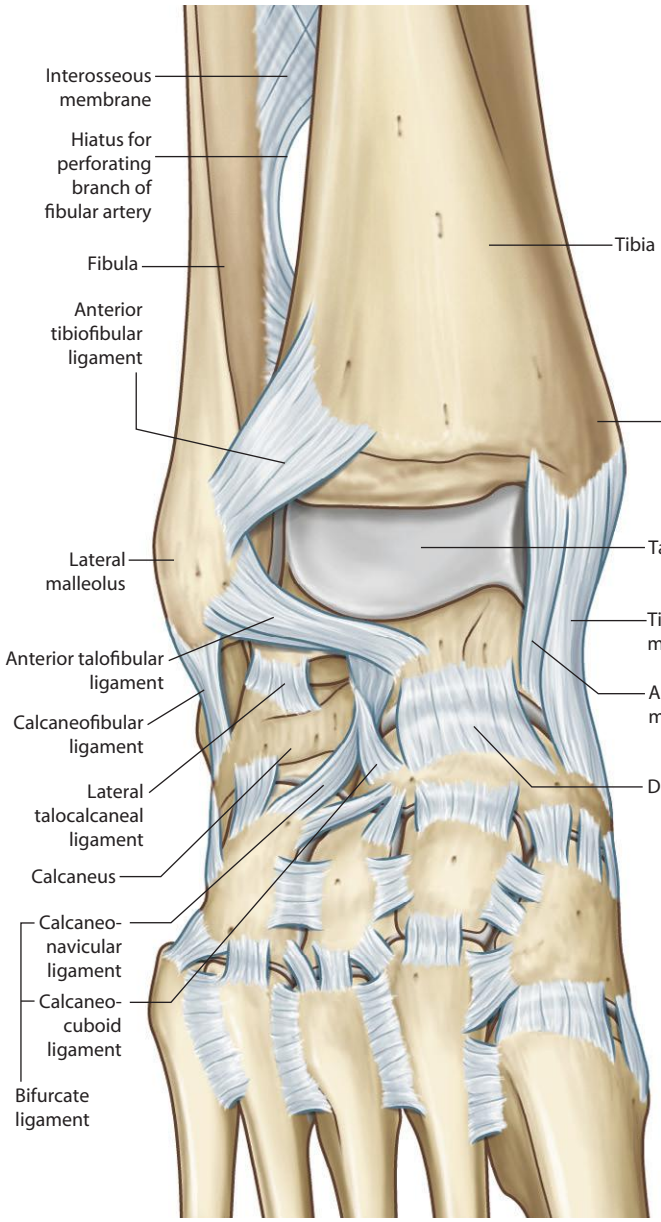

Anterior view

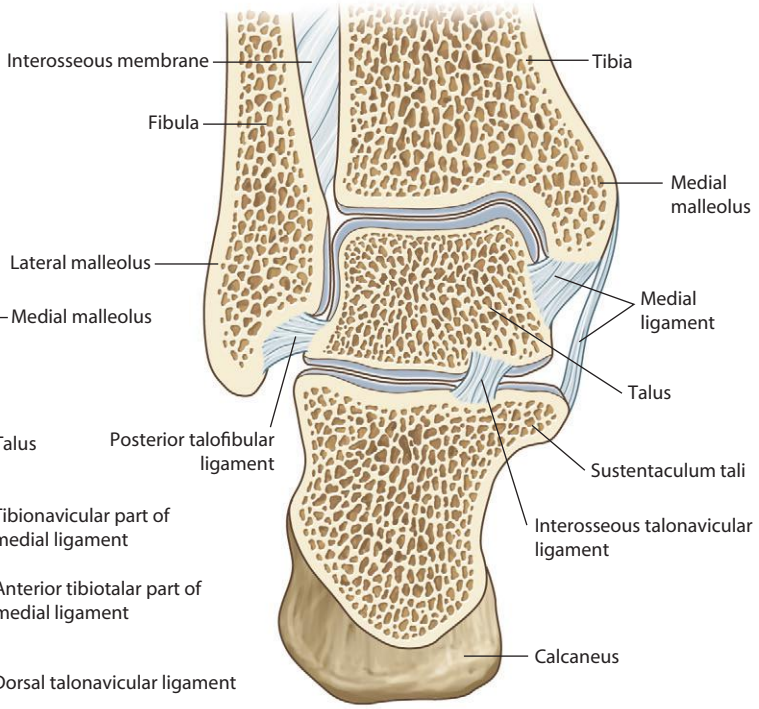

Coronal section through ankle joint (anterior view)

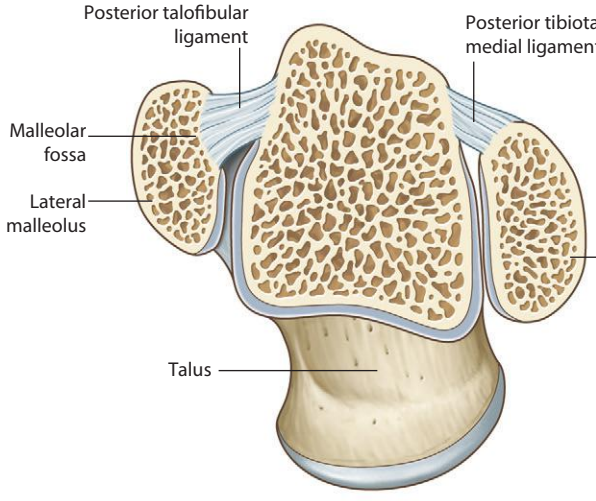

Transverse section through ankle joint (superior view)

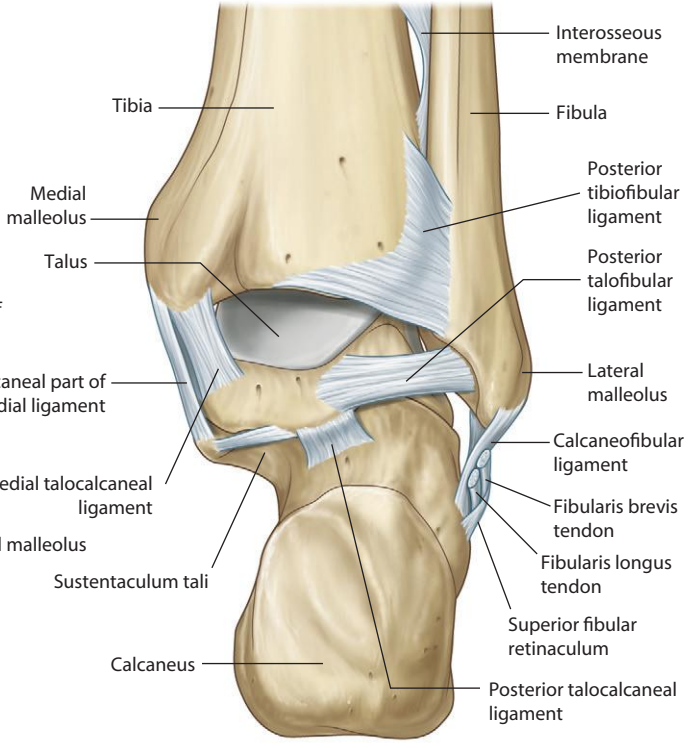

Posterior view

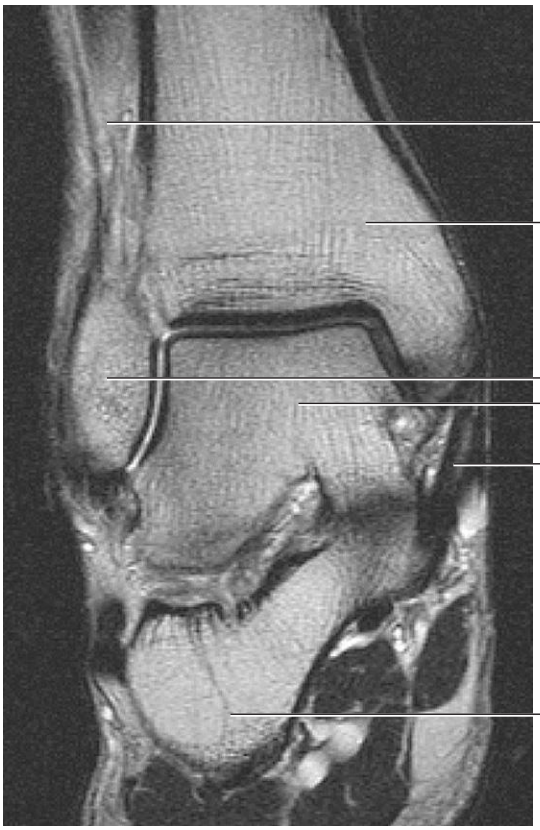

Coronal view of the ankle joint showing the medial ligament of the ankle joint (deltoid ligament).
T2-weighted MR image in coronal plane

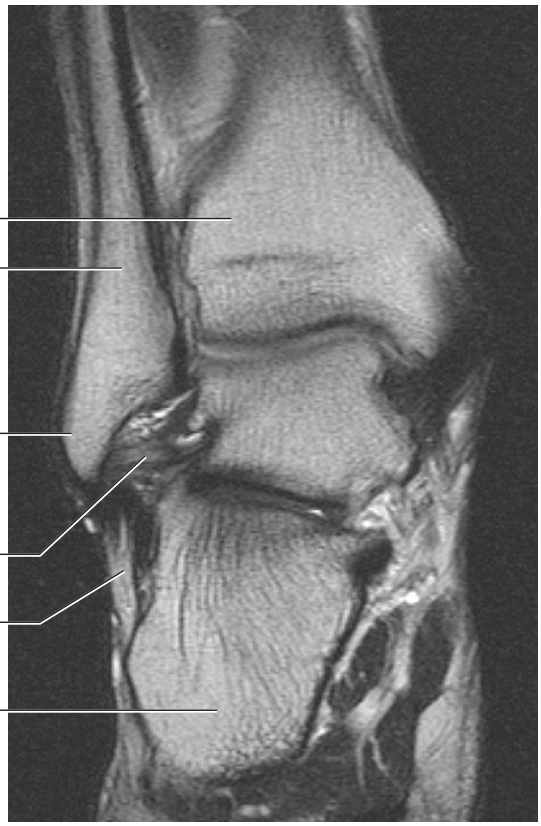

Coronal view of the ankle joint showing the posterior talofibular and calcaneofibular ligaments.
T2-weighted MR image in coronal plane

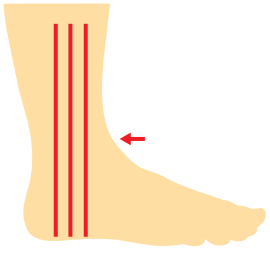

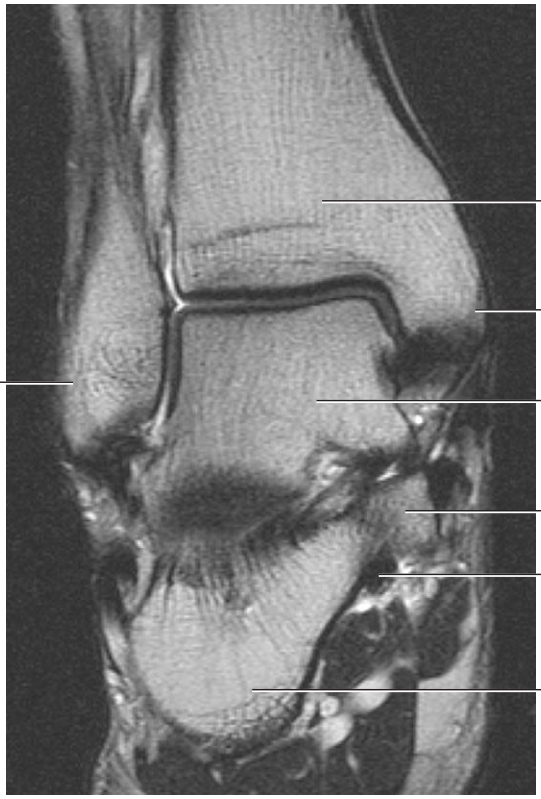

Coronal view of the ankle joint showing the flexor hallucis longus passing inferior to the sustentaculum tali.
T2-weighted MR image in coronal plane

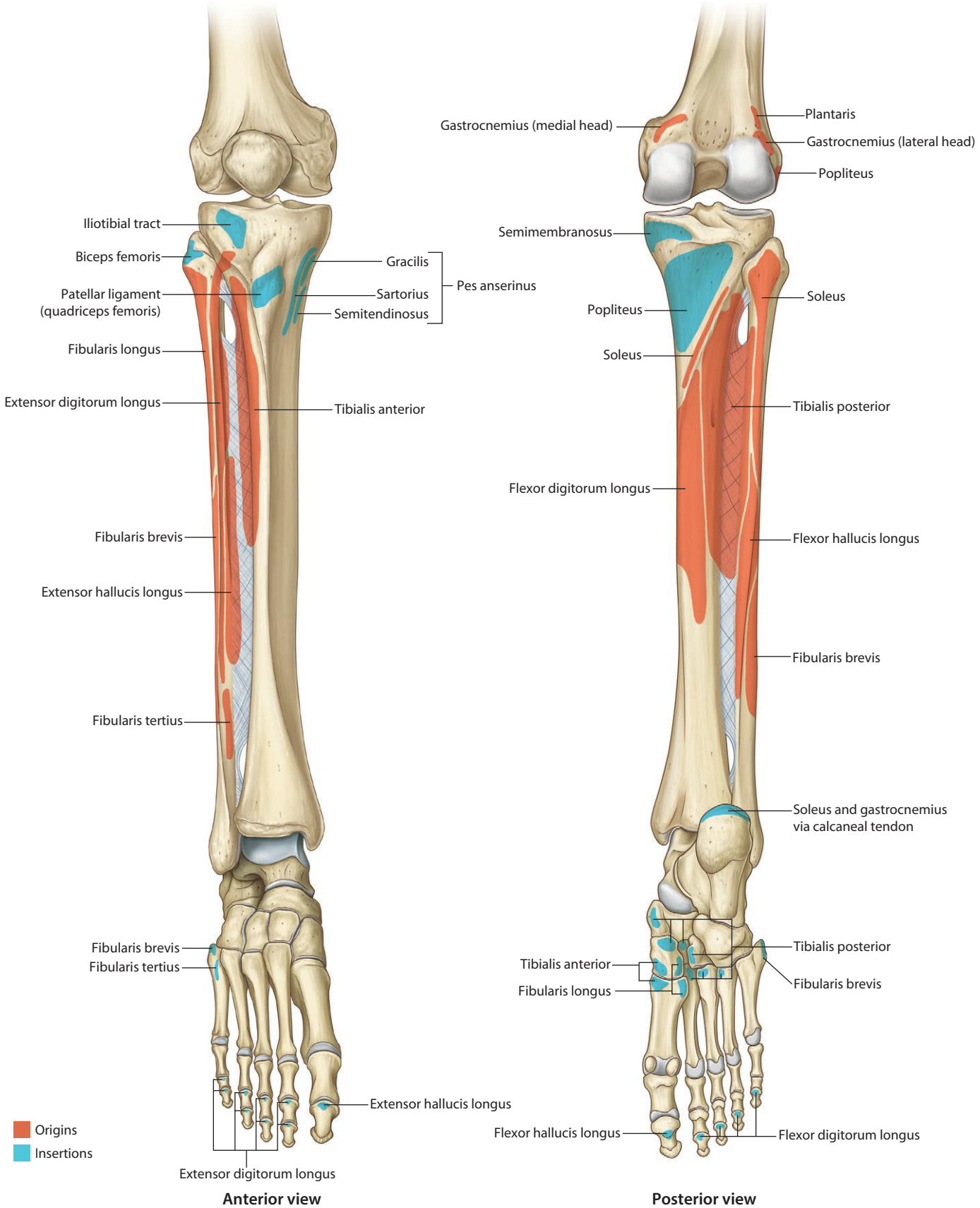
Iliotibial tract
Biceps femoris
Patellar ligament (quadriceps femoris)
Fibularis longus
Extensor digitorum longus
Fibularis brevis
Extensor hallucis longus
Fibularis tertius
Fibularis brevis
Fibularis tertius
Extensor hallucis longus
Extensor digitorum longus
Gracilis
Sartorius
Semitendinosus
Pes anserinus
Tibialis anterior
Origins
Insertions
Anterior view
Gastrocnemius (medial head)
Plantaris
Gastrocnemius (lateral head)
Popliteus
Semimembranosus
Popliteus
Soleus
Soleus
Tibialis posterior
Flexor digitorum longus
Flexor hallucis longus
Fibularis brevis
Soleus and gastrocnemius via calcaneal tendon
Tibialis anterior
Fibularis longus
Tibialis posterior
Fibularis brevis
Flexor hallucis longus
Flexor digitorum longus
Posterior view

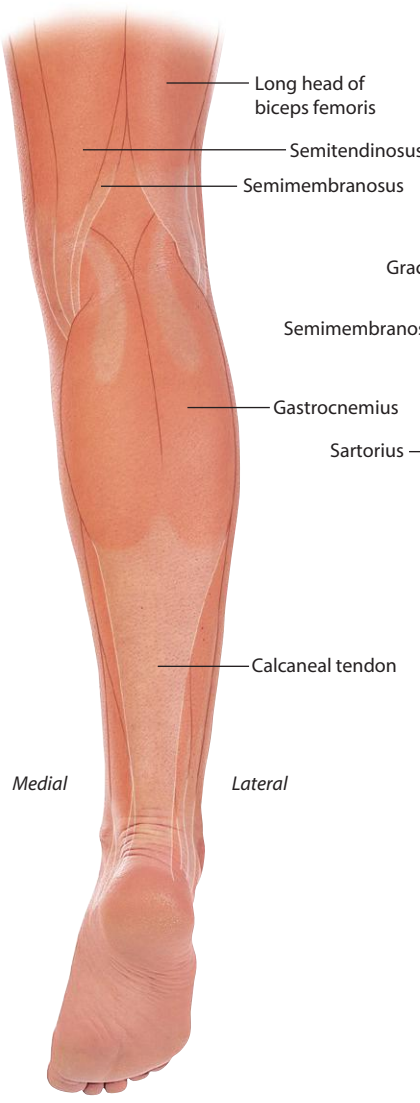

Surface anatomy of leg with overlay of muscles (posterior view)

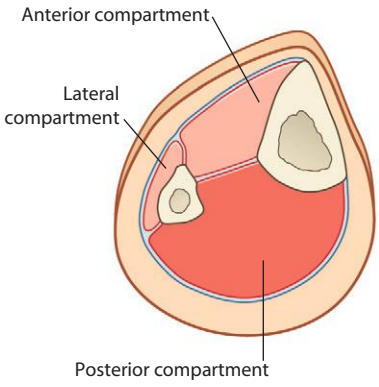

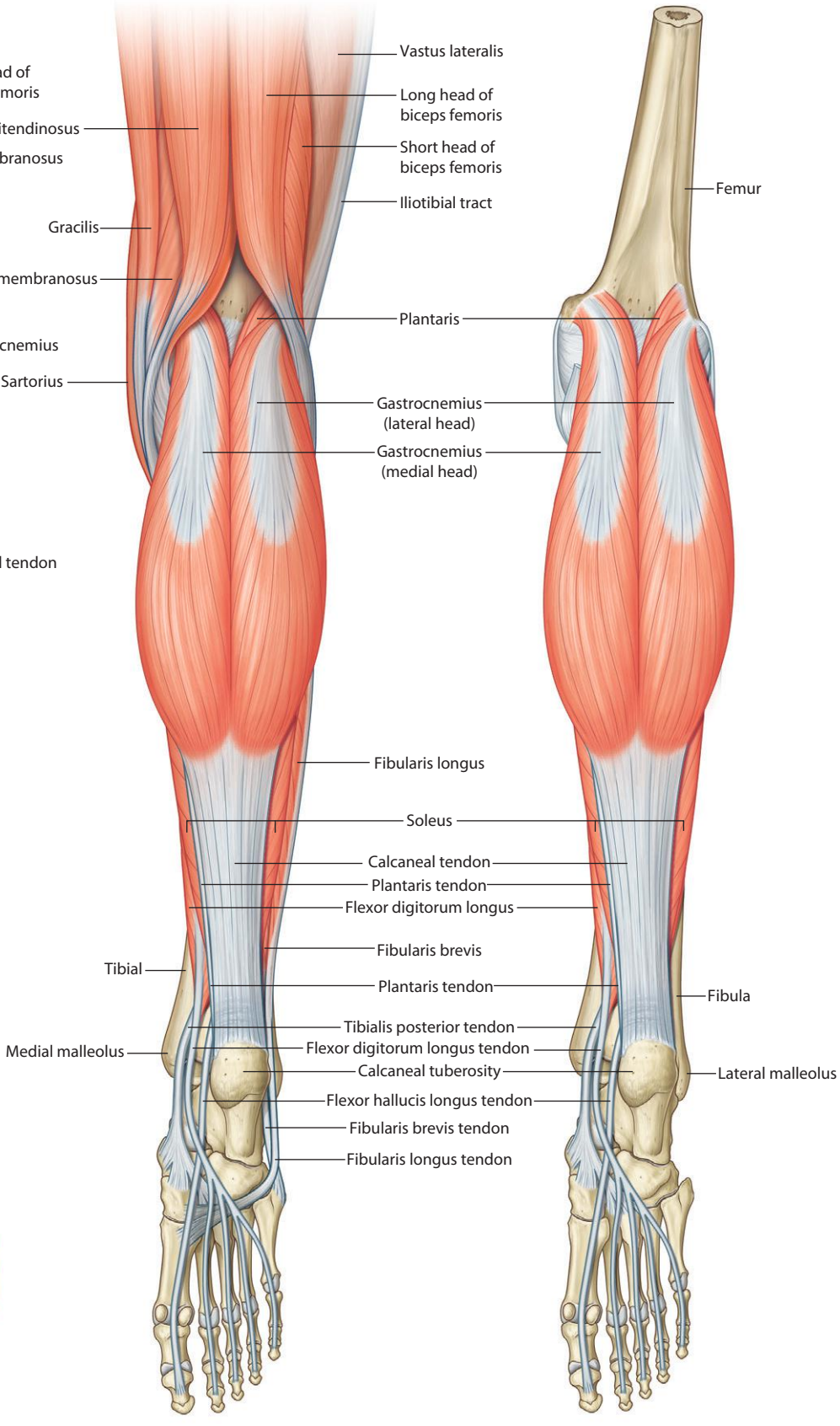

Superficial muscles of leg (posterior view)

Superficial muscles of the posterior compartment of leg

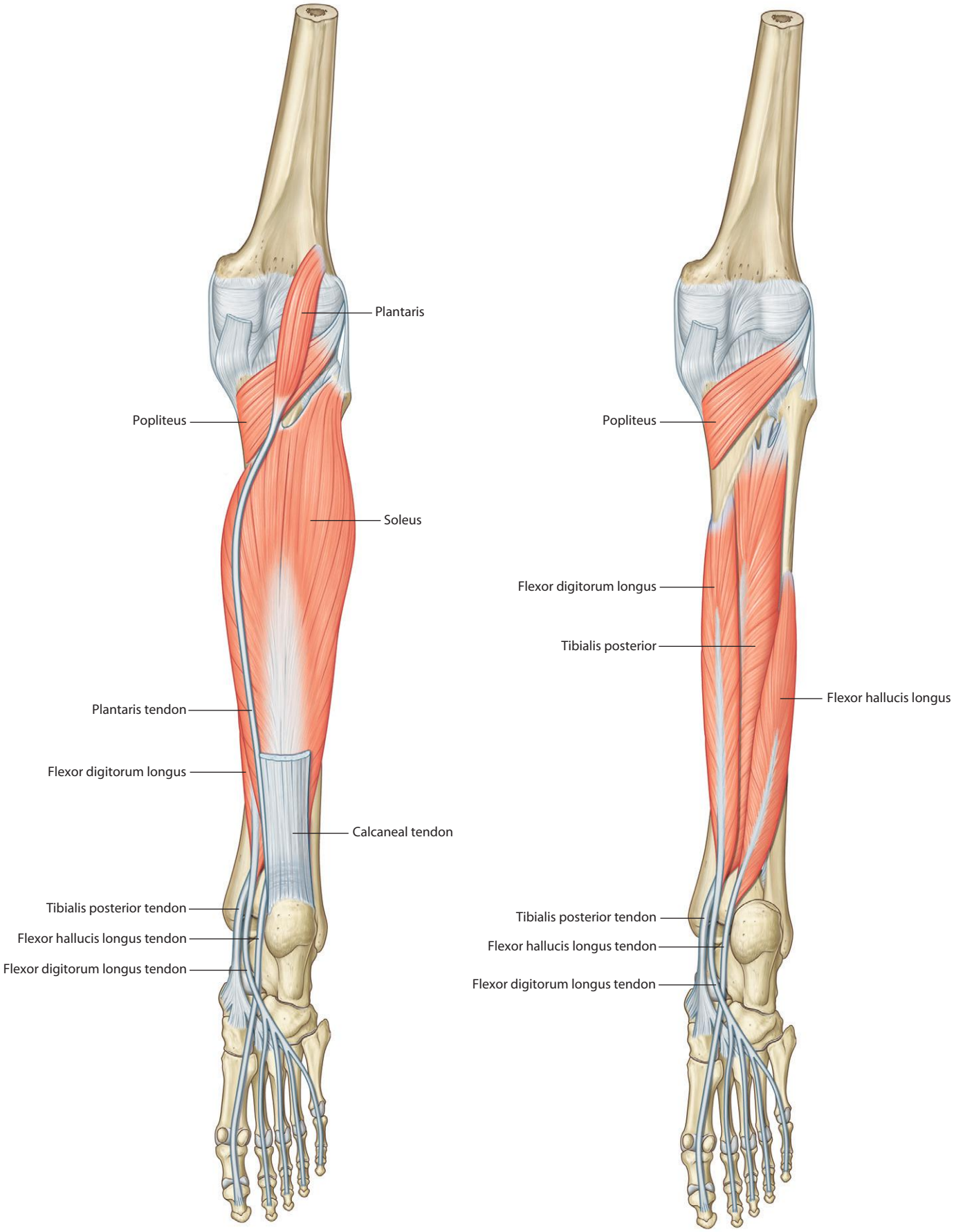

Deep muscles of the posterior compartment of leg

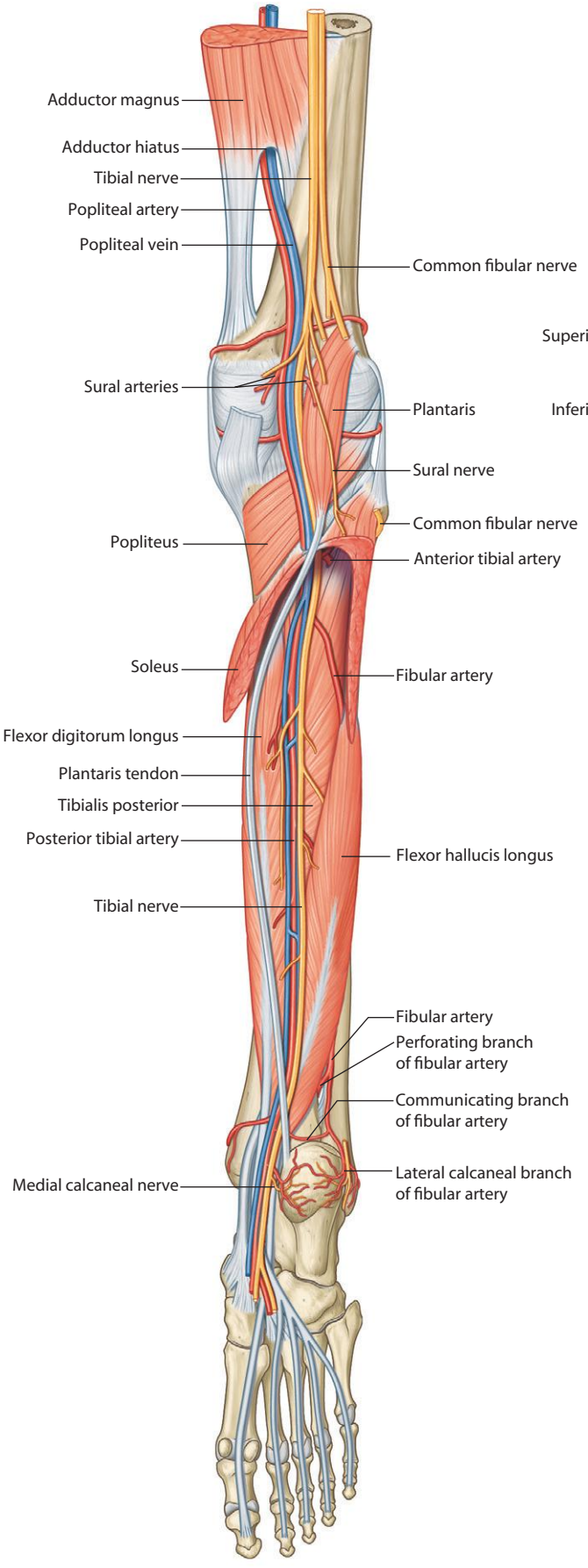

Arteries and nerves of leg (posterior view)

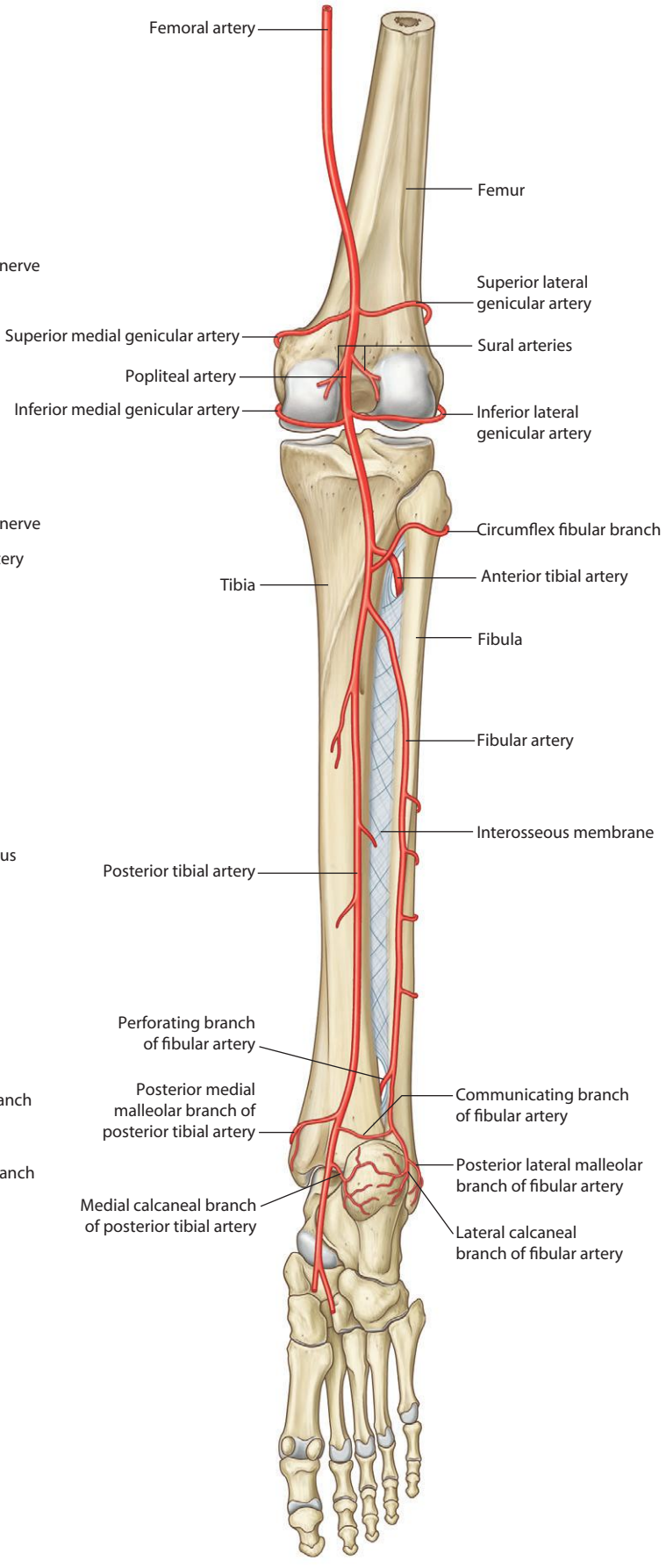

Arteries of leg (posterior view)

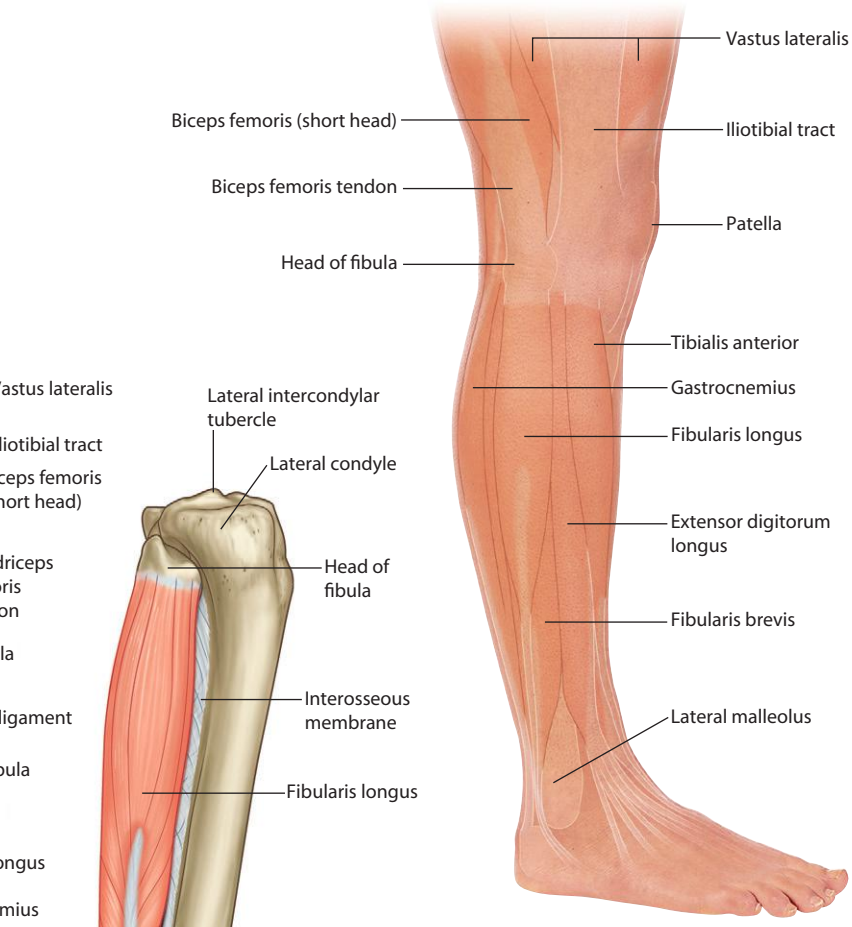

Surface anatomy of leg with overlay of muscles (lateral view)

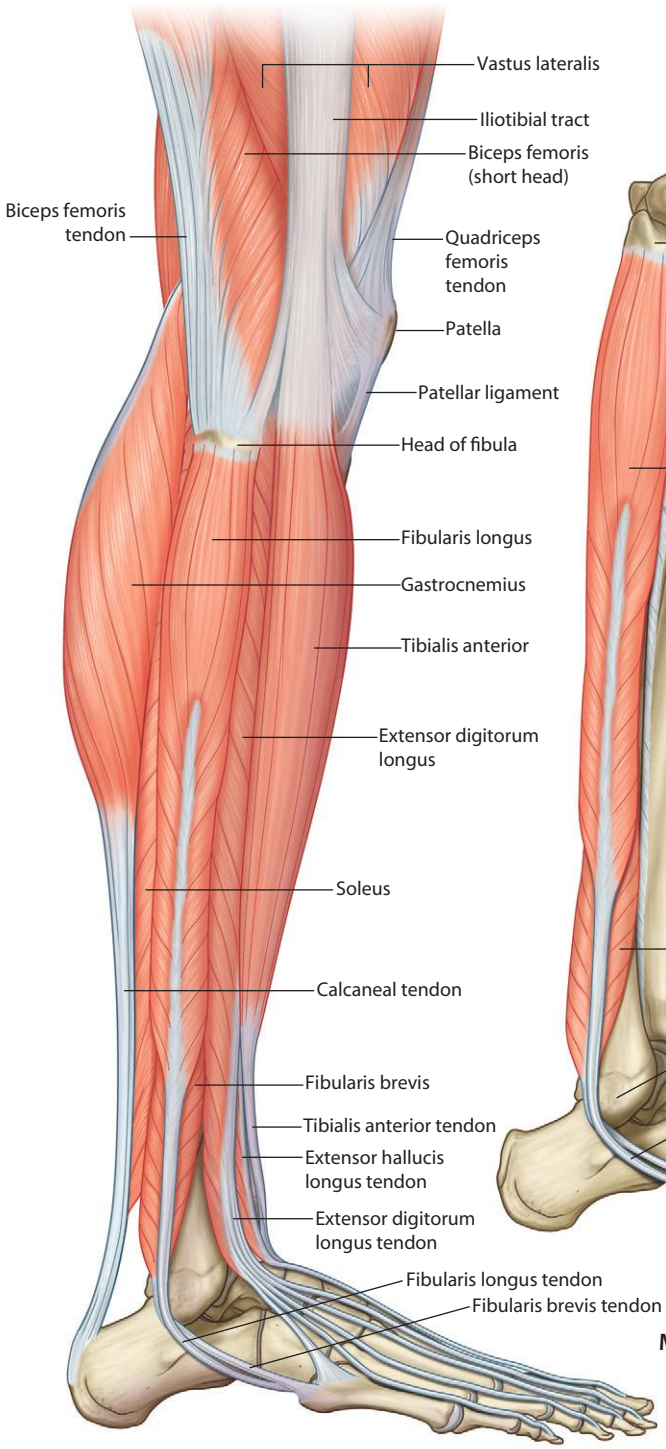

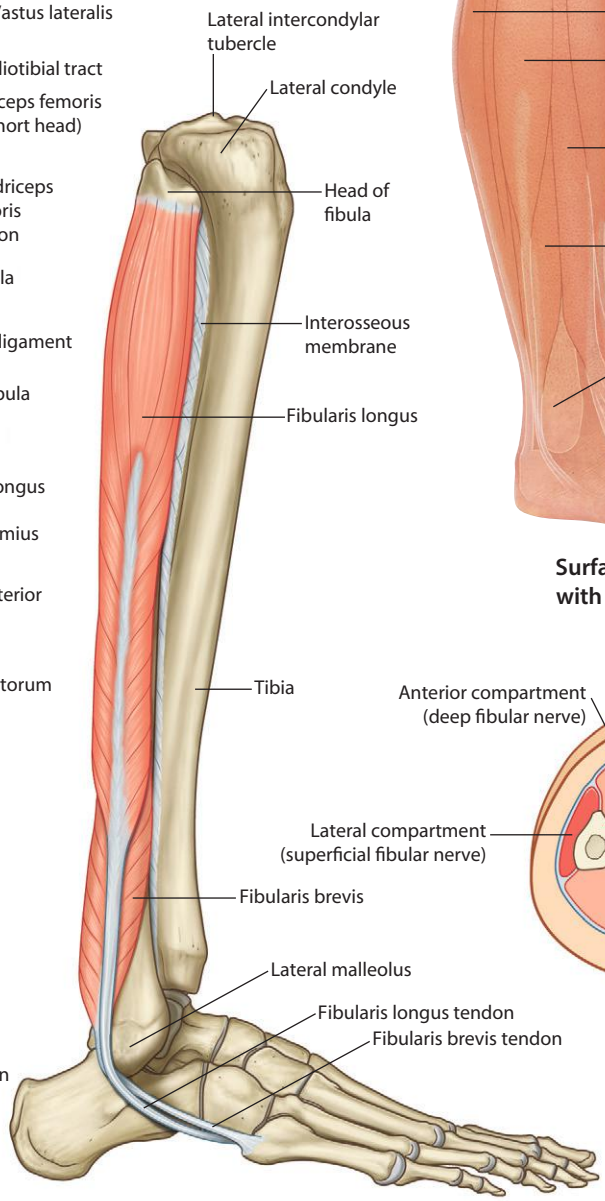

Muscles of the lateral compartment of leg (lateral view)

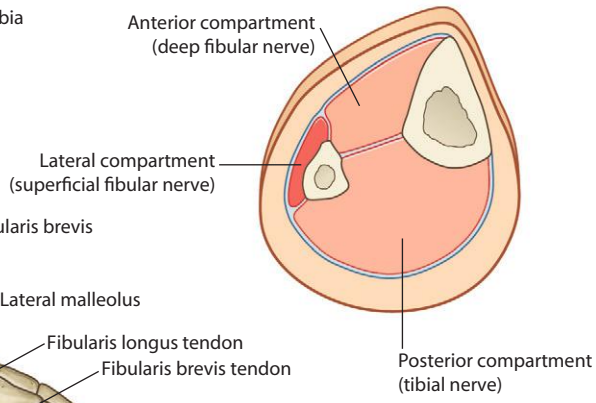

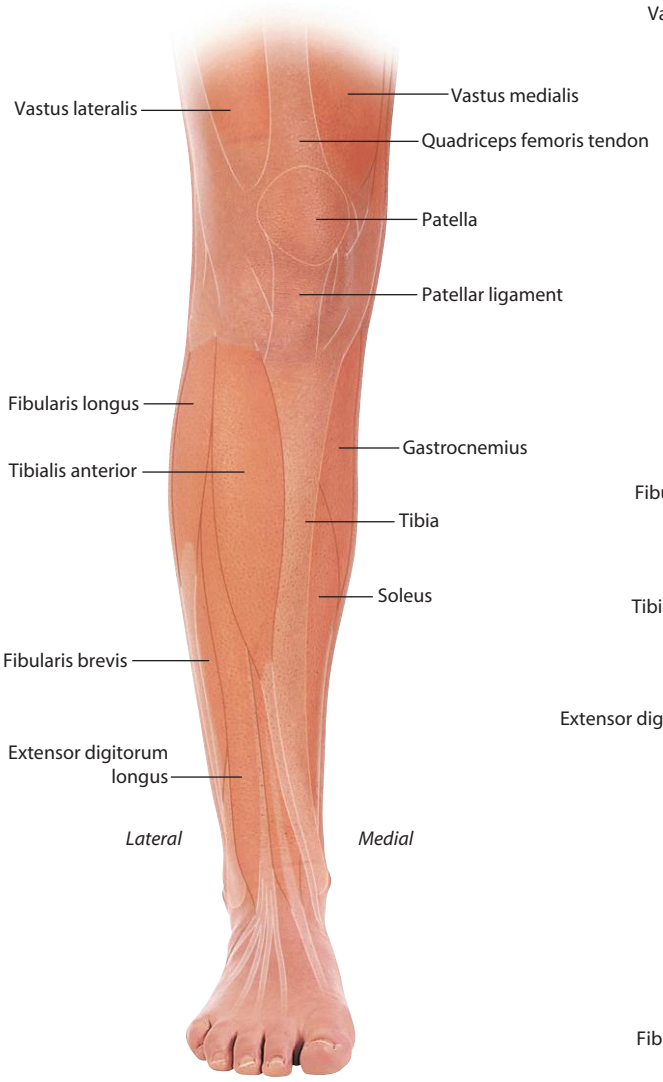

Surface anatomy of leg with overlay of muscles (anterior view)

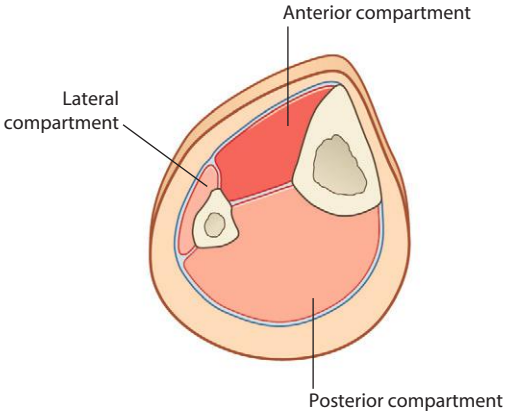

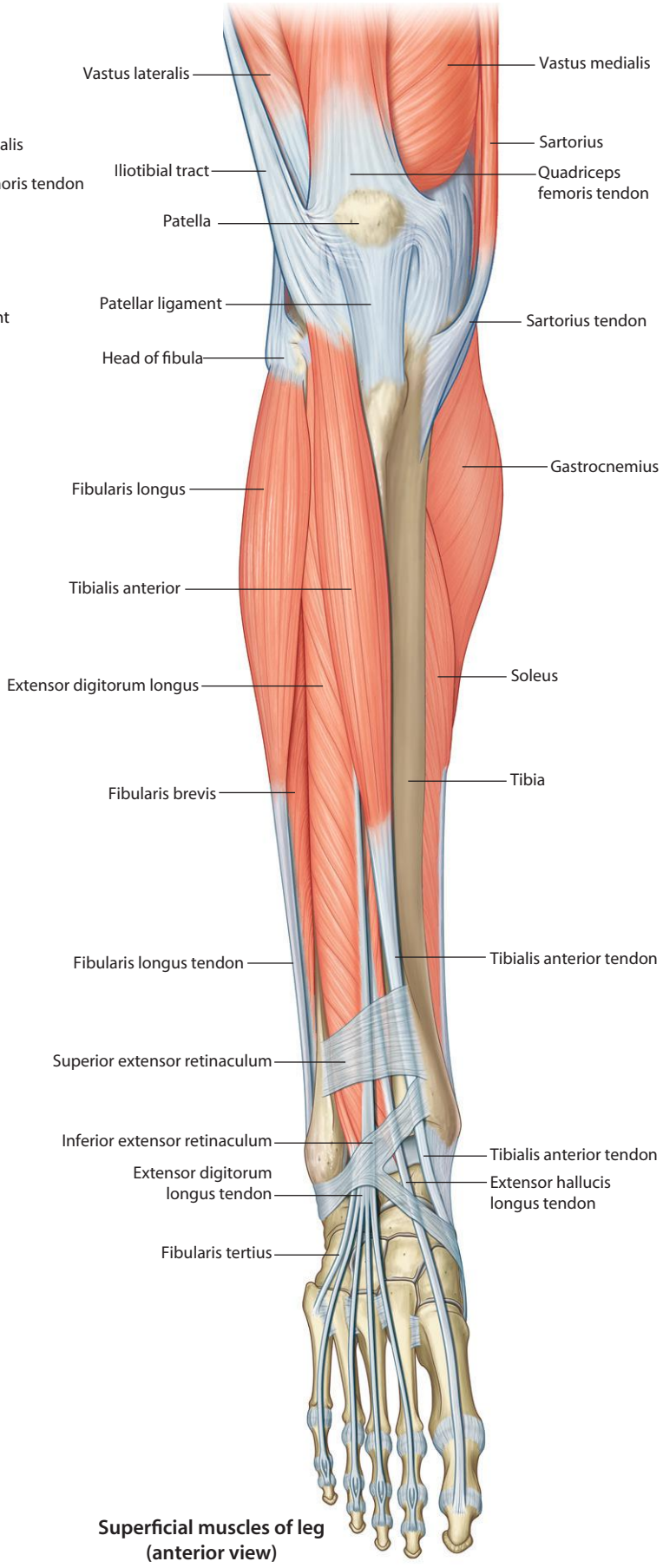

Superficial muscles of leg (anterior view)

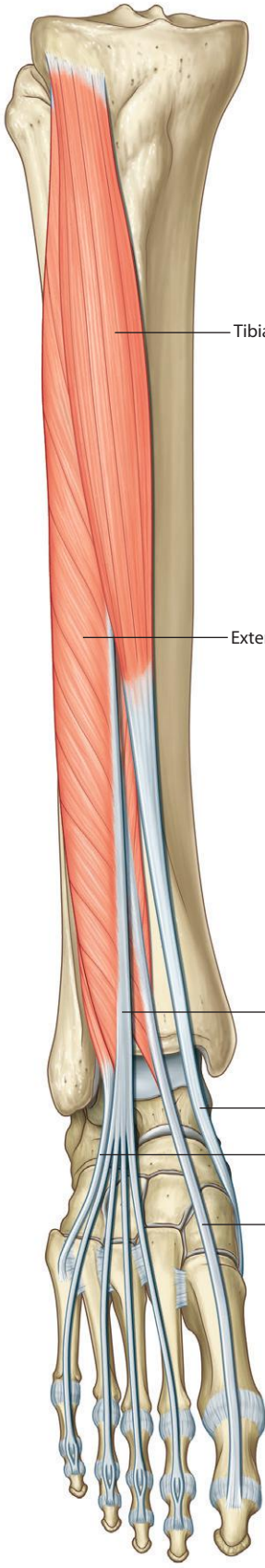

Superficial muscles of the anterior compartment of leg

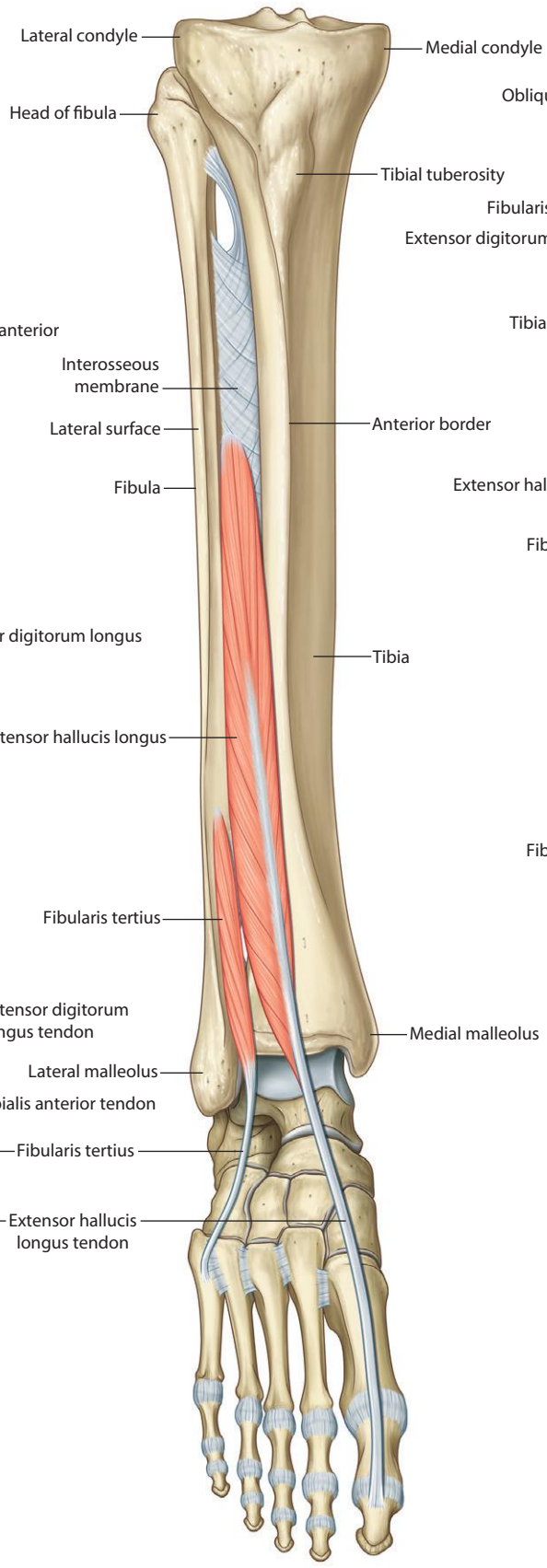

Deep muscles of the anterior compartment of leg

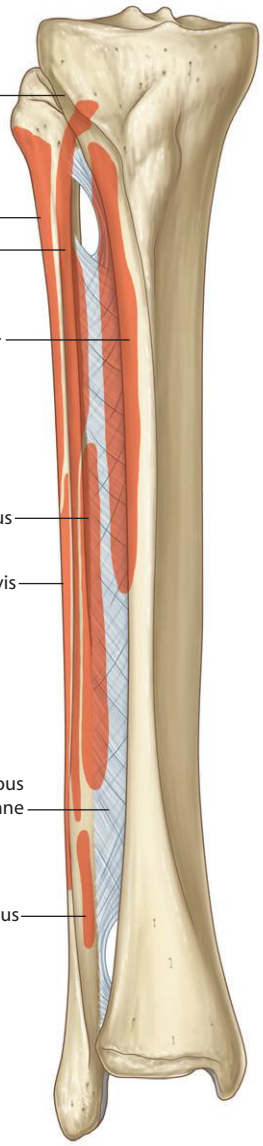

Muscle attachments of the anterior compartment of leg

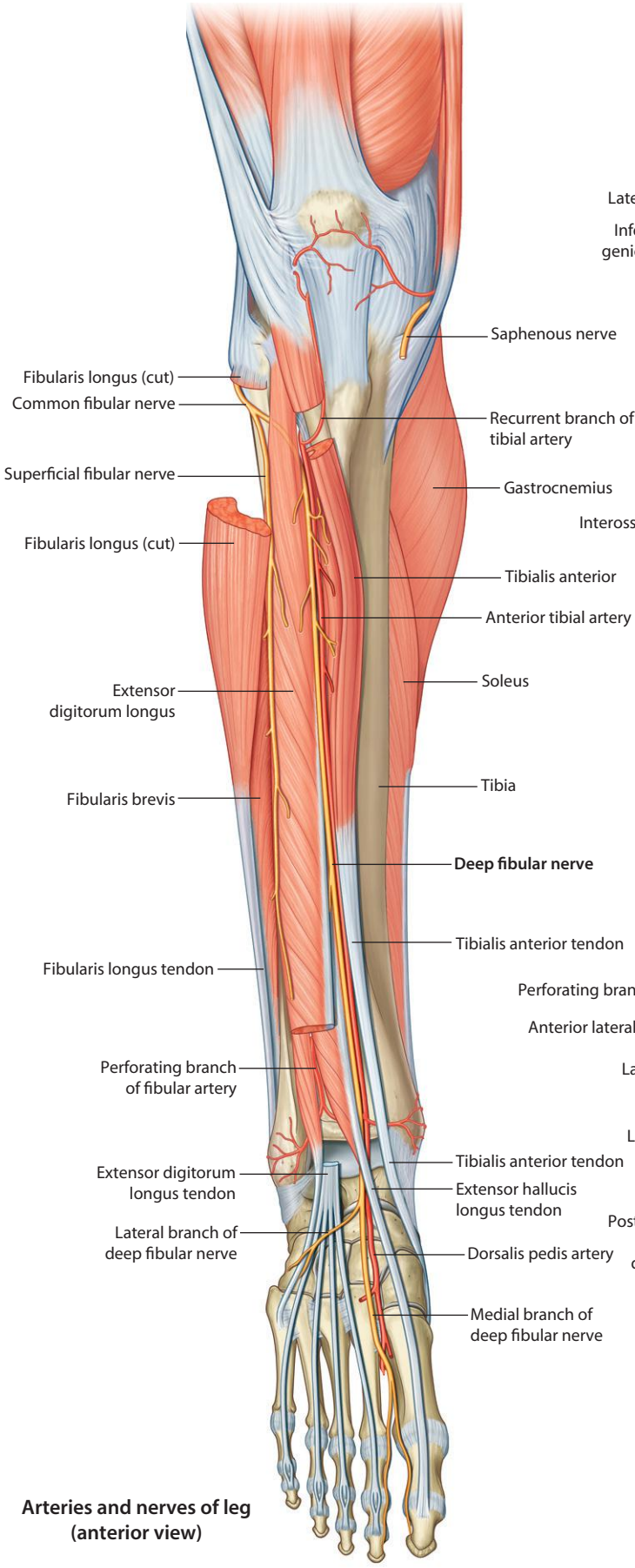

Arteries and nerves of leg (anterior view)

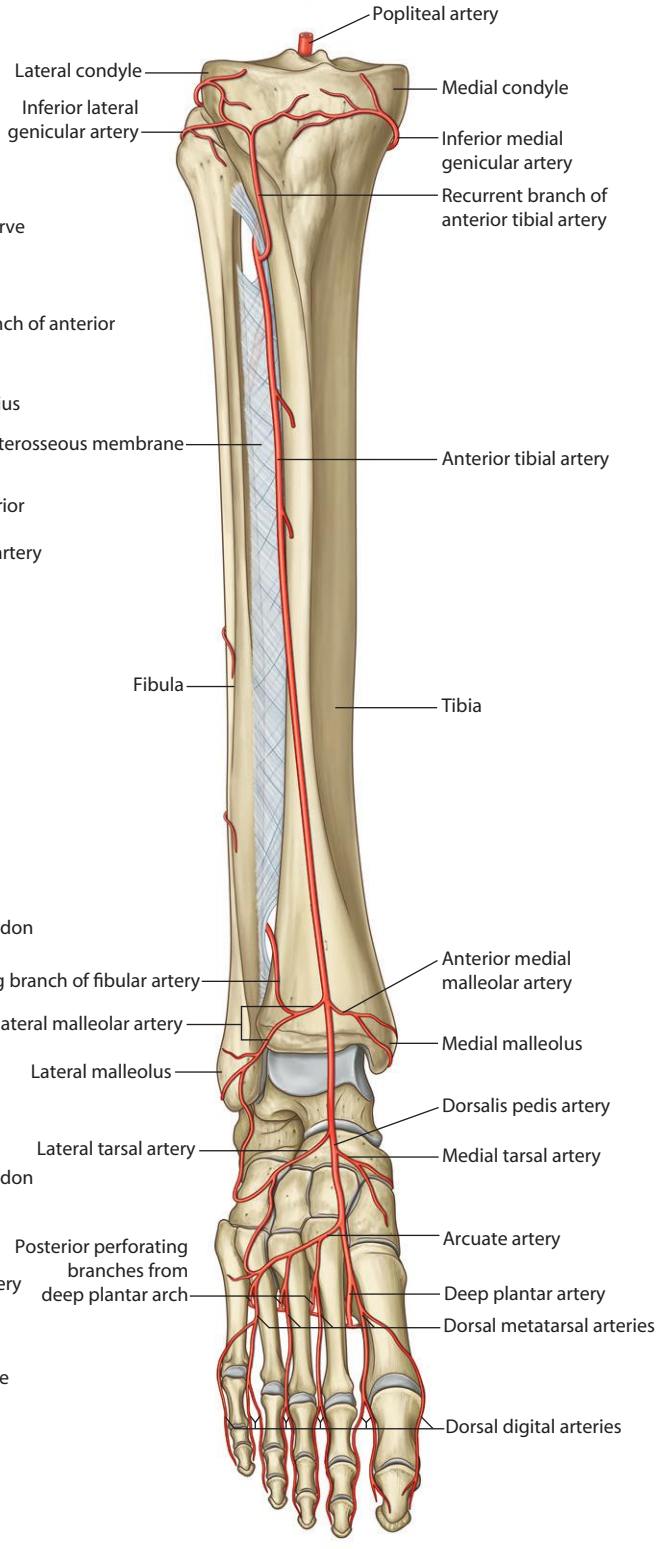

Arteries of leg (anterior view)

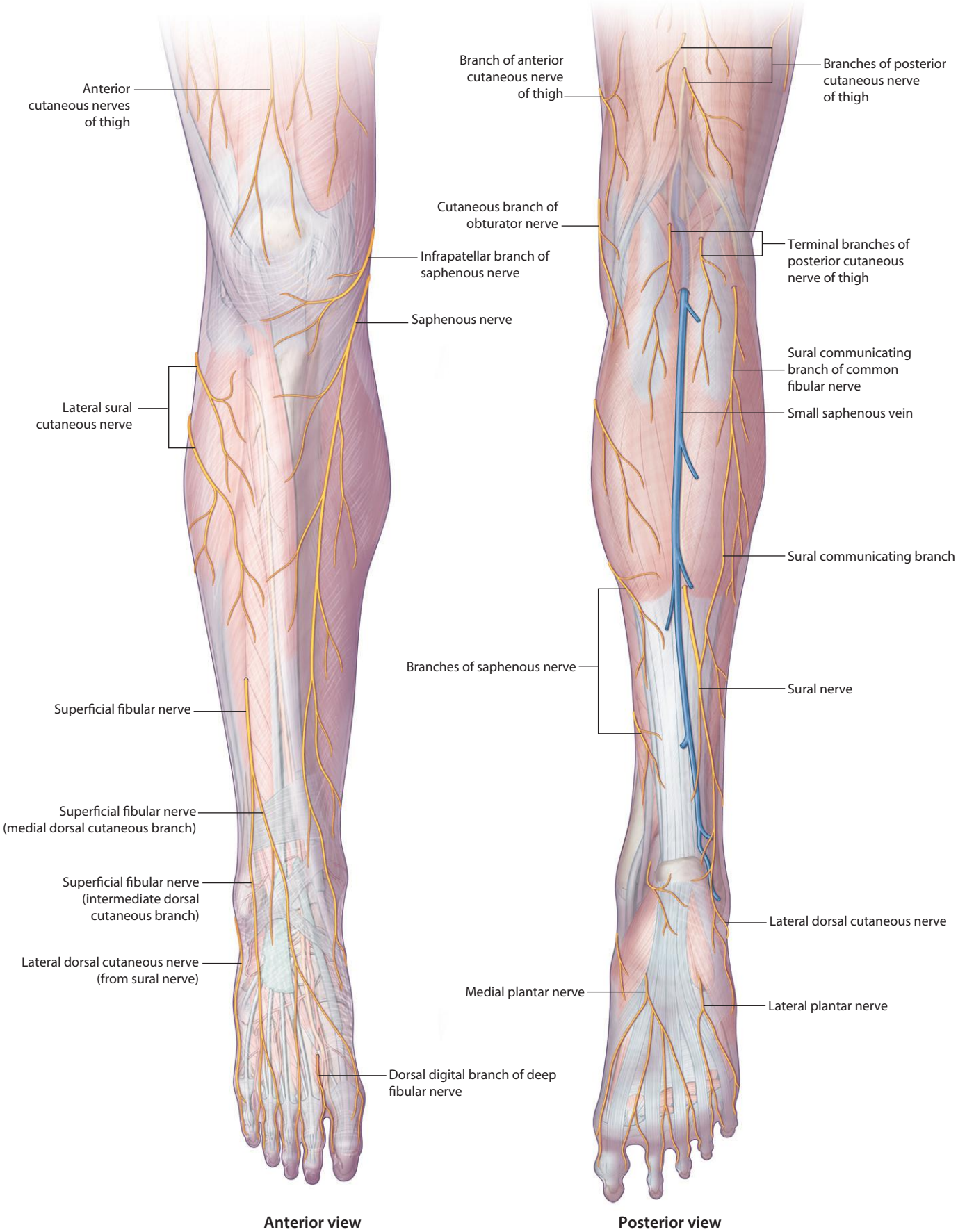
Anterior cutaneous nerves of thigh
Infrapatellar branch of saphenous nerve
Saphenous nerve
Lateral sural cutaneous nerve
Superficial fibular nerve
Superficial fibular nerve (medial dorsal cutaneous branch)
Superficial fibular nerve (intermediate dorsal cutaneous branch)
Lateral dorsal cutaneous nerve (from sural nerve)
Dorsal digital branch of deep fibular nerve
Anterior view
Branch of anterior cutaneous nerve of thigh
Branches of posterior cutaneous nerve of thigh
Cutaneous branch of obturator nerve
Terminal branches of posterior cutaneous nerve of thigh
Sural communicating branch of common fibular nerve
Small saphenous vein
Sural communicating branch
Branches of saphenous nerve
Sural nerve
Lateral dorsal cutaneous nerve
Medial plantar nerve
Lateral plantar nerve
Posterior view

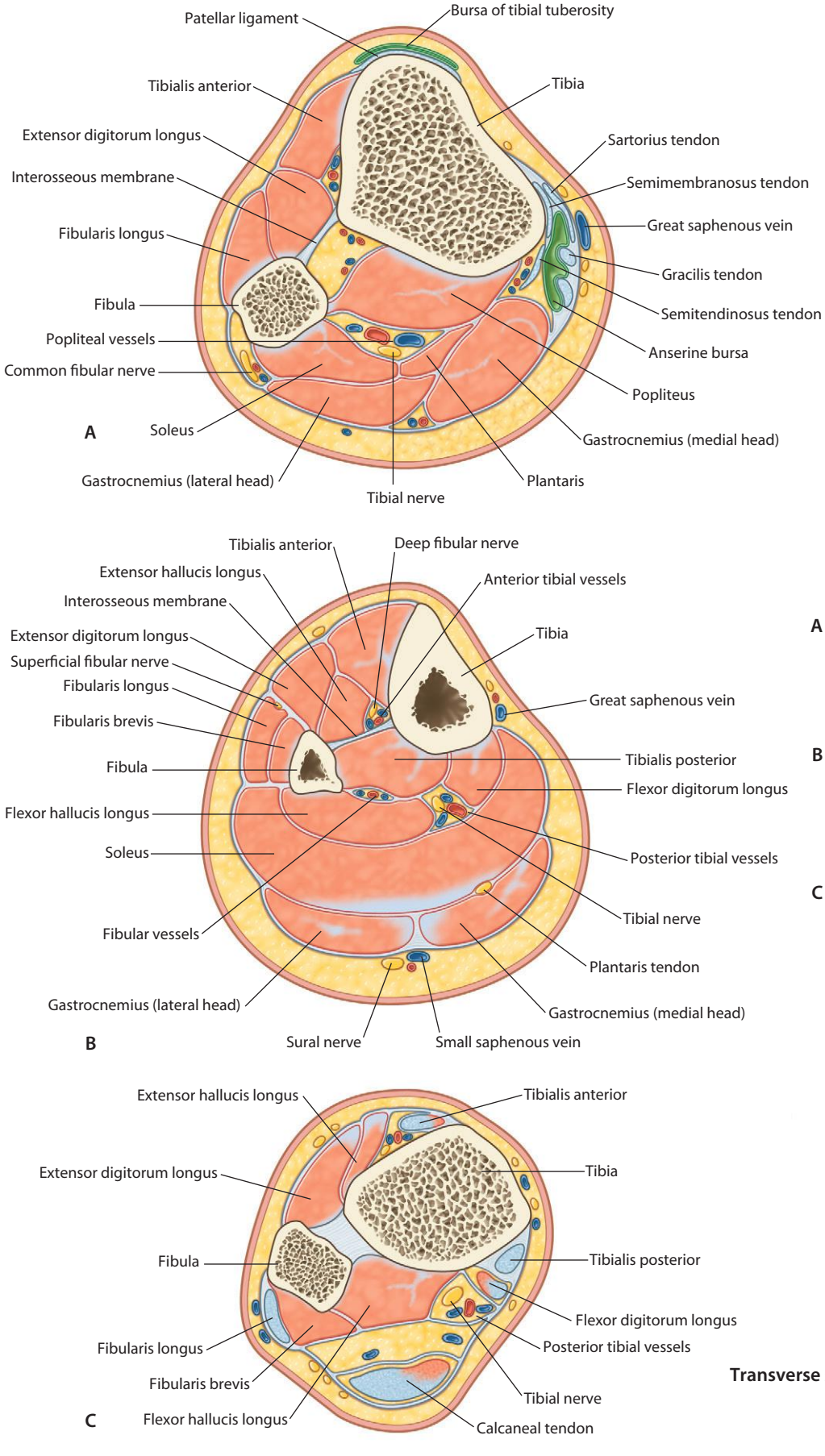

Transverse sections through leg

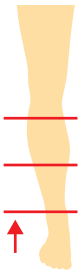

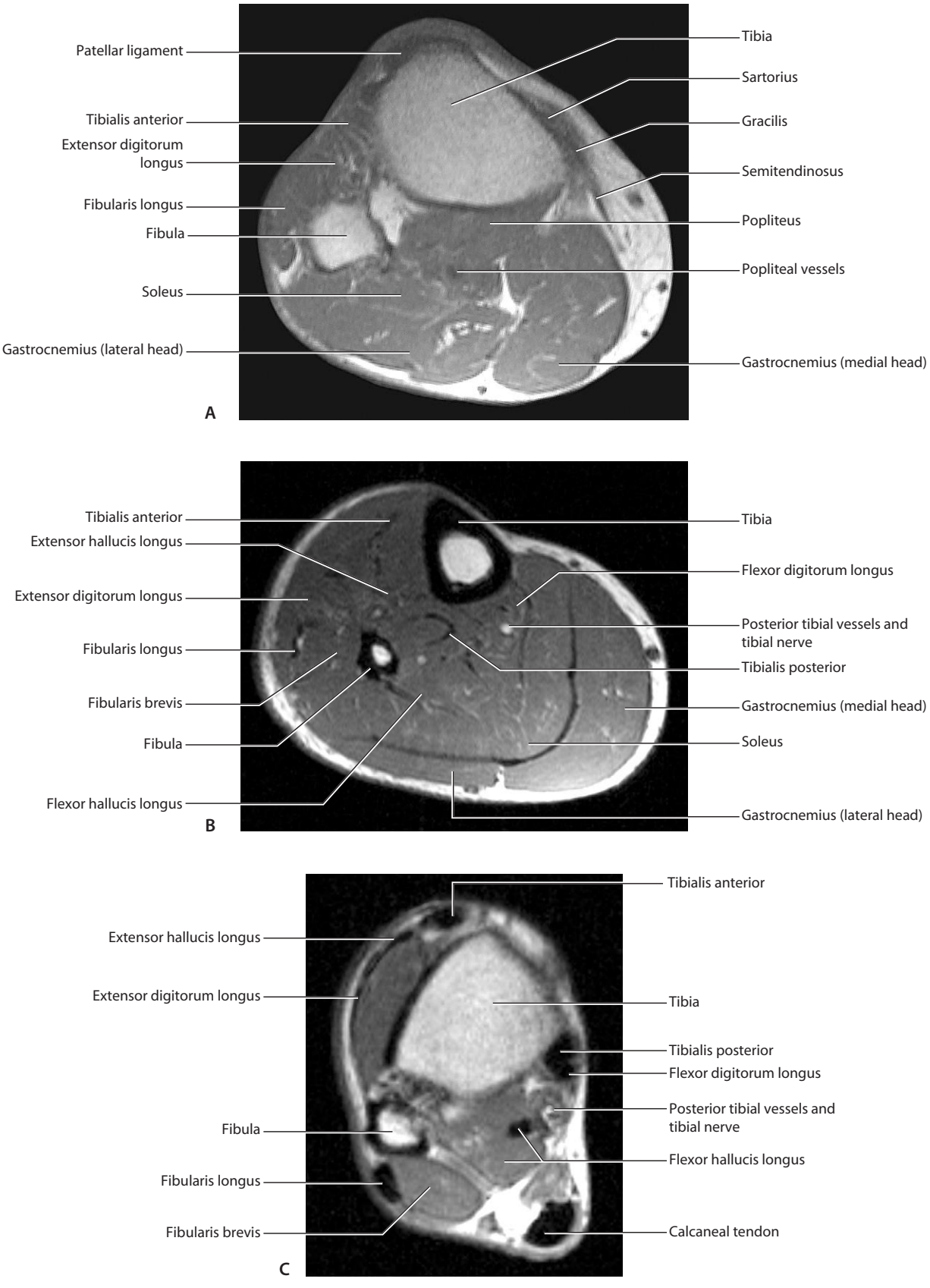

Transverse/axial sections through the leg.

A. Proximal/upper leg. T1-weighted MR image in axial plane
B. Middle leg. T1-weighted MR image in axial plane
C. Distal/lower leg. T1-weighted MR image in axial plane

Muscle attachments of the foot

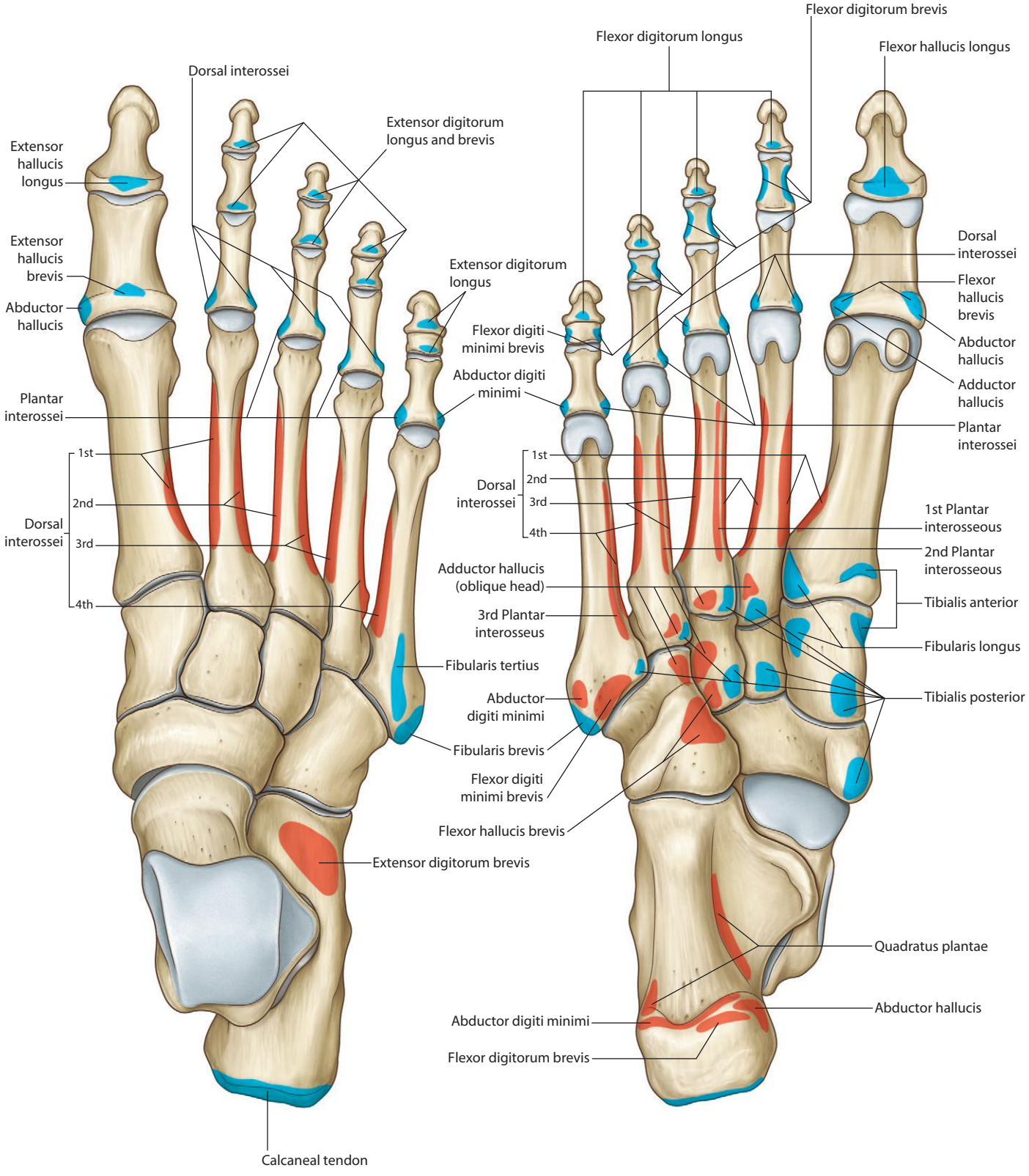

Origins
Insertions

Dorsal view **Plantar view**

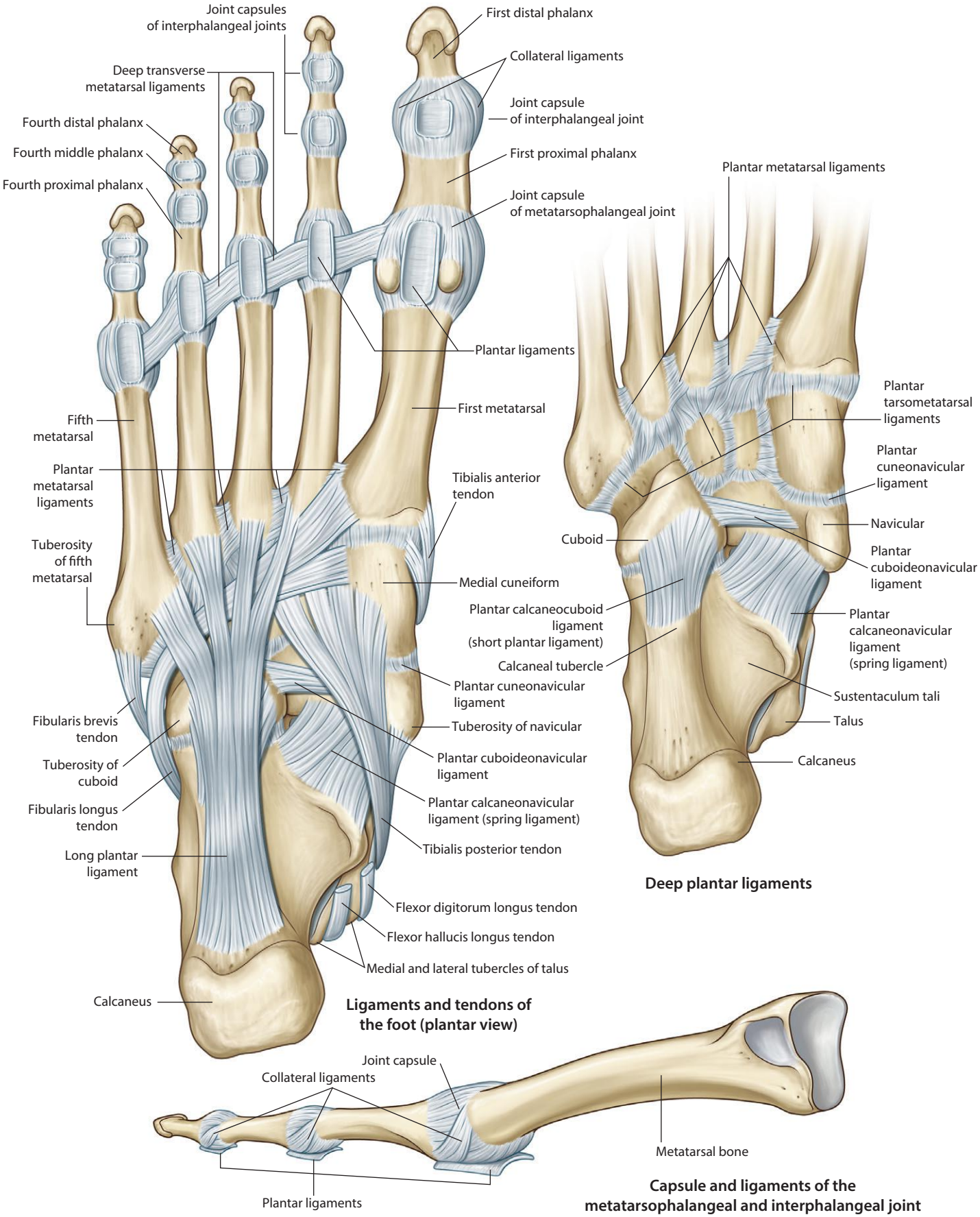
Joint capsules of interphalangeal joints
Deep transverse metatarsal ligaments
Fourth distal phalanx
Fourth middle phalanx
Fourth proximal phalanx
First distal phalanx
Collateral ligaments
Joint capsule of interphalangeal joint
First proximal phalanx
Joint capsule of metatarsophalangeal joint
Plantar ligaments
First metatarsal
Fifth metatarsal
Plantar metatarsal ligaments
Tibialis anterior tendon
Tuberosity of fifth metatarsal
Medial cuneiform
Fibularis brevis tendon
Tuberosity of cuboid
Fibularis longus tendon
Tuberosity of navicular
Plantar cuboideonavicular ligament
Plantar calcaneonavicular ligament (spring ligament)
Long plantar ligament
Tibialis posterior tendon
Flexor digitorum longus tendon
Flexor hallucis longus tendon
Medial and lateral tubercles of talus
Calcaneus
Ligaments and tendons of the foot (plantar view)
Plantar metatarsal ligaments
Plantar tarsometatarsal ligaments
Plantar cuneonavicular ligament
Navicular
Cuboid
Plantar cuboideonavicular ligament
Plantar calcaneocuboid ligament (short plantar ligament)
Plantar calcaneonavicular ligament (spring ligament)
Calcaneal tubercle
Sustentaculum tali
Talus
Calcaneus
Deep plantar ligaments
Joint capsule
Collateral ligaments
Metatarsal bone
Plantar ligaments
Capsule and ligaments of the metatarsophalangeal and interphalangeal joint

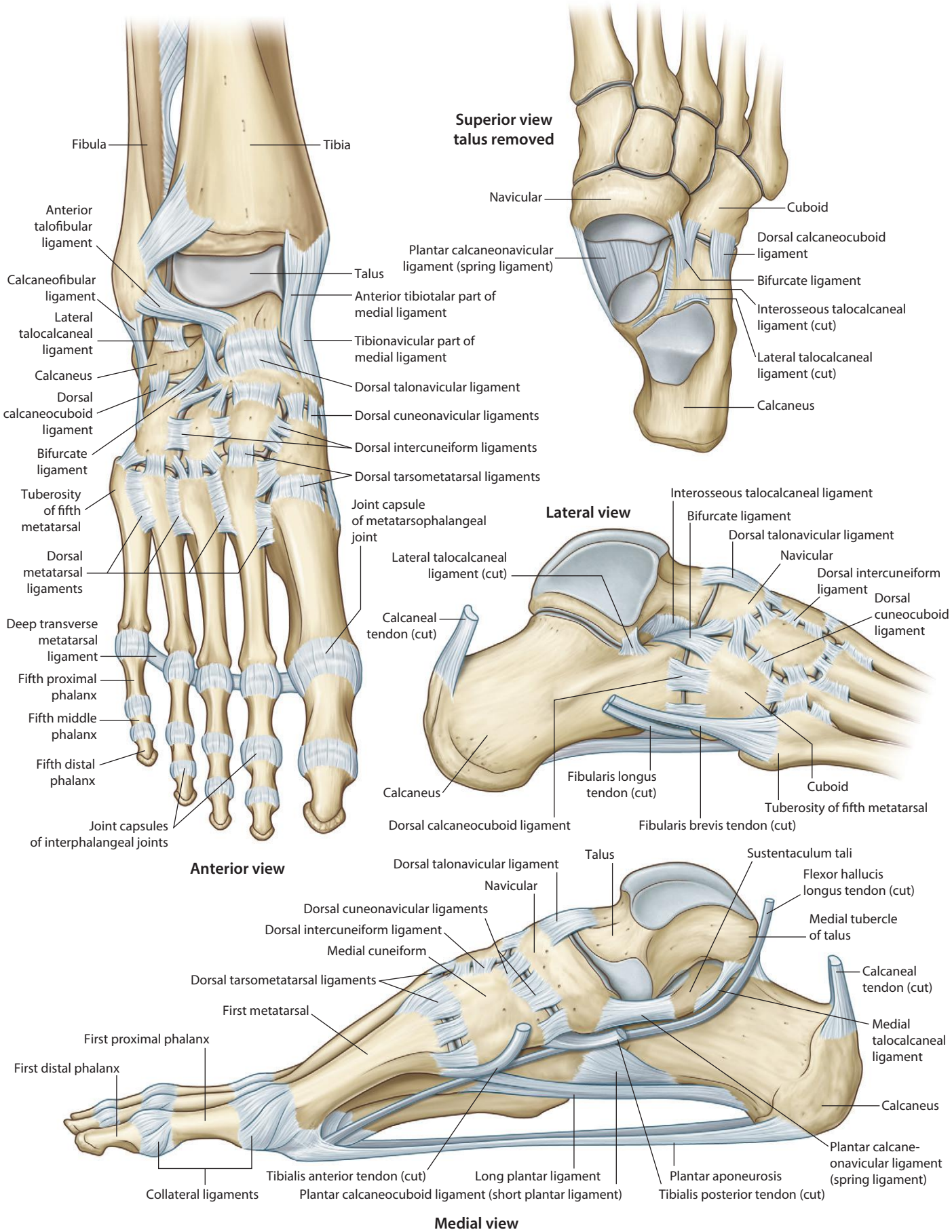
Fibula
Tibia
Anterior talofibular ligament
Calcaneofibular ligament
Lateral talocalcaneal ligament
Calcaneus
Dorsal calcaneocuboid ligament
Bifurcate ligament
Tuberosity of fifth metatarsal
Dorsal metatarsal ligaments
Deep transverse metatarsal ligament
Fifth proximal phalanx
Fifth middle phalanx
Fifth distal phalanx
Joint capsules of interphalangeal joints
Talus
Anterior tibiotalar part of medial ligament
Tibionavicular part of medial ligament
Dorsal talonavicular ligament
Dorsal cuneonavicular ligaments
Dorsal intercuneiform ligaments
Dorsal tarsometatarsal ligaments
Joint capsule of metatarsophalangeal joint
Anterior view
Superior view talus removed
Navicular
Cuboid
Plantar calcaneonavicular ligament (spring ligament)
Dorsal calcaneocuboid ligament
Bifurcate ligament
Interosseous talocalcaneal ligament (cut)
Lateral talocalcaneal ligament (cut)
Calcaneus
Lateral view
Interosseous talocalcaneal ligament
Bifurcate ligament
Dorsal talonavicular ligament
Navicular
Lateral talocalcaneal ligament (cut)
Dorsal intercuneiform ligament
Dorsal cuneocuboid ligament
Calcaneal tendon (cut)
Calcaneus
Fibularis longus tendon (cut)
Cuboid
Tuberosity of fifth metatarsal
Dorsal calcaneocuboid ligament
Fibularis brevis tendon (cut)
Dorsal talonavicular ligament
Talus
Sustentaculum tali
Navicular
Flexor hallucis longus tendon (cut)
Dorsal cuneonavicular ligaments
Medial tubercle of talus
Dorsal intercuneiform ligament
Medial cuneiform
Calcaneal tendon (cut)
Dorsal tarsometatarsal ligaments
First metatarsal
Medial talocalcaneal ligament
First proximal phalanx
First distal phalanx
Calcaneus
Plantar calcaneonavicular ligament (spring ligament)
Tibialis anterior tendon (cut)
Long plantar ligament
Plantar aponeurosis
Collateral ligaments
Plantar calcaneocuboid ligament (short plantar ligament)
Tibialis posterior tendon (cut)
Medial view

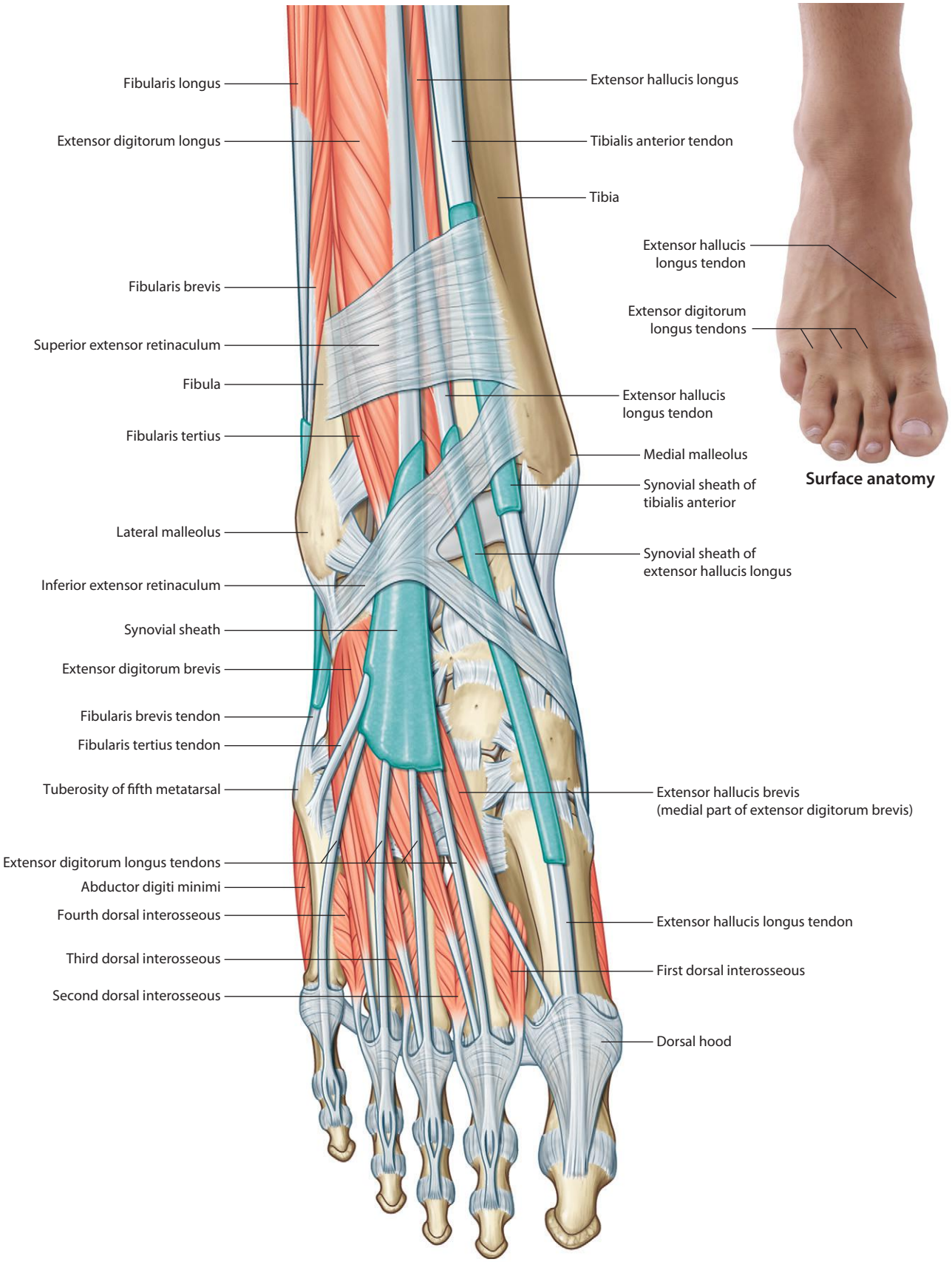

Superficial structures of the foot (dorsal view)

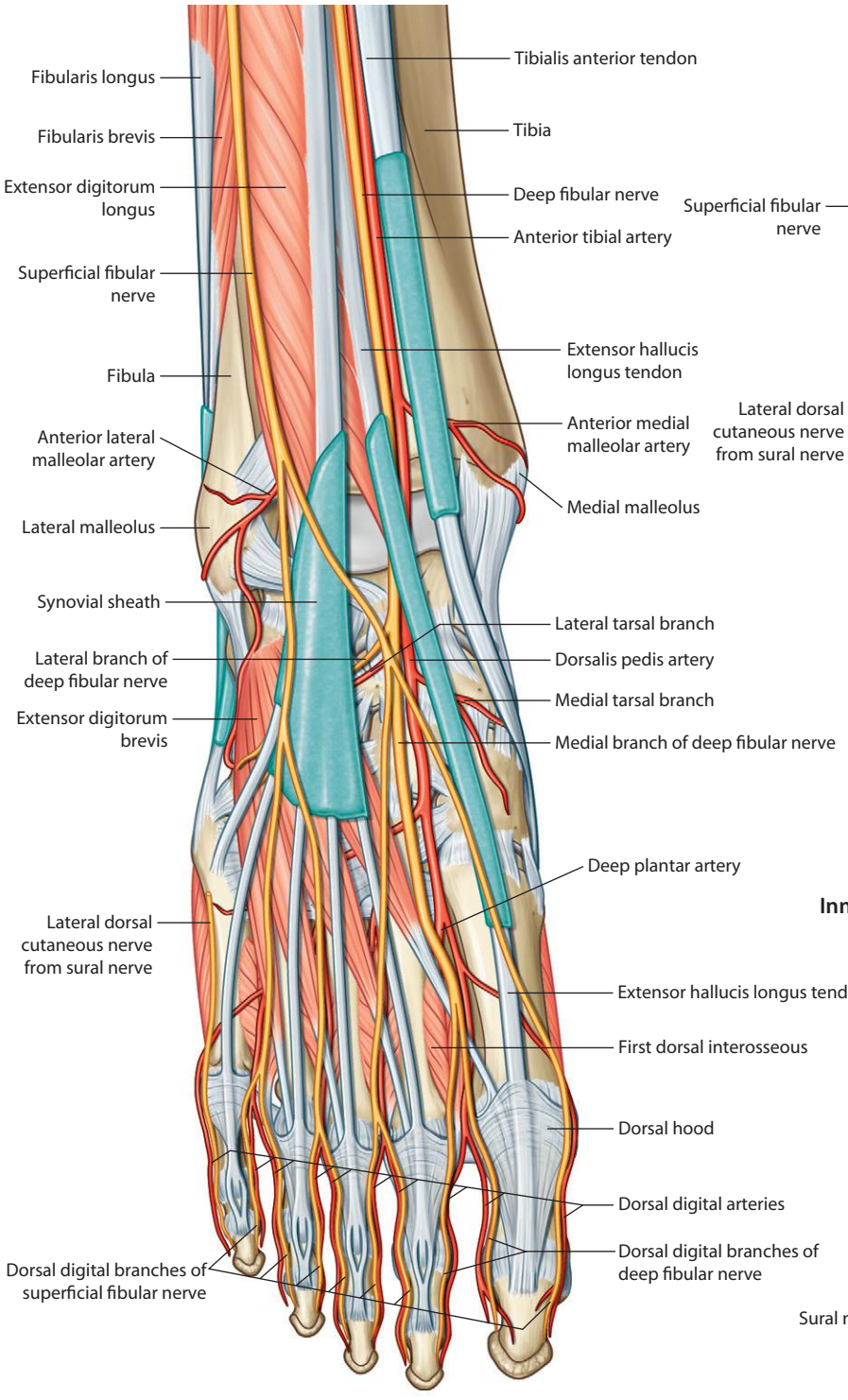

Arteries and nerves of the foot (dorsal view)

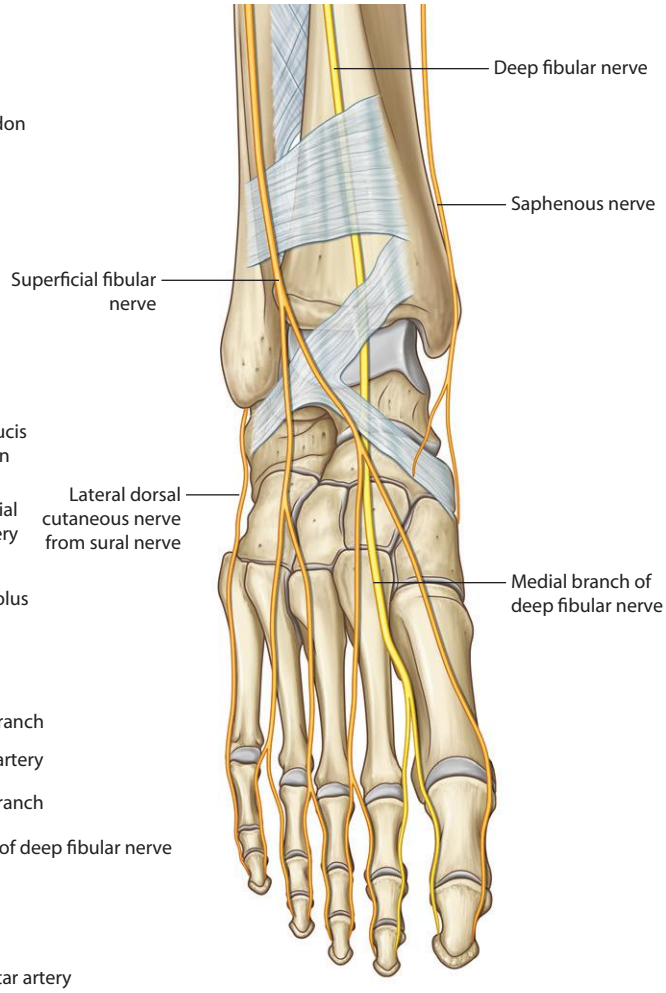

Innervation of the foot (dorsal view)

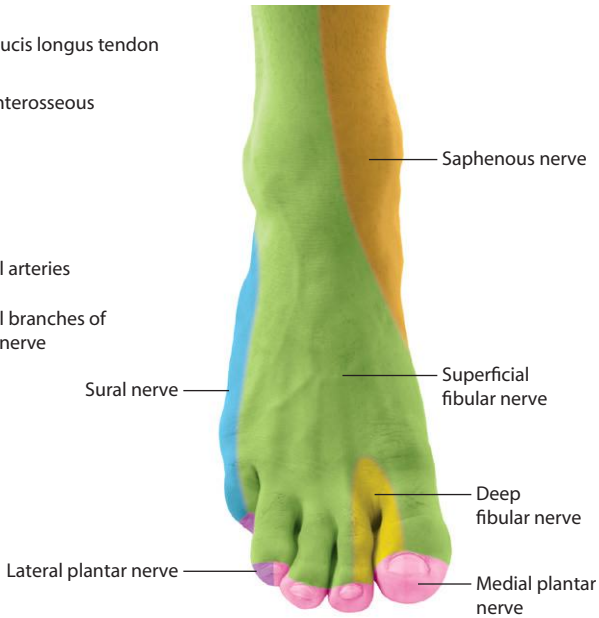

Cutaneous distribution

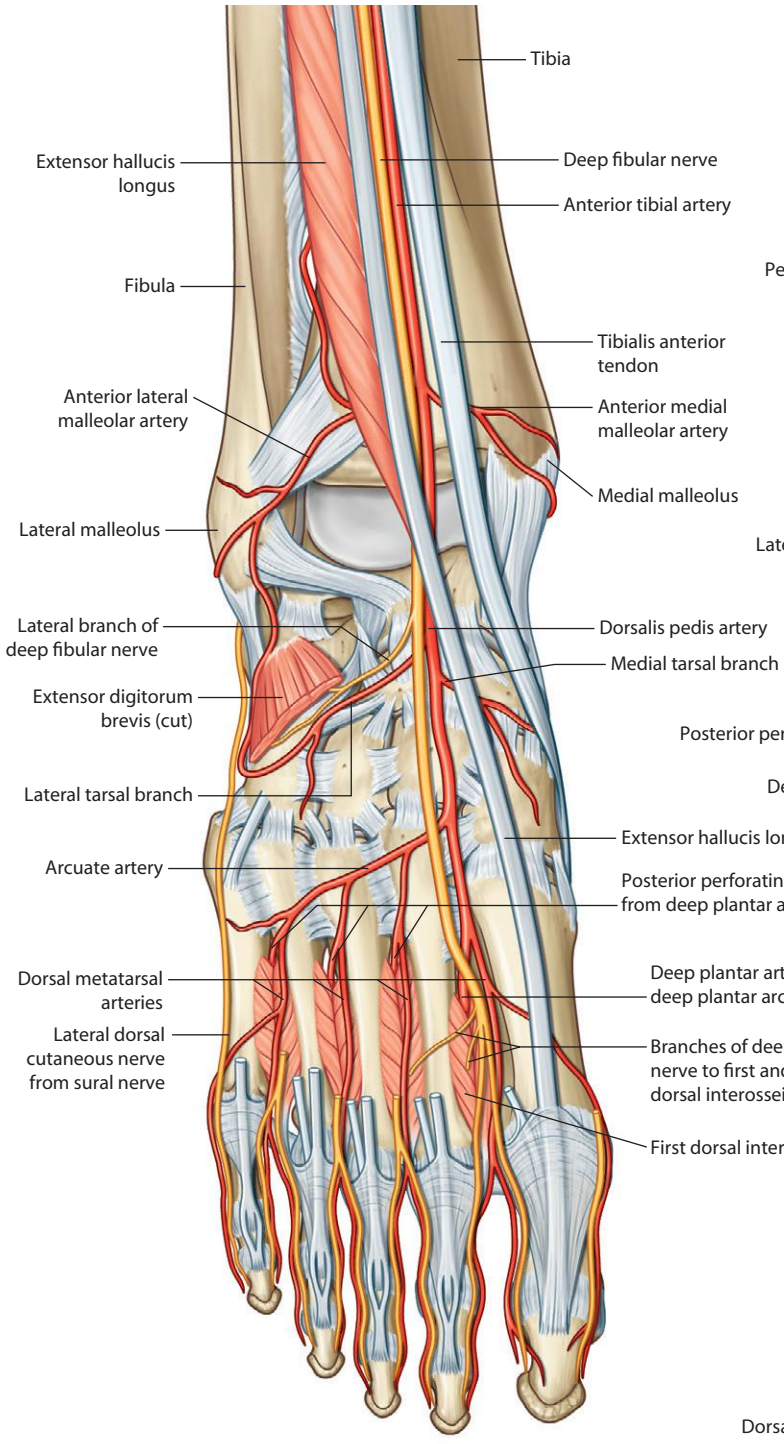

Deep arteries and nerves of the foot (dorsal view)

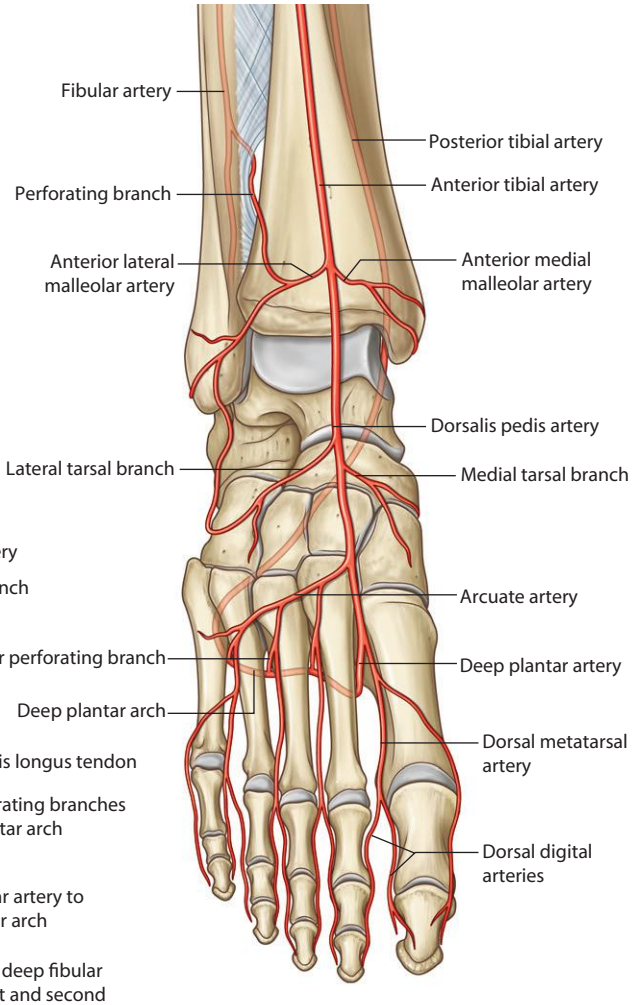

Arteries of the foot (dorsal view)

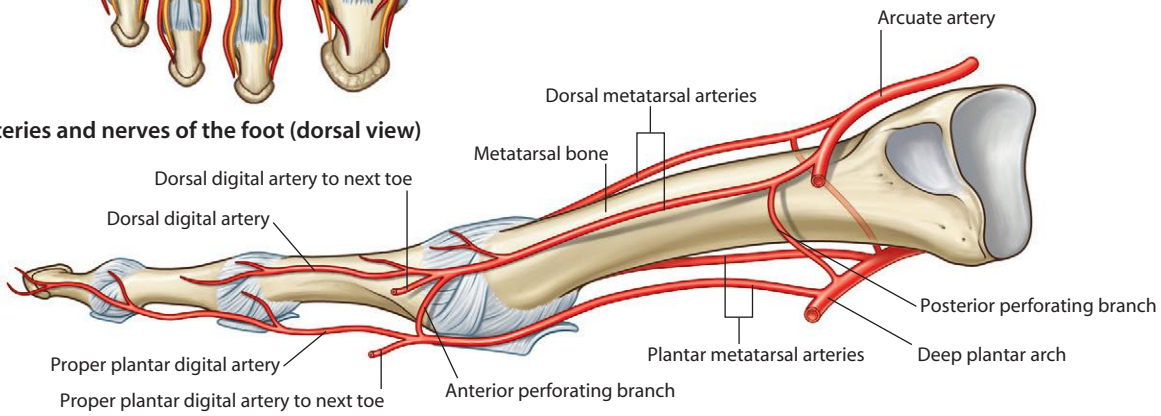

Arteries of digit III (middle toe)

Surface anatomy showing the area in contact with the ground when standing

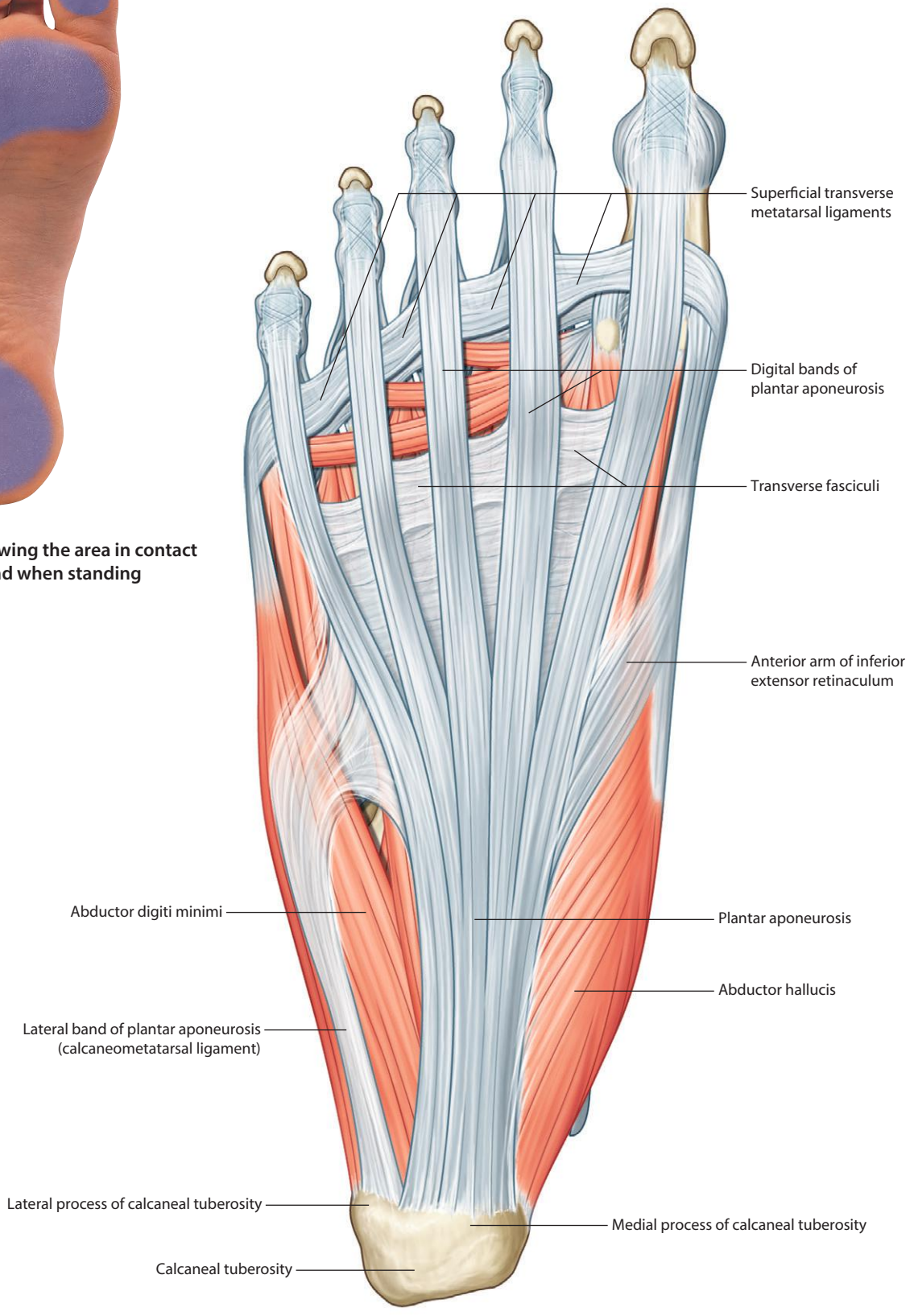

Superficial structures of the foot (plantar view)

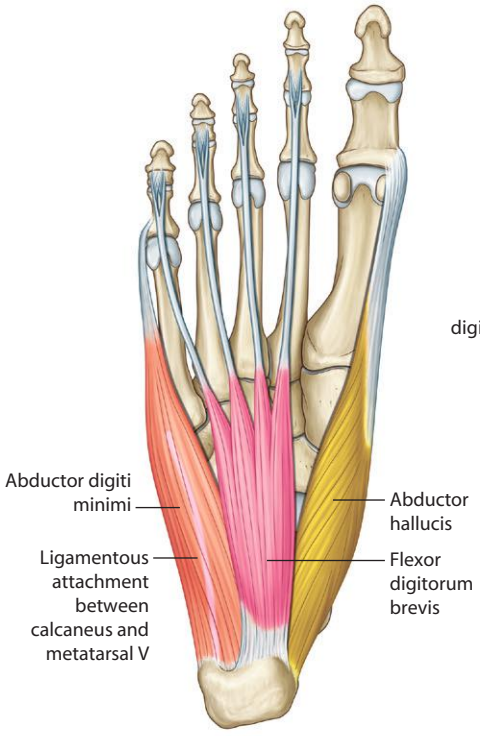

First layer of muscles in the sole of the foot

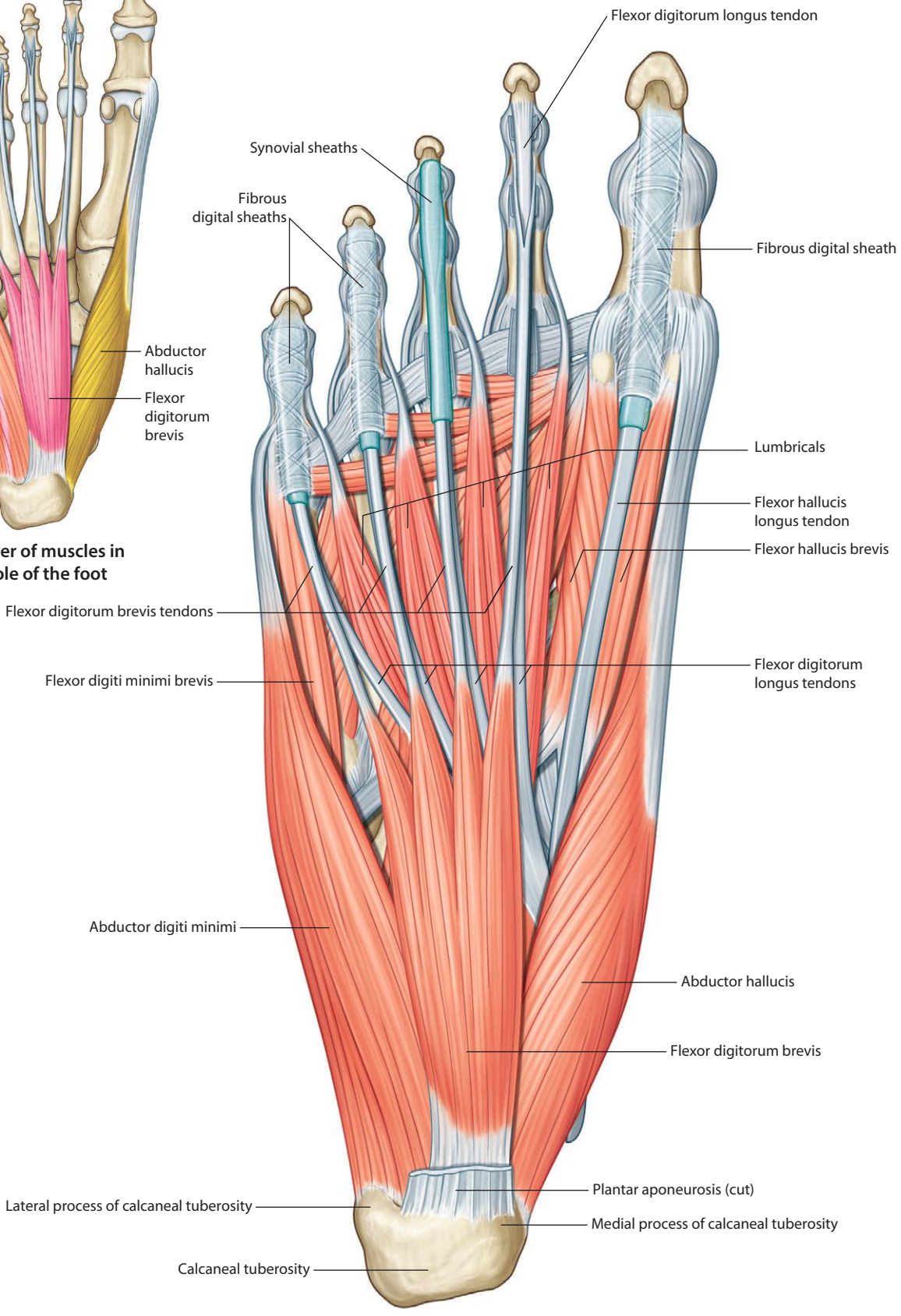

Muscles of sole of foot (first layer)

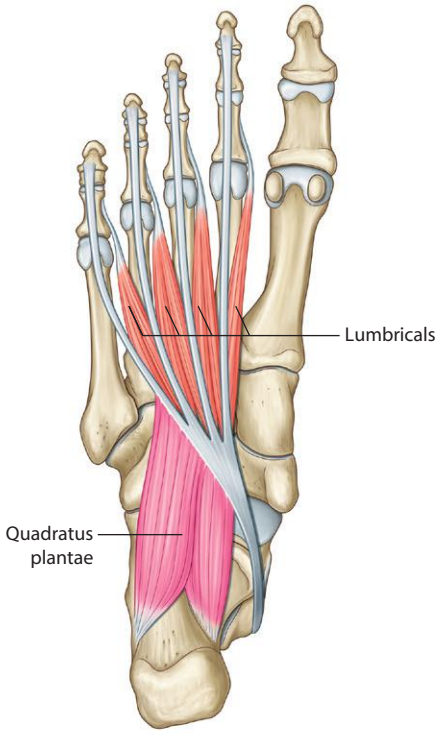

Second layer of muscles in the sole of the foot

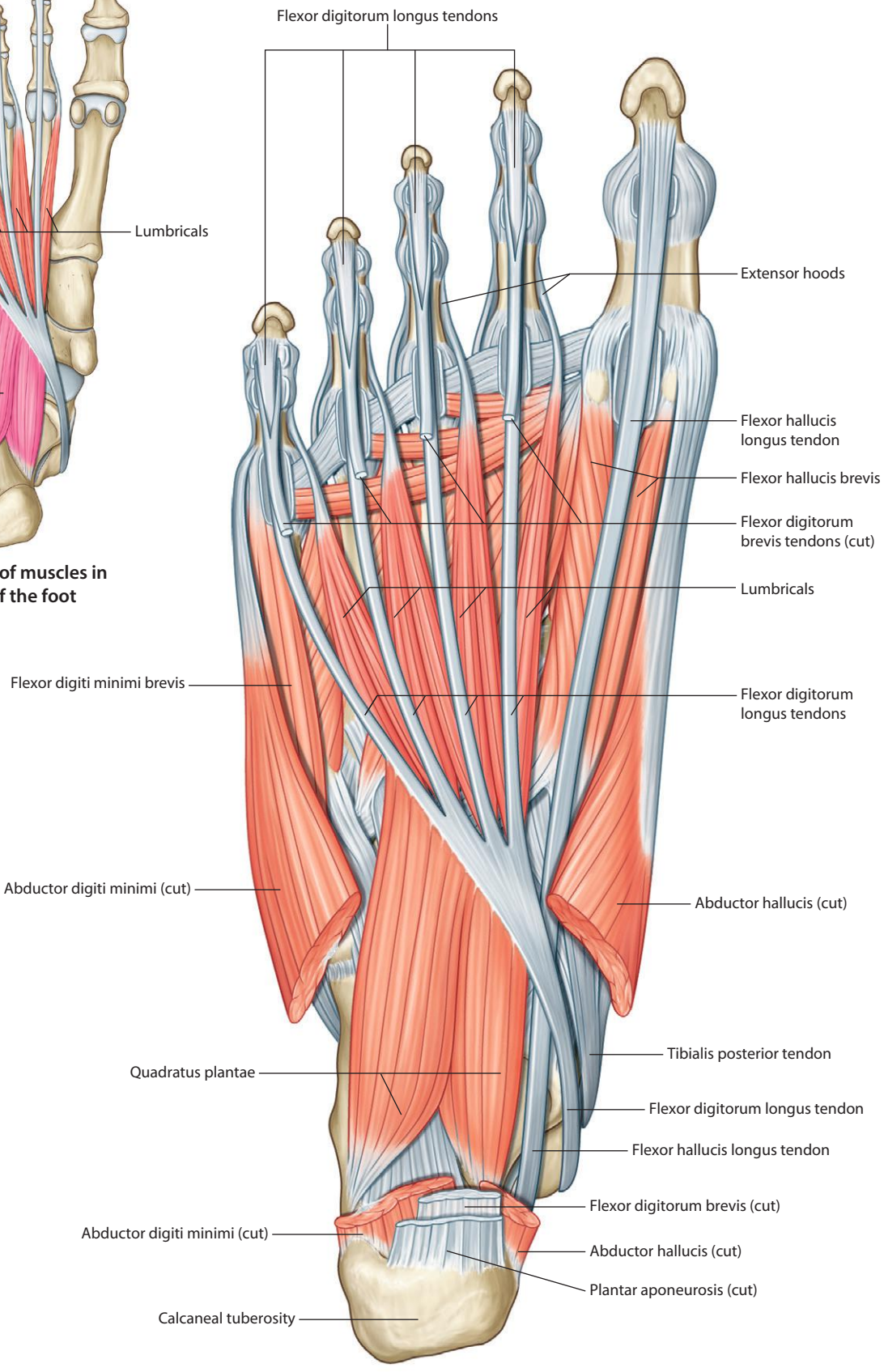

Muscles of sole of foot (second layer)

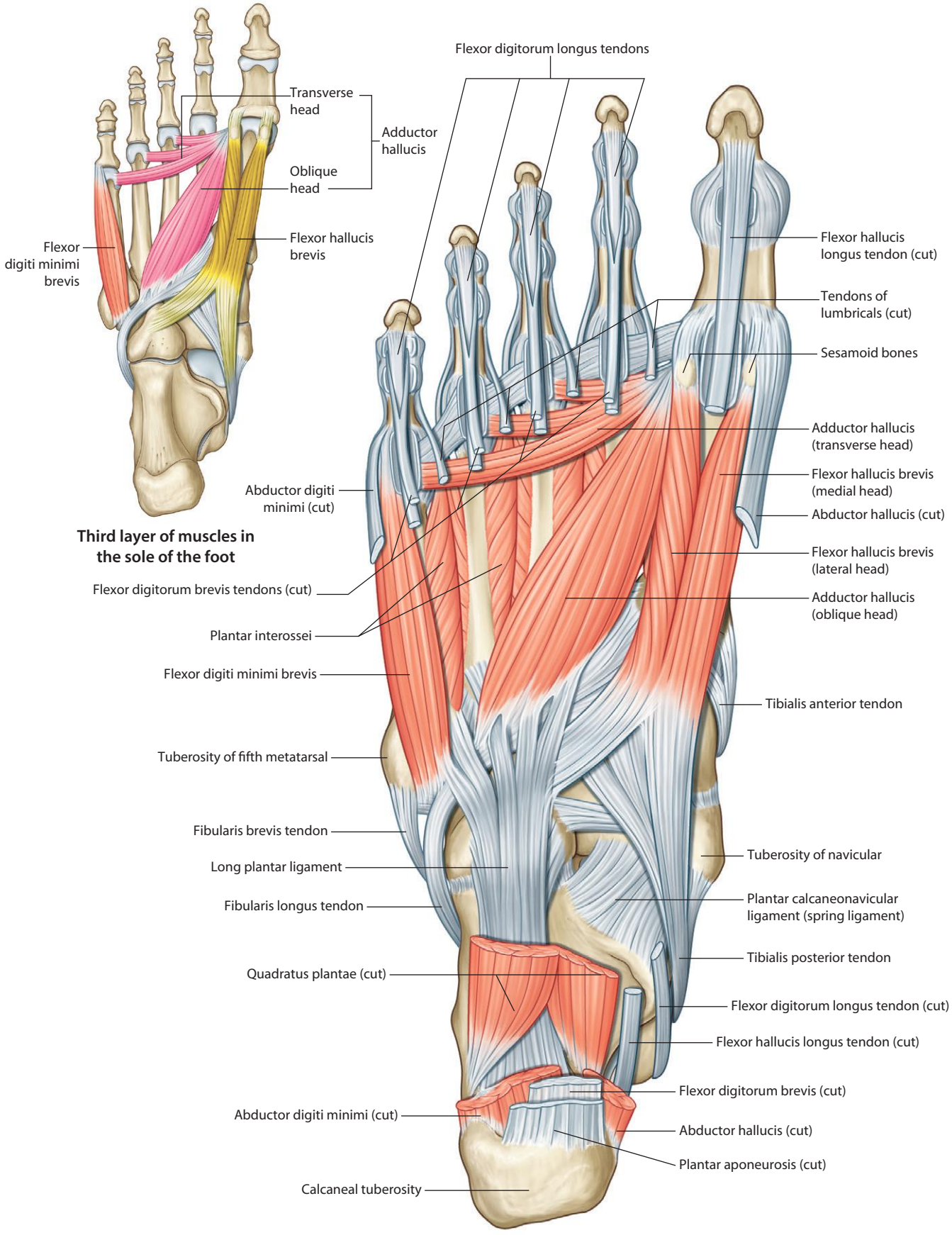

Third layer of muscles in the sole of the foot

Muscles of sole of foot (third layer)

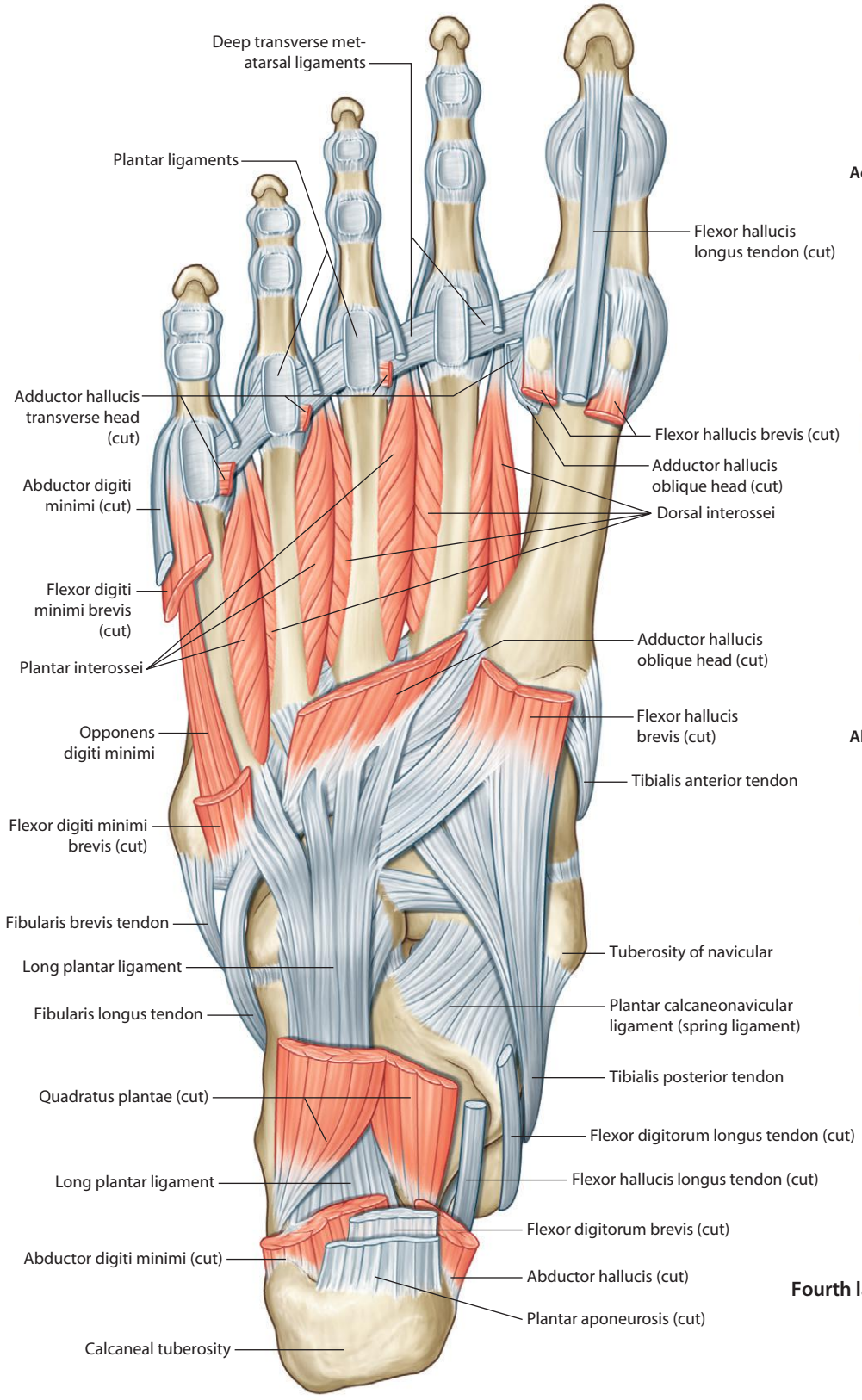

Muscles of sole of foot (fourth layer)

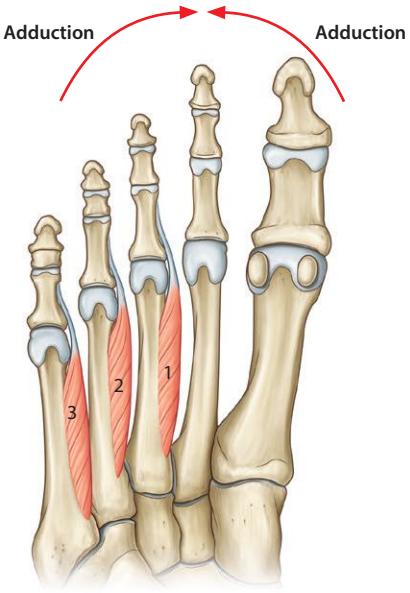

Plantar interossei (unipennate)

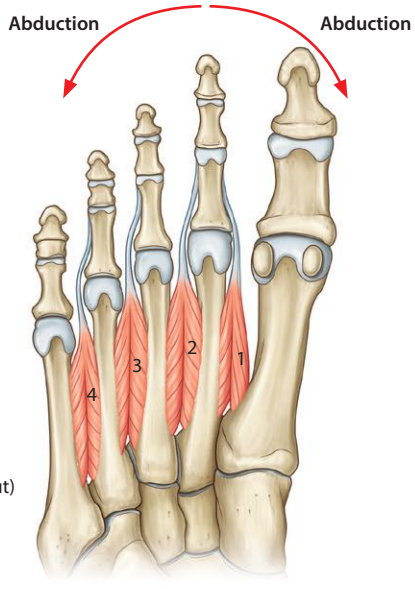

Dorsal interossei (bipennate)

Fourth layer of muscles in the sole of the foot

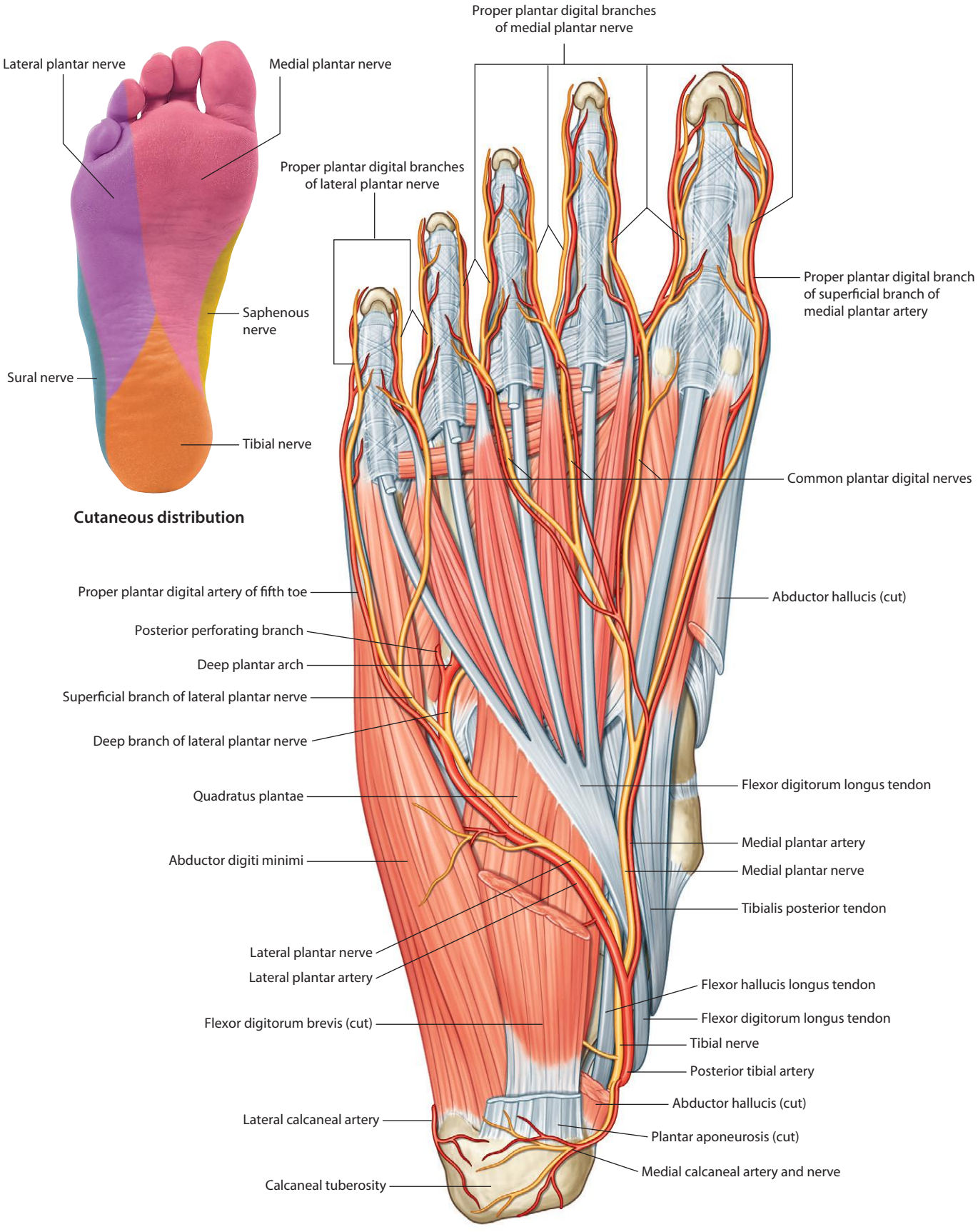

Arteries and nerves of sole of foot (plantar view)

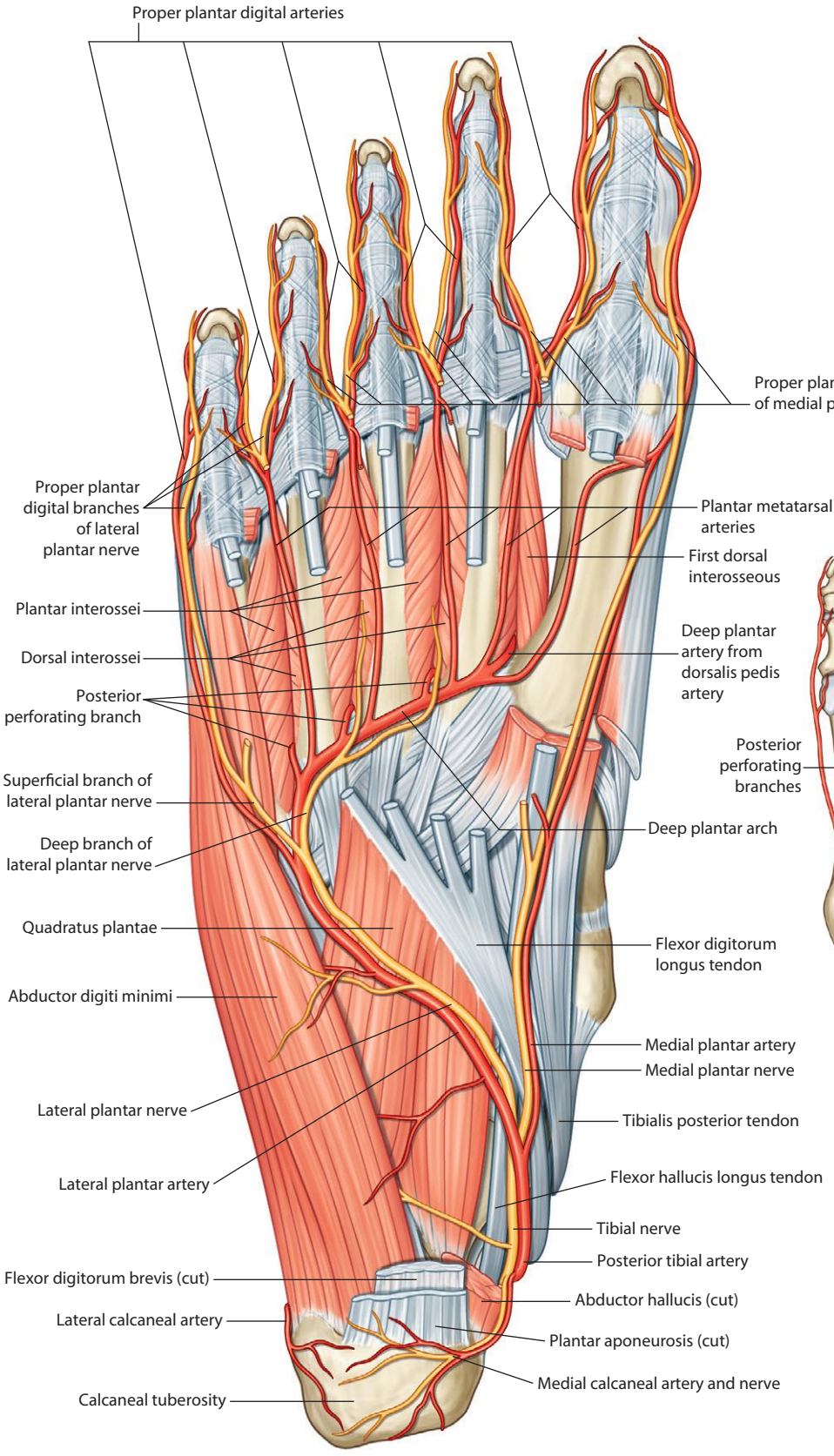

Arteries and nerves of sole of foot (plantar view)

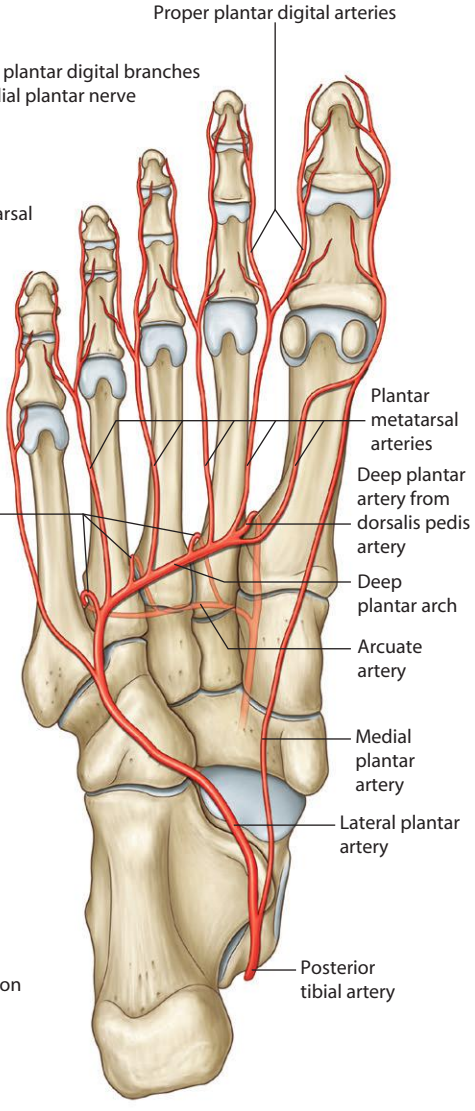

Arteries of sole of foot (plantar view)

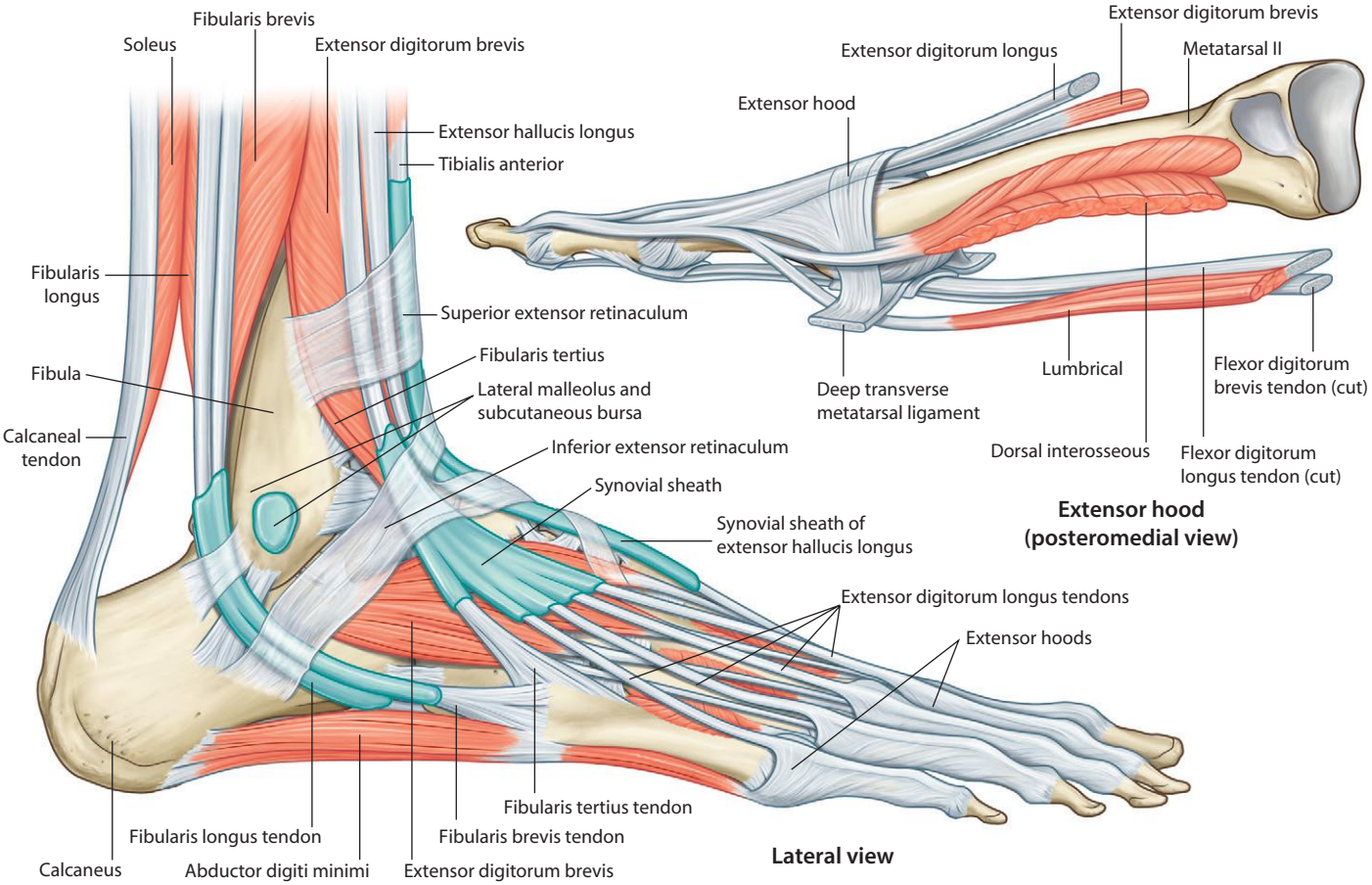
Fibularis brevis
Soleus
Extensor digitorum brevis
Extensor hallucis longus
Tibialis anterior
Fibularis longus
Superior extensor retinaculum
Fibula
Fibularis tertius
Lateral malleolus and subcutaneous bursa
Calcaneal tendon
Inferior extensor retinaculum
Synovial sheath
Synovial sheath of extensor hallucis longus
Extensor digitorum longus tendons
Extensor hoods
Fibularis tertius tendon
Fibularis longus tendon
Fibularis brevis tendon
Calcaneus
Abductor digiti minimi
Extensor digitorum brevis
Lateral view
Extensor digitorum brevis
Extensor digitorum longus
Metatarsal II
Extensor hood
Lumbrical
Flexor digitorum brevis tendon (cut)
Deep transverse metatarsal ligament
Dorsal interosseous
Flexor digitorum longus tendon (cut)
Extensor hood (posteromedial view)

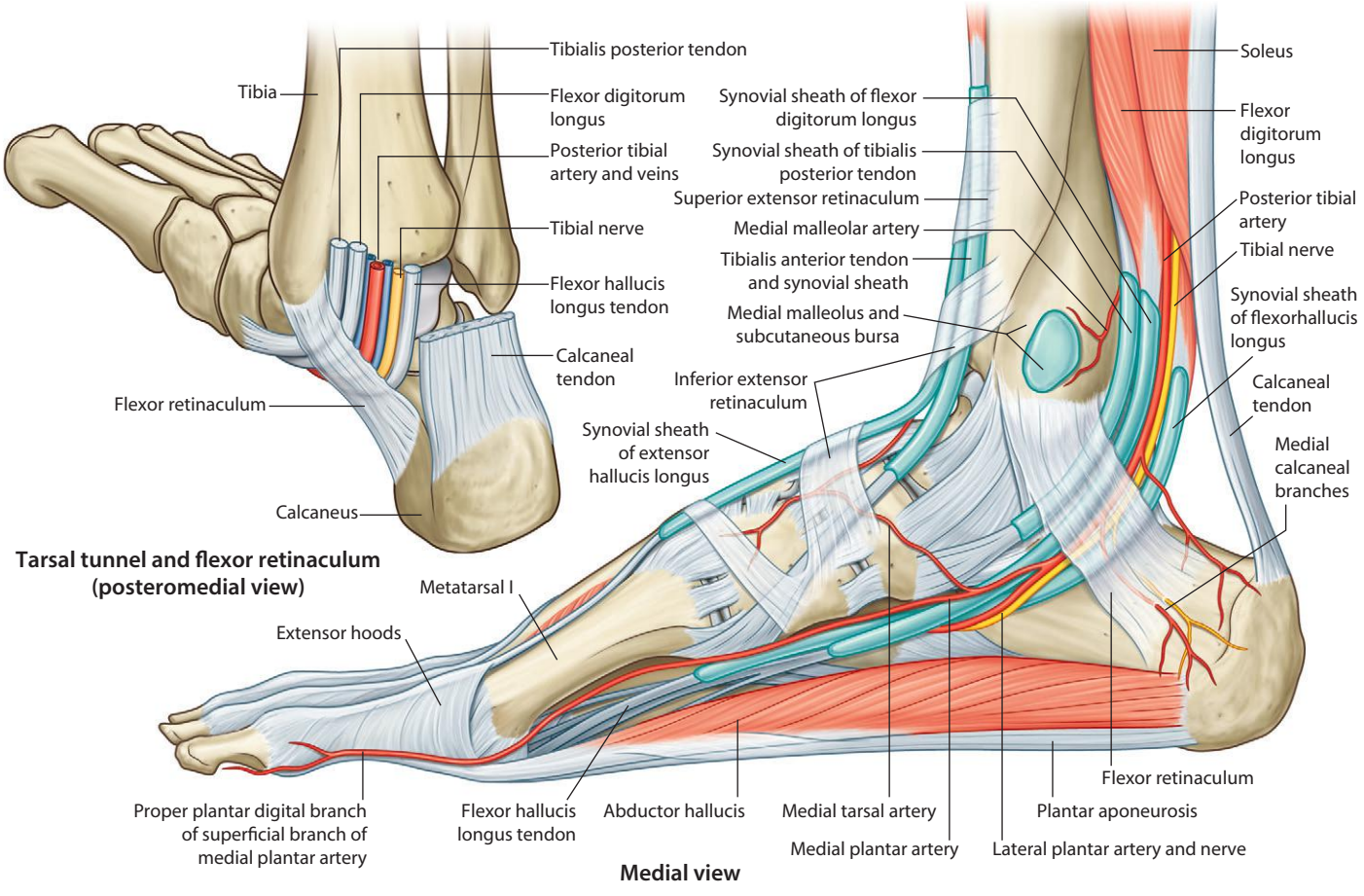
Tibialis posterior tendon
Tibia
Flexor digitorum longus
Posterior tibial artery and veins
Tibial nerve
Flexor hallucis longus tendon
Calcaneal tendon
Flexor retinaculum
Calcaneus
Tarsal tunnel and flexor retinaculum (posteromedial view)
Soleus
Synovial sheath of flexor digitorum longus
Flexor digitorum longus
Synovial sheath of tibialis posterior tendon
Superior extensor retinaculum
Posterior tibial artery
Medial malleolar artery
Tibial nerve
Tibialis anterior tendon and synovial sheath
Synovial sheath of flexorhallucis longus
Medial malleolus and subcutaneous bursa
Calcaneal tendon
Inferior extensor retinaculum
Medial calcaneal branches
Synovial sheath of extensor hallucis longus
Metatarsal I
Extensor hoods
Flexor retinaculum
Proper plantar digital branch of superficial branch of medial plantar artery
Flexor hallucis longus tendon
Abductor hallucis
Medial tarsal artery
Medial plantar artery
Plantar aponeurosis
Lateral plantar artery and nerve
Medial view

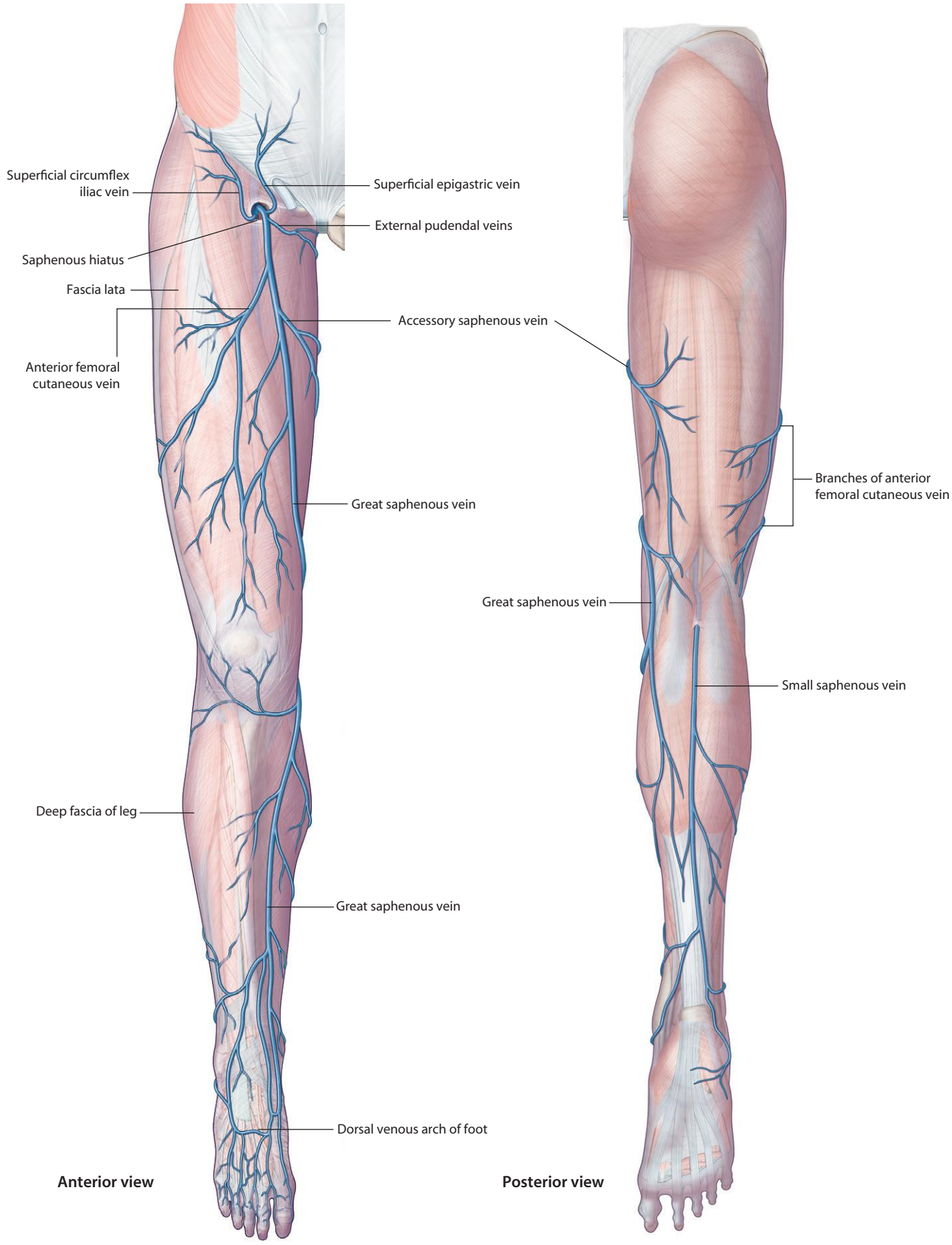
Superficial circumflex iliac vein
Superficial epigastric vein
External pudendal veins
Saphenous hiatus
Fascia lata
Accessory saphenous vein
Anterior femoral cutaneous vein
Great saphenous vein
Deep fascia of leg
Great saphenous vein
Dorsal venous arch of foot
Anterior view
Branches of anterior femoral cutaneous vein
Great saphenous vein
Small saphenous vein
Posterior view

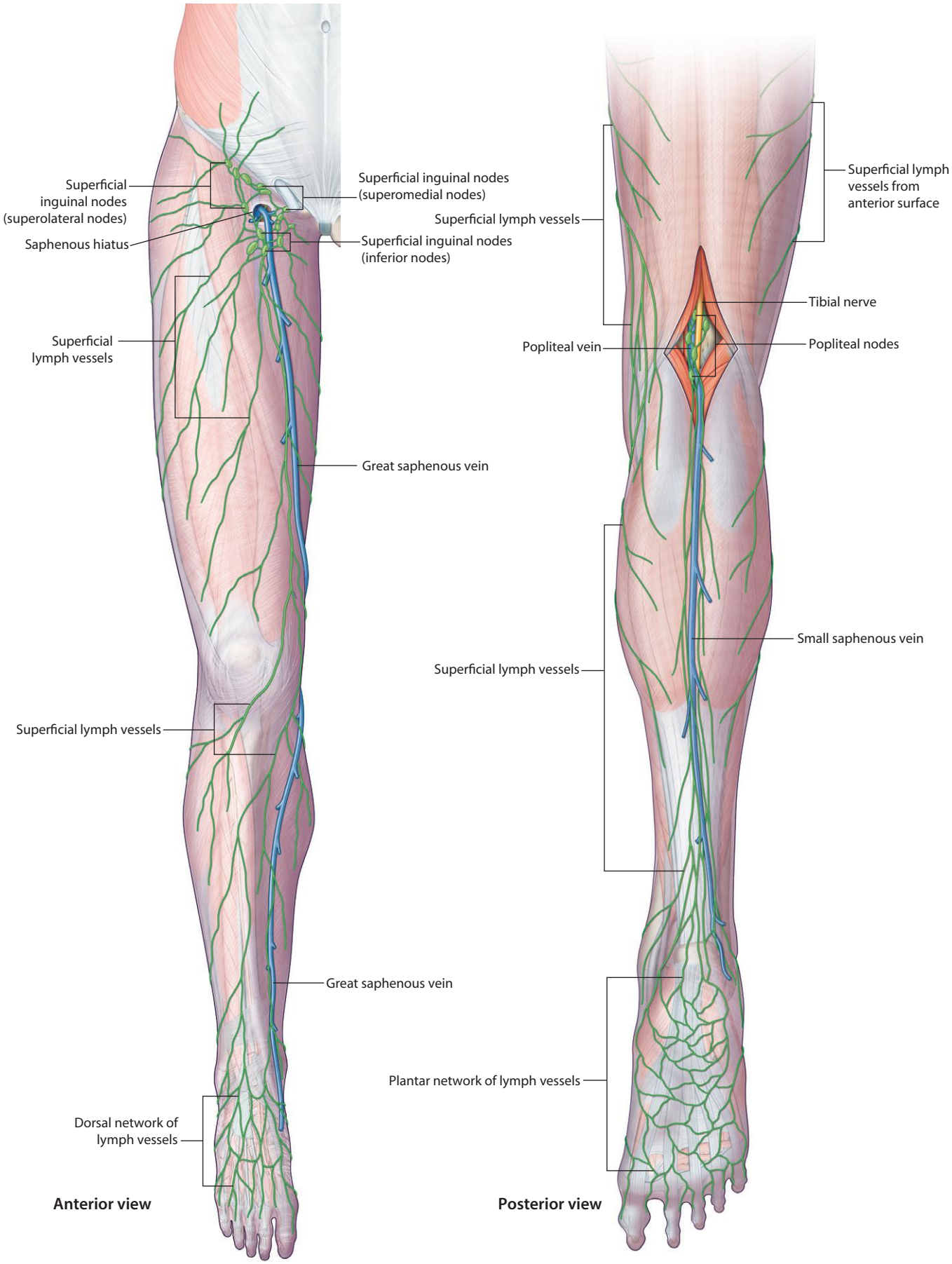
Superficial inguinal nodes (superolateral nodes)
Saphenous hiatus
Superficial inguinal nodes (superomedial nodes)
Superficial inguinal nodes (inferior nodes)
Superficial lymph vessels
Great saphenous vein
Superficial lymph vessels
Great saphenous vein
Dorsal network of lymph vessels
Anterior view
Superficial lymph vessels
Superficial lymph vessels from anterior surface
Tibial nerve
Popliteal vein
Popliteal nodes
Small saphenous vein
Superficial lymph vessels
Plantar network of lymph vessels
Posterior view

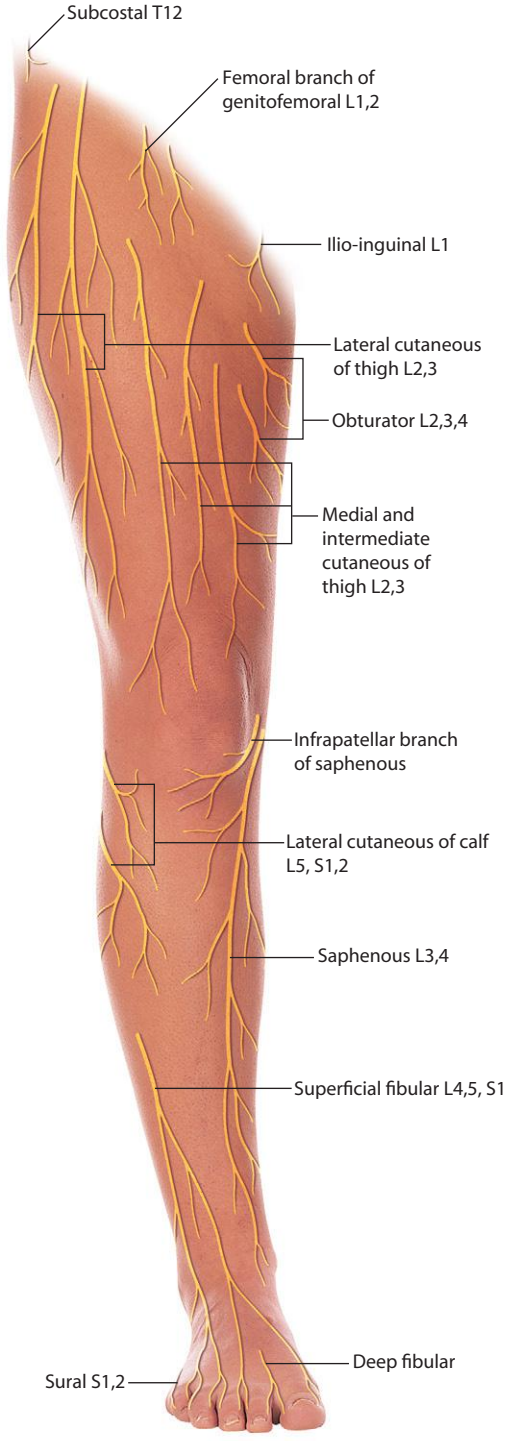

Cutaneous nerves of the lower limb

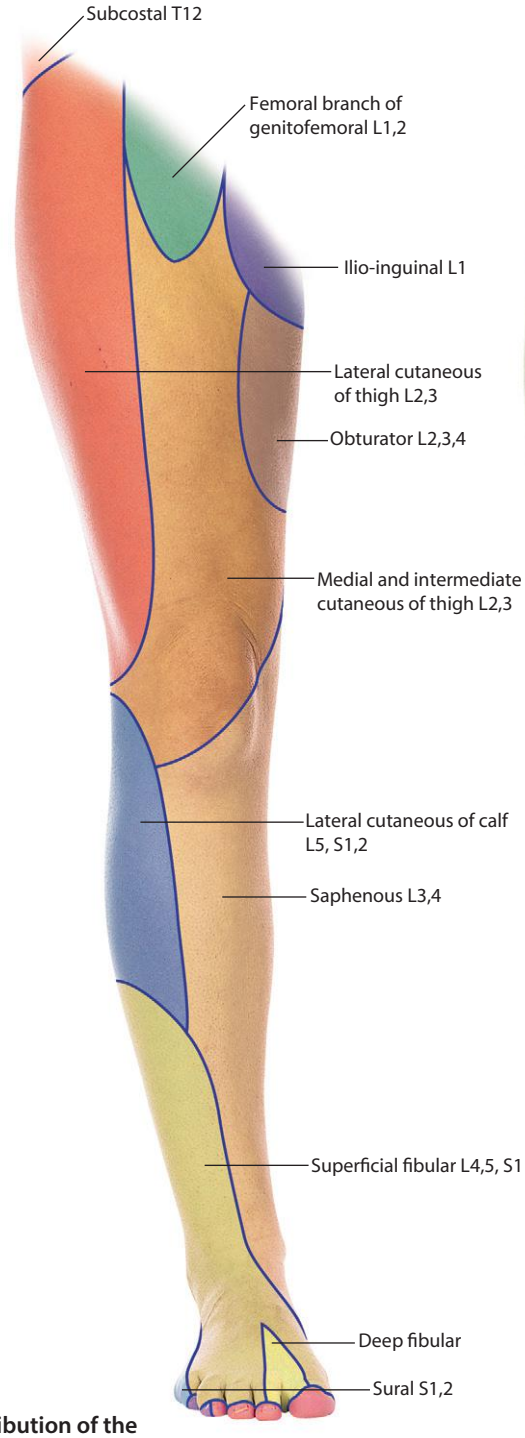

Areas of distribution of the cutaneous nerves of the lower limb

Dermatomes of the lower limb

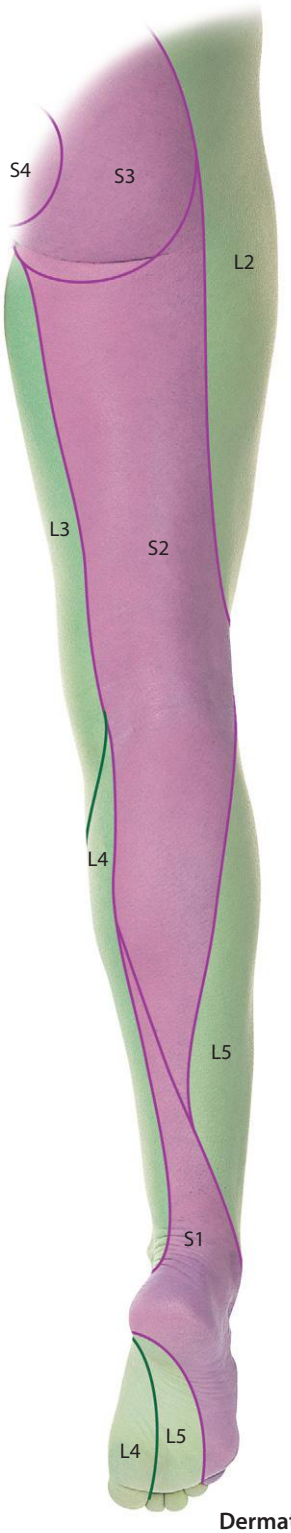

Dermatomes of the lower limb

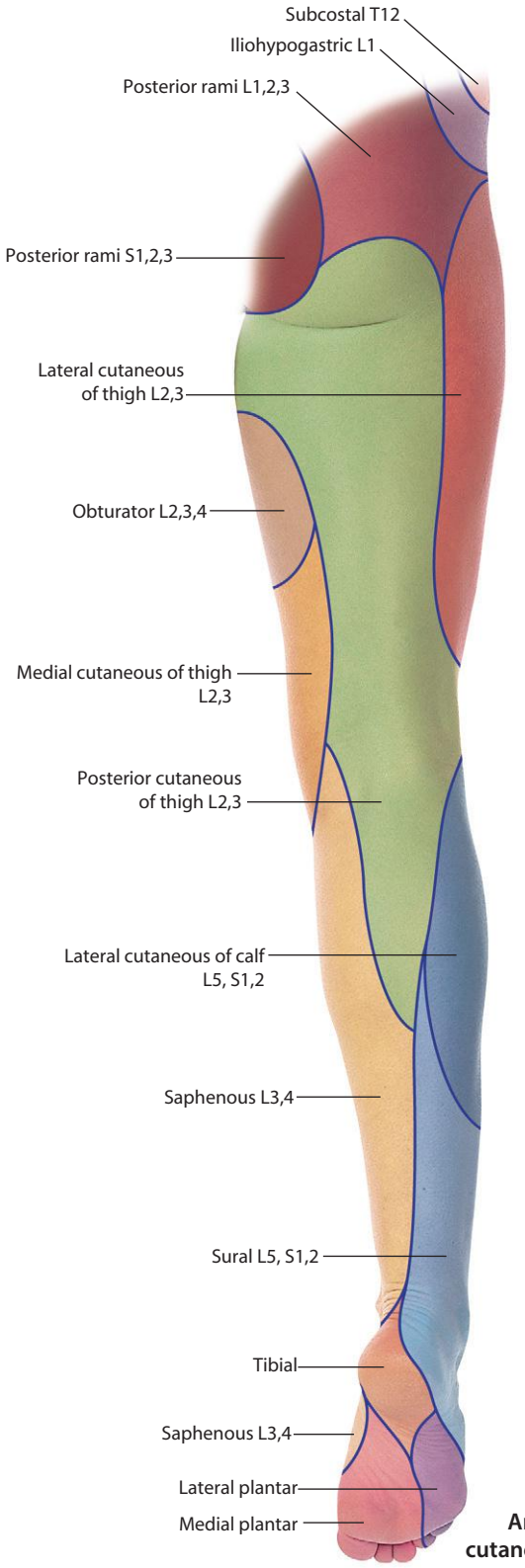

Areas of distribution of the cutaneous nerves of the lower limb

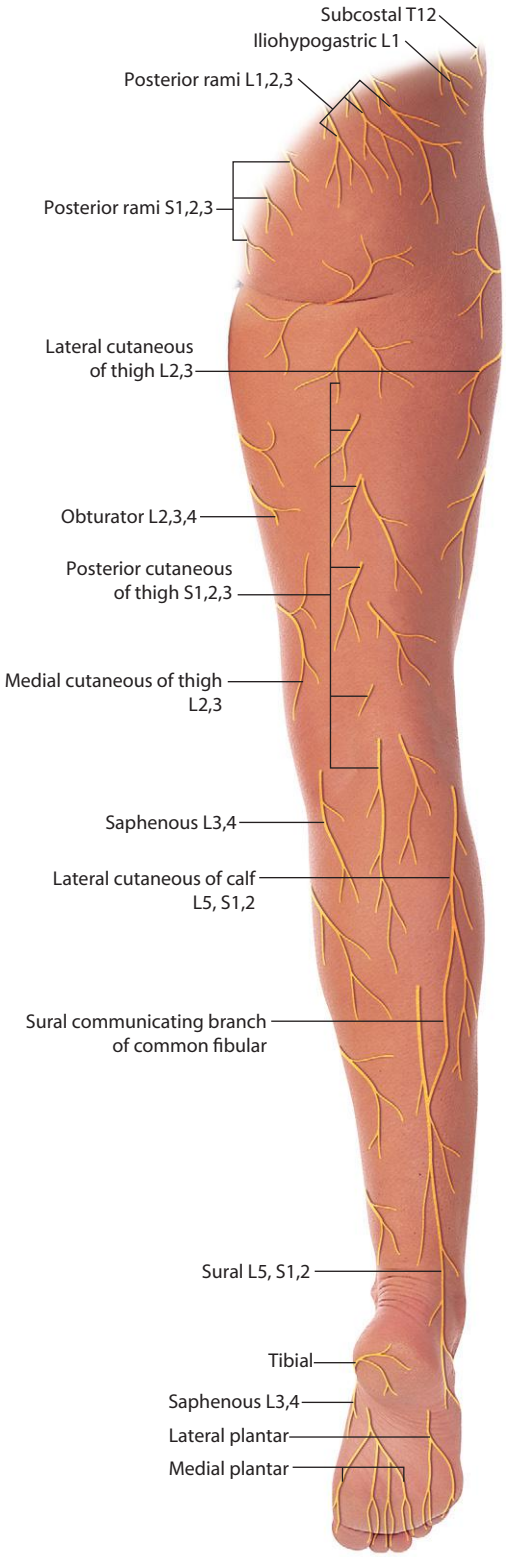

Cutaneous nerves of the lower limb

Branches of the lumbosacral plexus associated with the lower limb

Branch		Spinal segments	Function: motor	Function: sensory (cutaneous)
Ilio-inguinal	1	L1	No motor function in lower limb, but innervates muscles of the abdominal wall	Skin over anteromedial part of upper thigh and adjacent skin of perineum
Genitofemoral	2	L1, L2	No motor function in lower limb, but genital branch innervates cremaster muscle in the wall of the spermatic cord in men	Femoral branch innervates skin on anterior central part of upper thigh; the genital branch innervates skin in anterior part of perineum (anterior scrotum in men, and mons pubis and anterior labia majora in women)
Femoral	3	L2 to L4	All muscles in the anterior compartment of thigh; in the abdomen, also gives rise to branches that supply iliacus and pectineus	Skin over the anterior thigh, anteromedial knee, medial side of the leg, and the medial side of the foot
Obturator	4	L2 to L4	All muscles in the medial compartment of thigh (except pectineus and the part of adductor magnus attached to the ischium); also innervates obturator externus	Skin over upper medial aspect of thigh
Sciatic	5	L4 to S3	All muscles in the posterior compartment of thigh and the part of adductor magnus attached to the ischium; all muscles in the leg and foot	Skin over lateral side of leg and foot, and over the sole and dorsal surface of foot
Superior gluteal	6	L4 to S1	Muscles of the gluteal region (gluteus medius, gluteus minimus, tensor fasciae latae)	
Inferior gluteal	7	L5 to S2	Muscle of the gluteal region (gluteus maximus)	
Lateral cutaneous nerve of thigh	8	L2, L3		Parietal peritoneum in iliac fossa; skin over anterolateral thigh
Posterior cutaneous nerve of thigh	9	S1 to S3		Skin over gluteal fold and upper medial aspect of thigh and adjacent perineum, posterior aspect of thigh, and upper posterior leg
Nerve to quadratus femoris	10	L4 to S1	Muscles of gluteal region (quadratus femoris and gemellus inferior)	
Nerve to obturator internus	11	L5 to S2	Muscles of gluteal region (obturator internus and gemellus superior)	
Perforating cutaneous nerve	12	S2, S3		Skin over medial aspect of gluteal fold

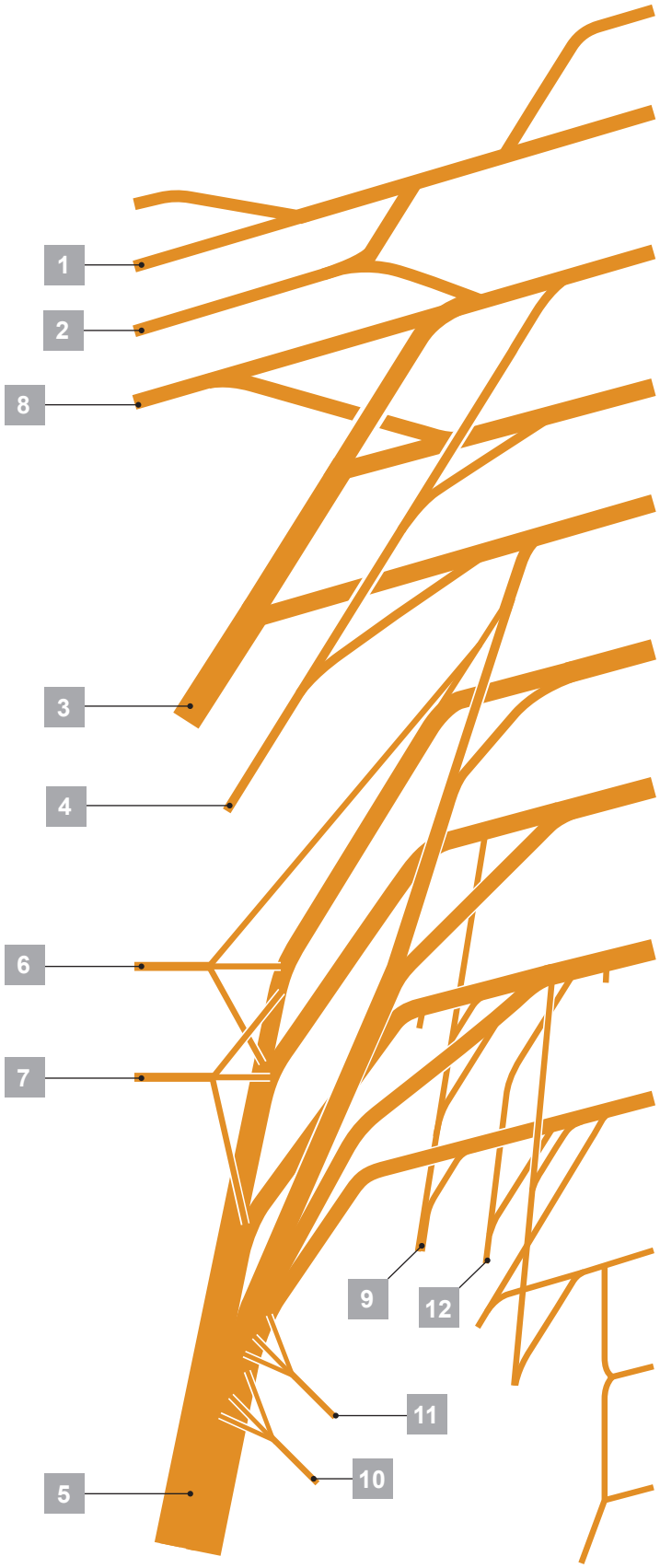
1
2
8
3
4
6
7
9
12
11
10
5

Muscles of the gluteal region

(spinal segments in bold are the major segments innervating the muscle)

Muscle		Origin	Insertion	Innervation	Function
Piriformis	1	Anterior surface of sacrum between anterior sacral foramina	Medial side of superior border of greater trochanter of femur	Branches from **L5**, **S1**, **S2**	Laterally rotates the extended femur at hip joint; abducts flexed femur at hip joint
Obturator internus	2	Anterolateral wall of true pelvis; deep surface of obturator membrane and surrounding bone	Medial side of greater trochanter of femur	Nerve to obturator internus (L5, **S1**)	Laterally rotates the extended femur at hip joint; abducts flexed femur at hip joint
Gemellus superior	3	External surface of ischial spine	Along length of superior surface of the obturator internus tendon and into the medial side of greater trochanter of femur with obturator internus tendon	Nerve to obturator internus (L5, **S1**)	Laterally rotates the extended femur at hip joint; abducts flexed femur at hip joint
Gemellus inferior	4	Upper aspect of ischial tuberosity	Along length of inferior surface of the obturator internus tendon and into the medial side of greater trochanter of femur with obturator internus tendon	Nerve to quadratus femoris (**L5**, **S1**)	Laterally rotates the extended femur at hip joint; abducts flexed femur at hip joint
Quadratus femoris	5	Lateral aspect of the ischium just anterior to the ischial tuberosity	Quadrate tubercle on the intertrochanteric crest of the proximal femur	Nerve to quadratus femoris (**L5**, **S1**)	Laterally rotates femur at hip joint
Gluteus minimus	6	External surface of ilium between inferior and anterior gluteal lines	Linear facet on the anterolateral aspect of the greater trochanter	Superior gluteal nerve (**L4**, **L5**, S1)	Abducts femur at hip joint; holds pelvis secure over stance leg and prevents pelvic drop on the opposite swing side during walking; medially rotates thigh
Gluteus medius	7	External surface of ilium between anterior and posterior gluteal lines	Elongate facet on the lateral surface of the greater trochanter	Superior gluteal nerve (**L4**, **L5**, S1)	Abducts femur at hip joint; holds pelvis secure over stance leg and prevents pelvic drop on the opposite swing side during walking; medially rotates thigh
Gluteus maximus	8	Fascia covering gluteus medius, external surface of ilium behind posterior gluteal line, fascia of erector spinae, dorsal surface of lower sacrum, lateral margin of coccyx, external surface of sacrotuberous ligament	Posterior aspect of iliotibial tract of fascia lata and gluteal tuberosity of proximal femur	Inferior gluteal nerve (**L5**, **S1**, S2)	Powerful extensor of flexed femur at hip joint; lateral stabilizer of hip joint and knee joint; laterally rotates and abducts thigh
Tensor fasciae latae	9	Lateral aspect of crest of ilium between anterior superior iliac spine and tubercle of the crest	Iliotibial tract of fascia lata	Superior gluteal nerve (**L4**, **L5**, S1)	Stabilizes the knee in extension

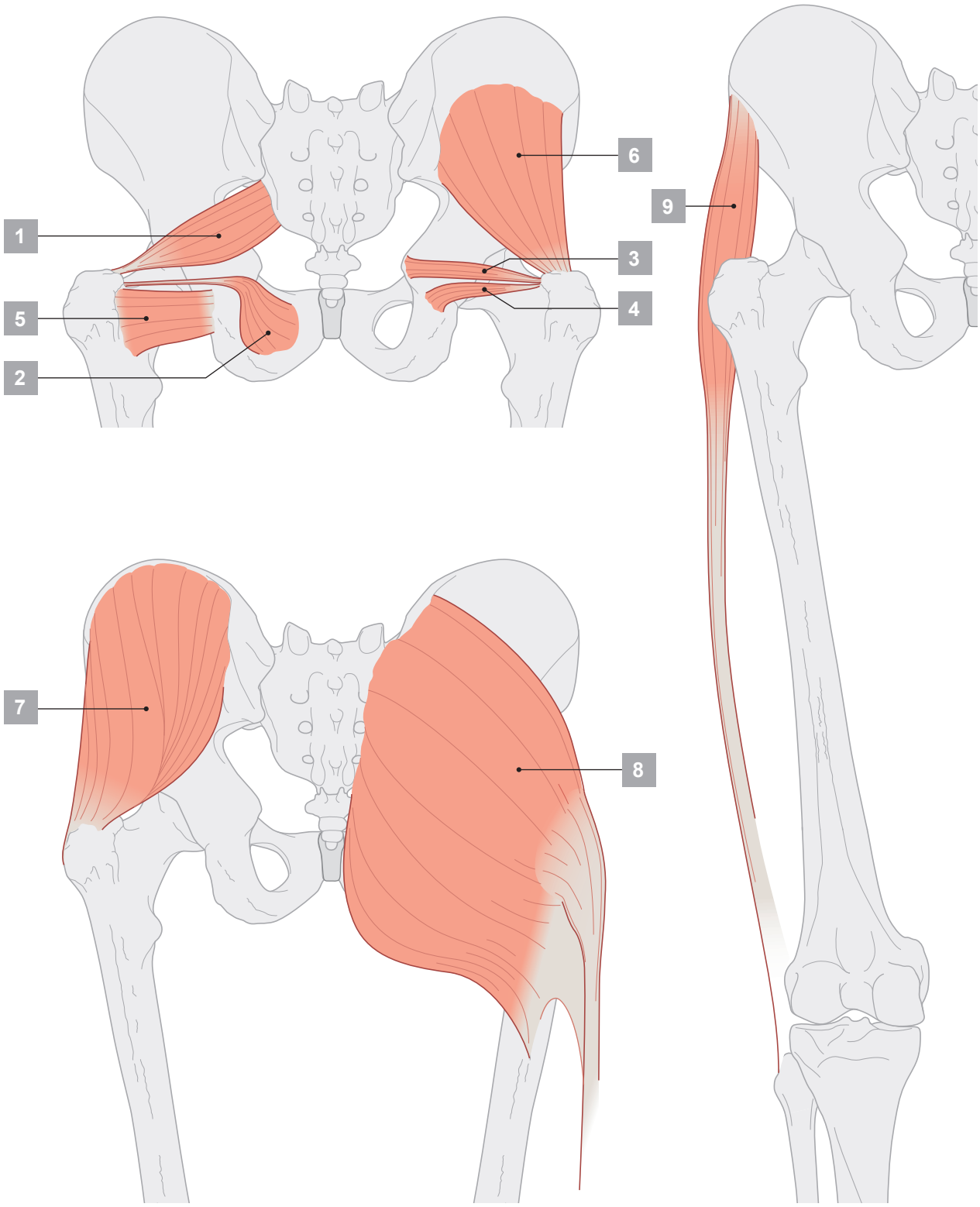
1
2
3
4
5
6
7
8
9

Muscles of the anterior compartment of thigh

(spinal segments in bold are the major segments innervating the muscle)

Muscle		Origin	Insertion	Innervation	Function
Psoas major	1	Posterior abdominal wall (lumbar transverse processes, intervertebral discs, and adjacent bodies from TXII to LV and tendinous arches between these points)	Lesser trochanter of femur	Anterior rami [**L1**, **L2**, L3]	Flexes the thigh at the hip joint
Iliacus	2	Posterior abdominal wall (iliac fossa)	Lesser trochanter of femur	Femoral nerve [**L2**, L3]	Flexes the thigh at the hip joint
Vastus medialis	3	Femur—medial part of intertrochanteric line, pectineal line, medial lip of the linea aspera, medial supracondylar line	Quadriceps femoris tendon and medial border of patella	Femoral nerve [L2, **L3**, **L4**]	Extends the leg at the knee joint
Vastus intermedius	4	Femur—upper two thirds of anterior and lateral surfaces	Quadriceps femoris tendon and lateral margin of patella	Femoral nerve [L2, **L3**, **L4**]	Extends the leg at the knee joint
Vastus lateralis	5	Femur—lateral part of intertrochanteric line, margin of greater trochanter, lateral margin of gluteal tuberosity, lateral lip of the linea aspera	Quadriceps femoris tendon	Femoral nerve [L2, **L3**, **L4**]	Extends the leg at the knee joint
Rectus femoris	6	Straight head originates from the anterior inferior iliac spine; reflected head originates from the ilium just superior to the acetabulum	Quadriceps femoris tendon	Femoral nerve [L2, **L3**, **L4**]	Flexes the thigh at the hip joint and extends the leg at the knee joint
Sartorius	7	Anterior superior iliac spine	Medial surface of tibia just inferomedial to tibial tuberosity	Femoral nerve [**L2**, **L3**]	Flexes the thigh at the hip joint and flexes the leg at the knee joint

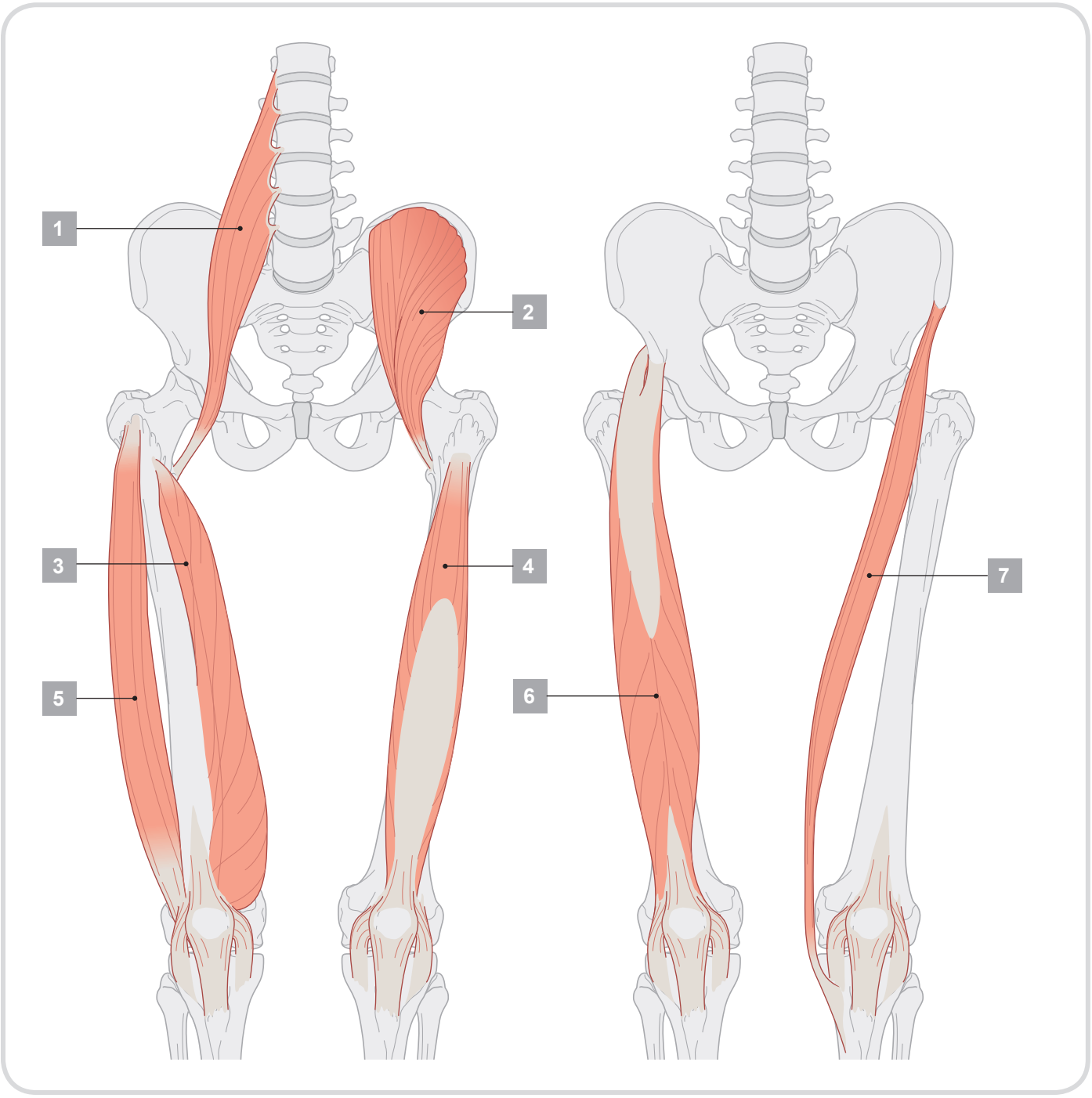
1
2
3
4
5
6
7

Muscles of the medial compartment of thigh

(spinal segments in bold are the major segments innervating the muscle)

Muscle		Origin	Insertion	Innervation	Function
Gracilis	1	A line on the external surfaces of the body of the pubis, the inferior pubic ramus, and the ramus of the ischium	Medial surface of proximal shaft of tibia	Obturator nerve [**L2**, L3]	Adducts thigh at hip joint and flexes leg at knee joint
Pectineus	2	Pectineal line (pecten pubis) and adjacent bone of pelvis	Oblique line extending from base of lesser trochanter to linea aspera on posterior surface of proximal femur	Femoral nerve [**L2**, L3]	Adducts and flexes thigh at hip joint
Adductor longus	3	External surface of body of pubis (triangular depression inferior to pubic crest and lateral to pubic symphysis)	Linea aspera on middle one third of shaft of femur	Obturator nerve (anterior division) [**L2**, **L3**, L4]	Adducts and medially rotates thigh at hip joint
Adductor brevis	4	External surface of body of pubis and inferior pubic ramus	Posterior surface of proximal femur and upper one third of linea aspera	Obturator nerve [**L2**, **L3**]	Adducts and medially rotates thigh at hip joint
Adductor magnus	5	Adductor part—ischiopubic ramus Hamstring part—ischial tuberosity	Posterior surface of proximal femur, linea aspera, medial supracondylar line Adductor tubercle and supracondylar line	Obturator nerve [**L2**, **L3**, L4] Sciatic nerve (tibial division) [**L2**, **L3**, L4]	Adducts and medially rotates thigh at hip joint
Obturator externus	6	External surface of obturator membrane and adjacent bone	Trochanteric fossa	Obturator nerve (posterior division) [L3, **L4**]	Laterally rotates thigh at hip joint

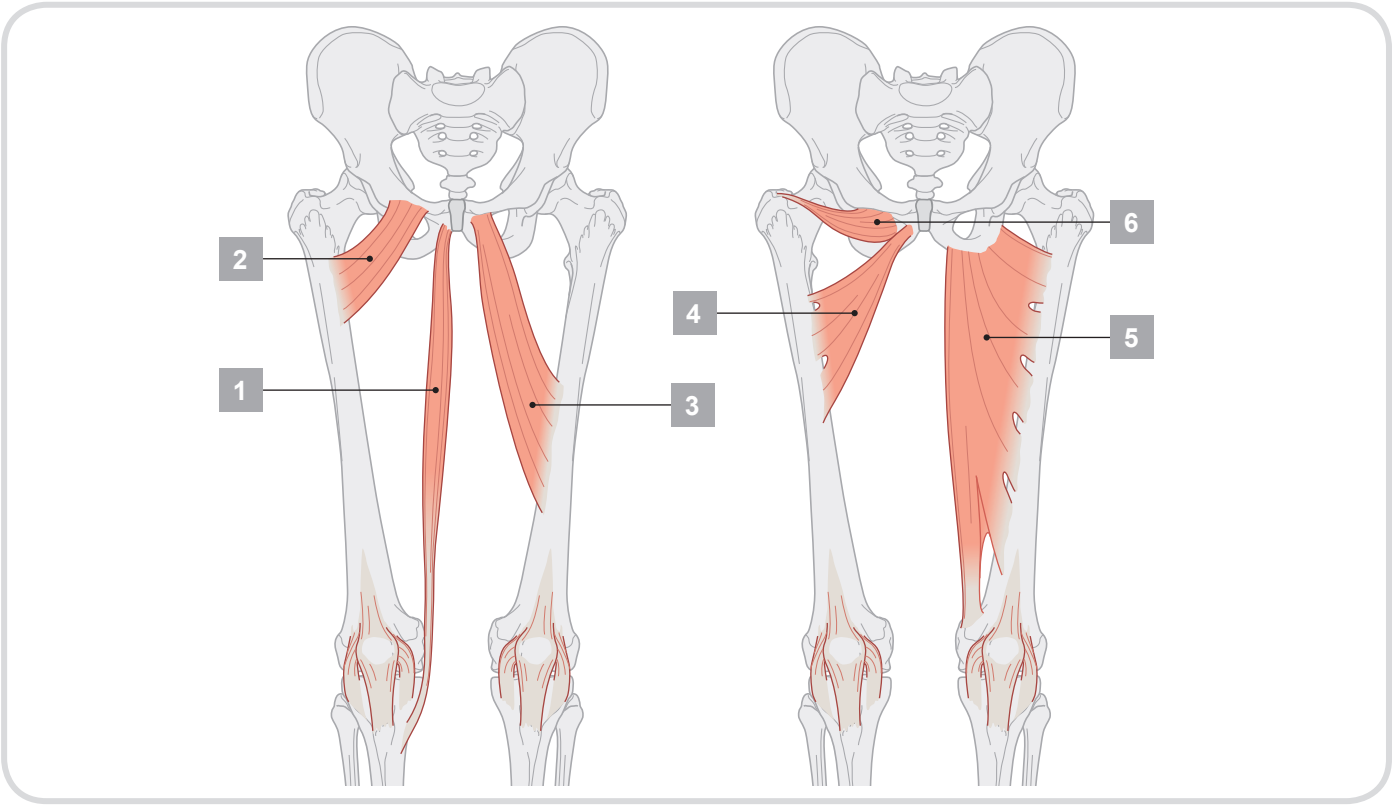

Muscles of the posterior compartment of thigh

(spinal segments in bold are the major segments innervating the muscle)

Muscle		Origin	Insertion	Innervation	Function
Biceps femoris	1	Long head—inferomedial part of the upper area of the ischial tuberosity; short head—lateral lip of linea aspera	Head of fibula	Sciatic nerve [L5, **S1**, S2]	Flexes leg at knee joint; extends and laterally rotates thigh at hip joint and laterally rotates leg at knee joint
Semitendinosus	2	Inferomedial part of the upper area of the ischial tuberosity	Medial surface of proximal tibia	Sciatic nerve [L5, **S1**, S2]	Flexes leg at knee joint and extends thigh at hip joint; medially rotates thigh at hip joint and leg at knee joint
Semimembranosus	3	Superolateral impression on the ischial tuberosity	Groove and adjacent bone on medial and posterior surface of medial tibial condyle	Sciatic nerve [L5, **S1**, S2]	Flexes leg at knee joint and extends thigh at hip joint; medially rotates thigh at hip joint and leg at knee joint

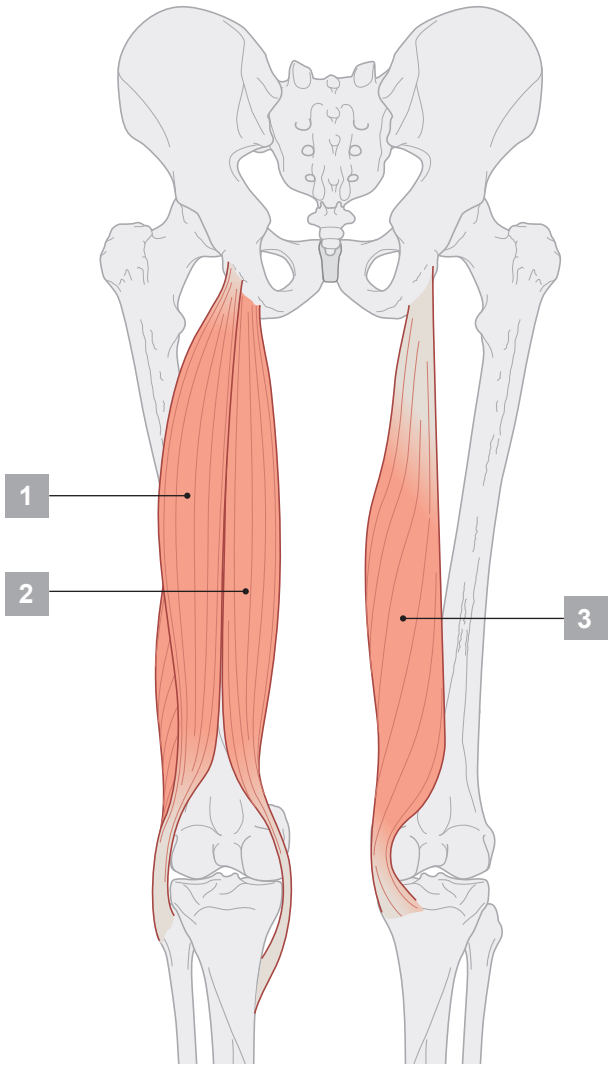

Superficial group of muscles in the posterior compartment of leg

(spinal segments in bold are the major segments innervating the muscle)

Muscle		Origin	Insertion	Innervation	Function
Gastrocnemius	1	Medial head—posterior surface of distal femur just superior to medial condyle; lateral head—upper posterolateral surface of lateral femoral condyle	Via calcaneal tendon, to posterior surface of calcaneus	Tibial nerve [**S1**, **S2**]	Plantarflexes foot and flexes knee
Plantaris	2	Inferior part of lateral supracondylar line of femur and oblique popliteal ligament of knee	Via calcaneal tendon, to posterior surface of calcaneus	Tibial nerve [**S1**, **S2**]	Plantarflexes foot and flexes knee
Soleus	3	Soleal line and medial border of tibia; posterior aspect of fibular head and adjacent surfaces of neck and proximal shaft; tendinous arch between tibial and fibular attachments	Via calcaneal tendon, to posterior surface of calcaneus	Tibial nerve [**S1**, **S2**]	Plantarflexes the foot

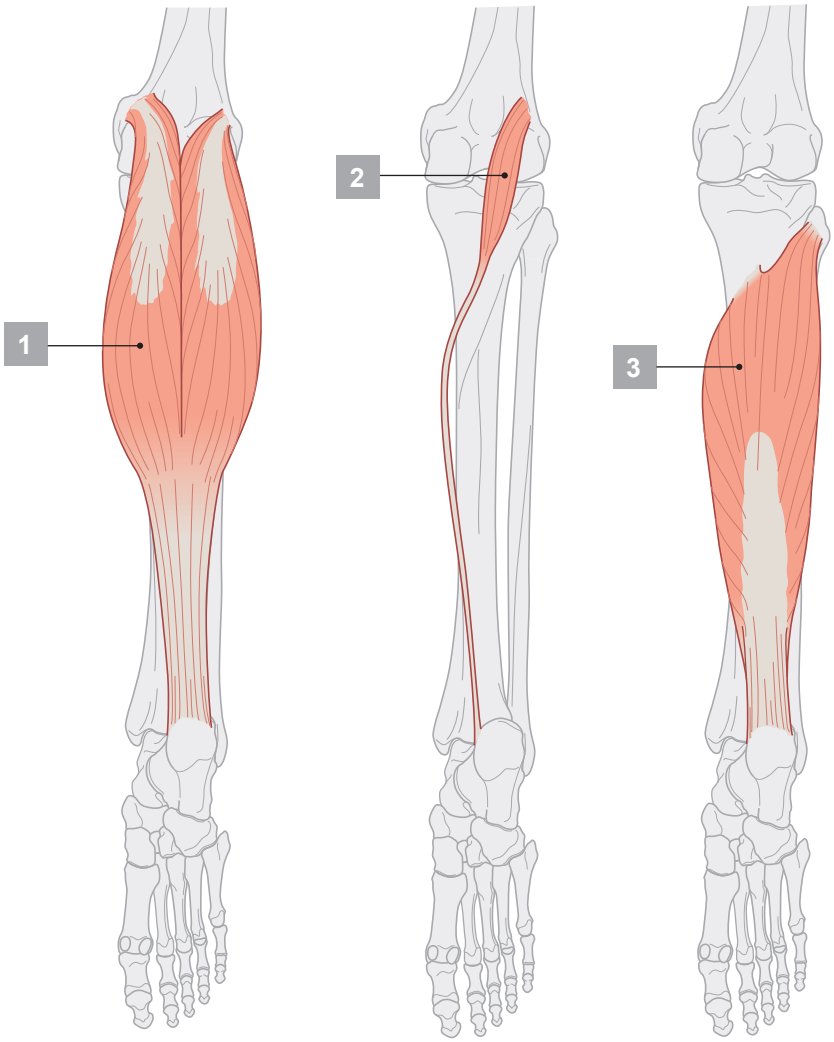

Deep group of muscles in the posterior compartment of leg

(spinal segments in bold are the major segments innervating the muscle)

Muscle		Origin	Insertion	Innervation	Function
Popliteus	1	Lateral femoral condyle	Posterior surface of proximal tibia	Tibial nerve [L4 to S1]	Stabilizes knee joint (resists lateral rotation of tibia on femur) Unlocks knee joint (laterally rotates femur on fixed tibia)
Flexor hallucis longus	2	Posterior surface of fibula and adjacent interosseous membrane	Plantar surface of distal phalanx of great toe	Tibial nerve [**S2**, S3]	Flexes great toe
Flexor digitorum longus	3	Medial side of posterior surface of the tibia	Plantar surfaces of bases of distal phalanges of the lateral four toes	Tibial nerve [**S2**, S3]	Flexes lateral four toes
Tibialis posterior	4	Posterior surfaces of interosseous membrane and adjacent regions of tibia and fibula	Mainly to tuberosity of navicular and adjacent region of medial cuneiform	Tibial nerve [L4, L5]	Inversion and plantarflexion of foot; support of medial arch of foot during walking

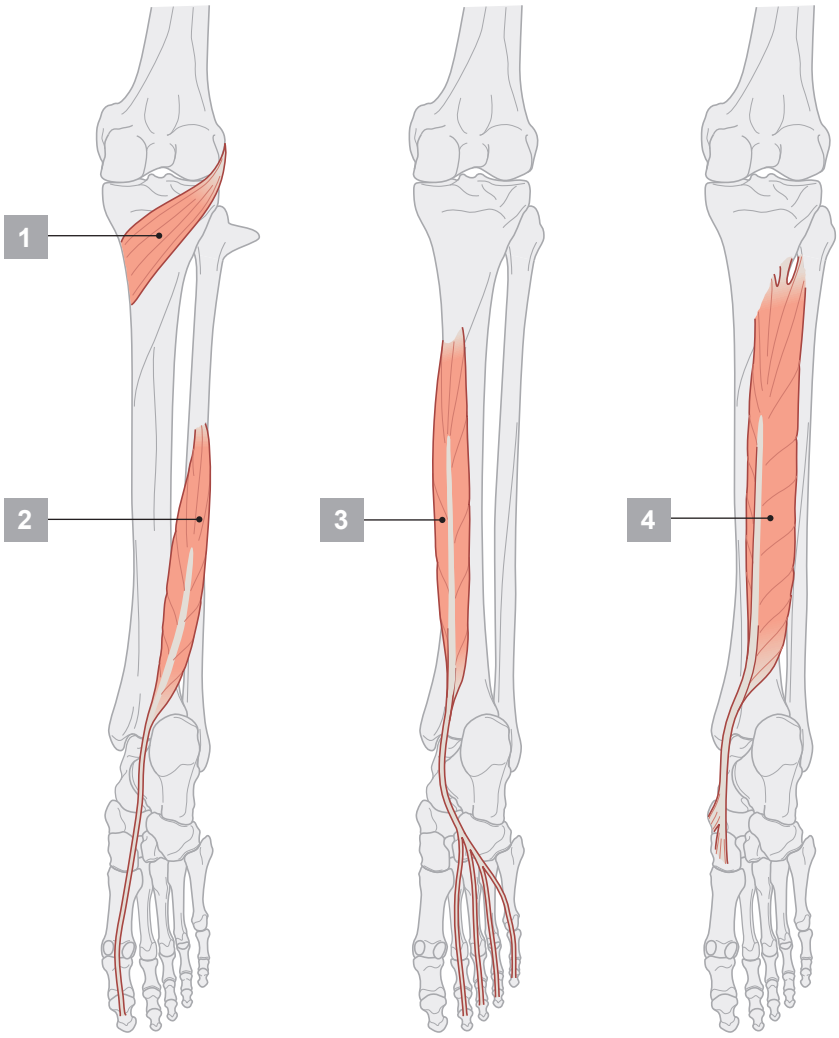

Muscles of the lateral compartment of leg

(spinal segments in bold are the major segments innervating the muscle)

Muscle		Origin	Insertion	Innervation	Function
Fibularis longus	1	Upper lateral surface of fibula, head of fibula, and occasionally the lateral tibial condyle	Undersurface of lateral sides of distal end of medial cuneiform and base of metatarsal I	Superficial fibular nerve [**L5**, **S1**, S2]	Eversion and plantarflexion of foot; supports arches of foot
Fibularis brevis	2	Lower two thirds of lateral surface of shaft of fibula	Lateral tubercle at base of metatarsal V	Superficial fibular nerve [**L5**, **S1**, S2]	Eversion of foot

Muscles of the anterior compartment of leg

Tibialis anterior	3	Lateral surface of tibia and adjacent interosseous membrane	Medial and inferior surfaces of medial cuneiform and adjacent surfaces on base of metatarsal I	Deep fibular nerve [**L4**, L5]	Dorsiflexion of foot at ankle joint; inversion of foot; dynamic support of medial arch of foot
Extensor hallucis longus	4	Middle one half of medial surface of fibula and adjacent surface of interosseous membrane	Dorsal surface of base of distal phalanx of great toe	Deep fibular nerve [**L5**, **S1**]	Extension of great toe and dorsiflexion of foot
Extensor digitorum longus	5	Proximal one half of medial surface of fibula and related surface of lateral tibial condyle	Via dorsal digital expansions into bases of distal and middle phalanges of lateral four toes	Deep fibular nerve [**L5**, **S1**]	Extension of lateral four toes and dorsiflexion of foot
Fibularis tertius	6	Distal part of medial surface of fibula	Dorsomedial surface of base of metatarsal V	Deep fibular nerve [**L5**, **S1**]	Dorsiflexion and eversion of foot

Muscles of the dorsal aspect of the foot

Extensor digitorum brevis	7	Superolateral surface of the calcaneus	Lateral sides of the tendons of extensor digitorum longus of toes II to IV	Deep fibular nerve [**S1**, **S2**]	Extension of metatarsophalangeal joints of toes II to IV
Extensor hallucis brevis	8	Superolateral surface of calcaneus	Base of proximal phalanx of great toe	Deep fibular nerve [S1, S2]	Extension of metatarsophalangeal joint of great toe

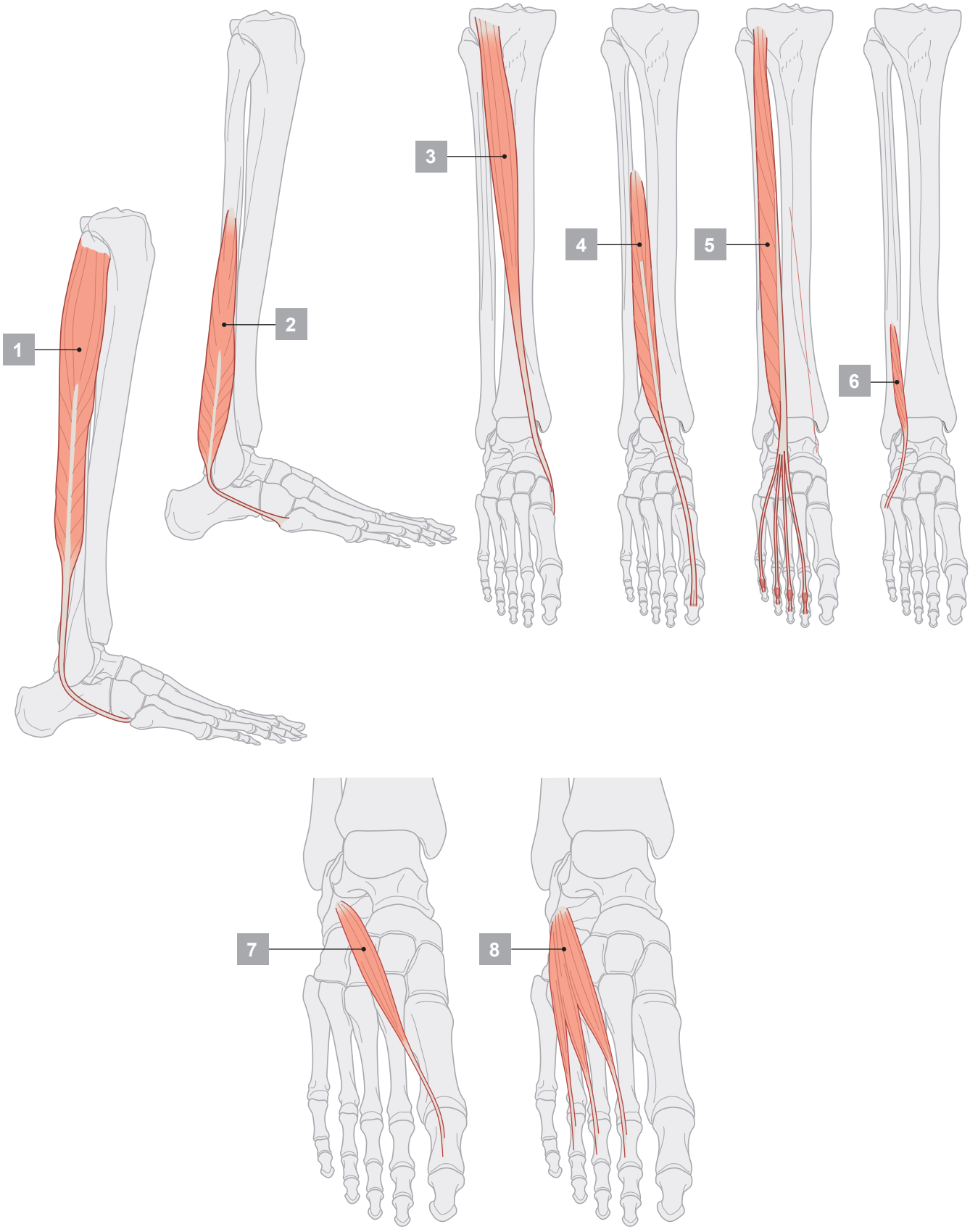
1
2
3
4
5
6
7
8

First layer of muscles in the sole of the foot

(spinal segments in bold are the major segments innervating the muscle)

Muscle		Origin	Insertion	Innervation	Function
Abductor hallucis	1	Medial process of calcaneal tuberosity	Medial side of base of proximal phalanx of great toe	Medial plantar nerve from the tibial nerve [**S1**, **S2**, **S3**]	Abducts and flexes great toe at metatarsophalangeal joint
Flexor digitorum brevis	2	Medial process of calcaneal tuberosity and plantar aponeurosis	Sides of plantar surface of middle phalanges of lateral four toes	Medial plantar nerve from the tibial nerve [**S1**, **S2**, **S3**]	Flexes lateral four toes at proximal interphalangeal joint
Abductor digiti minimi	3	Lateral and medial processes of calcaneal tuberosity, and band of connective tissue connecting calcaneus with base of metatarsal V	Lateral side of base of proximal phalanx of little toe	Lateral plantar nerve from the tibial nerve [**S1**, **S2**, **S3**]	Abducts little toe at the metatarsophalangeal joint

Second layer of muscles in the sole of the foot

Quadratus plantae	4	Medial surface of calcaneus and lateral process of calcaneal tuberosity	Lateral side of tendon of flexor digitorum longus in proximal sole of the foot	Lateral plantar nerve from tibial nerve [**S1**, **S2**, **S3**]	Assists flexor digitorum longus tendon in flexing toes II to V
Lumbricals	5	First lumbrical—medial side of tendon of flexor digitorum longus associated with toe II; second, third, and fourth lumbricals—adjacent surfaces of adjacent tendons of flexor digitorum longus	Medial free margins of extensor hoods of toes II to V	First lumbrical—medial plantar nerve from the tibial nerve; second, third, and fourth lumbricals—lateral plantar nerve from the tibial nerve [**S2**, **S3**]	Flexion of metatarsophalangeal joint and extension of interphalangeal joints

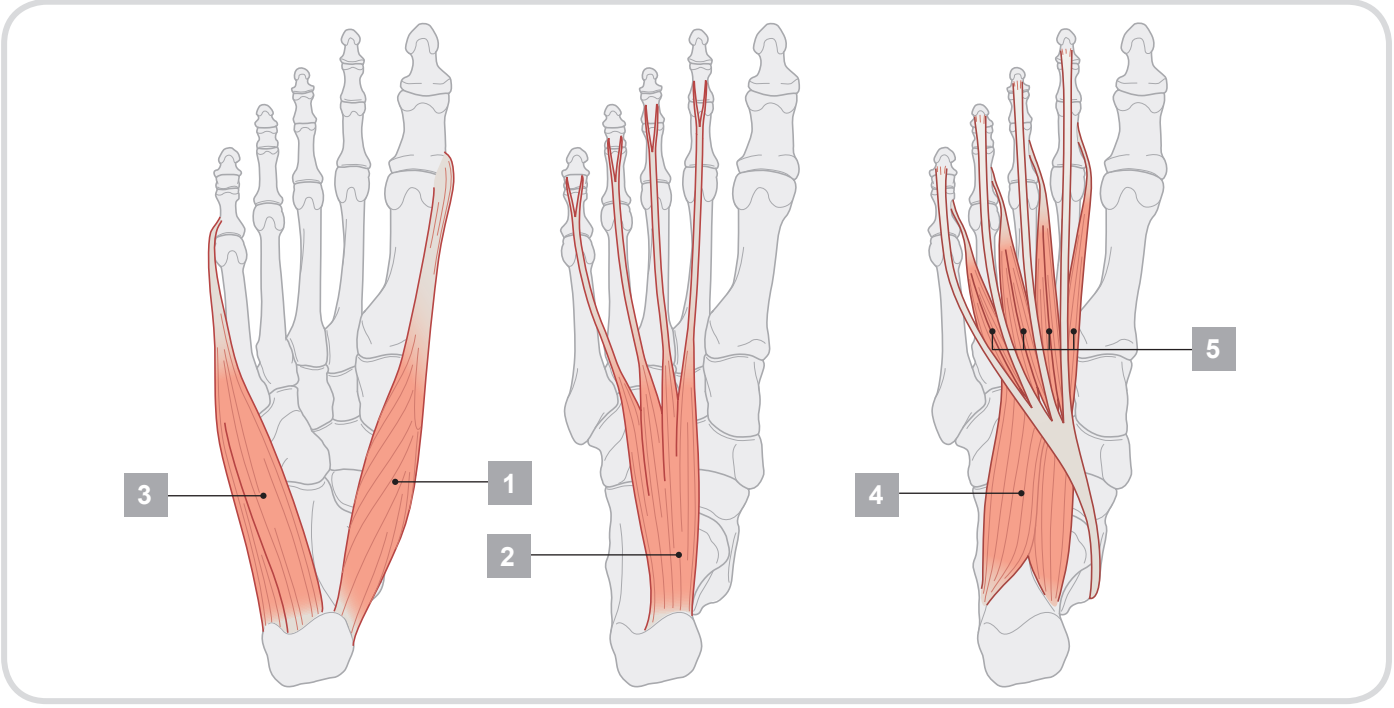

Third layer of muscles in the sole of the foot

(spinal segments in bold are the major segments innervating the muscle)

Muscle		Origin	Insertion	Innervation	Function
Flexor digiti minimi brevis	1	Base of metatarsal V and related sheath of fibularis longus tendon	Lateral side of base of proximal phalanx of little toe	Lateral plantar nerve from tibial nerve [**S2**, **S3**]	Flexes little toe at metatarsophalangeal joint
Flexor hallucis brevis	2	Plantar surface of cuboid and lateral cuneiform; tendon of tibialis posterior	Lateral and medial sides of base of proximal phalanx of the great toe	Medial plantar nerve from tibial nerve [**S1**, S2]	Flexes metatarsophalangeal joint of the great toe
Adductor hallucis	3	Transverse head—ligaments associated with metatarsophalangeal joints of lateral three toes; oblique head—bases of metatarsals II to IV and from sheath covering fibularis longus	Lateral side of base of proximal phalanx of great toe	Lateral plantar nerve from tibial nerve [**S2**, **S3**]	Adducts great toe at metatarsophalangeal joint

Fourth layer of muscles in the sole of the foot

Dorsal interossei	4	Sides of adjacent metatarsals	Extensor hoods and bases of proximal phalanges of toes II to IV	Lateral plantar nerve from tibial nerve; first and second dorsal interossei also innervated by deep fibular nerve [**S2**, **S3**]	Abduction of toes II to IV at metatarsophalangeal joints; resist extension of metatarsophalangeal joints and flexion of interphalangeal joints
Plantar interossei	5	Medial sides of metatarsals of toes III to V	Extensor hoods and bases of proximal phalanges of toes III to V	Lateral plantar nerve from tibial nerve [**S2**, **S3**]	Adduction of toes III to V at metatarsophalangeal joints; resist extension of the metatarsophalangeal joints and flexion of the interphalangeal joints

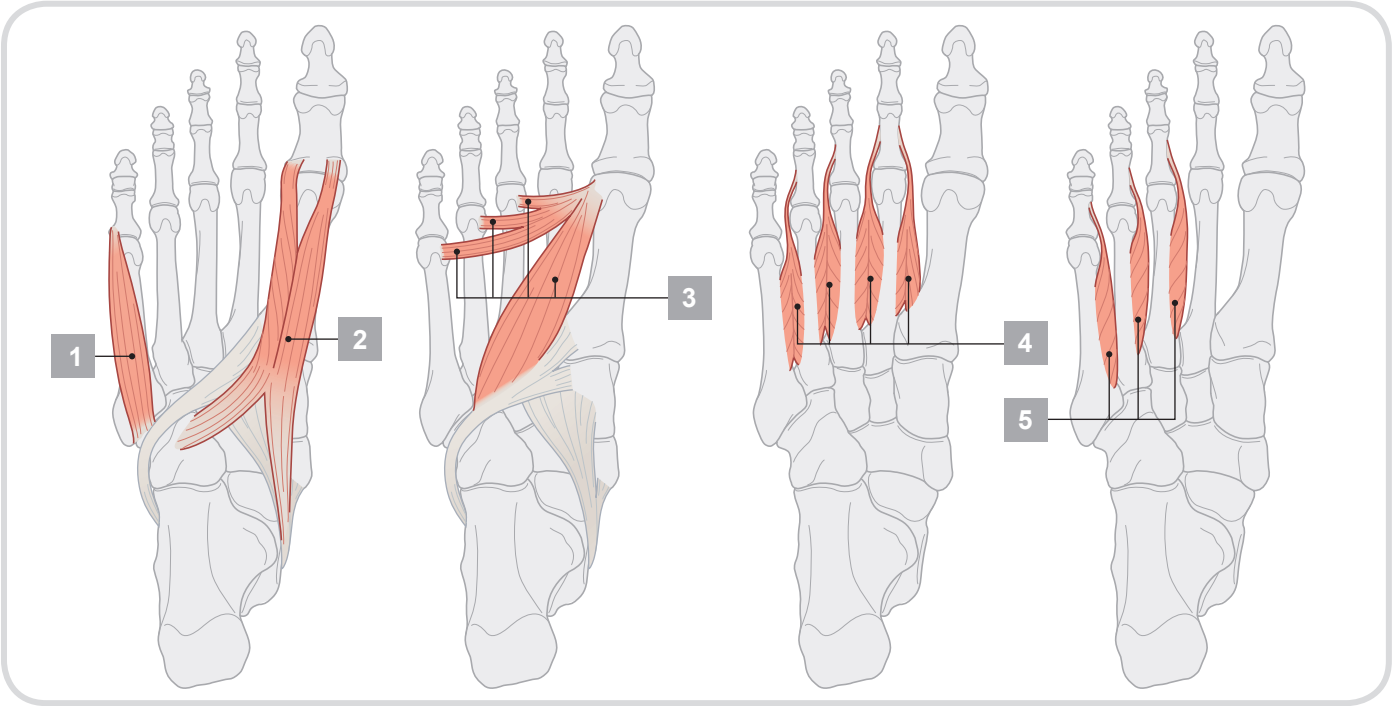

This page intentionally left blank

7

UPPER LIMB

CONTENTS

Surface anatomy **384**
Bones of the upper limb **385**
Bony framework of shoulder **386**
Scapula **387**
Clavicle: joints and ligaments **388**
Proximal humerus **389**
Glenohumeral joint **390**
Muscle attachments **392**
Pectoral region **394**
Deep pectoral region **395**
Walls of the axilla **396**
The four rotator cuff muscles **398**
Deep vessels and nerves of the shoulder **400**
Axillary artery **401**
Brachial artery **402**
Brachial plexus **403**
Medial and lateral cords **404**
Posterior cord **405**
Distal end of humerus and proximal end of radius and ulna **406**
Muscle attachments **407**
Anterior compartment: muscles **408**
Anterior compartment: arteries and nerves **410**
Veins of the arm **411**
Posterior compartment: muscles **412**
Posterior compartment: arteries and nerves **414**
Lymphatics of the arm **415**
Transverse sections: arm **416**
Anterior cutaneous nerves of the arm **418**
Posterior cutaneous nerves of the arm **419**
Elbow joint **420**
Elbow joint: capsule and ligaments **422**
Cubital fossa **424**
Radius and ulna **425**
Bones of the hand and wrist joint **426**
Imaging of the hand and wrist joint **427**
Bones of the hand **428**
Joints and ligaments of the hand **429**
Muscle attachments of forearm **430**
Anterior compartment of forearm: muscles **431**
Anterior compartment of forearm: arteries and nerves **434**
Posterior compartment of forearm: muscles **435**
Posterior compartment of forearm: arteries and nerves **437**
Transverse sections: forearm **438**
Carpal tunnel **440**
Muscle attachments of the hand **442**
Superficial palmar region (palm) of hand **443**
Tendon sheaths of hand **444**
Lumbrical muscles **445**
Intrinsic muscles of hand **446**
Palmar region (palm) of hand: arteries and nerves **448**
Arteries of the hand **450**
Innervation of the hand: median and ulnar nerves **451**
Dorsum of hand **452**
Dorsal hoods **453**
Dorsum of hand: arteries **454**
Dorsum of hand: nerves **455**
Anatomical snuffbox **456**
Superficial veins and lymphatics of forearm **457**
Anterior cutaneous nerves of forearm **458**
Posterior cutaneous nerves of upper limb **459**
Tables **460**

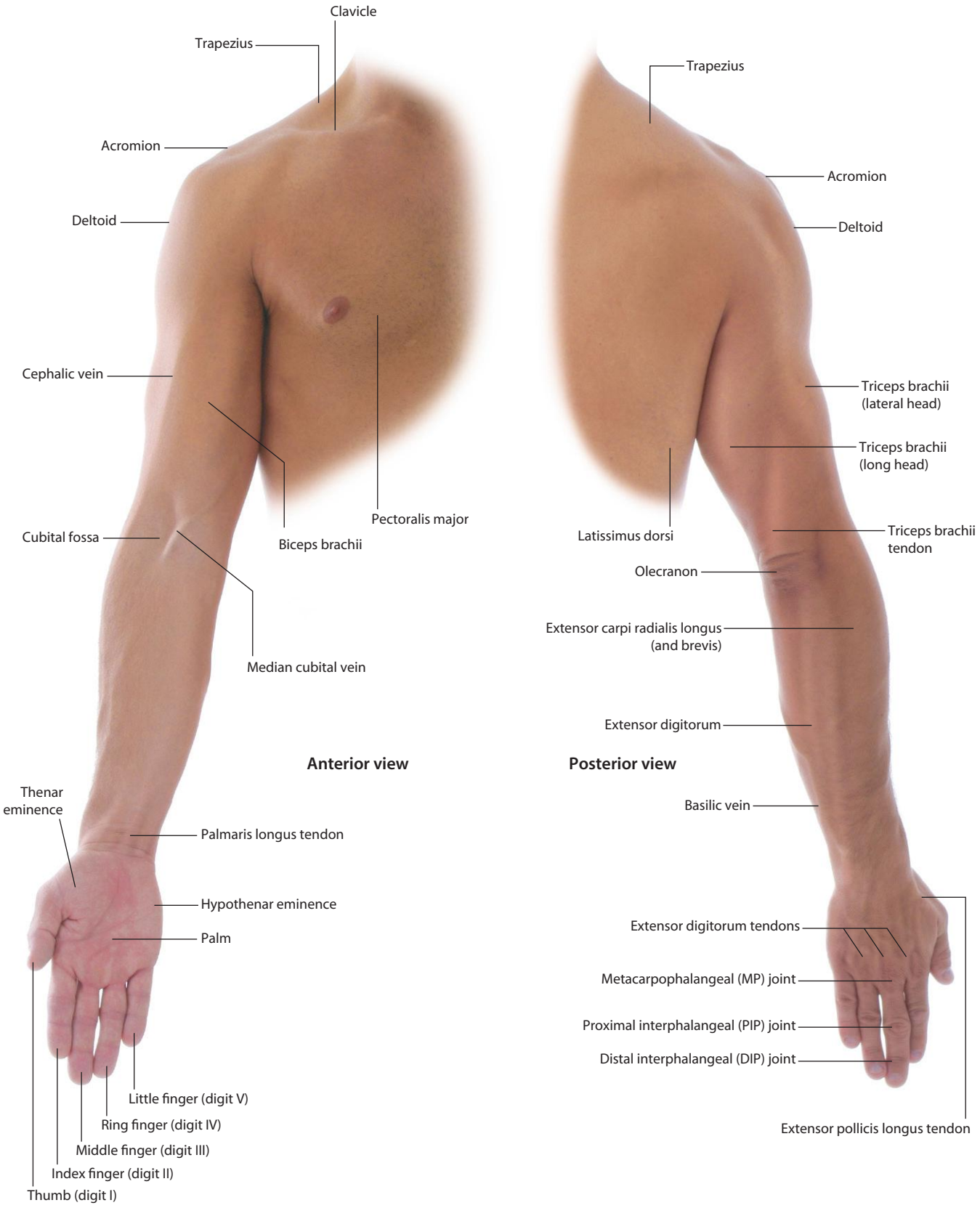
Clavicle
Trapezius
Acromion
Deltoid
Cephalic vein
Pectoralis major
Biceps brachii
Cubital fossa
Median cubital vein
Anterior view
Thenar eminence
Palmaris longus tendon
Hypothenar eminence
Palm
Little finger (digit V)
Ring finger (digit IV)
Middle finger (digit III)
Index finger (digit II)
Thumb (digit I)
Trapezius
Acromion
Deltoid
Triceps brachii (lateral head)
Triceps brachii (long head)
Latissimus dorsi
Triceps brachii tendon
Olecranon
Extensor carpi radialis longus (and brevis)
Extensor digitorum
Posterior view
Basilic vein
Extensor digitorum tendons
Metacarpophalangeal (MP) joint
Proximal interphalangeal (PIP) joint
Distal interphalangeal (DIP) joint
Extensor pollicis longus tendon

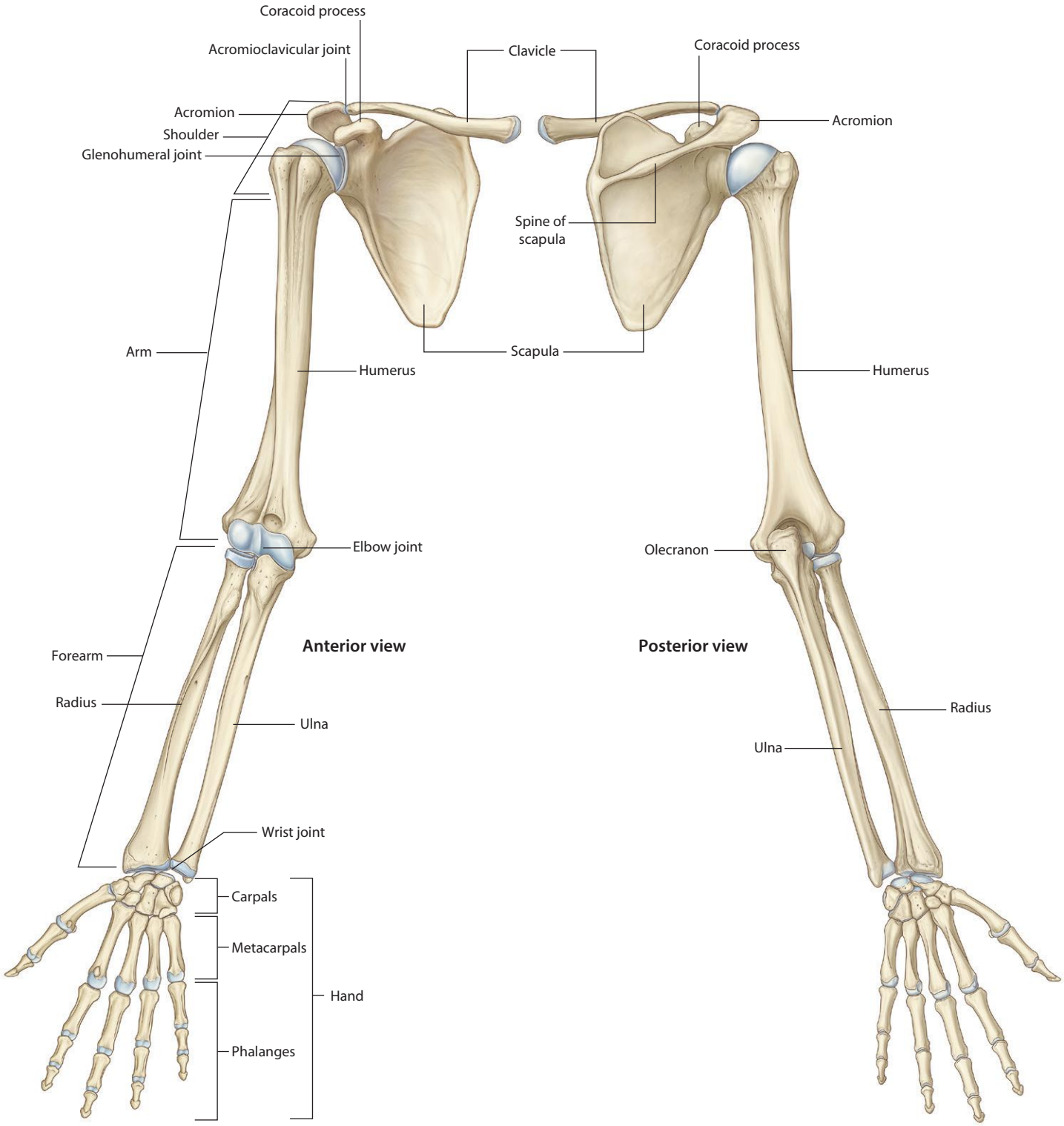
Coracoid process
Acromioclavicular joint
Clavicle
Acromion
Shoulder
Glenohumeral joint
Arm
Humerus
Elbow joint
Forearm
Radius
Ulna
Wrist joint
Carpals
Metacarpals
Phalanges
Hand
Anterior view
Coracoid process
Acromion
Spine of scapula
Scapula
Humerus
Olecranon
Radius
Ulna
Posterior view

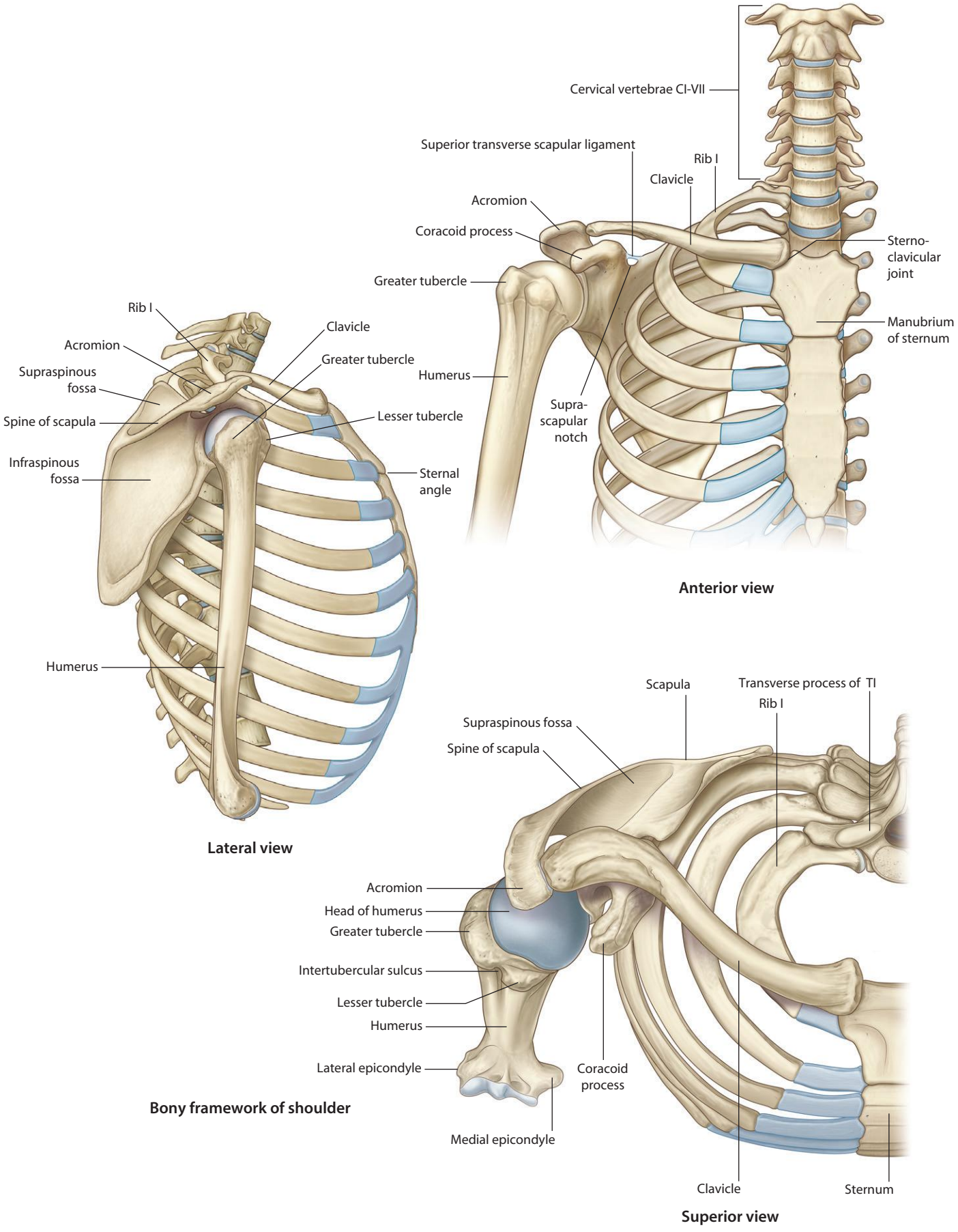
Cervical vertebrae CI-VII
Superior transverse scapular ligament
Rib I
Clavicle
Acromion
Coracoid process
Sterno-clavicular joint
Greater tubercle
Manubrium of sternum
Humerus
Supra-scapular notch
Anterior view
Rib I
Clavicle
Acromion
Supraspinous fossa
Greater tubercle
Spine of scapula
Lesser tubercle
Infraspinous fossa
Sternal angle
Humerus
Lateral view
Scapula
Transverse process of TI
Rib I
Supraspinous fossa
Spine of scapula
Acromion
Head of humerus
Greater tubercle
Intertubercular sulcus
Lesser tubercle
Humerus
Lateral epicondyle
Coracoid process
Medial epicondyle
Clavicle
Sternum
Superior view
Bony framework of shoulder

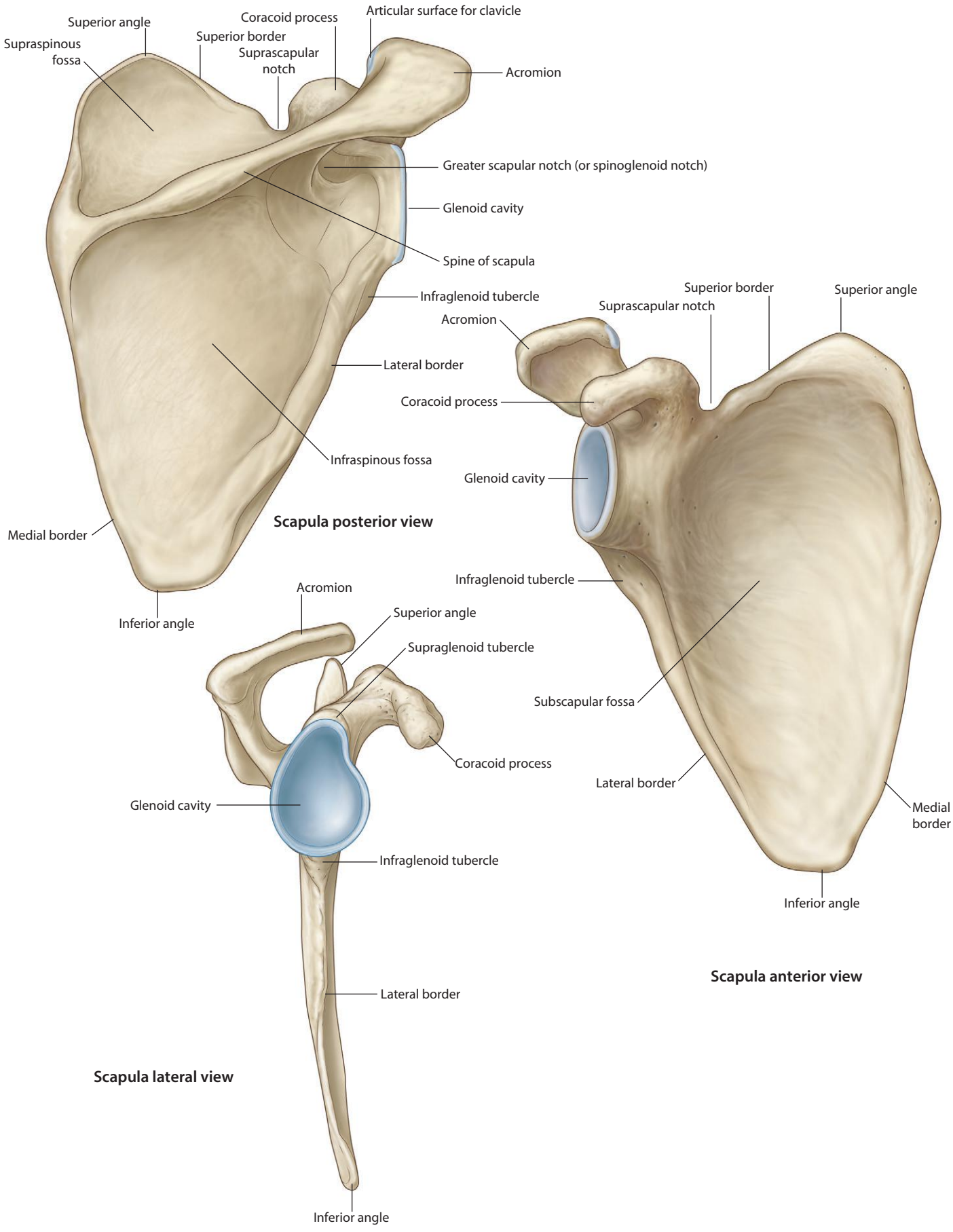
Superior angle
Supraspinous fossa
Superior border
Coracoid process
Suprascapular notch
Articular surface for clavicle
Acromion
Greater scapular notch (or spinoglenoid notch)
Glenoid cavity
Spine of scapula
Infraglenoid tubercle
Lateral border
Infraspinous fossa
Medial border
Inferior angle
Scapula posterior view
Superior border
Superior angle
Suprascapular notch
Acromion
Coracoid process
Glenoid cavity
Infraglenoid tubercle
Subscapular fossa
Lateral border
Medial border
Inferior angle
Scapula anterior view
Acromion
Superior angle
Supraglenoid tubercle
Coracoid process
Glenoid cavity
Infraglenoid tubercle
Lateral border
Inferior angle
Scapula lateral view

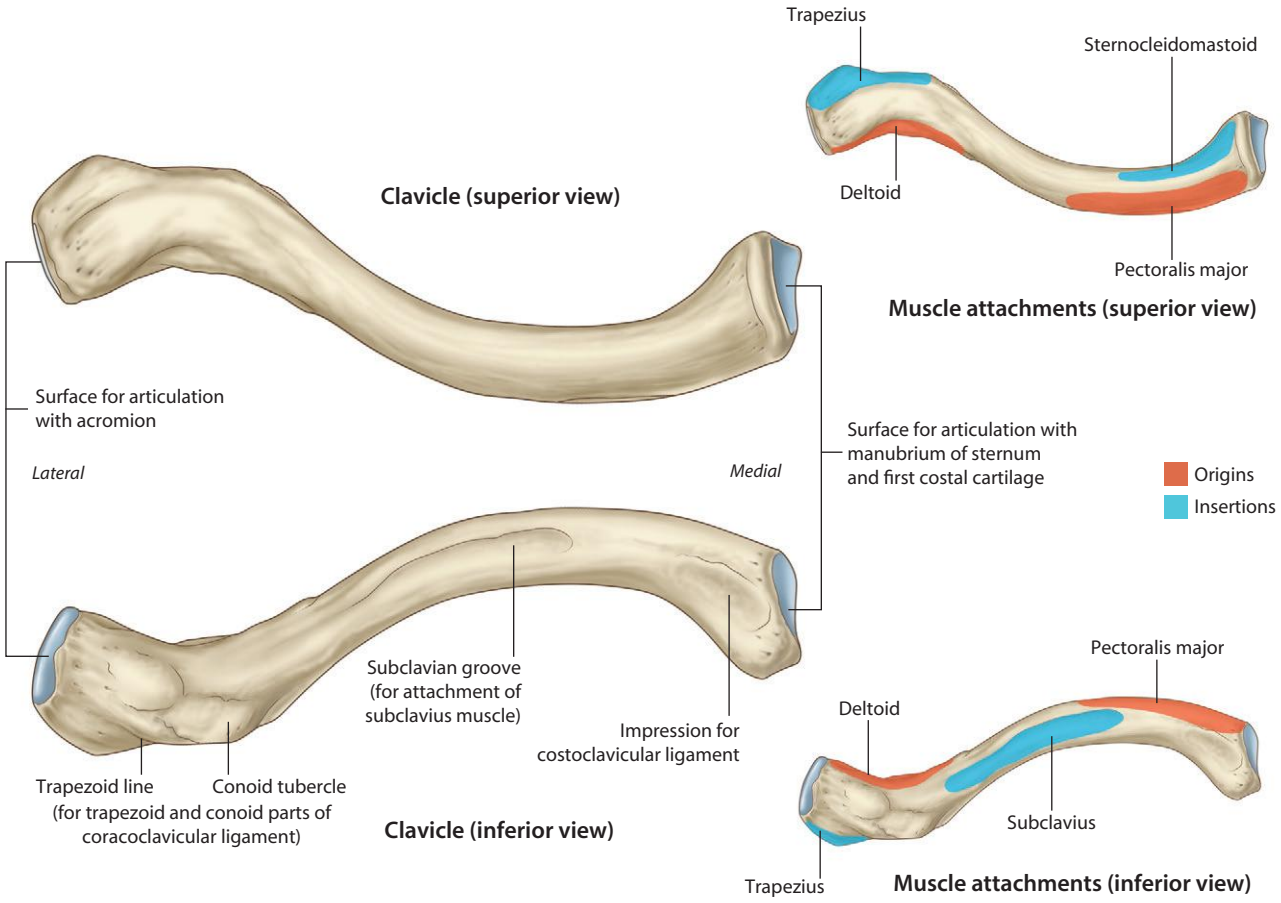

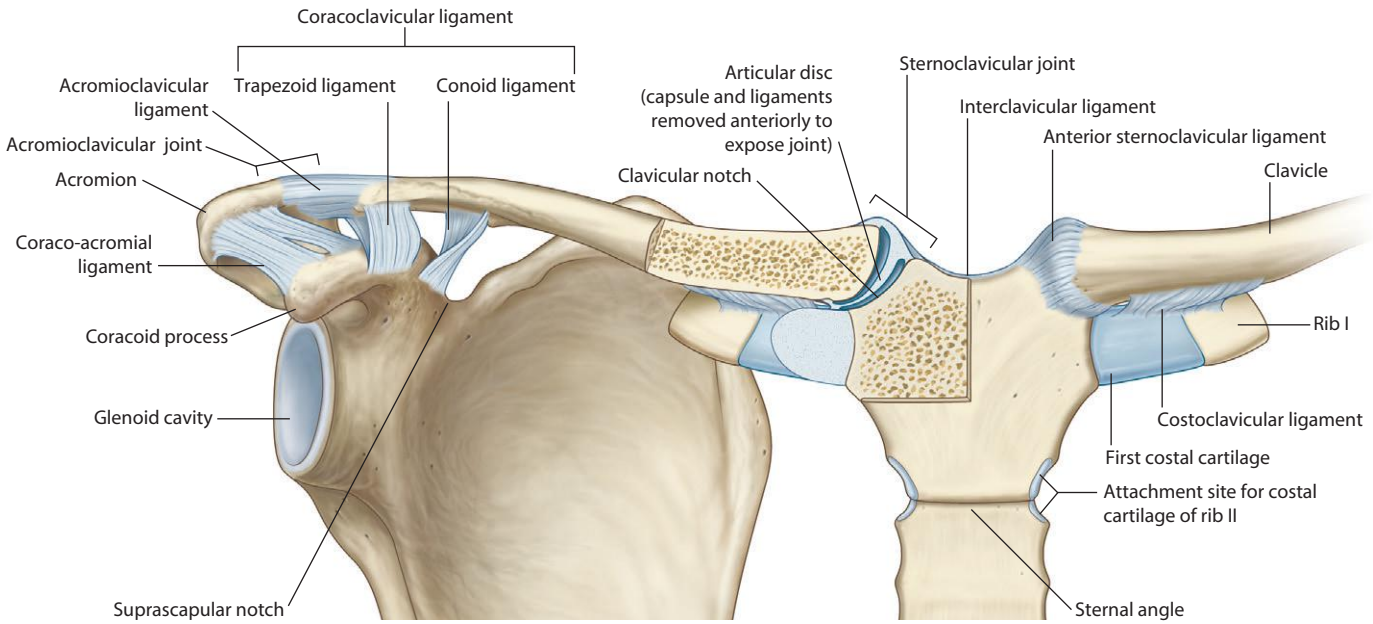

Joints and ligaments of the clavicle (anterior view)

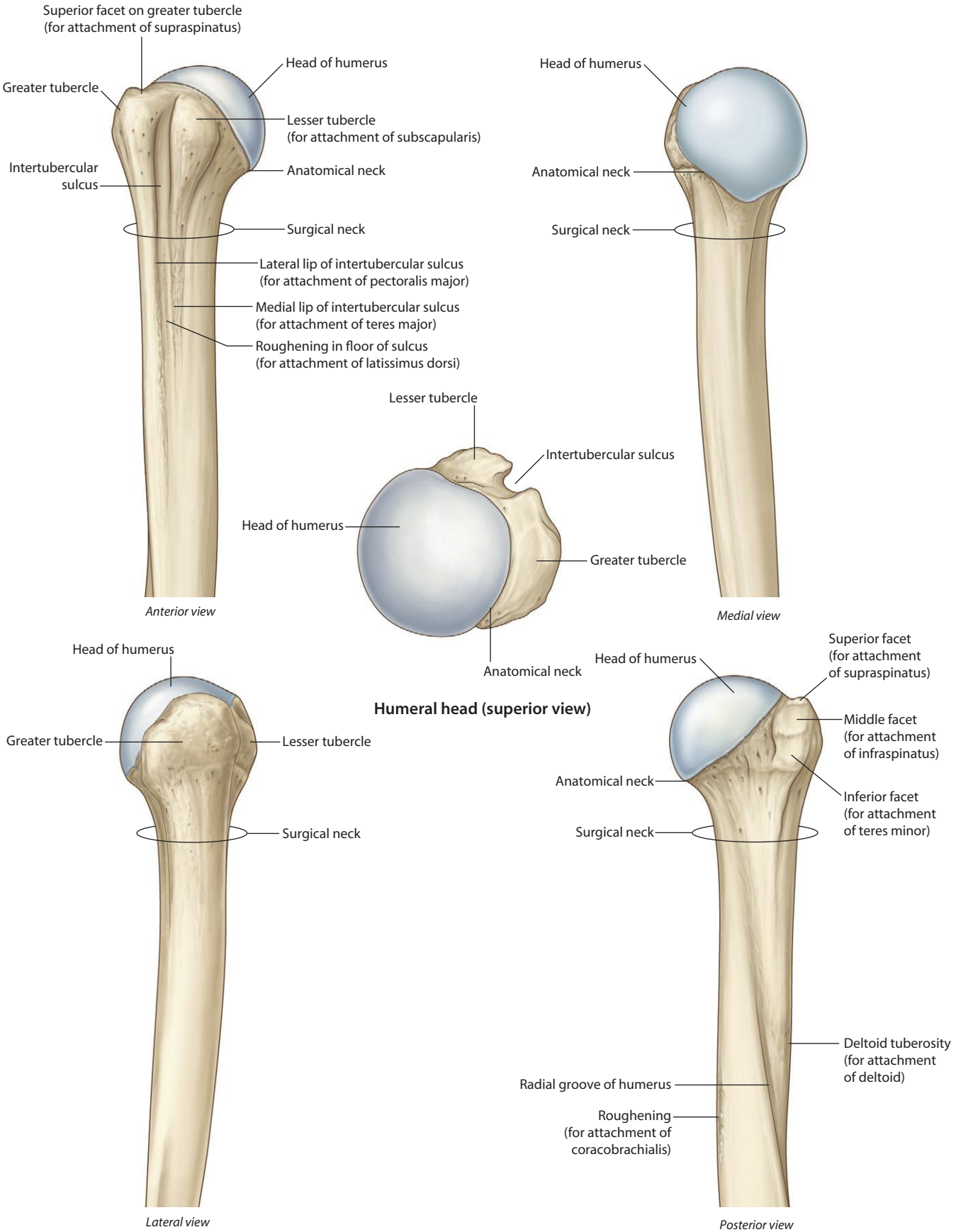

Proximal end of humerus

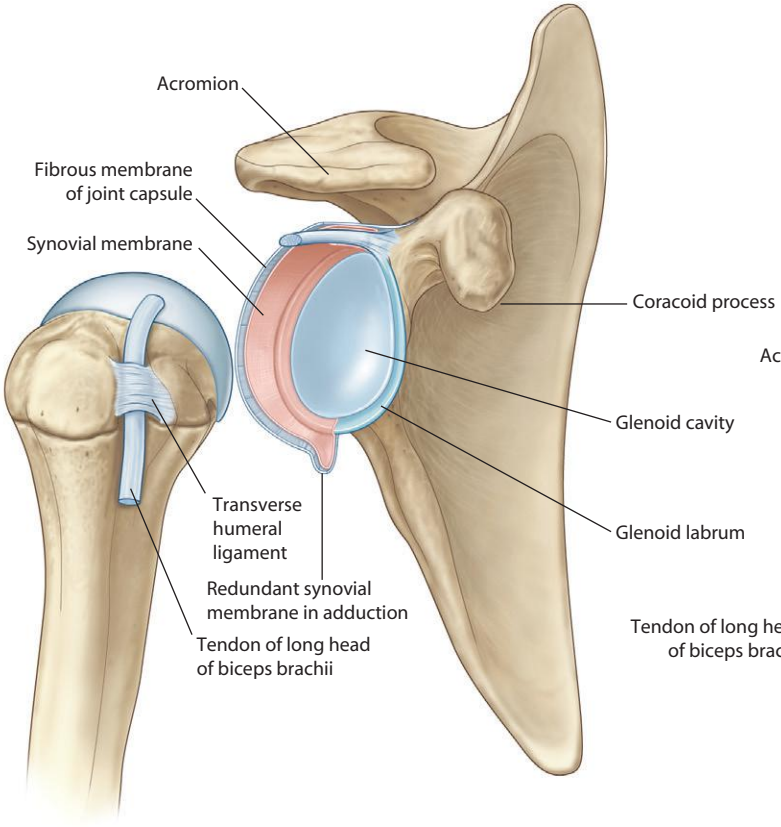

Articular surfaces of glenohumeral joint (anterolateral oblique view)

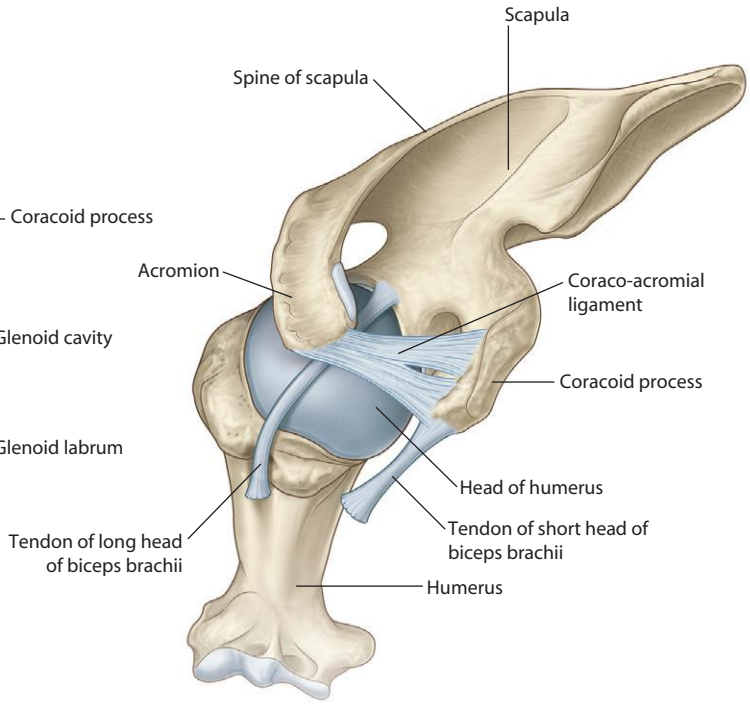

Origins of biceps brachii tendons (superior view)

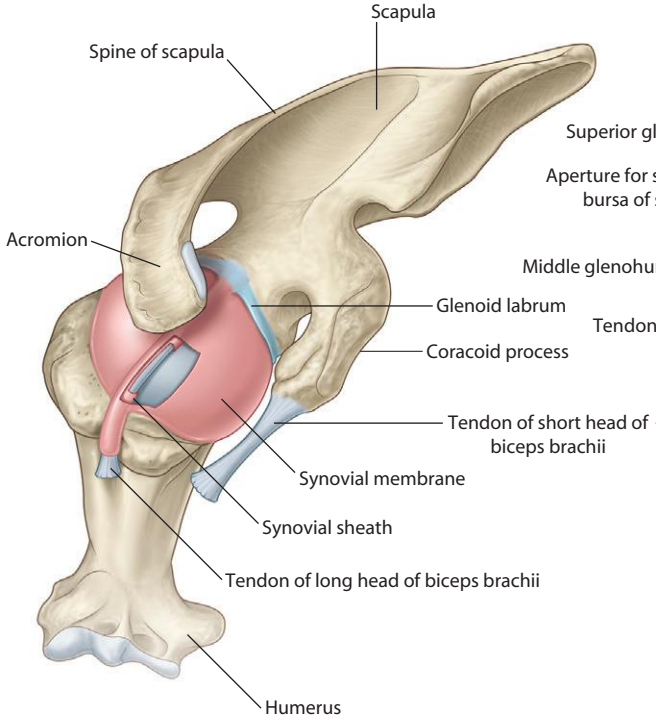

Synovial membrane (superior view)

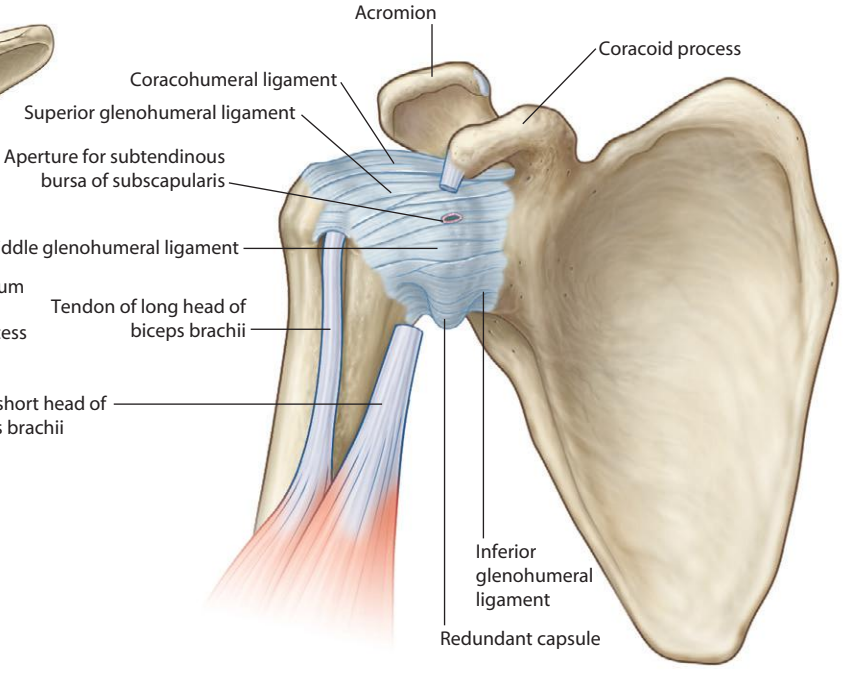

Fibrous membrane of joint capsule (anterior view)

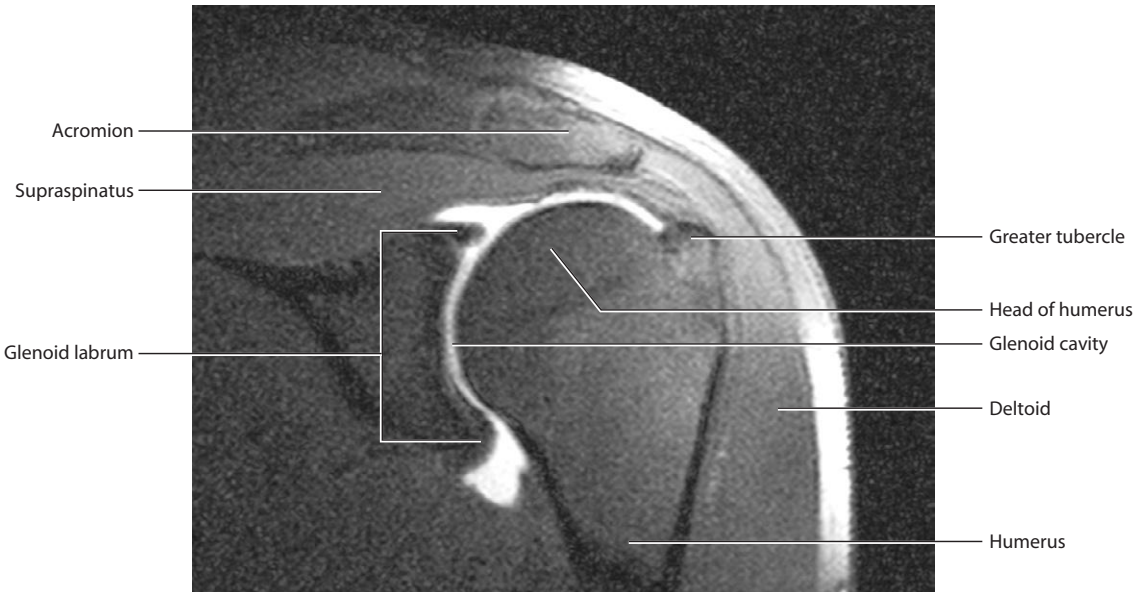

Anterior view of the glenohumeral joint.
T1-weighted MR image in coronal plane

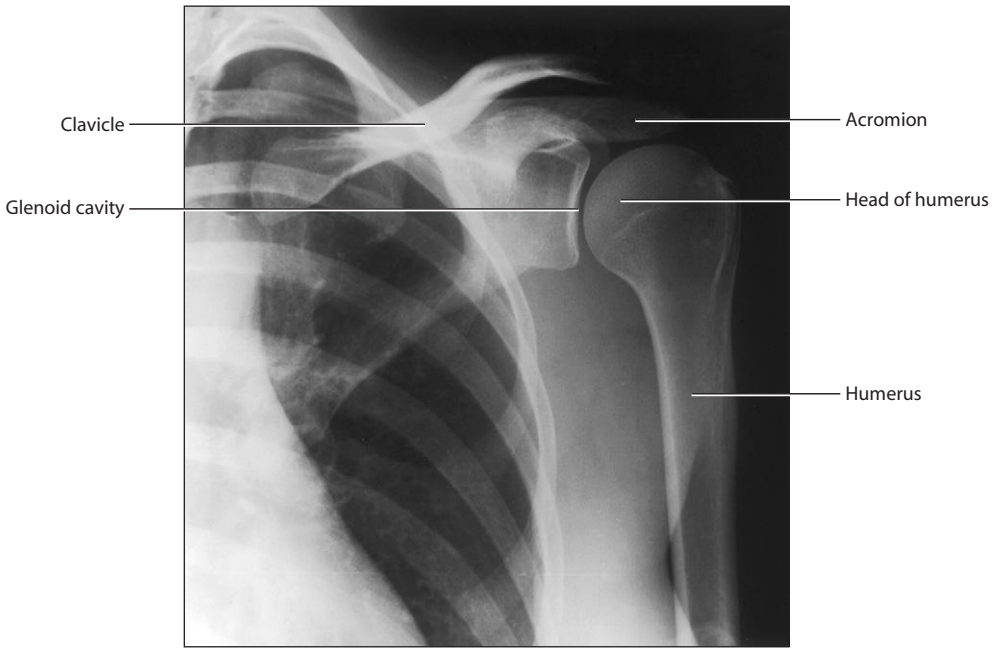

Normal glenohumeral joint.
Radiograph, AP view

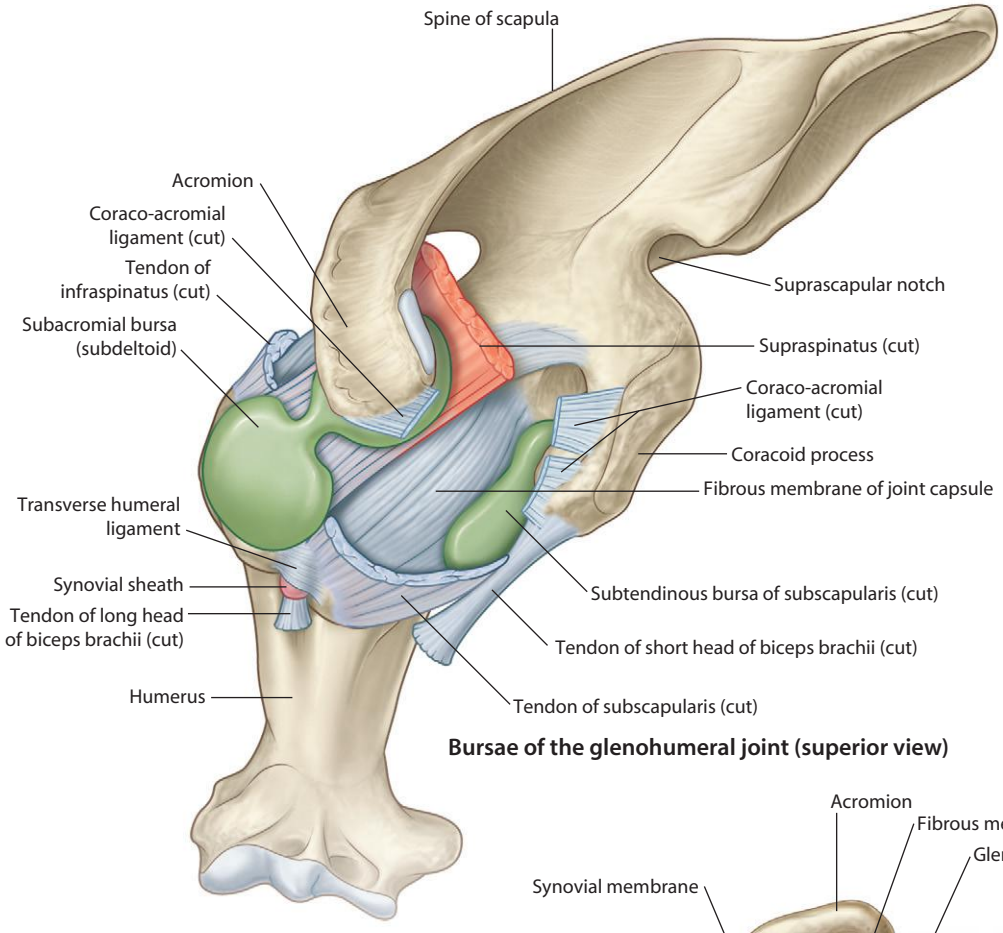

Bursae of the glenohumeral joint (superior view)

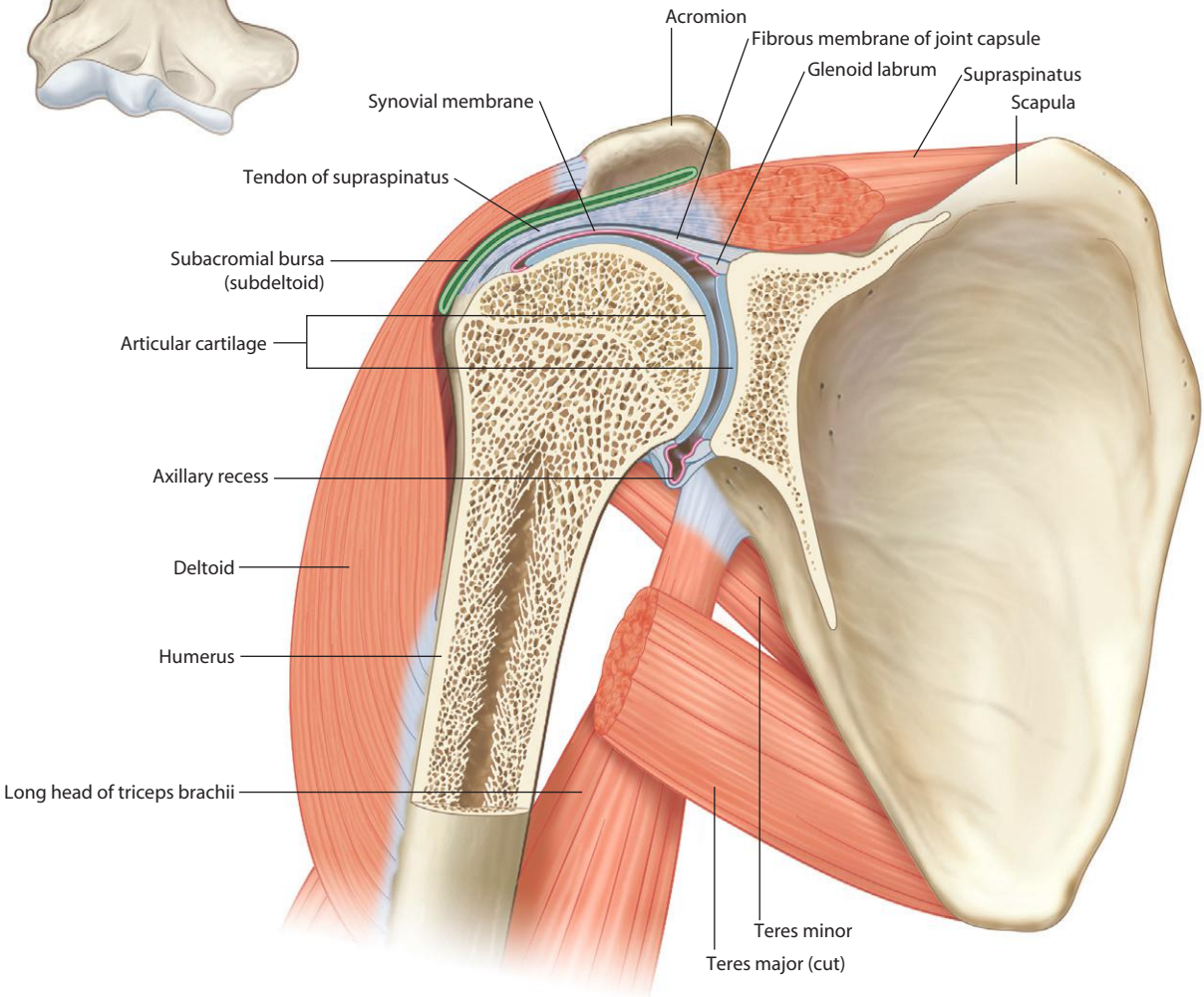

Glenohumeral joint (anterior view)

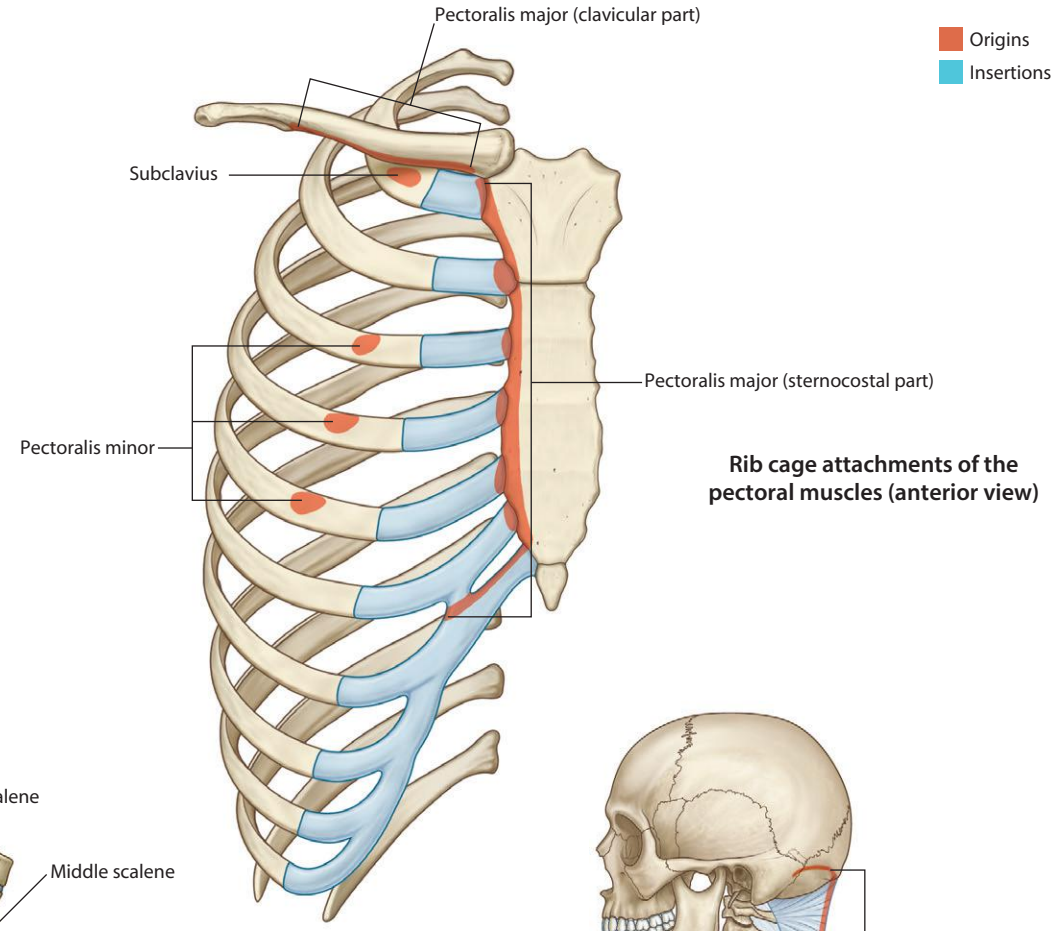

Rib cage attachments of the pectoral muscles (anterior view)

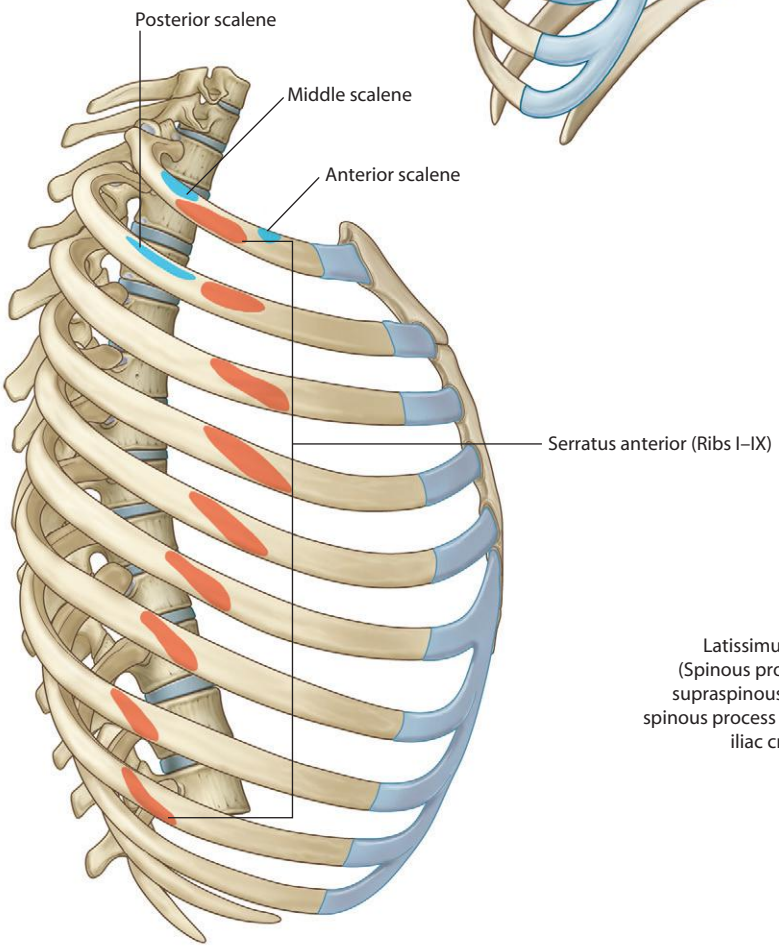

Rib cage attachments of serratus anterior and scalene muscles (lateral view)

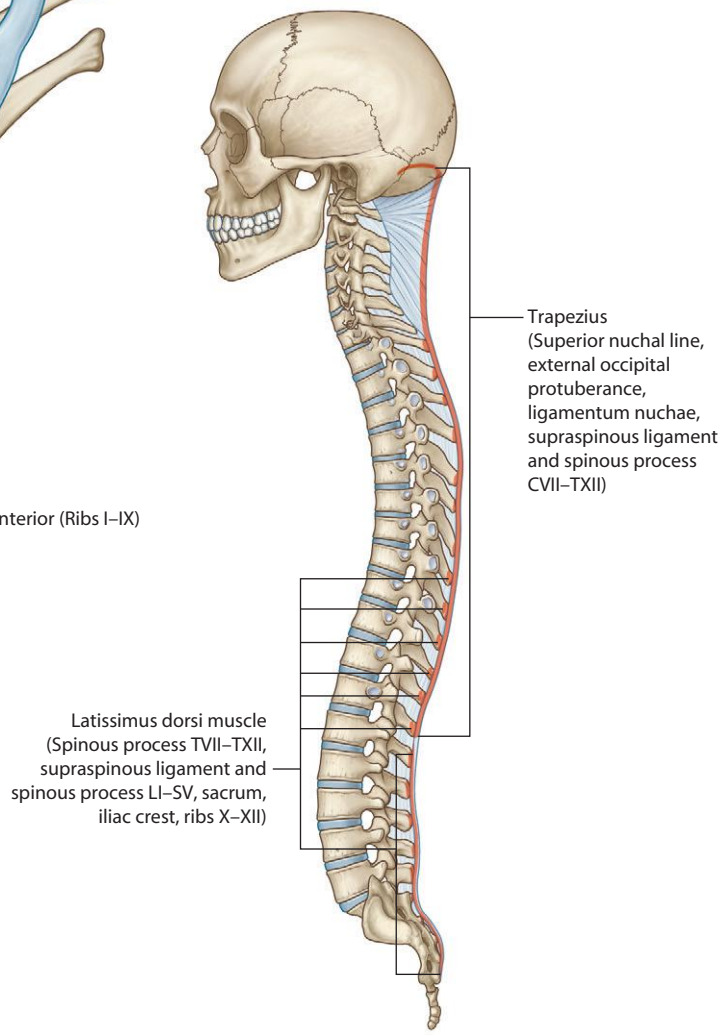

Attachments of trapezius and latissimus dorsi muscles (lateral view)

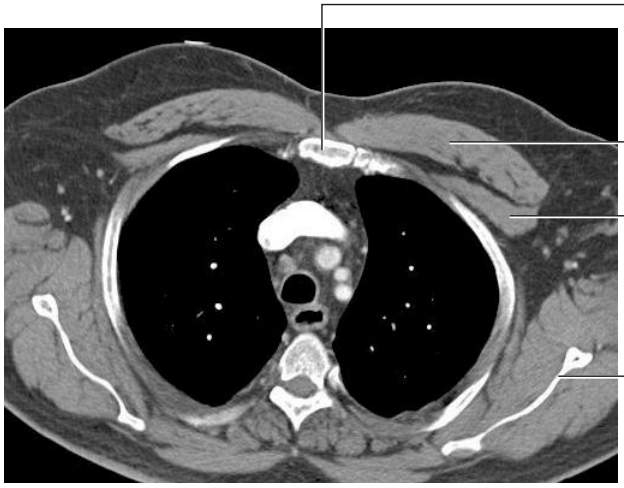

Pectoralis major and minor muscles on anterior thoracic wall.
CT image, with contrast, in axial plane

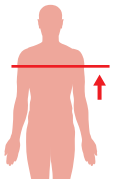

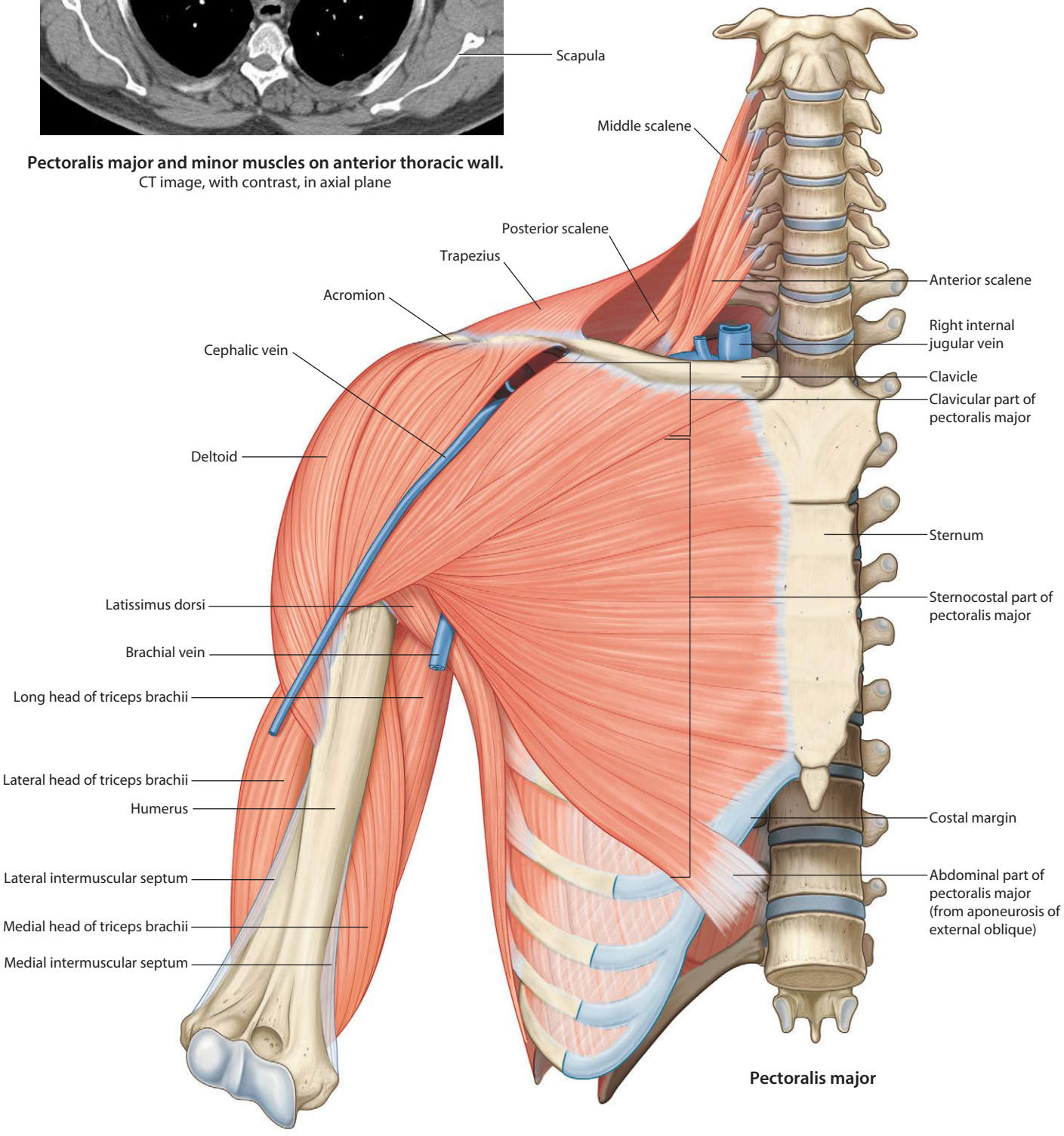

Pectoralis major

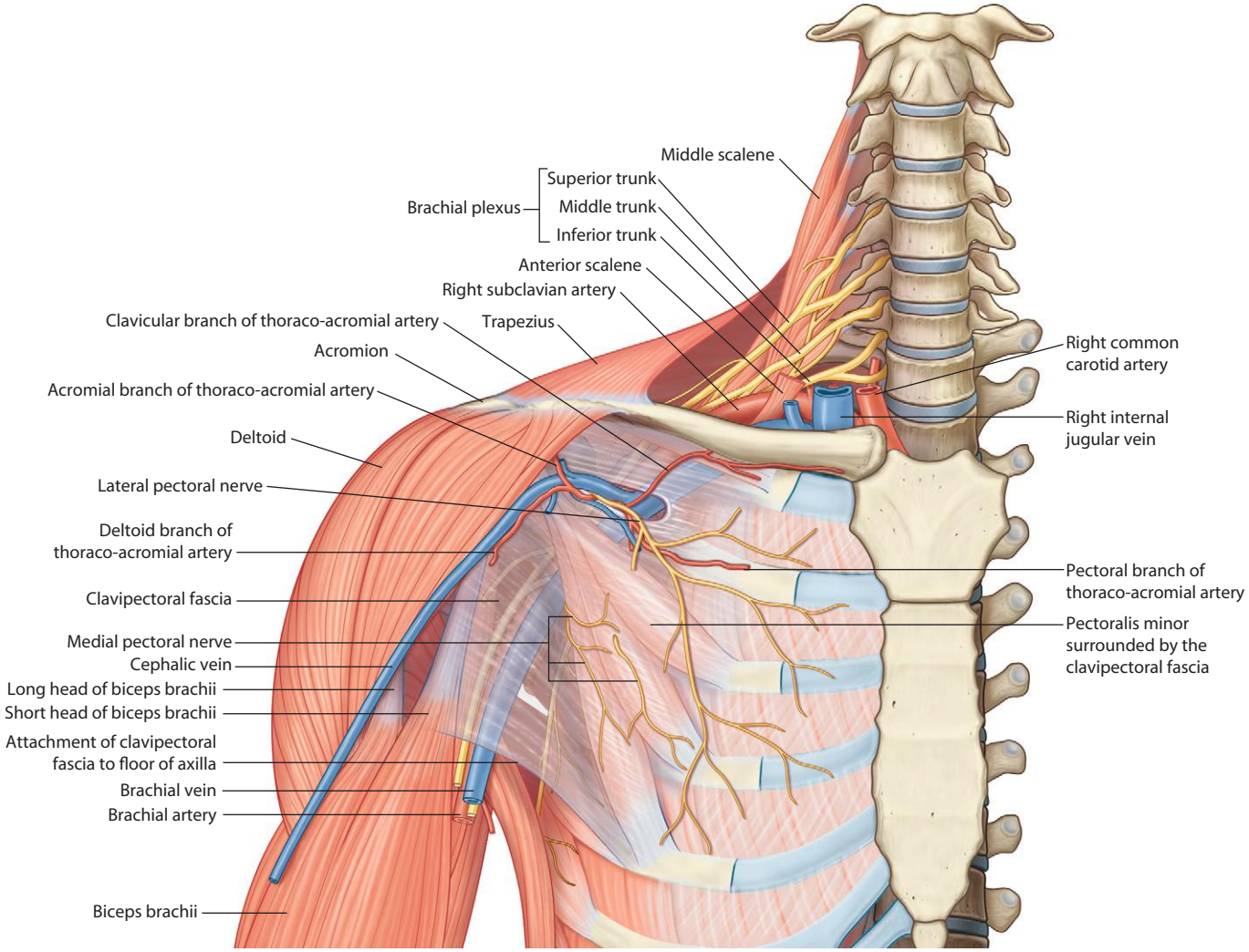

Clavipectoral fascia and related structures

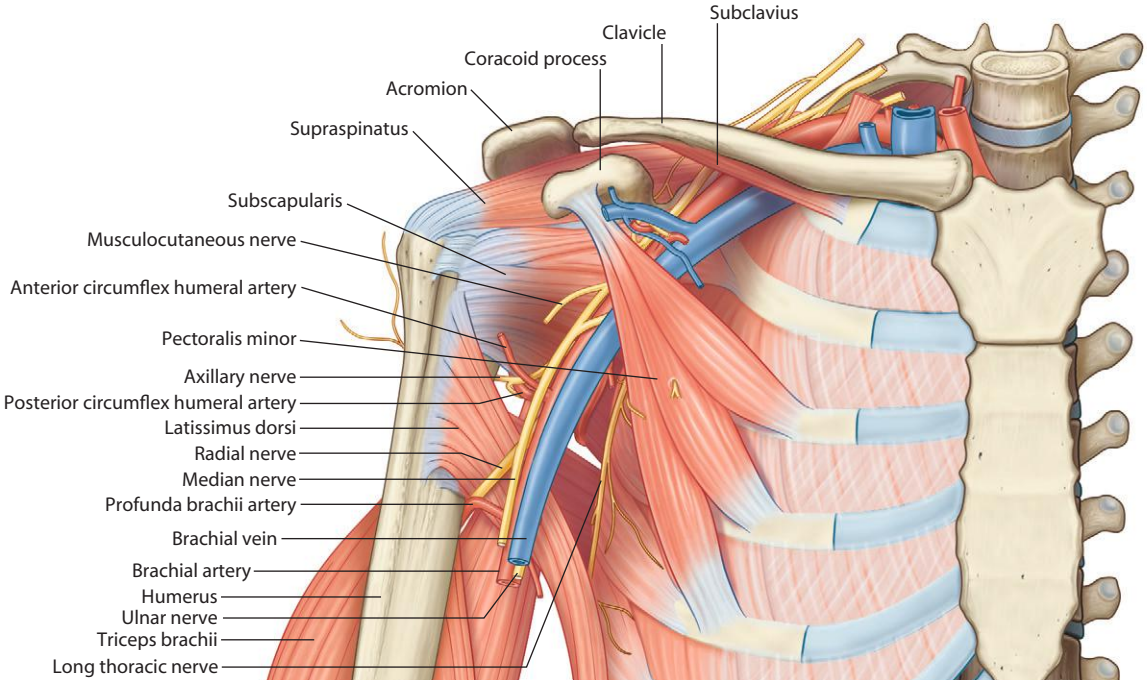

Pectoralis minor

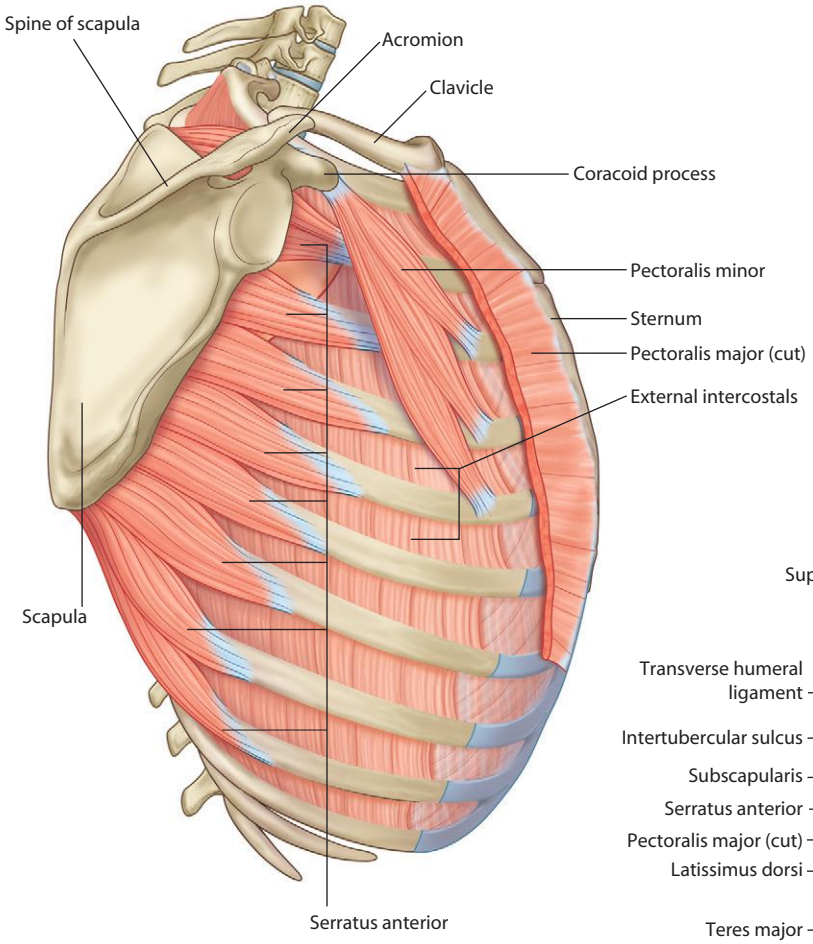

Medial and anterior walls of axilla

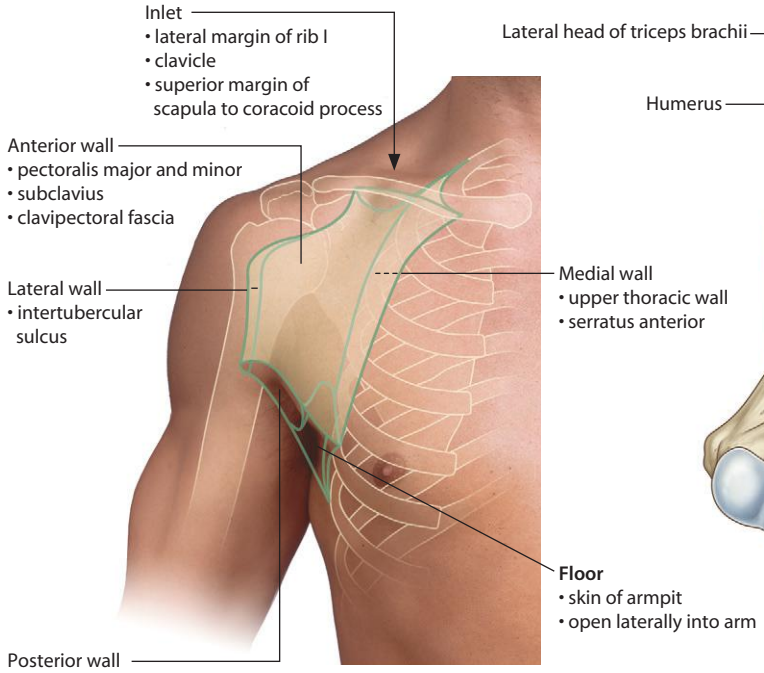

Boundaries of axilla

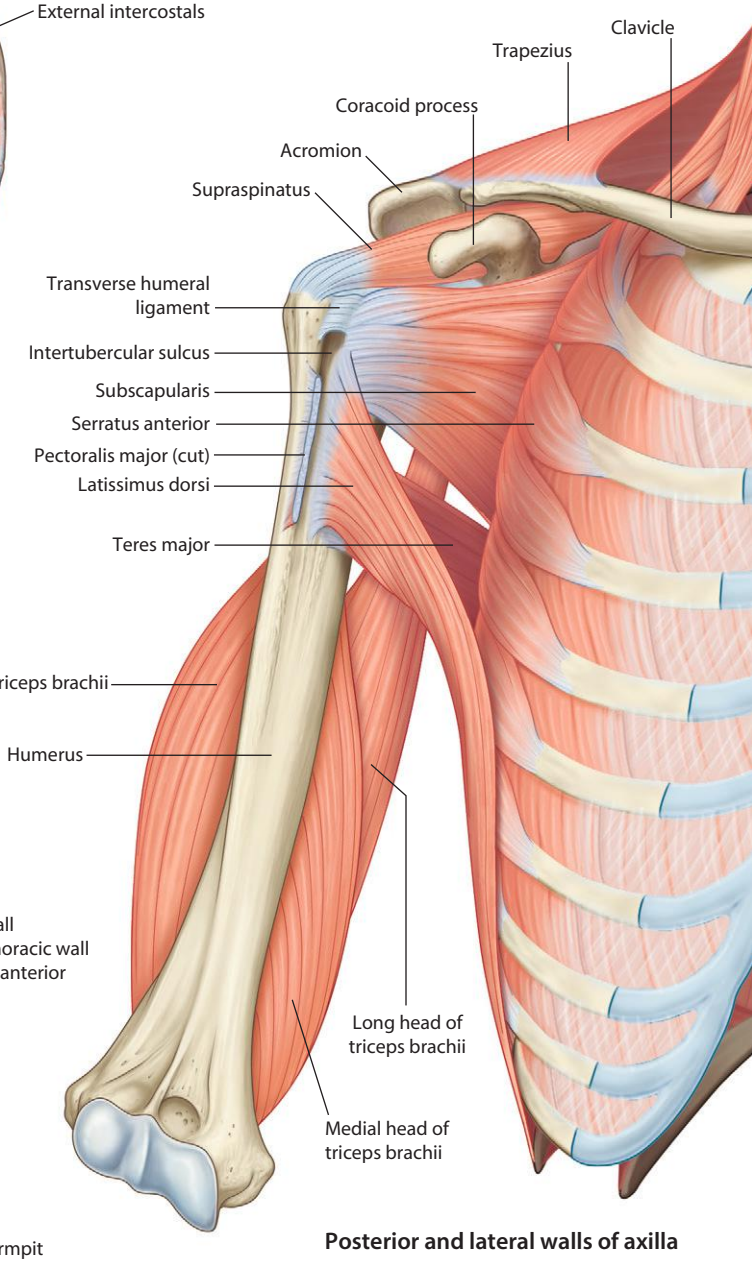

Posterior and lateral walls of axilla

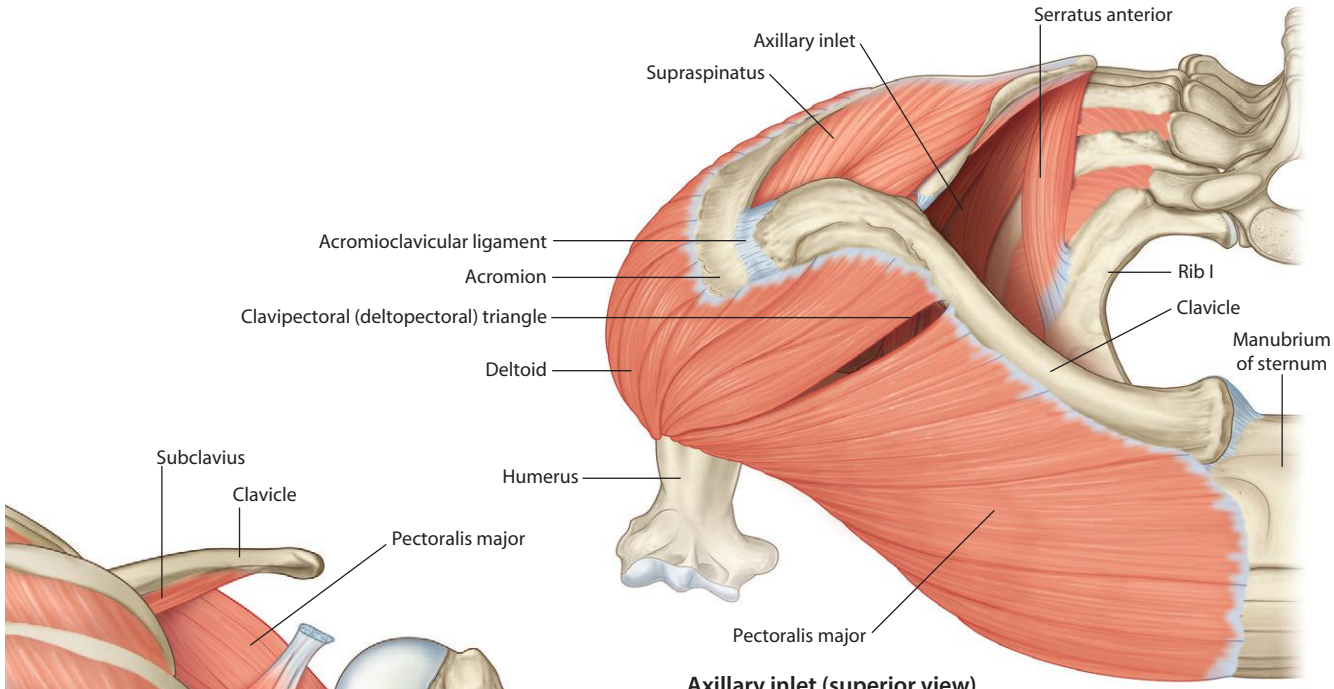

Axillary inlet (superior view)

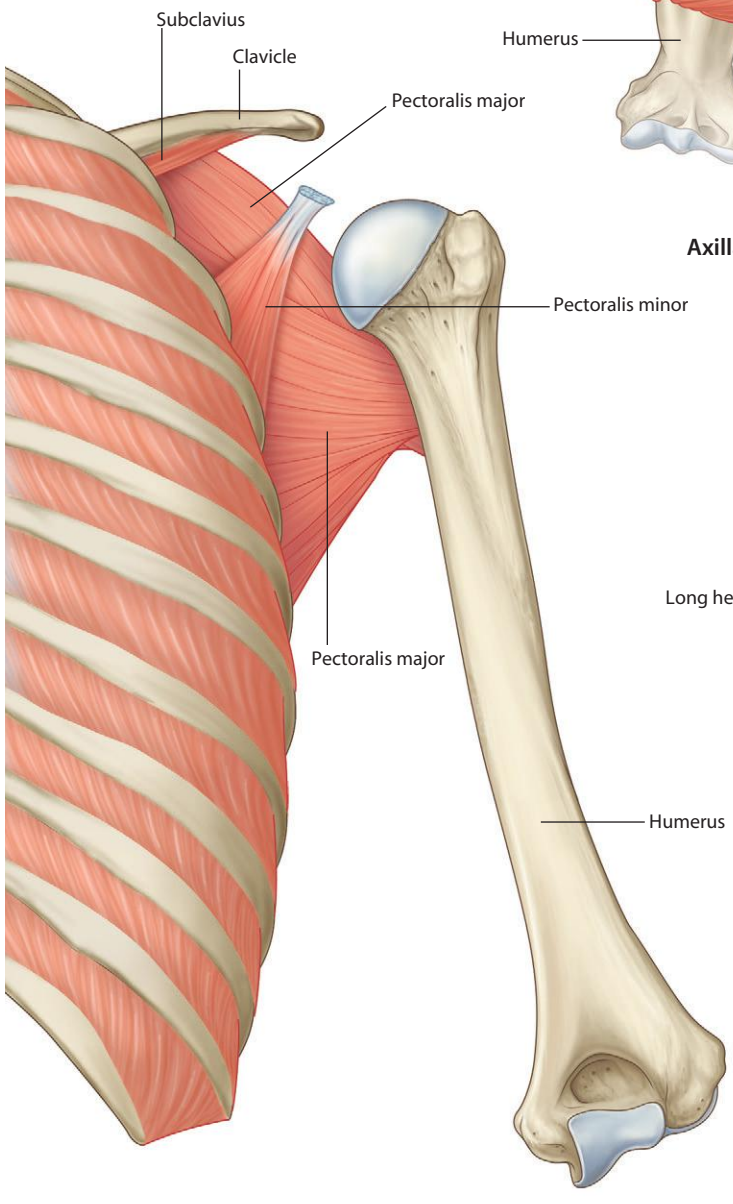

Anterior wall of axilla (posterior view)

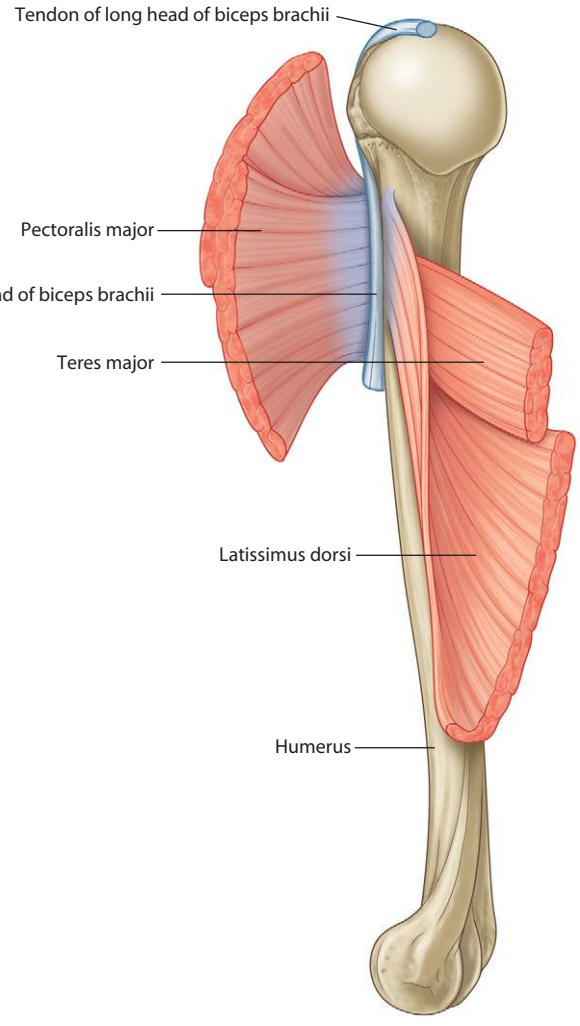

Lateral wall of axilla (medial view)

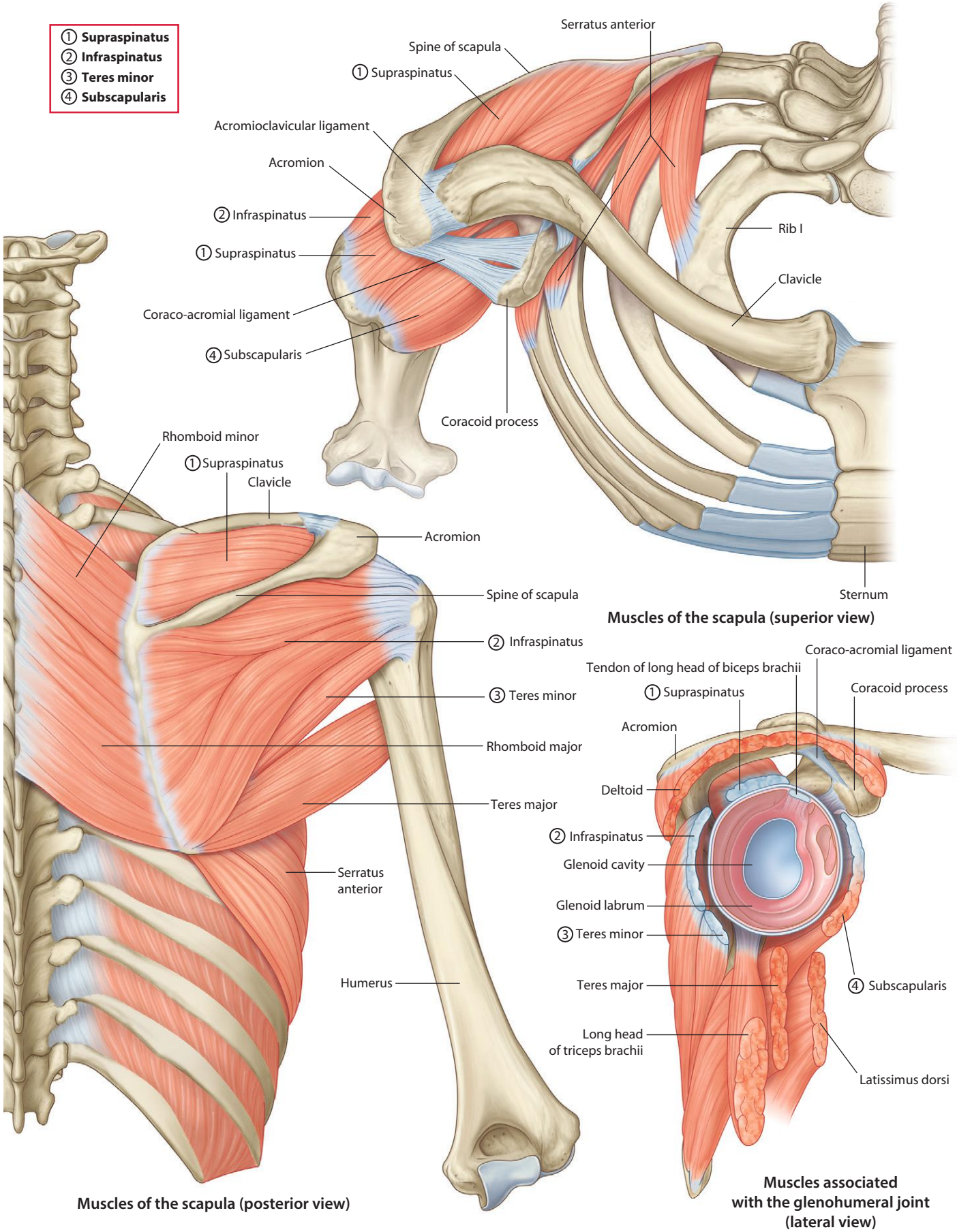
① Supraspinatus
② Infraspinatus
③ Teres minor
④ Subscapularis
Serratus anterior
Spine of scapula
① Supraspinatus
Acromioclavicular ligament
Acromion
② Infraspinatus
① Supraspinatus
Coraco-acromial ligament
④ Subscapularis
Coracoid process
Rib I
Clavicle
Sternum
Muscles of the scapula (superior view)
Rhomboid minor
① Supraspinatus
Clavicle
Acromion
Spine of scapula
② Infraspinatus
③ Teres minor
Rhomboid major
Teres major
Serratus anterior
Humerus
Muscles of the scapula (posterior view)
Coraco-acromial ligament
Tendon of long head of biceps brachii
① Supraspinatus
Coracoid process
Acromion
Deltoid
② Infraspinatus
Glenoid cavity
Glenoid labrum
③ Teres minor
Teres major
④ Subscapularis
Long head of triceps brachii
Latissimus dorsi
Muscles associated with the glenohumeral joint (lateral view)

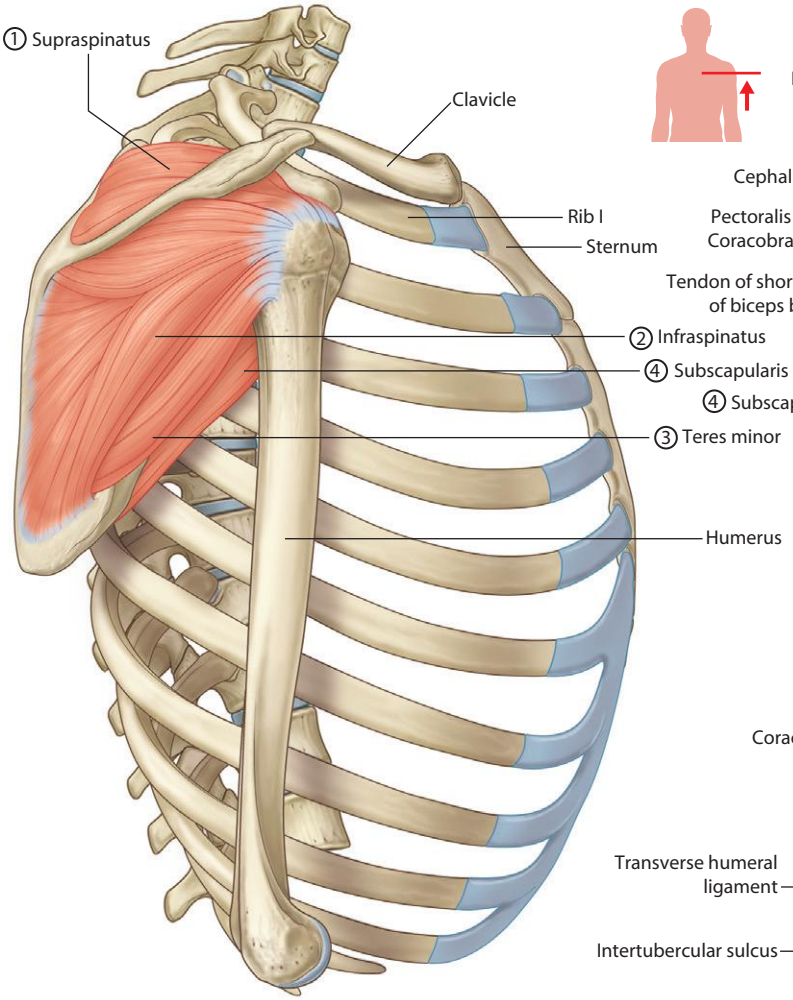

Muscles of the scapula (lateral view)

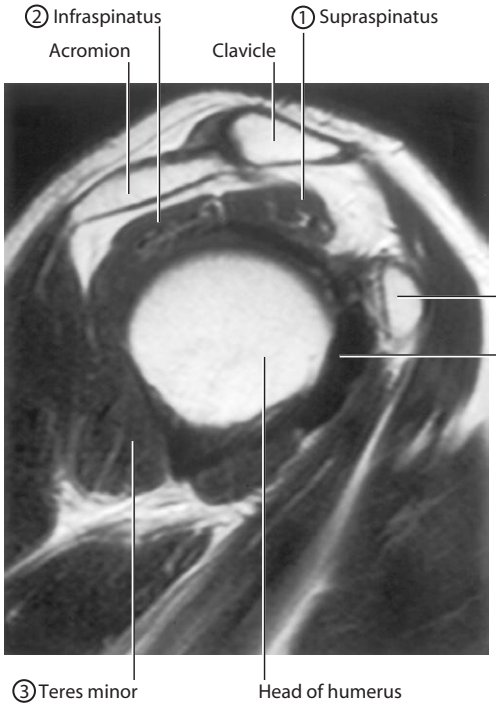

Muscles associated with the glenohumeral joint.
T1-weighted MR image in sagittal plane

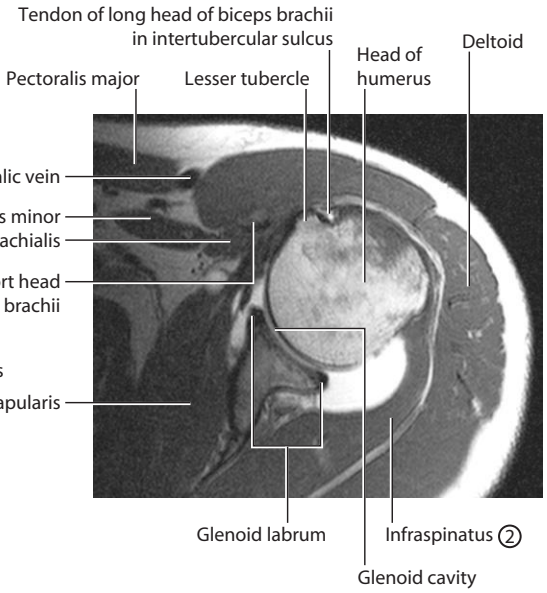

Muscles associated with the glenohumeral joint.
T1-weighted MR image in axial plane

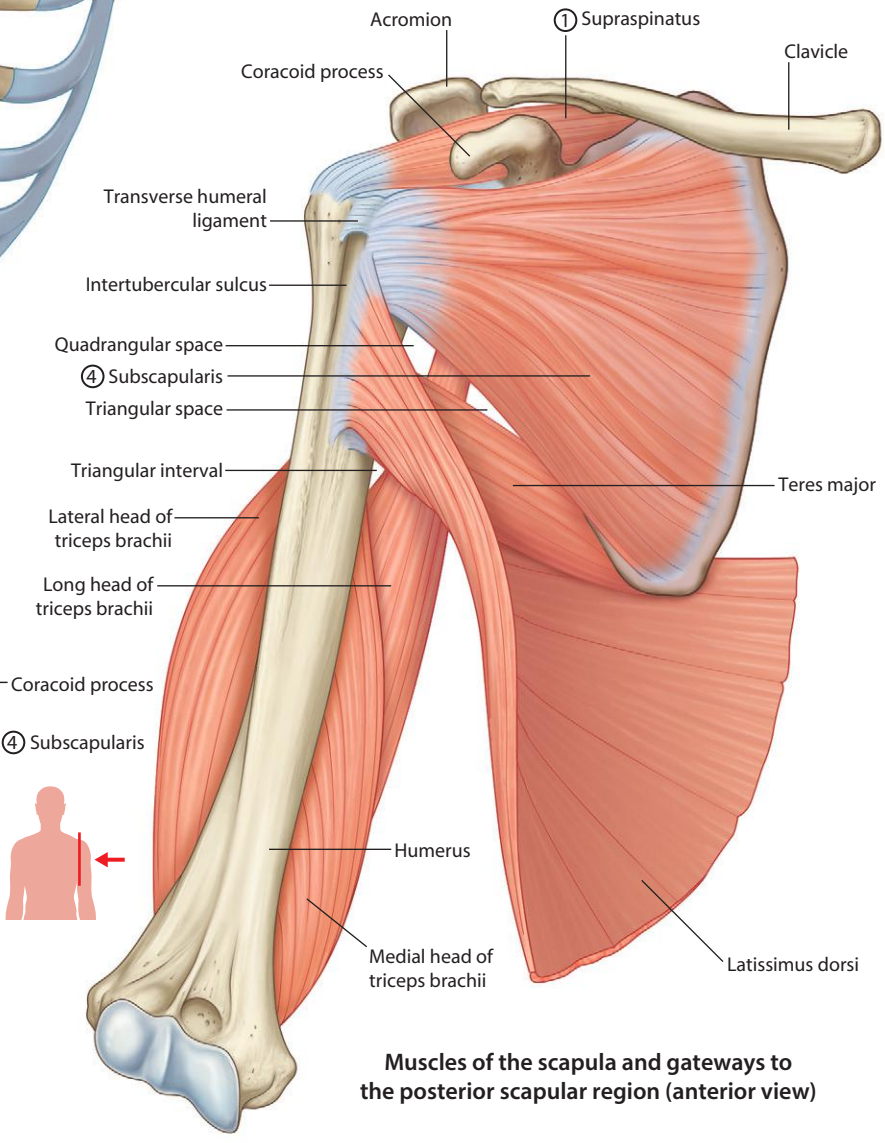

Muscles of the scapula and gateways to the posterior scapular region (anterior view)

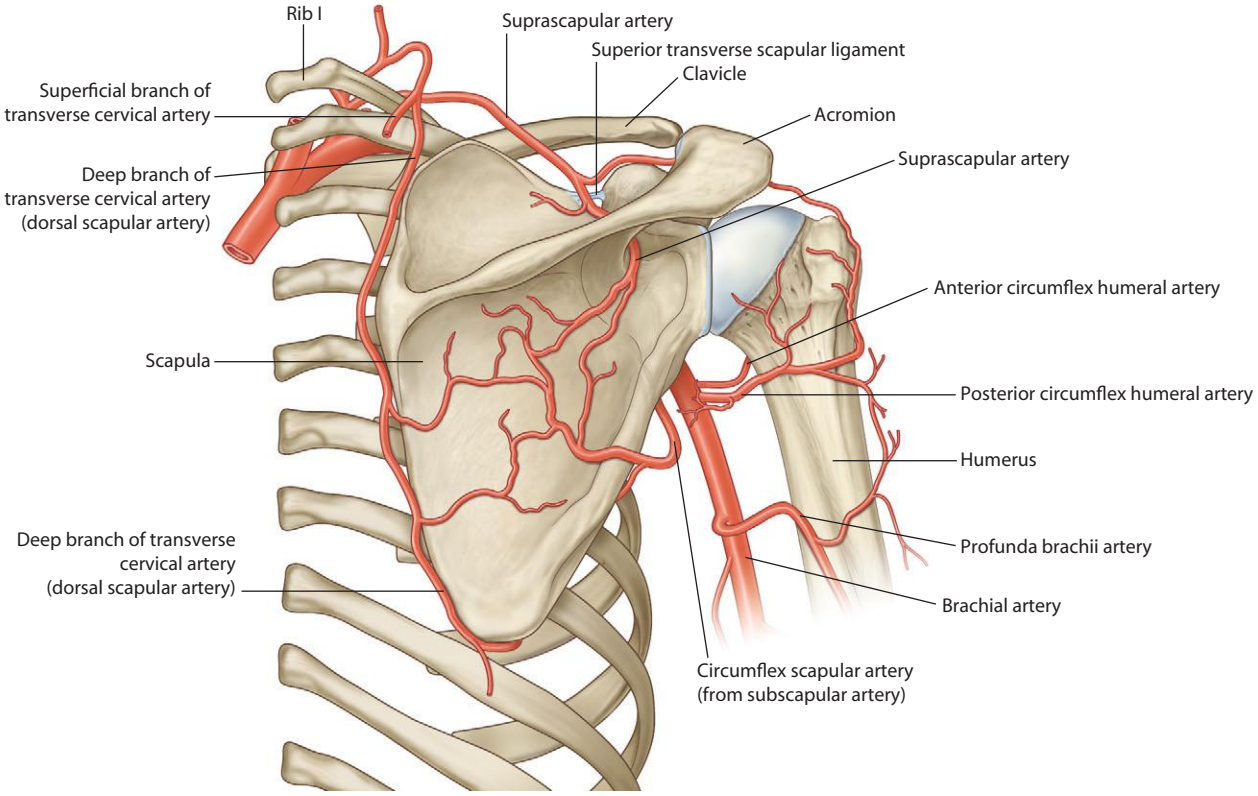

Arteries of the shoulder (posterior view)

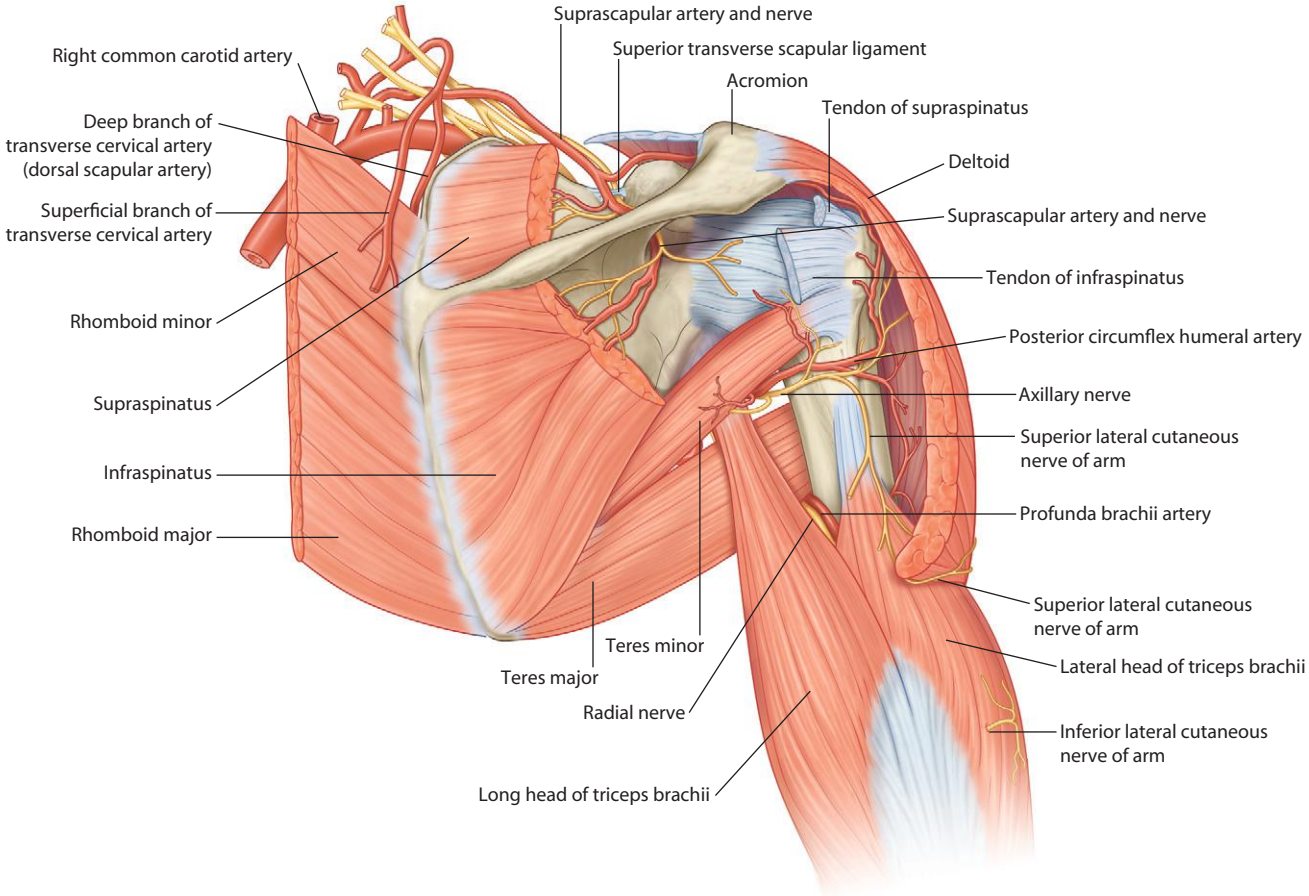

Deep arteries and nerves of the shoulder (posterior view)

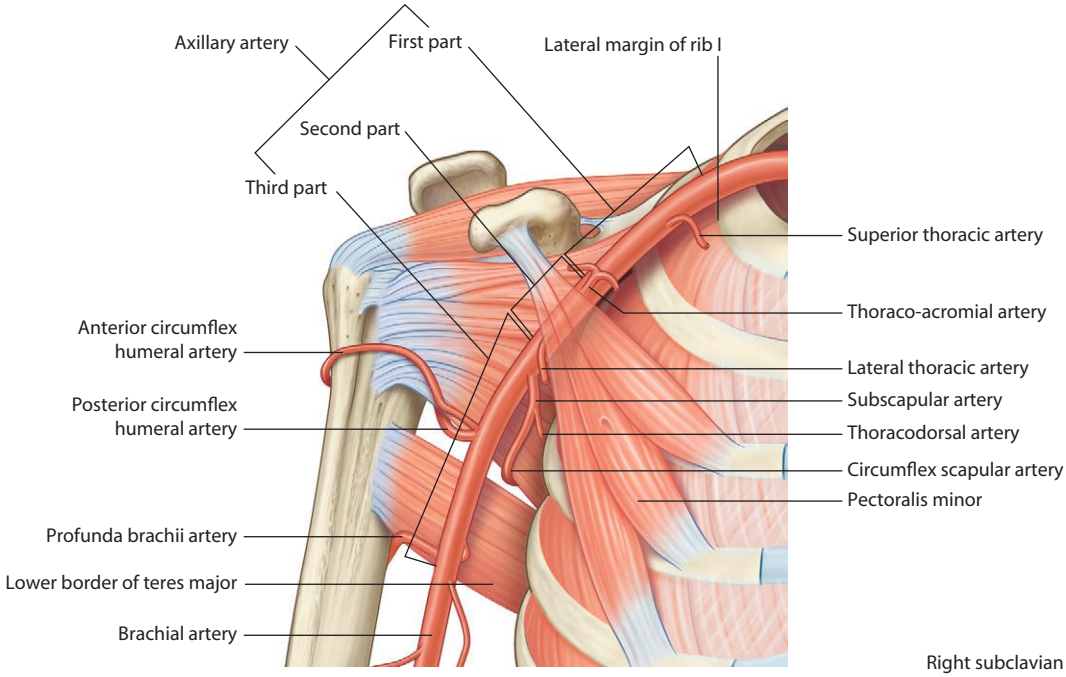

Axillary artery (anterior view)

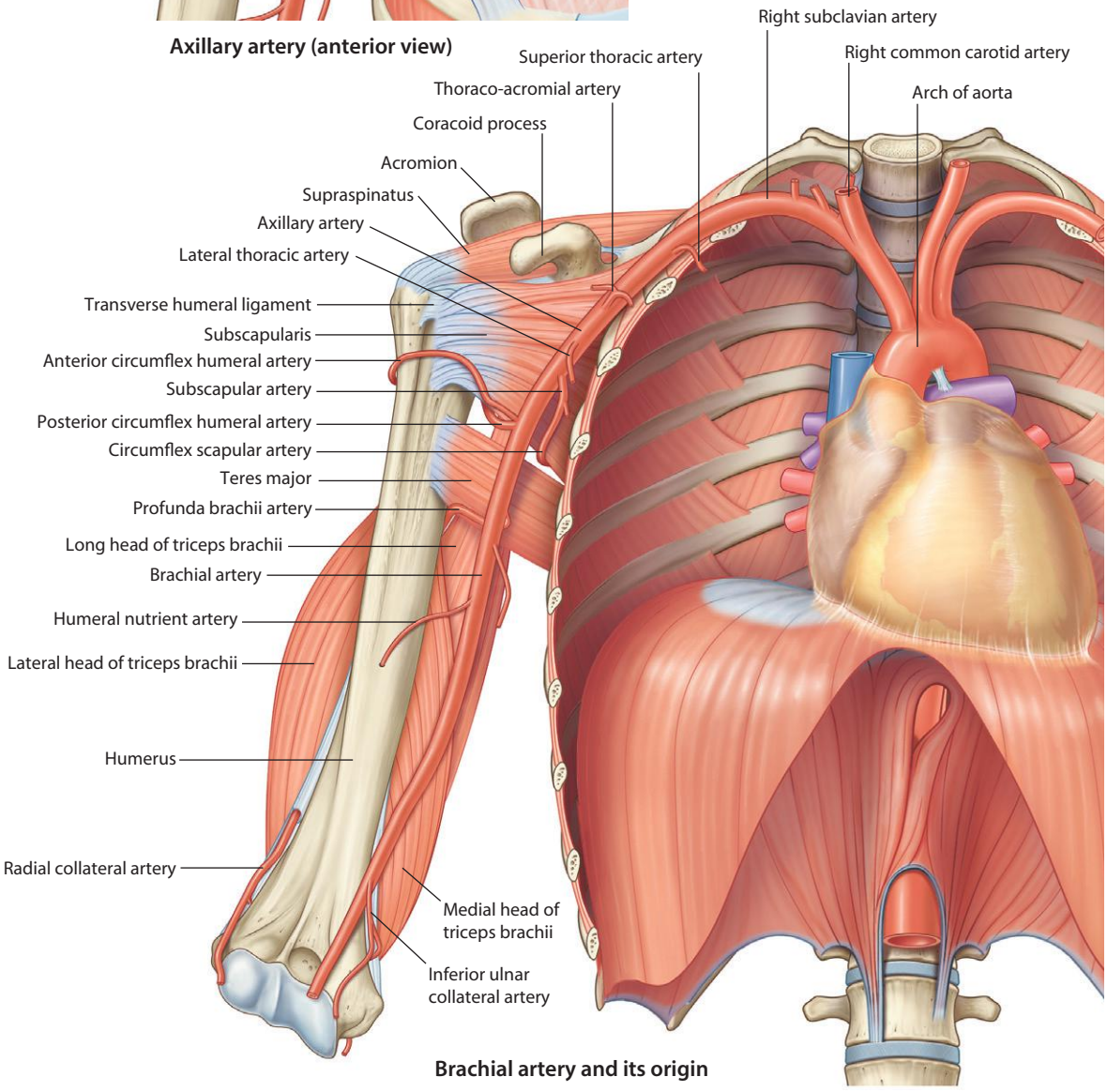

Brachial artery and its origin

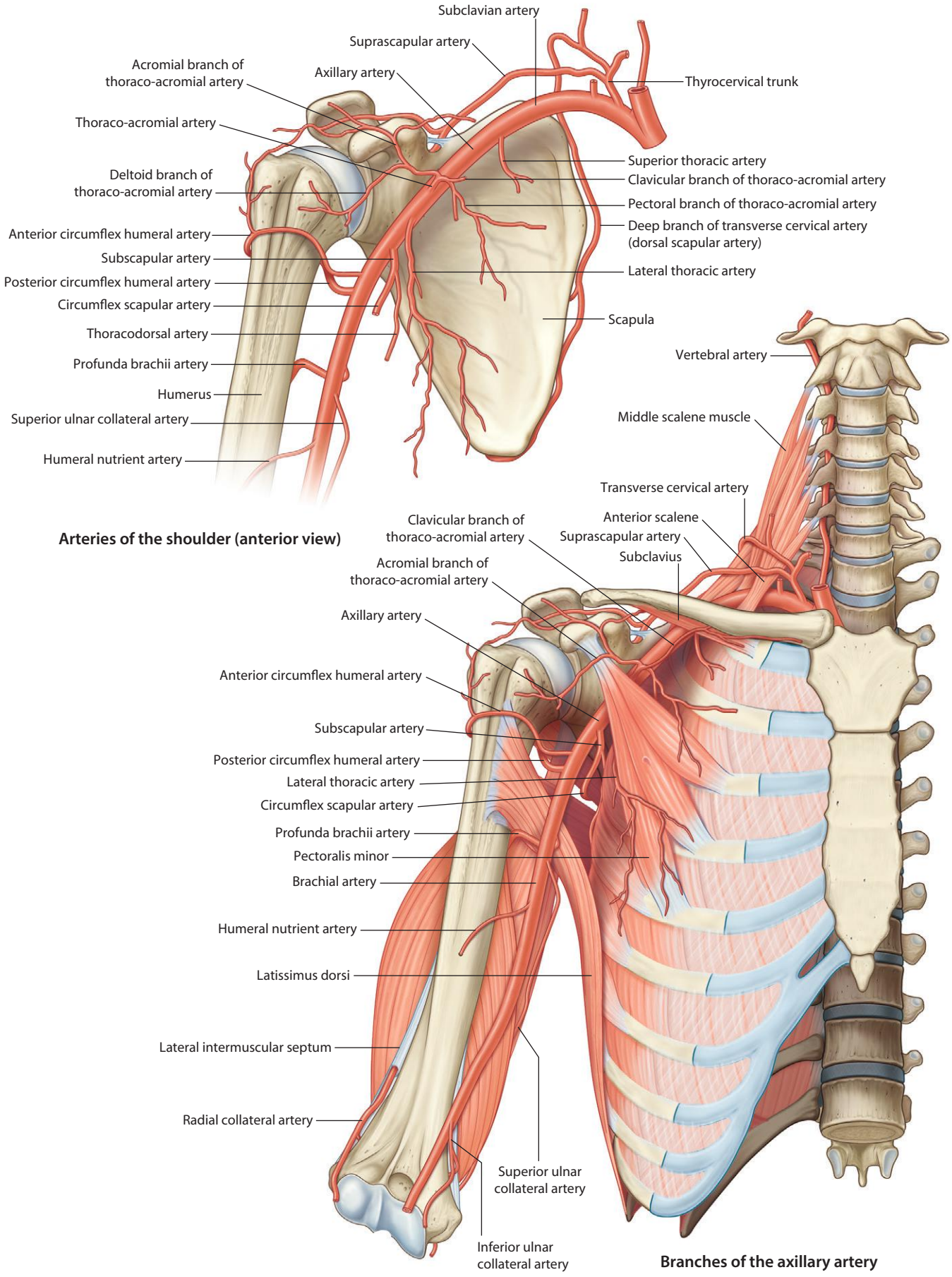

Arteries of the shoulder (anterior view)

Branches of the axillary artery

tahir99-VRG & vip.persianss.ir

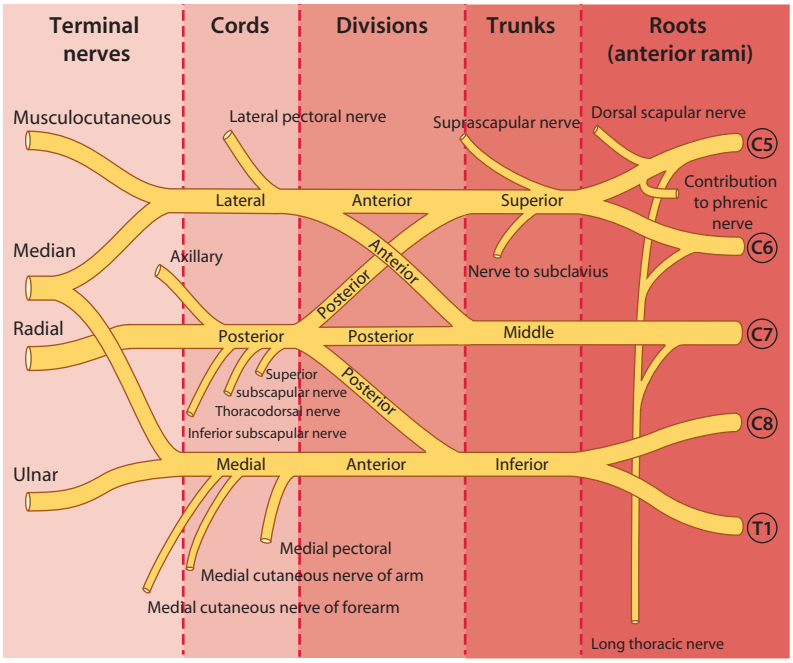

Schematic showing branches of the brachial plexus

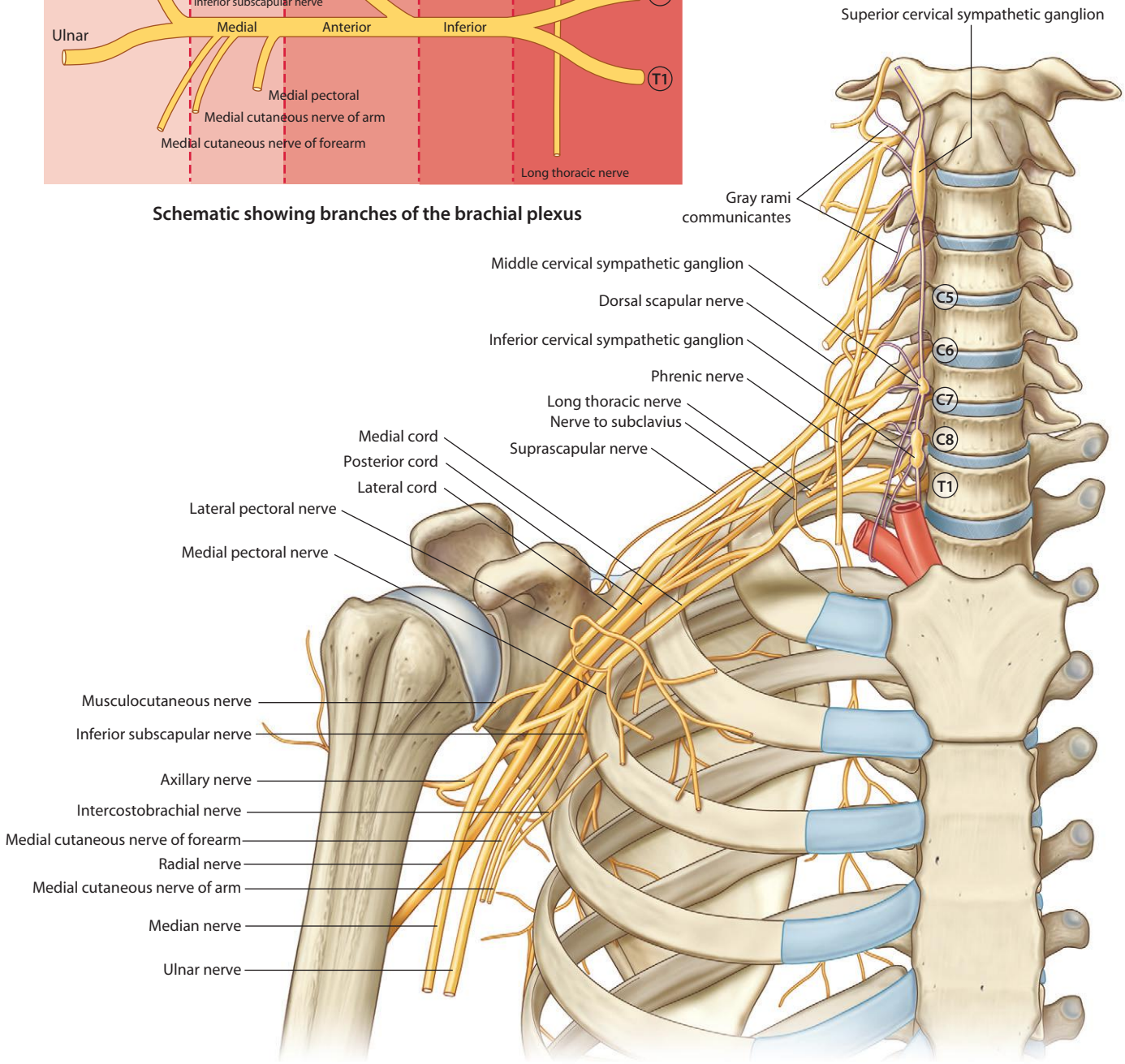

Brachial plexus

tahir99-VRG & vip.persianss.ir

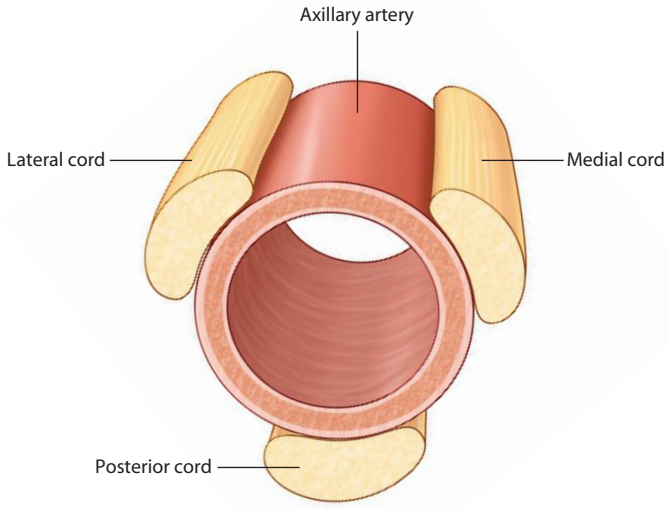

Cords around the axillary artery

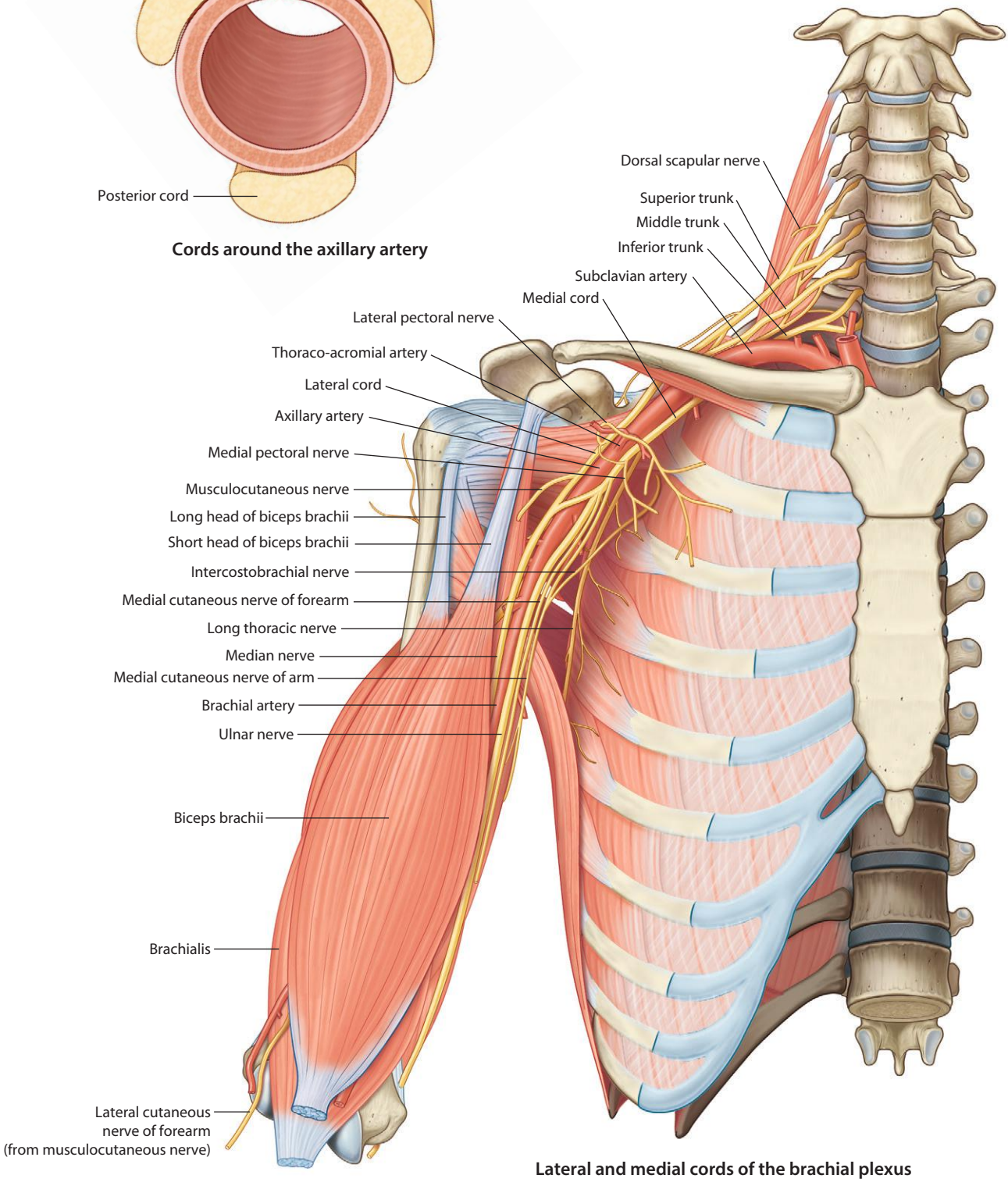

Lateral and medial cords of the brachial plexus

tahir99-VRG & vip.persianss.ir

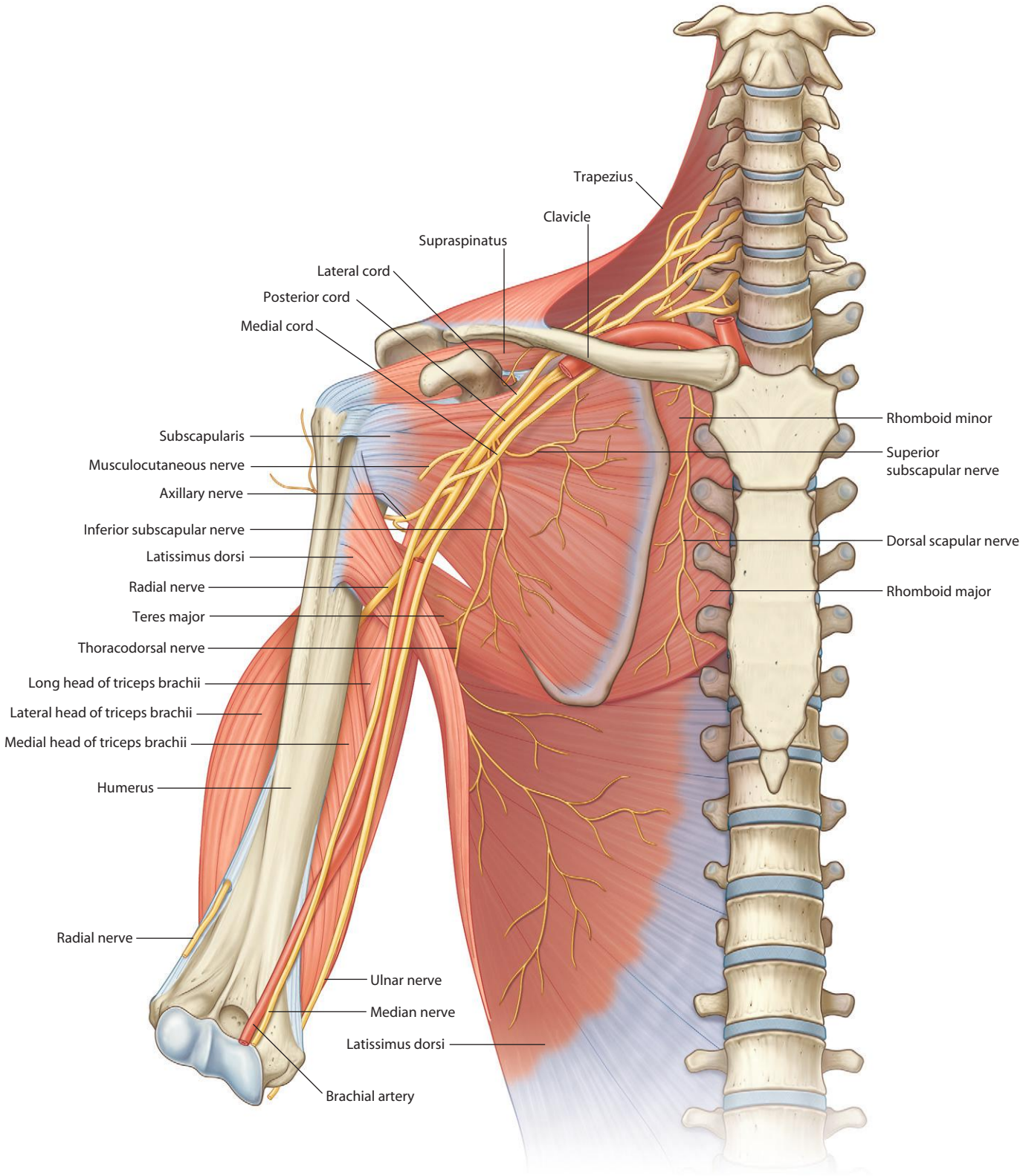

Posterior cord of the brachial plexus (ribs and associated muscles removed)

tahir99-VRG & vip.persianss.ir

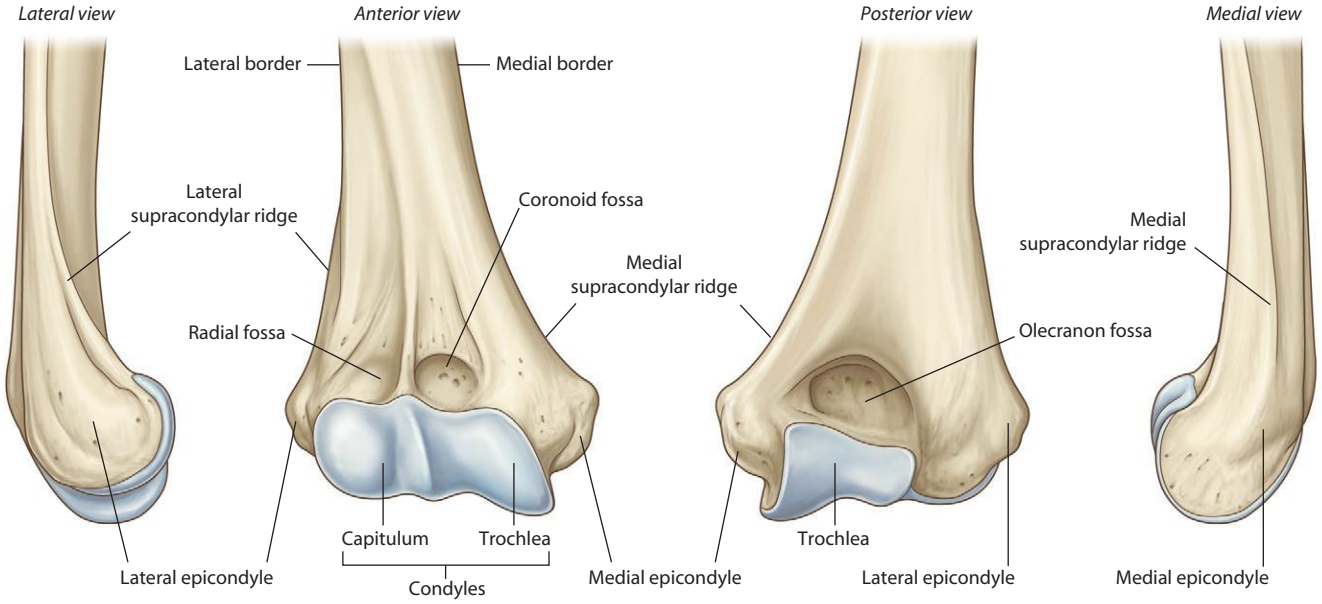

Distal end of humerus

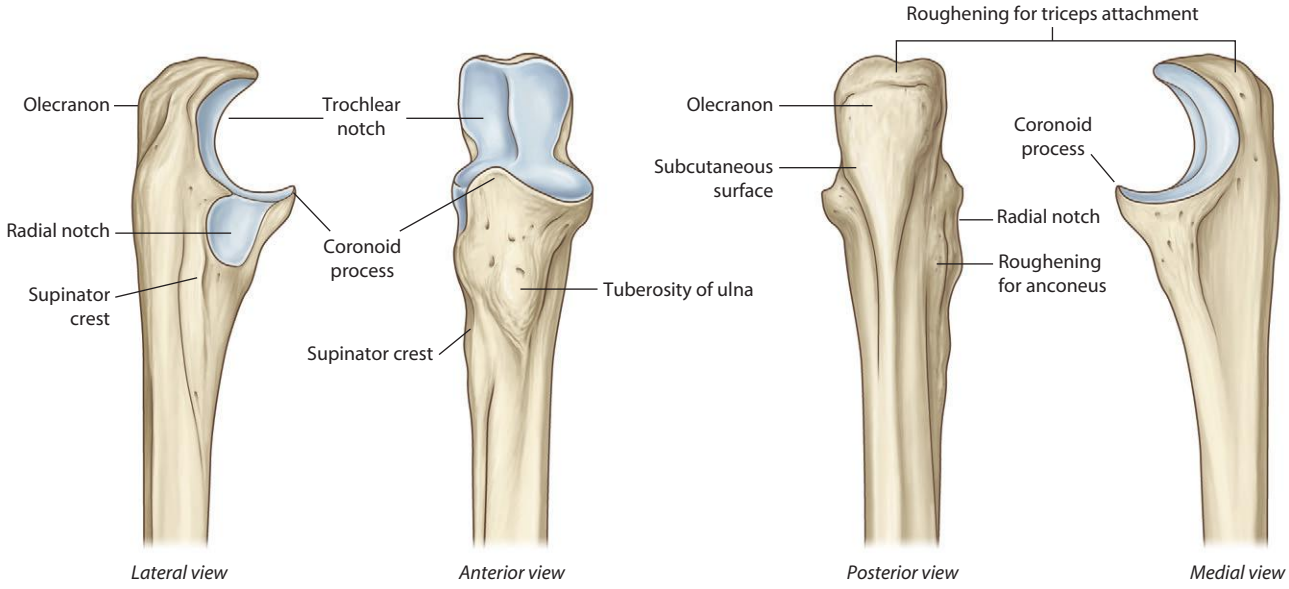

Proximal end of ulna

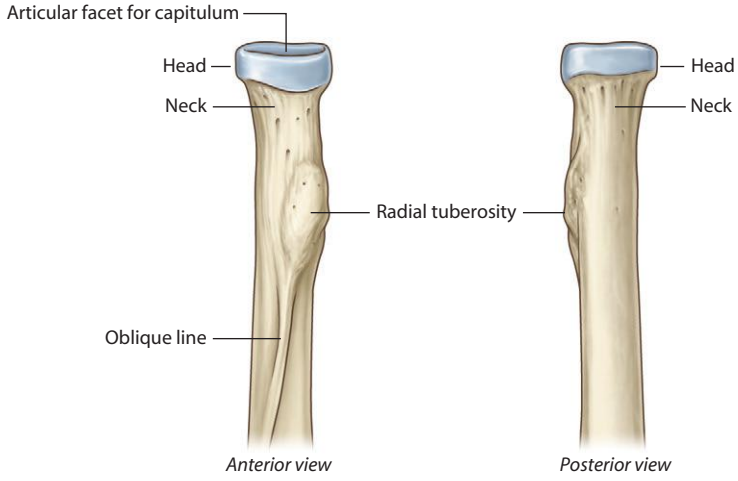

Proximal end of radius

tahir99-VRG & vip.persianss.ir

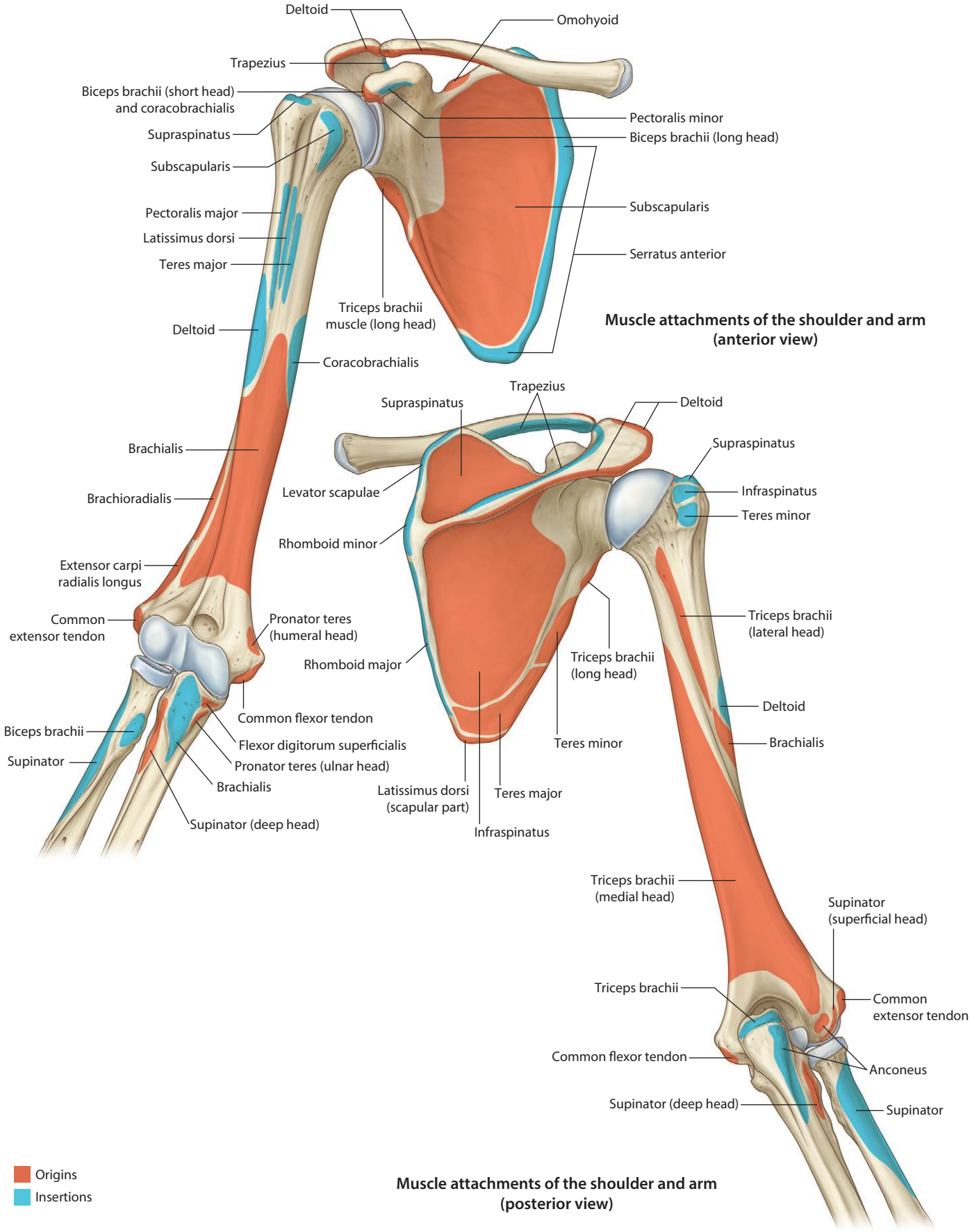

Muscle attachments of the shoulder and arm (anterior view)

Muscle attachments of the shoulder and arm (posterior view)

tahir99-VRG & vip.persianss.ir

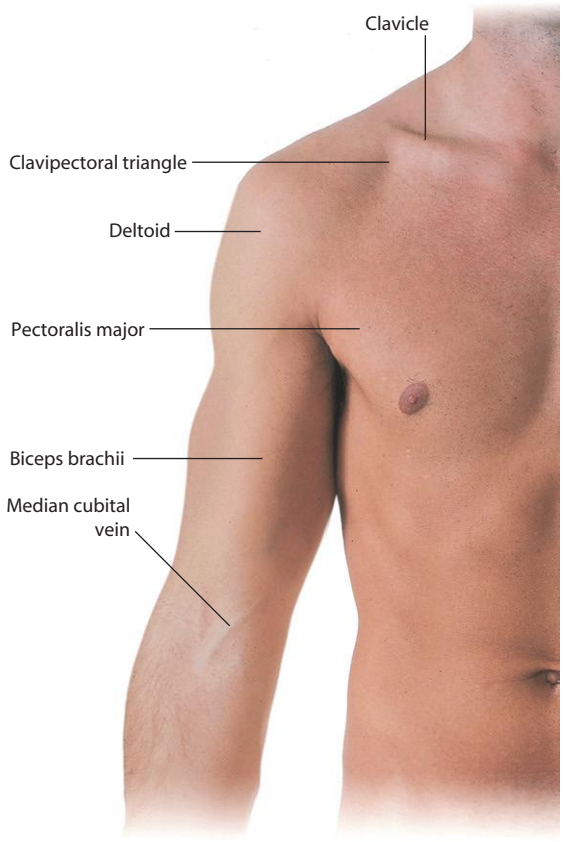

Surface anatomy of anterior compartment

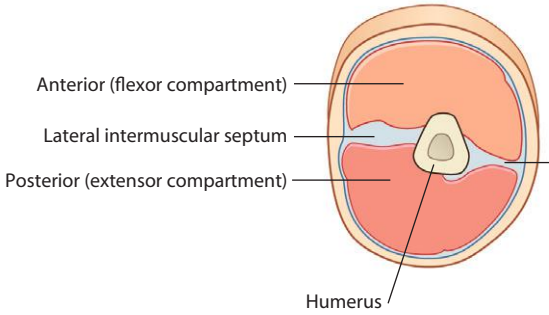

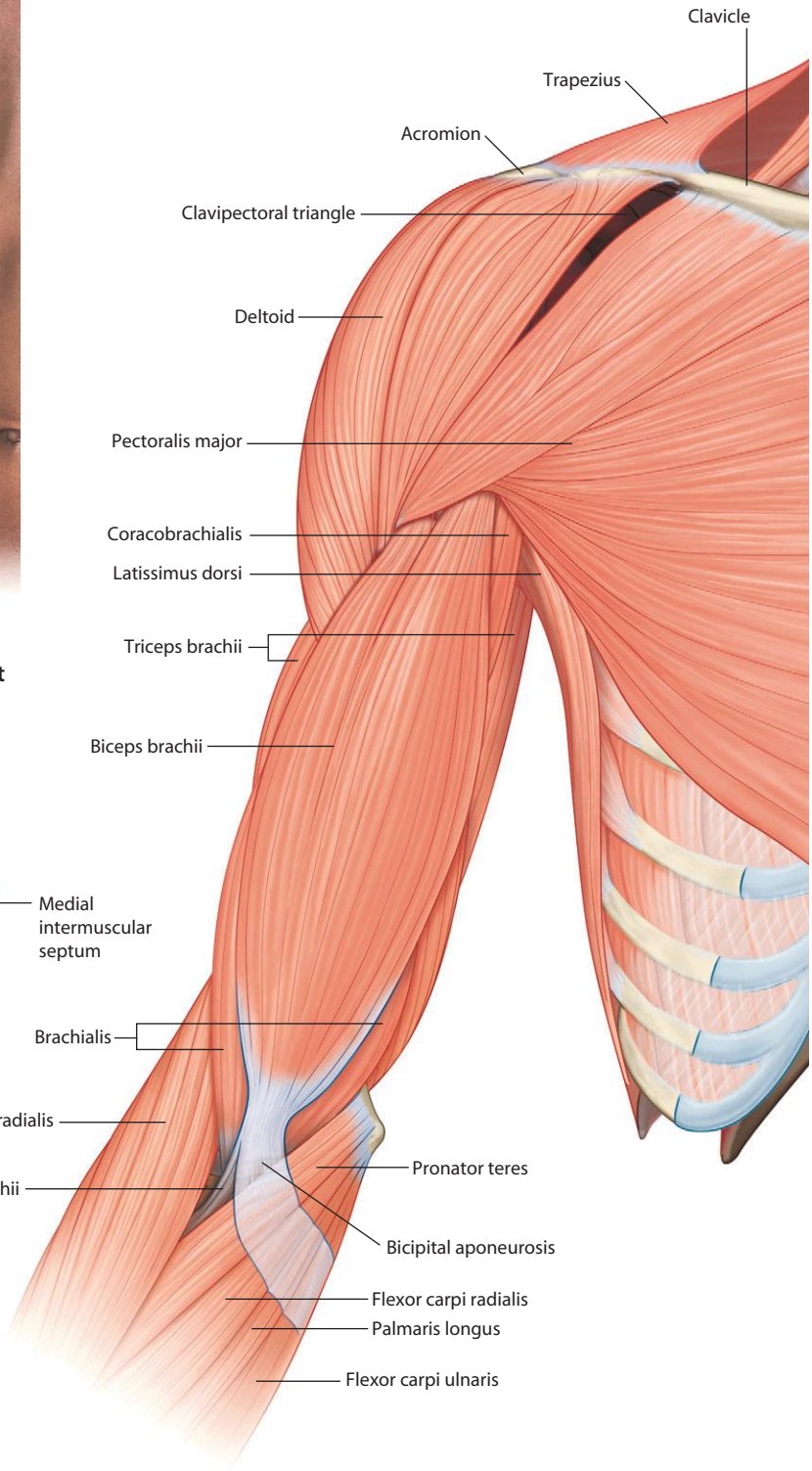

Muscles of anterior compartment of arm

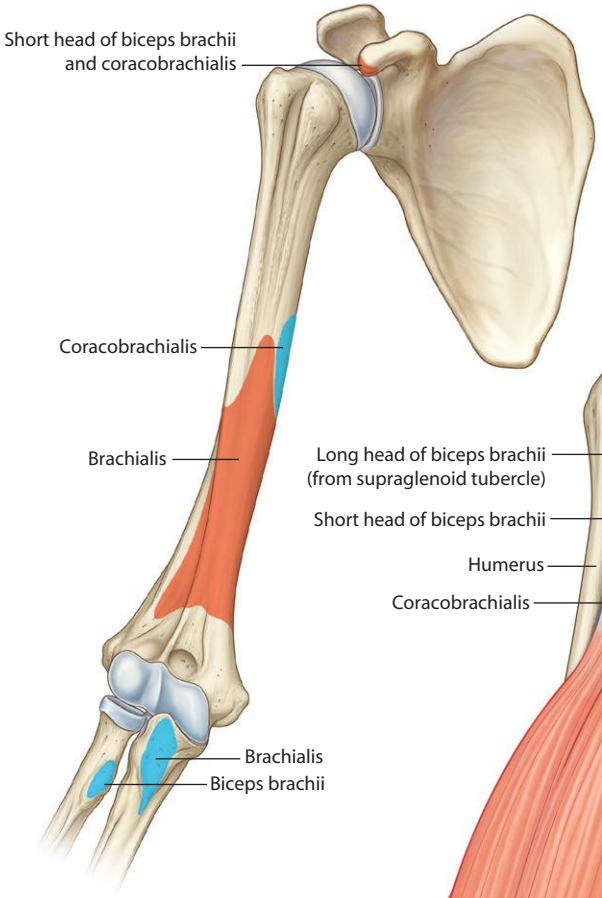

Muscle attachments of anterior compartment of arm

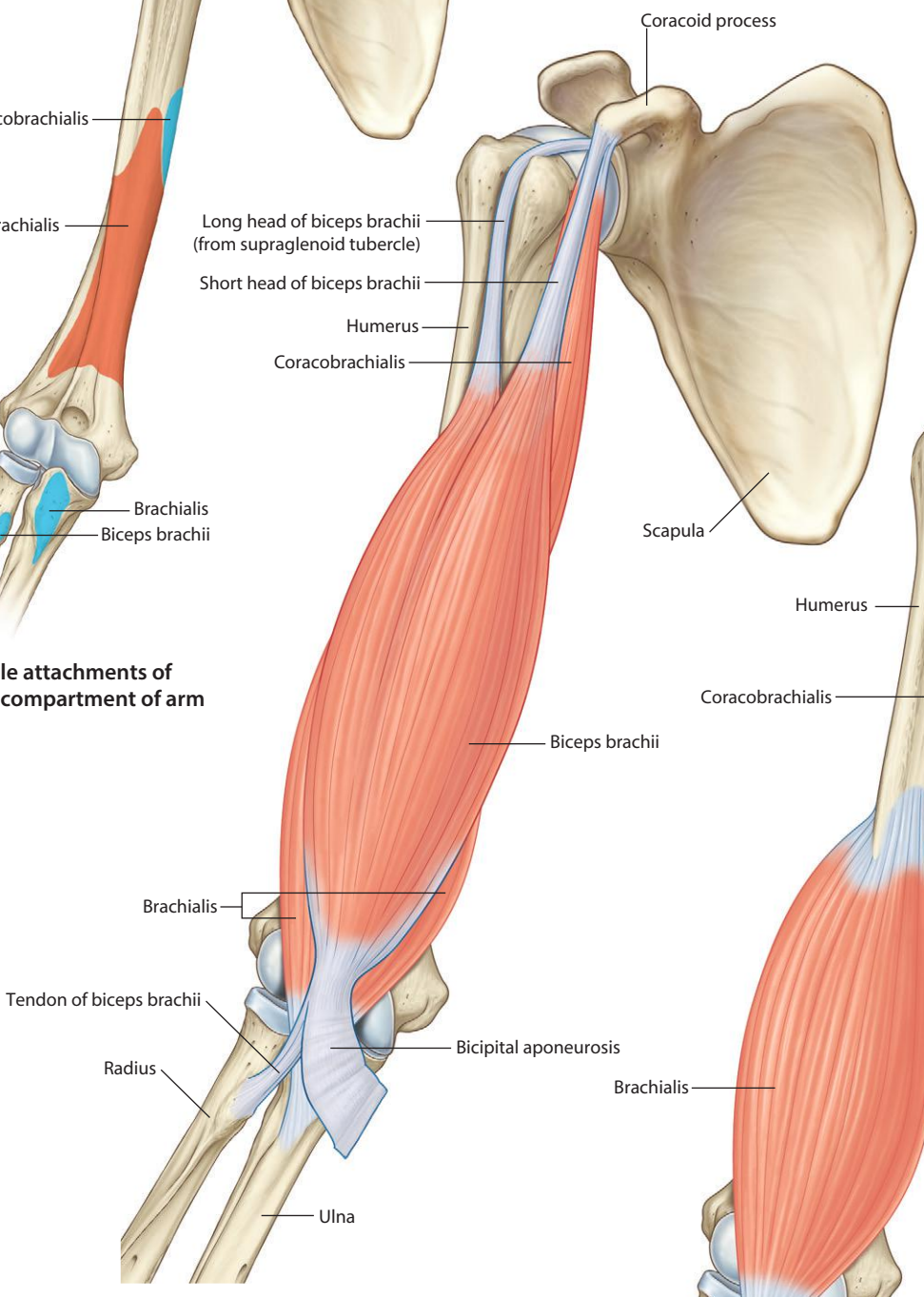

Biceps brachii muscle

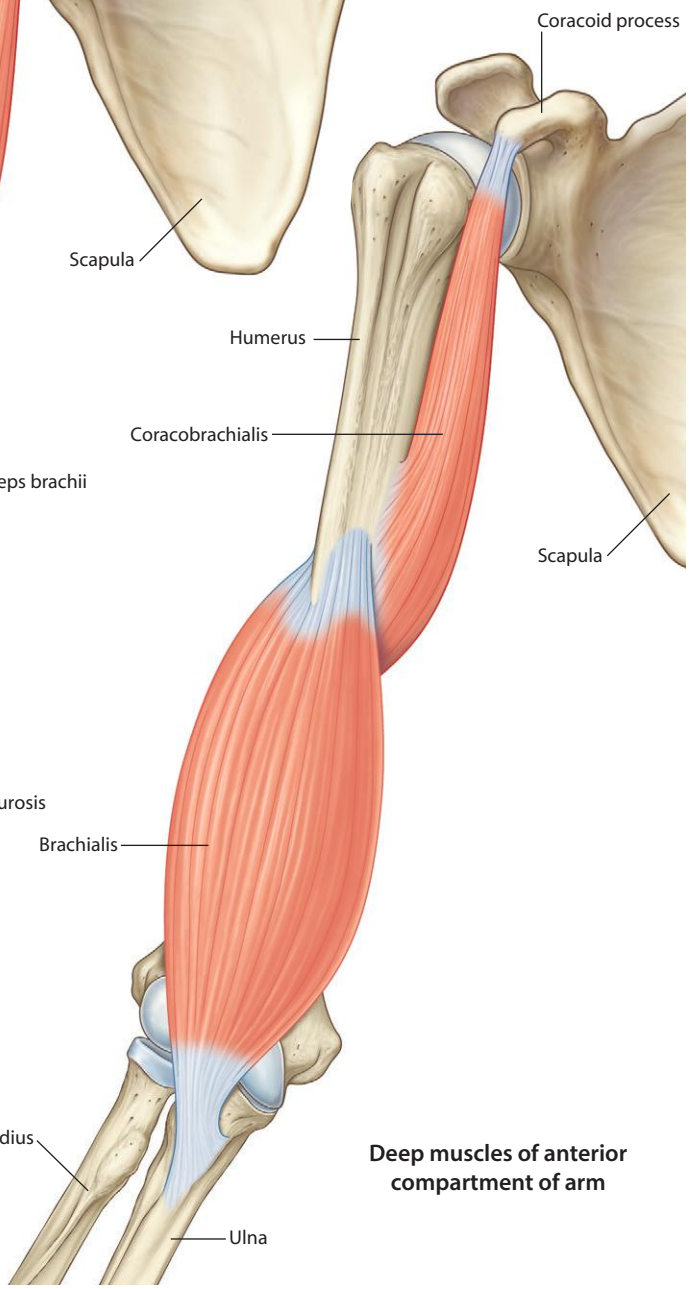

Deep muscles of anterior compartment of arm

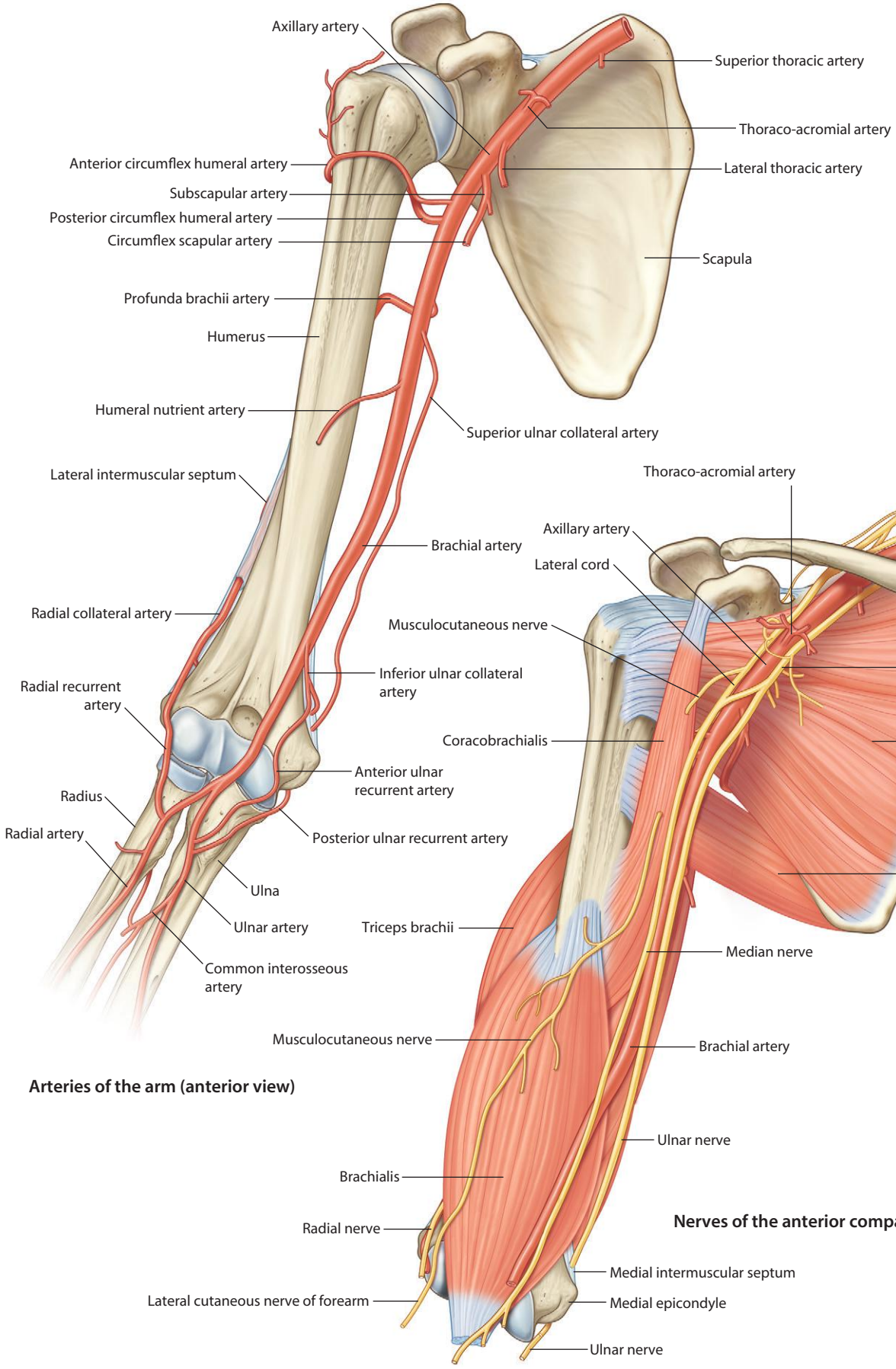

Arteries of the arm (anterior view)

Nerves of the anterior compartment

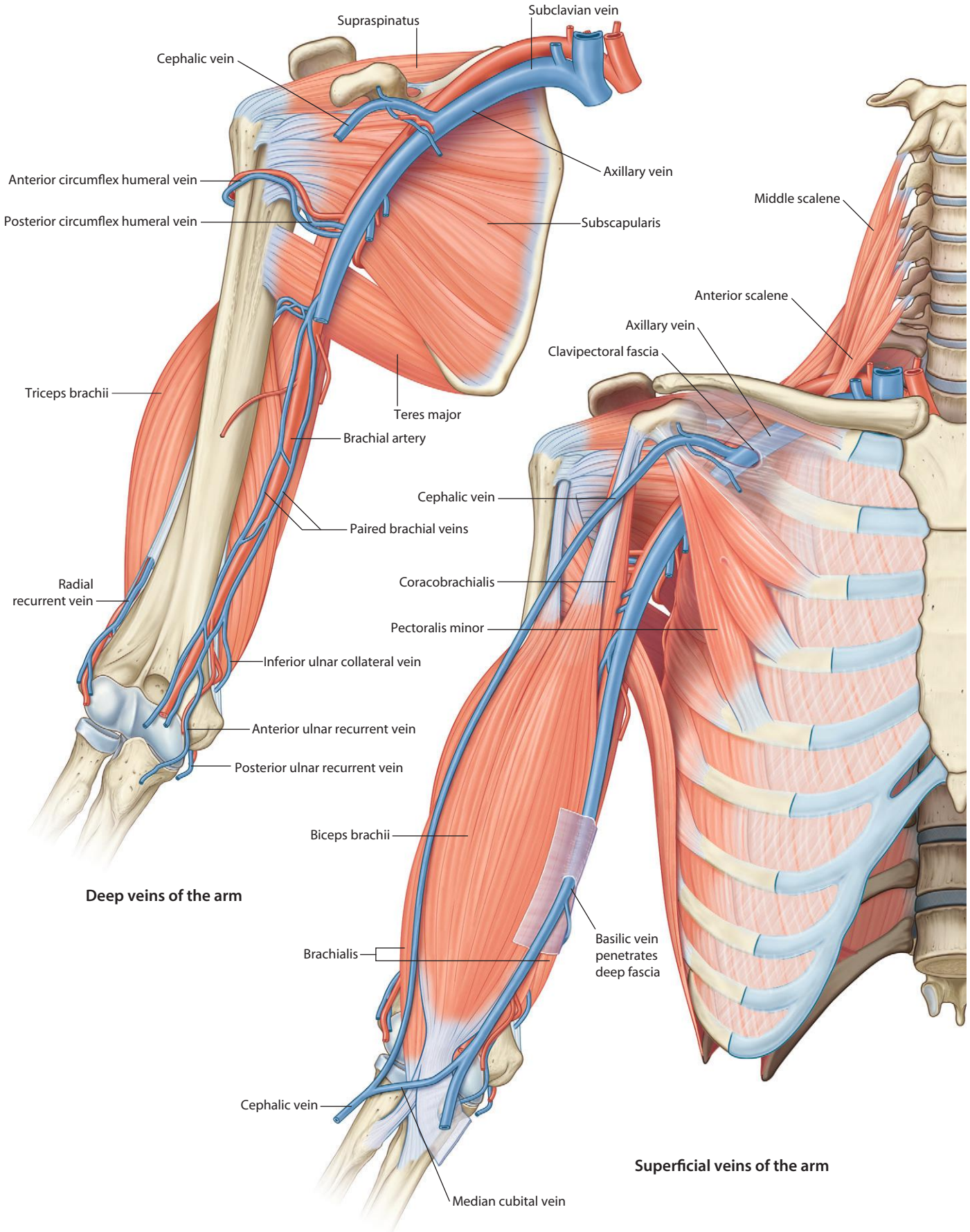

Deep veins of the arm

Superficial veins of the arm

Surface anatomy of posterior compartment of arm

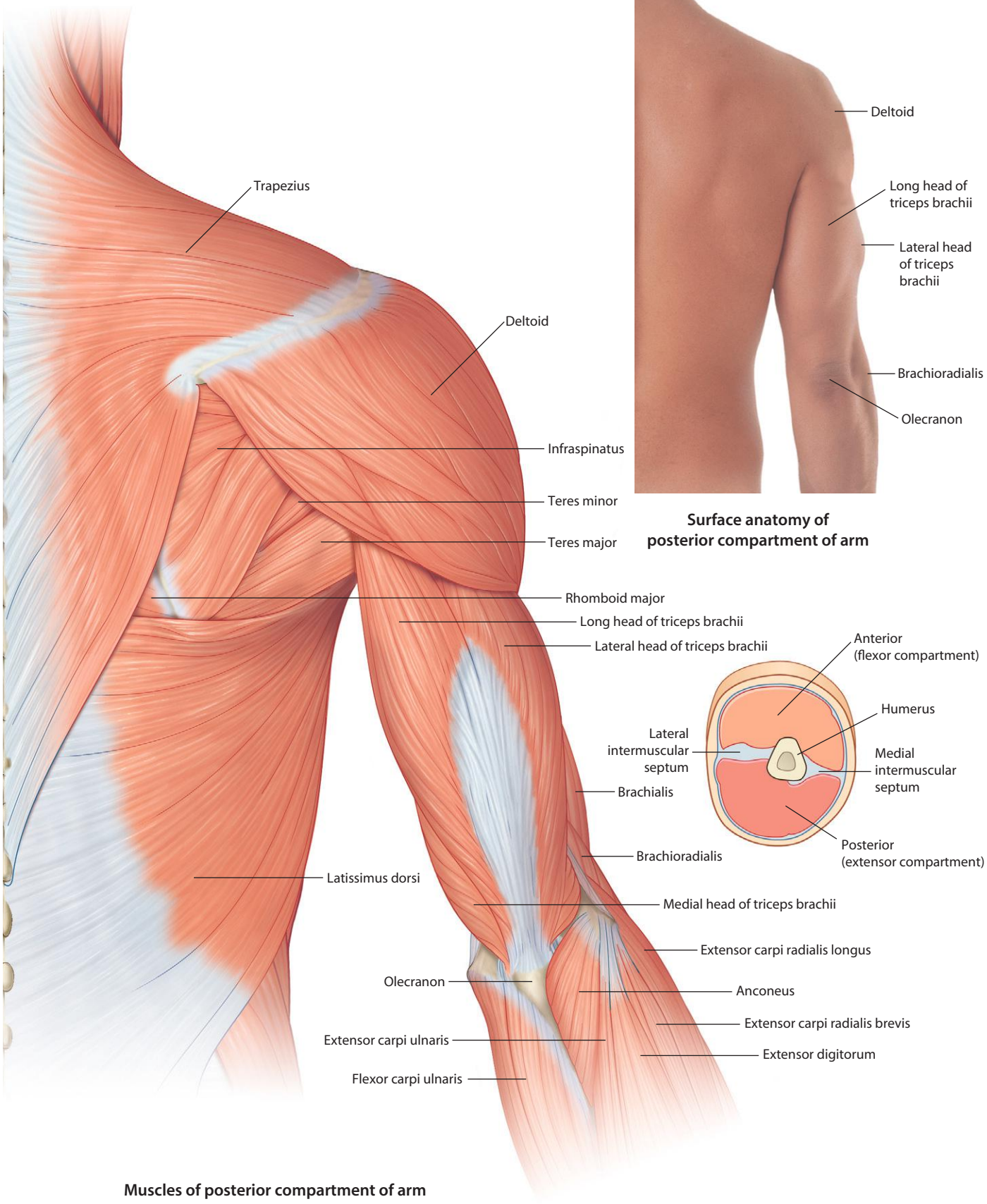

Muscles of posterior compartment of arm

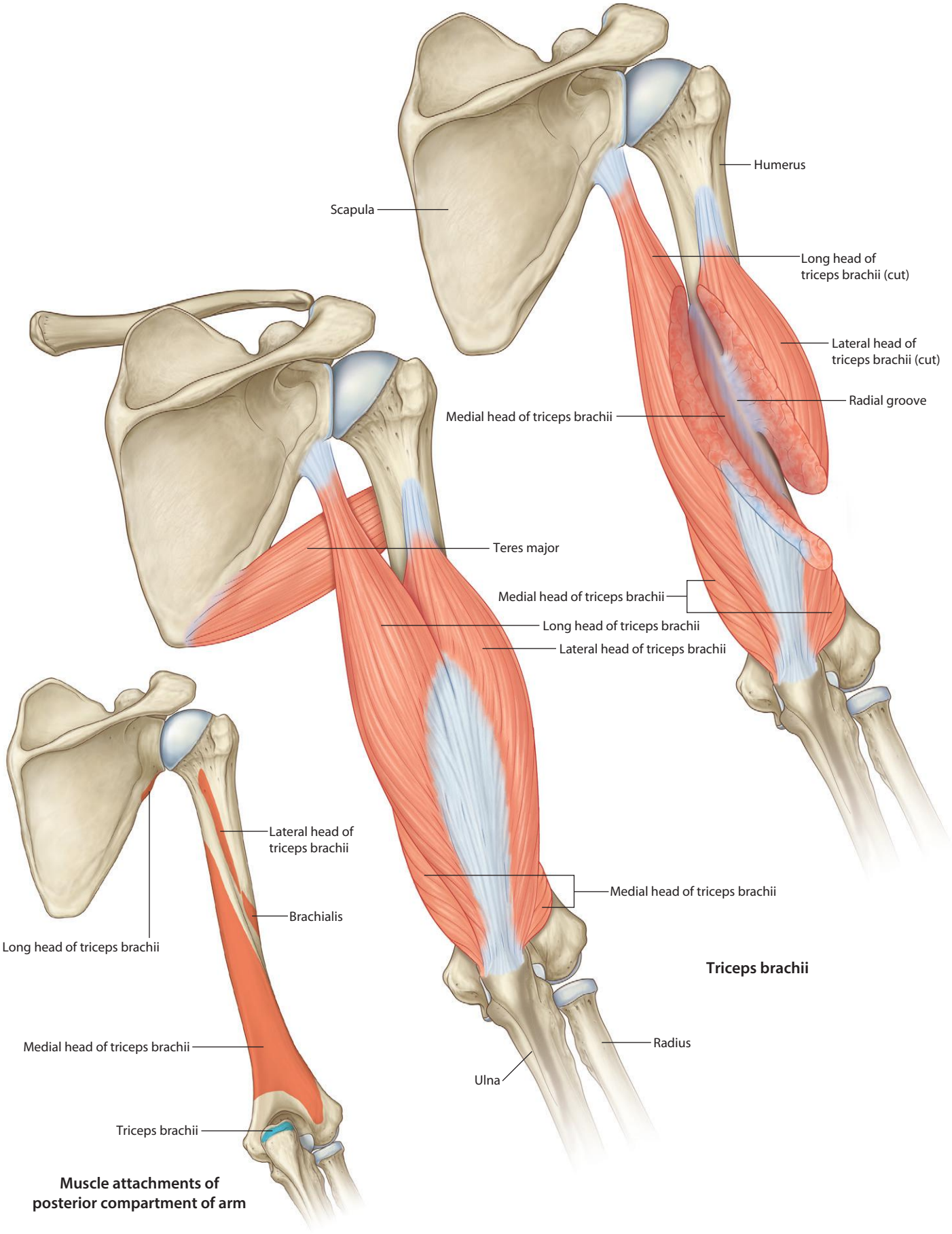

Triceps brachii

Muscle attachments of posterior compartment of arm

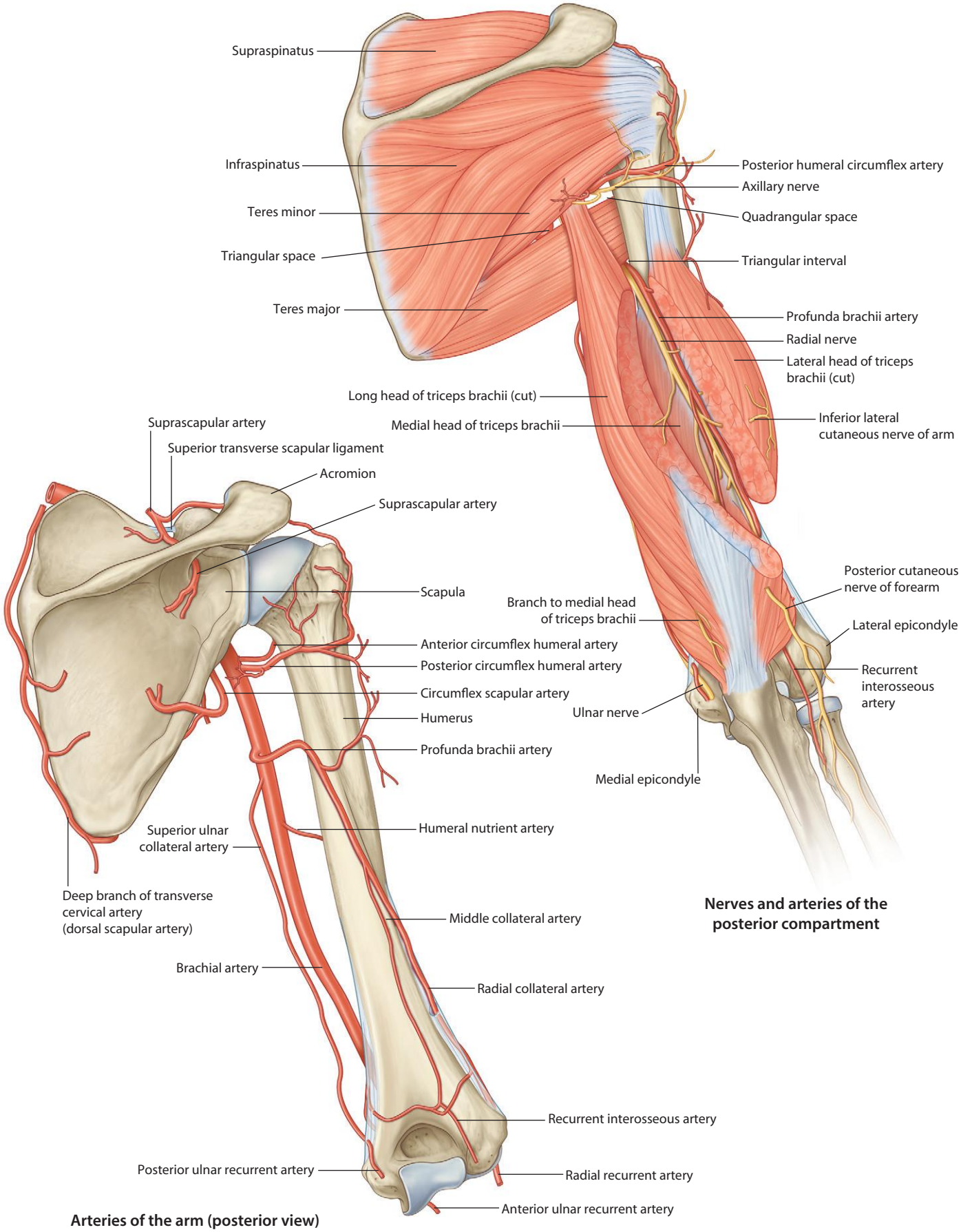

Arteries of the arm (posterior view)

Nerves and arteries of the posterior compartment

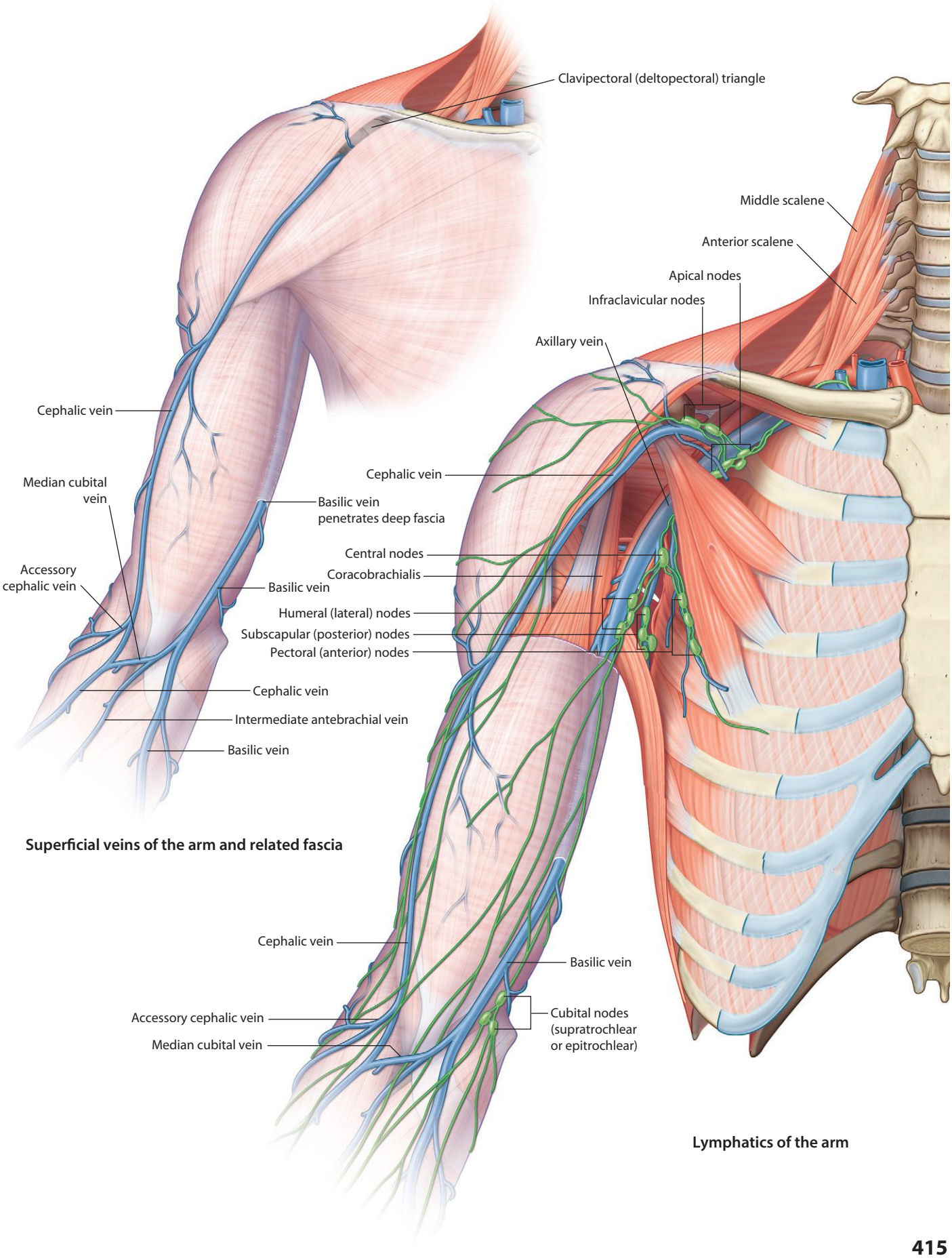

Superficial veins of the arm and related fascia

Lymphatics of the arm

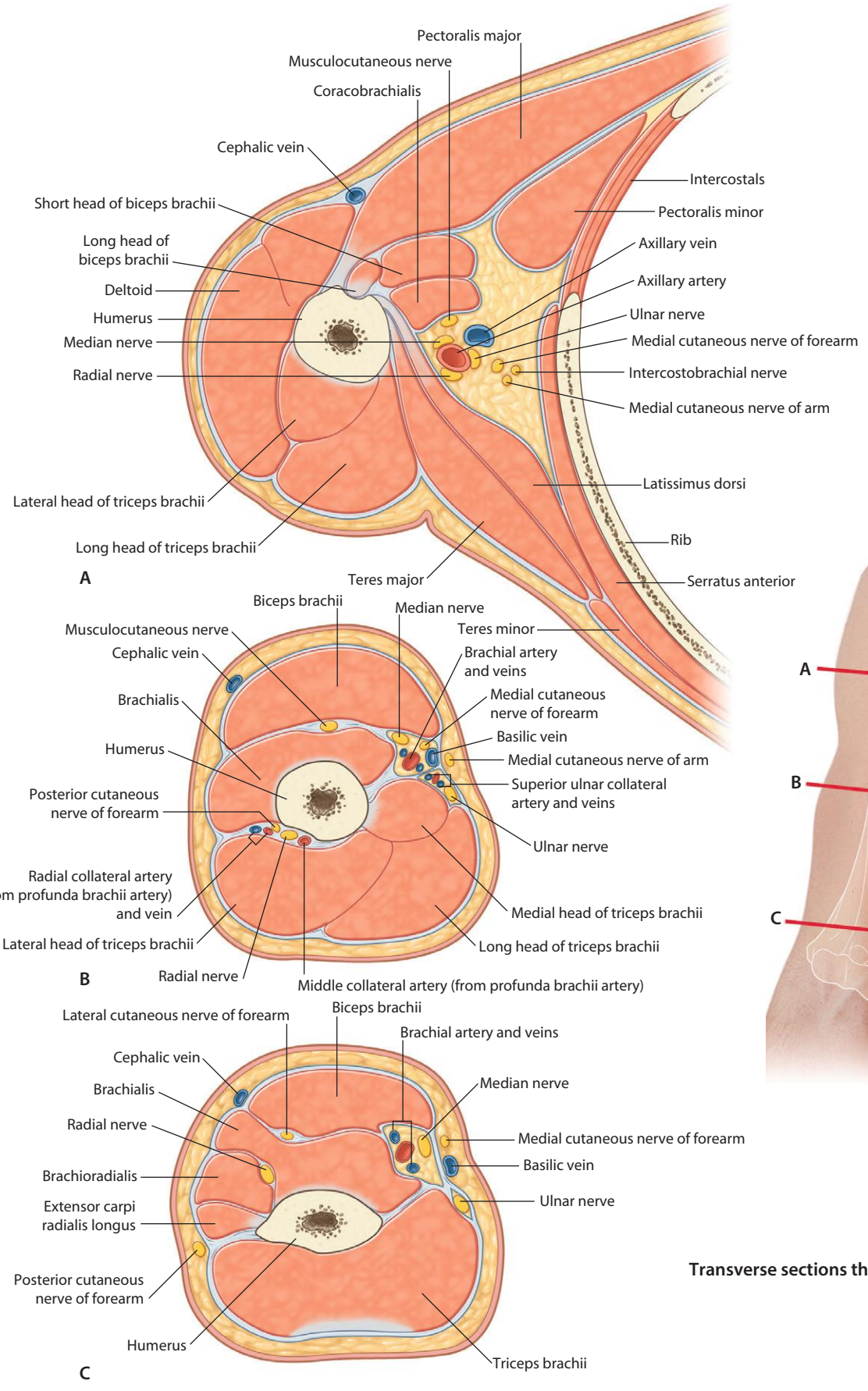

Transverse sections through arm

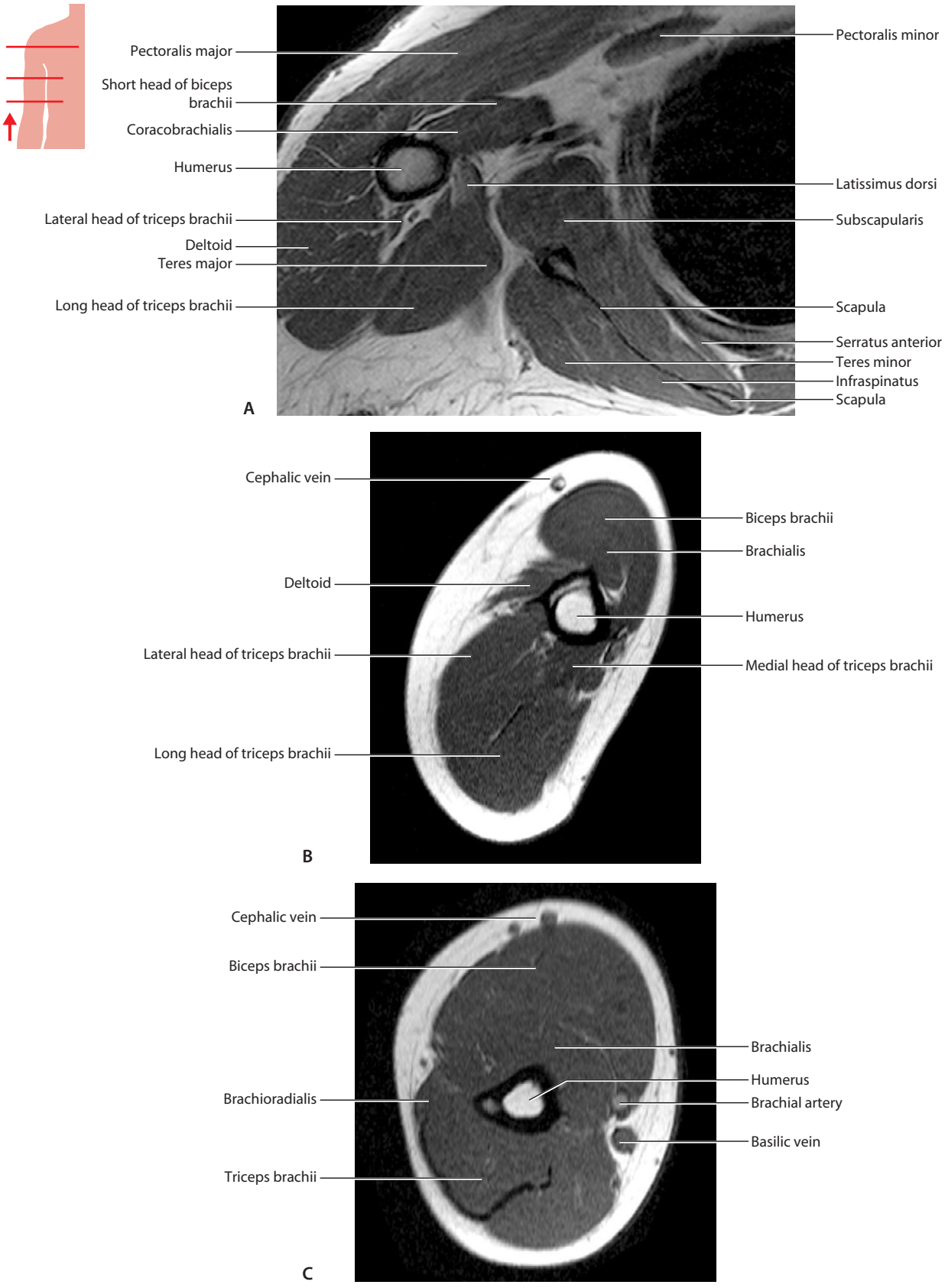

Transverse/axial sections through the arm.
A. Proximal/upper arm. B. Middle arm. C. Distal/lower arm.
T1-weighted MR images in axial plane

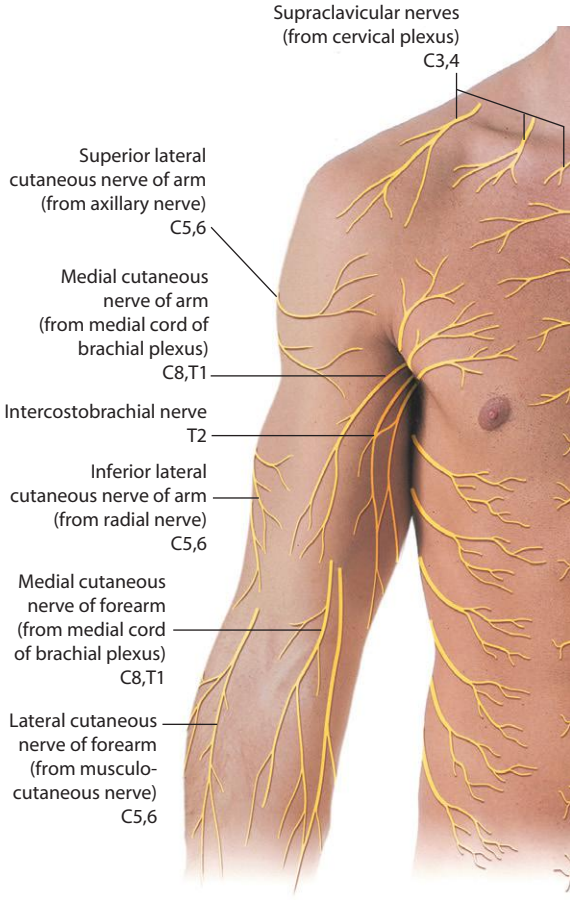

Cutaneous nerves of the arm

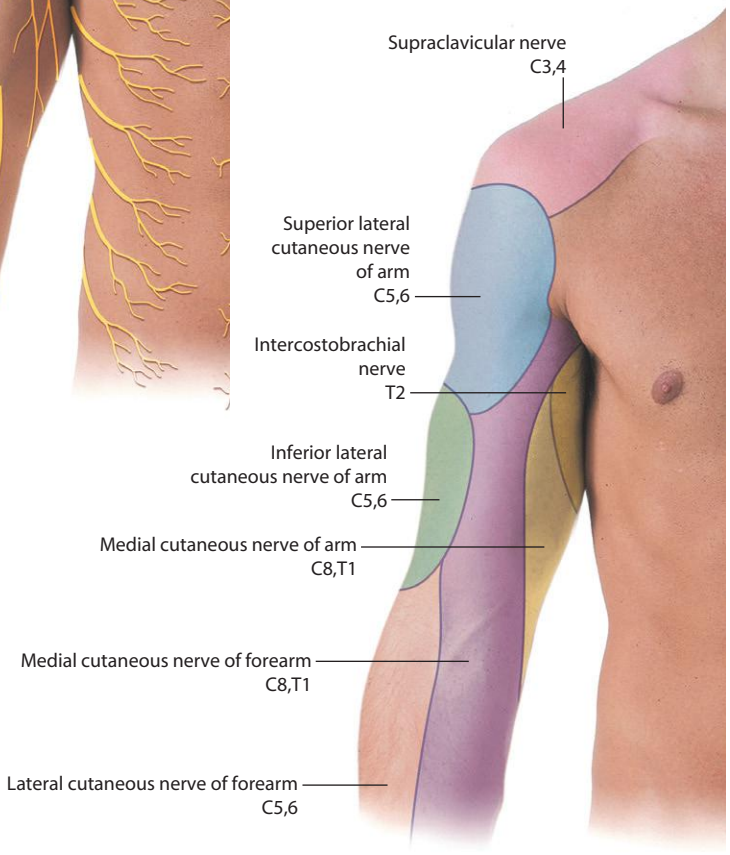

Areas of distribution of the cutaneous nerves of the arm

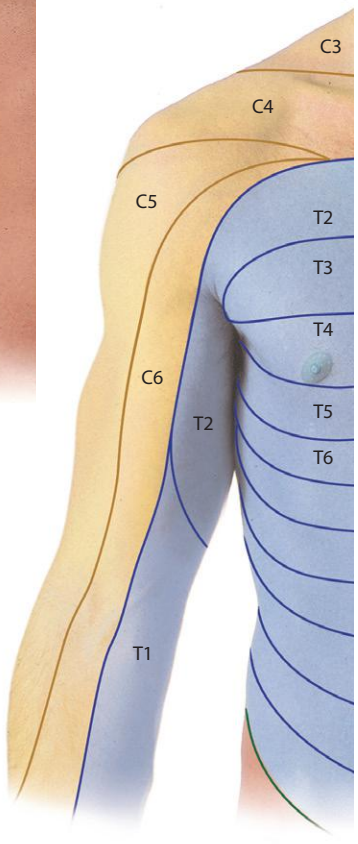

Dermatomes of the arm

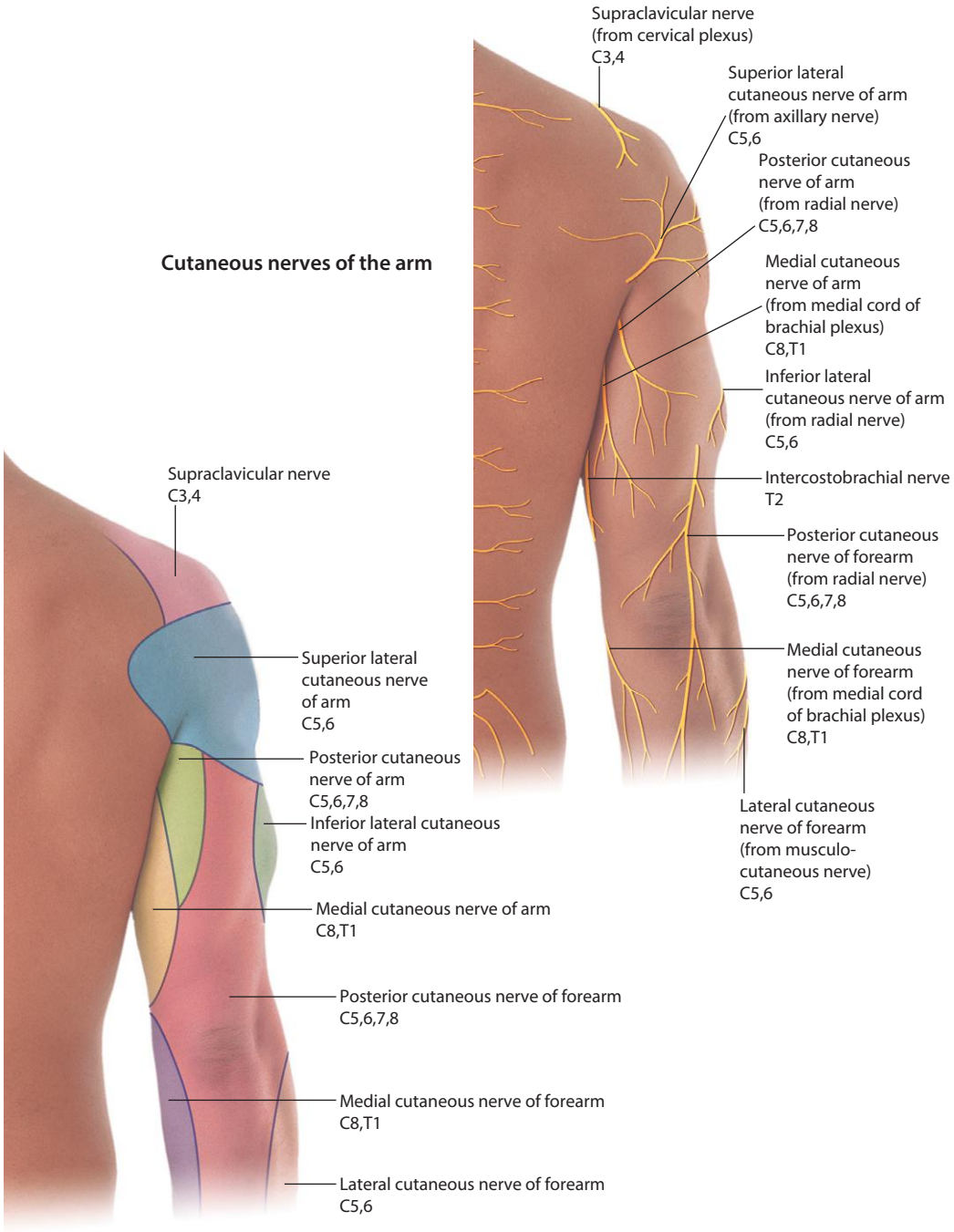

Cutaneous nerves of the arm

Areas of distribution of the cutaneous nerves of the arm

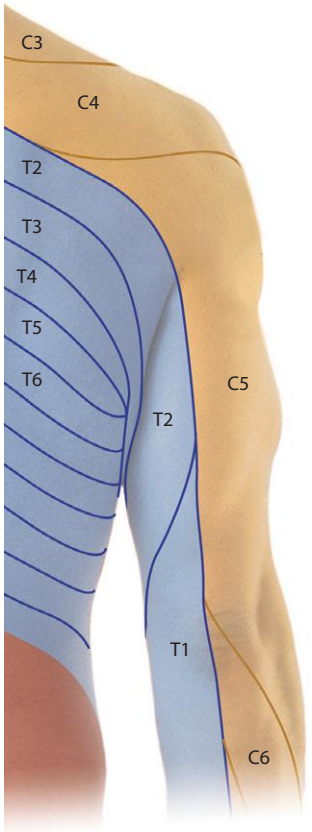

Dermatomes of the arm

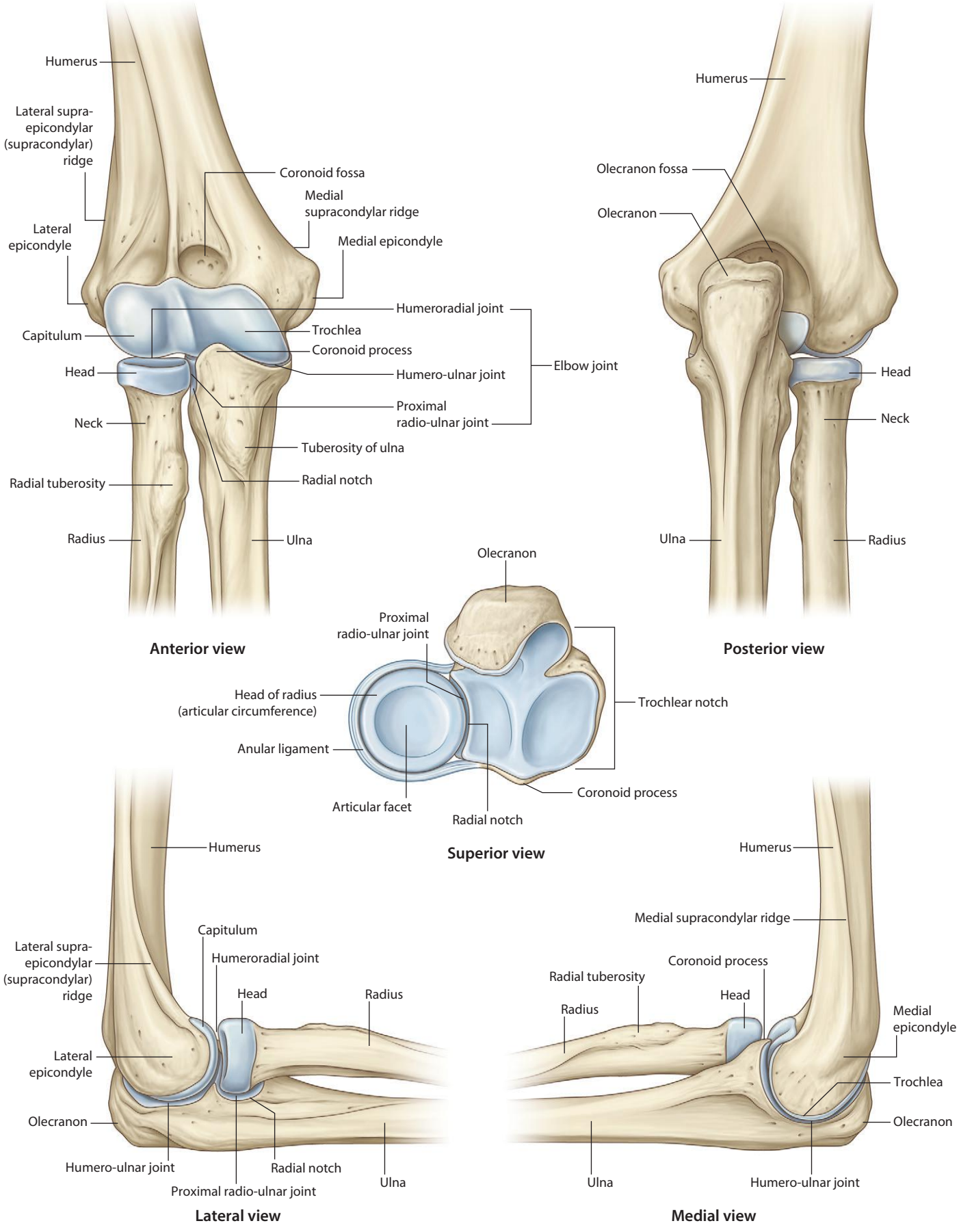
Humerus
Lateral supra-epicondylar (supracondylar) ridge
Coronoid fossa
Medial supracondylar ridge
Lateral epicondyle
Medial epicondyle
Humeroradial joint
Capitulum
Trochlea
Coronoid process
Head
Humero-ulnar joint
Elbow joint
Proximal radio-ulnar joint
Neck
Tuberosity of ulna
Radial tuberosity
Radial notch
Radius
Ulna
Anterior view
Humerus
Olecranon fossa
Olecranon
Head
Neck
Ulna
Radius
Posterior view
Olecranon
Proximal radio-ulnar joint
Head of radius (articular circumference)
Trochlear notch
Anular ligament
Coronoid process
Articular facet
Radial notch
Superior view
Humerus
Capitulum
Lateral supra-epicondylar (supracondylar) ridge
Humeroradial joint
Head
Radius
Lateral epicondyle
Olecranon
Humero-ulnar joint
Radial notch
Ulna
Proximal radio-ulnar joint
Lateral view
Humerus
Medial supracondylar ridge
Coronoid process
Radial tuberosity
Head
Radius
Medial epicondyle
Trochlea
Olecranon
Ulna
Humero-ulnar joint
Medial view

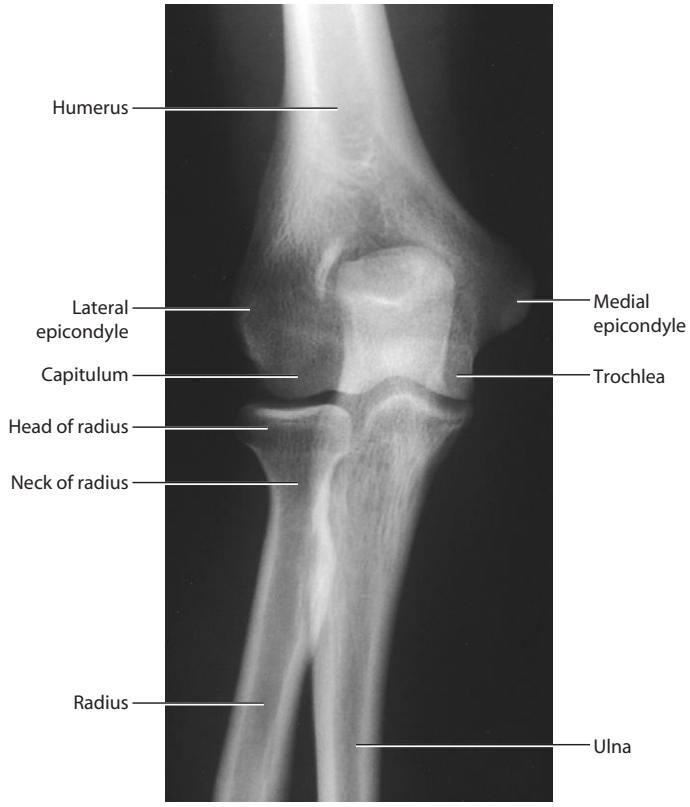

Normal elbow joint.
Radiograph, AP view

Normal elbow joint.
Radiograph, lateral view

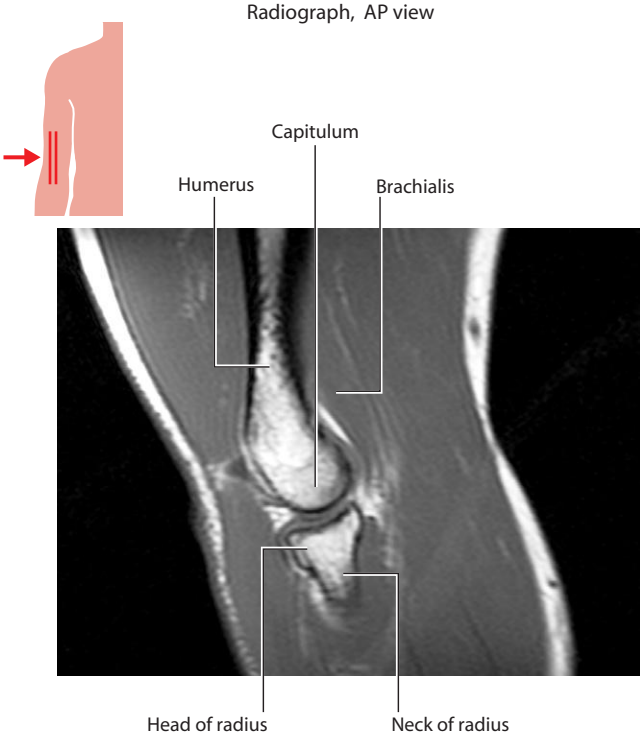

Articulation of the capitulum of the humerus and the head of the radius at the elbow joint.
T2-weighted MR image in sagittal plane

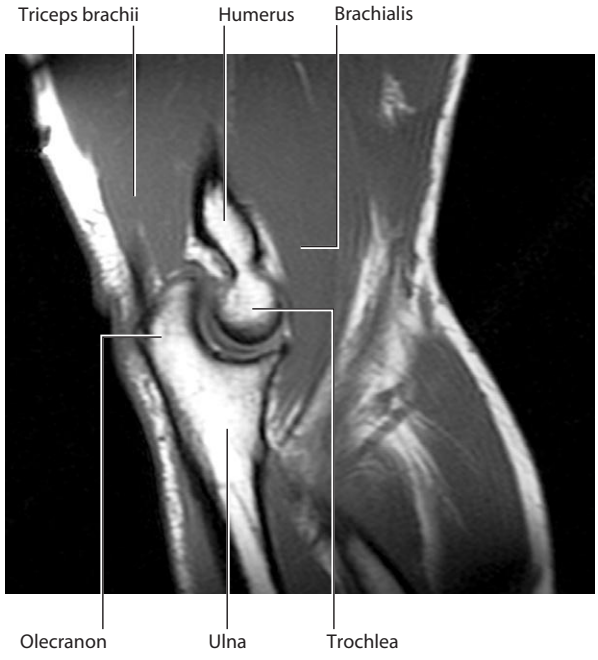

Articulation of the trochlea of the humerus and the trochlear notch of the ulna.
T2-weighted MR image in sagittal plane

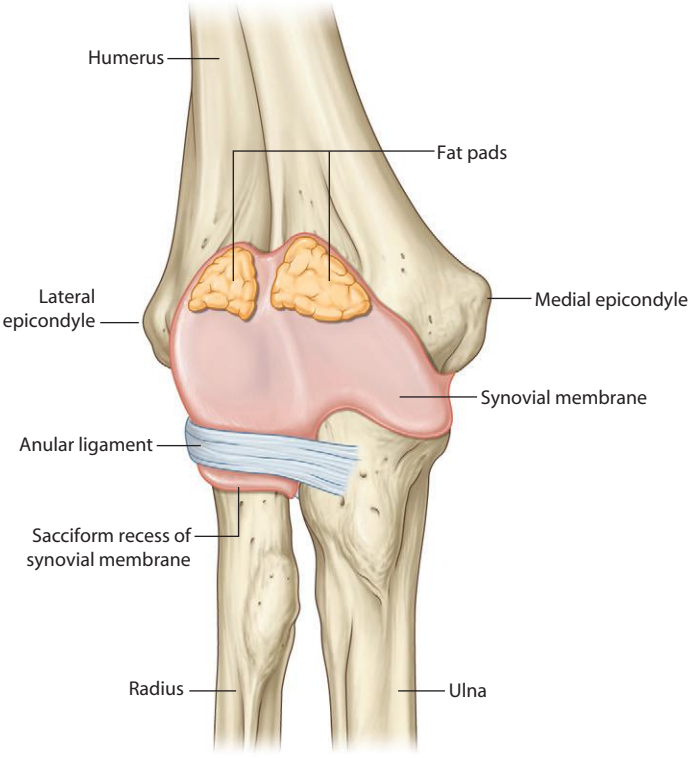

Synovial membrane of the elbow joint (anterior view)

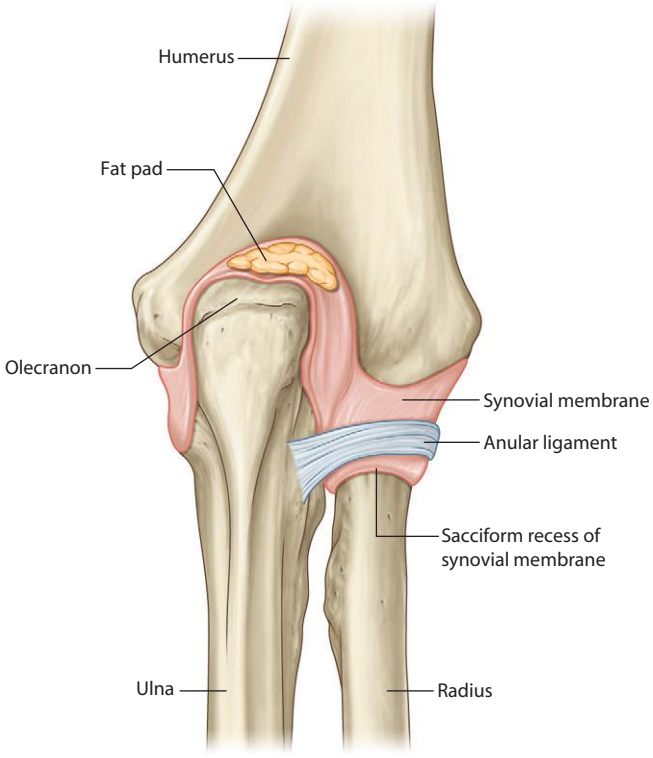

Synovial membrane of the elbow joint (posterior view)

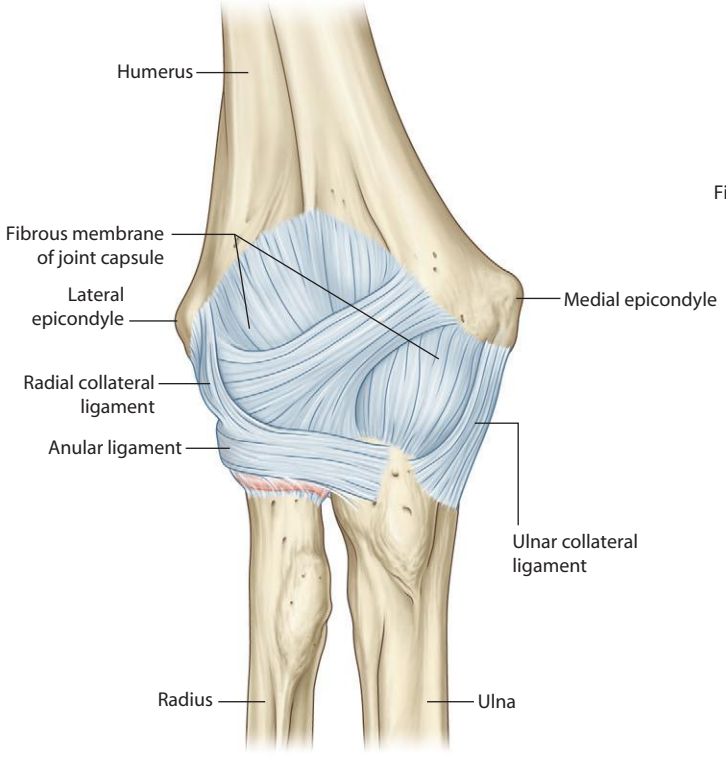

Fibrous membrane of joint capsule and ligaments of the elbow joint (anterior view)

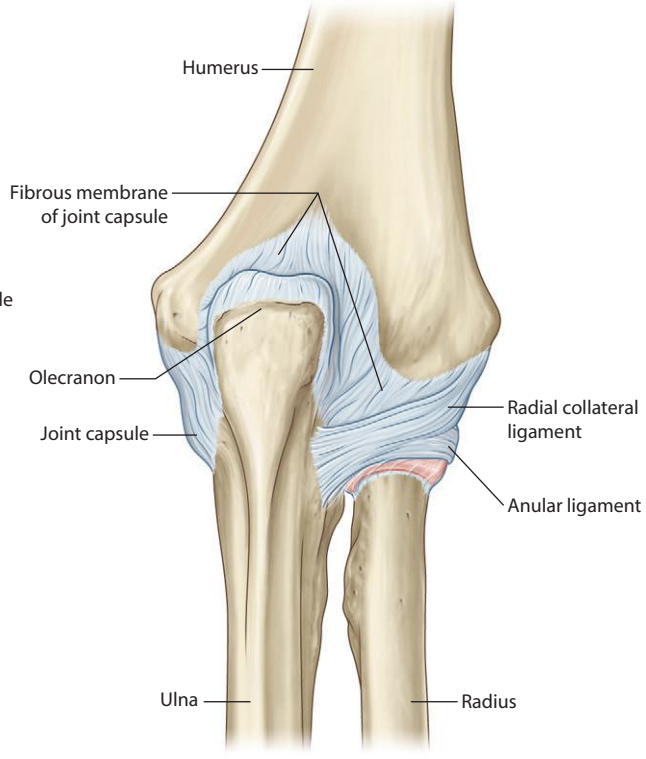

Fibrous membrane of joint capsule and ligaments of the elbow joint (posterior view)

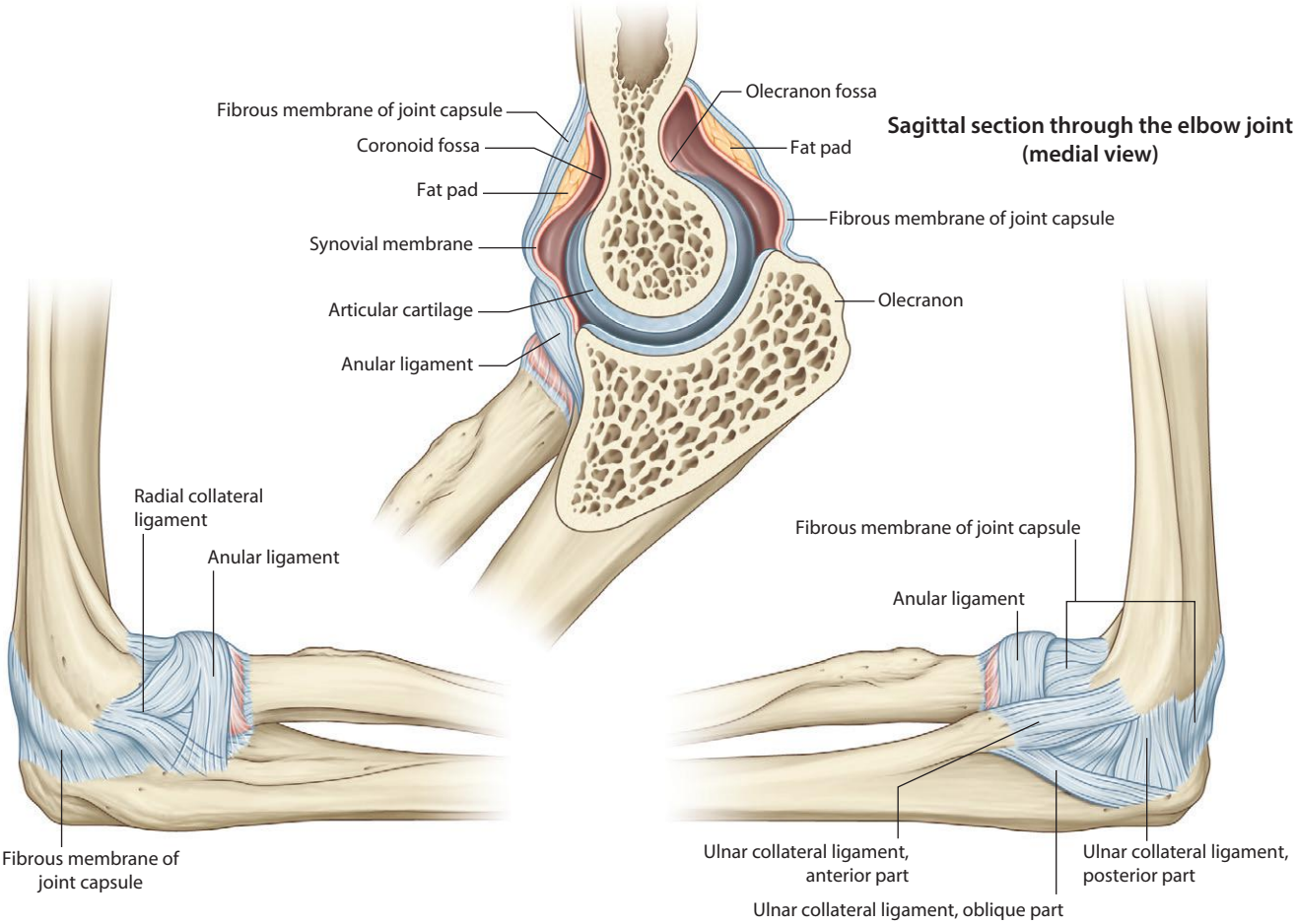

Sagittal section through the elbow joint (medial view)

Fibrous membrane of joint capsule and ligaments of the elbow joint (lateral view)

Fibrous membrane of joint capsule and ligaments of the elbow joint (medial view)

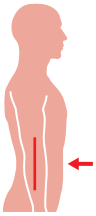

Normal elbow joint.
T2-weighted MR image in coronal plane

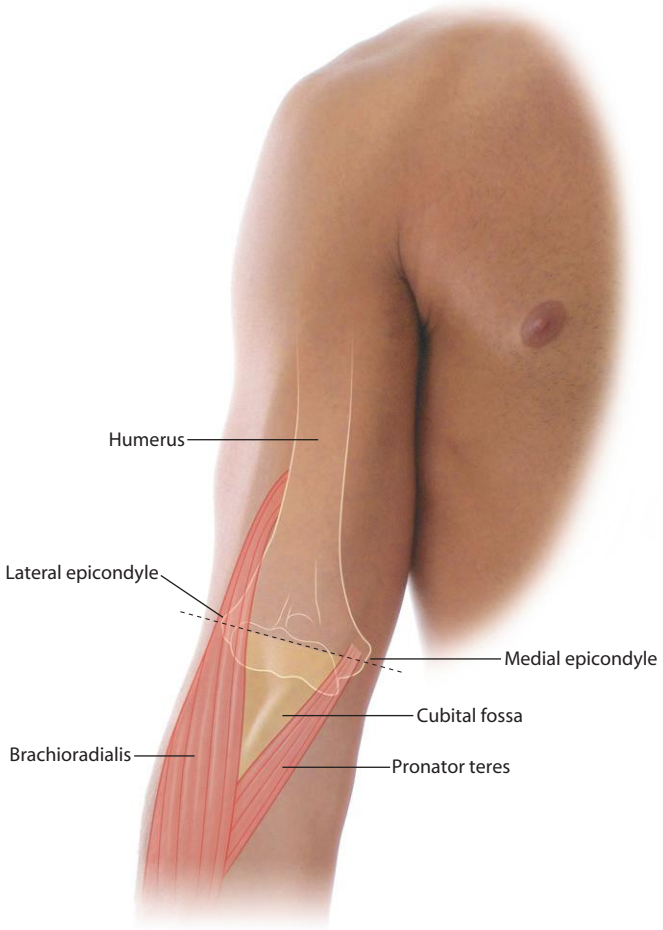

Margins of the cubital fossa

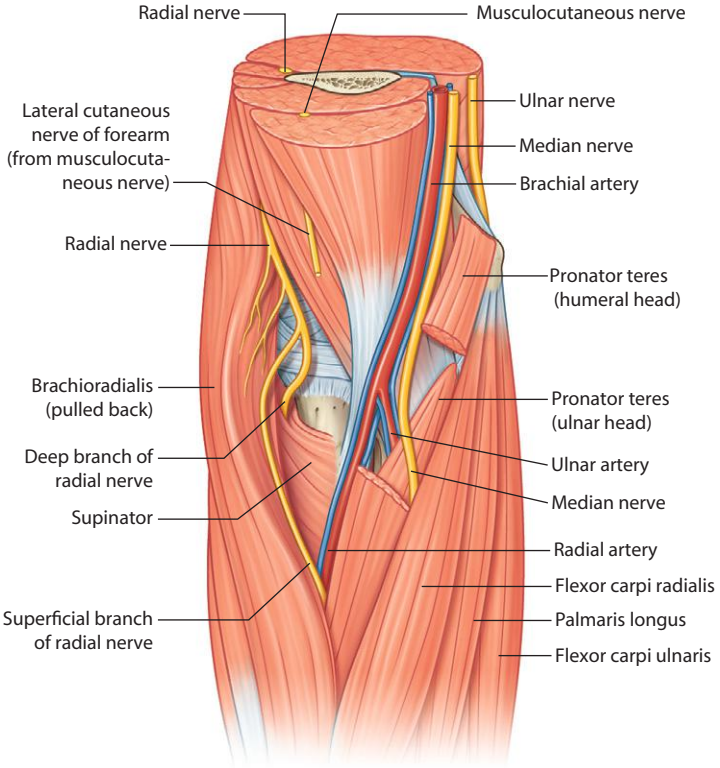

Position of the radial nerve

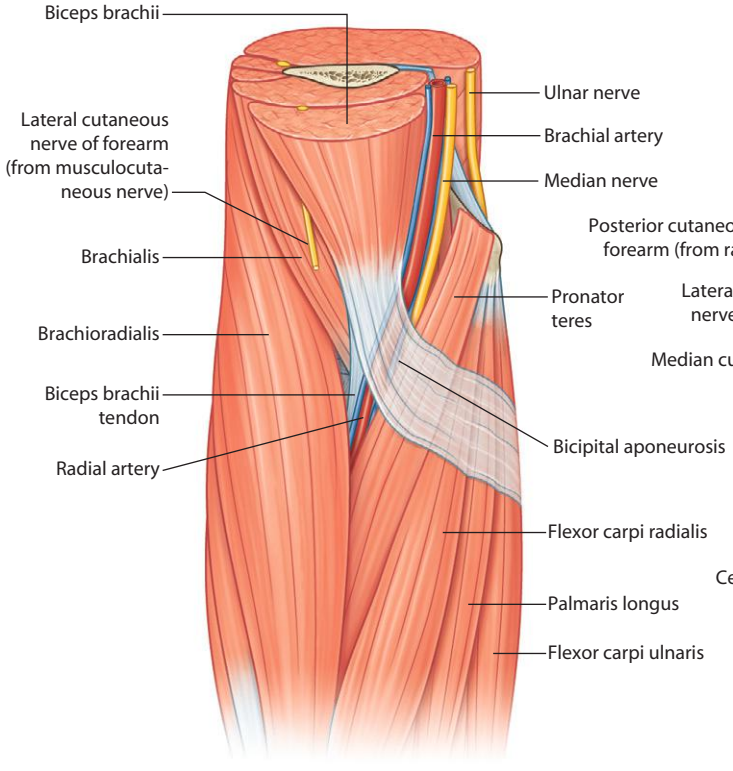

Contents of the cubital fossa

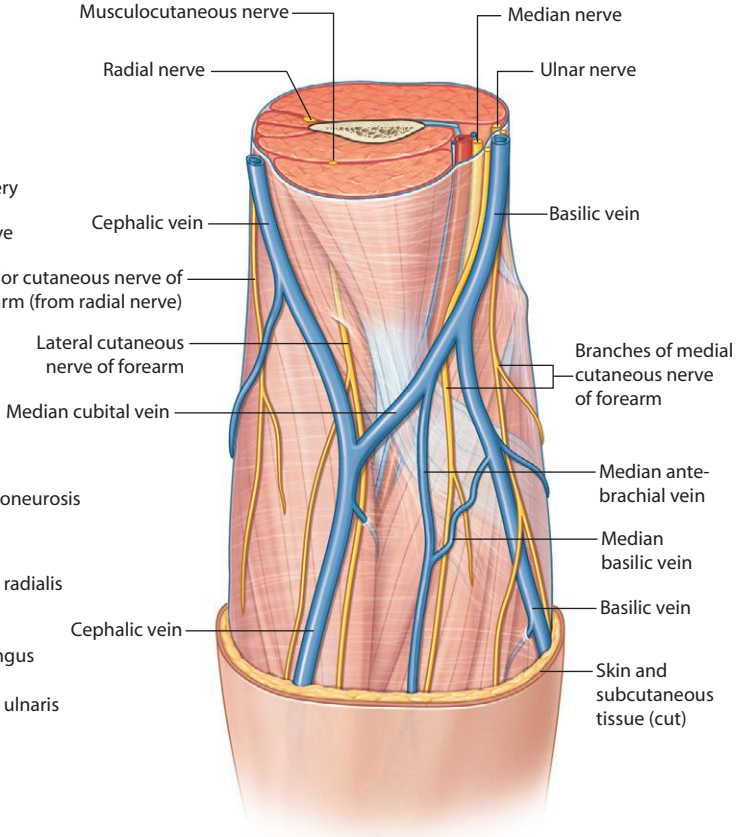

Superficial structures

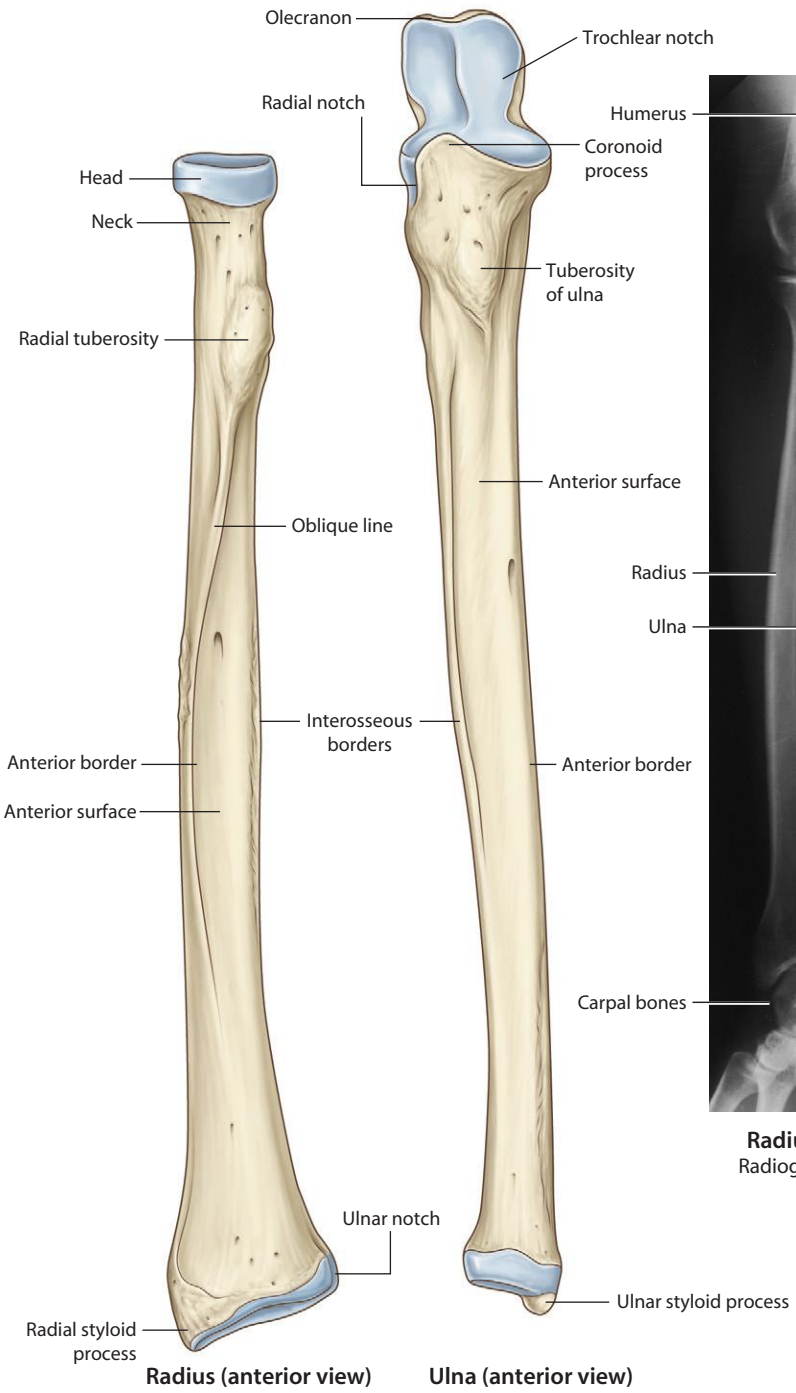

Radius (anterior view) **Ulna (anterior view)**

Radius and ulna.
Radiograph, AP view

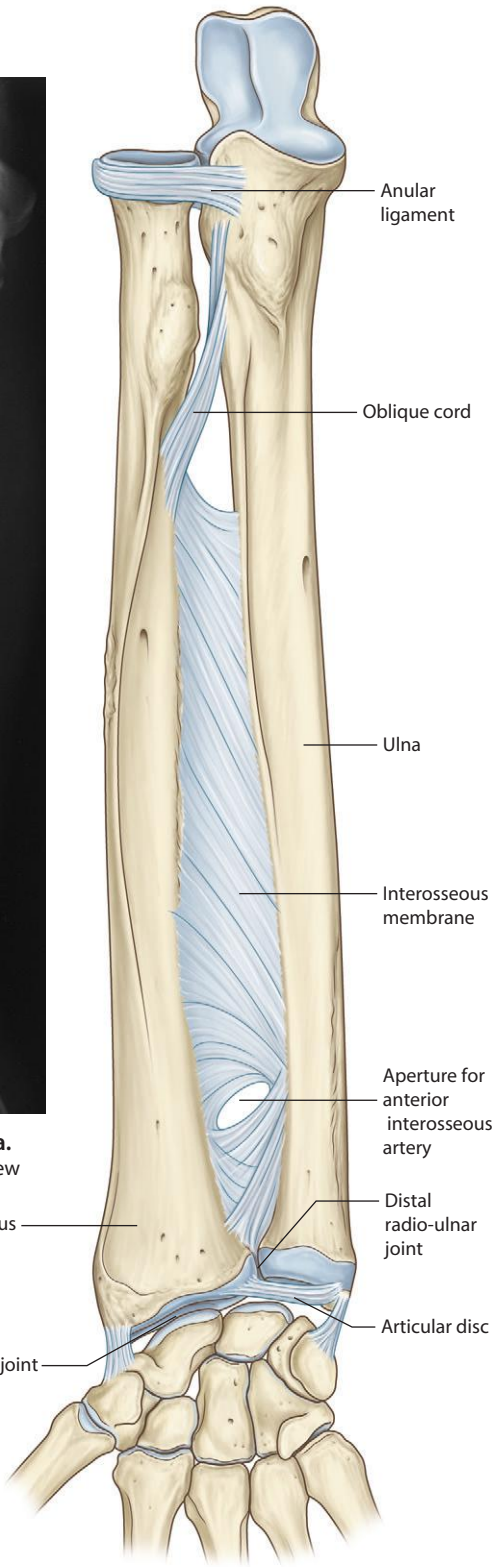

Distal radio-ulnar joint and the interosseous membrane

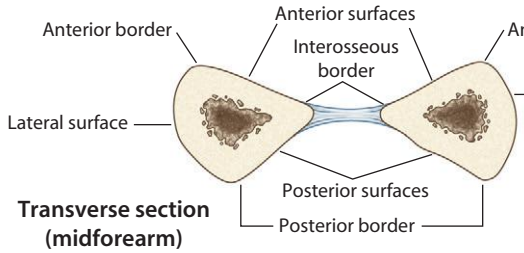

Transverse section (midforearm)

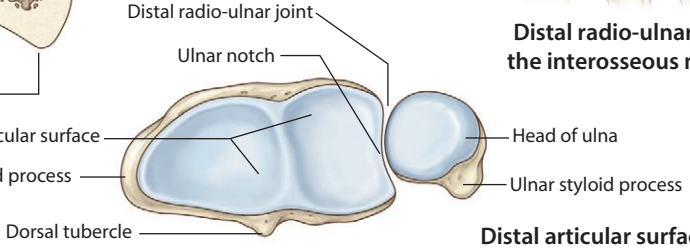

Distal articular surface

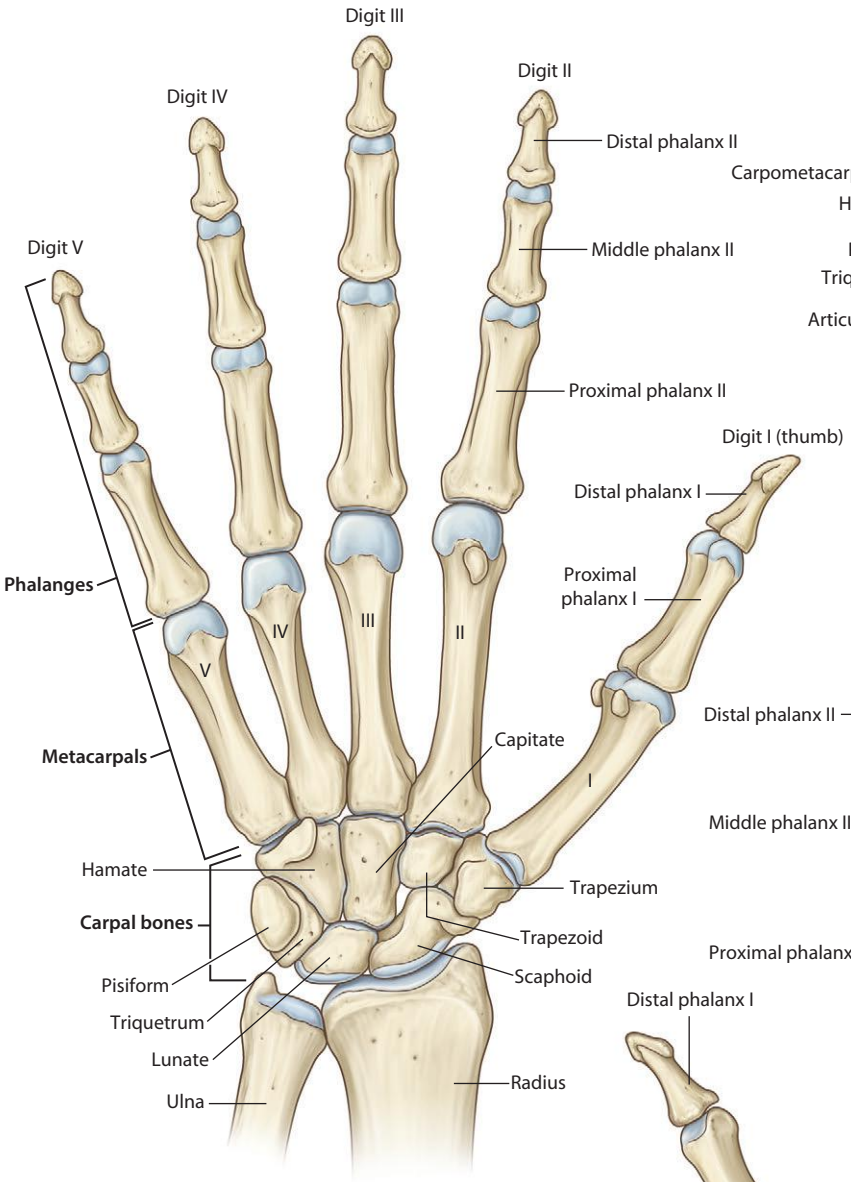

Bones of the hand (palmar view)

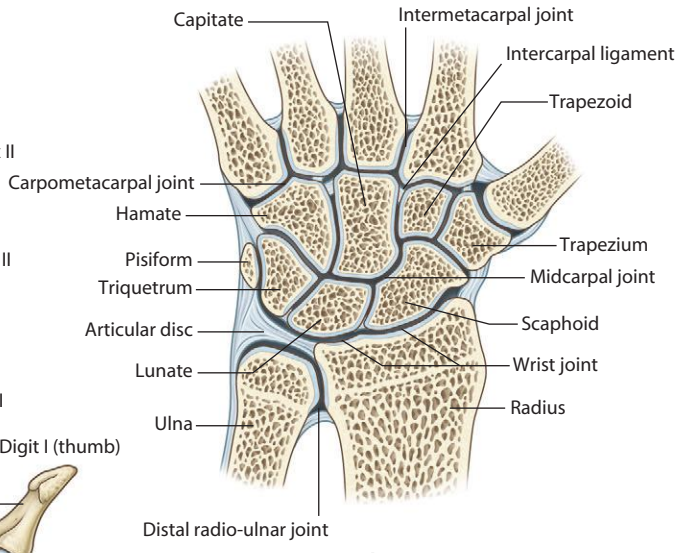

Coronal section

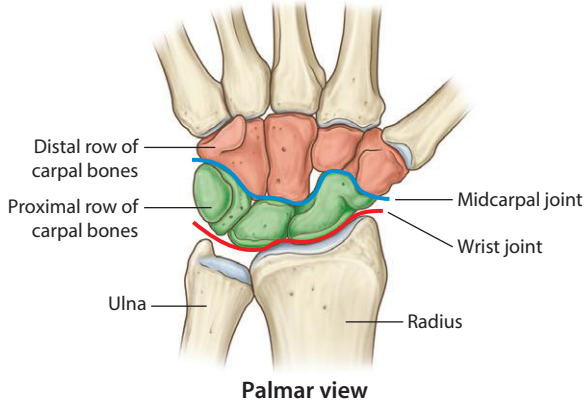

Palmar view

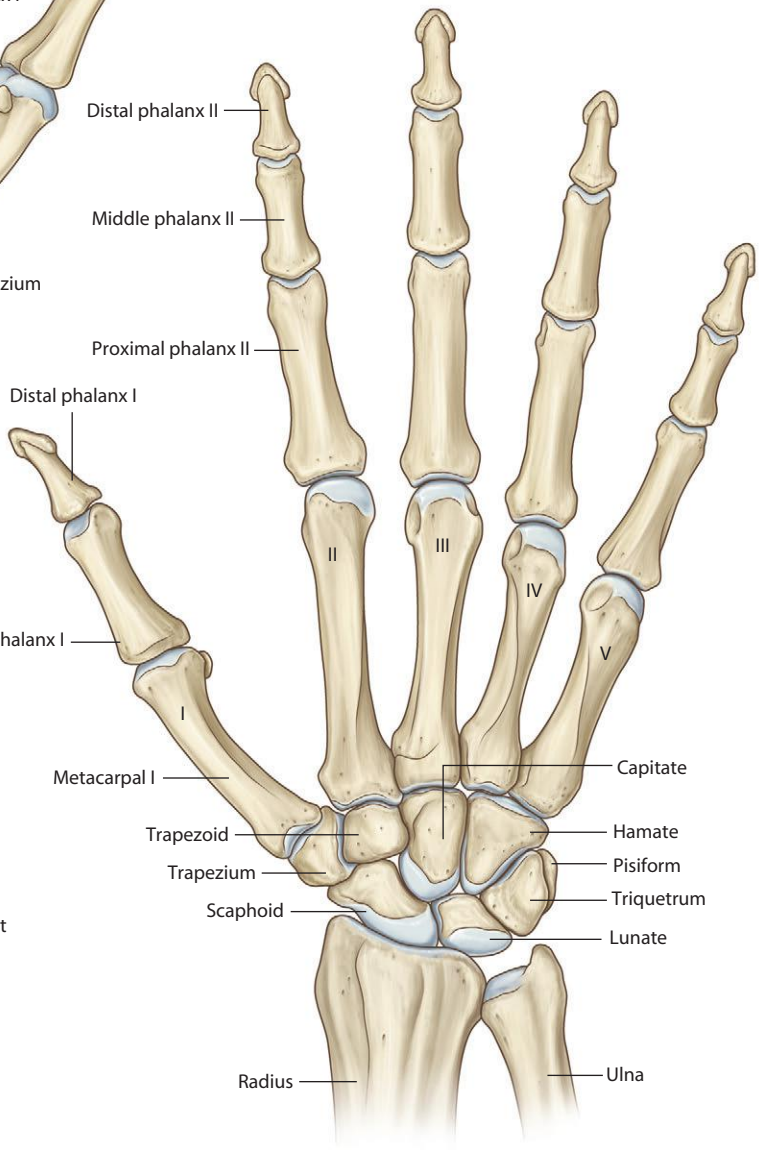

Bones of the hand (dorsal view)

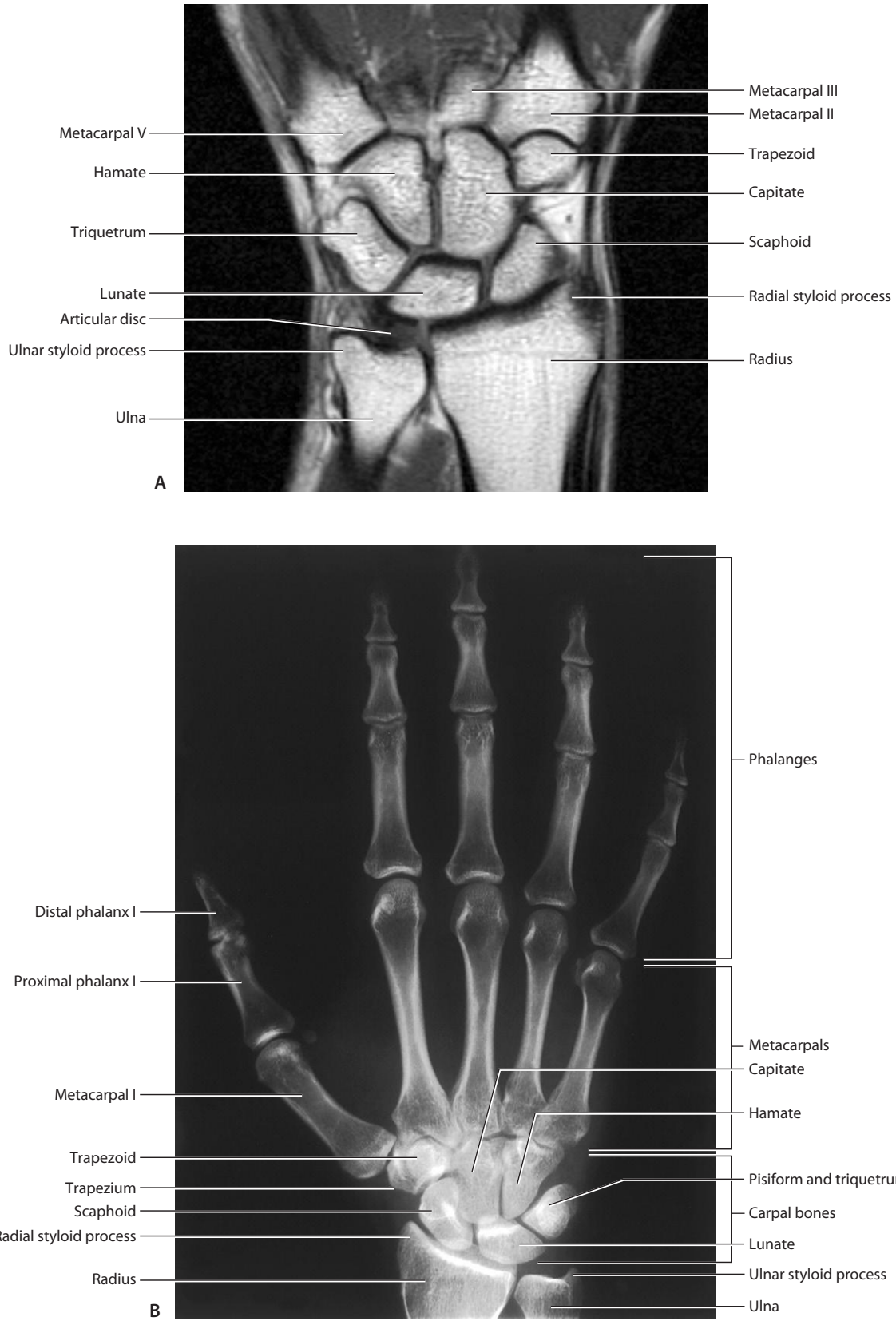

Imaging of the wrist joint, the carpal bones, and the hand.
A. T1-weighted MR image in coronal plane
B. Radiograph, AP view

Bones of the hand (anterior view)

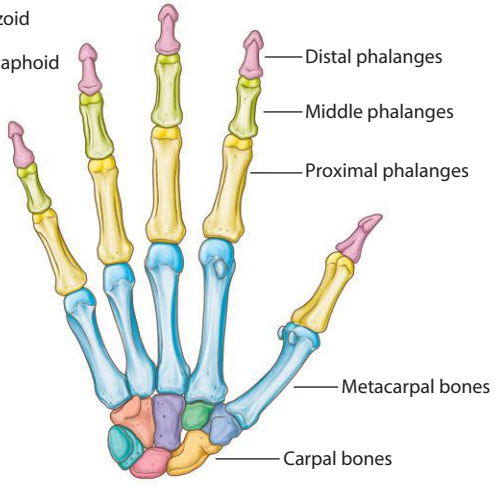

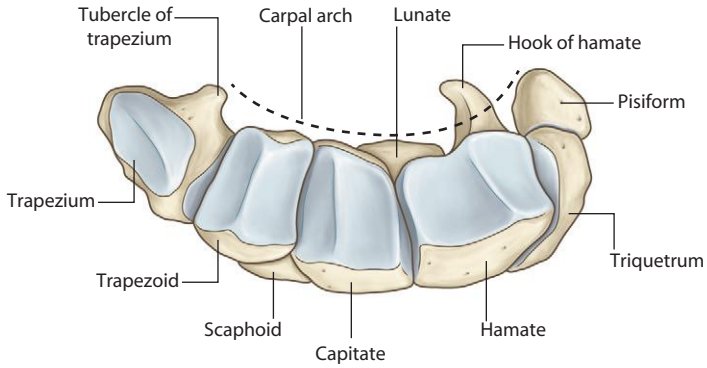

Carpal bones (distal view; pronated)

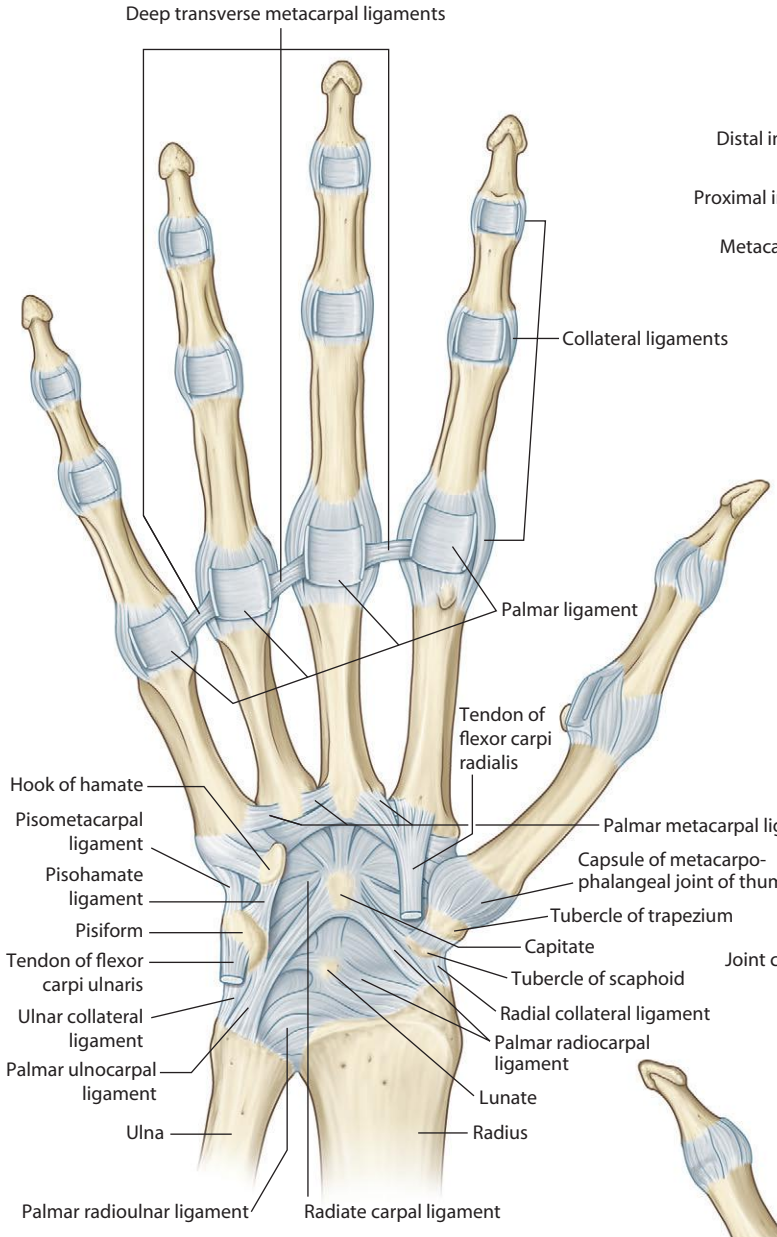

Ligaments of the hand (palmar view)

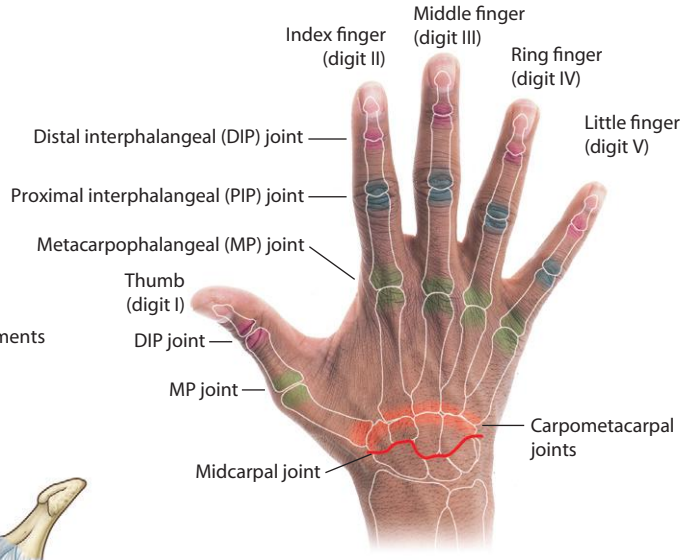

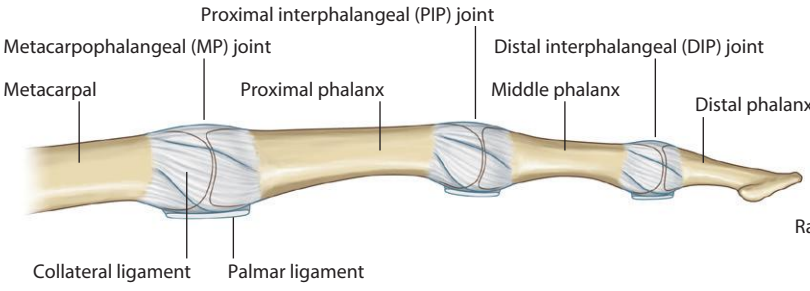

Interphalangeal joints (medial view)

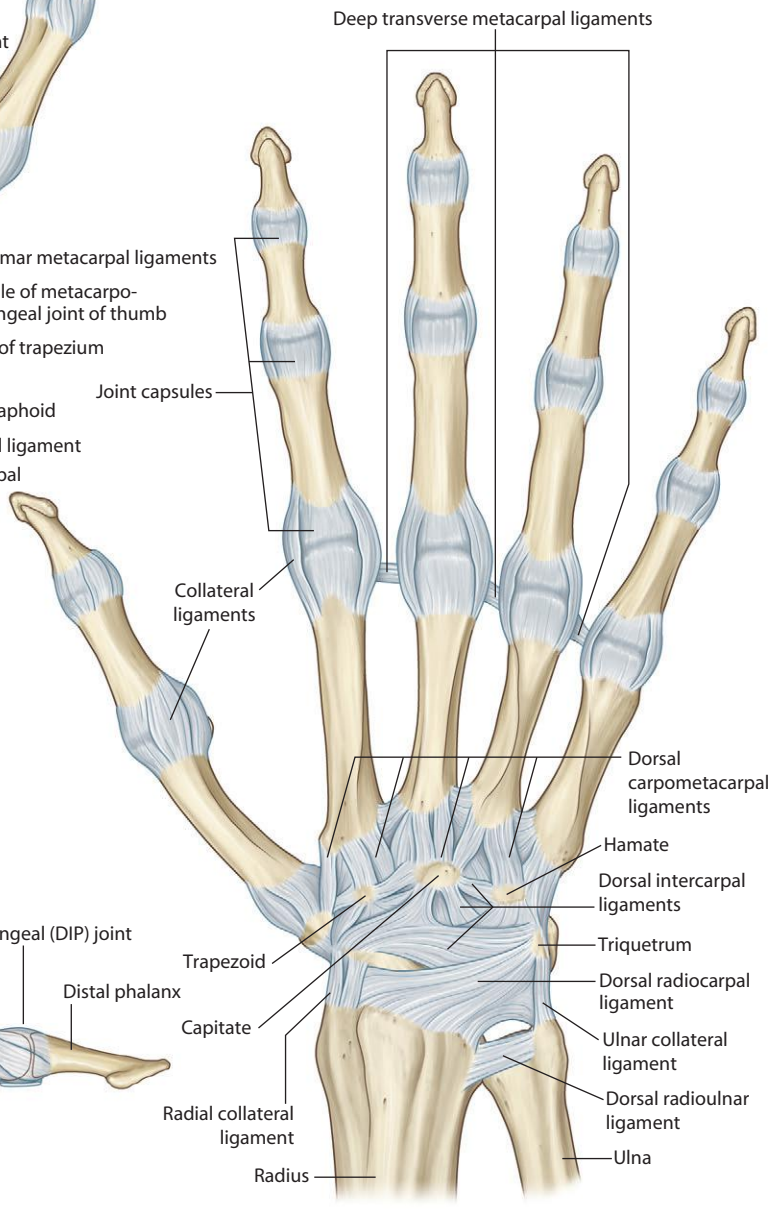

Ligaments of the hand (dorsal view)

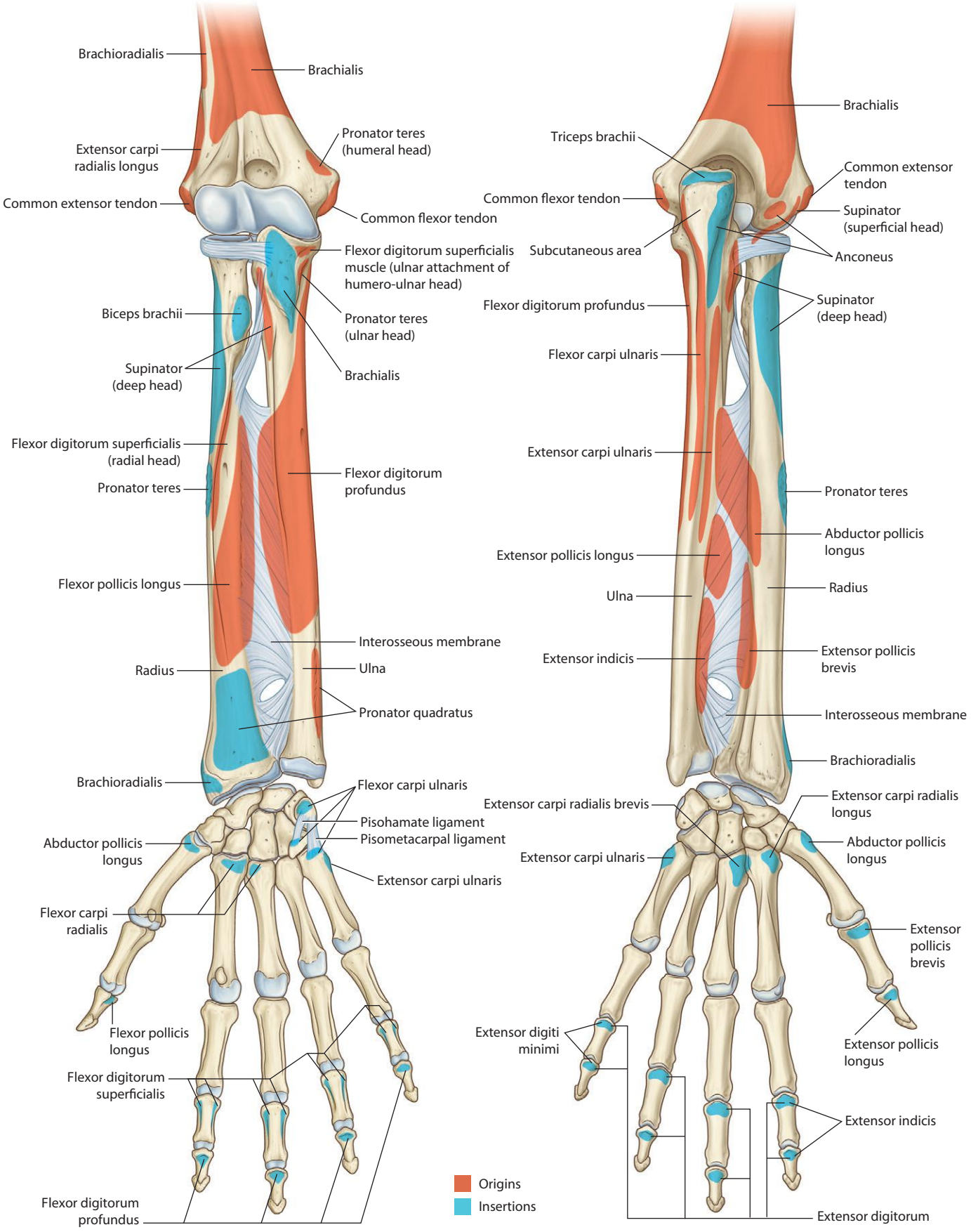

Muscle attachments of forearm (anterior view)

Muscle attachments of forearm (posterior view)

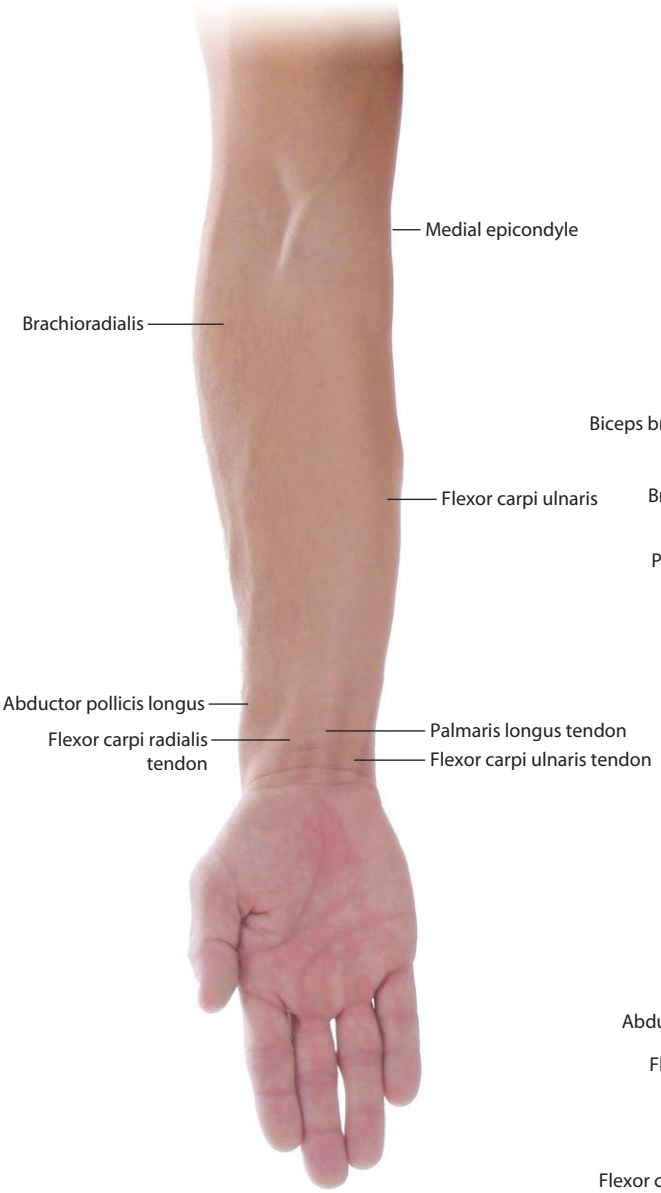

Surface anatomy (anterior view)

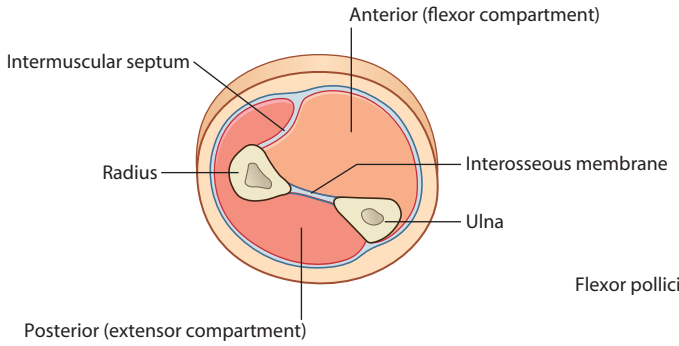

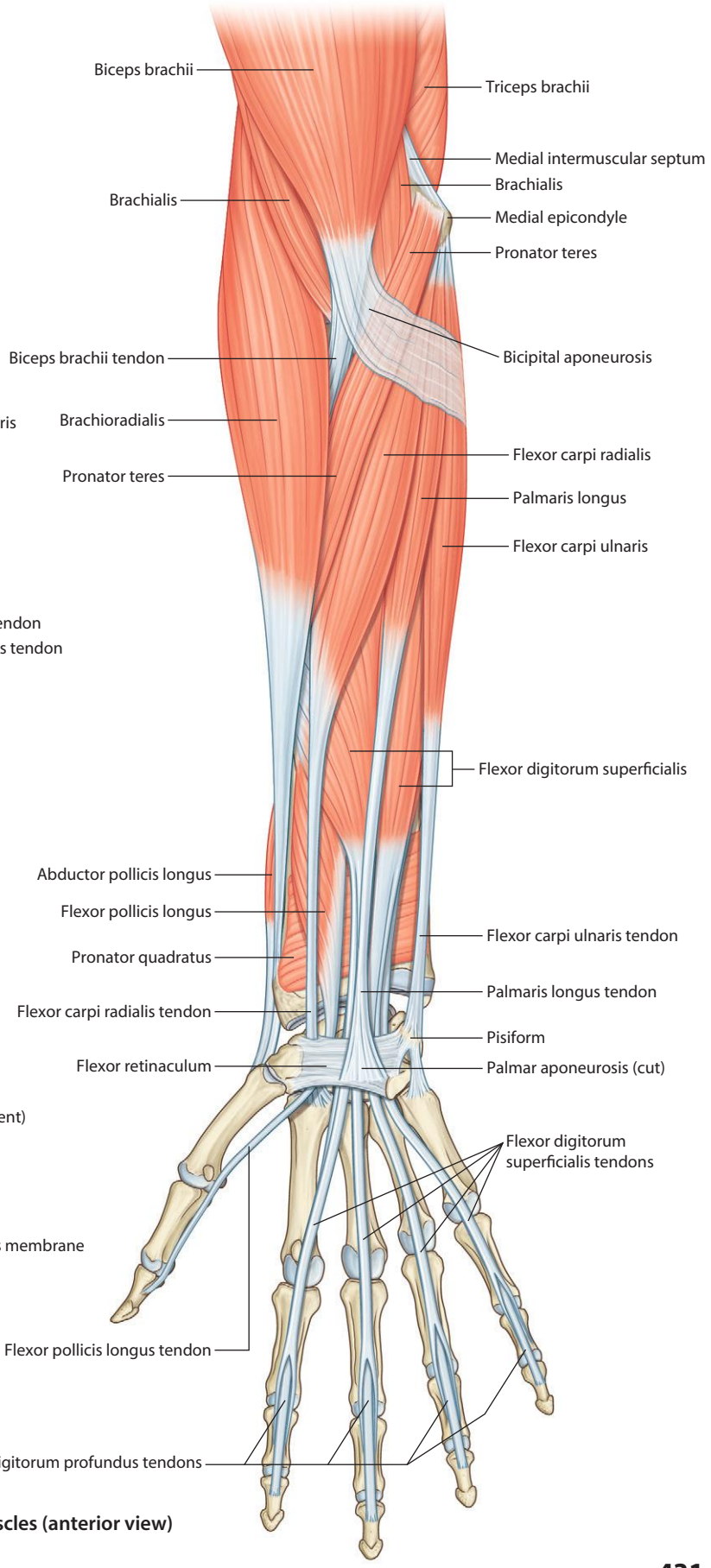

Superficial layer of forearm muscles (anterior view)

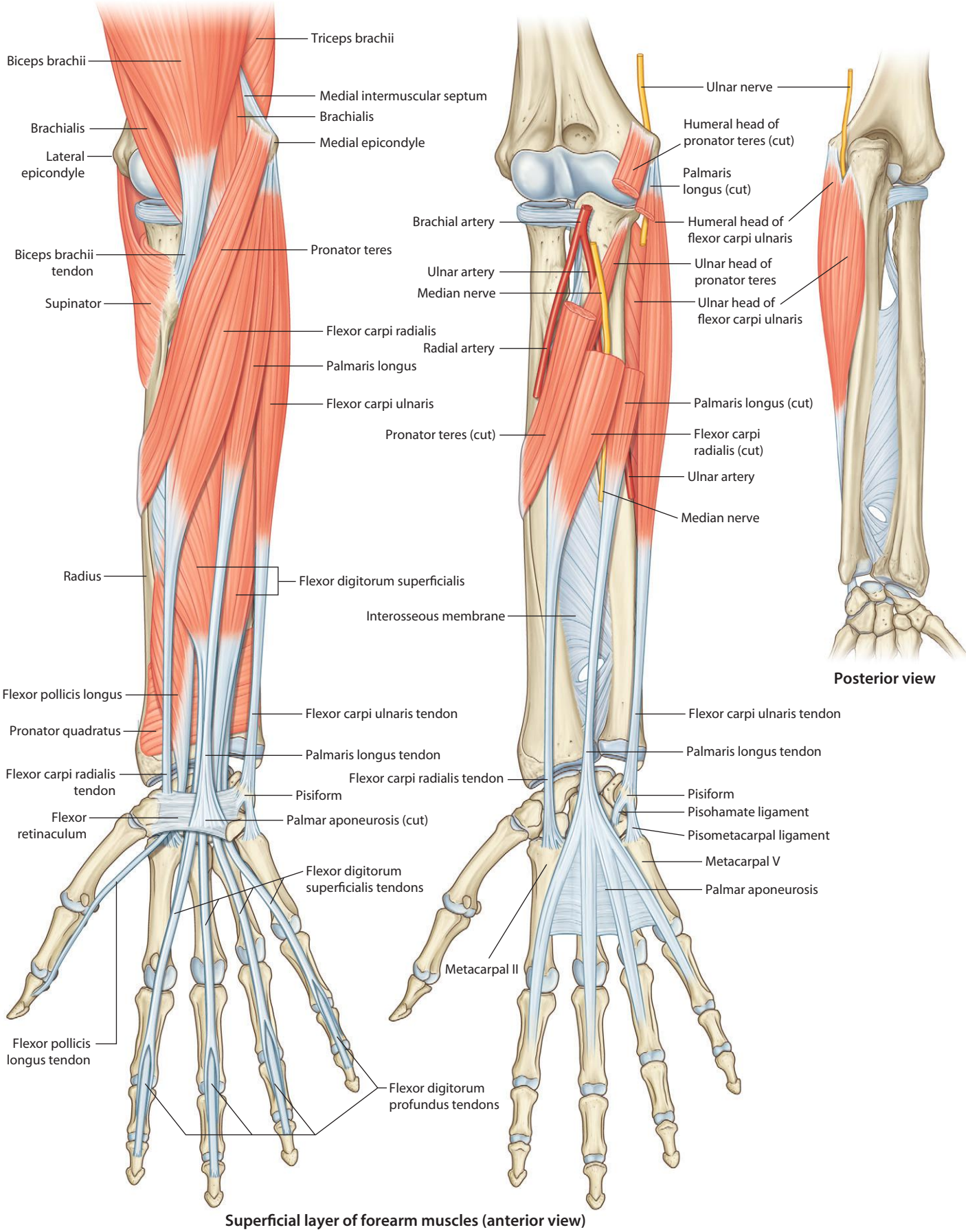

Superficial layer of forearm muscles (anterior view)

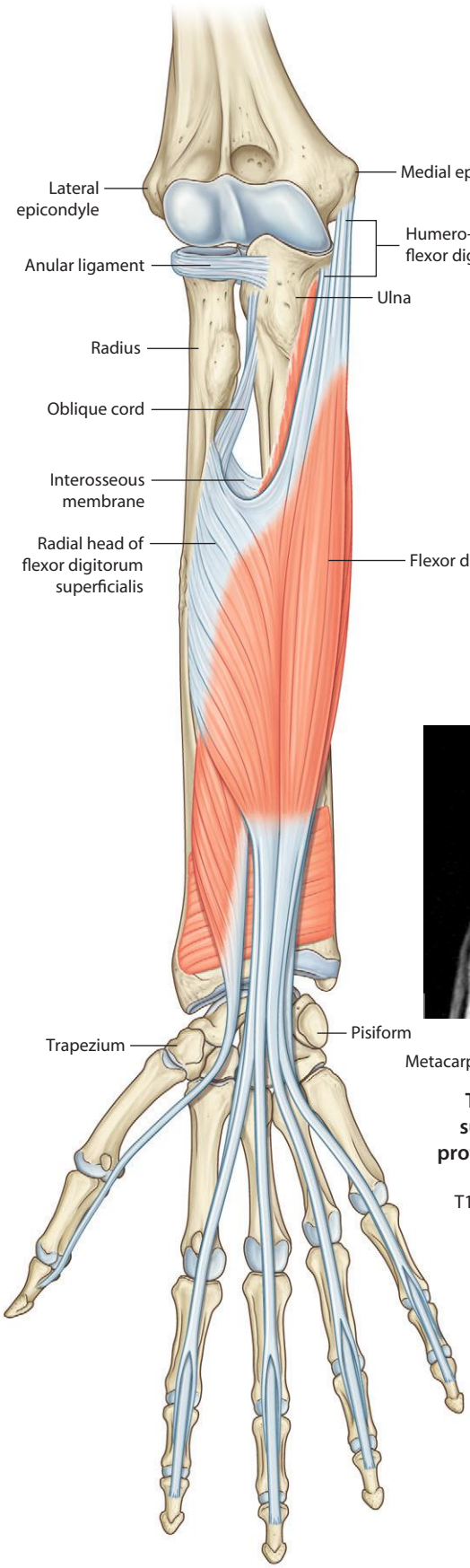

Intermediate layer of forearm muscles (anterior view)

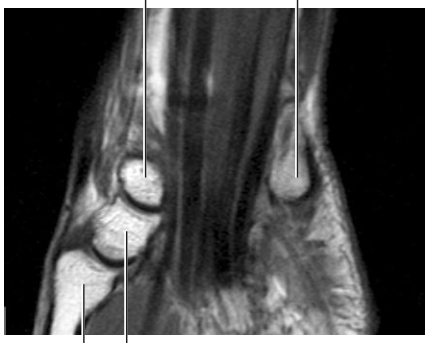

Tendons of the flexor digitorum superficialis and flexor digitorum profundus passing through the carpal tunnel into the hand.
T1-weighted MR image in coronal plane

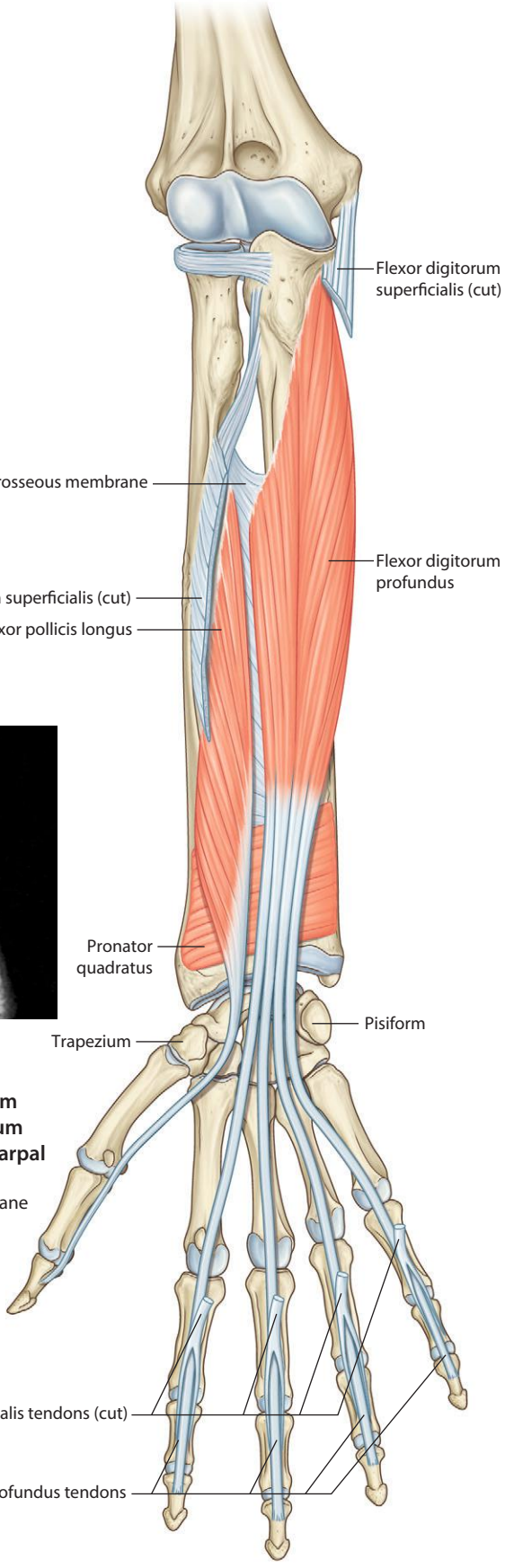

Deep layer of forearm muscles (anterior view)

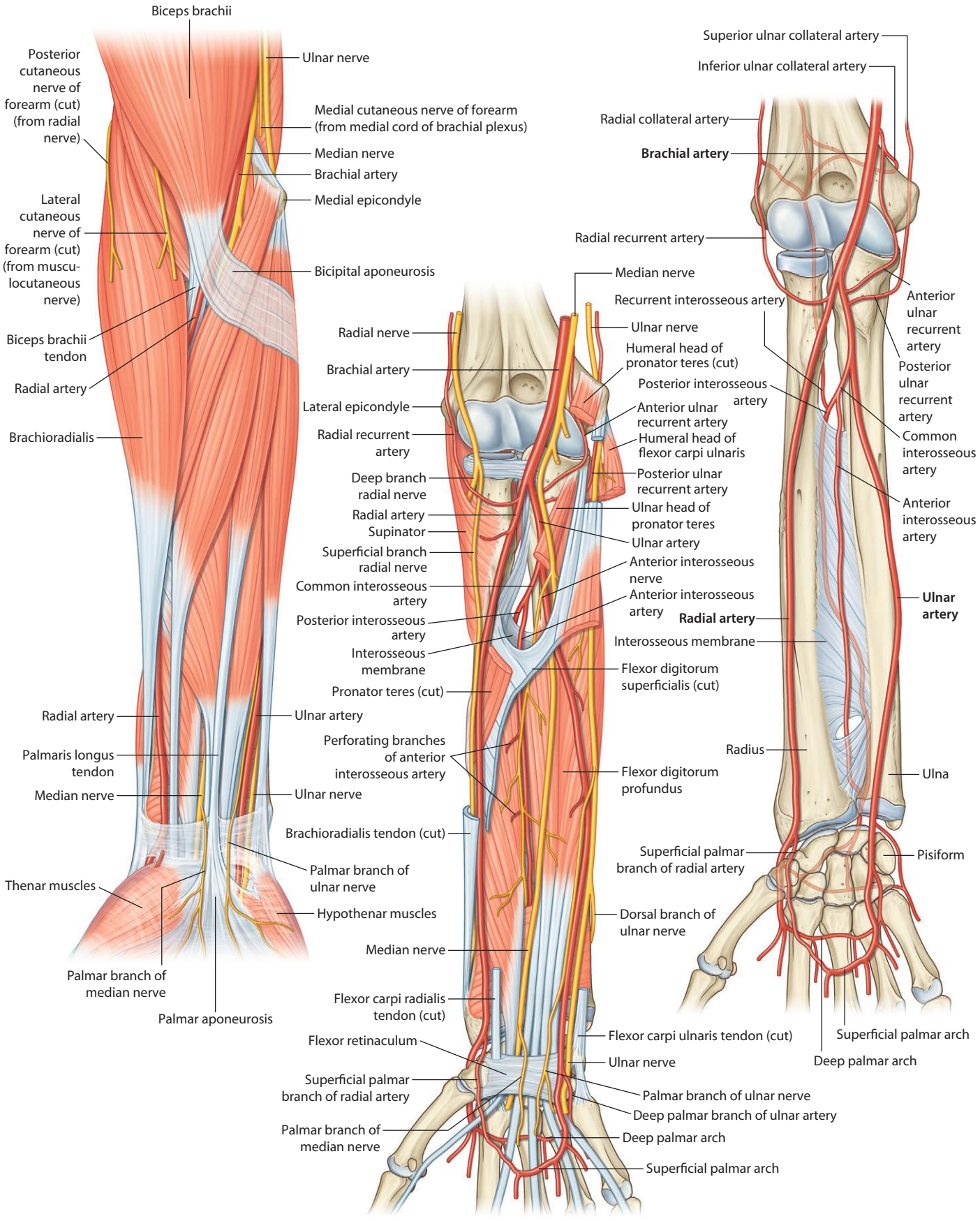

Arteries and nerves of forearm (anterior view)

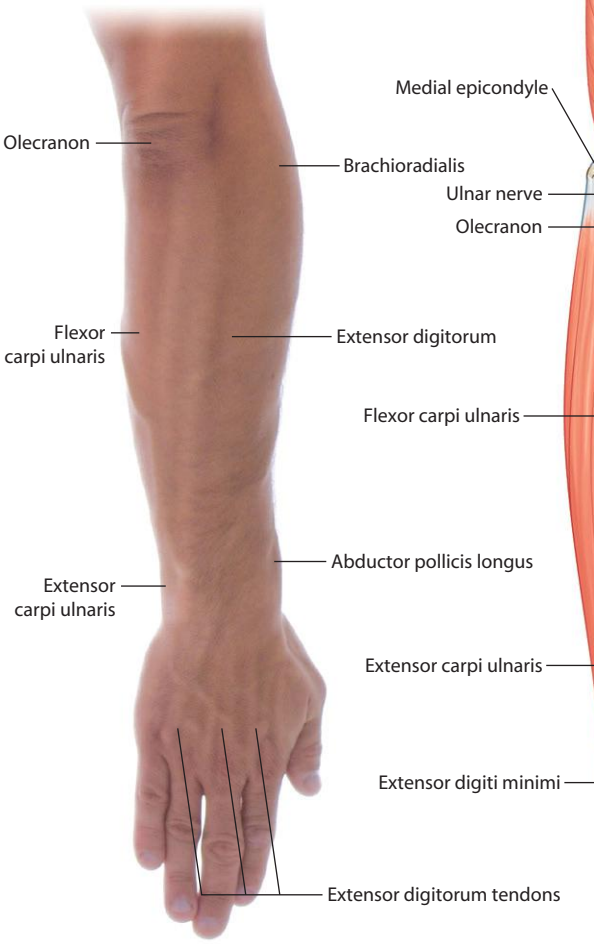

Surface anatomy (posterior view)

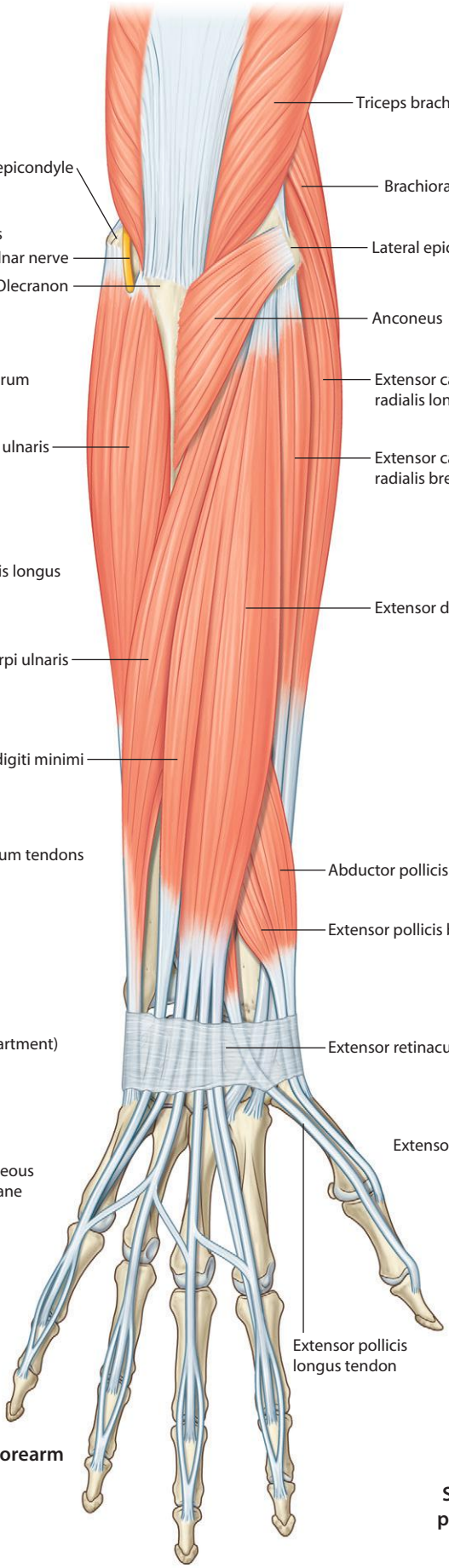

Superficial muscles of forearm (posterior view)

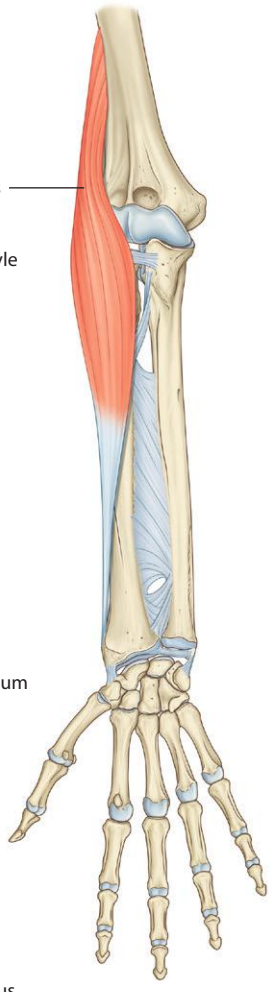

Anterior view

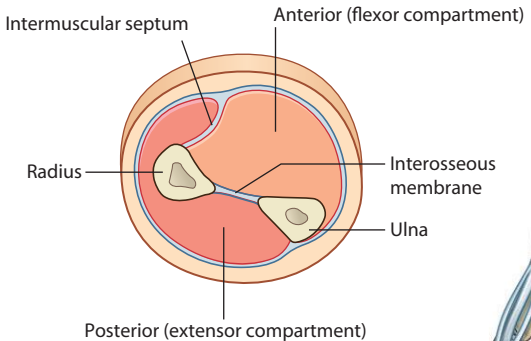

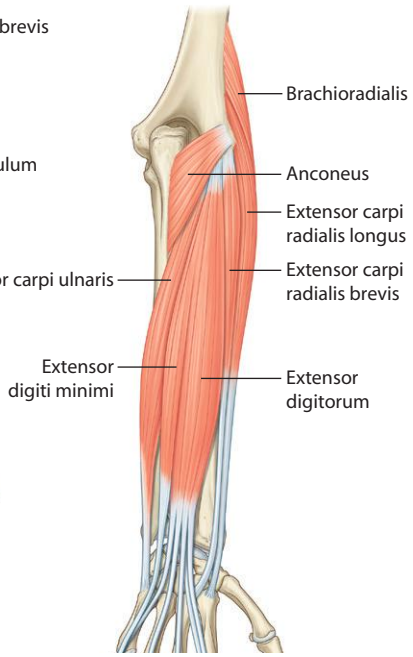

Superficial layer of muscles in the posterior compartment of forearm

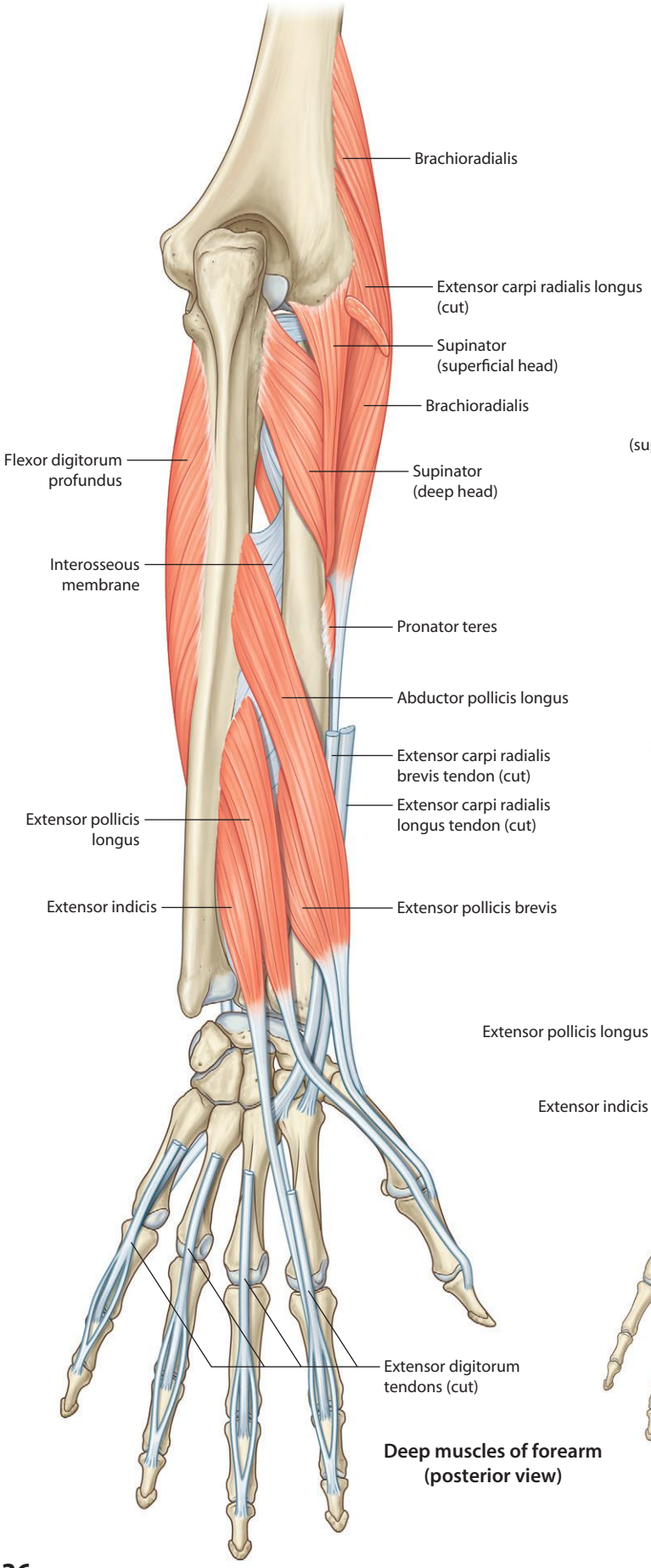

Deep muscles of forearm (posterior view)

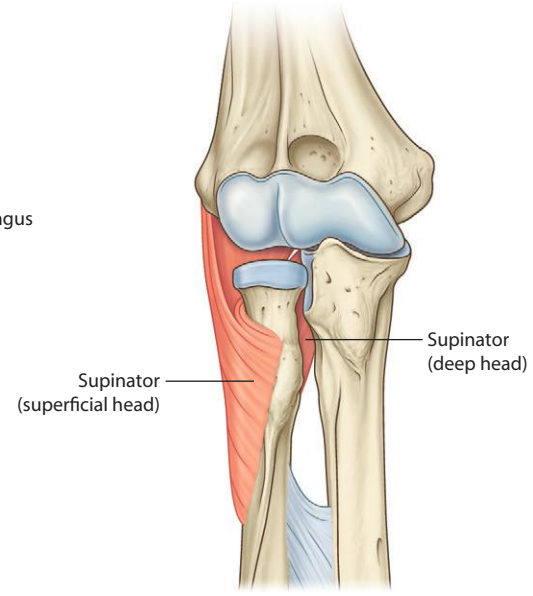

Anterior view

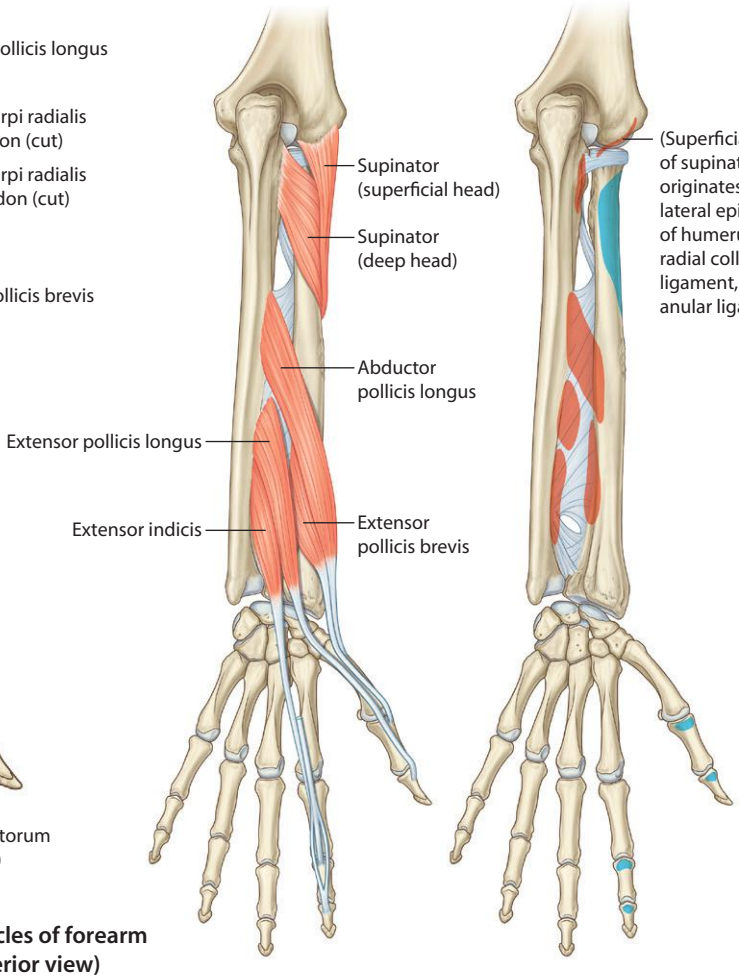

Origin of deep layer of muscles in the posterior compartment of forearm

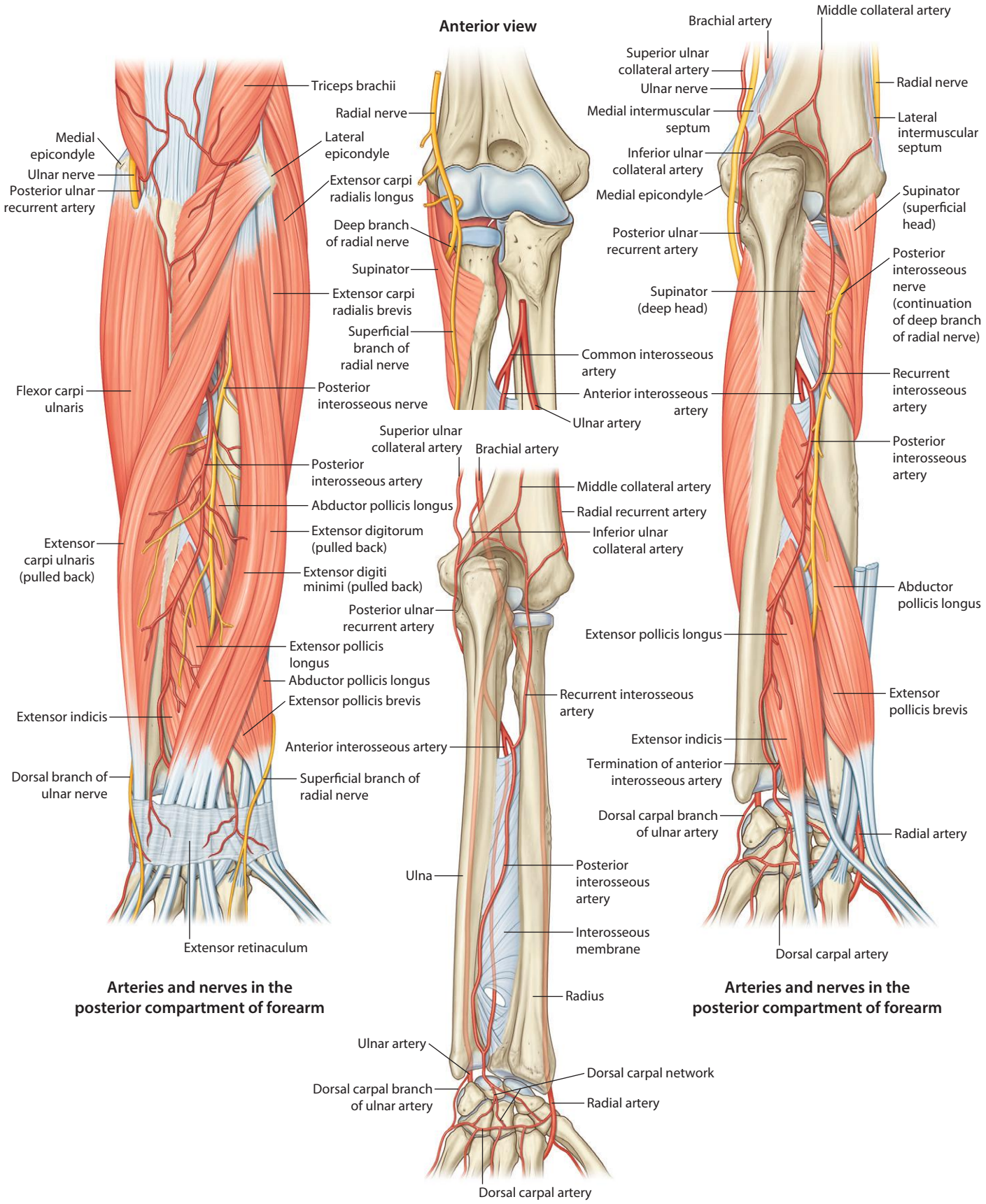
Anterior view
Triceps brachii
Radial nerve
Medial epicondyle
Lateral epicondyle
Ulnar nerve
Posterior ulnar recurrent artery
Extensor carpi radialis longus
Deep branch of radial nerve
Supinator
Extensor carpi radialis brevis
Superficial branch of radial nerve
Flexor carpi ulnaris
Posterior interosseous nerve
Common interosseous artery
Anterior interosseous artery
Ulnar artery
Superior ulnar collateral artery
Brachial artery
Posterior interosseous artery
Middle collateral artery
Abductor pollicis longus
Radial recurrent artery
Extensor digitorum (pulled back)
Inferior ulnar collateral artery
Extensor carpi ulnaris (pulled back)
Extensor digiti minimi (pulled back)
Posterior ulnar recurrent artery
Extensor pollicis longus
Abductor pollicis longus
Extensor pollicis brevis
Extensor indicis
Anterior interosseous artery
Dorsal branch of ulnar nerve
Superficial branch of radial nerve
Recurrent interosseous artery
Ulna
Posterior interosseous artery
Interosseous membrane
Extensor retinaculum
Radius
Ulnar artery
Dorsal carpal network
Dorsal carpal branch of ulnar artery
Radial artery
Dorsal carpal artery
Arteries and nerves in the posterior compartment of forearm
Arteries of the forearm (posterior view)
Brachial artery
Middle collateral artery
Superior ulnar collateral artery
Radial nerve
Ulnar nerve
Lateral intermuscular septum
Medial intermuscular septum
Inferior ulnar collateral artery
Medial epicondyle
Supinator (superficial head)
Posterior ulnar recurrent artery
Posterior interosseous nerve (continuation of deep branch of radial nerve)
Supinator (deep head)
Recurrent interosseous artery
Posterior interosseous artery
Abductor pollicis longus
Extensor pollicis longus
Extensor pollicis brevis
Extensor indicis
Termination of anterior interosseous artery
Dorsal carpal branch of ulnar artery
Radial artery
Dorsal carpal artery
Arteries and nerves in the posterior compartment of forearm

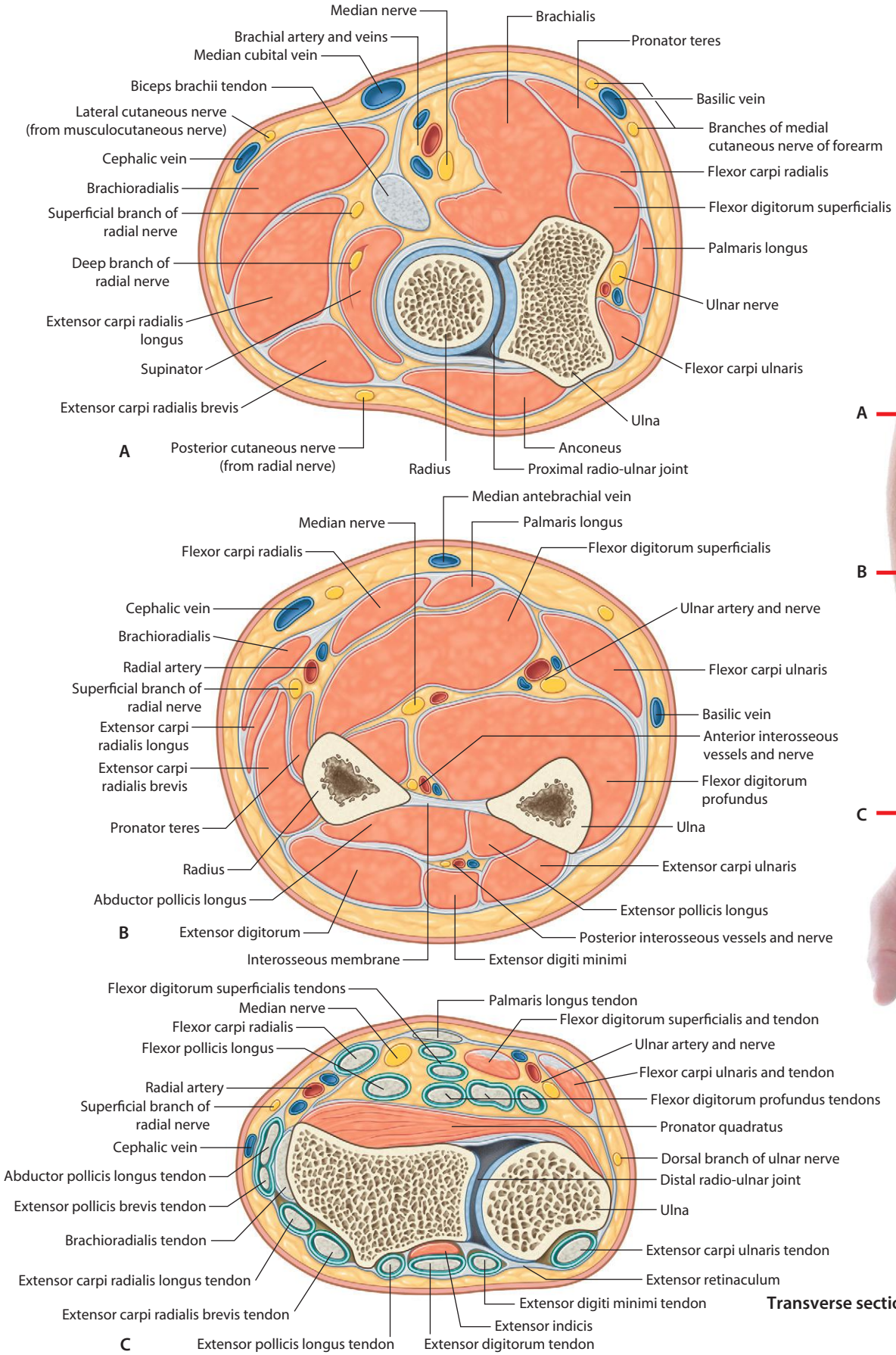

Transverse sections through forearm

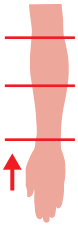

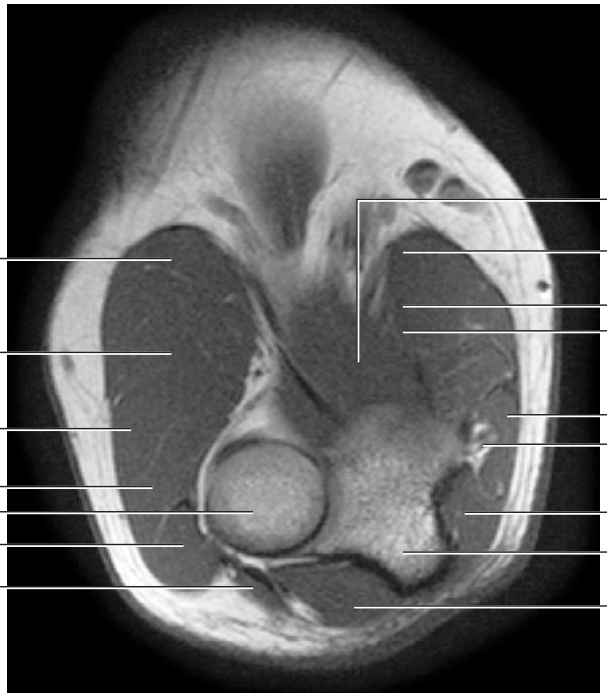

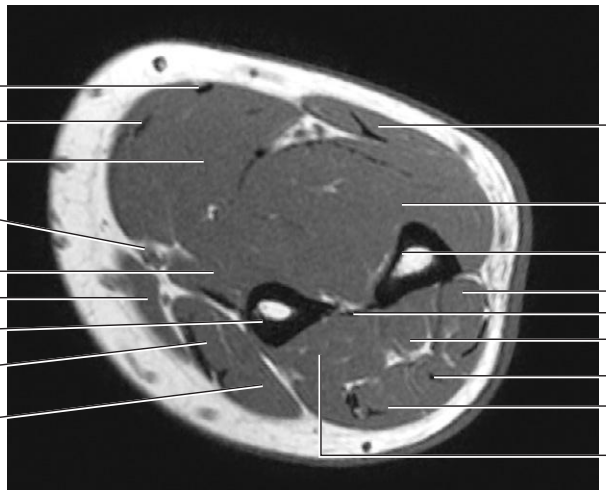

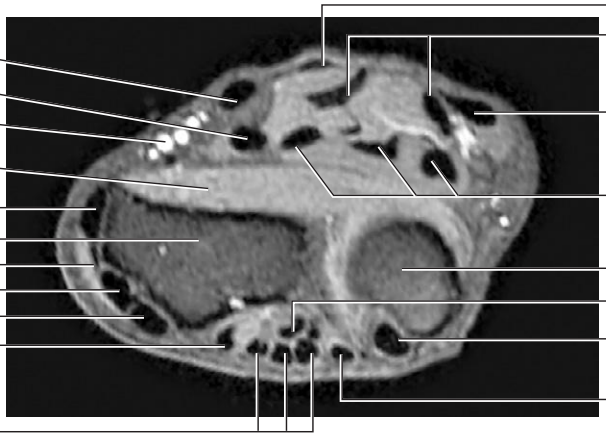

Transverse/axial sections through the forearm.
A. Proximal/upper forearm. T1-weighted MR image in axial plane
B. Middle forearm. T1-weighted MR image in axial plane
C. Distal/lower forearm. Fat-saturated proton density MR image in axial plane

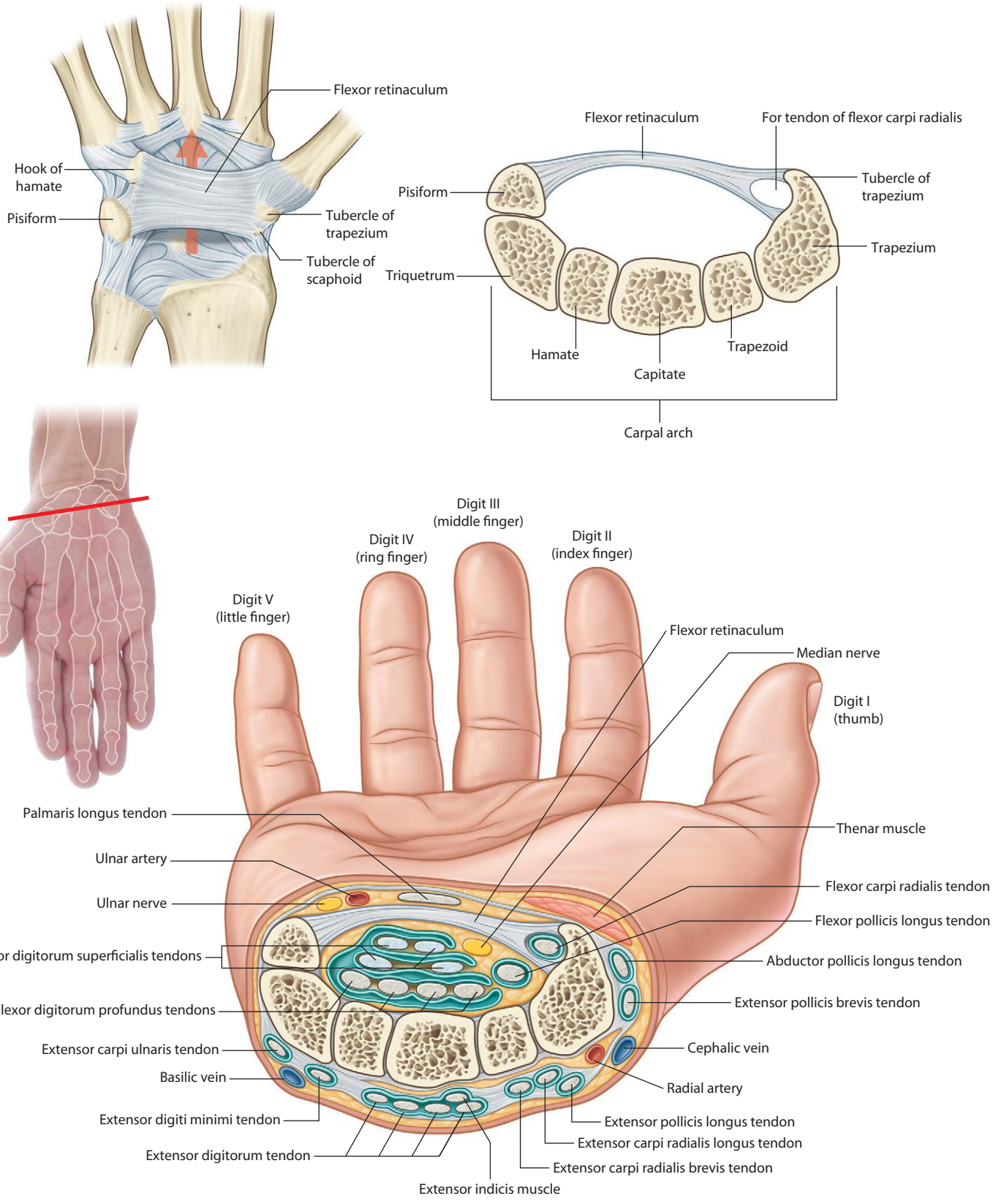

Carpal tunnel, structures and relations

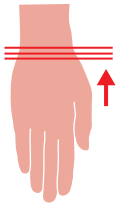

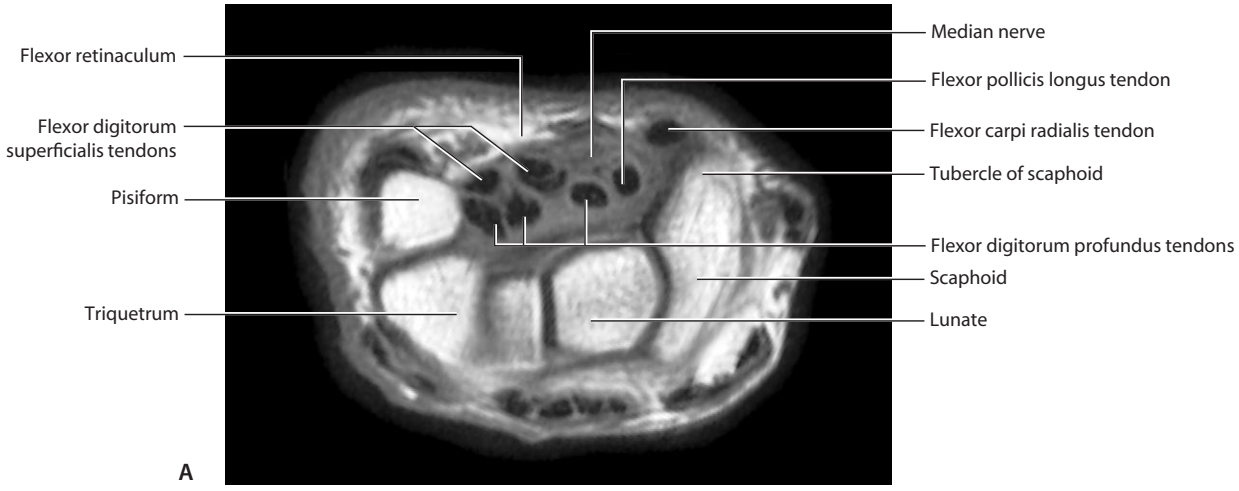

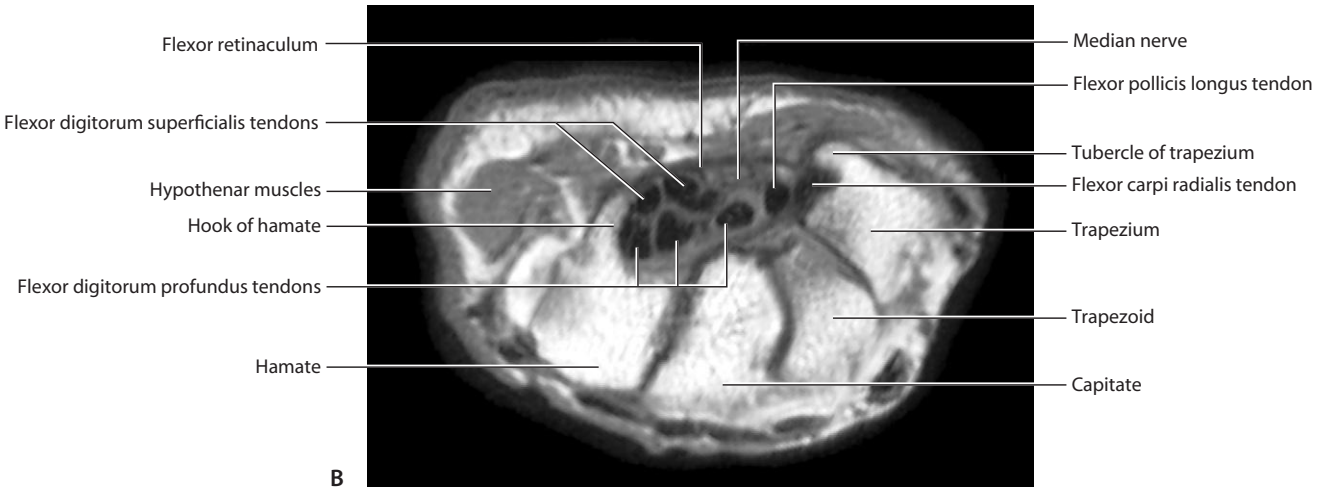

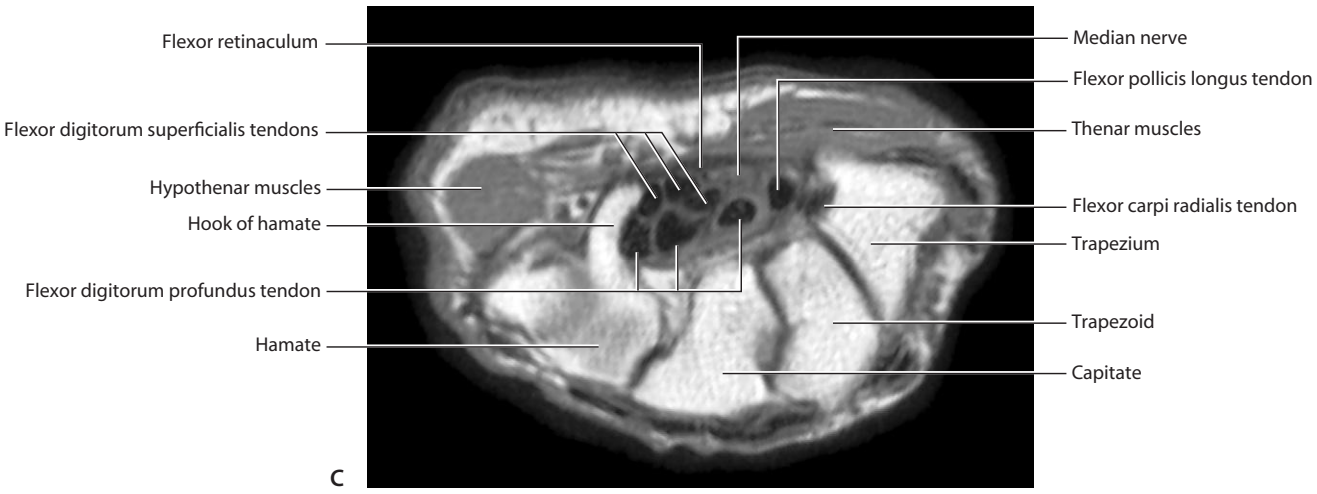

Transverse/axial sections through the carpal tunnel.
A. Proximal end of carpal tunnel.
B. Middle portion of carpal tunnel.
C. Distal portion of carpal tunnel.
T1-weighted MR images in axial plane

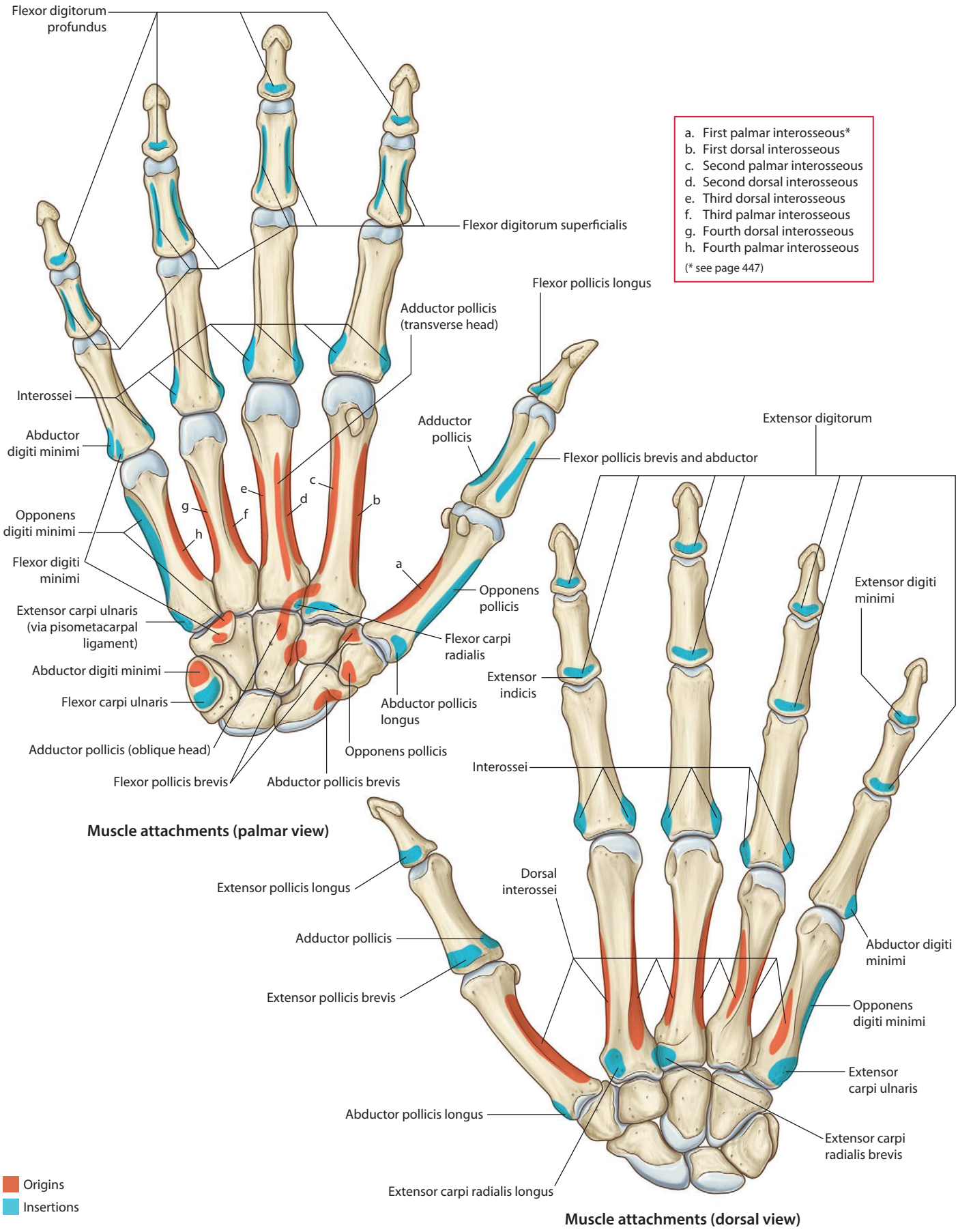
Flexor digitorum profundus
Flexor digitorum superficialis
Flexor pollicis longus
Adductor pollicis (transverse head)
Interossei
Abductor digiti minimi
Adductor pollicis
Flexor pollicis brevis and abductor
Opponens digiti minimi
Flexor digiti minimi
Extensor carpi ulnaris (via pisometacarpal ligament)
Abductor digiti minimi
Flexor carpi ulnaris
Adductor pollicis (oblique head)
Flexor pollicis brevis
Abductor pollicis brevis
Opponens pollicis
Abductor pollicis longus
Flexor carpi radialis
Opponens pollicis
a
b
c
d
e
f
g
h
a. First palmar interosseous*
b. First dorsal interosseous
c. Second palmar interosseous
d. Second dorsal interosseous
e. Third dorsal interosseous
f. Third palmar interosseous
g. Fourth dorsal interosseous
h. Fourth palmar interosseous
(* see page 447)
Muscle attachments (palmar view)
Extensor digitorum
Extensor digiti minimi
Extensor indicis
Interossei
Dorsal interossei
Extensor pollicis longus
Adductor pollicis
Extensor pollicis brevis
Abductor digiti minimi
Opponens digiti minimi
Extensor carpi ulnaris
Abductor pollicis longus
Extensor carpi radialis brevis
Extensor carpi radialis longus
Muscle attachments (dorsal view)
Origins
Insertions

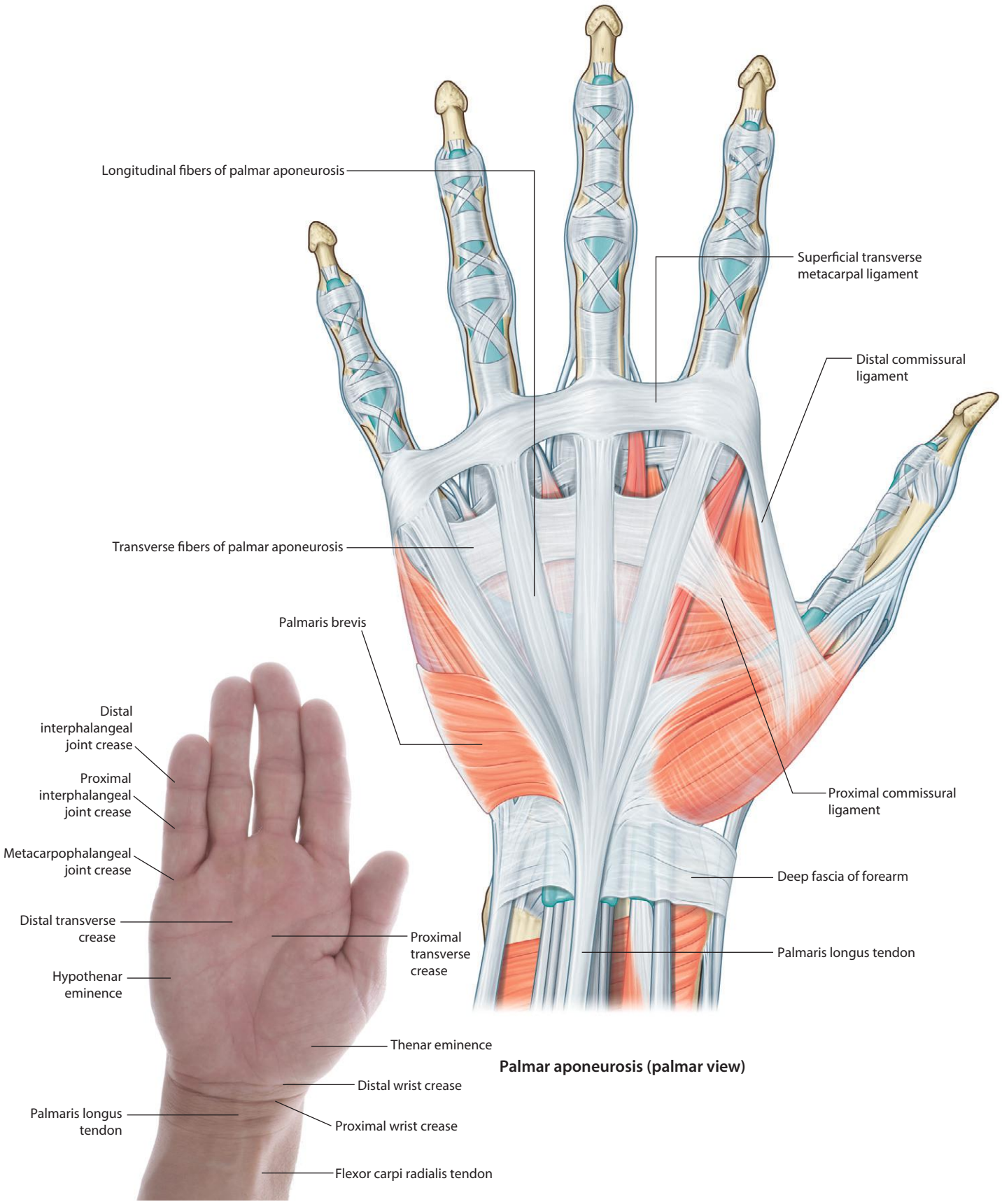

Palmar aponeurosis (palmar view)

Surface anatomy (palmar view)

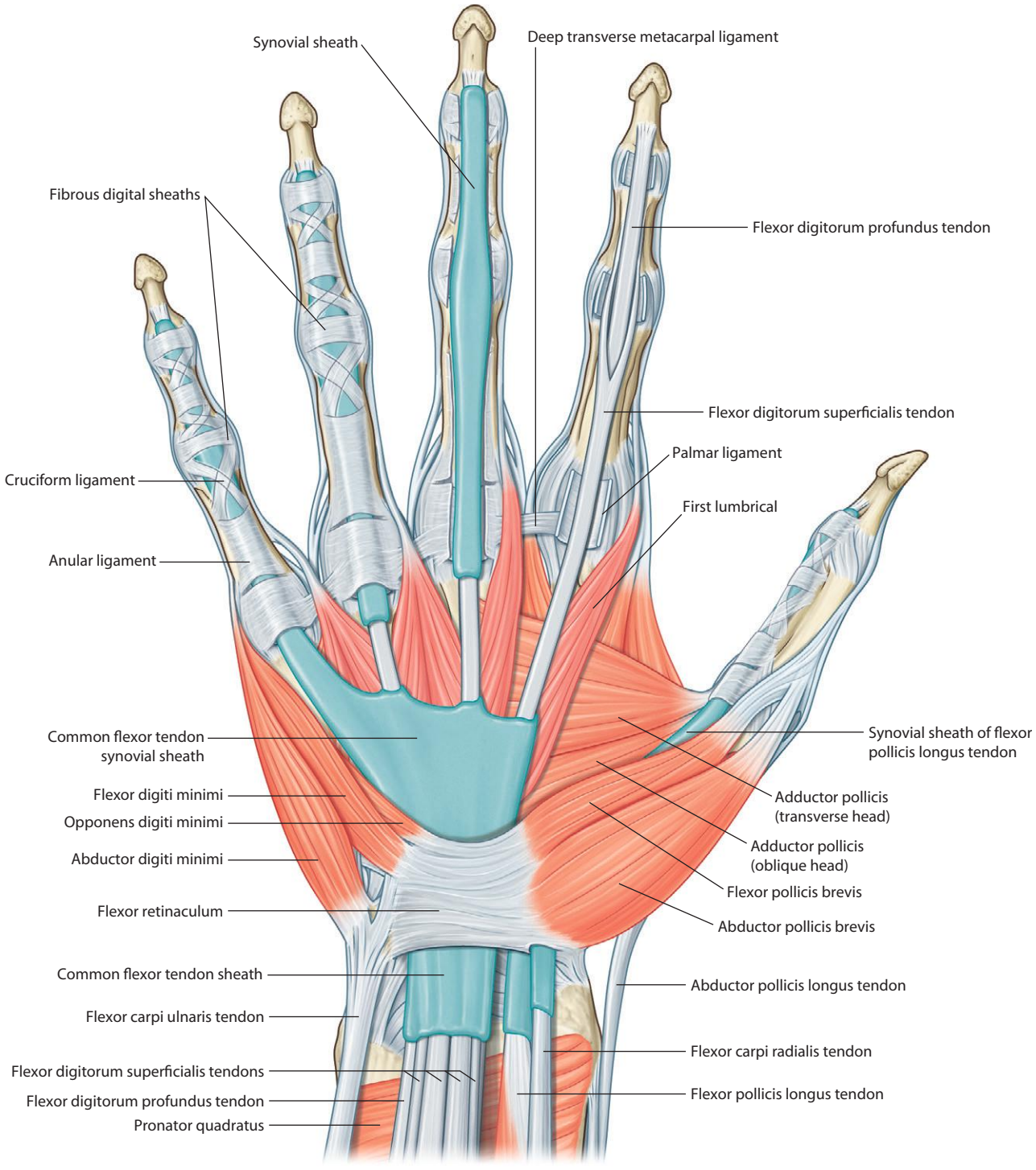

Superficial muscles of the hand (palmar view)

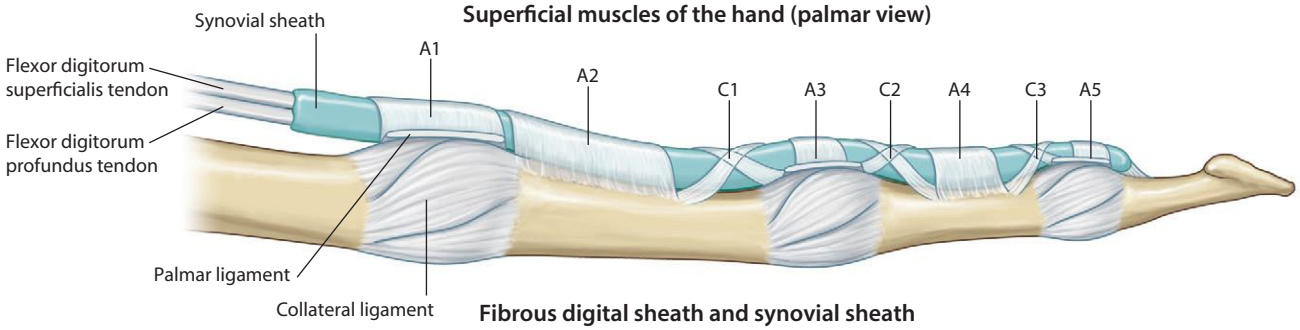

Fibrous digital sheath and synovial sheath
Anular ligaments (A), cruciform ligaments (C)

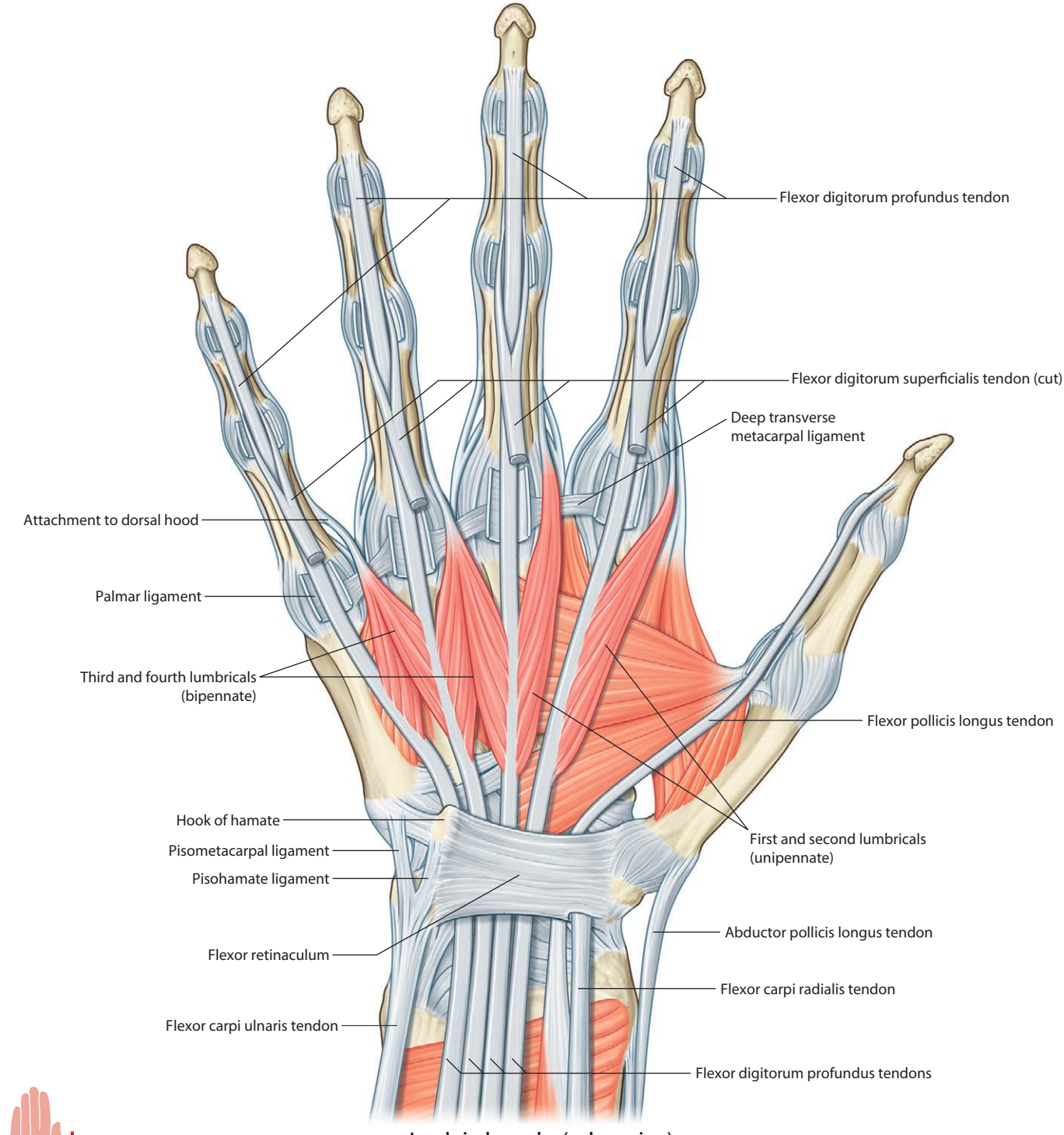

Lumbrical muscles (palmar view)

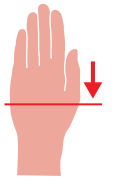

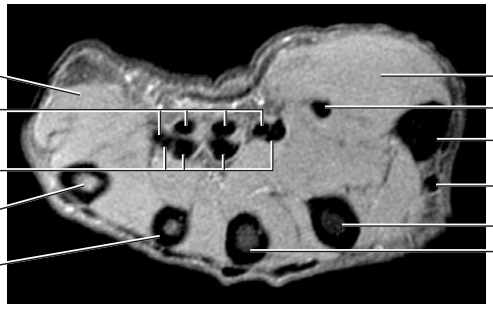

Imaging of the proximal portion of the hand.
T1-weighted MR image in axial plane

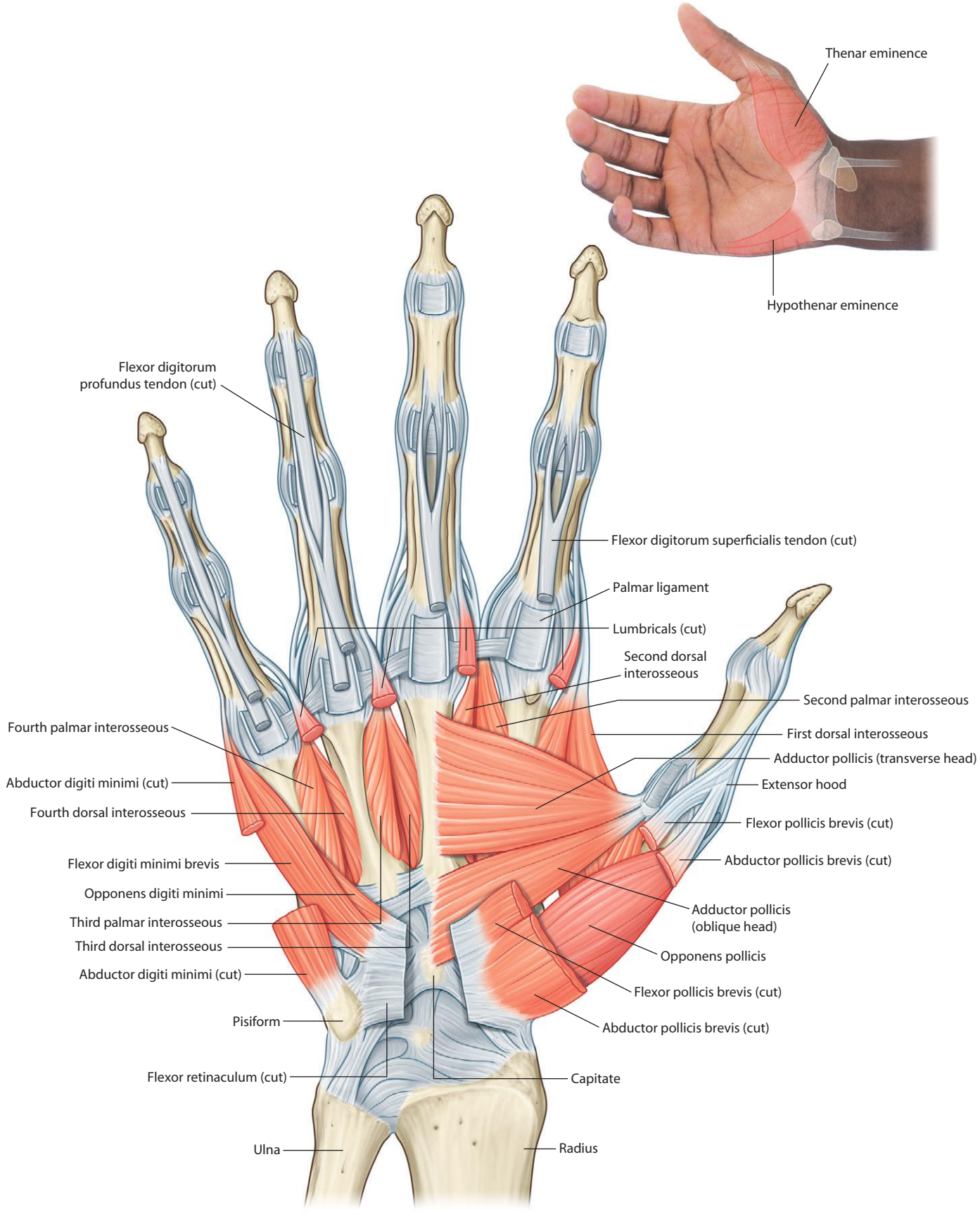

Deep muscles of the hand (palmar view)

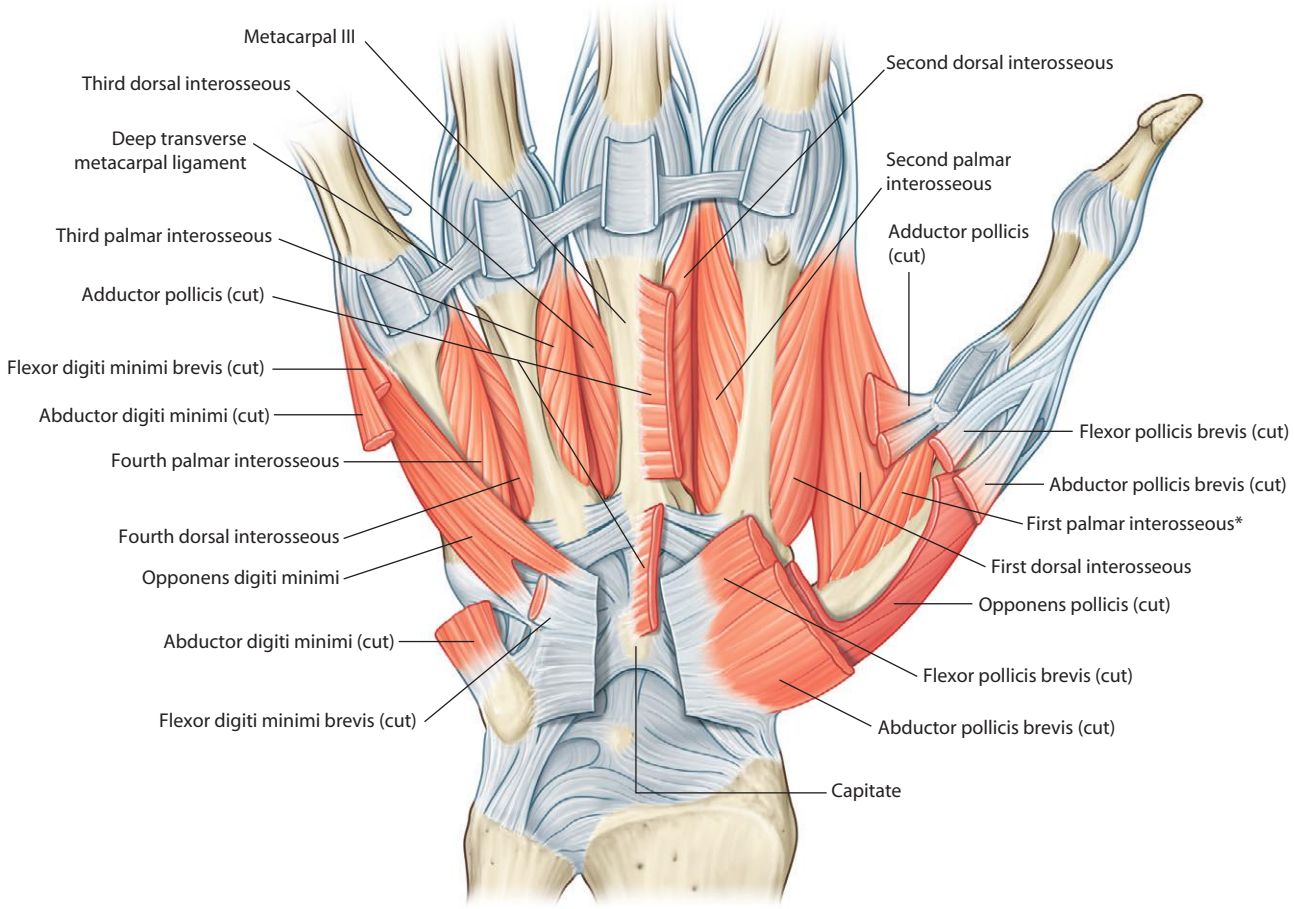

Deep muscles of the hand (palmar view)

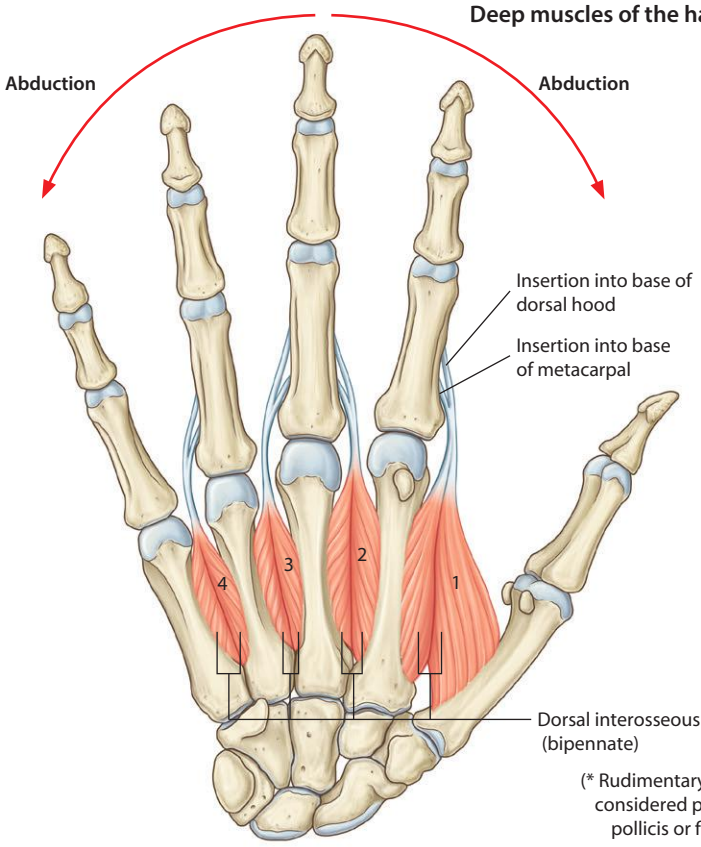

Dorsal interossei (palmar view)

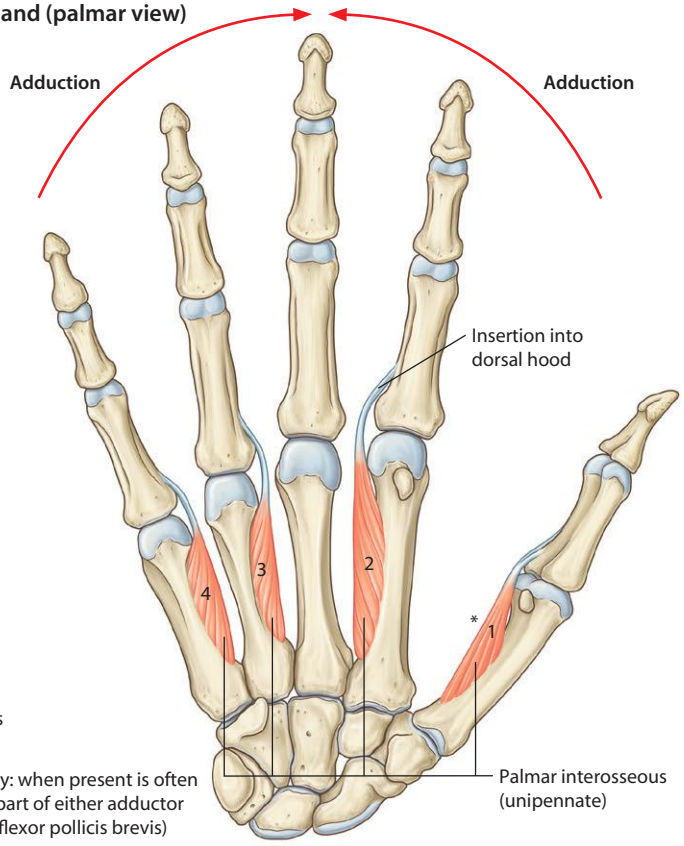

(* Rudimentary: when present is often considered part of either adductor pollicis or flexor pollicis brevis)

Palmar interossei (palmar view)

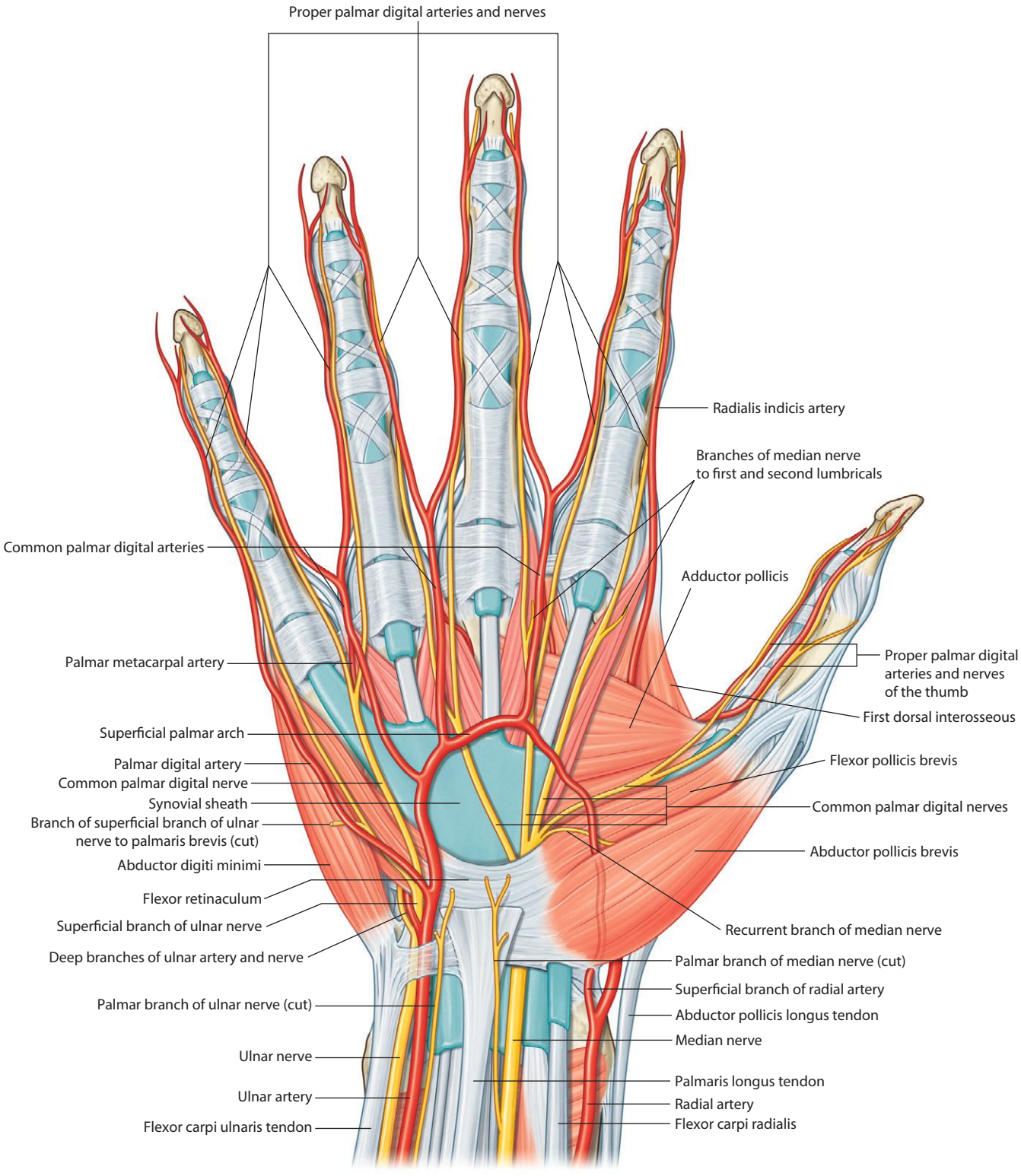

Superficial arteries and nerves of the hand (palmar view)

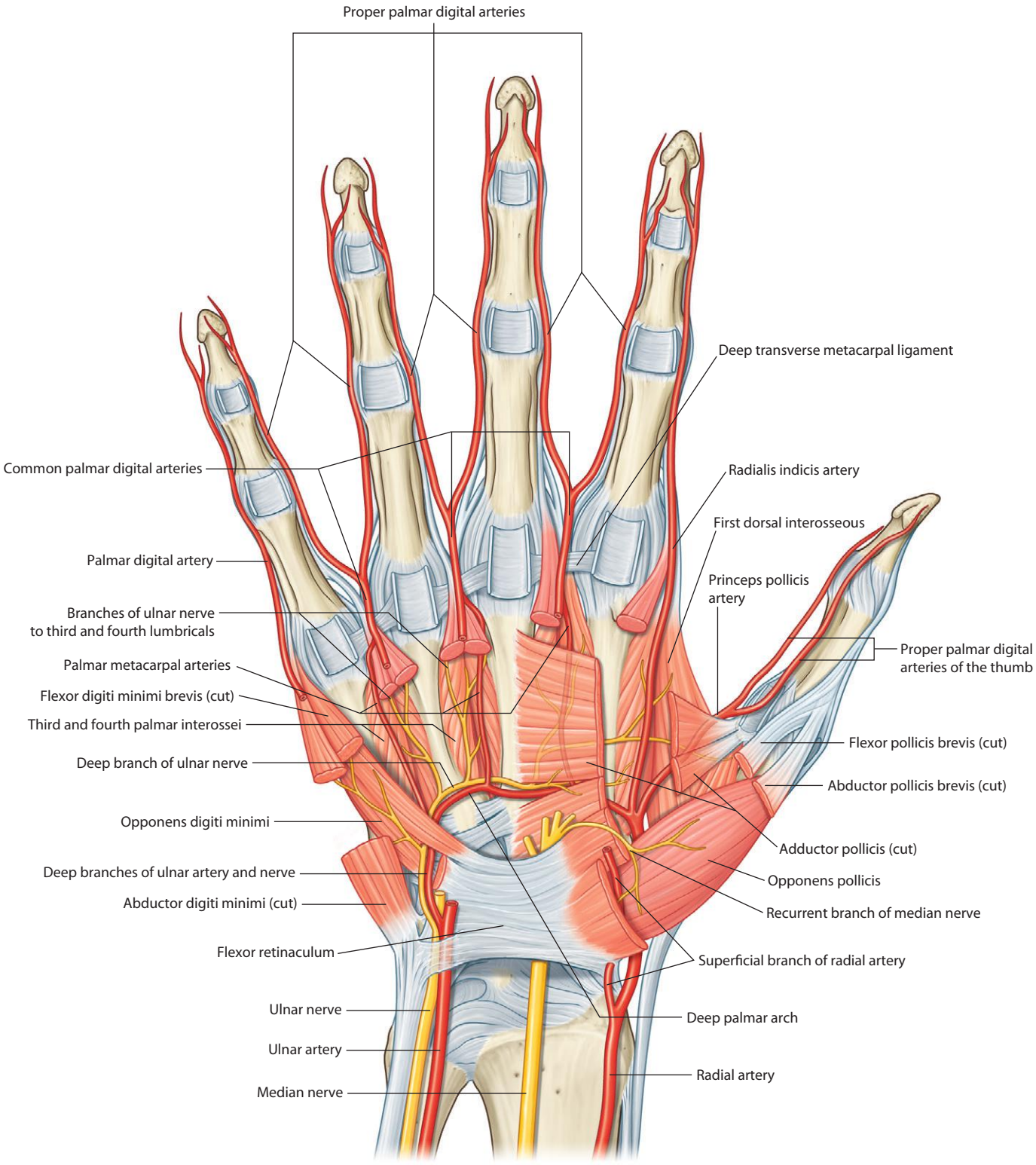

Deep arteries and nerves of the hand (palmar view)

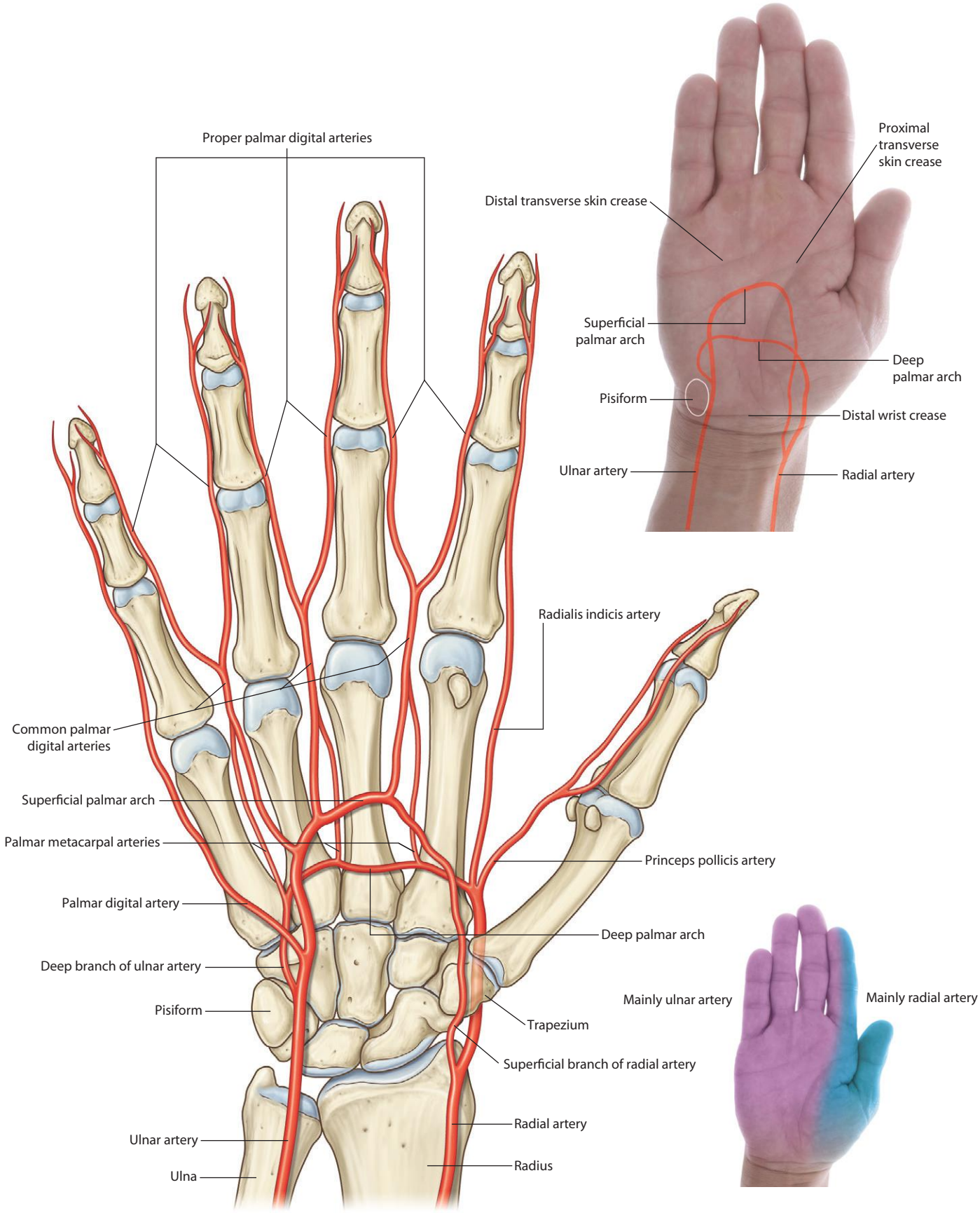

Arteries of the hand (palmar view)

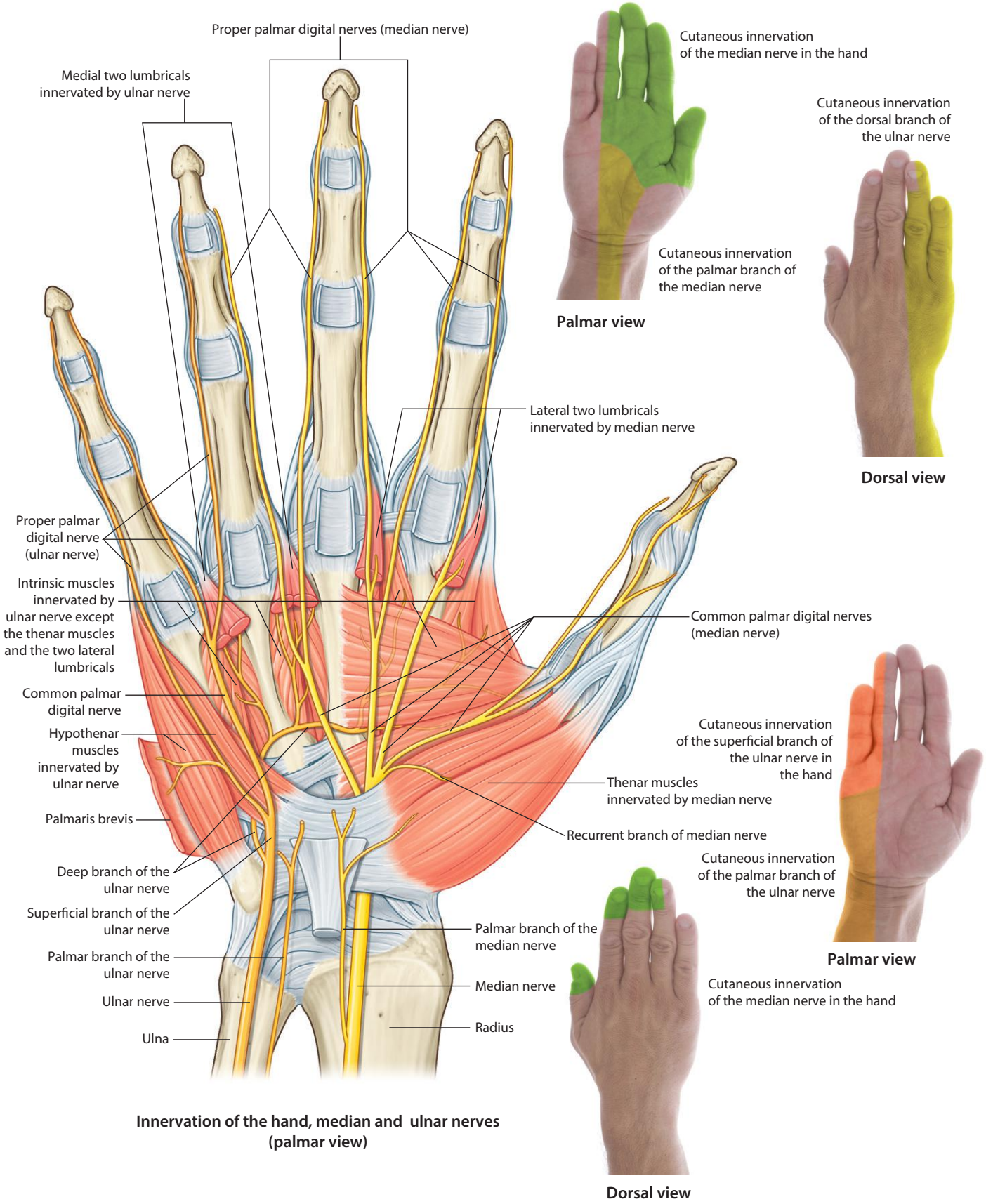

Innervation of the hand, median and ulnar nerves (palmar view)

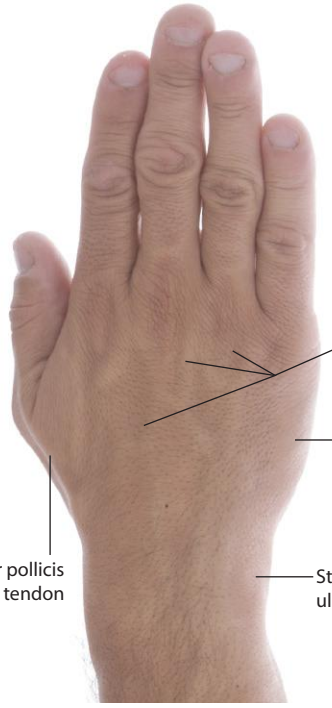

Surface anatomy (dorsal view)

Tendons of the extensor muscles of the forearm crossing the wrist joint and passing onto the dorsal surface of the hand.
T1-weighted MR image in coronal plane

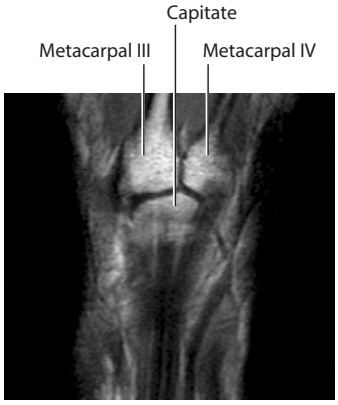

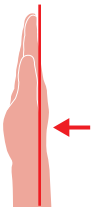

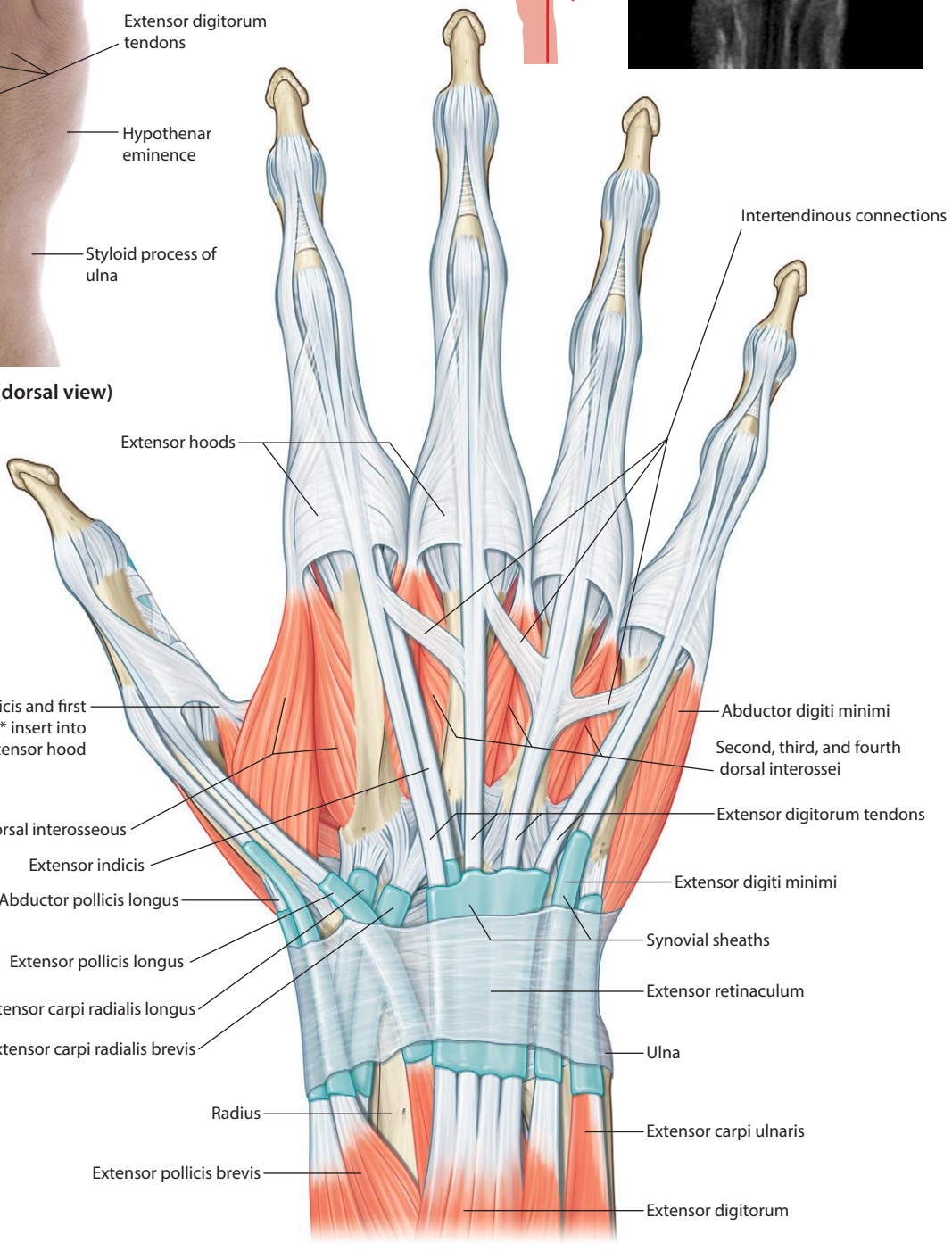

Superficial structures of the hand (dorsal view)
(* see page 447)

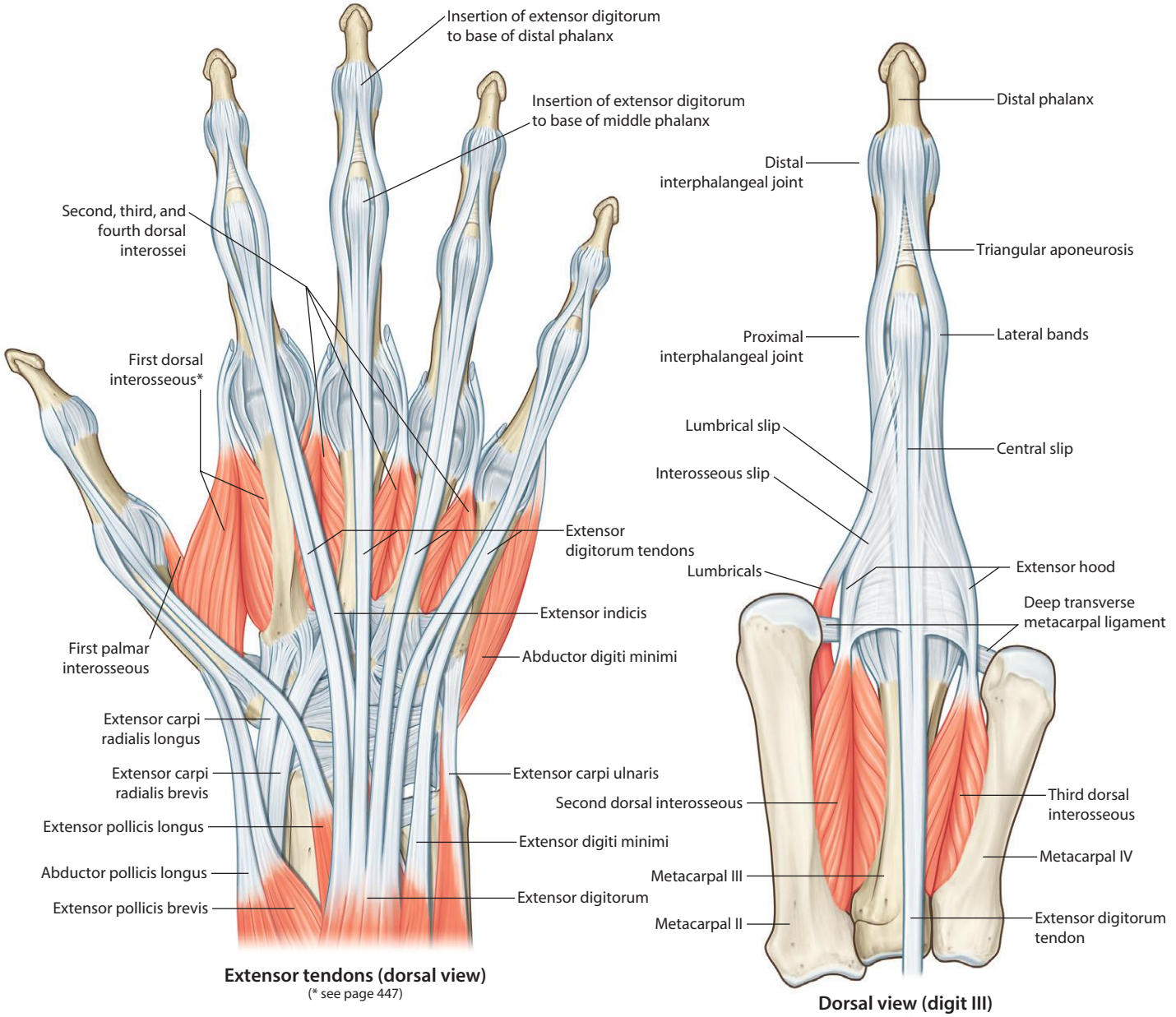

Extensor tendons (dorsal view)
(* see page 447)

Dorsal view (digit III)

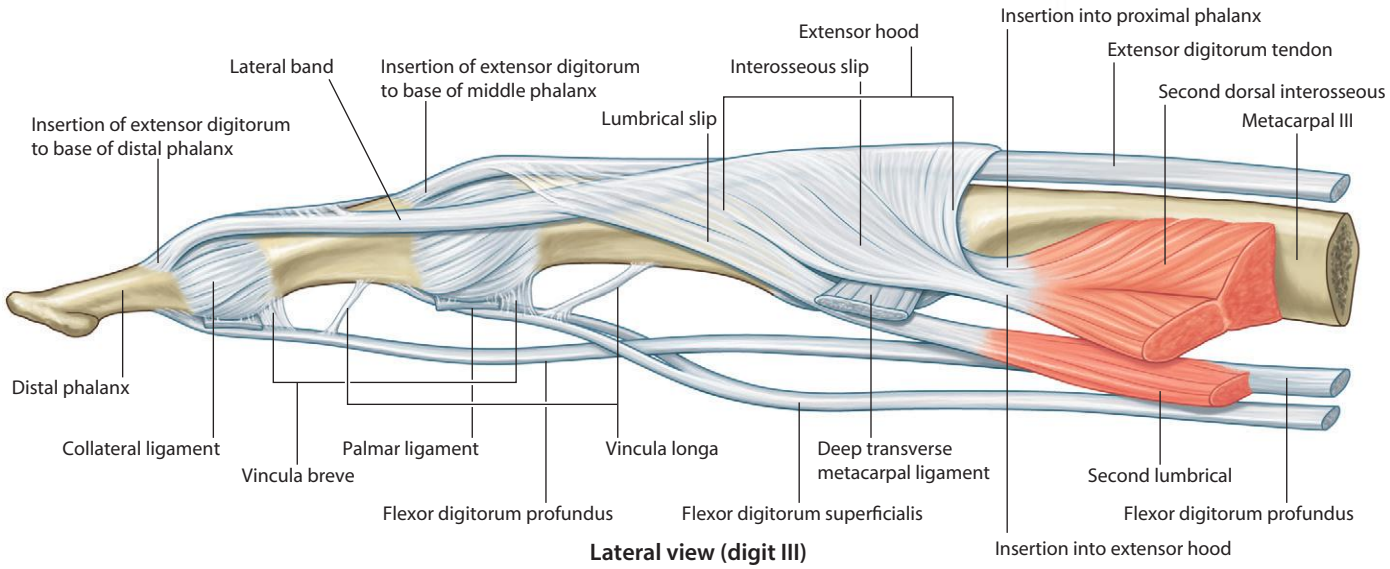

Lateral view (digit III)

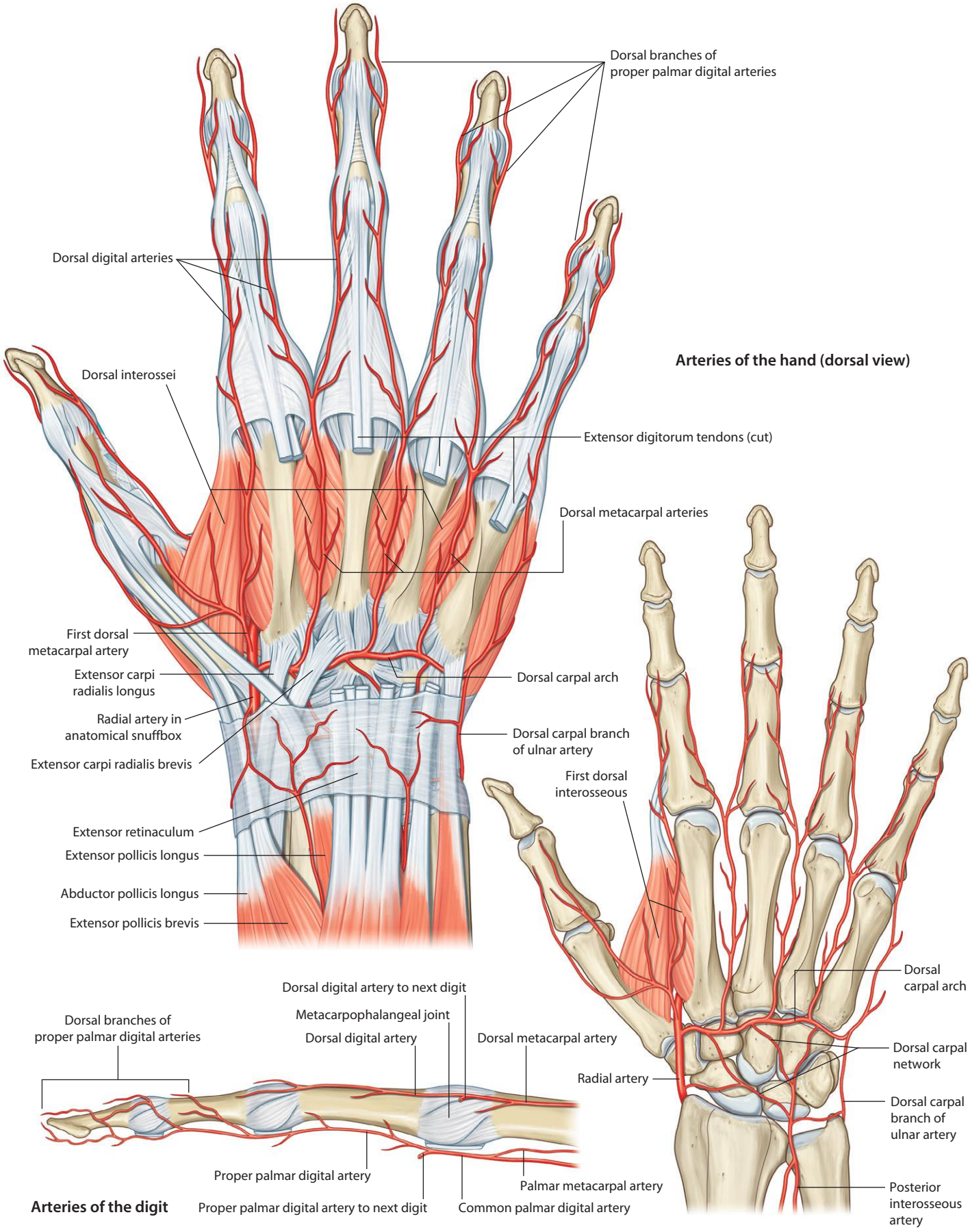

Arteries of the hand (dorsal view)

Arteries of the digit

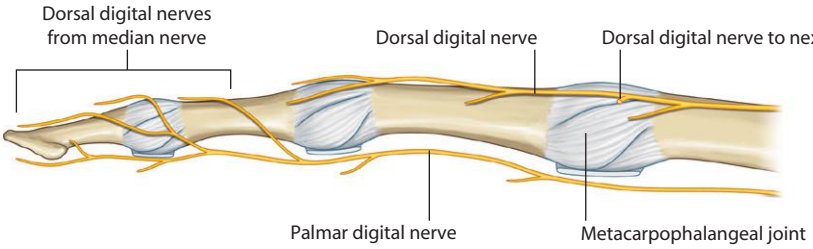

Nerves of the digit

Cutaneous innervation of the superficial branch of the radial nerve

Dorsal view

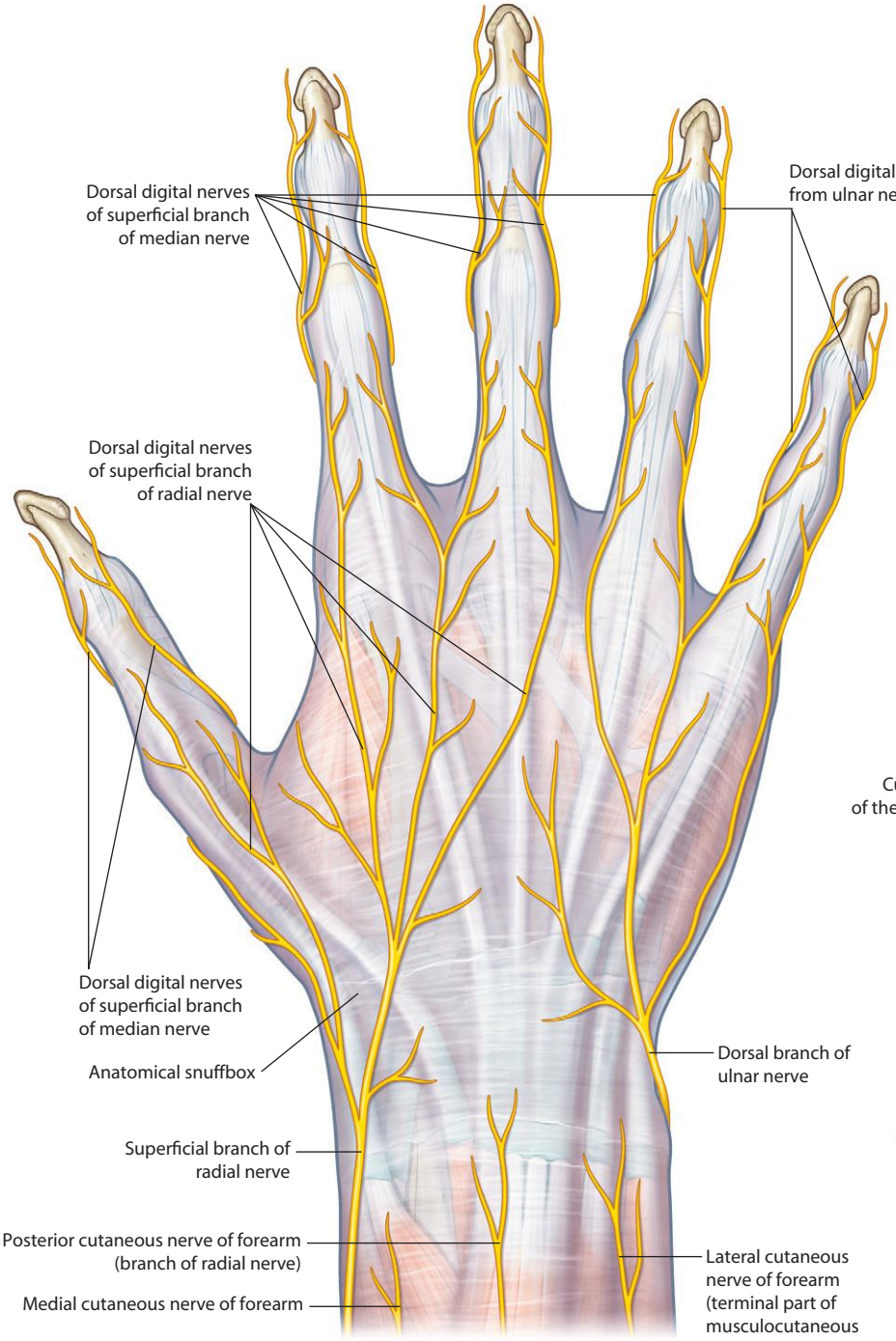

Nerves of the hand (dorsal view)

Cutaneous innervation of the superficial branch of the radial nerve

Palmar view

Cutaneous innervation of the superficial branch of the median nerve

Dorsal view

Cutaneous innervation of the dorsal branch of the ulnar nerve

Dorsal view

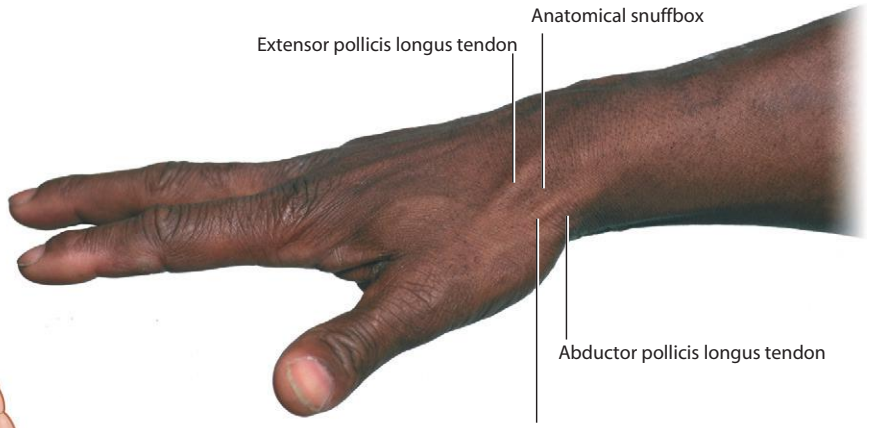

Surface anatomy

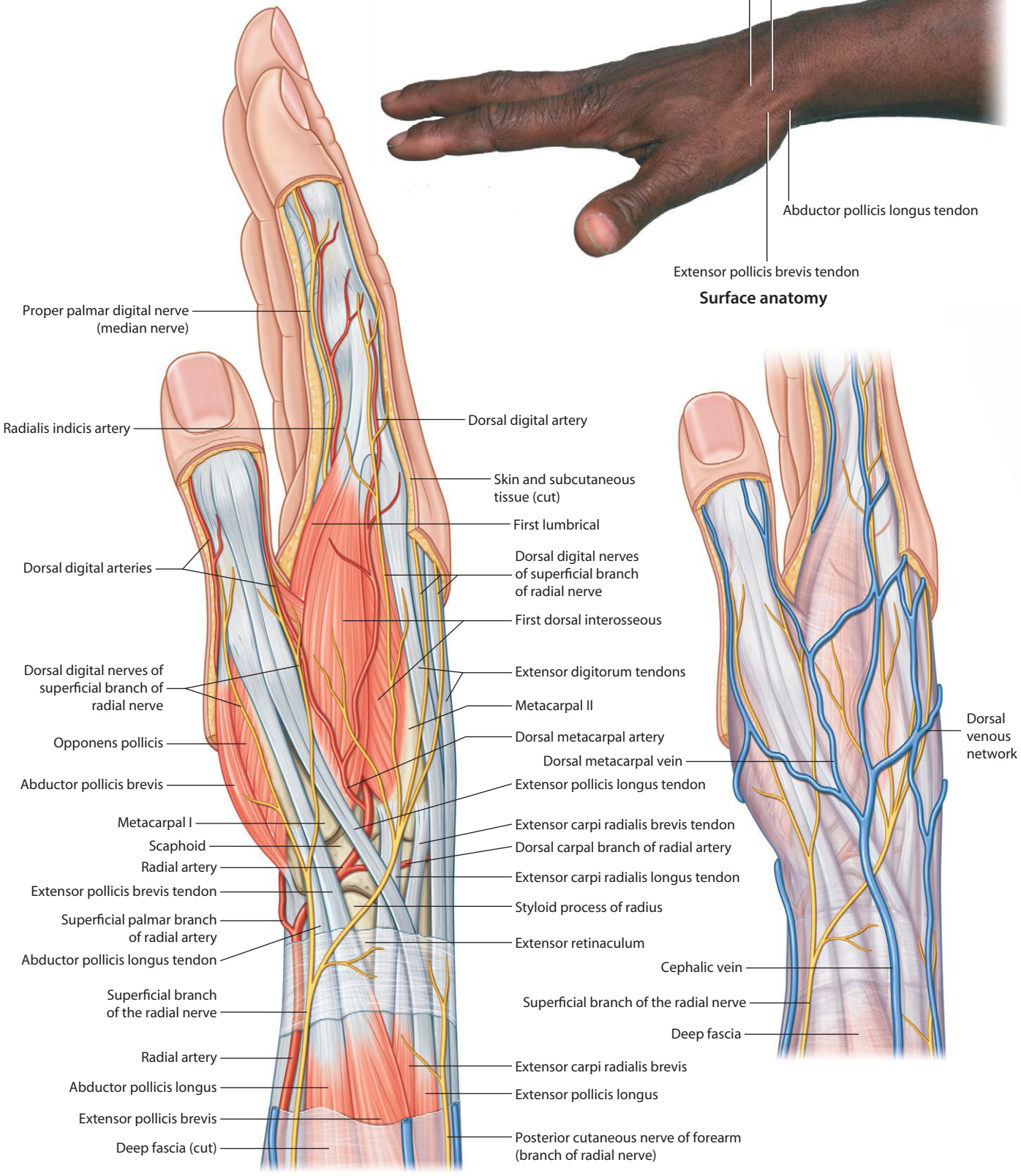

Anatomical snuffbox (lateral view)

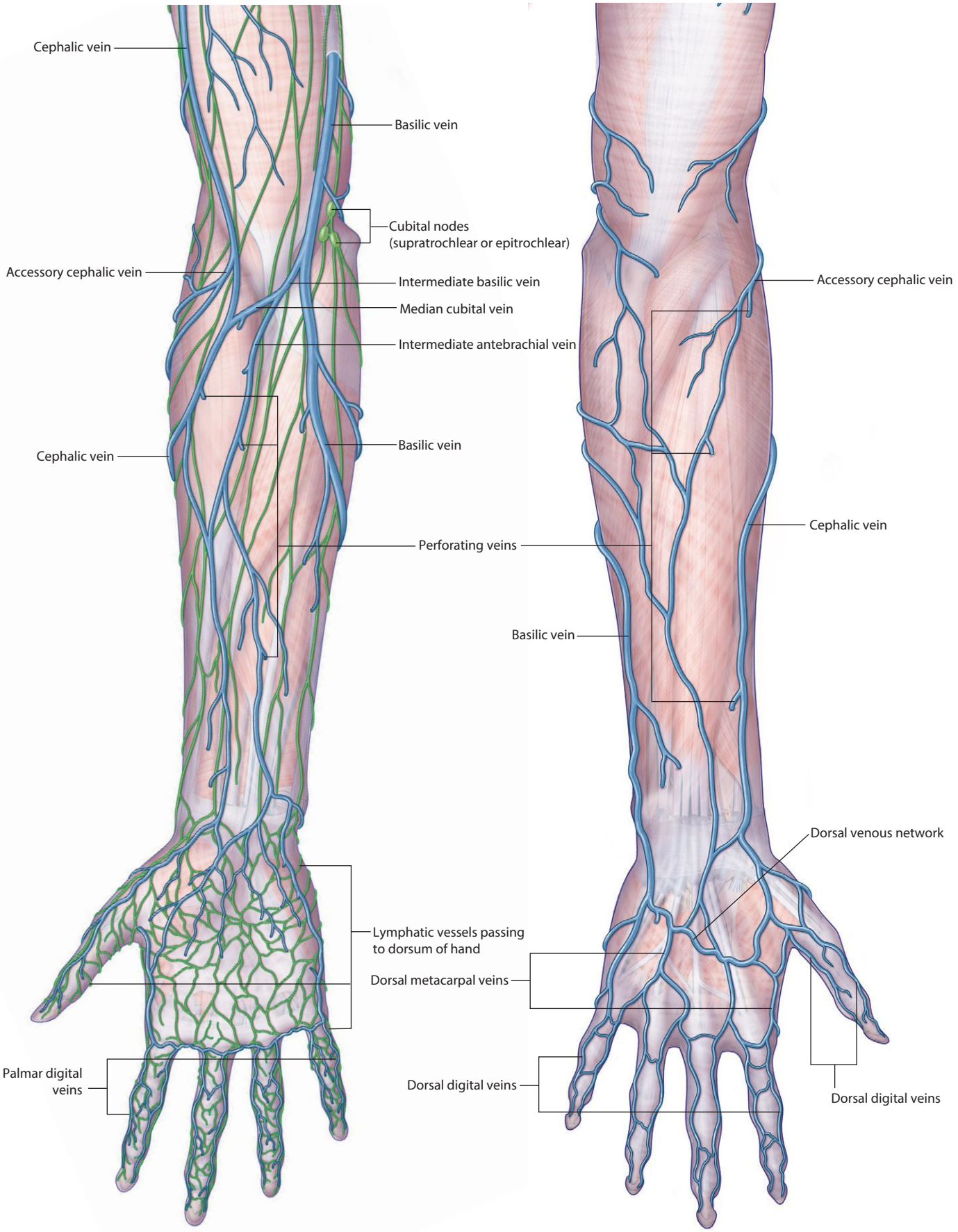

Superficial veins and lymphatics of the forearm (palmar view)

Superficial veins of the forearm (dorsal view)

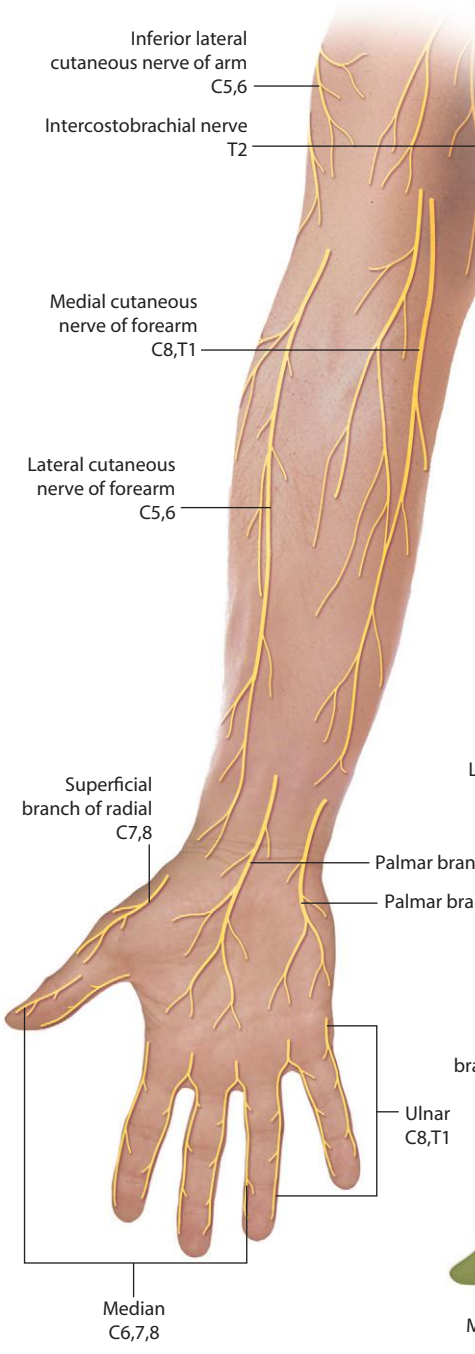

Cutaneous nerves of the forearm

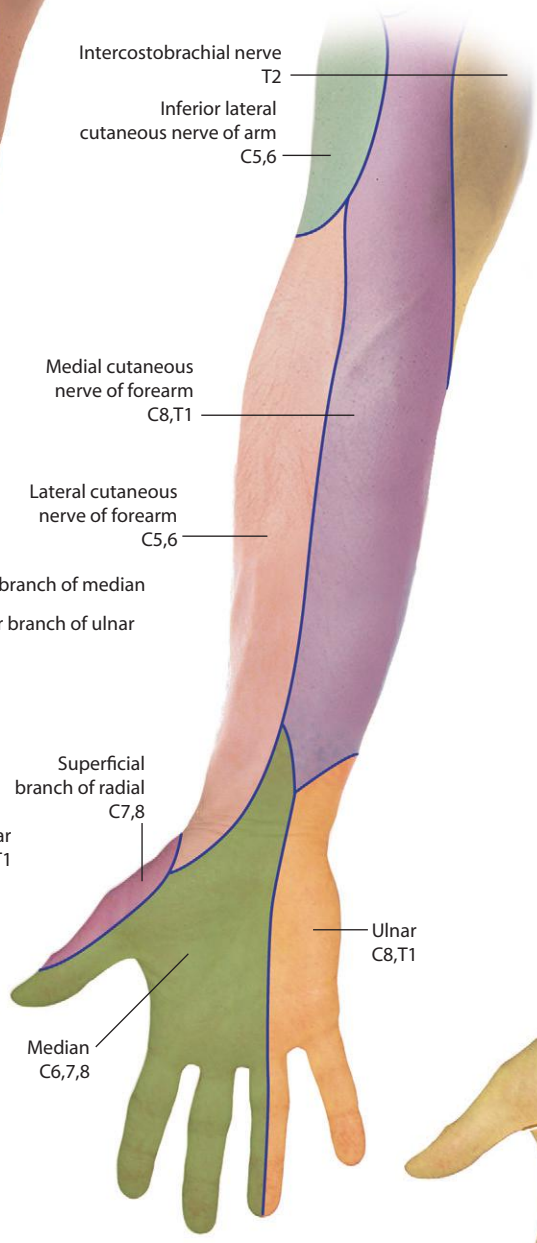

Areas of distribution of the cutaneous nerves of the forearm

Dermatomes of the forearm

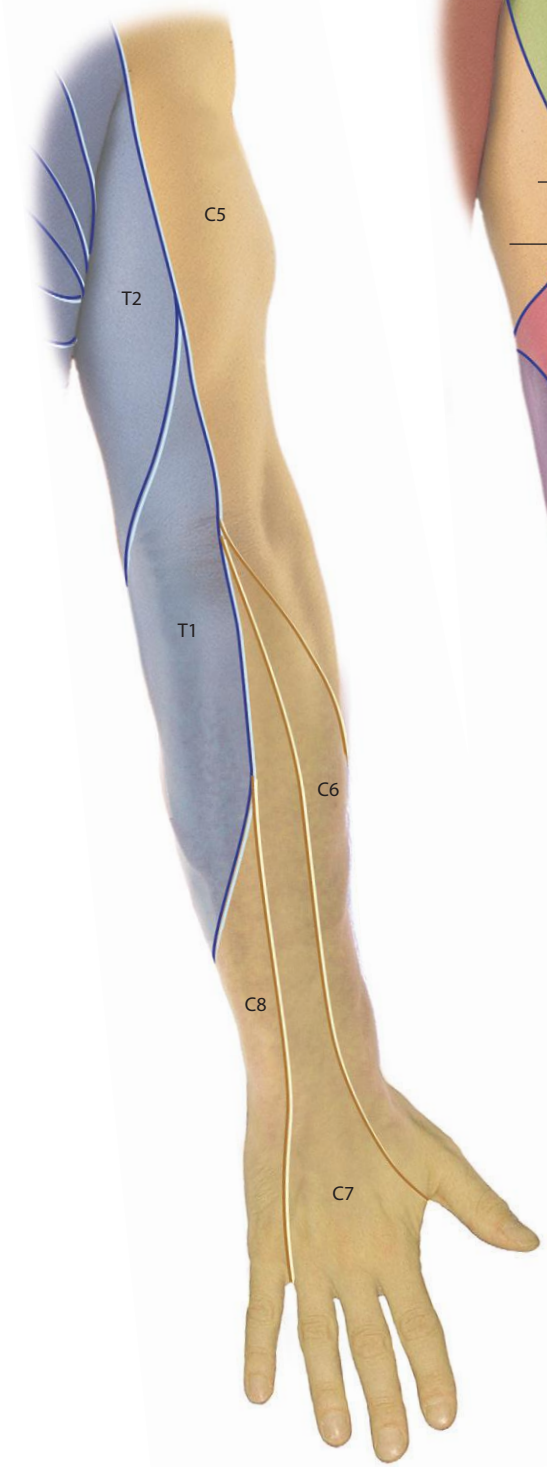

Dermatomes of the upper limb

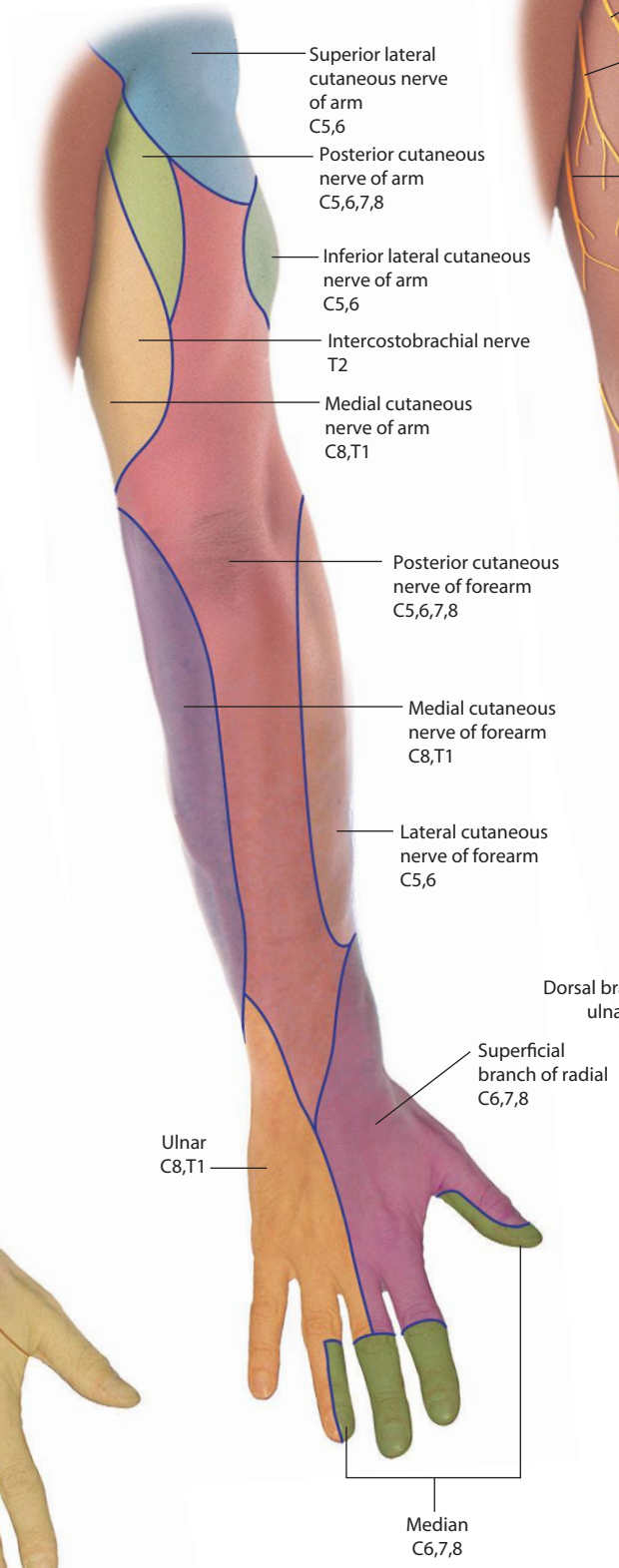

Areas of distribution of the cutaneous nerves of the upper limb

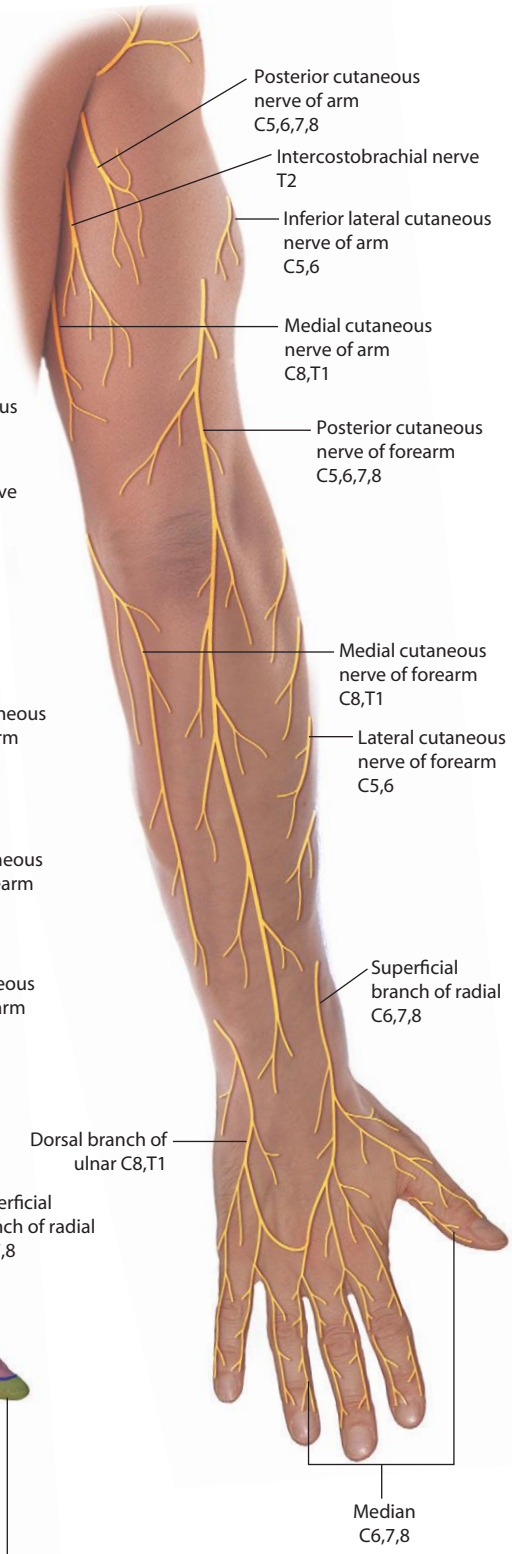

Cutaneous nerves of the upper limb

Branches of the brachial plexus

Branch		Origin	Spinal segments	Function: motor	Function: sensory
Dorsal scapular	1	C5 root	C5	Rhomboid major, rhomboid minor	
Long thoracic	2	C5 to C7 roots	C5 to C7	Serratus anterior	
Suprascapular	3	Superior trunk	C5, C6	Supraspinatus, infraspinatus	
Nerve to subclavius	4	Superior trunk	C5, C6	Subclavius	
Lateral pectoral	5	Lateral cord	C5 to C7	Pectoralis major	
Musculocutaneous	6	Lateral cord	C5 to C7	All muscles in the anterior compartment of the arm	Skin on lateral side of forearm
Medial pectoral	7	Medial cord	C8, T1 (also receives contributions from spinal segments C5 to C7 through a communication with the lateral pectoral nerve)	Pectoralis major, pectoralis minor	
Medial cutaneous of arm	8	Medial cord	Spinal segments: C8, T1		Skin on medial side of distal one third of arm
Medial cutaneous of forearm	9	Medial cord	C8, T1		Skin on medial side of forearm
Median	10	Medial and lateral cords	(C5), C6 to T1	All muscles in the anterior compartment of the forearm (except flexor carpi ulnaris and medial half of flexor digitorum profundus), three thenar muscles of the thumb, and two lateral lumbrical muscles	Skin over the palmar surface of the lateral three and one half digits and over the lateral side of the palm and middle of the wrist
Ulnar	11	Medial cord	(C7), C8, T1	All intrinsic muscles of the hand (except three thenar muscles and two lateral lumbricals); also flexor carpi ulnaris and the medial half of flexor digitorum profundus in the forearm	Skin over the palmar surface of the medial one and one half digits and associated palm and wrist, and skin over the dorsal surface of the medial one and one half digits
Superior subscapular	12	Posterior cord	C5, C6	Subscapularis	
Thoracodorsal	13	Posterior cord	C6 to C8	Latissimus dorsi	

Branches of the brachial plexus

Branch		Origin	Spinal segments	Function: motor	Function: sensory
Inferior subscapular	14	Posterior cord	C5, C6	Subscapularis, teres major	
Axillary	15	Posterior cord	C5, C6	Deltoid, teres minor	Skin over upper lateral part of arm
Radial	16	Posterior cord	C5 to C8, (T1)	All muscles in the posterior compartments of arm and forearm	Skin on the posterior aspects of the arm and forearm, the lower lateral surface of the arm, and the dorsal lateral surface of the hand

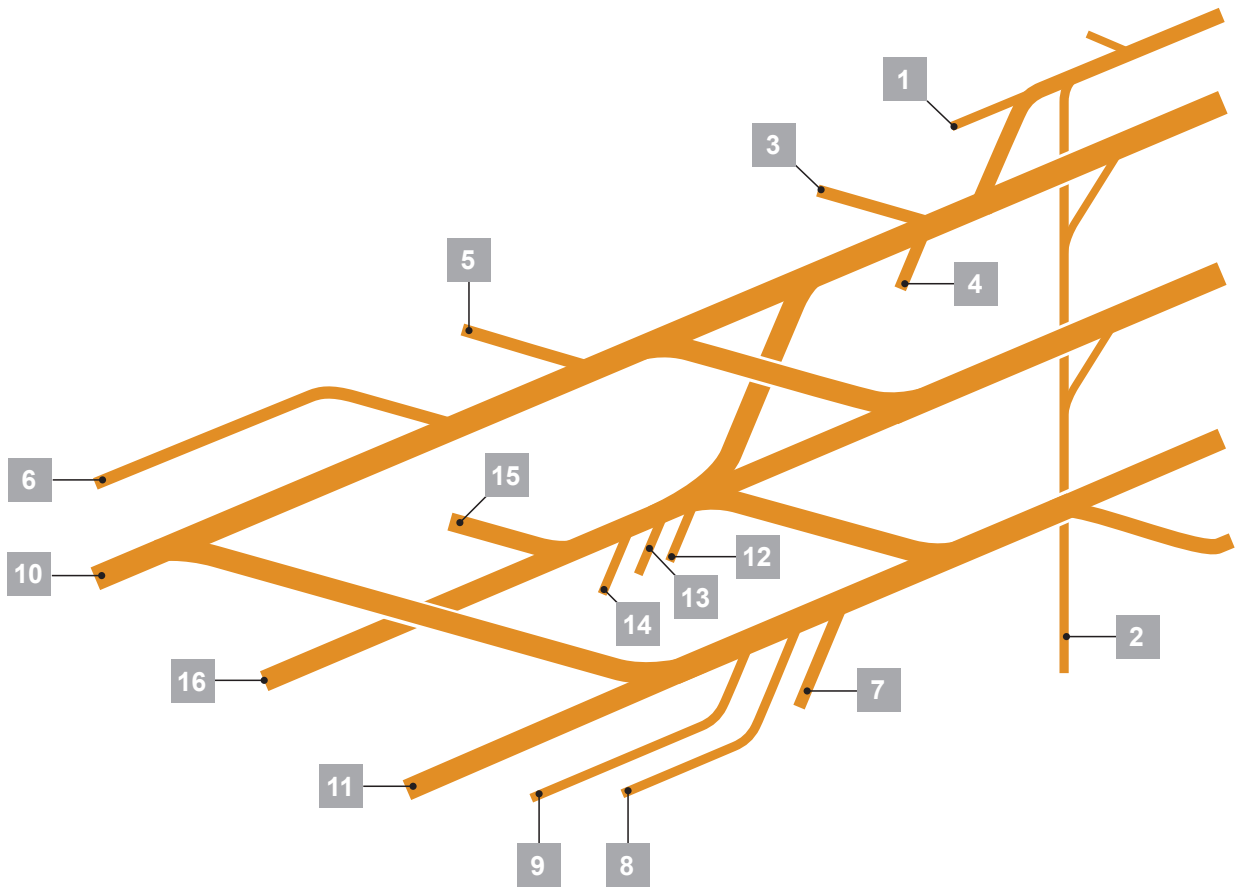

Muscles of the shoulder

(muscles of the shoulder spinal segments indicated in bold are the major segments innervating the muscle)

Muscle		Origin	Insertion	Innervation	Function
Trapezius	1	Superior nuchal line, external occipital protuberance, medial margin of the ligamentum nuchae, spinous processes of CVII to TXII and the related supraspinous ligaments	Superior edge of the crest of the spine of the scapula, acromion, posterior border of lateral one third of clavicle	Motor spinal part of accessory nerve [XI]. Sensory (proprioception) anterior rami of C3 and C4	Powerful elevator of the scapula; rotates the scapula during abduction of humerus above horizontal; middle fibers retract scapula; lower fibers depress scapula
Deltoid	2	Inferior edge of the crest of the spine of the scapula, lateral margin of the acromion, anterior border of lateral one third of clavicle	Deltoid tuberosity of humerus	Axillary nerve [**C5**, C6]	Major abductor of arm (abducts arm beyond initial 15° done by supraspinatus); clavicular fibers assist in flexing the arm; posterior fibers assist in extending the arm
Levator scapulae	3	Transverse processes of CI and CII vertebrae and posterior tubercles of transverse processes of CIII and CIV vertebrae	Posterior surface of medial border of scapula from superior angle to root of spine of the scapula	Branches directly from anterior rami of **C3** and **C4** spinal nerves and by branches [**C5**] from the dorsal scapular nerve	Elevates the scapula
Rhomboid minor	4	Lower end of ligamentum nuchae and spinous processes of CVII and TI vertebrae	Posterior surface of medial border of scapula at the root of the spine of the scapula	Dorsal scapular nerve [C4, C5]	Elevates and retracts the scapula
Rhomboid major	5	Spinous processes of TII–TV vertebrae and intervening supraspinous ligaments	Posterior surface of medial border of scapula from the root of the spine of the scapula to the inferior angle	Dorsal scapular nerve [**C4**, **C5**]	Elevates and retracts the scapula

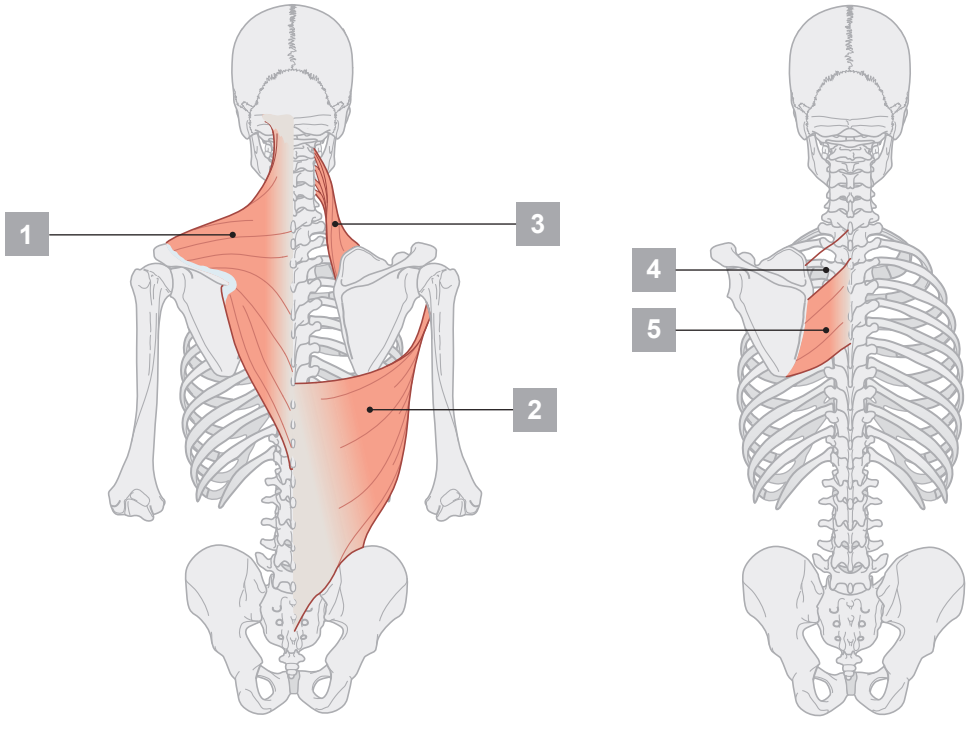

Muscles of the posterior scapular region

(spinal segments in bold are the major segments innervating the muscle)

Muscle		Origin	Insertion	Innervation	Function
Supraspinatus	1	Medial two thirds of the supraspinous fossa of the scapula and the deep fascia that covers the muscle	Most superior facet on the greater tubercle of the humerus	Suprascapular nerve [**C5**, C6]	Rotator cuff muscle; initiation of abduction of arm to 15° at glenohumeral joint
Infraspinatus	2	Medial two thirds of the infraspinous fossa of the scapula and the deep fascia that covers the muscle	Middle facet on posterior surface of the greater tubercle of the humerus	Suprascapular nerve [**C5**, C6]	Rotator cuff muscle; lateral rotation of arm at the glenohumeral joint
Teres minor	3	Upper two thirds of a flattened strip of bone on the posterior surface of the scapula immediately adjacent to the lateral border of the scapula	Inferior facet on the posterior surface of the greater tubercle of the humerus	Axillary nerve [**C5**, C6]	Rotator cuff muscle; lateral rotation of arm at the glenohumeral joint
Teres major	4	Elongate oval area on the posterior surface of the inferior angle of the scapula	Medial lip of the intertubercular sulcus on the anterior surface of the humerus	Inferior subscapular nerve [**C5**, **C6**, **C7**]	Medial rotation and extension of the arm at the glenohumeral joint
Long head of triceps brachii	5	Infraglenoid tubercle on scapula	Common tendon of insertion with medial and lateral heads on the olecranon process of ulna	Radial nerve [C6, **C7**, C8]	Extension of the forearm at the elbow joint; accessory adductor and extensor of the arm at the glenohumeral joint

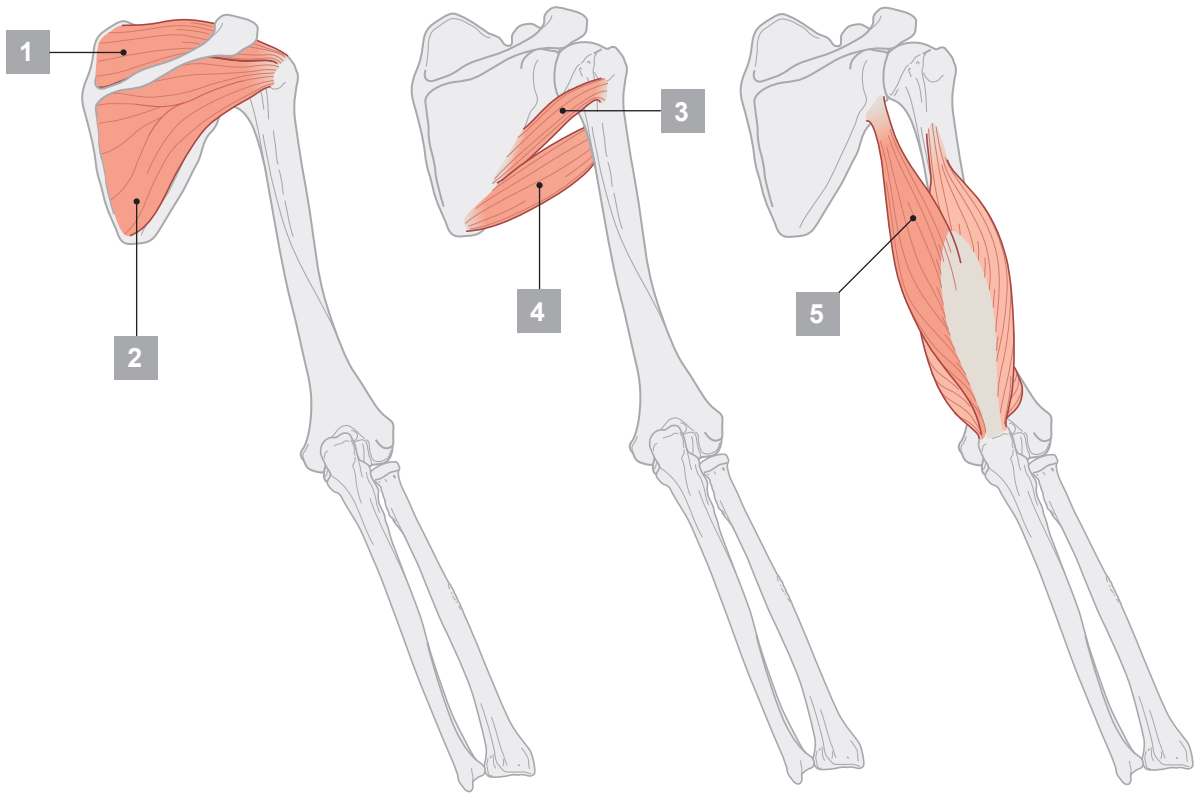

Muscles of the anterior wall of the axilla

(spinal segments in bold are the major segments innervating the muscle)

Muscle		Origin	Insertion	Innervation	Function
Pectoralis major	1	Clavicular head—anterior surface of medial half of clavicle; sternocostal head—anterior surface of sternum; first seven costal cartilages; sternal end of sixth rib; aponeurosis of external oblique	Lateral lip of intertubercular sulcus of humerus	Medial and lateral pectoral nerves; clavicular head [**C5**, C6]; sternocostal head [C6, C7, C8, T1]	Flexion, adduction, and medial rotation of arm at glenohumeral joint; clavicular head—flexion of extended arm; sternocostal head—extension of flexed arm
Subclavius	2	First rib at junction between rib and costal cartilage	Groove on inferior surface of middle one third of clavicle	Nerve to subclavius [**C5**, **C6**]	Pulls tip of shoulder down; pulls clavicle medially to stabilize sternoclavicular joint
Pectoralis minor	3	Anterior surfaces and superior borders of ribs III to V; and from deep fascia overlying the related intercostal spaces	Coracoid process of scapula (medial border and upper surface)	Medial pectoral nerve [C5, C6, **C7**, **C8**, T1]	Pulls tip of shoulder down; protracts scapula

Muscles of the medial wall of the axilla

Serratus anterior	4	Lateral surfaces of upper 8–9 ribs and deep fascia overlying the related intercostal spaces	Costal surface of medial border of scapula	Long thoracic nerve [**C5**, C6, C7]	Protraction and rotation of the scapula; keeps medial border and inferior angle of scapula opposed to thoracic wall

Muscles of the lateral and posterior wall of the axilla

(spinal segments enclosed in parentheses do not consistently innervate the muscle)

Subscapularis	5	Medial two thirds of subscapular fossa	Lesser tubercle of humerus	Upper and lower subscapular nerves [C5, **C6**, (C7)]	Rotator cuff muscle; medial rotation of the arm at the glenohumeral joint
Teres major	6	Elongate oval area on the posterior surface of the inferior angle of the scapula	Medial lip of the intertubercular sulcus on the anterior surface of the humerus	Lower subscapular nerve [**C5**, **C6**, **C7**]	Medial rotation and extension of the arm at the glenohumeral joint
Latissimus dorsi	7	Spinous processes of lower six thoracic vertebrae and related interspinous ligaments; via the thoracolumbar fascia to the spinous processes of the lumbar vertebrae, related interspinous ligaments, and iliac crest; lower 3–4 ribs	Floor of intertubercular sulcus	Thoracodorsal nerve [C6, **C7**, C8]	Adduction, medial rotation, and extension of the arm at the glenohumeral joint
Long head of triceps brachii	8	Infraglenoid tubercle on scapula	Common tendon of insertion with medial and lateral heads on the olecranon process of ulna	Radial nerve [C6, **C7**, C8]	Extension of the forearm at the elbow joint; accessory adductor and extensor of the arm at the glenohumeral joint

Muscles having parts that pass through the axilla

(spinal segments in bold are the major segments innervating the muscle)

Muscle		Origin	Insertion	Innervation	Function
Biceps brachii	1	Long head—supraglenoid tubercle of scapula; short head—apex of coracoid process	Tuberosity of radius	Musculocutaneous nerve [**C5**, **C6**]	Powerful flexor of the forearm at the elbow joint and supinator of the forearm; accessory flexor of the arm at the glenohumeral joint
Coracobrachialis	2	Apex of coracoid process	Linear roughening on midshaft of humerus on medial side	Musculocutaneous nerve [**C5**, **C6**, **C7**]	Flexor of the arm at the glenohumeral joint; adducts arm

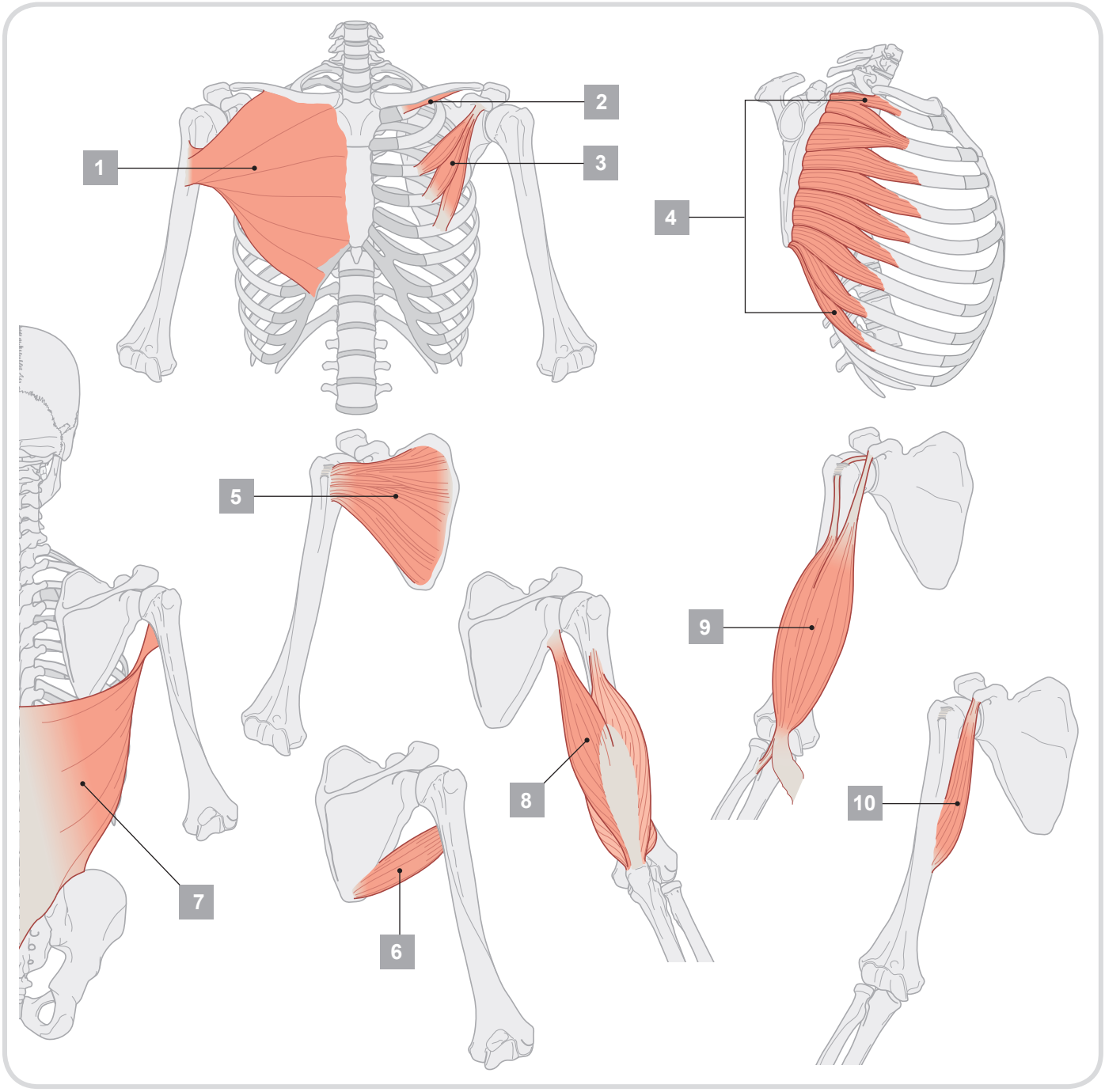

Muscles of the anterior compartment of the arm

(spinal segments in bold are the major segments innervating the muscle)

Muscle		Origin	Insertion	Innervation	Function
Coracobrachialis	1	Apex of coracoid process	Linear roughening on midshaft of humerus on medial side	Musculocutaneous nerve [**C5**, **C6**, **C7**]	Flexor of the arm at the glenohumeral joint
Biceps brachii	2	Long head—supraglenoid tubercle of scapula; short head—apex of coracoid process	Radial tuberosity	Musculocutaneous nerve [**C5**, **C6**]	Powerful flexor of the forearm at the elbow joint and supinator of the forearm; accessory flexor of the arm at the glenohumeral joint
Brachialis	3	Anterior aspect of humerus (medial and lateral surfaces) and adjacent intermuscular septae	Tuberosity of the ulna	Musculocutaneous nerve [C5, **C6**]; (small contribution by the radial nerve [C7] to lateral part of muscle)	Powerful flexor of the forearm at the elbow joint

Muscle of the posterior compartment of the arm

Triceps brachii	4	Long head—infraglenoid tubercle of scapula; medial head—posterior surface of humerus; lateral head—posterior surface of humerus	Olecranon	Radial nerve [C6, **C7**, C8]	Extension of the forearm at the elbow joint. Long head can also extend and adduct the arm at the shoulder joint

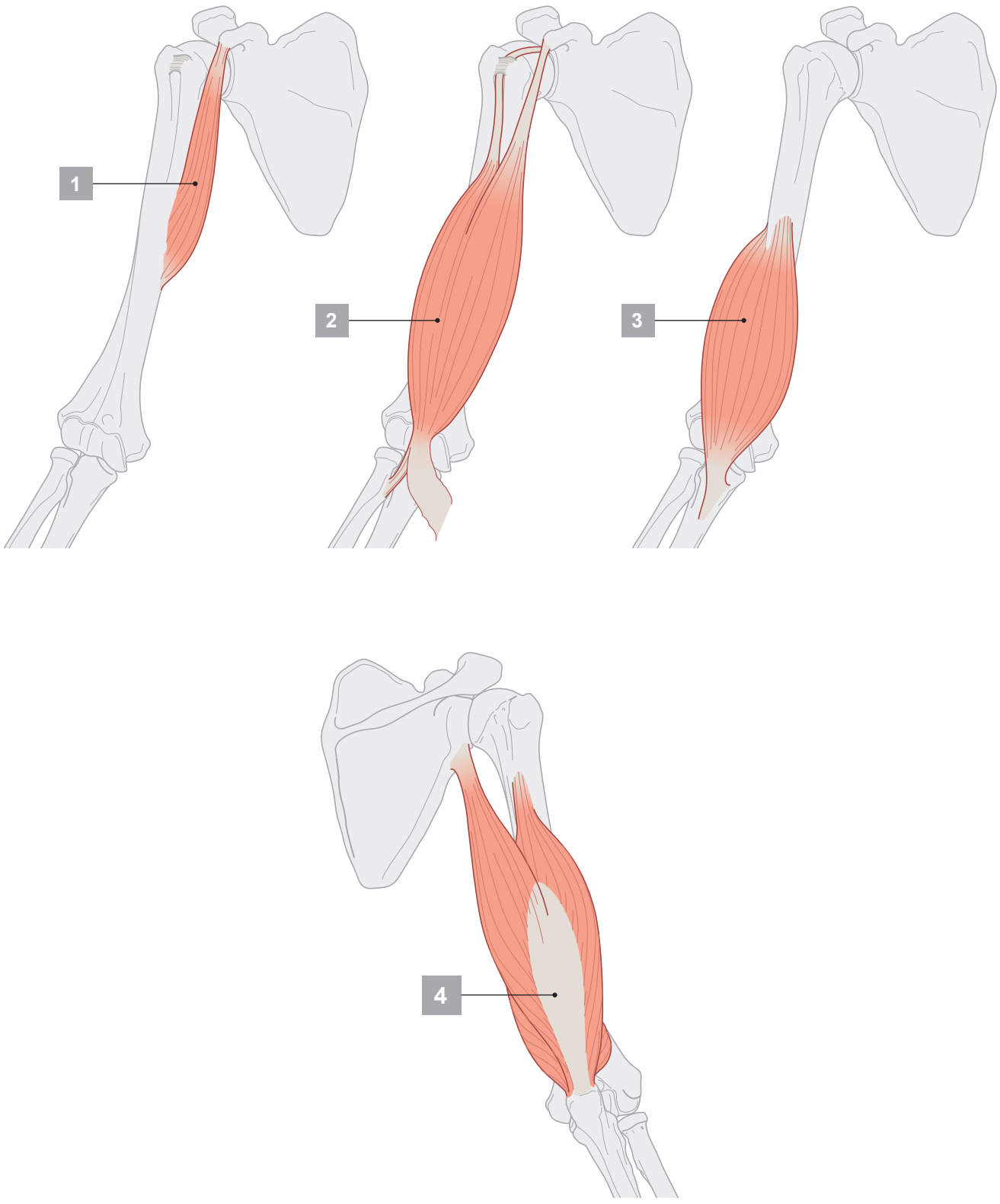
1
2
3
4

Superficial layer of muscles in the anterior compartment of the forearm

(spinal segments indicated in bold are the major segments innervating the muscle)

Muscle		Origin	Insertion	Innervation	Function
Flexor carpi ulnaris	1	Humeral head—medial epicondyle of humerus; ulnar head—olecranon and posterior border of ulna	Pisiform bone, and then via pisohamate and pisometacarpal ligaments into the hamate and base of metacarpal V	Ulnar nerve [C7, **C8**, T1]	Flexes and adducts the wrist joint
Palmaris longus	2	Medial epicondyle of humerus	Palmar aponeurosis of hand	Median nerve [**C7**, **C8**]	Flexes wrist joint; because the palmar aponeurosis anchors skin of the hand, contraction of the muscle resists shearing forces when gripping
Flexor carpi radialis	3	Medial epicondyle of humerus	Base of metacarpals II and III	Median nerve [**C6**, **C7**]	Flexes and abducts the wrist
Pronator teres	4	Humeral head—medial epicondyle and adjacent supracondylar ridge; ulnar head—medial side of coronoid process	Roughening on lateral surface, midshaft, of radius	Median nerve [**C6**, **C7**]	Pronation

Intermediate layer of muscles in the anterior compartment of the forearm

Flexor digitorum superficialis	5	Humero-ulnar head—medial epicondyle of humerus and adjacent margin of coronoid process; radial head—oblique line of radius	Four tendons, which attach to the palmar surfaces of the middle phalanges of the index, middle, ring, and little fingers	Median nerve [**C8**, T1]	Flexes proximal interphalangeal joints of the index, middle, ring, and little fingers; can also flex metacarpophalangeal joints of the same fingers and the wrist joint

Deep layer of muscles in the anterior compartment of the forearm

Flexor digitorum profundus	6	Anterior and medial surfaces of ulna and anterior medial half of interosseous membrane	Four tendons, which attach to the palmar surfaces of the distal phalanges of the index, middle, ring, and little fingers	Lateral half by median nerve (anterior interosseous nerve); medial half by ulnar nerve [**C8**, T1]	Flexes distal interphalangeal joints of the index, middle, ring, and little fingers; can also flex metacarpophalangeal joints of the same fingers and the wrist joint
Flexor pollicis longus	7	Anterior surface of radius and radial half of interosseous membrane	Palmar surface of base of distal phalanx of thumb	Median nerve (anterior interosseous nerve) [C7, **C8**]	Flexes interphalangeal joint of the thumb; can also flex metacarpophalangeal joint of the thumb
Pronator quadratus	8	Linear ridge on distal anterior surface of ulna	Distal anterior surface of radius	Median nerve (anterior interosseous nerve) [C7, **C8**]	Pronation

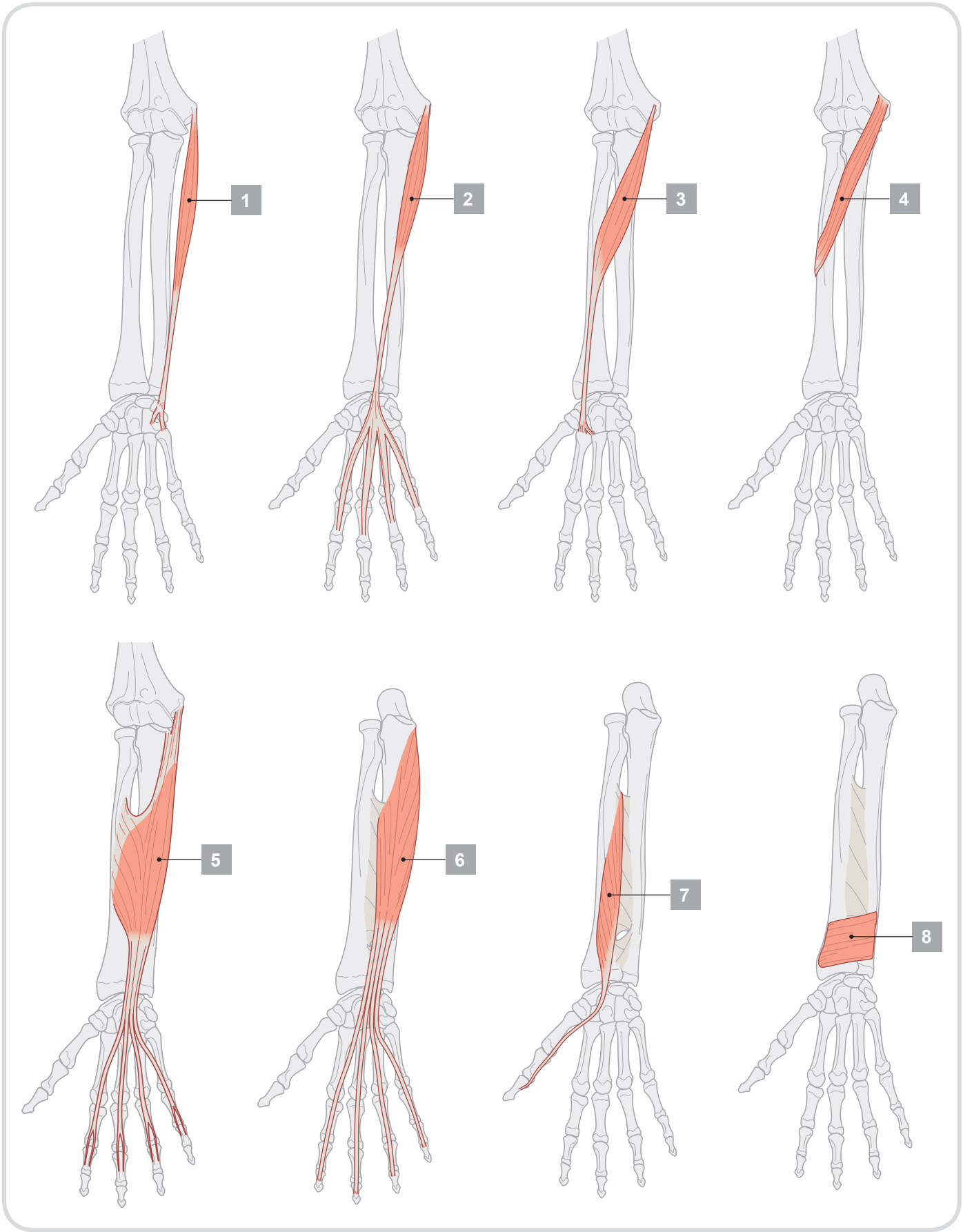
1
2
3
4
5
6
7
8

Superficial layer of muscles in the posterior compartment of the forearm

(spinal segments indicated in bold are the major segments innervating the muscle)

Muscle		Origin	Insertion	Innervation	Function
Brachioradialis	1	Proximal part of lateral supracondylar ridge of humerus and adjacent intermuscular septum	Lateral surface of distal end of radius	Radial nerve [C5, **C6**] before division into superficial and deep branches	Accessory flexor of elbow joint when forearm is midpronated
Extensor carpi radialis longus	2	Distal part of lateral supracondylar ridge of humerus and adjacent intermuscular septum	Dorsal surface of base of metacarpal II	Radial nerve [**C6**, C7] before division into superficial and deep branches	Extends and abducts the wrist
Extensor carpi radialis brevis	3	Lateral epicondyle of humerus and adjacent intermuscular septum	Dorsal surface of base of metacarpals II and III	Deep branch of radial nerve [**C7**, C8] before penetrating supinator muscle	Extends and abducts the wrist
Extensor digitorum	4	Lateral epicondyle of humerus and adjacent intermuscular septum and deep fascia	Four tendons, which insert via extensor hoods into the dorsal aspects of the bases of the middle and distal phalanges of the index, middle, ring, and little fingers	Posterior interosseous nerve [**C7**, C8]	Extends the index, middle, ring, and little fingers; can also extend the wrist
Extensor digiti minimi	5	Lateral epicondyle of humerus and adjacent intermuscular septum together with extensor digitorum	Extensor hood of the little finger	Posterior interosseous nerve [**C7**, C8]	Extends the little finger
Extensor carpi ulnaris	6	Lateral epicondyle of humerus and posterior border of ulna	Tubercle on the base of the medial side of metacarpal V	Posterior interosseous nerve [**C7**, C8]	Extends and adducts the wrist
Anconeus	7	Lateral epicondyle of humerus	Olecranon and proximal posterior surface of ulna	Radial nerve [**C6**, **C7**, **C8**] (via branch to medial head of triceps brachii)	Abduction of the ulna in pronation; accessory extensor of the elbow joint

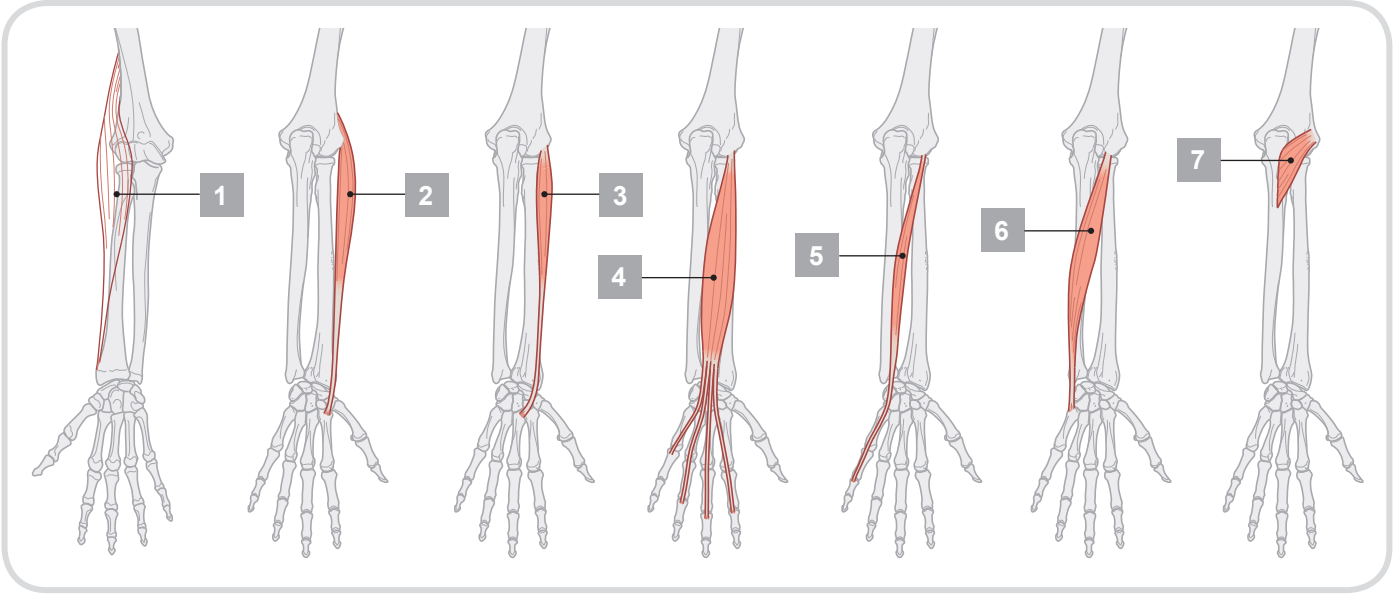

Deep layer of muscles in the posterior compartment of the forearm

(spinal segments indicated in bold are the major segments innervating the muscle)

Muscle		Origin	Insertion	Innervation	Function
Supinator	1	Superficial part—lateral epicondyle of humerus, radial collateral and anular ligaments; deep part—supinator crest of the ulna	Lateral surface of radius superior to the anterior oblique line	Posterior interosseous nerve [**C6**, C7]	Supination
Abductor pollicis longus	2	Posterior surfaces of ulna and radius (distal to the attachments of supinator and anconeus) and intervening interosseous membrane	Lateral side of base of metacarpal I	Posterior interosseous nerve [**C7**, C8]	Abducts carpometacarpal joint of thumb; accessory extensor of the thumb
Extensor pollicis brevis	3	Posterior surface of radius (distal to abductor pollicis longus) and the adjacent interosseous membrane	Dorsal surface of base of proximal phalanx of the thumb	Posterior interosseous nerve [**C7**, C8]	Extends metacarpophalangeal joint of the thumb; can also extend the carpometacarpal joint of the thumb
Extensor pollicis longus	4	Posterior surface of ulna (distal to the abductor pollicis longus) and the adjacent interosseous membrane	Dorsal surface of base of distal phalanx of thumb	Posterior interosseous nerve [**C7**, C8]	Extends interphalangeal joint of the thumb; can also extend carpometacarpal and metacarpophalangeal joints of the thumb
Extensor indicis	5	Posterior surface of ulna (distal to extensor pollicis longus) and adjacent interosseous membrane	Extensor hood of index finger	Posterior interosseous nerve [**C7**, C8]	Extends index finger

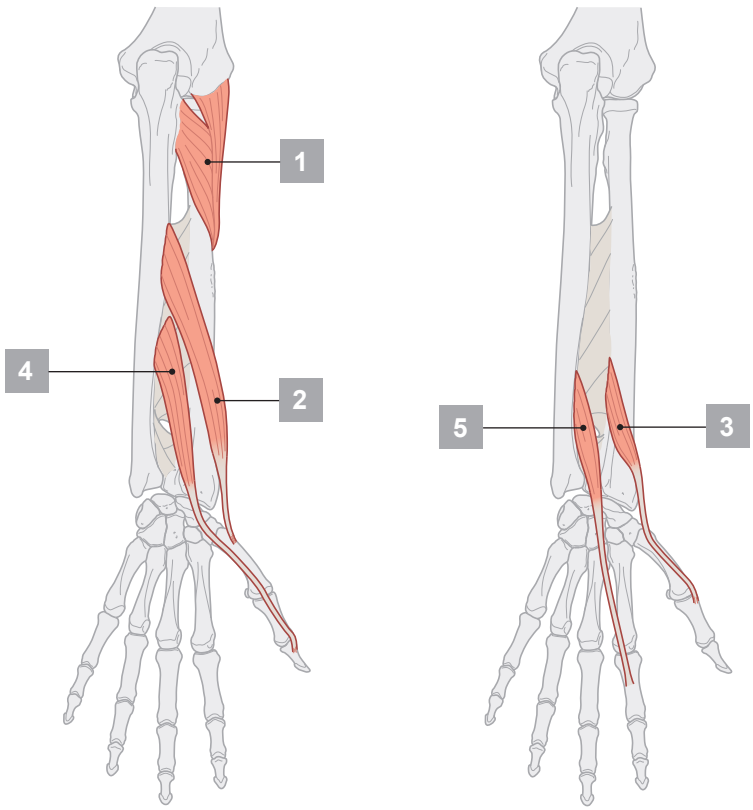

Intrinsic muscles of the hand

(spinal segments indicated in bold are the major segments innervating the muscle)

Muscle		Origin	Insertion	Innervation	Function
Palmaris brevis	1	Palmar aponeurosis and flexor retinaculum	Dermis of skin on the medial margin of the hand	Superficial branch of the ulnar nerve [C8, **T1**]	Improves grip
Dorsal interossei (four muscles)	2	Adjacent sides of metacarpals	Extensor hood and base of proximal phalanges of index, middle, and ring fingers	Deep branch of ulnar nerve [C8, **T1**]	Abduction of index, middle, and ring fingers at the metacarpophalangeal joints
Palmar interossei (four muscles)	3	Sides of metacarpals	Extensor hoods of the thumb, index, ring, and little fingers and the proximal phalanx of thumb	Deep branch of ulnar nerve [C8, **T1**]	Adduction of the thumb, index, ring, and little fingers at the metacarpophalangeal joints
Adductor pollicis	4	Transverse head—metacarpal III; oblique head—capitate and bases of metacarpals II and III	Base of proximal phalanx and extensor hood of thumb	Deep branch of ulnar nerve [C8, **T1**]	Adducts thumb
Lumbricals (four muscles)	5	Tendons of flexor digitorum profundus	Extensor hoods of index, ring, middle, and little fingers	Medial two by the deep branch of the ulnar nerve; lateral two by digital branches of the median nerve	Flex metacarpophalangeal joints while extending interphalangeal joints
Thenar muscles					
Opponens pollicis	6	Tubercle of trapezium and flexor retinaculum	Lateral margin and adjacent palmar surface of metacarpal I	Recurrent branch of median nerve [C8, **T1**]	Medially rotates thumb
Abductor pollicis brevis	7	Tubercles of scaphoid and trapezium and adjacent flexor retinaculum	Proximal phalanx and extensor hood of thumb	Recurrent branch of median nerve [C8, **T1**]	Abducts thumb at metacarpophalangeal joint
Flexor pollicis brevis	8	Tubercle of the trapezium and flexor retinaculum	Proximal phalanx of the thumb	Recurrent branch of median nerve [C8, **T1**]	Flexes thumb at metacarpophalangeal joint
Hypothenar muscles					
Opponens digiti minimi	9	Hook of hamate and flexor retinaculum	Medial aspect of metacarpal V	Deep branch of ulnar nerve [C8, **T1**]	Laterally rotates metacarpal V
Abductor digiti minimi	10	Pisiform, the pisohamate ligament, and tendon of flexor carpi ulnaris	Proximal phalanx of little finger	Deep branch of ulnar nerve [C8, **T1**]	Abducts little finger at metacarpophalangeal joint
Flexor digiti minimi brevis	11	Hook of the hamate and flexor retinaculum	Proximal phalanx of little finger	Deep branch of ulnar nerve [C8, **T1**]	Flexes little finger at metacarpophalangeal joint

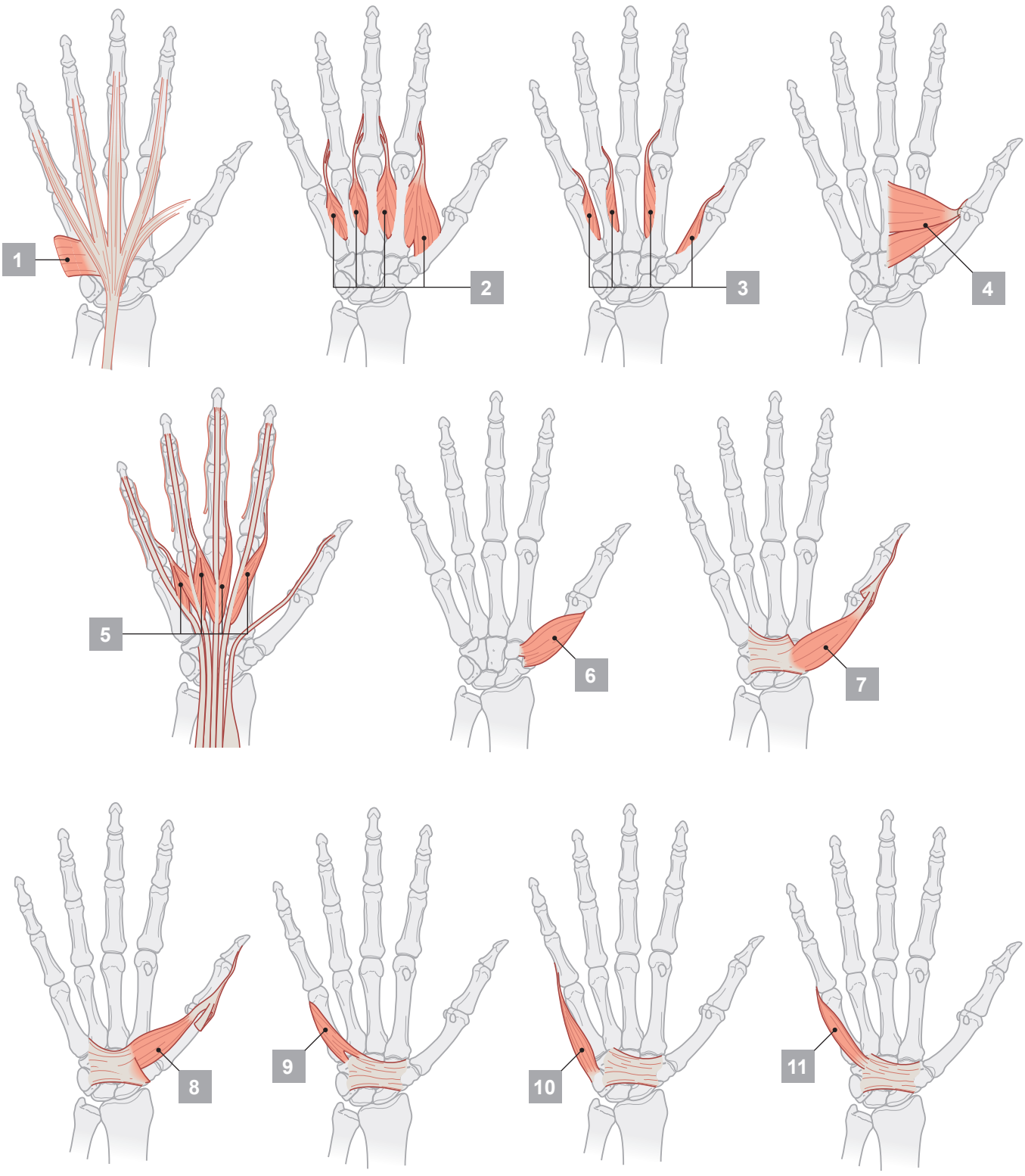
1
2
3
4
5
6
7
8
9
10
11

This page intentionally left blank

8

HEAD AND NECK

CONTENTS

Surface anatomy with bones **476**
Bones of the skull **477**
Skull: anterior view **478**
Skull: lateral view **480**
Skull: posterior view **482**
Skull: superior view and roof **483**
Skull: inferior view **484**
Skull: cranial cavity **485**
Ethmoid, lacrimal bone, inferior concha, and vomer **486**
Maxilla and palatine bone **487**
Skull: muscle attachments **488**
Scalp and meninges **490**
Dural partitions **491**
Dural arteries and nerves **492**
Dural venous sinuses **493**
Brain **494**
Brain: imaging **496**
Cranial nerves **498**
Arterial supply to brain **500**
Cutaneous distribution of trigeminal nerve [V] **503**
Facial muscles **504**
Vasculature, facial nerve [VII], and lymphatics **506**
Deep arteries and veins of parotid region **507**
Bony orbit **508**
Section through orbit and structures of eyelid **509**
Eyelids and lacrimal apparatus **510**
Innervation of the lacrimal gland **511**
Muscles of the eyeball **512**
Innervation of the orbit and eyeball **513**
Eye movements **514**
Vasculature of orbit **515**
Eyeball **516**
Eye imaging **517**
Ear surface and sensory innervation **520**
Ear **521**
Middle ear **522**
Internal ear **524**
Ear imaging **525**
Temporal and infratemporal fossae **526**
Bones of the temporal and infratemporal fossae **527**
Temporal and infratemporal fossae **528**
Temporomandibular joint **530**
Mandibular division of the trigeminal nerve [V] **531**
Parasympathetic innervation **532**
Arteries and veins of temporal and infratemporal fossae **533**
Pterygopalatine fossa **534**
Neck surface anatomy **536**
Bones of the neck **537**
Compartments and fascia of the neck **538**
Superficial veins of the neck **539**
Muscles of the neck **540**
Nerves in the neck **542**
Cranial nerves in the neck **543**
Cervical plexus and sympathetic trunk **544**
Arteries of the neck **546**
Root of the neck: arteries **548**
Lymphatics of the neck **550**
Pharynx **552**
Muscles of the pharynx **554**
Innervation of the pharynx **556**
Vasculature of the pharynx **557**
Larynx **558**
Laryngeal cavity **560**
Muscles of the larynx **561**
Innervation of the larynx **562**
Thyroid gland **563**
Vasculature of the thyroid gland **564**
Nose and paranasal sinuses **566**
Nasal cavity: bones **567**
Nasal cavity: mucosal linings **568**
Vasculature and innervation of the nasal cavity **569**
Sinus imaging **570**
Oral cavity: bones **572**
Teeth **573**
Teeth: imaging **574**
Anatomy of teeth **575**
Vessels and nerves supplying teeth **576**
Innervation of teeth and gums **577**
Muscles and salivary glands of the oral cavity **578**
Vessels and nerves of the tongue **579**
Tongue **580**
Hard and soft palate **581**
Palate **582**
Innervation of oral cavity **583**
Cranial nerves **584**
Visceral motor pathways in the head **586**
Tables **588**

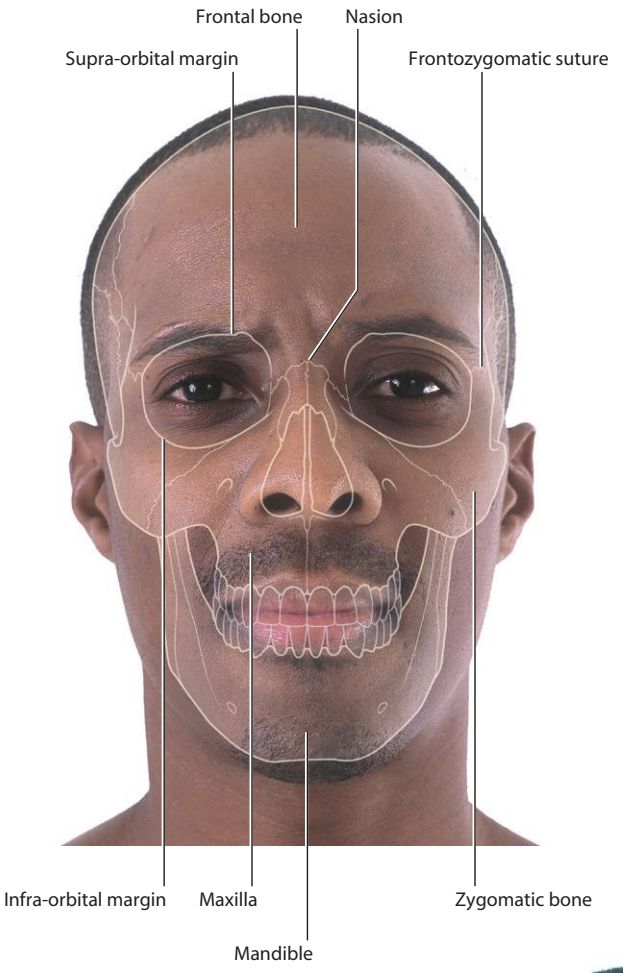

Anterior view

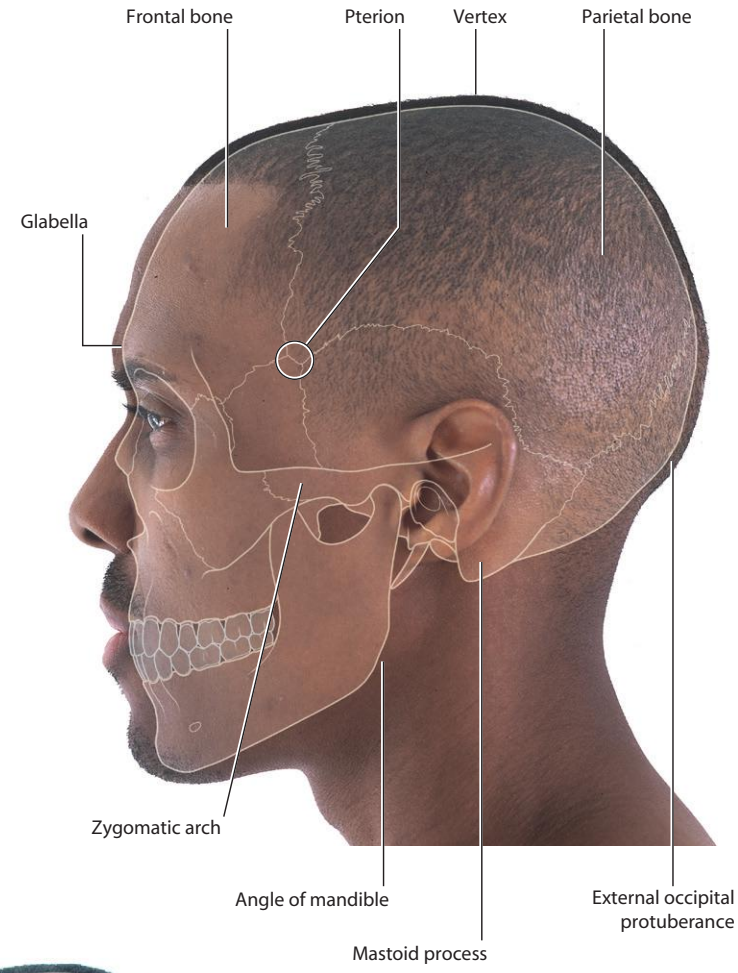

Lateral view

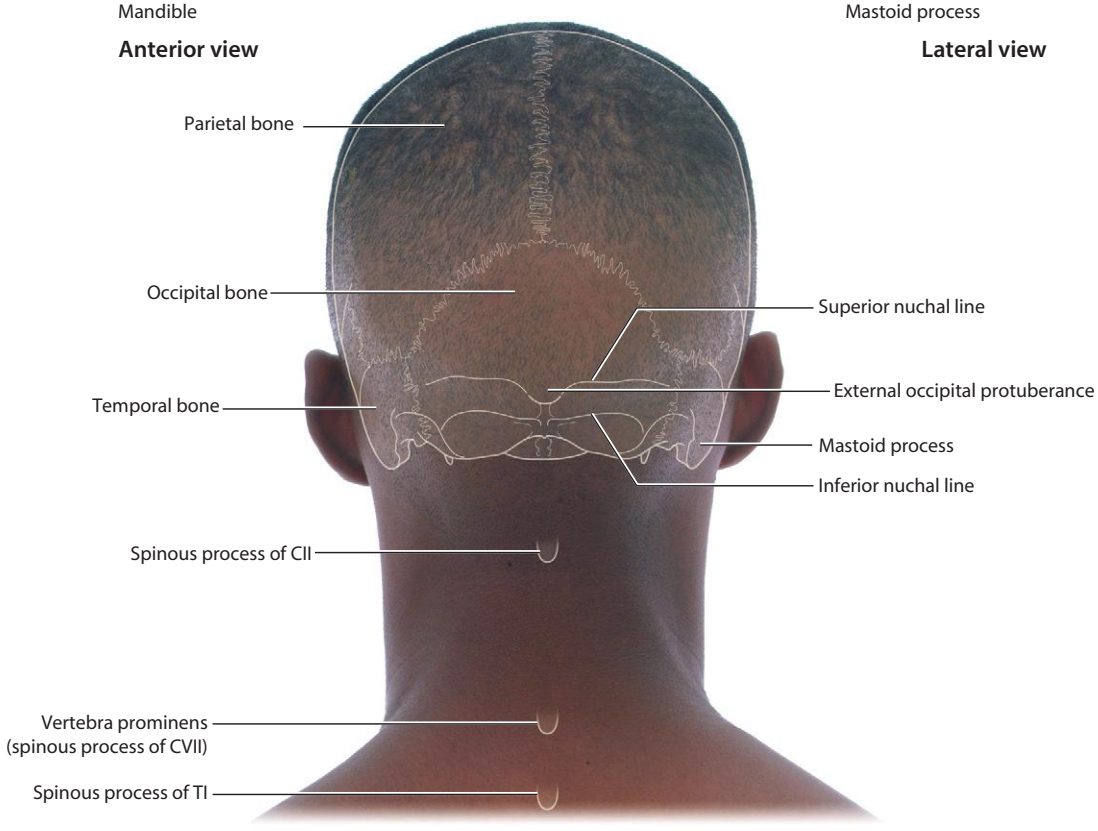

Posterior view

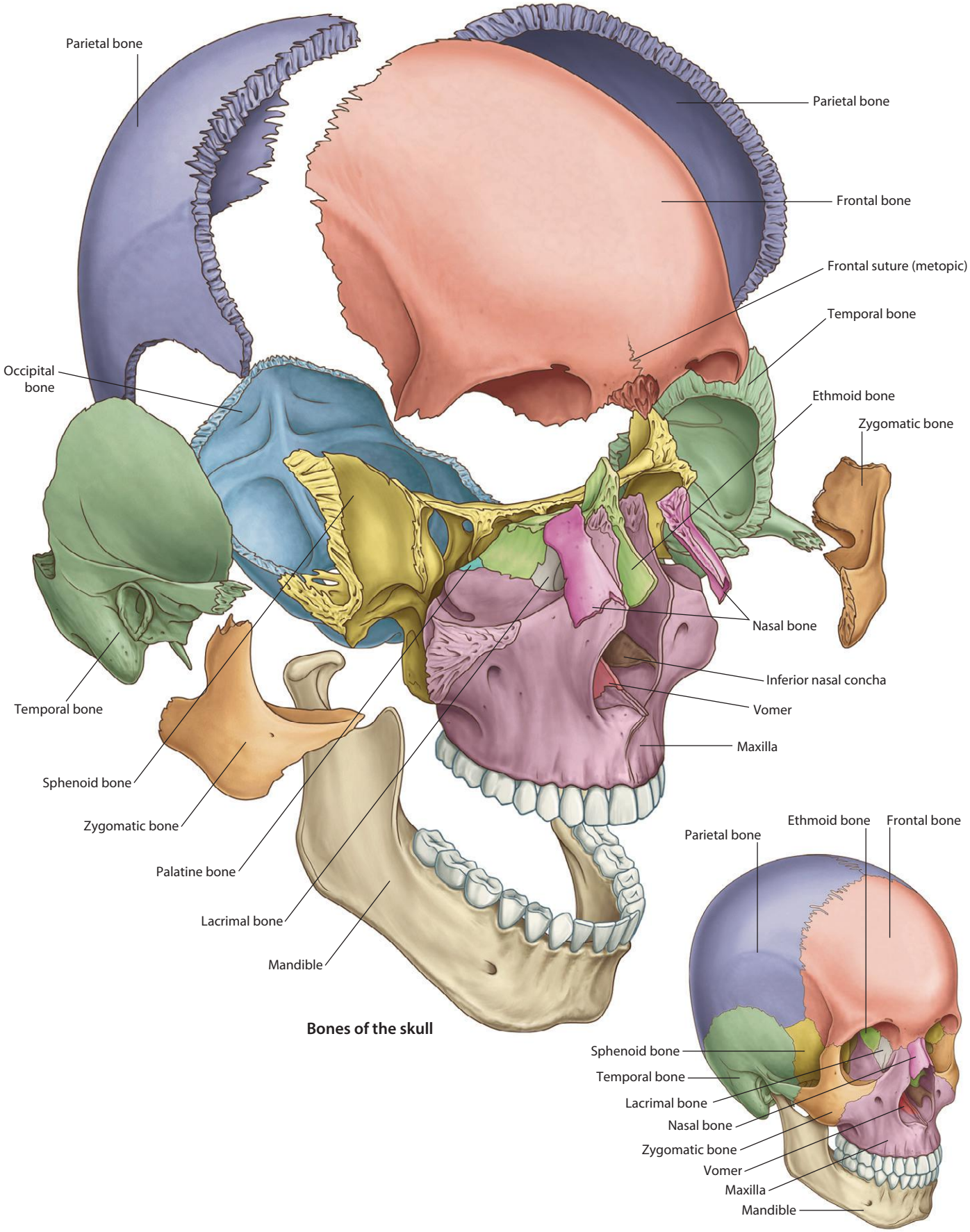

Bones of the skull

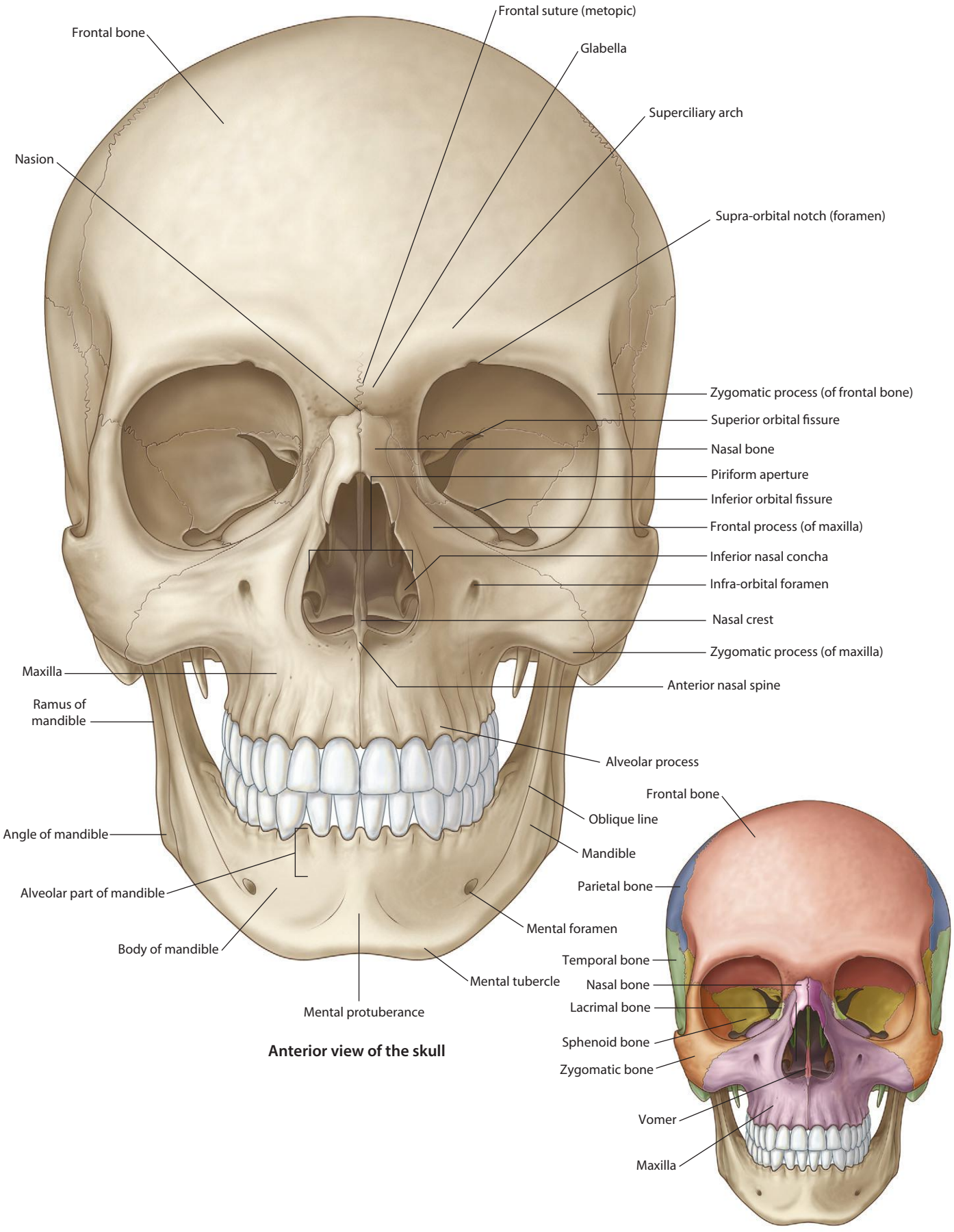

Anterior view of the skull

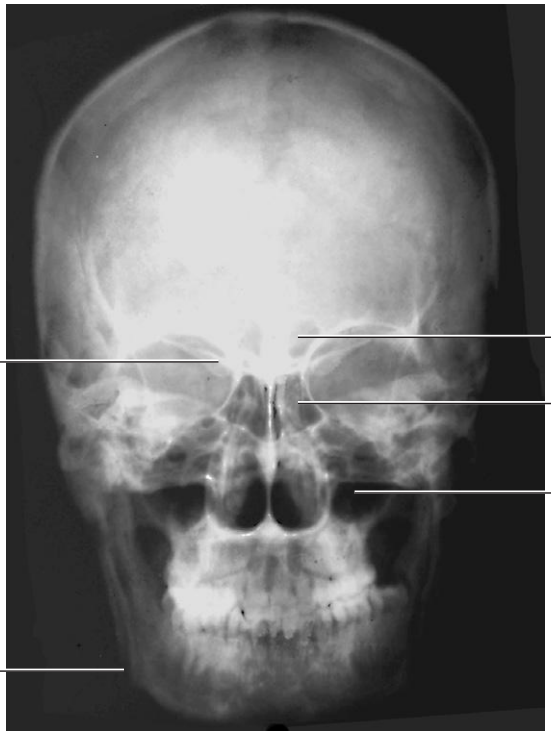

Anterior view of the skull.
Radiograph, AP view

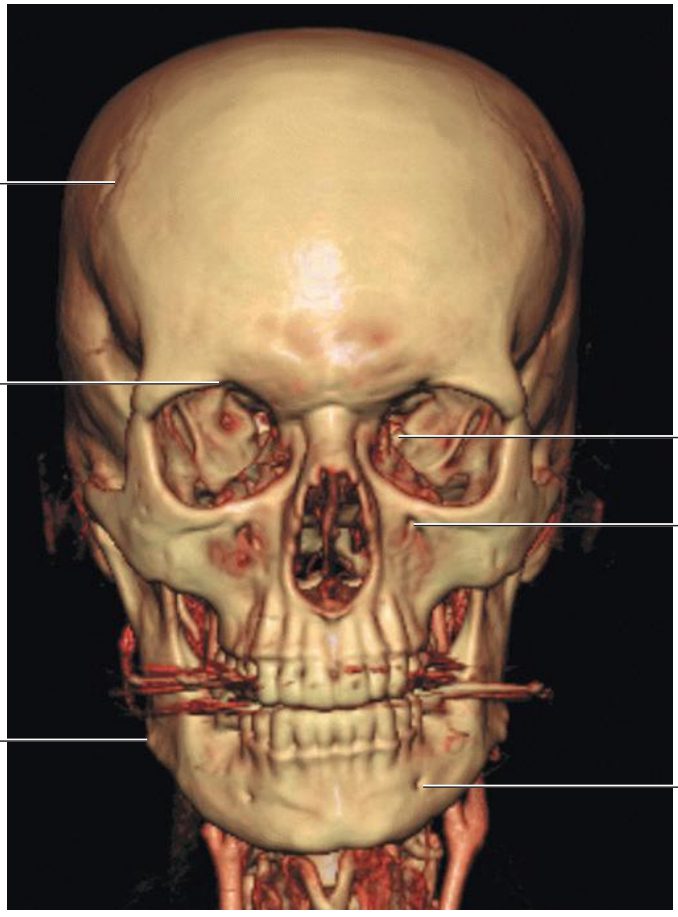

Anterior view of the skull.
Volume-rendered anterior view using multidetector computed tomography

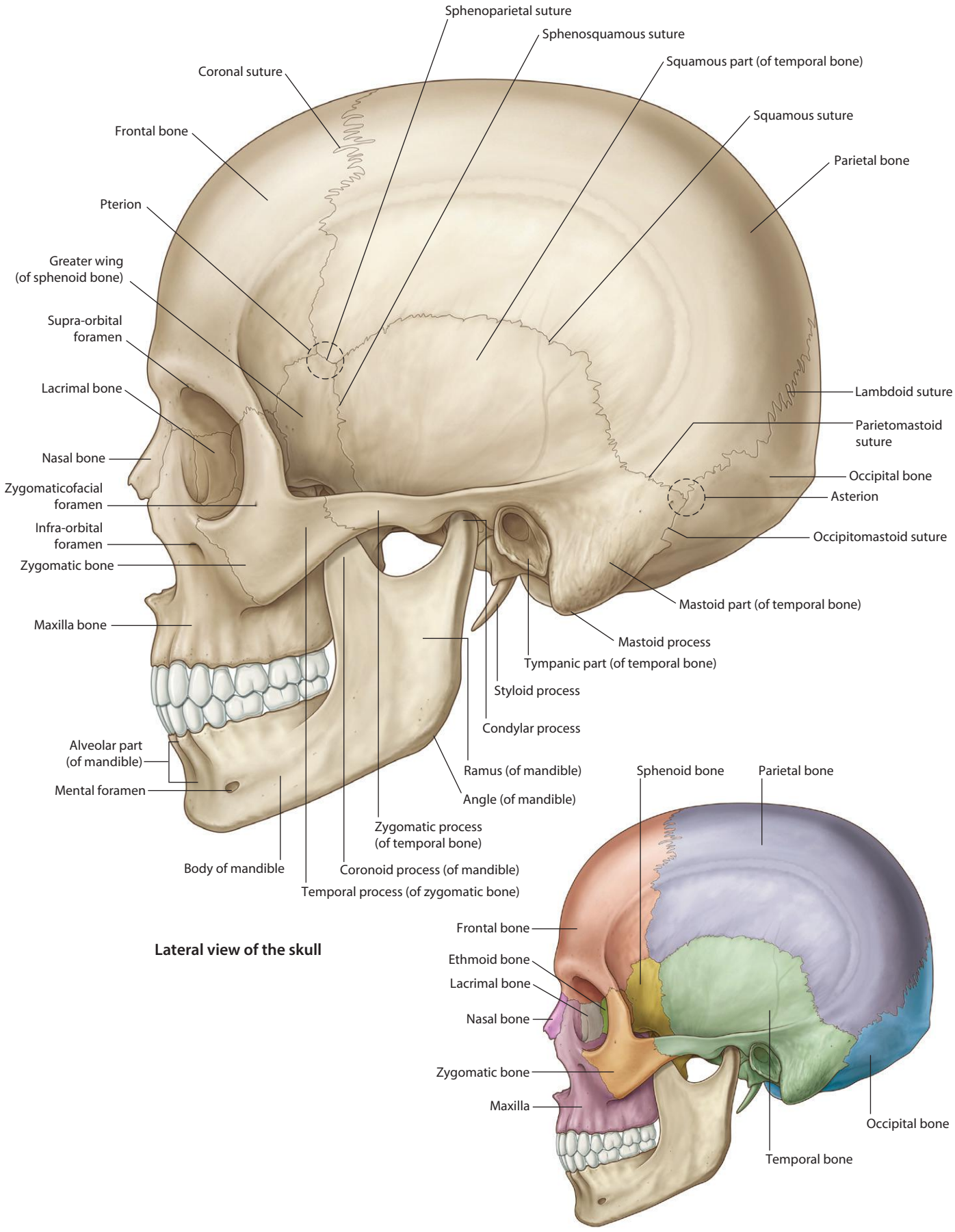

Lateral view of the skull

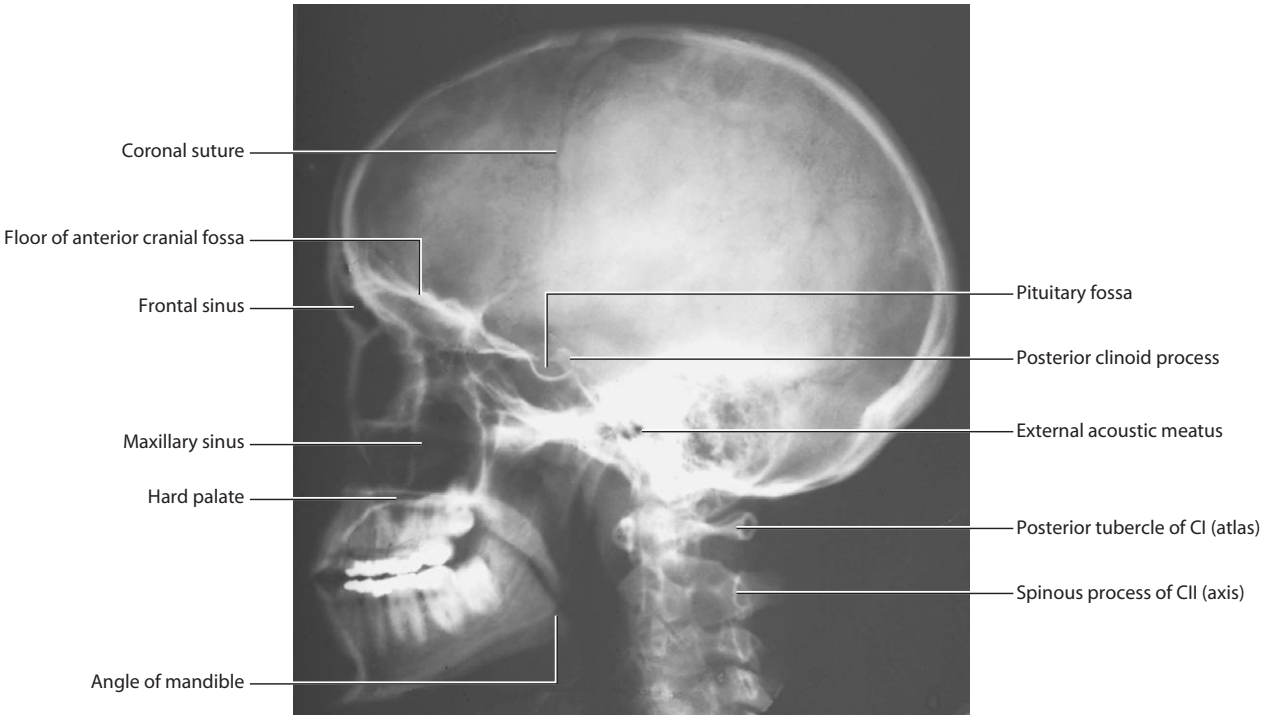

Lateral view of the skull.
Radiograph, lateral view

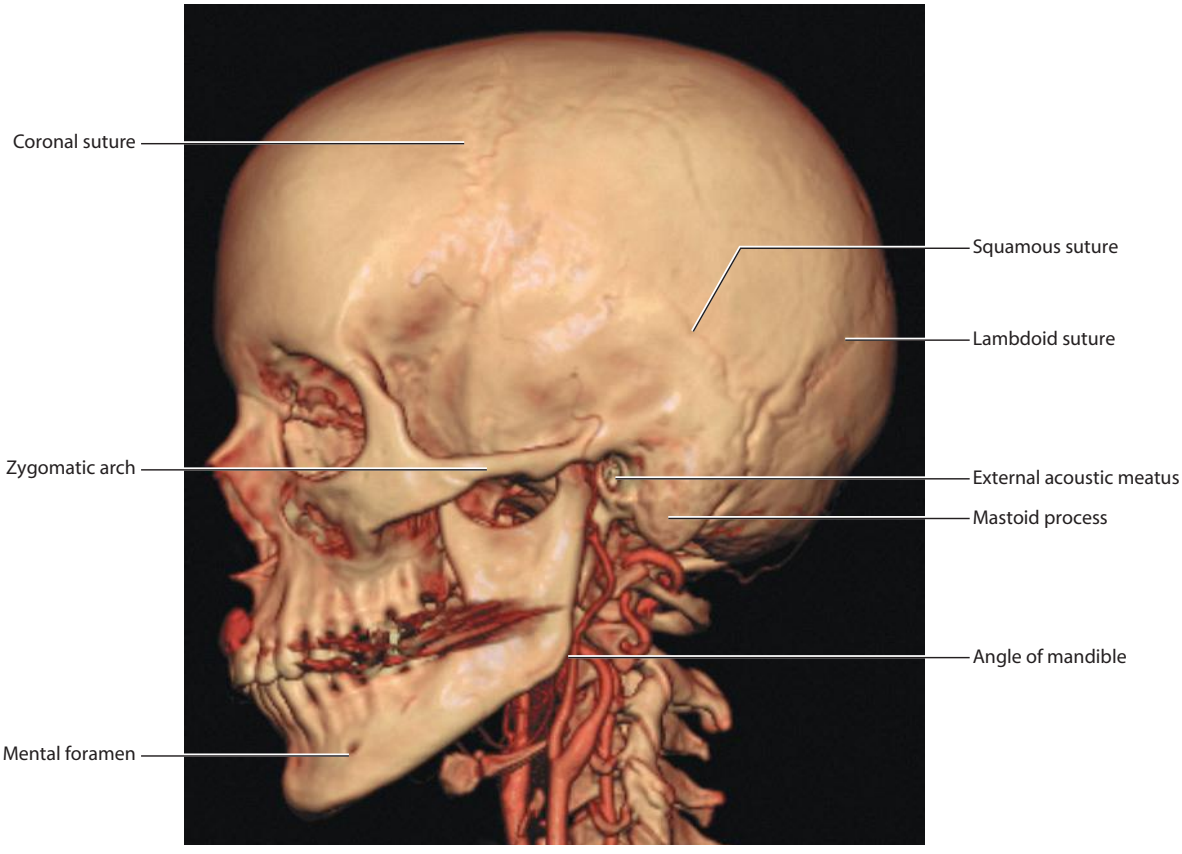

Lateral view of the skull.
Volume-rendered lateral view using multidetector computed tomography

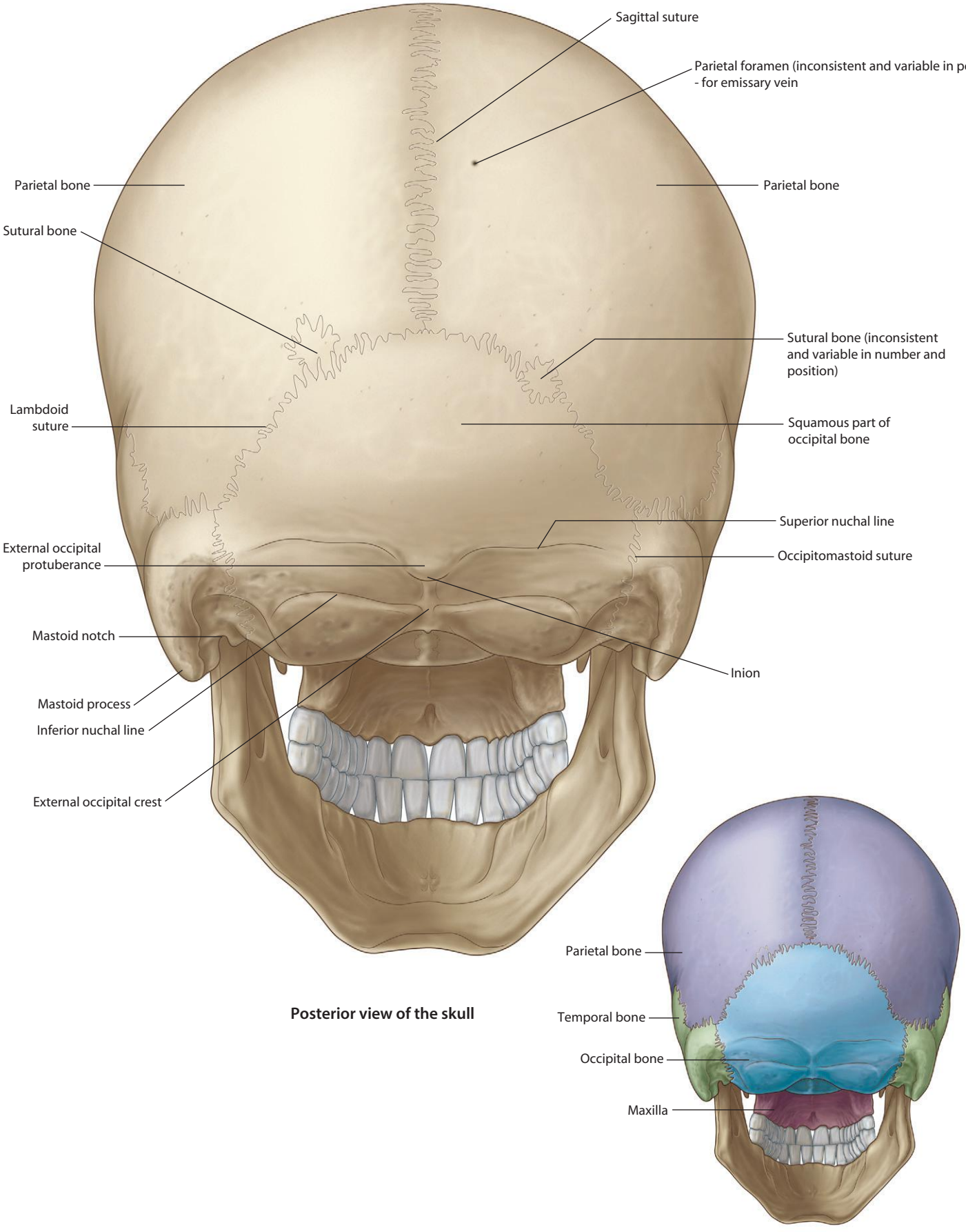

Posterior view of the skull

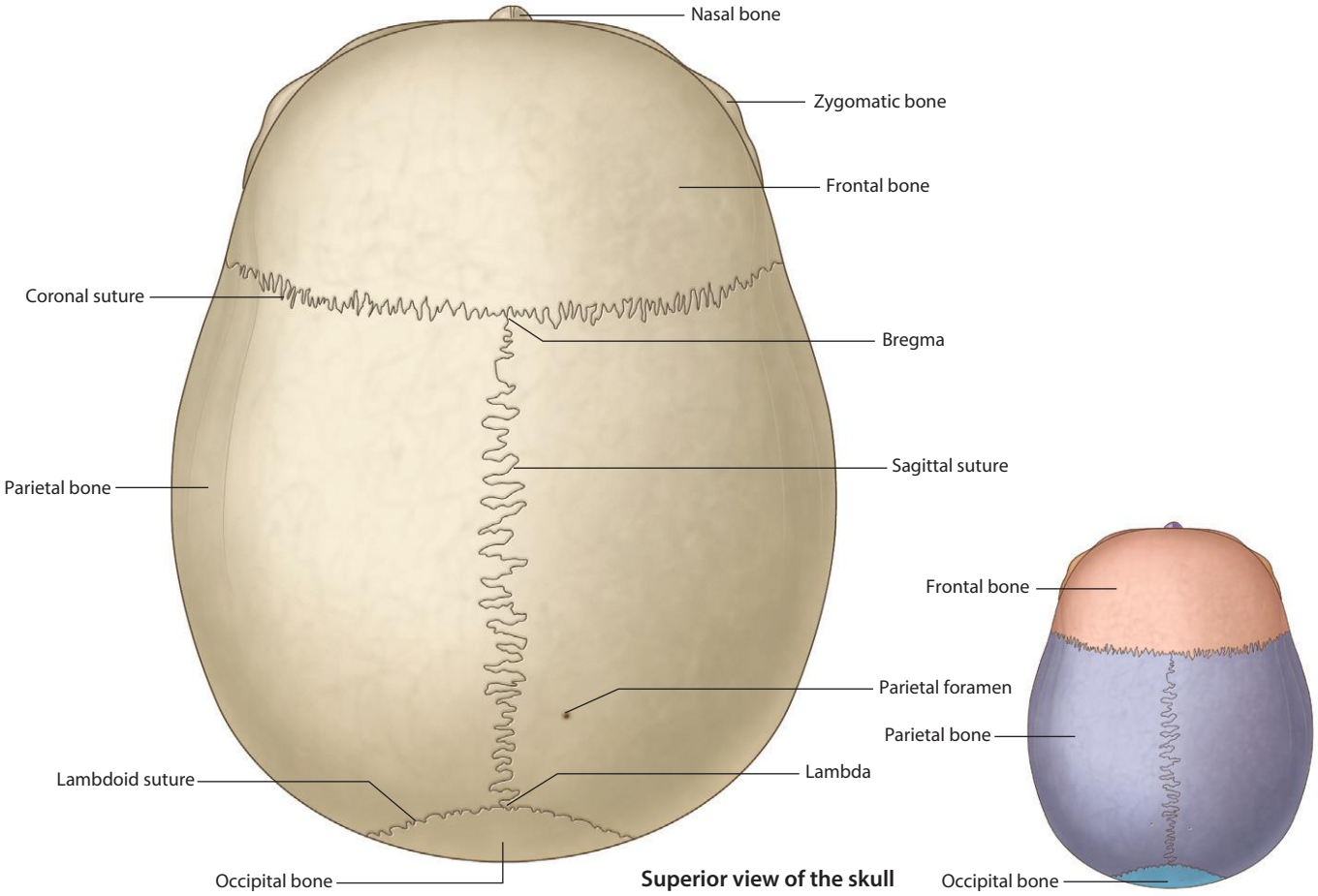

Superior view of the skull

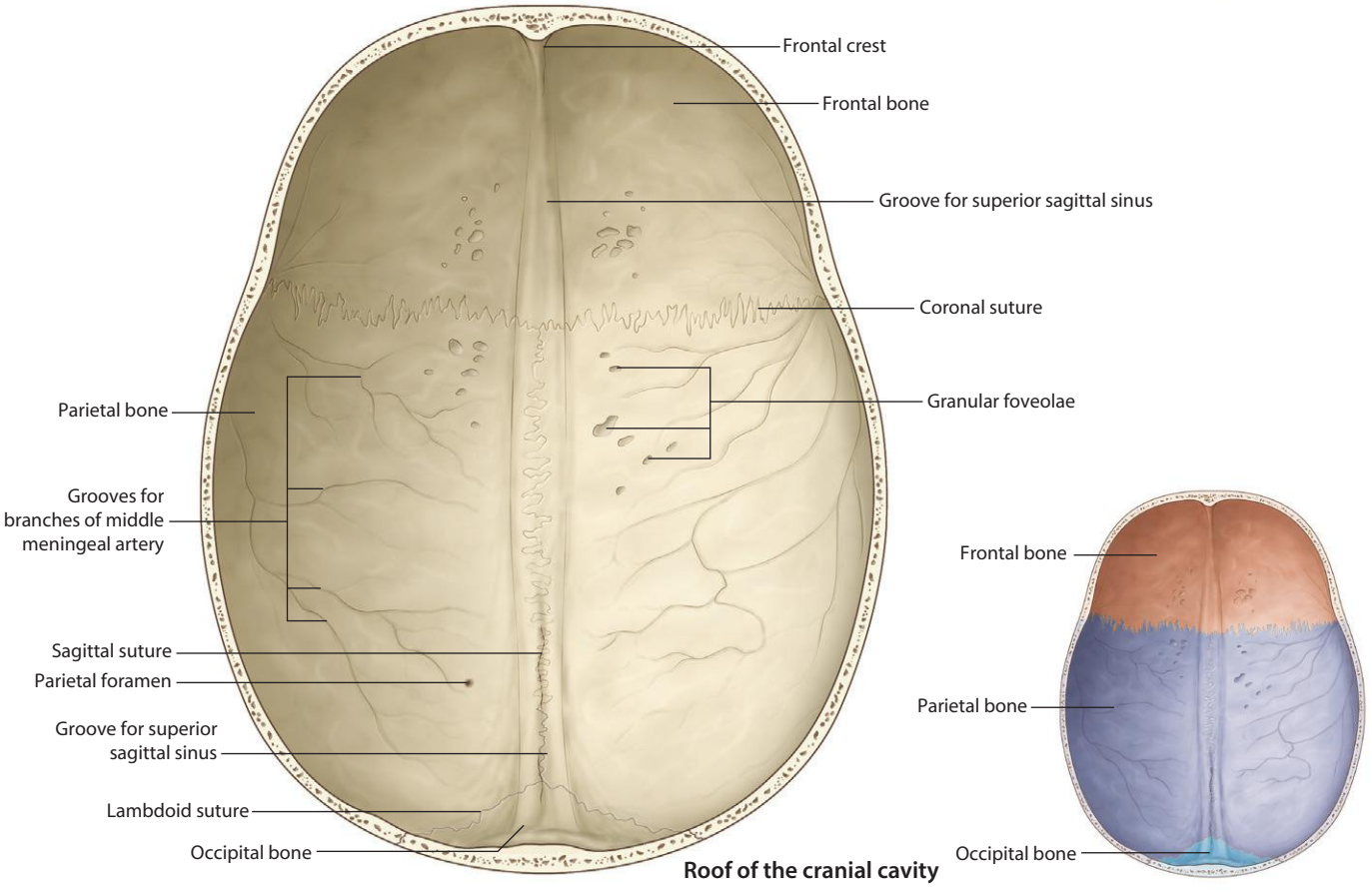

Roof of the cranial cavity

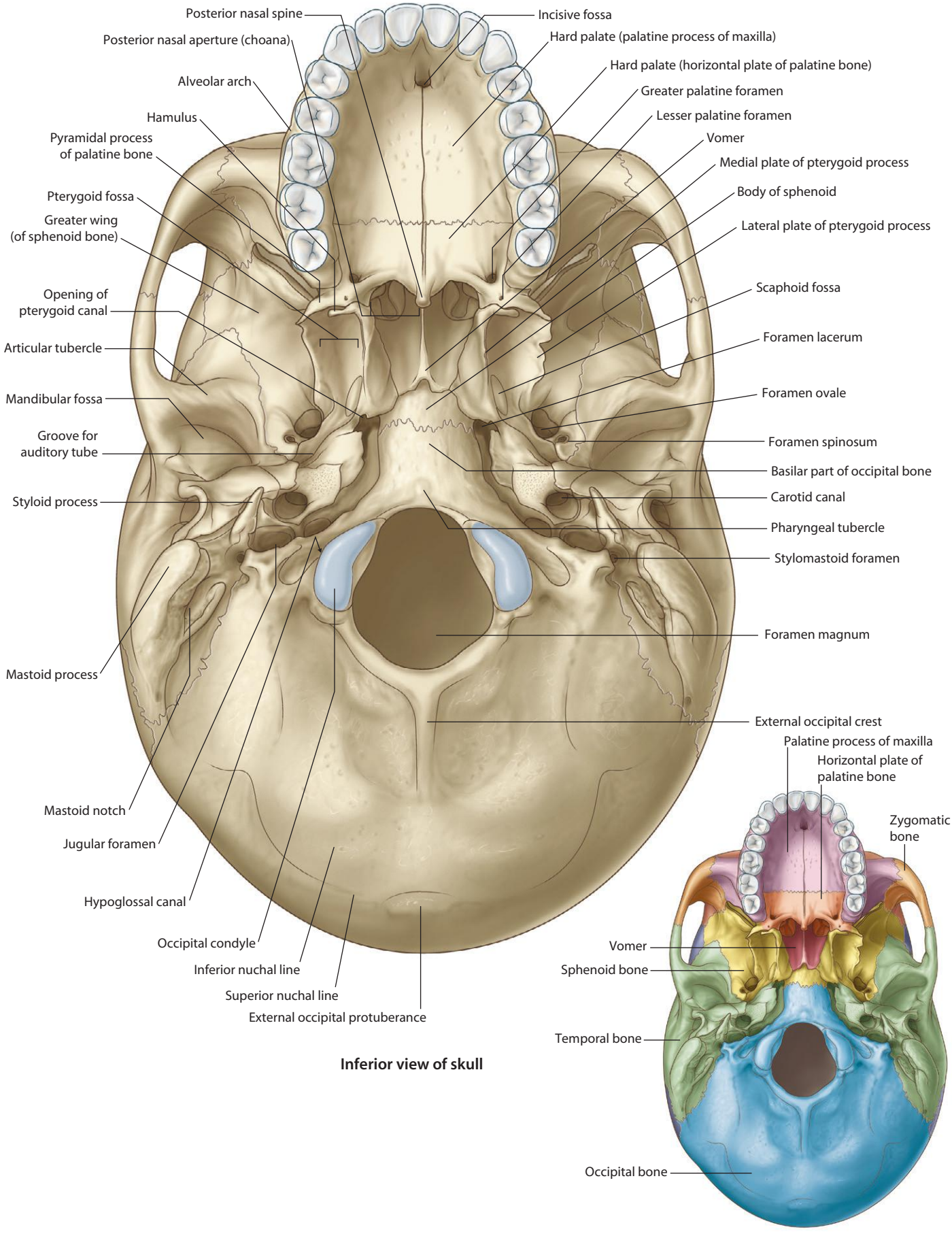

Inferior view of skull

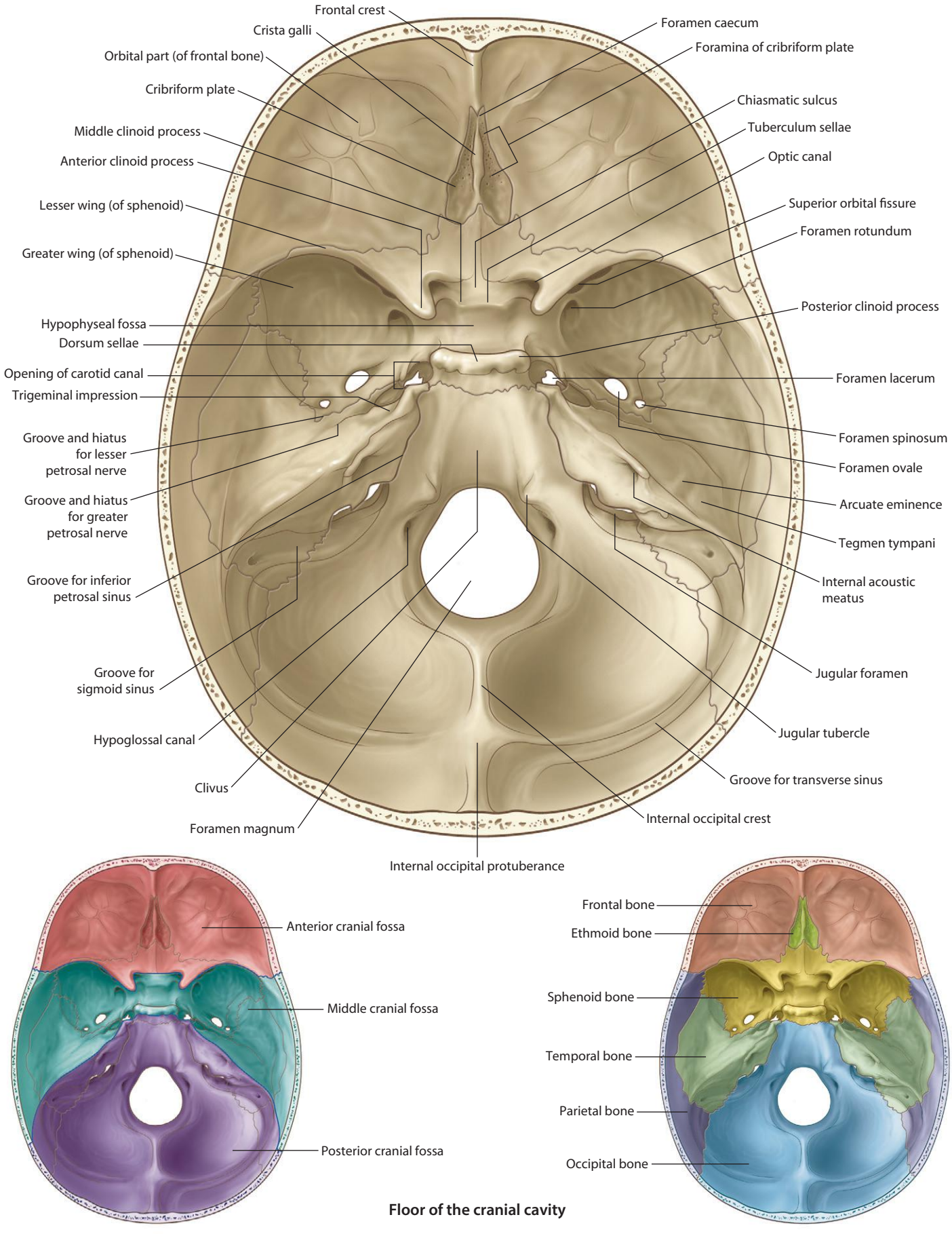

Floor of the cranial cavity

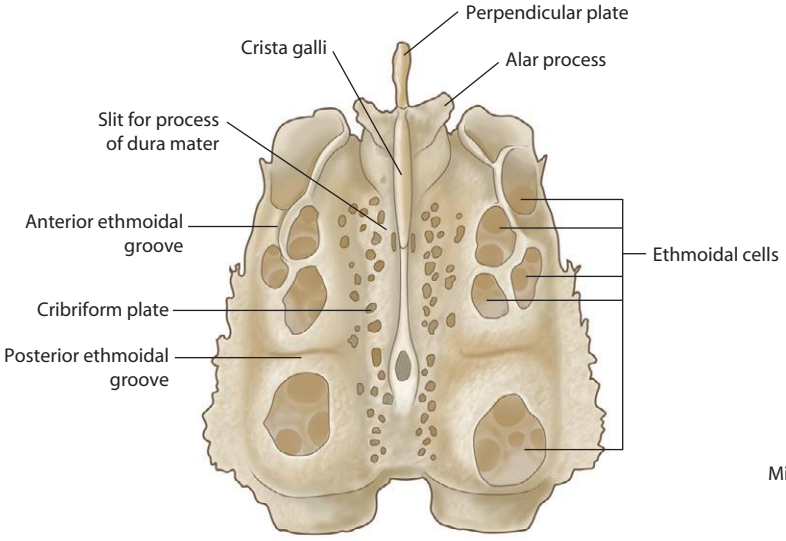

Ethmoid bone (superior view)

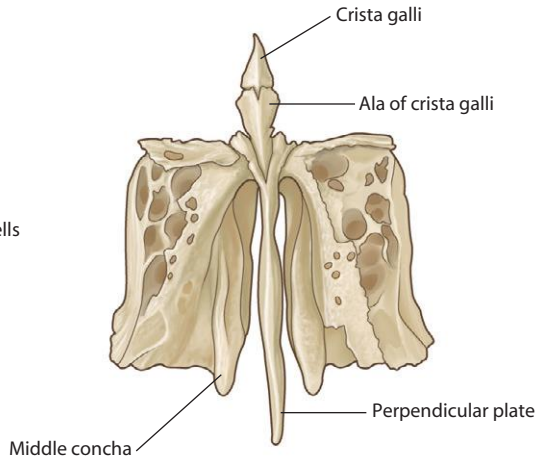

Ethmoid bone (posterior view)

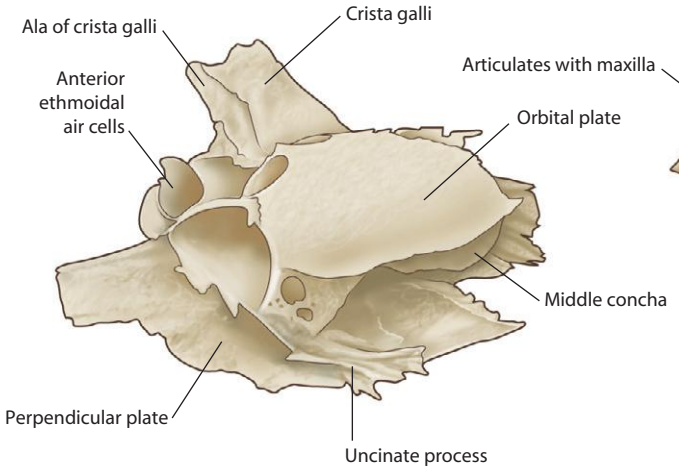

Ethmoid bone (lateral view)

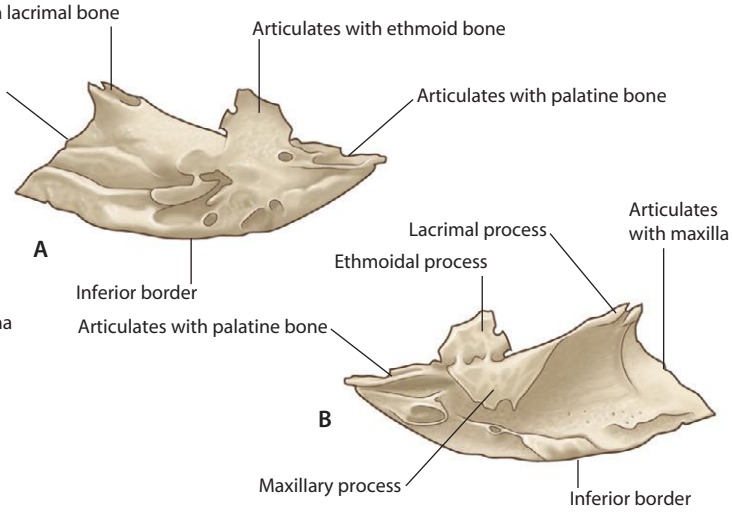

Right inferior concha
A. Medial view B. Lateral view

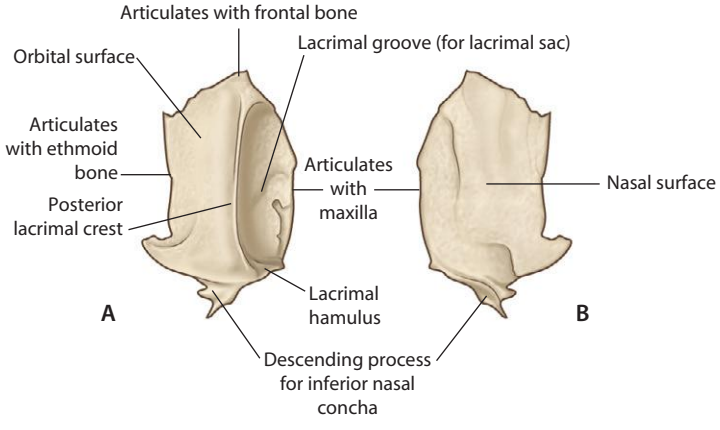

Right lacrimal bone
A. Lateral view B. Medial view

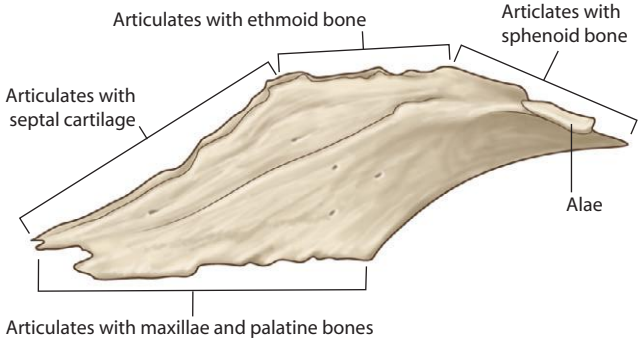

Vomer (lateral view)

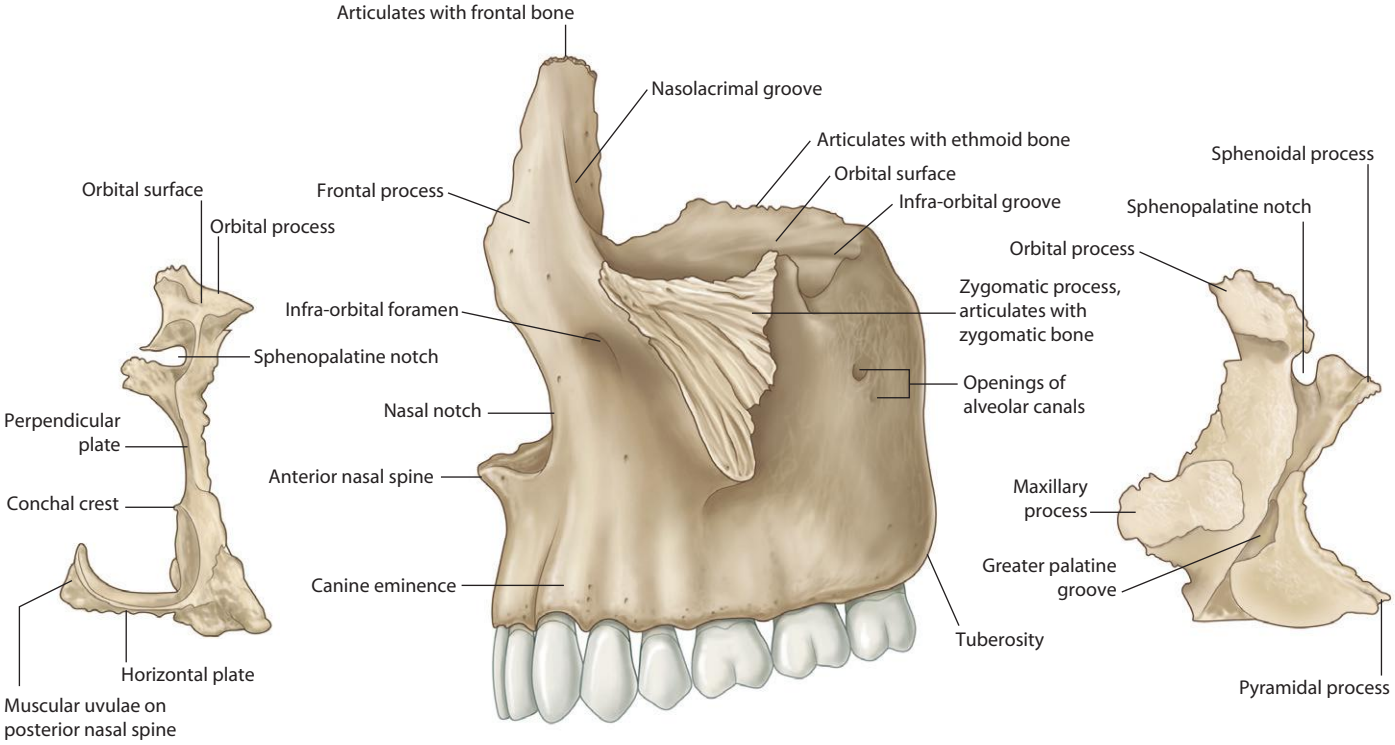

Left palatine bone (anterior view)

Left maxilla bone (lateral view)

Left palatine bone (lateral view)

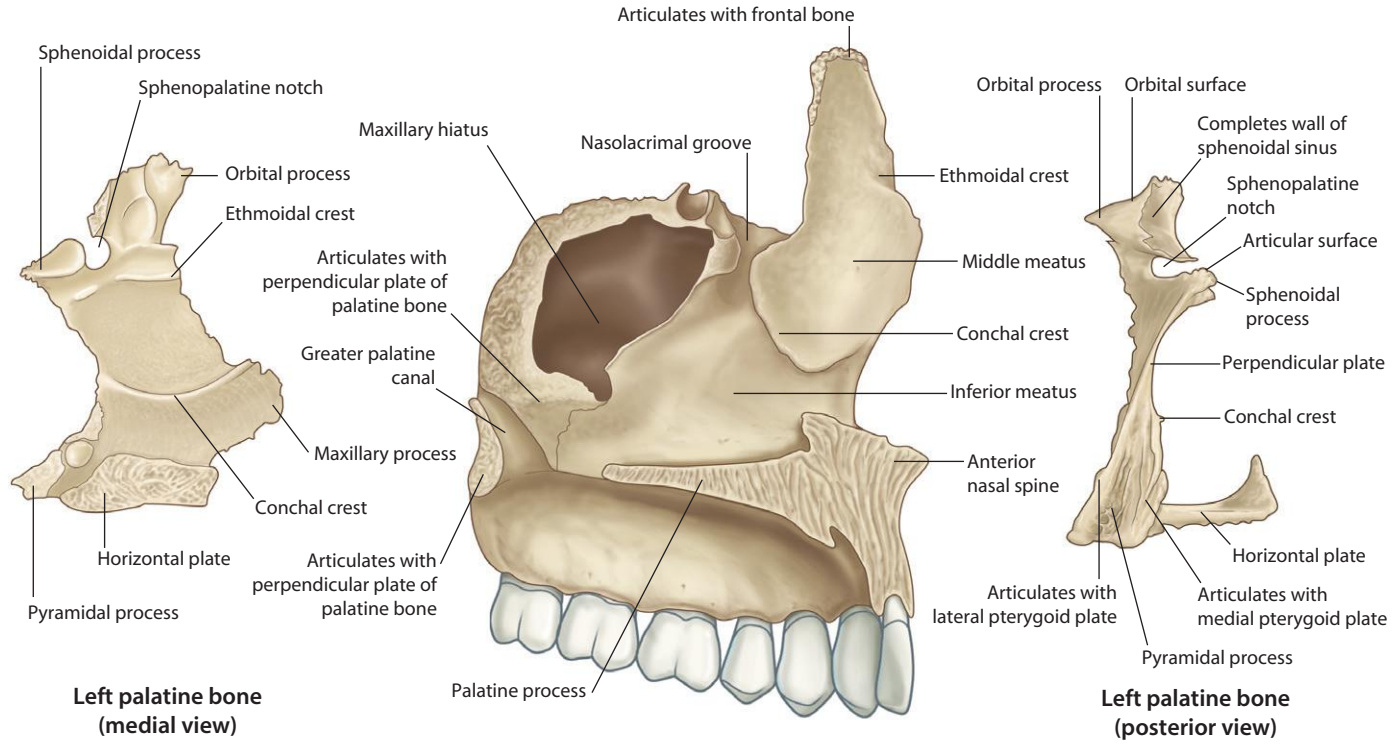

Left palatine bone (medial view)

Left maxilla bone (medial view)

Left palatine bone (posterior view)

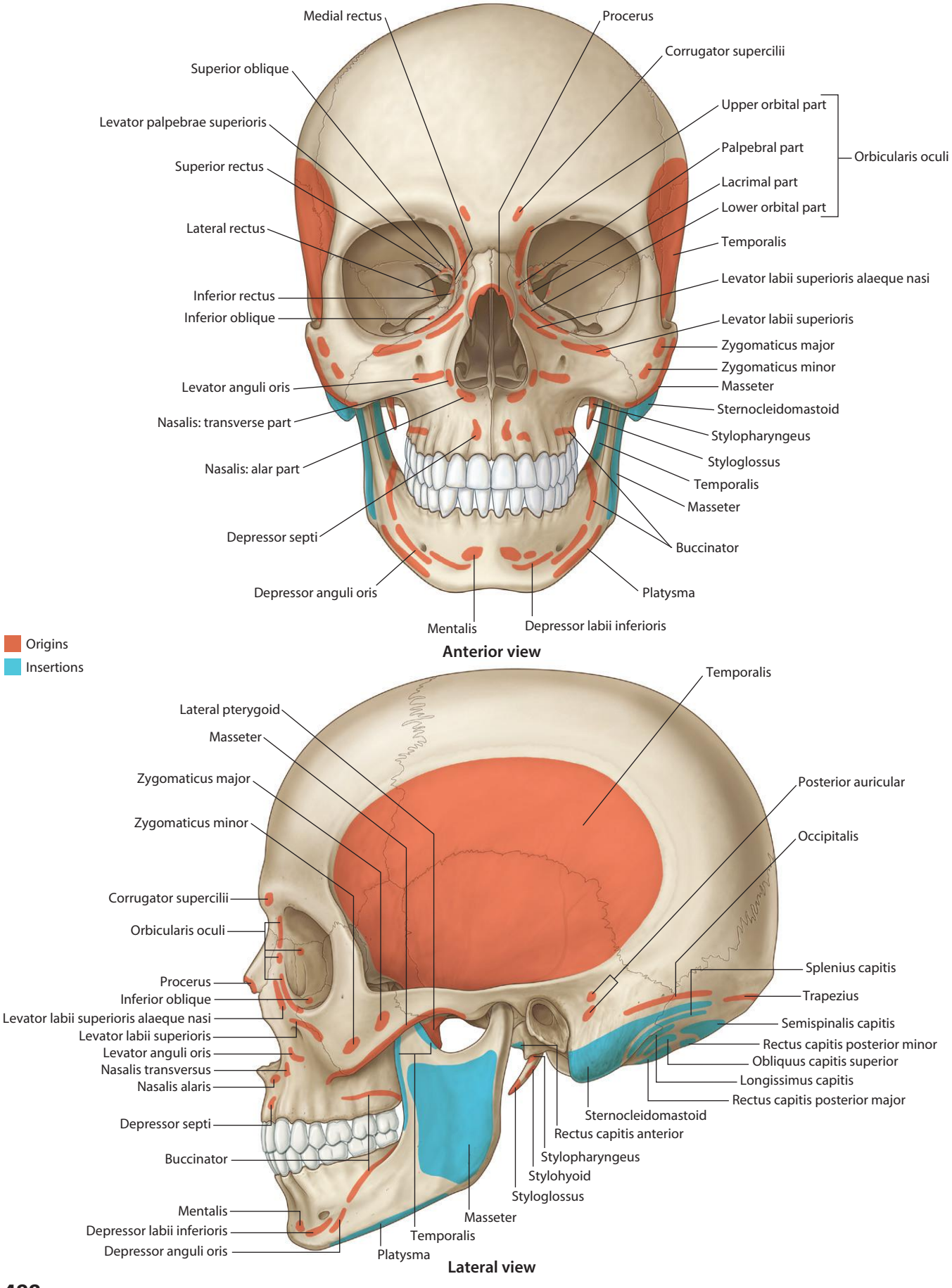
Medial rectus
Procerus
Corrugator supercilii
Superior oblique
Upper orbital part
Levator palpebrae superioris
Palpebral part
Orbicularis oculi
Superior rectus
Lacrimal part
Lower orbital part
Lateral rectus
Temporalis
Levator labii superioris alaeque nasi
Inferior rectus
Inferior oblique
Levator labii superioris
Zygomaticus major
Zygomaticus minor
Levator anguli oris
Masseter
Sternocleidomastoid
Nasalis: transverse part
Stylopharyngeus
Styloglossus
Nasalis: alar part
Temporalis
Masseter
Depressor septi
Buccinator
Depressor anguli oris
Platysma
Mentalis
Depressor labii inferioris
Origins
Insertions
Anterior view
Temporalis
Lateral pterygoid
Masseter
Posterior auricular
Zygomaticus major
Occipitalis
Zygomaticus minor
Corrugator supercilii
Orbicularis oculi
Splenius capitis
Procerus
Trapezius
Inferior oblique
Semispinalis capitis
Levator labii superioris alaeque nasi
Rectus capitis posterior minor
Levator labii superioris
Obliquus capitis superior
Levator anguli oris
Longissimus capitis
Nasalis transversus
Rectus capitis posterior major
Nasalis alaris
Sternocleidomastoid
Depressor septi
Rectus capitis anterior
Stylopharyngeus
Buccinator
Stylohyoid
Styloglossus
Mentalis
Masseter
Depressor labii inferioris
Temporalis
Depressor anguli oris
Platysma
Lateral view

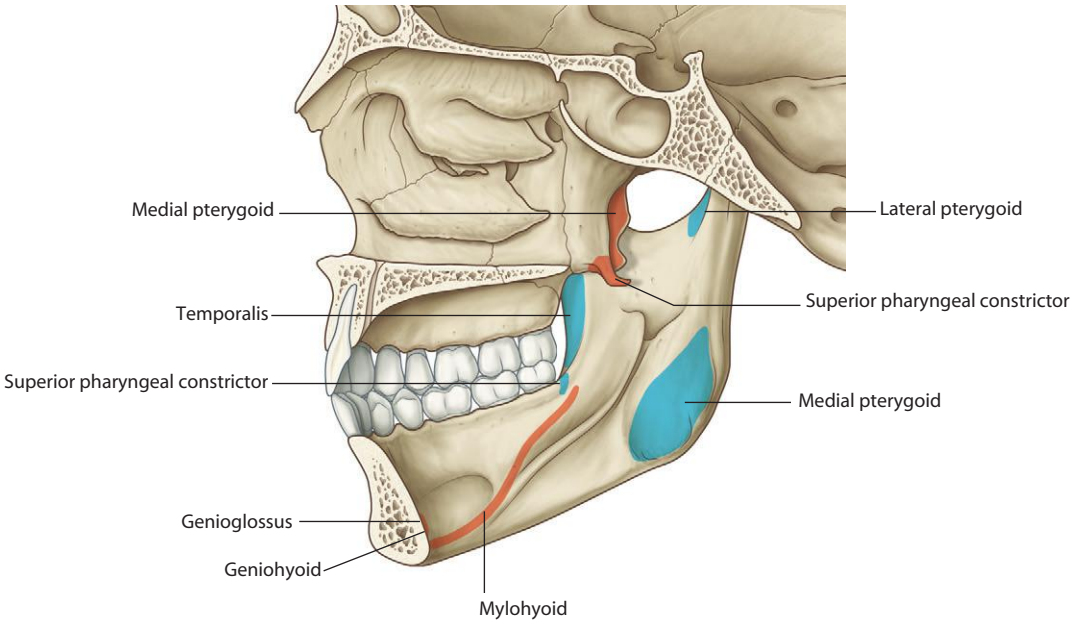

Medial view

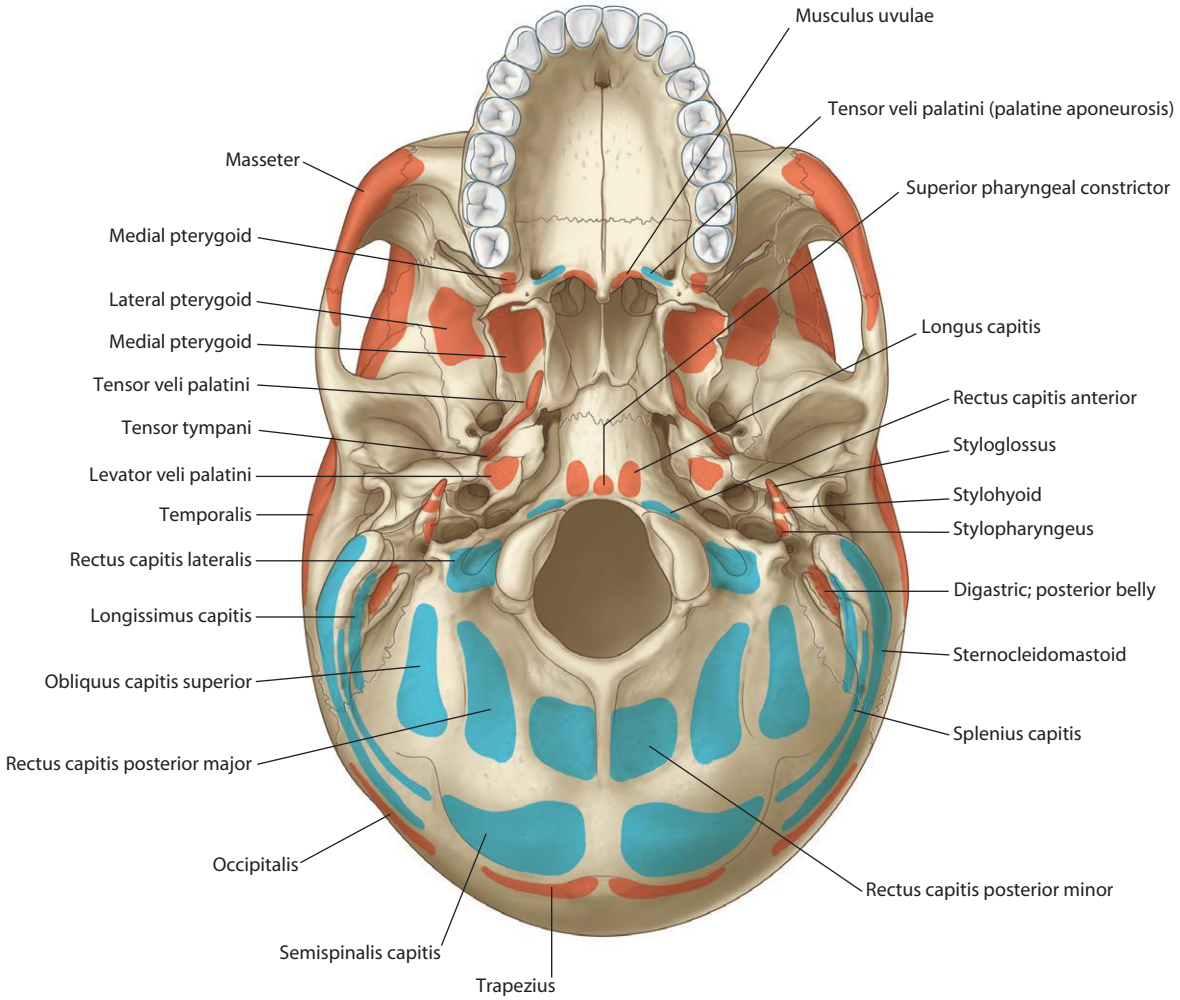

Inferior view

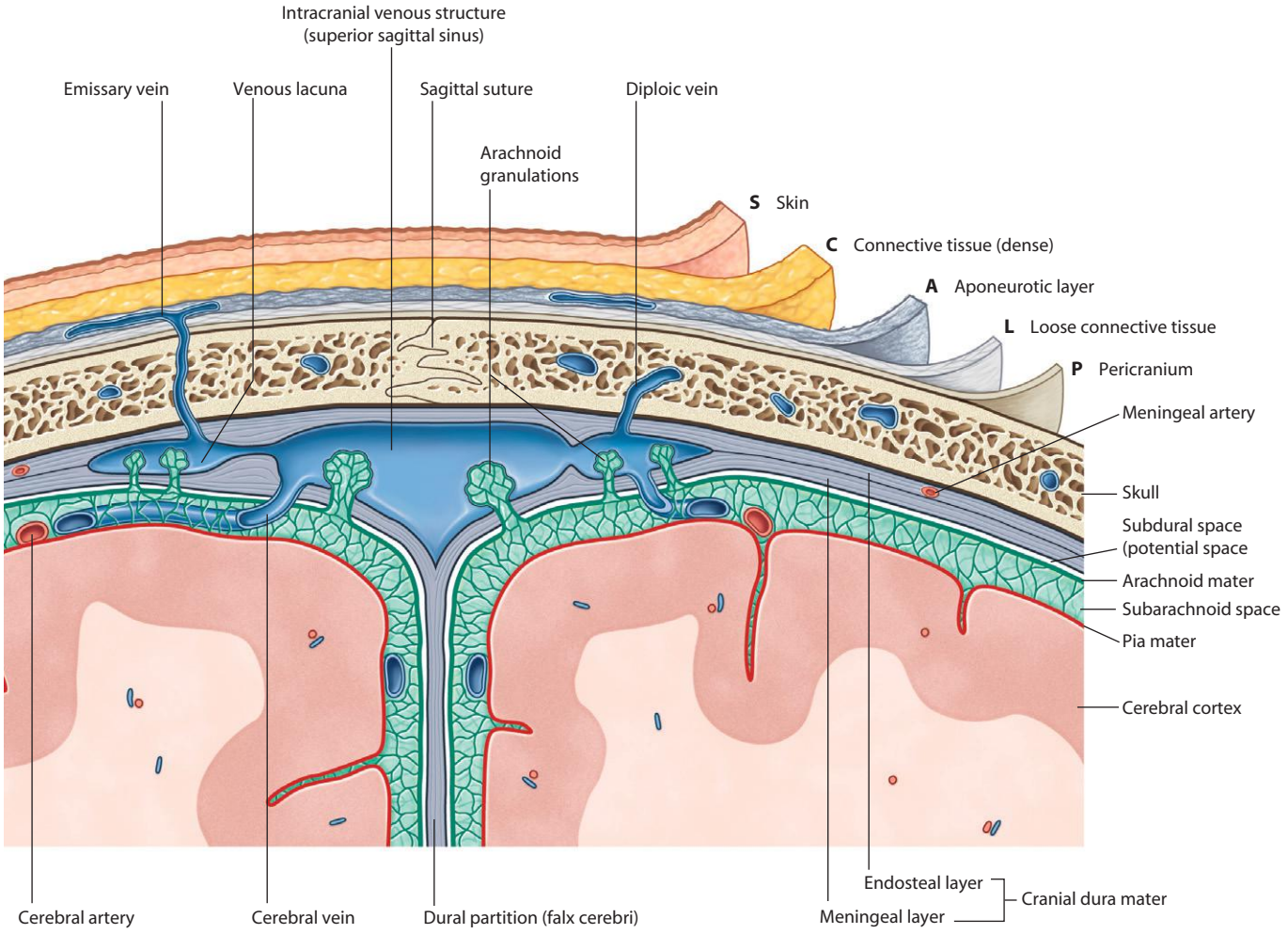

Scalp and cranial meninges

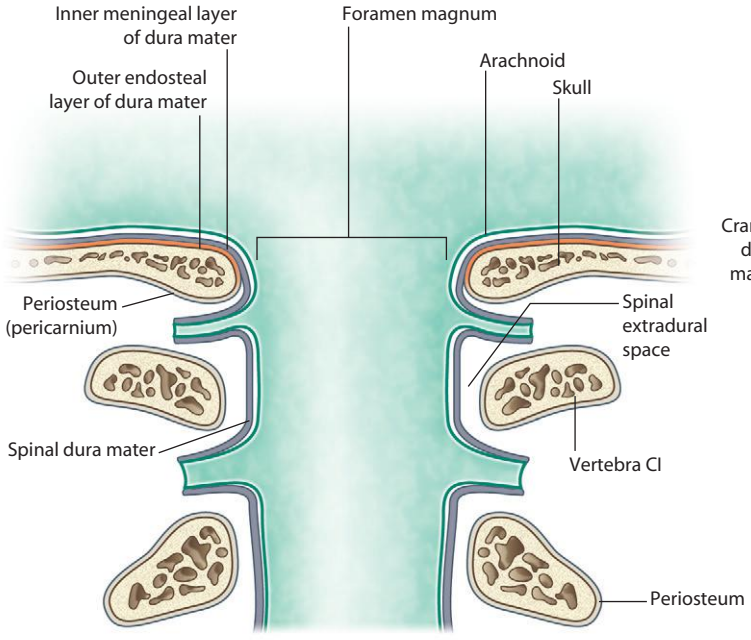

Continuity of cranial meninges with spinal meninges

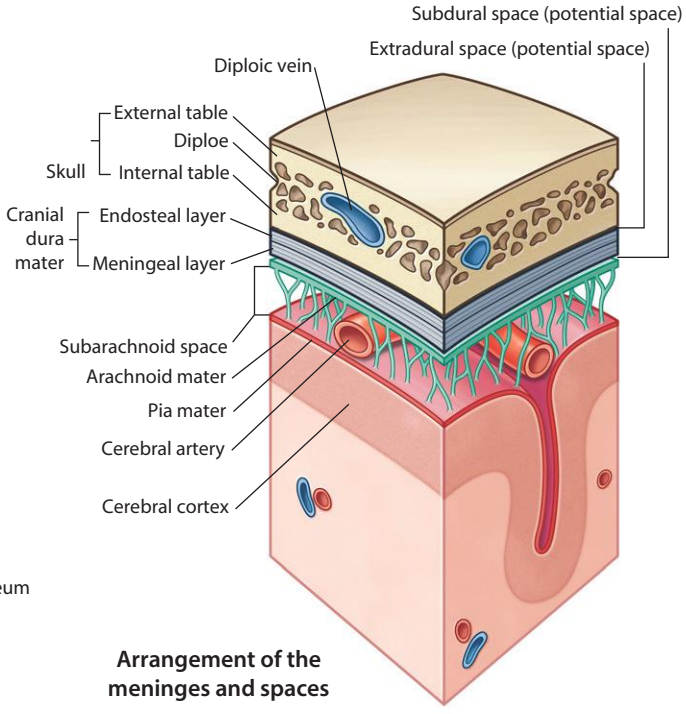

Arrangement of the meninges and spaces

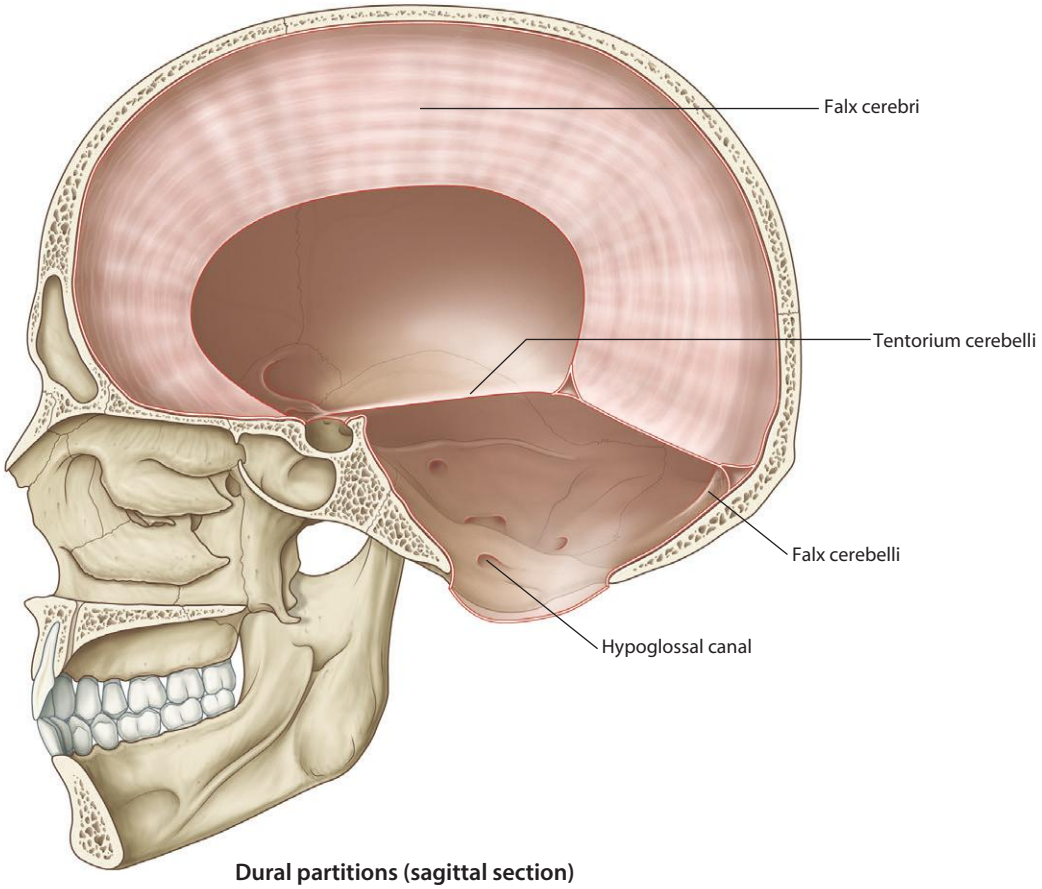

Dural partitions (sagittal section)

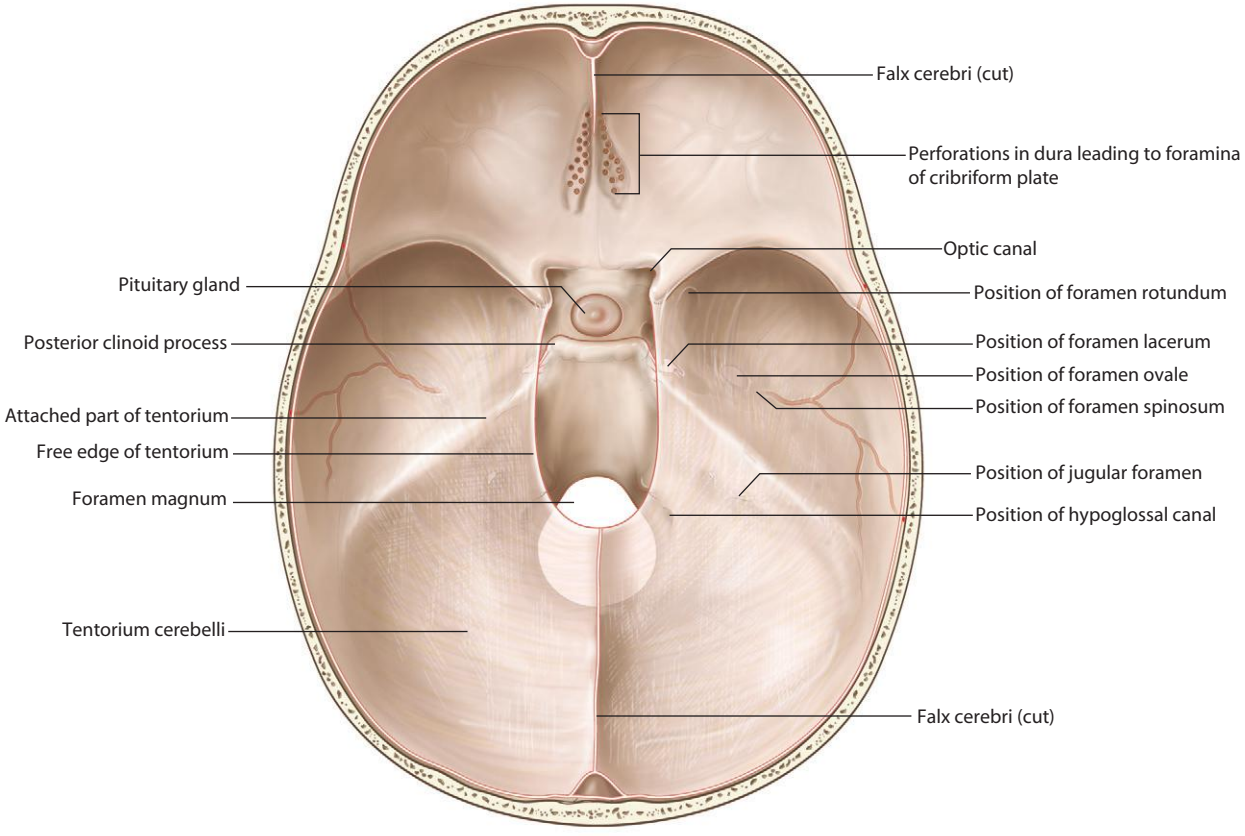

Cranial cavity (superior view)

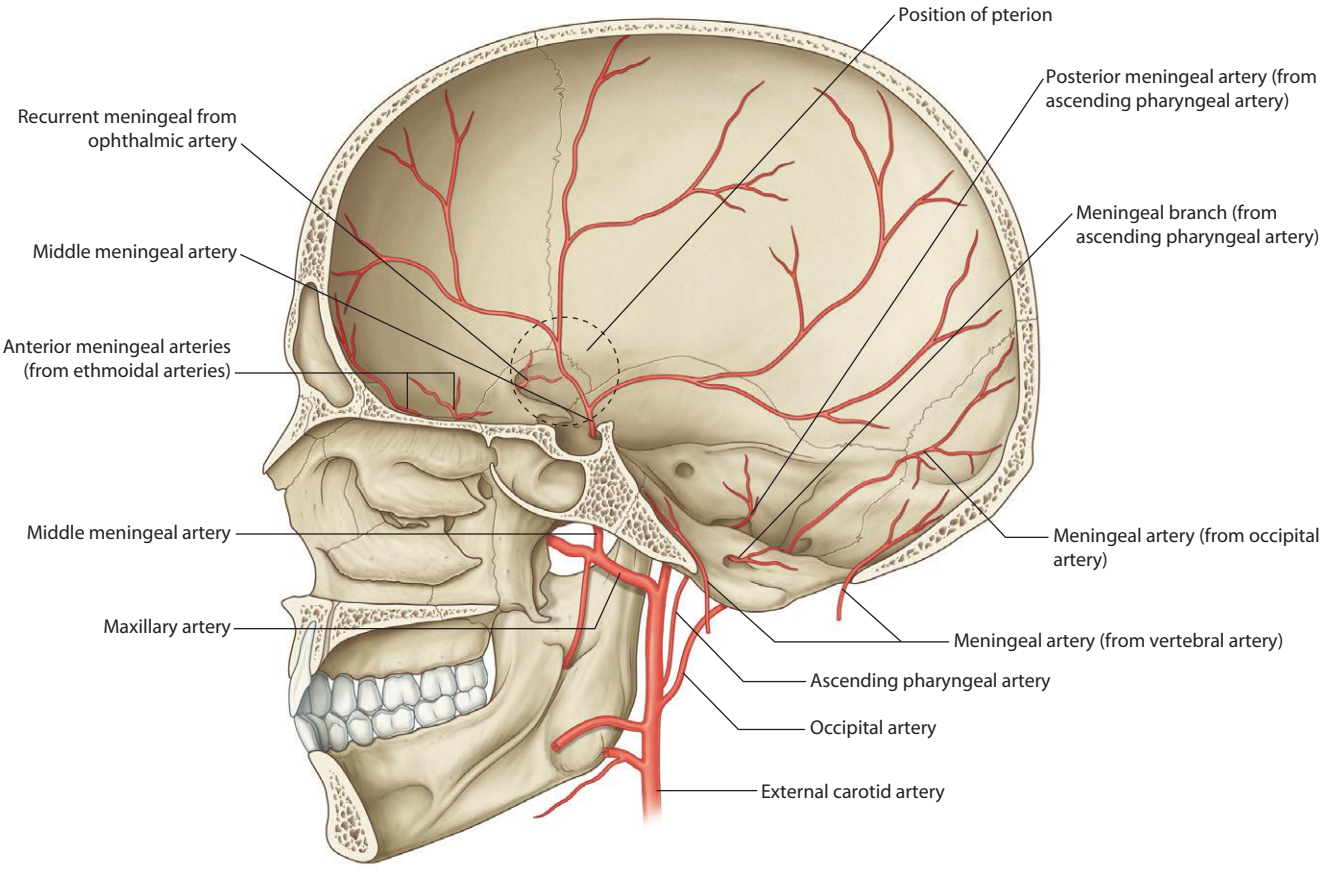

Dural arterial supply (medial view)

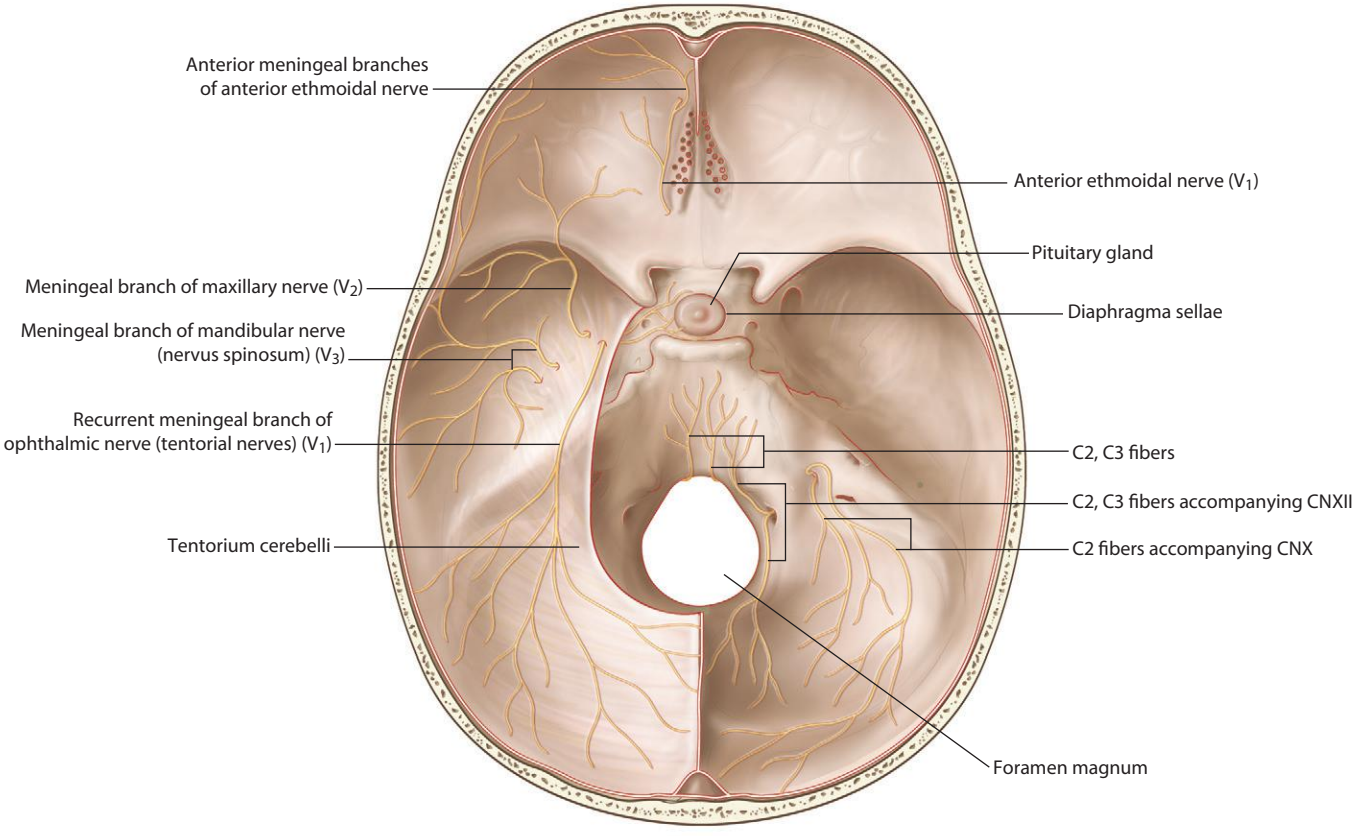

Dural innervation (superior view)

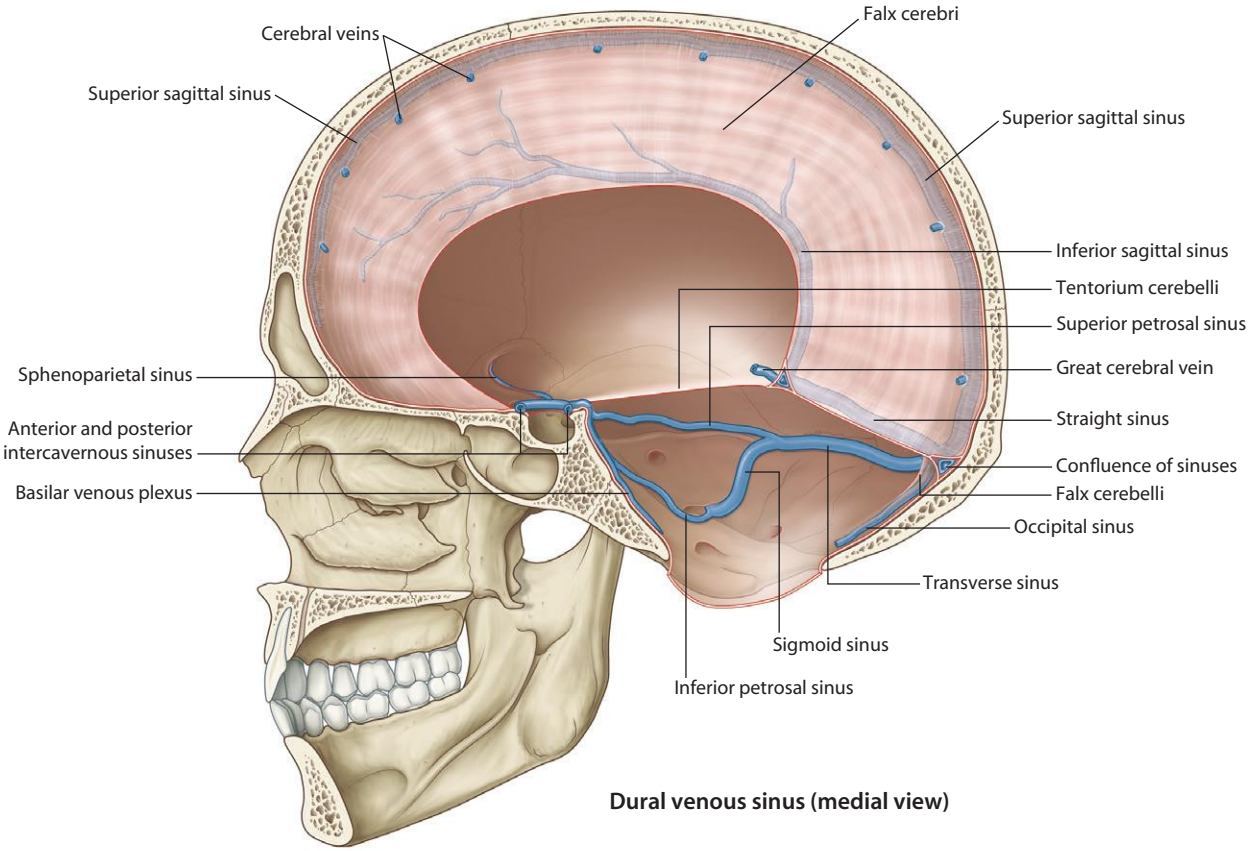

Dural venous sinus (medial view)

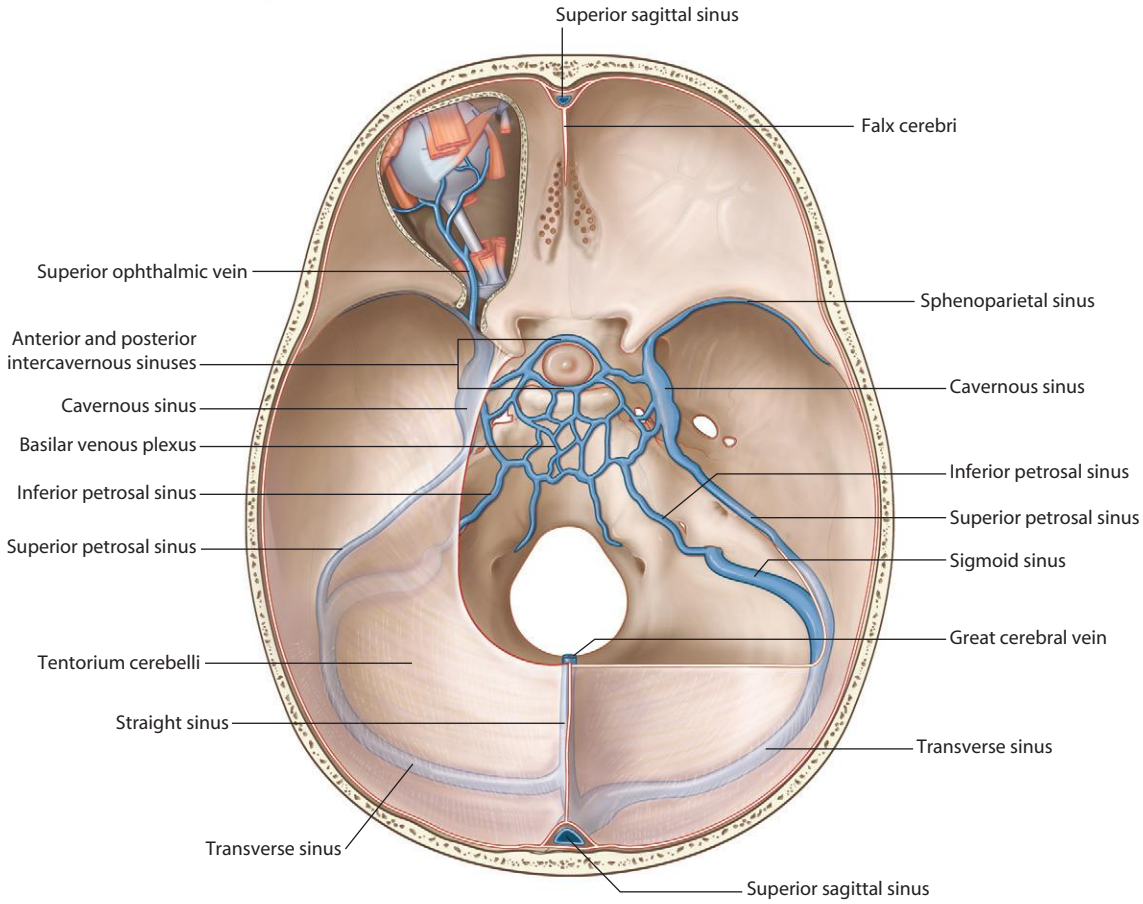

Superior view

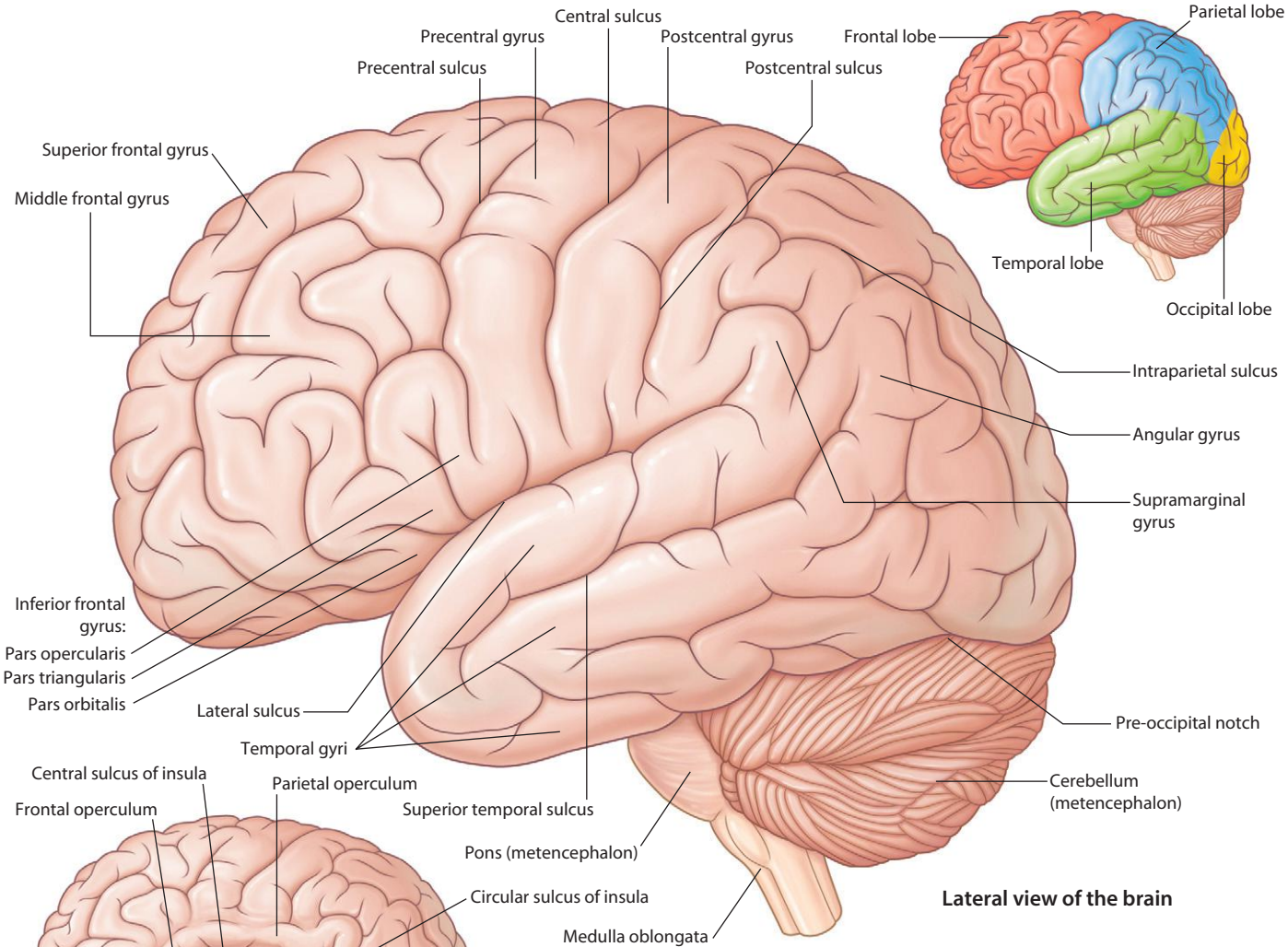

Lateral view of the brain

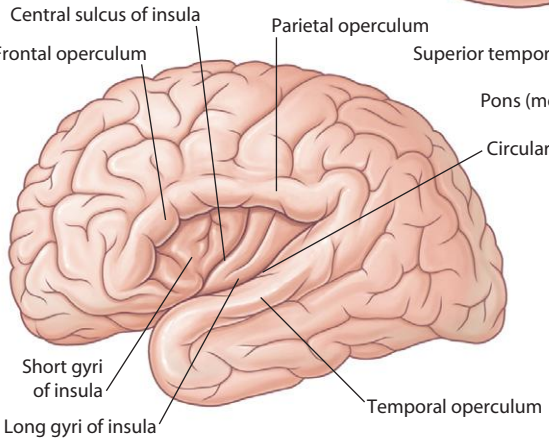

Insula exposed by retracting opercula

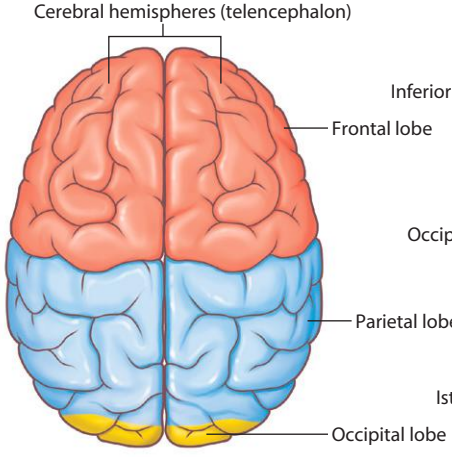

Superior view

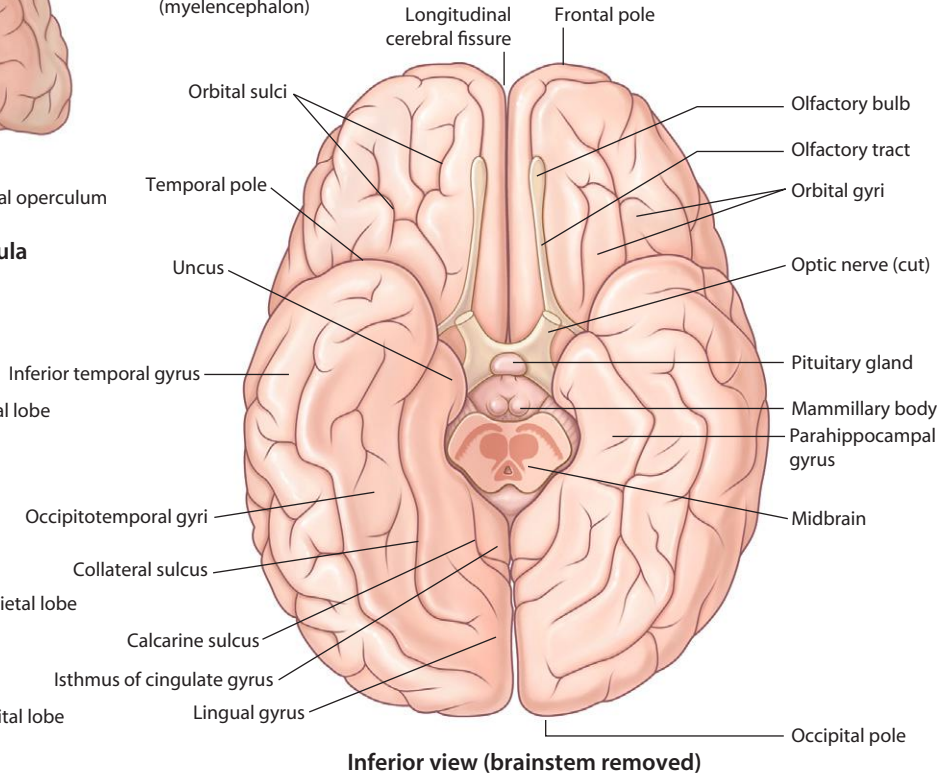

Inferior view (brainstem removed)

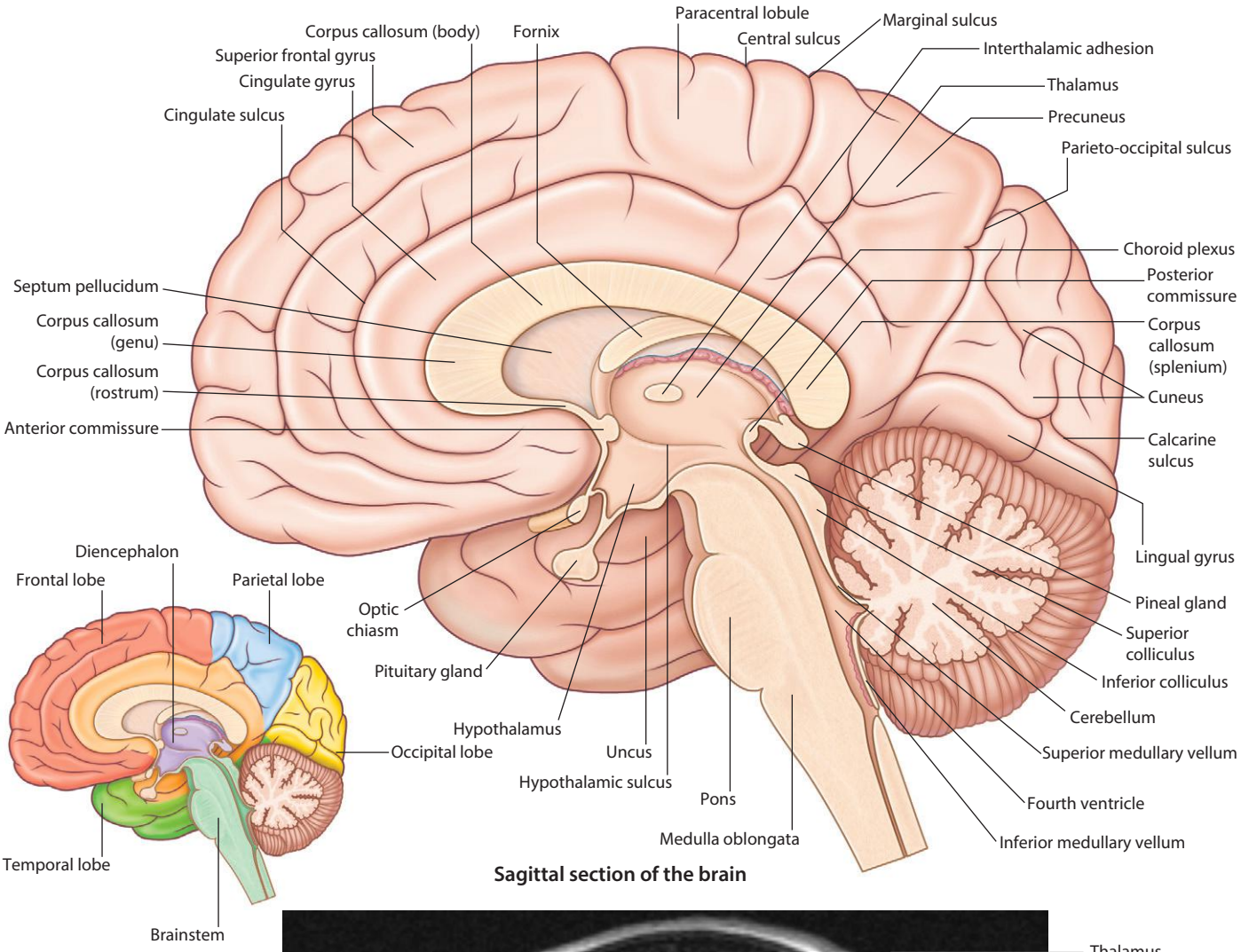

Sagittal section of the brain

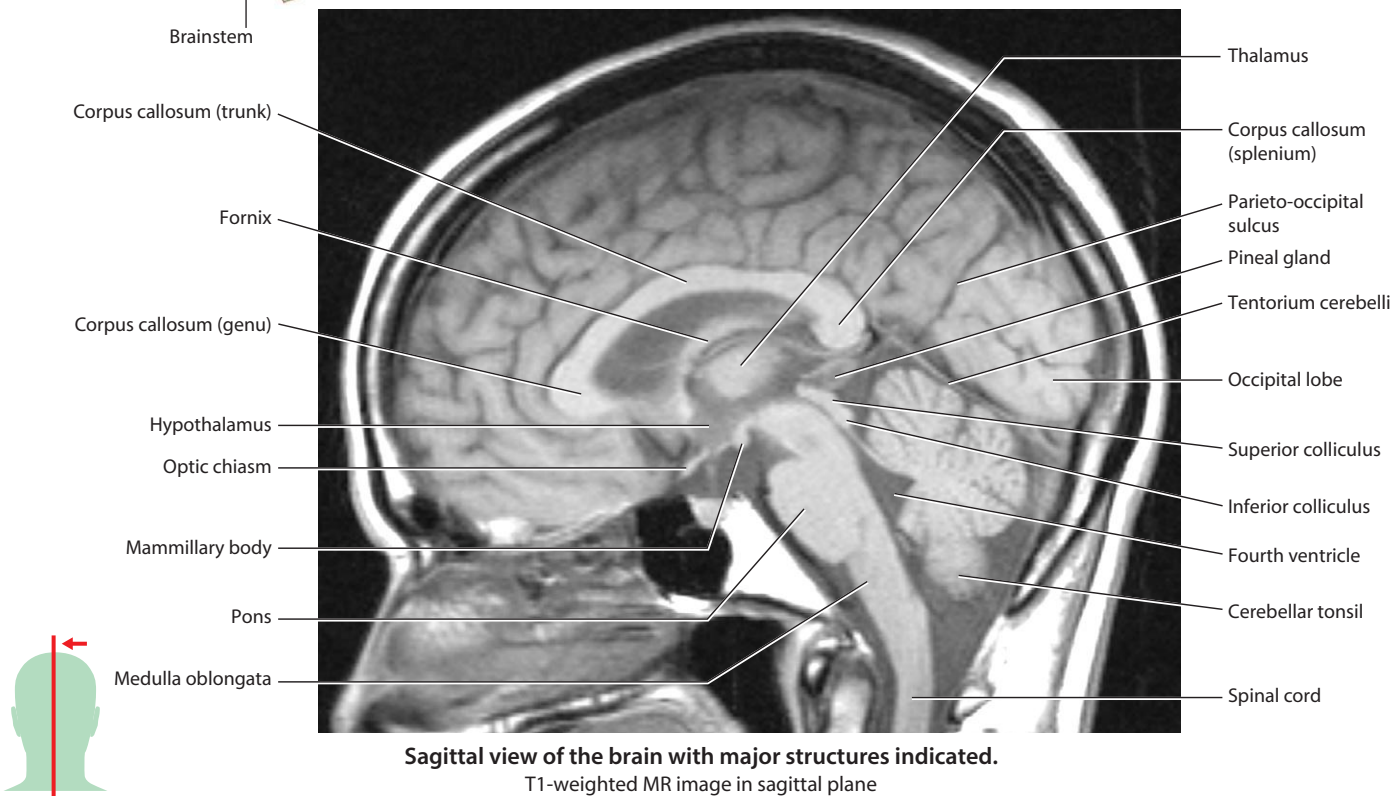

Sagittal view of the brain with major structures indicated.
T1-weighted MR image in sagittal plane

Axial or horizontal sections through the brain with major structures indicated.
A. Section showing structures related to the internal capsule.
B. Section showing structures related to the midbrain.
T1-weighted MR images in axial plane

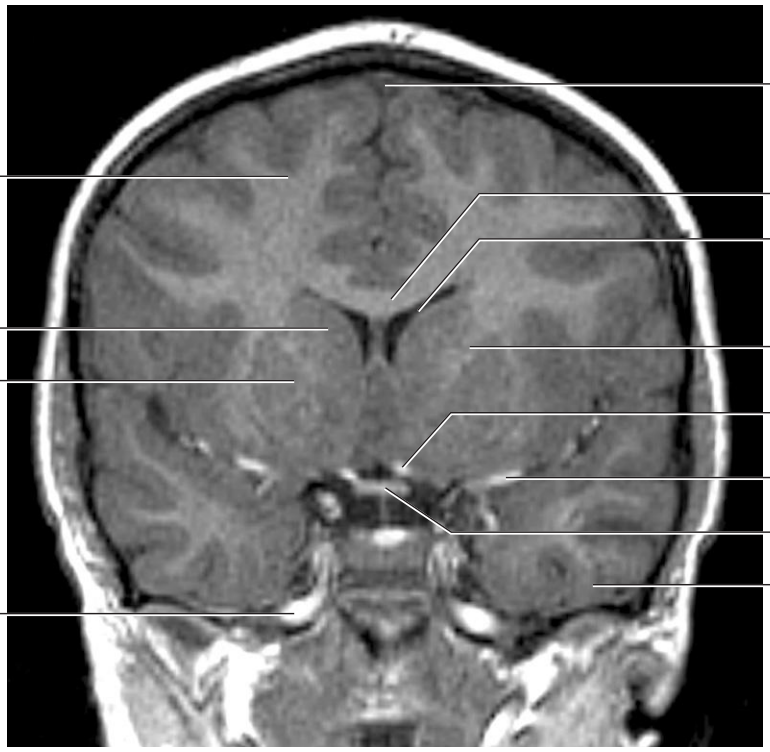

Superior sagittal sinus
Frontal lobe
Corpus callosum (body)
Lateral ventricle (anterior horn)
Caudate nucleus (head)
Internal capsule (anterior limb)
Putamen
Anterior cerebral artery
Middle cerebral artery
Optic chiasm
Temporal lobe
Internal carotid artery

A

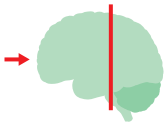

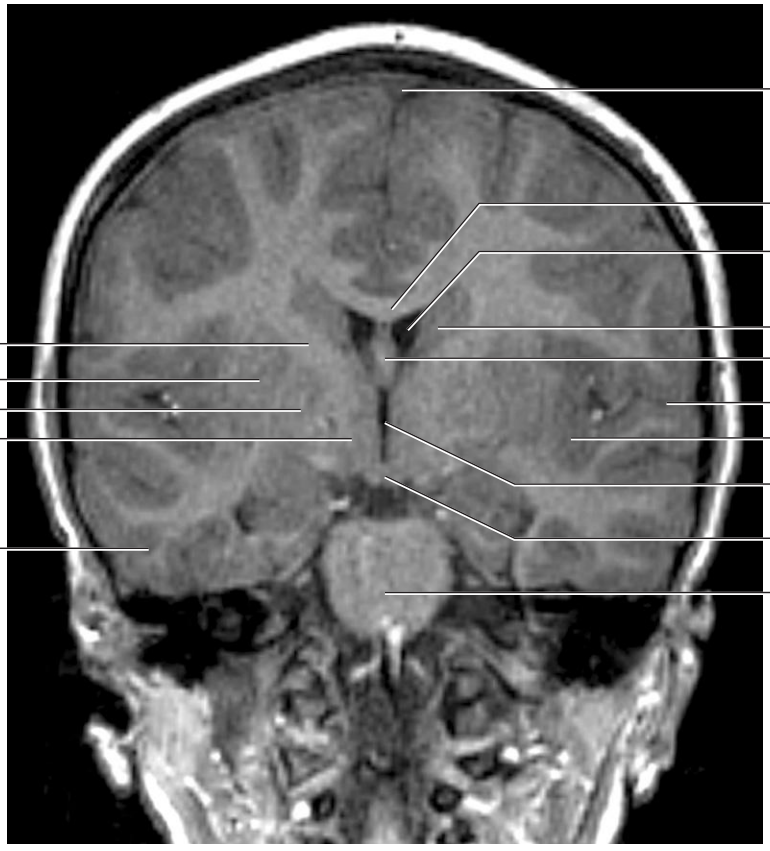

Superior sagittal sinus
Corpus callosum (body)
Lateral ventricle (body)
Caudate nucleus (body)
Internal capsule
Fornix
Putamen
Lateral sulcus (sylvian fissure)
Globus pallidus
Insula
Thalamus
Third ventricle
Hypothalamus
Temporal lobe
Pons

B

Coronal sections through the brain with major structures indicated.
A. Section showing structures related to the optic chiasm.
B. Section showing structures related to the third ventricle.
T1-weighted MR images in coronal plane

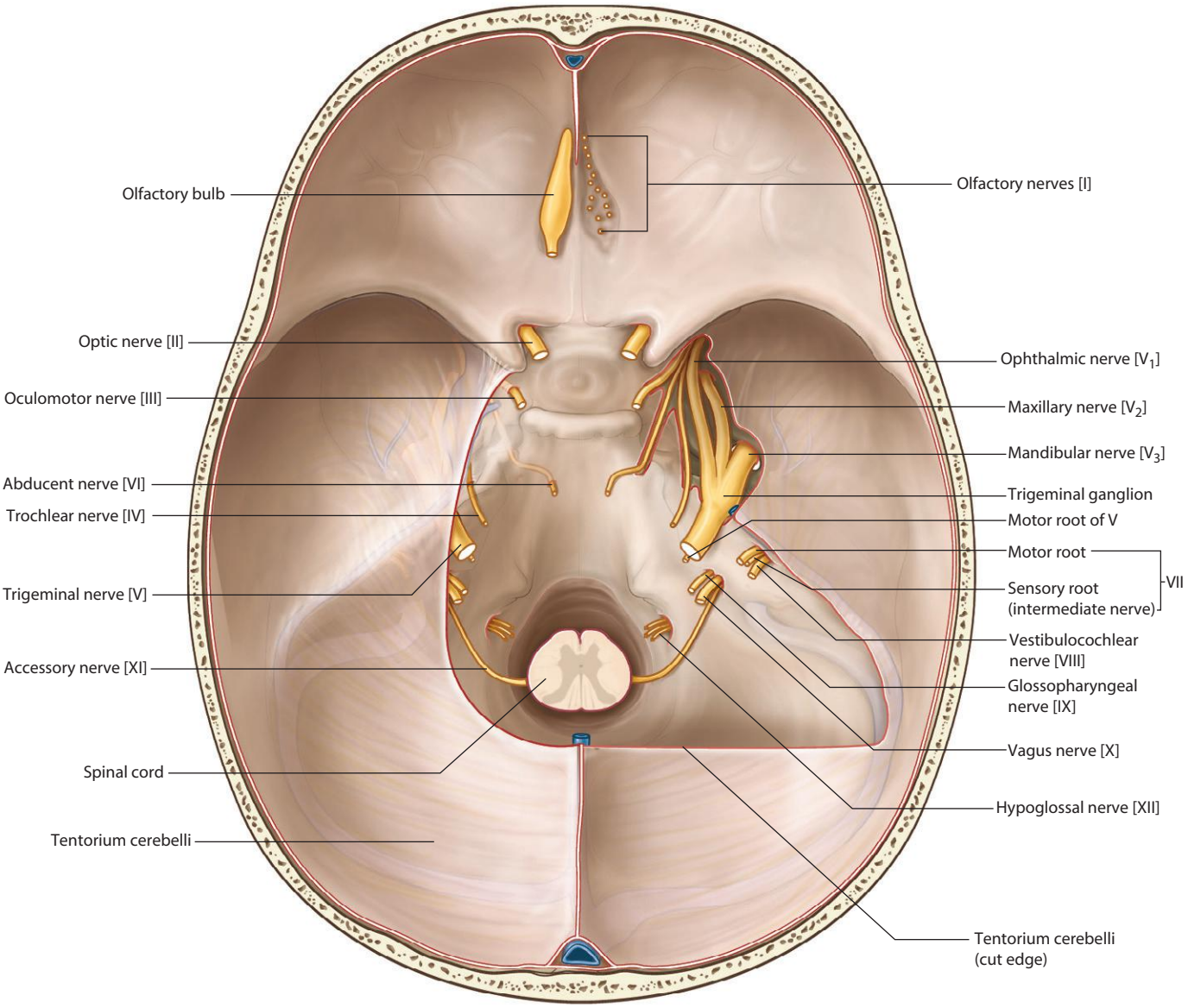
Olfactory bulb
Olfactory nerves [I]
Optic nerve [II]
Oculomotor nerve [III]
Abducent nerve [VI]
Trochlear nerve [IV]
Trigeminal nerve [V]
Accessory nerve [XI]
Spinal cord
Tentorium cerebelli
Ophthalmic nerve [V1]
Maxillary nerve [V2]
Mandibular nerve [V3]
Trigeminal ganglion
Motor root of V
Motor root
Sensory root (intermediate nerve)
VII
Vestibulocochlear nerve [VIII]
Glossopharyngeal nerve [IX]
Vagus nerve [X]
Hypoglossal nerve [XII]
Tentorium cerebelli (cut edge)

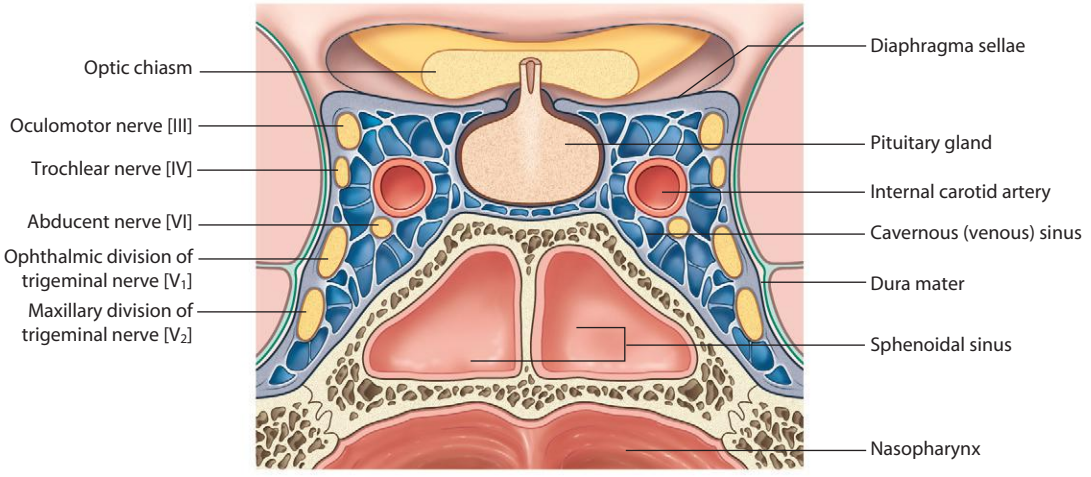
Optic chiasm
Oculomotor nerve [III]
Trochlear nerve [IV]
Abducent nerve [VI]
Ophthalmic division of trigeminal nerve [V1]
Maxillary division of trigeminal nerve [V2]
Diaphragma sellae
Pituitary gland
Internal carotid artery
Cavernous (venous) sinus
Dura mater
Sphenoidal sinus
Nasopharynx

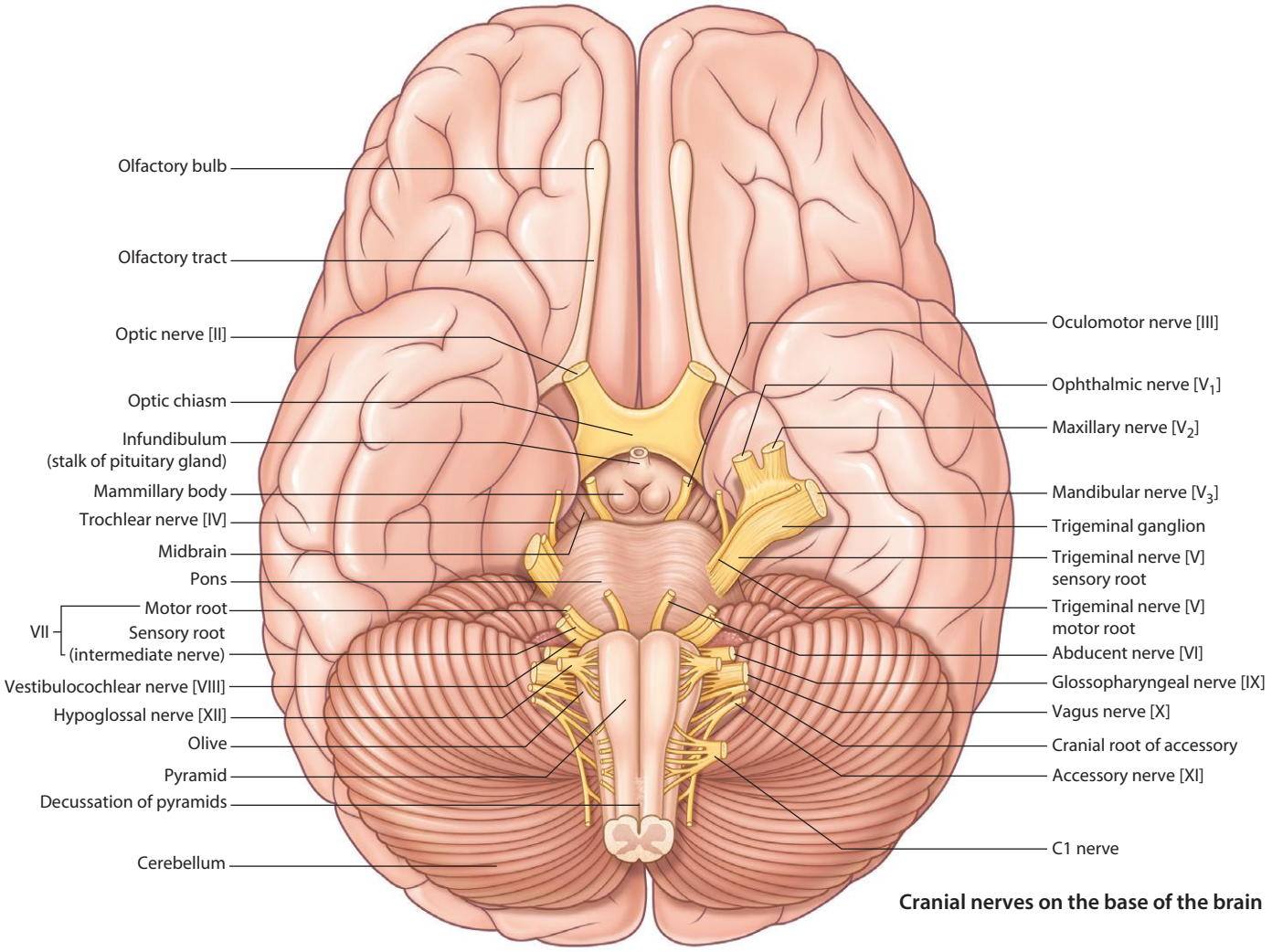

Cranial nerves on the base of the brain

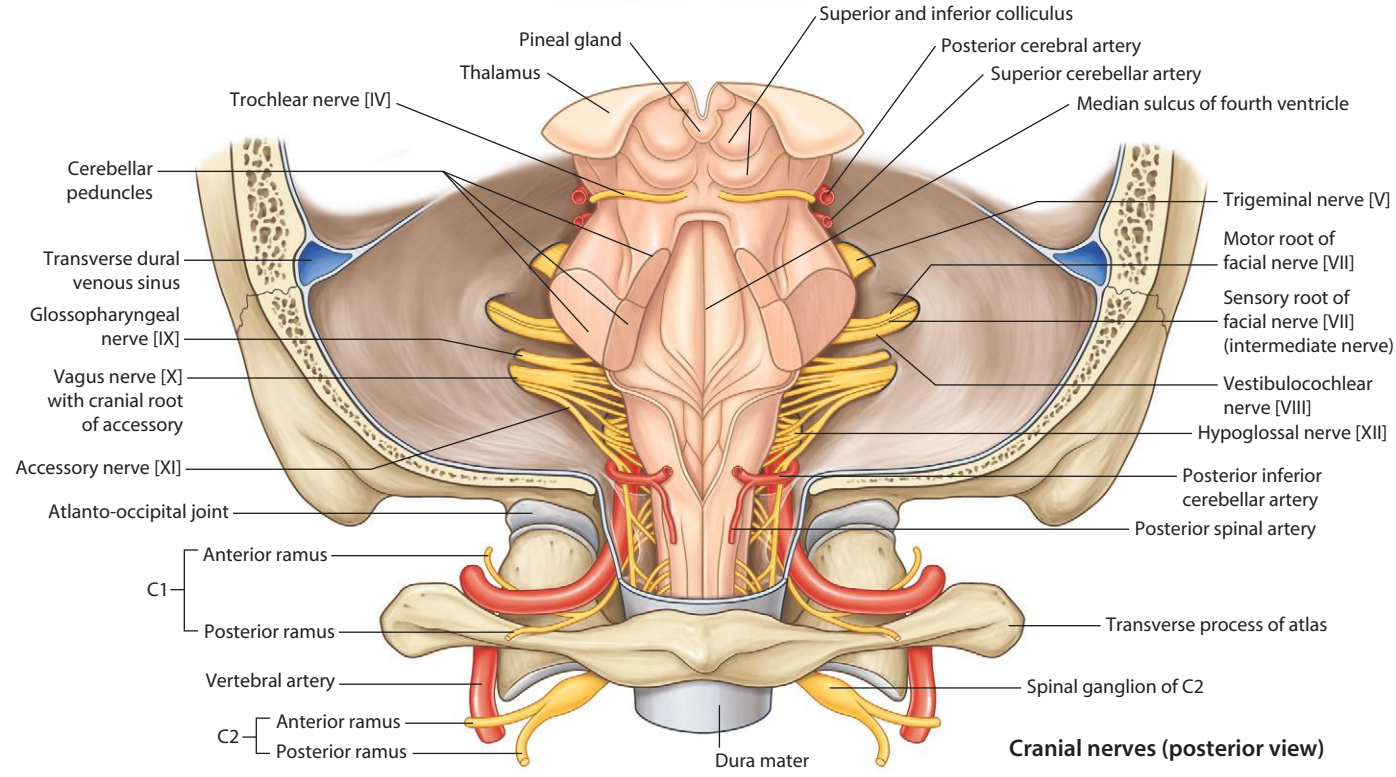

Cranial nerves (posterior view)

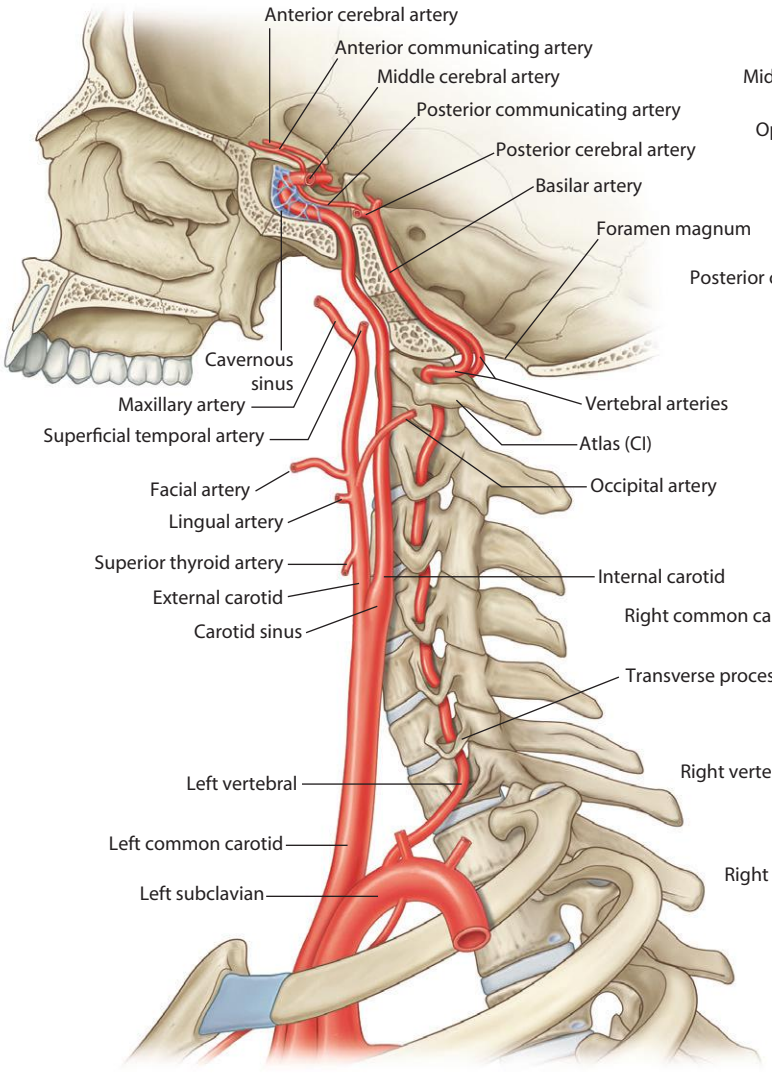

Arteries to brain (lateral view)

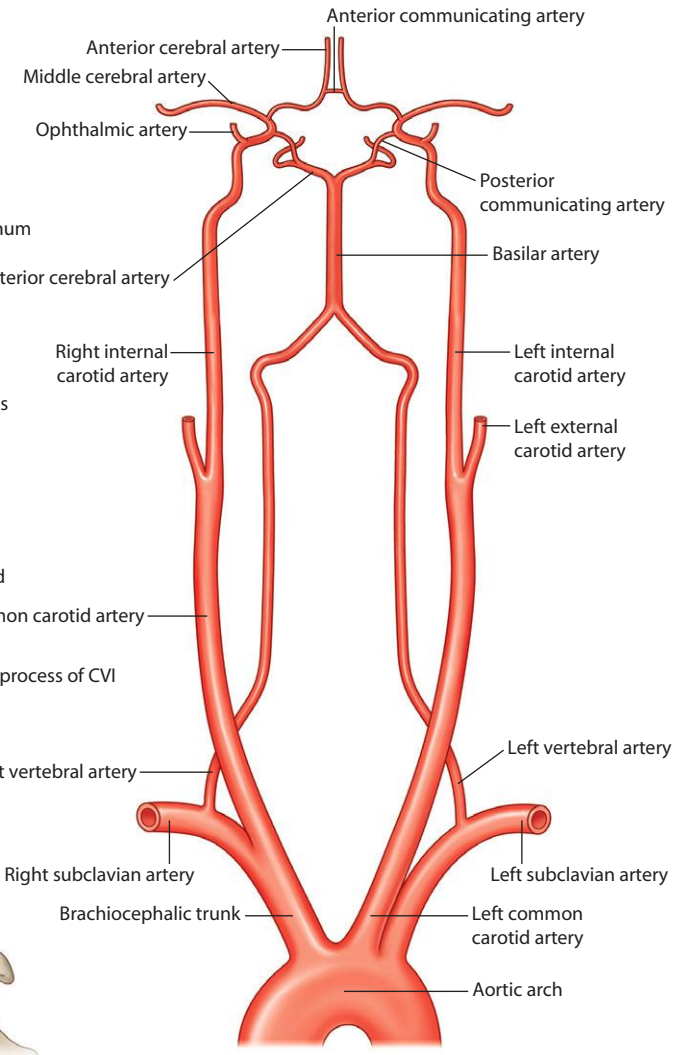

Diagram showing blood supply to brain

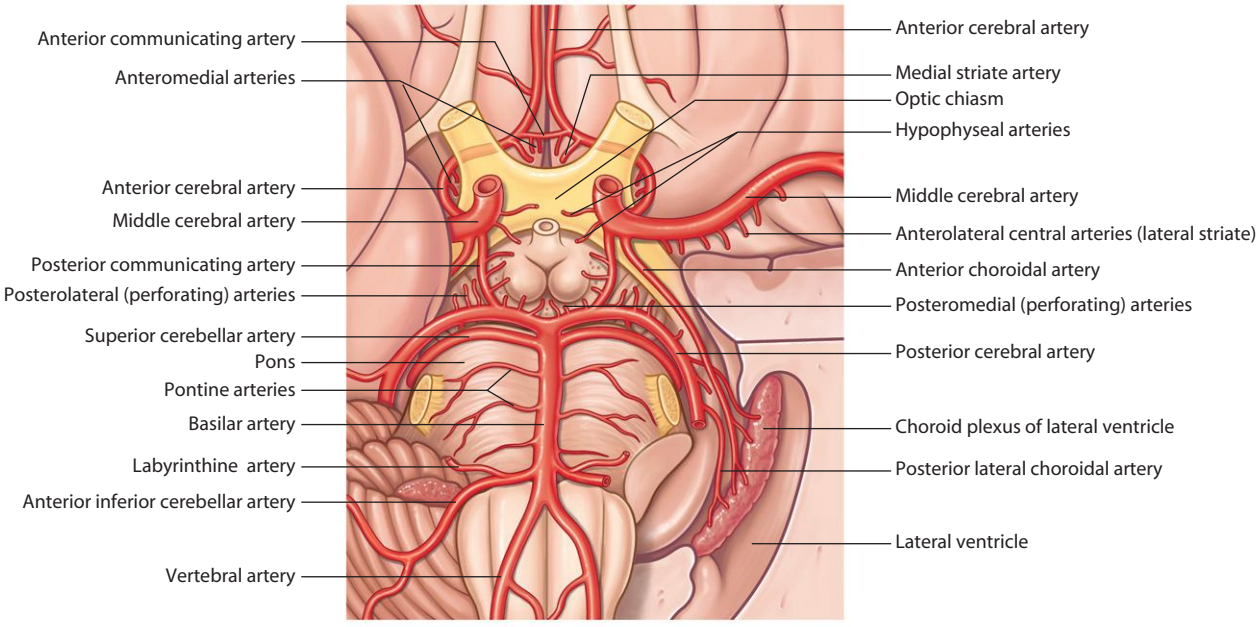

Cerebral arterial circle (of Willis)

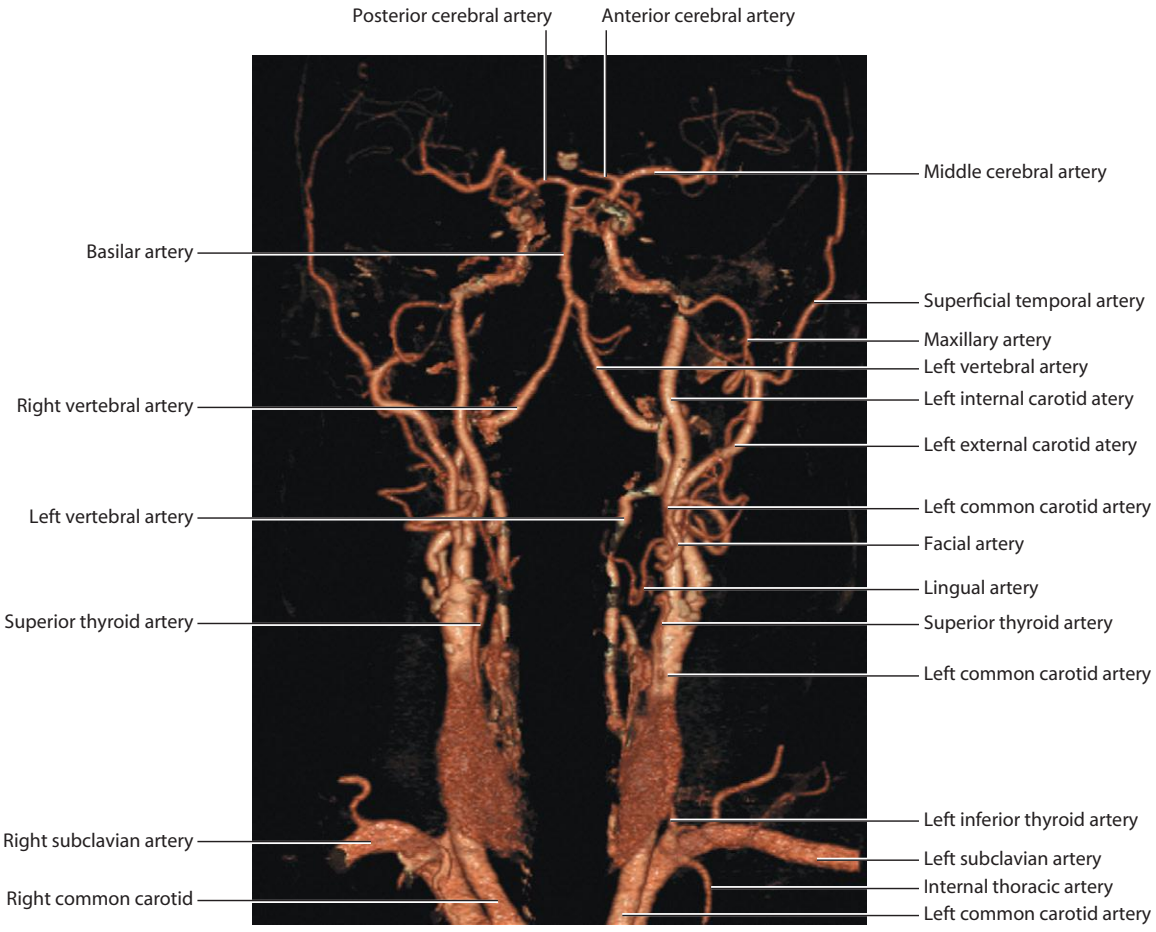

Anterior view of the carotid and vertebral arterial systems.
Volume-rendered anterior view using multidetector computed tomography

Posterior view of the cerebral arterial circle (of Willis).
Volume-rendered posterior view using multidetector computed tomography

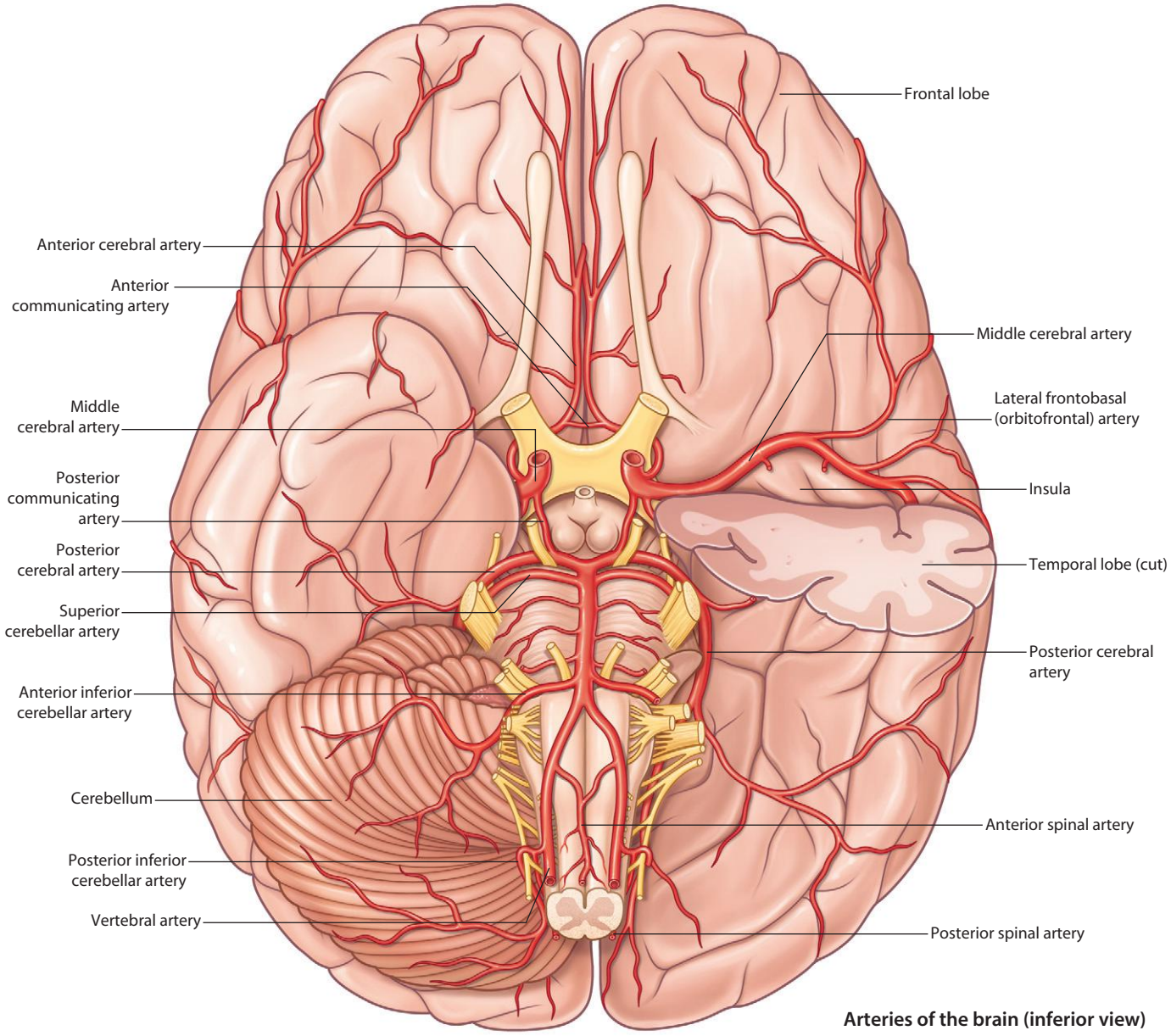

Arteries of the brain (inferior view)

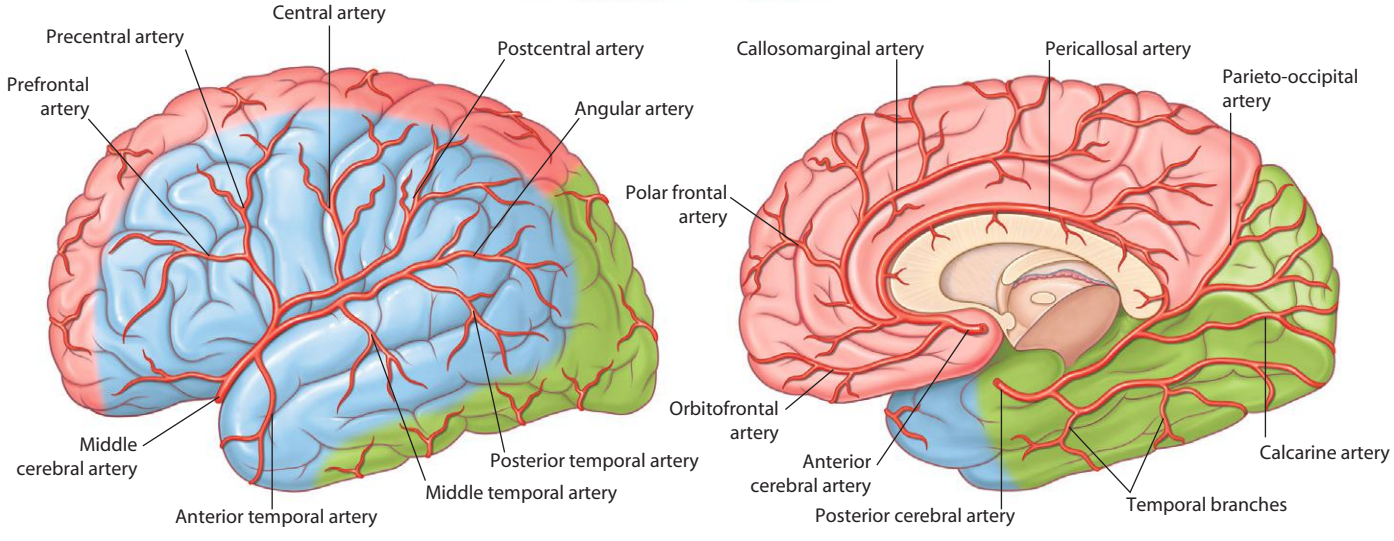

Lateral view

Blood supply to the cerebral hemispheres.
Anterior cerebral artery (pink), middle cerebral artery (blue), posterior cerebral artery (green)

Medial view

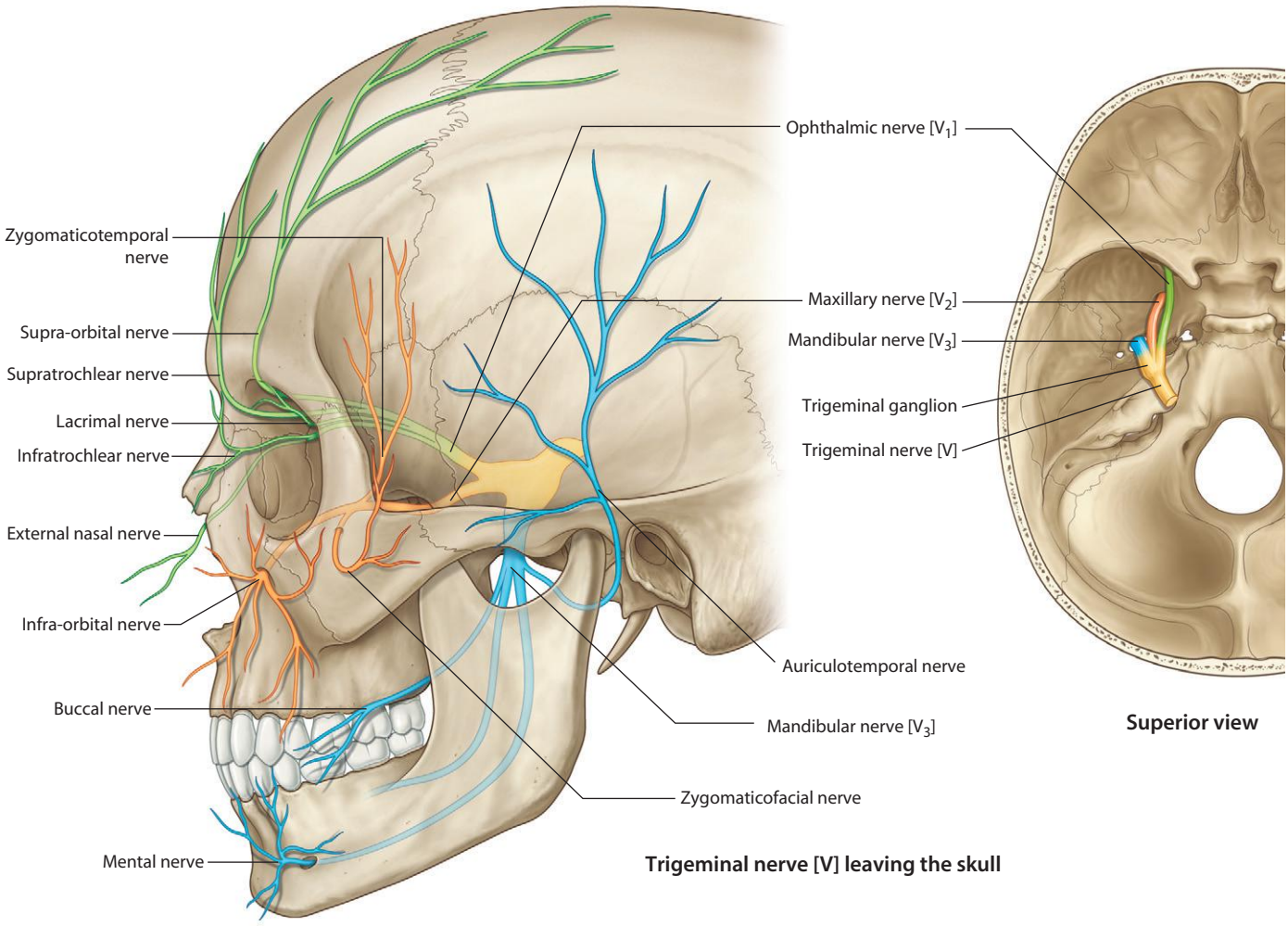

Trigeminal nerve [V] leaving the skull

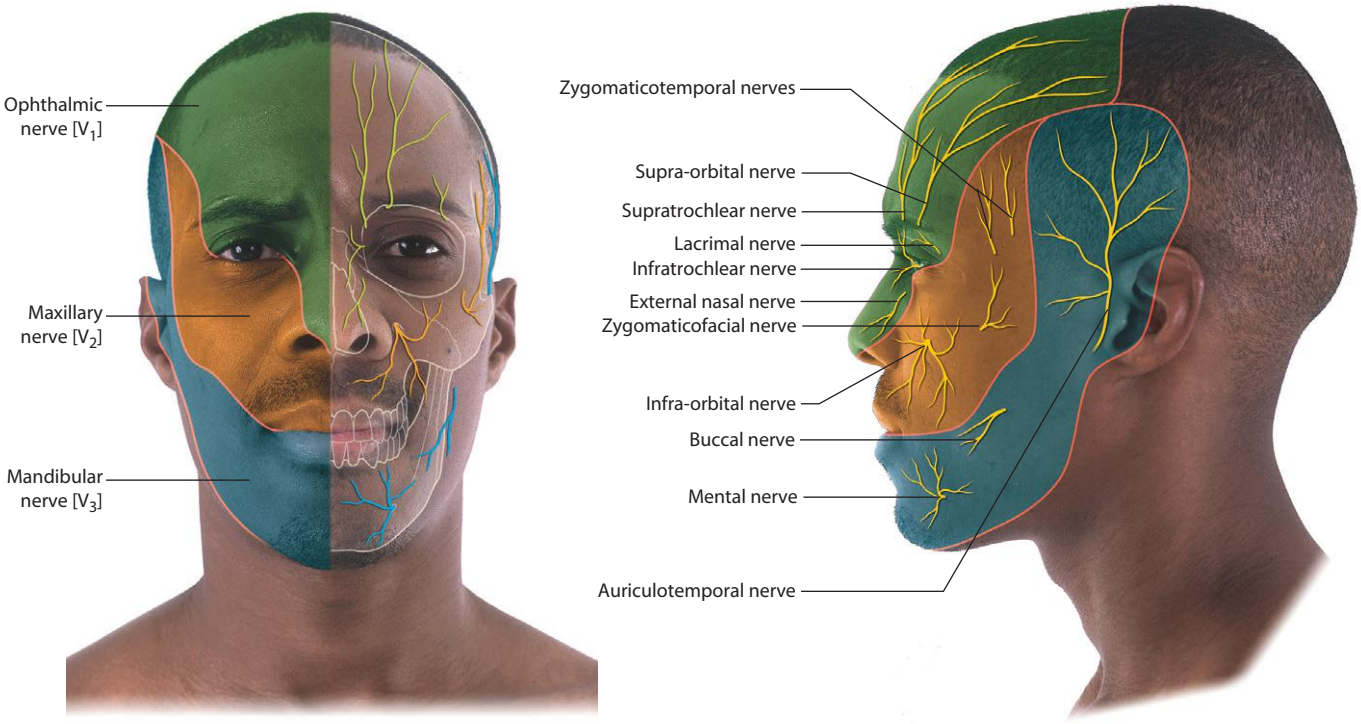

Cutaneous distribution of the trigeminal nerve [V]

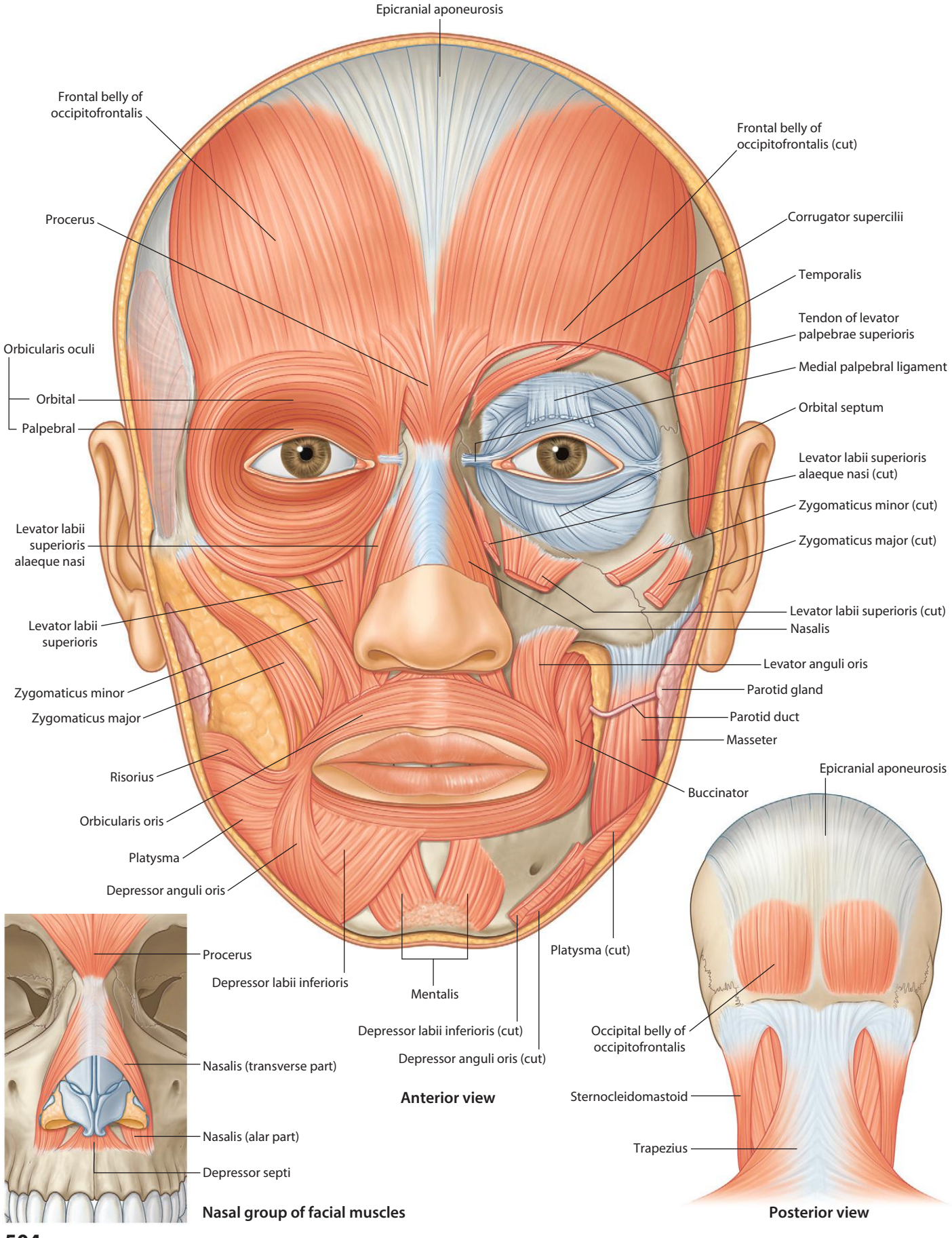
Epicranial aponeurosis
Frontal belly of occipitofrontalis
Frontal belly of occipitofrontalis (cut)
Procerus
Corrugator supercilii
Temporalis
Tendon of levator palpebrae superioris
Orbicularis oculi
Orbital
Palpebral
Medial palpebral ligament
Orbital septum
Levator labii superioris alaeque nasi (cut)
Zygomaticus minor (cut)
Levator labii superioris alaeque nasi
Zygomaticus major (cut)
Levator labii superioris (cut)
Nasalis
Levator labii superioris
Levator anguli oris
Zygomaticus minor
Parotid gland
Zygomaticus major
Parotid duct
Masseter
Risorius
Buccinator
Orbicularis oris
Platysma
Depressor anguli oris
Platysma (cut)
Procerus
Depressor labii inferioris
Mentalis
Depressor labii inferioris (cut)
Depressor anguli oris (cut)
Nasalis (transverse part)
Nasalis (alar part)
Depressor septi
Anterior view
Nasal group of facial muscles
Epicranial aponeurosis
Occipital belly of occipitofrontalis
Sternocleidomastoid
Trapezius
Posterior view

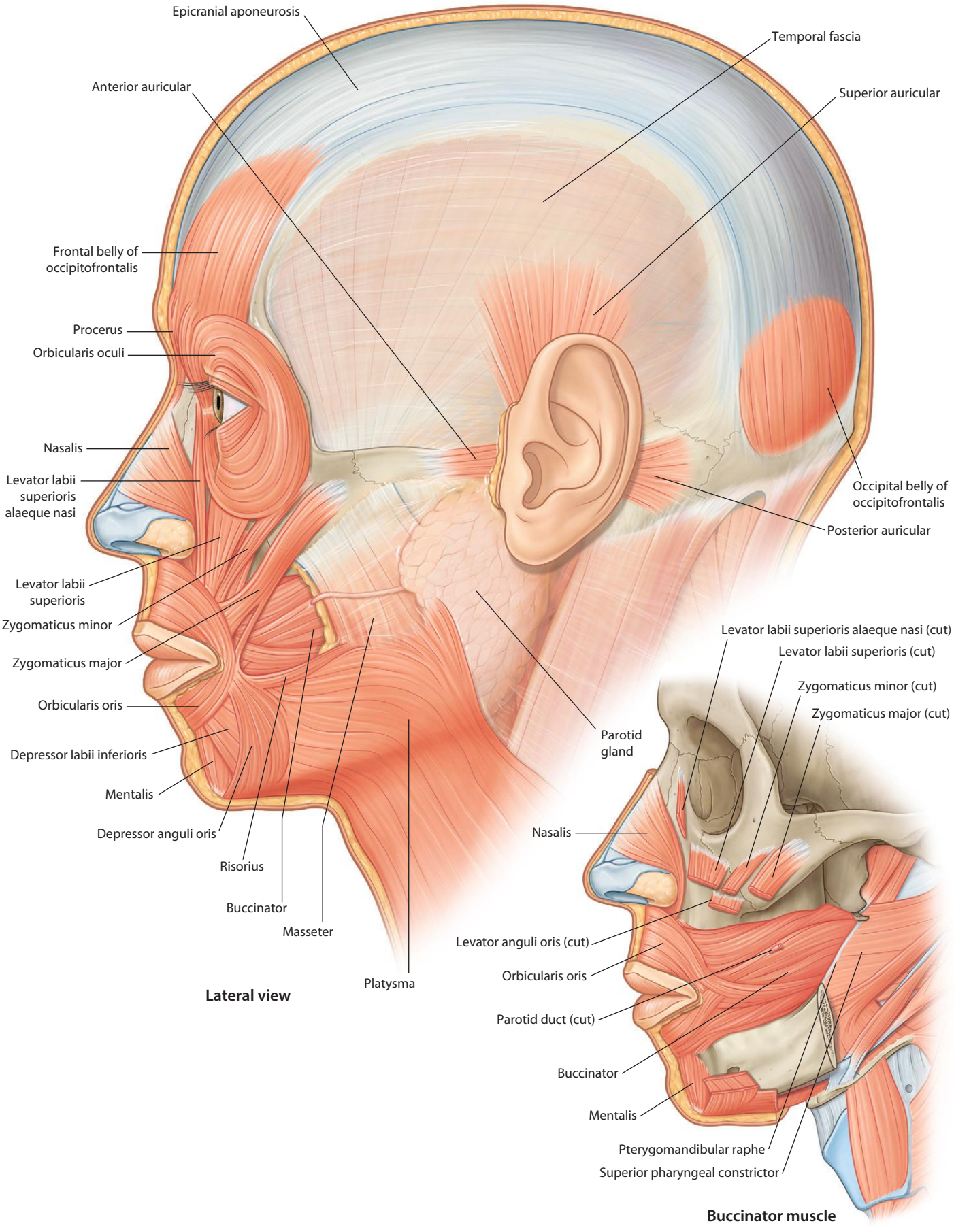
Epicranial aponeurosis
Temporal fascia
Anterior auricular
Superior auricular
Frontal belly of occipitofrontalis
Procerus
Orbicularis oculi
Nasalis
Levator labii superioris alaeque nasi
Occipital belly of occipitofrontalis
Posterior auricular
Levator labii superioris
Zygomaticus minor
Zygomaticus major
Orbicularis oris
Depressor labii inferioris
Mentalis
Depressor anguli oris
Risorius
Buccinator
Masseter
Platysma
Parotid gland
Lateral view
Levator labii superioris alaeque nasi (cut)
Levator labii superioris (cut)
Zygomaticus minor (cut)
Zygomaticus major (cut)
Nasalis
Levator anguli oris (cut)
Orbicularis oris
Parotid duct (cut)
Buccinator
Mentalis
Pterygomandibular raphe
Superior pharyngeal constrictor
Buccinator muscle

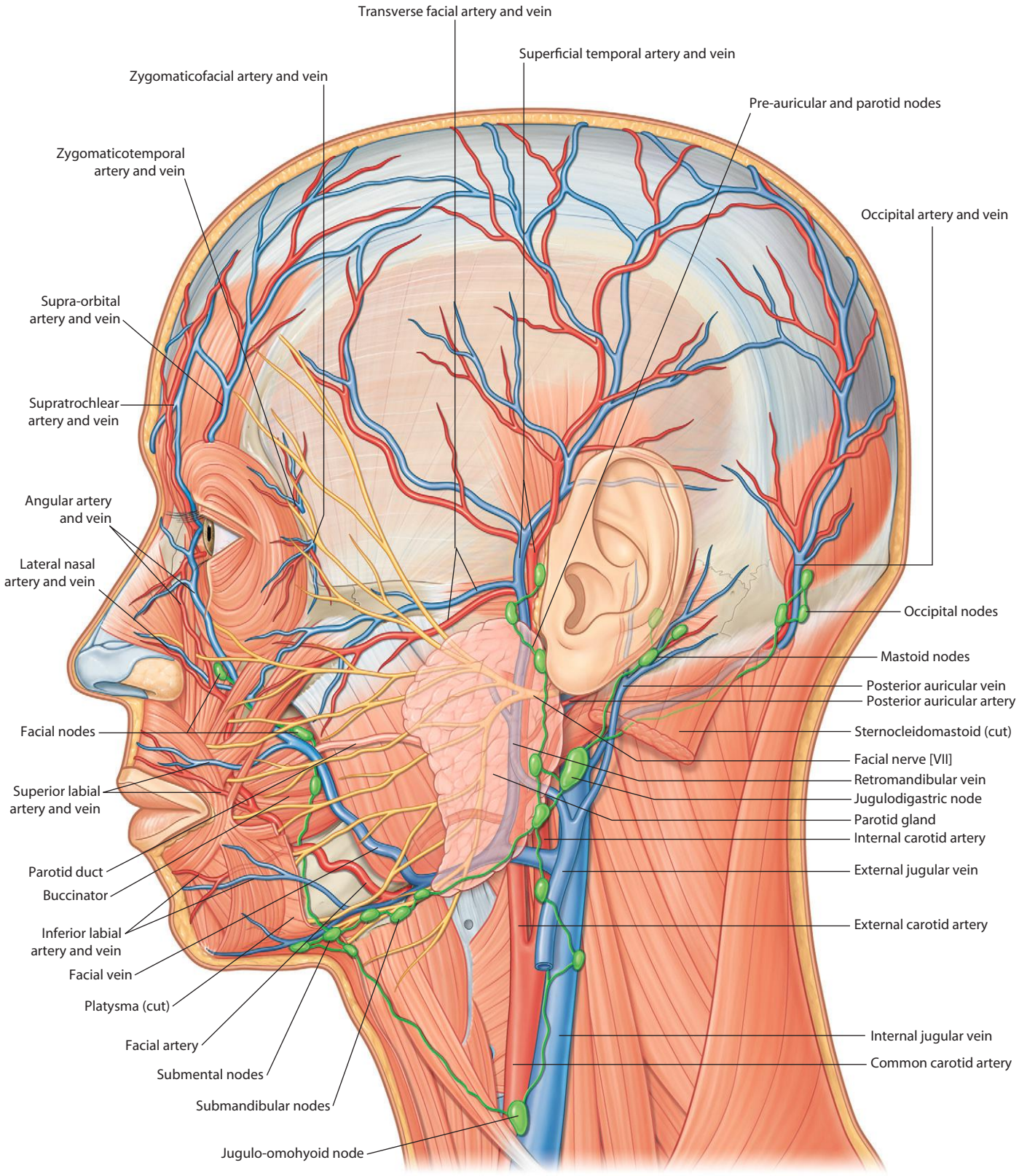

Vasculature, facial nerve [VII], and lymphatics of the face

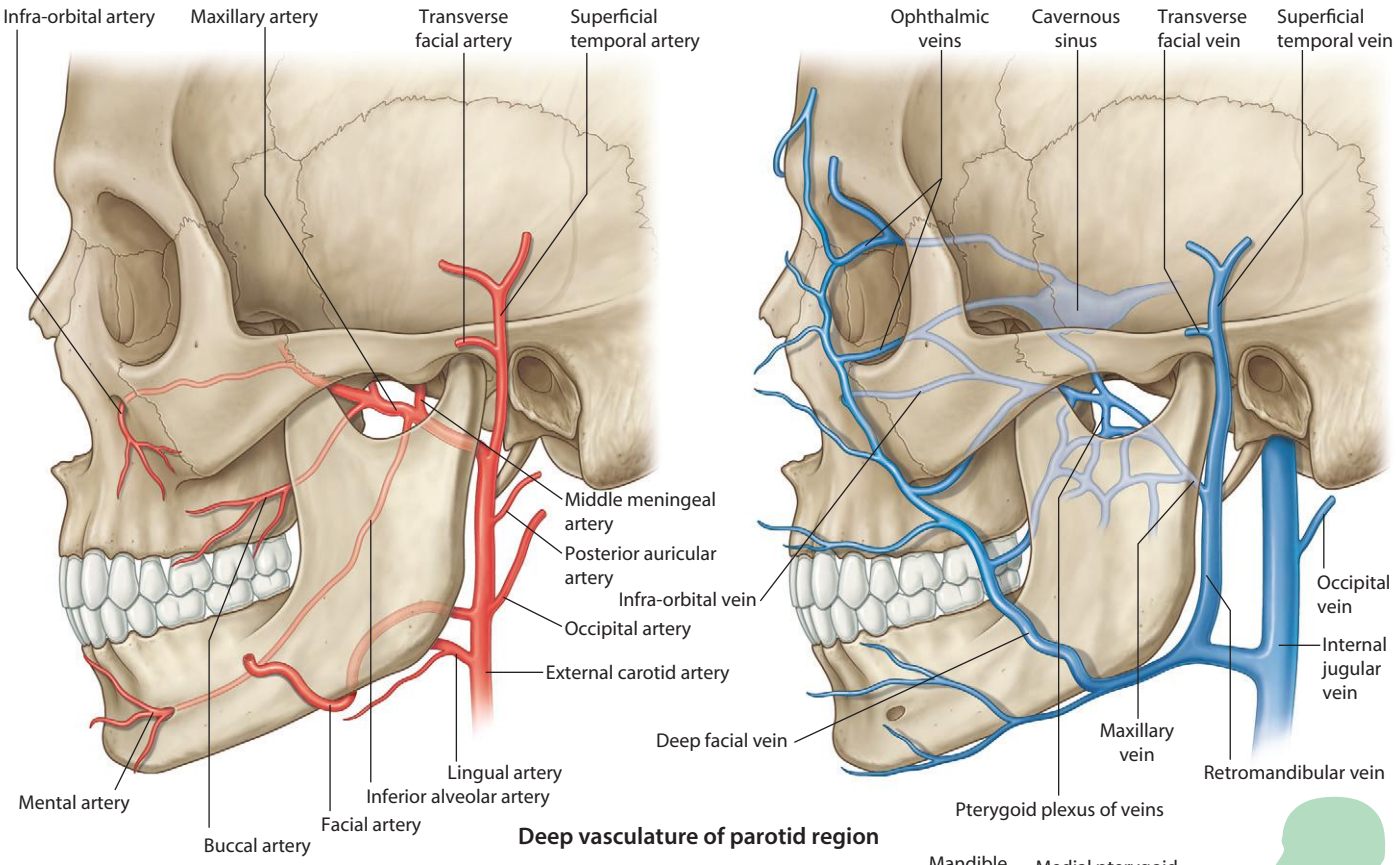

Deep vasculature of parotid region

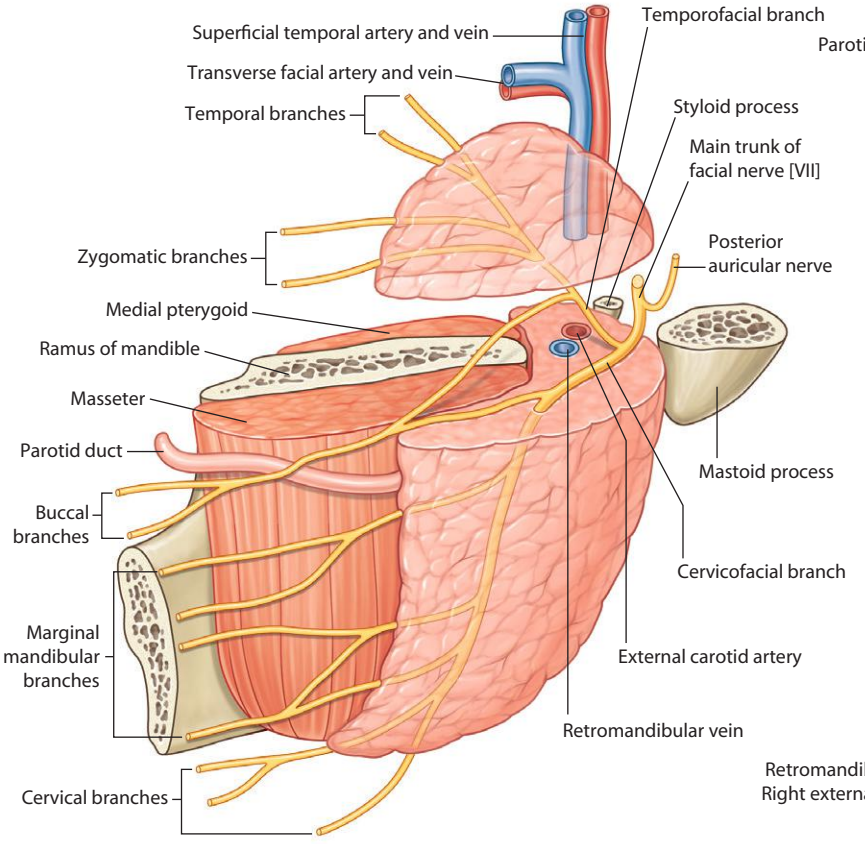

Parotid gland and facial nerve [VII]

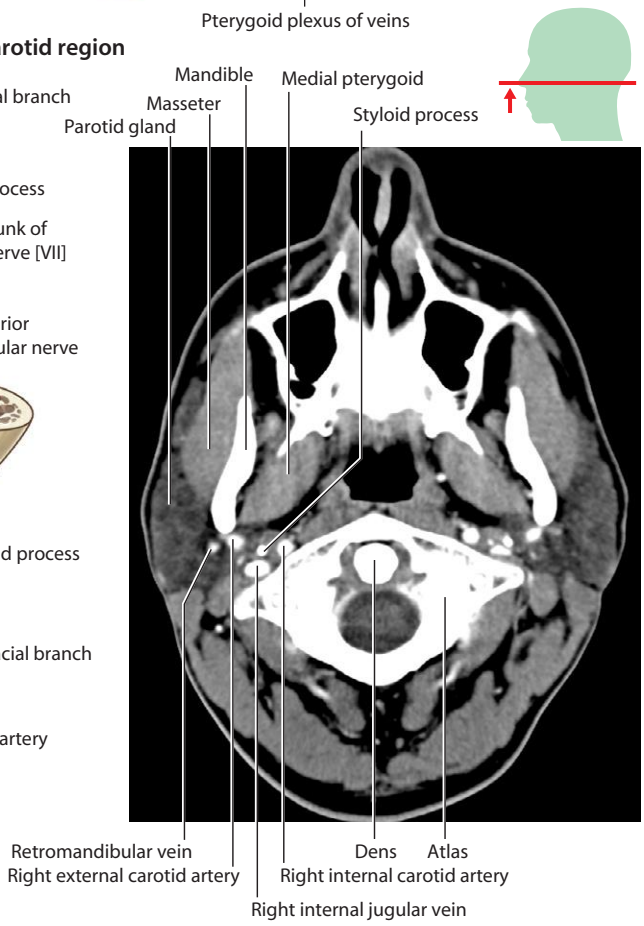

Axial section through the parotid gland showing its relationship to surrounding structures.
CT image in axial plane

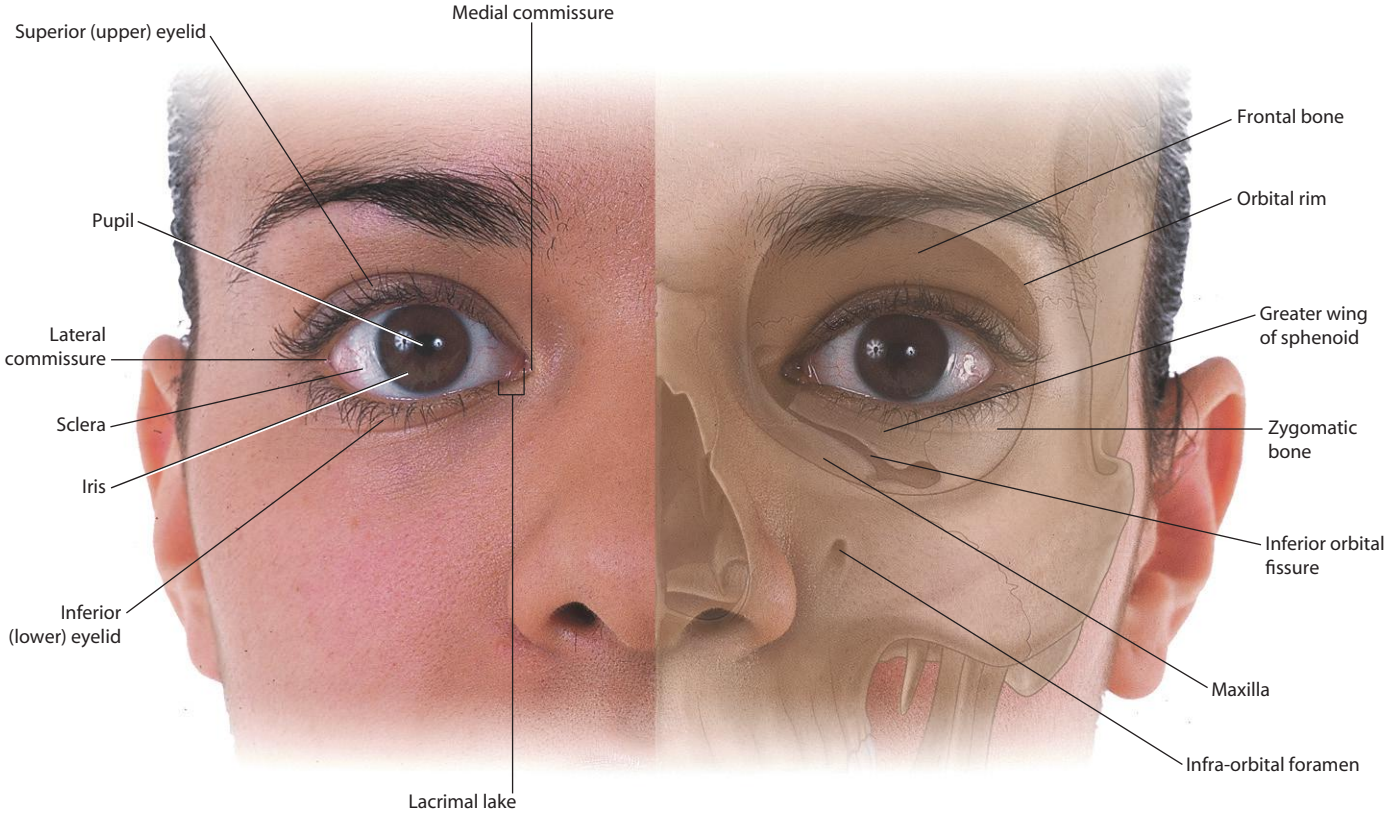

Surface anatomy

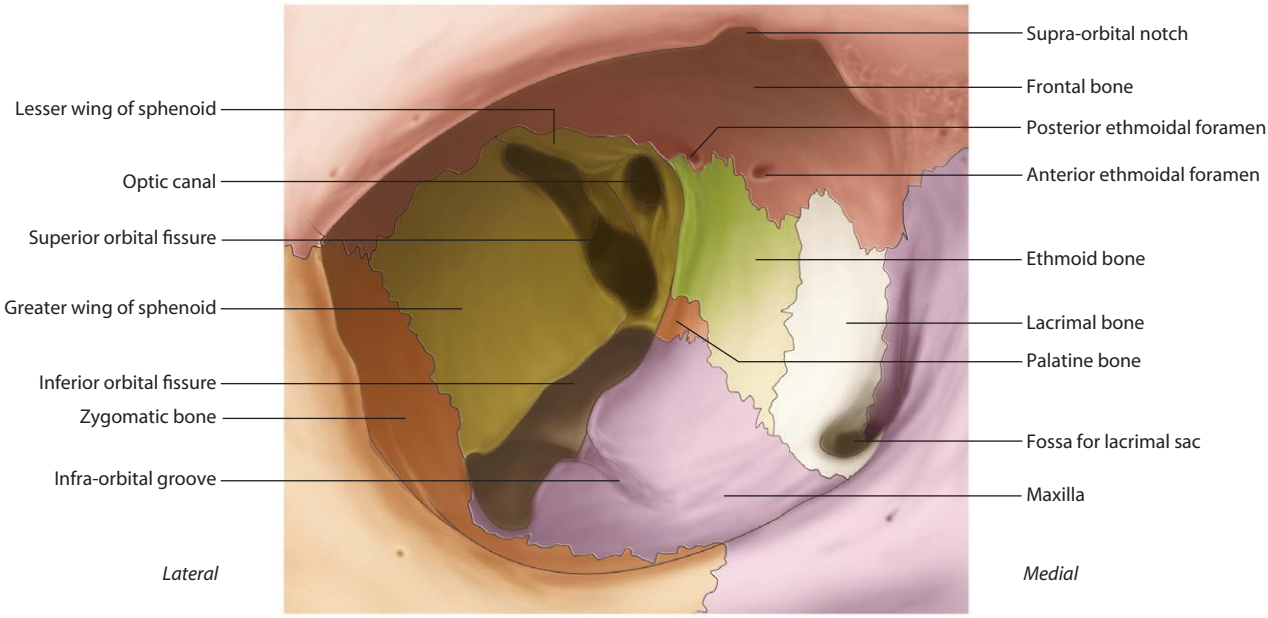

Bones of the right orbit

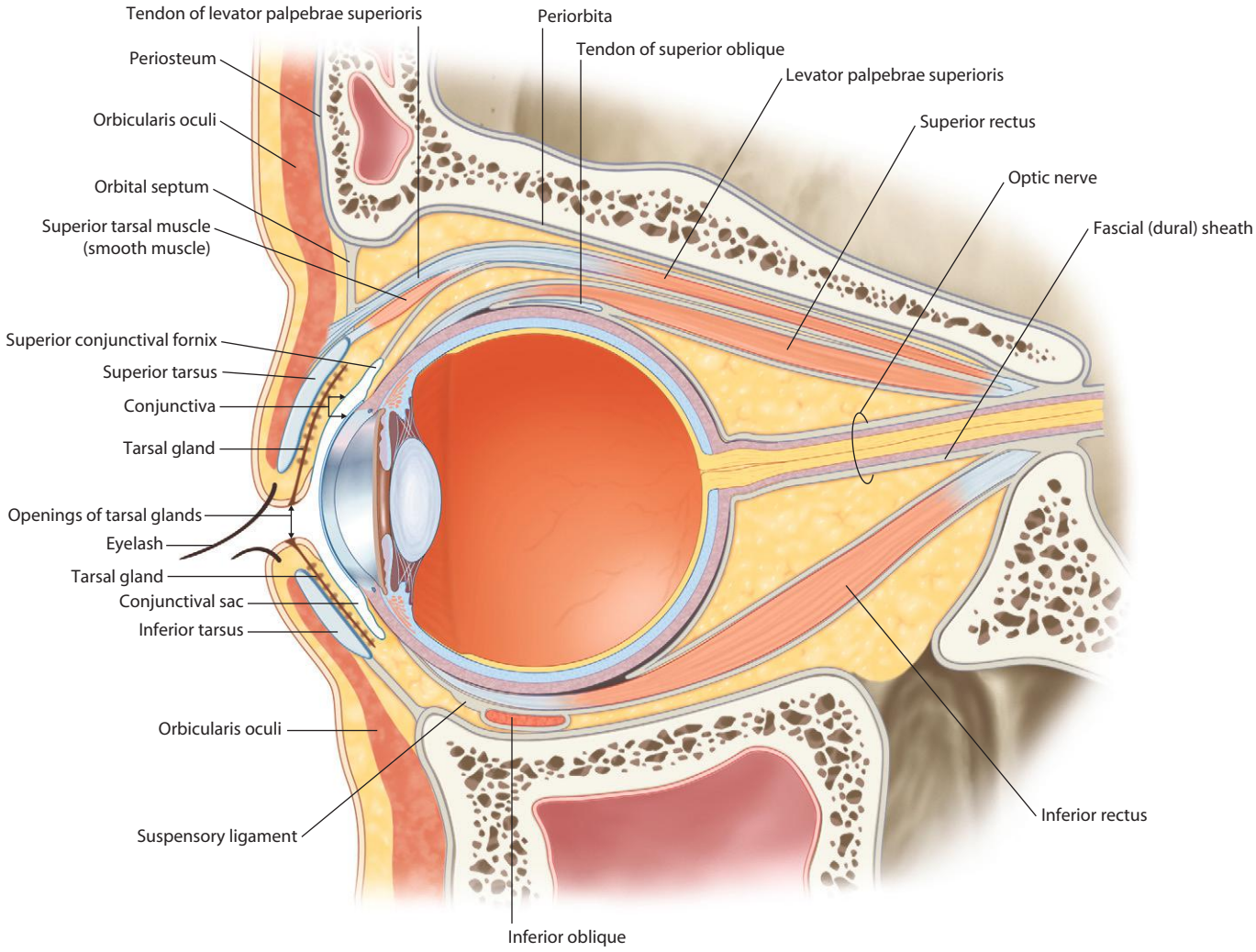

Sagittal section through orbit and eyeball

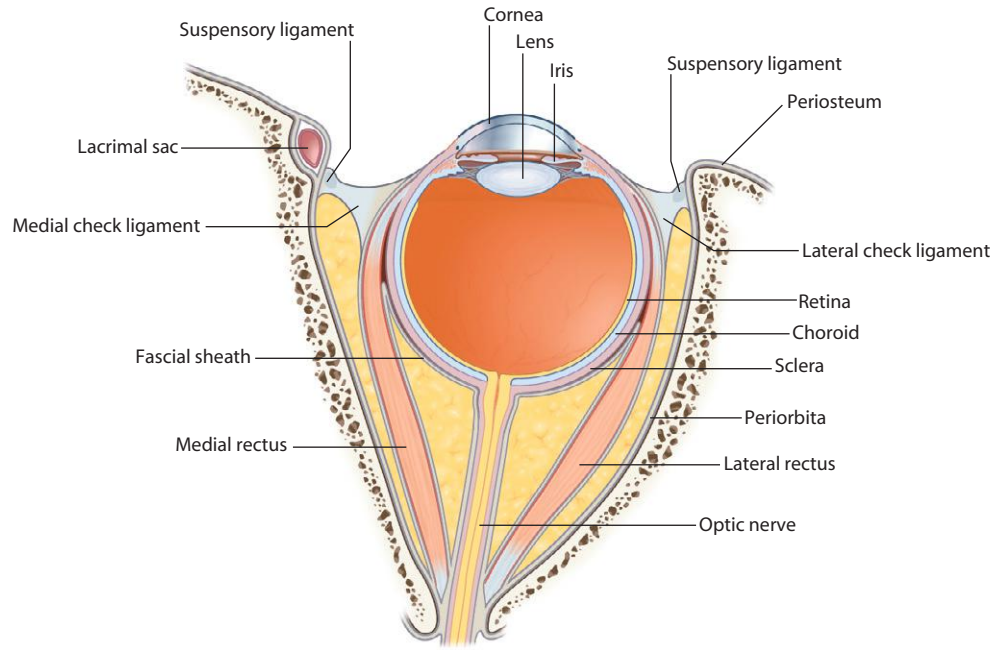

Horizontal (axial) section through orbit and eyeball

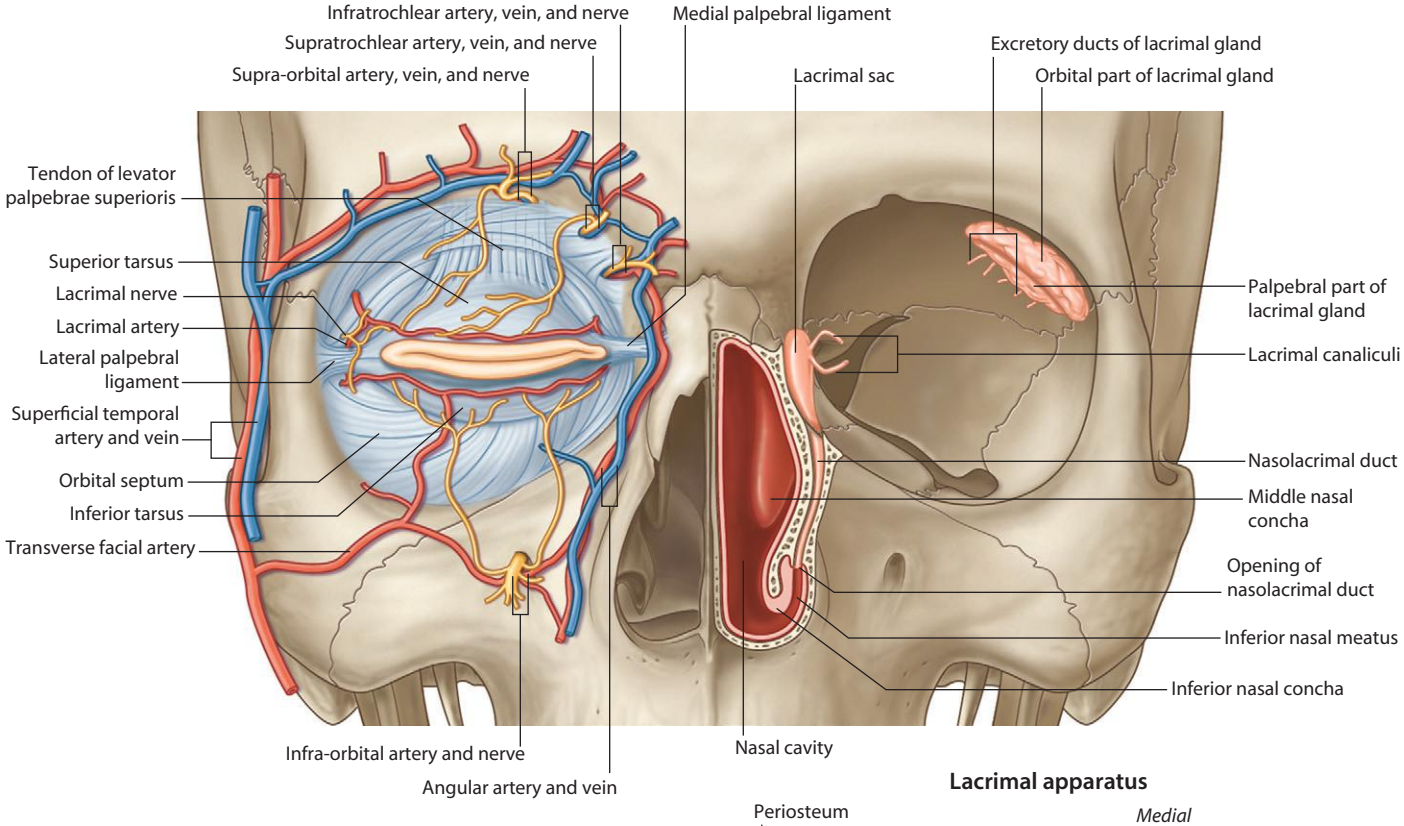

Vasculature and nerves of the eyelids

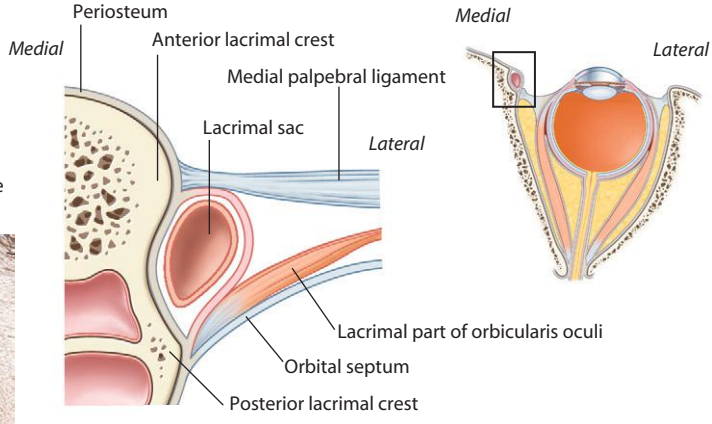

Lacrimal apparatus

Lacrimal sac (horizontal section)

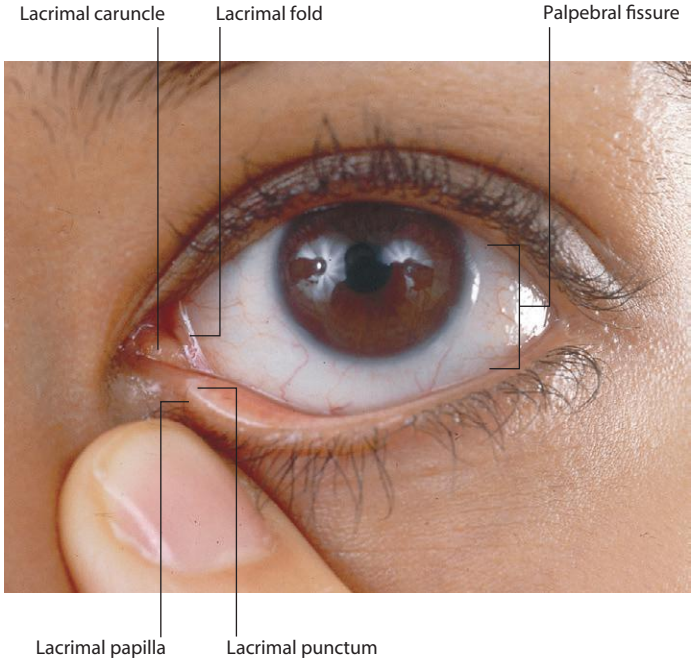

Lacrimal papilla and punctum of left eye

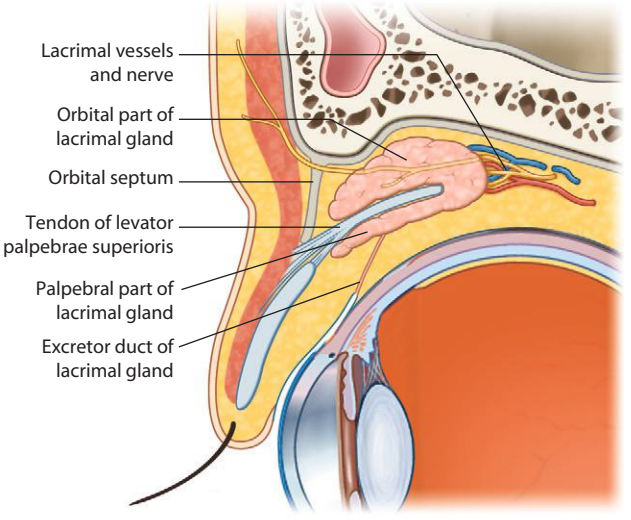

Lacrimal gland and levator palpebrae superioris (parasagittal section)

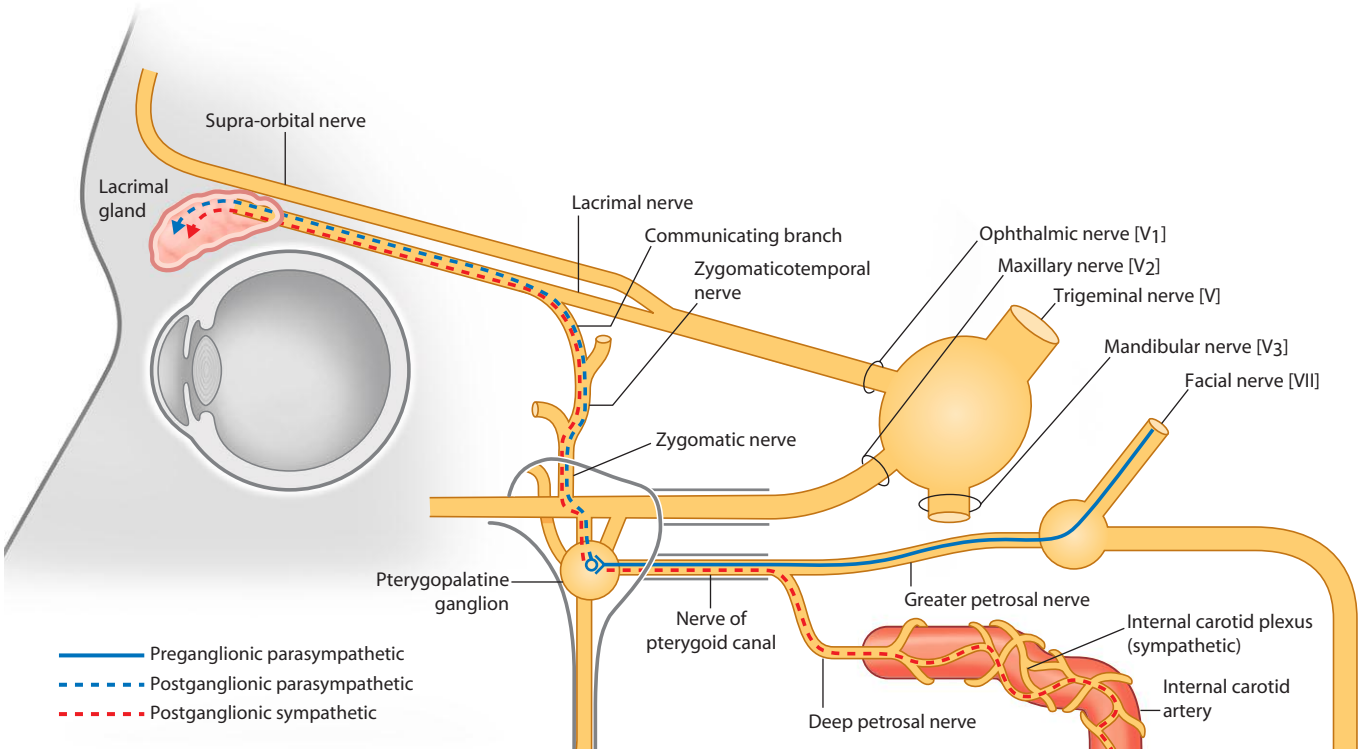

Visceral efferent (motor) innervation of the lacrimal gland

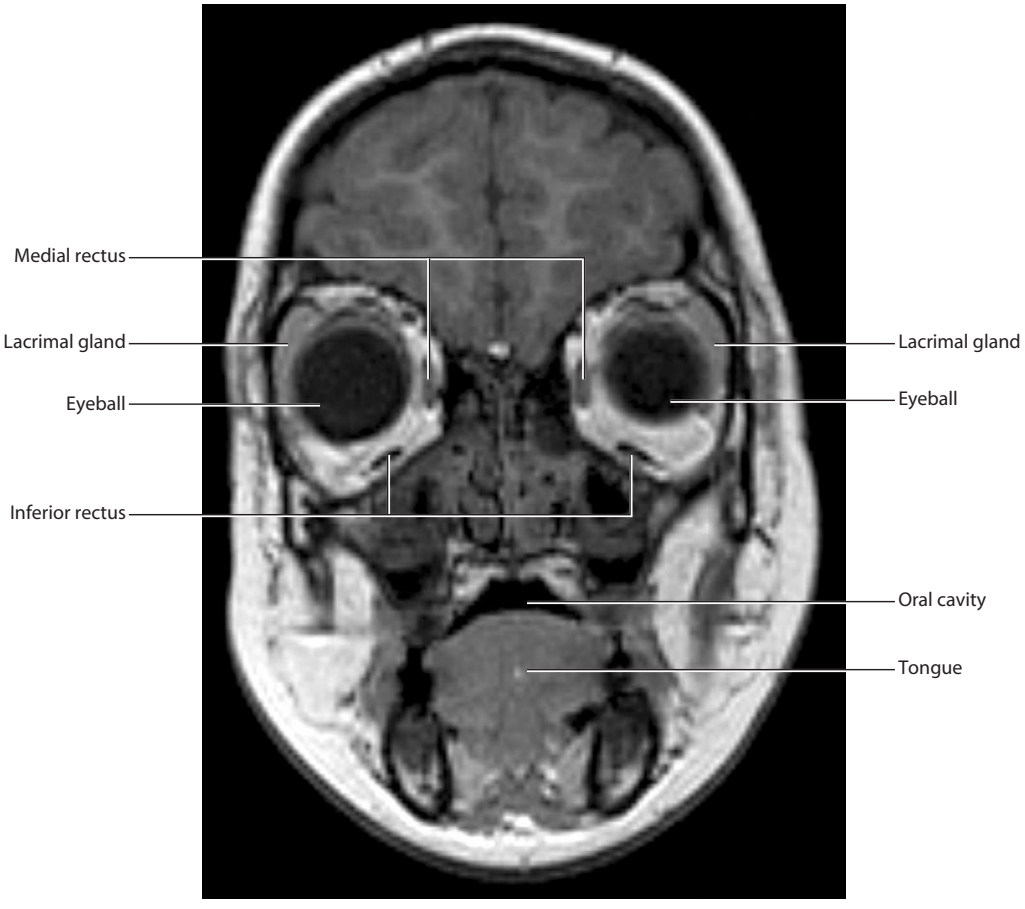

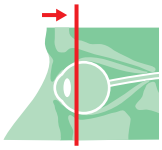

Coronal section through the orbit showing the lacrimal gland and its relationship to surrounding structures.
T1-weighted MR image in coronal plane

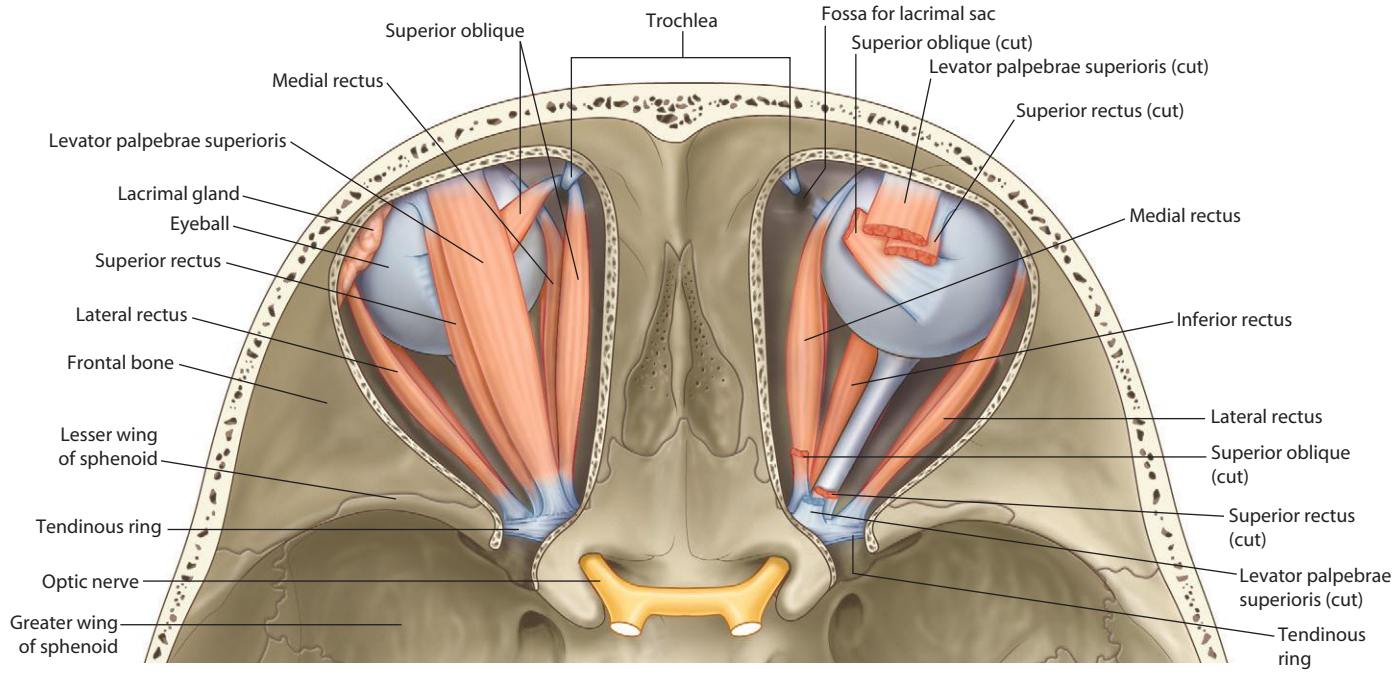

Superior view

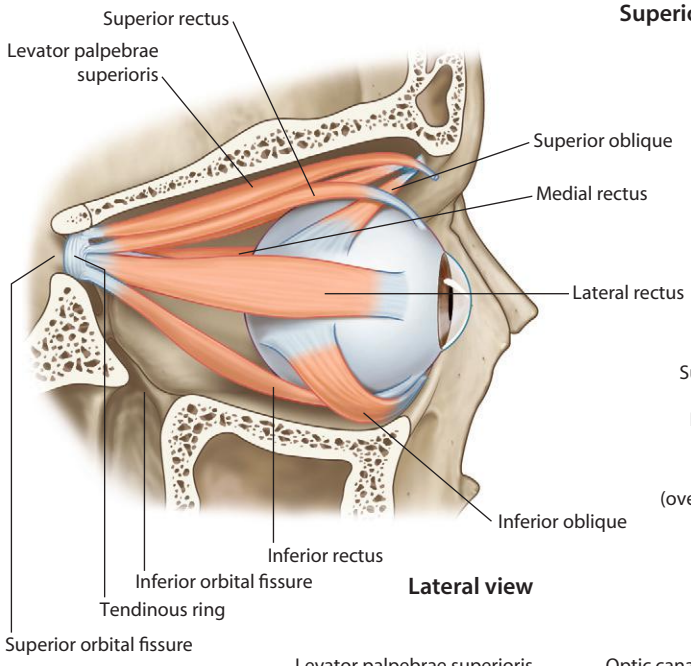

Lateral view

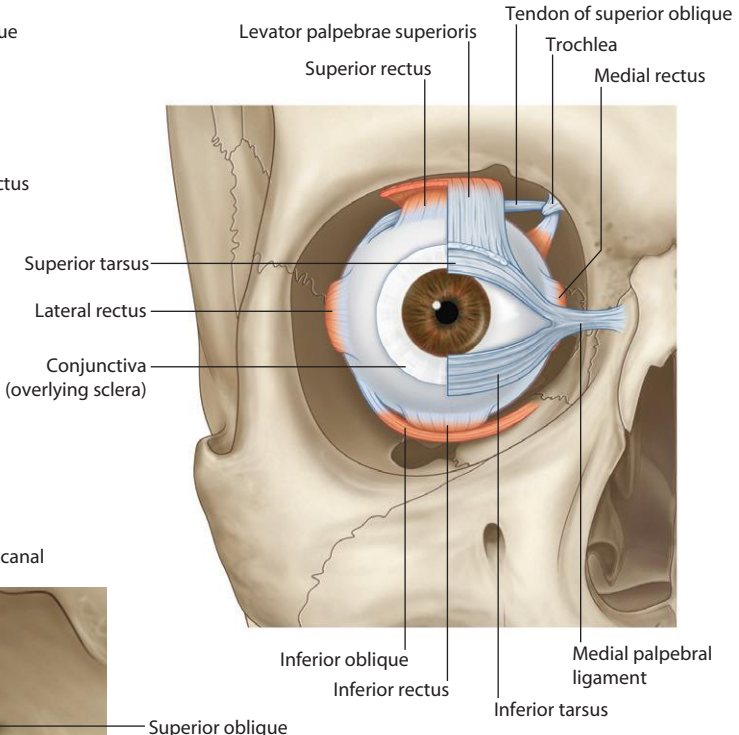

Anterior view

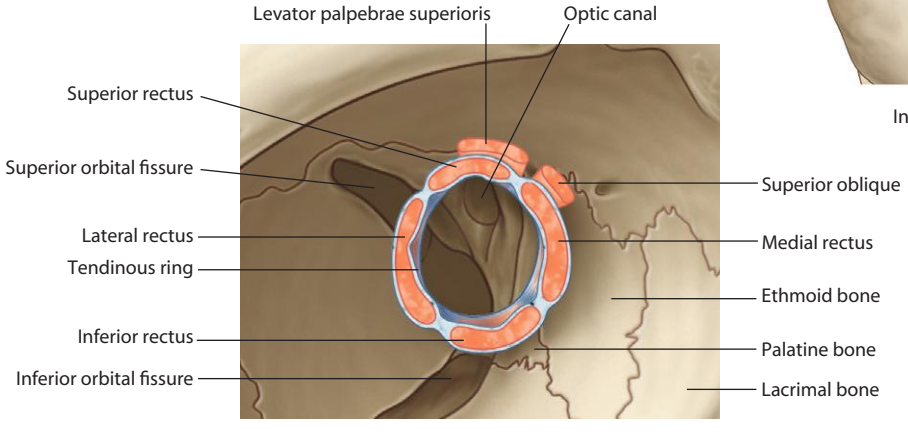

Origins of muscles of the eyeball

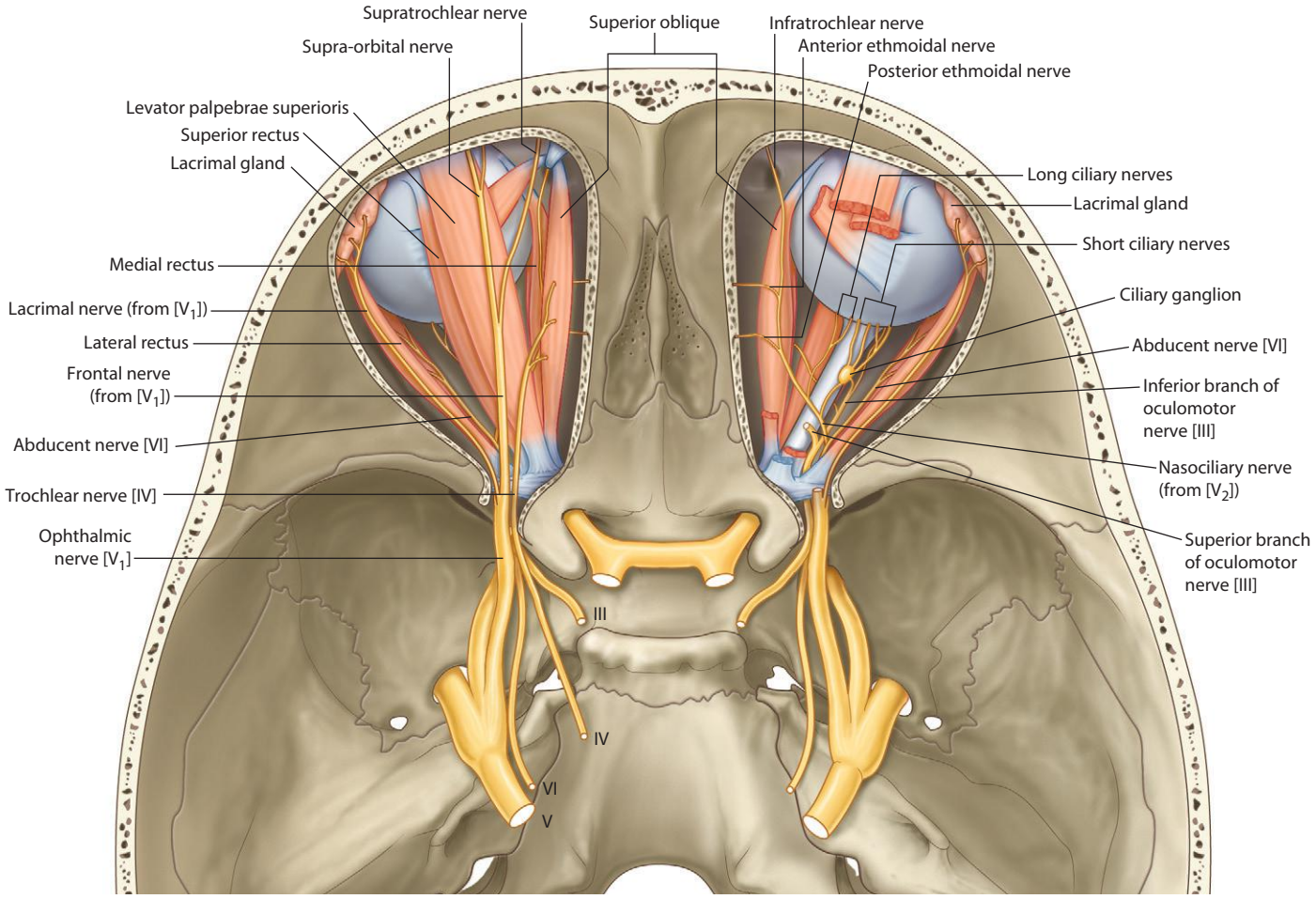

Superior view

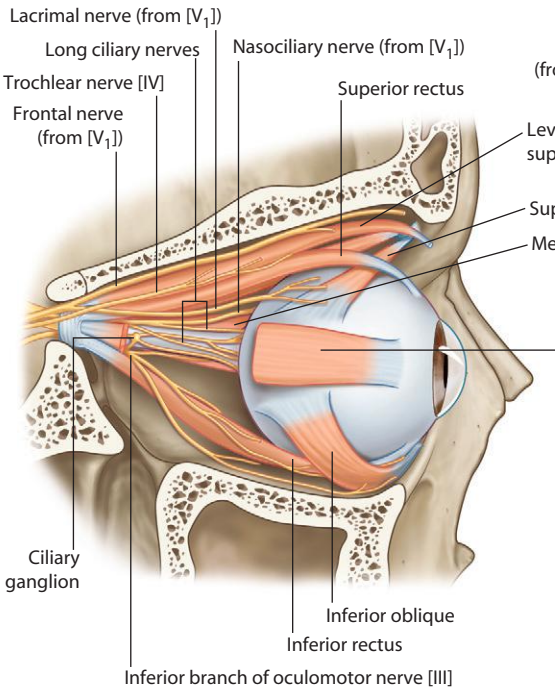

Lateral view

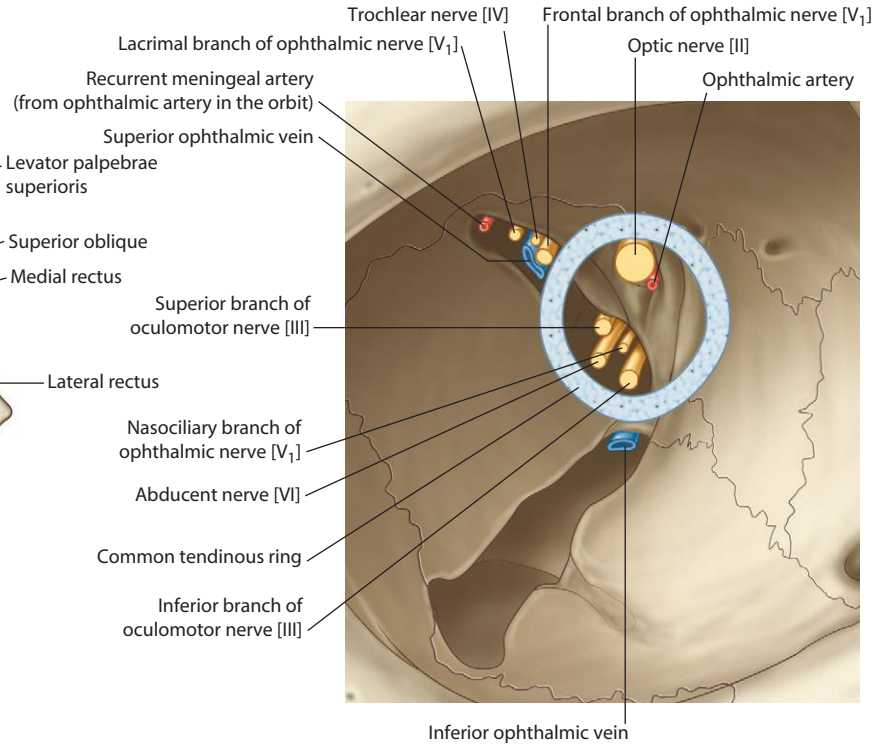

Anterior view

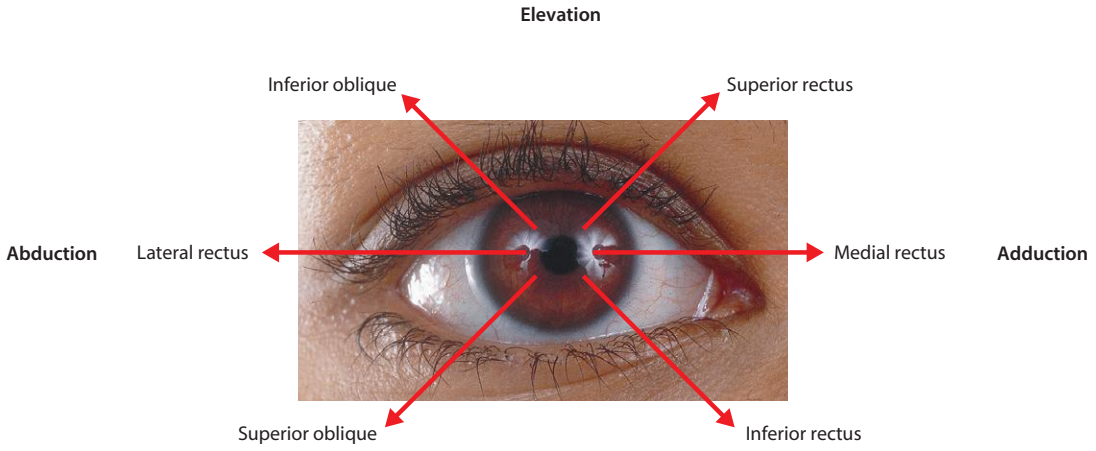

Actions of individual muscles (anatomical action)

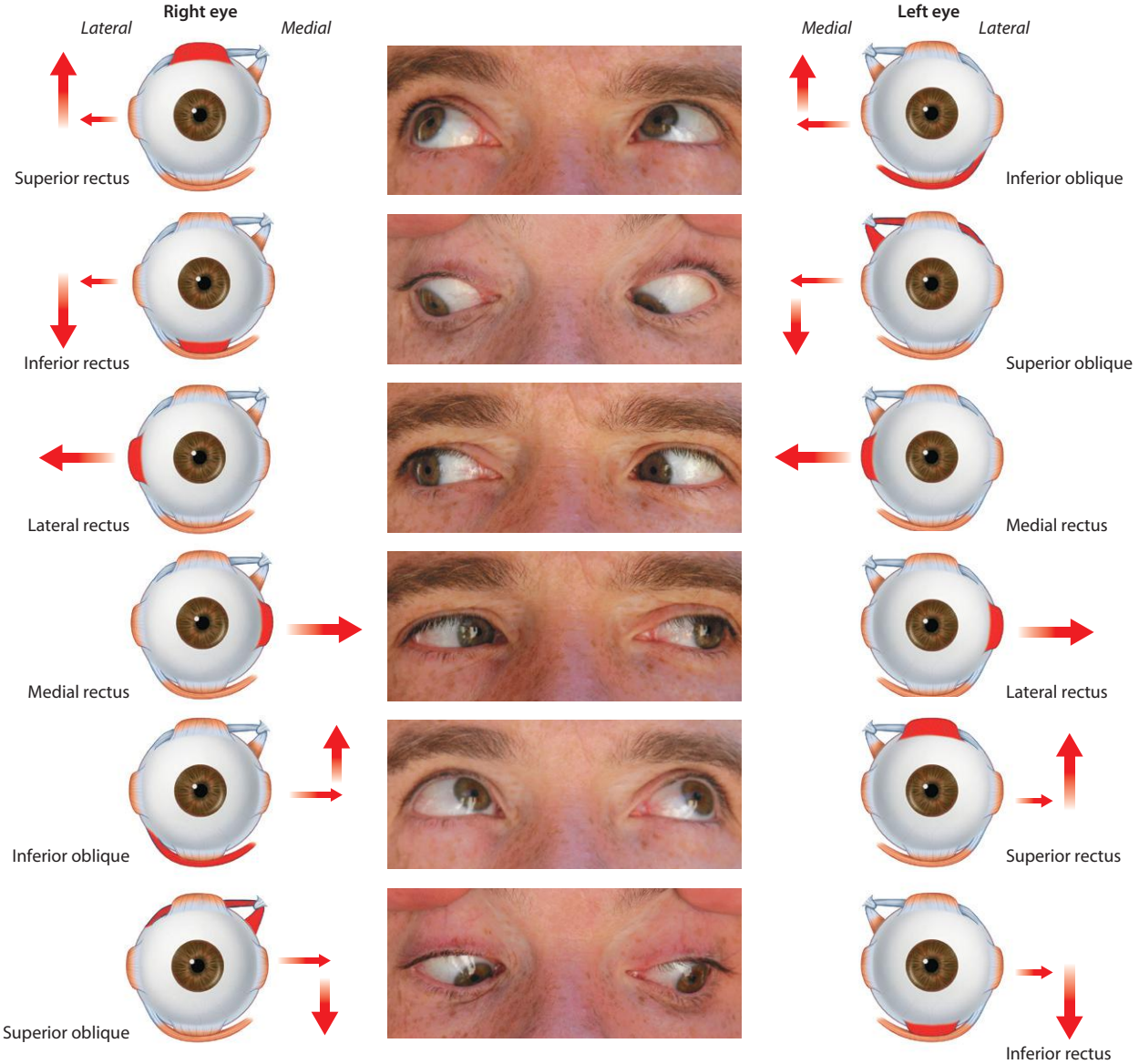

Movement of eyes when testing specific muscle (clinical testing).

For testing some muscles, a patient is "asked" first to move the eye into a position (small arrow) where the indicated muscle can best be tested. The large arrow indicates the direction the patient is then "asked" to move the eye to test the muscle

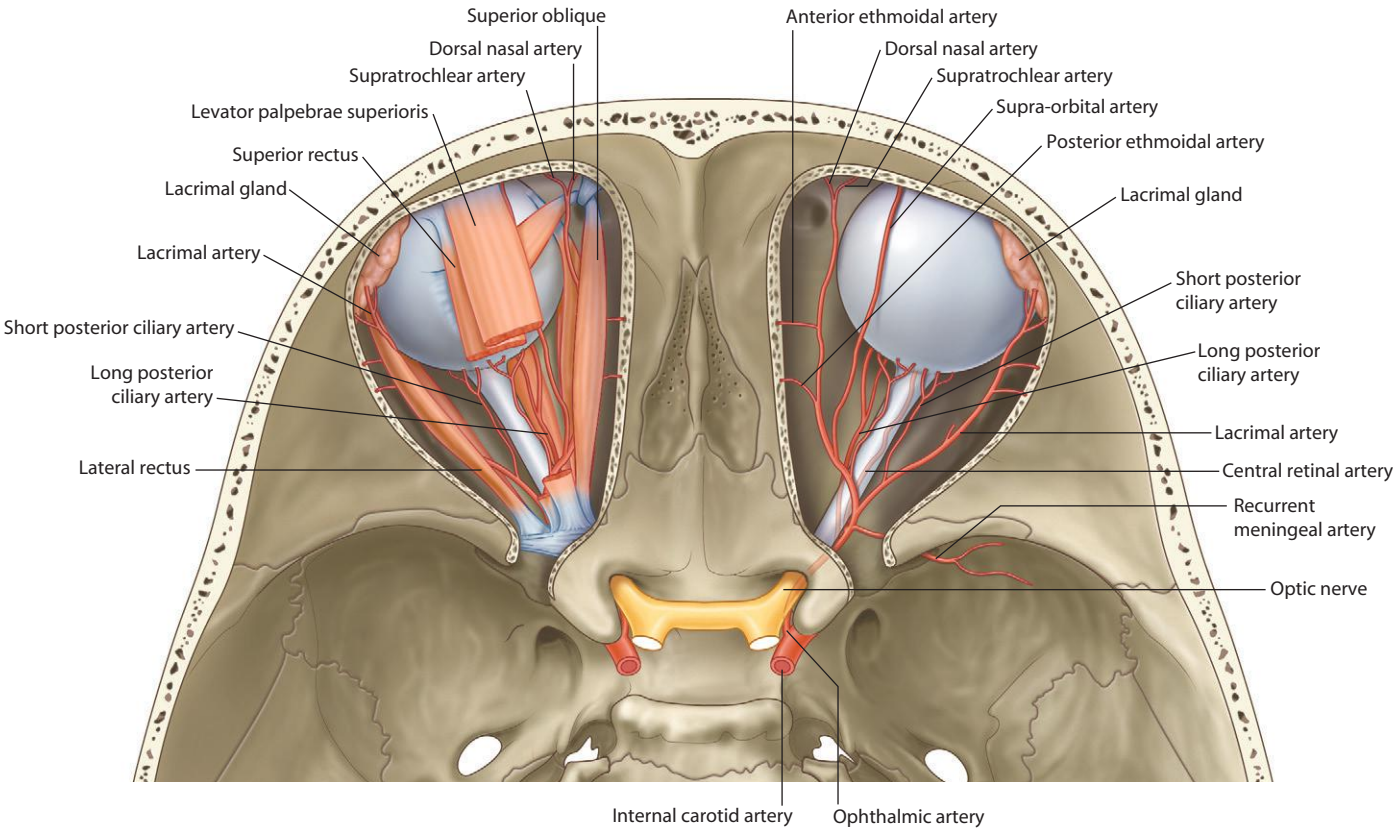

Arteries of the orbit and eyeball (superior view)

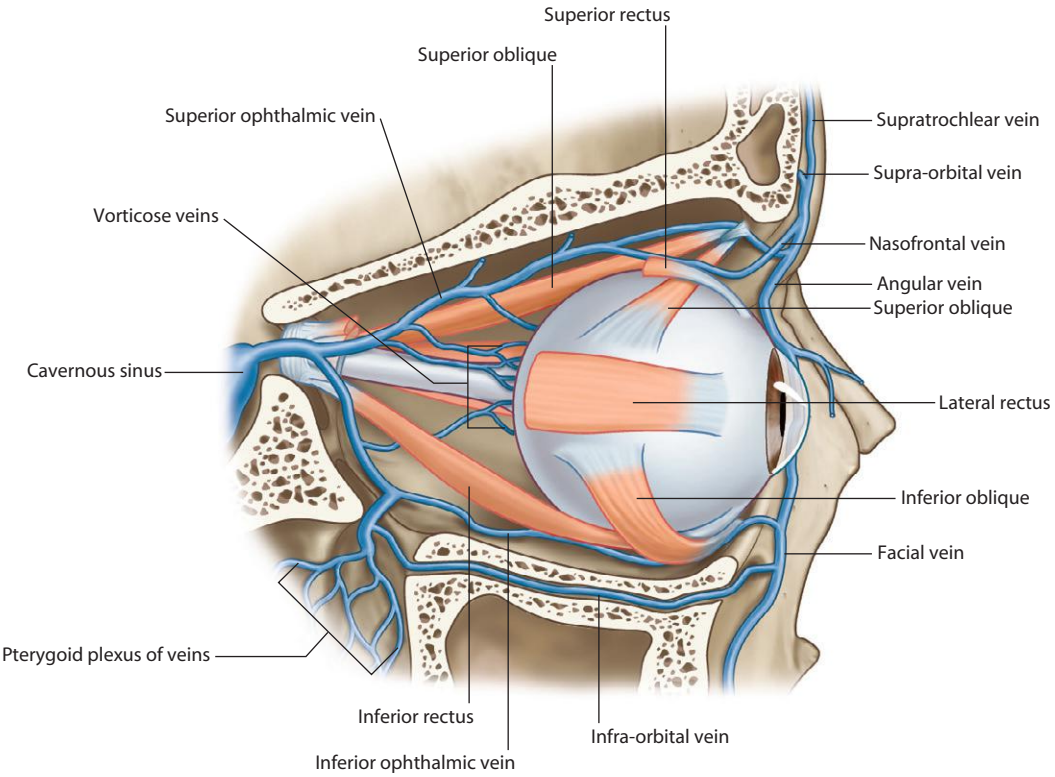

Veins of the orbit and eyeball (lateral view)

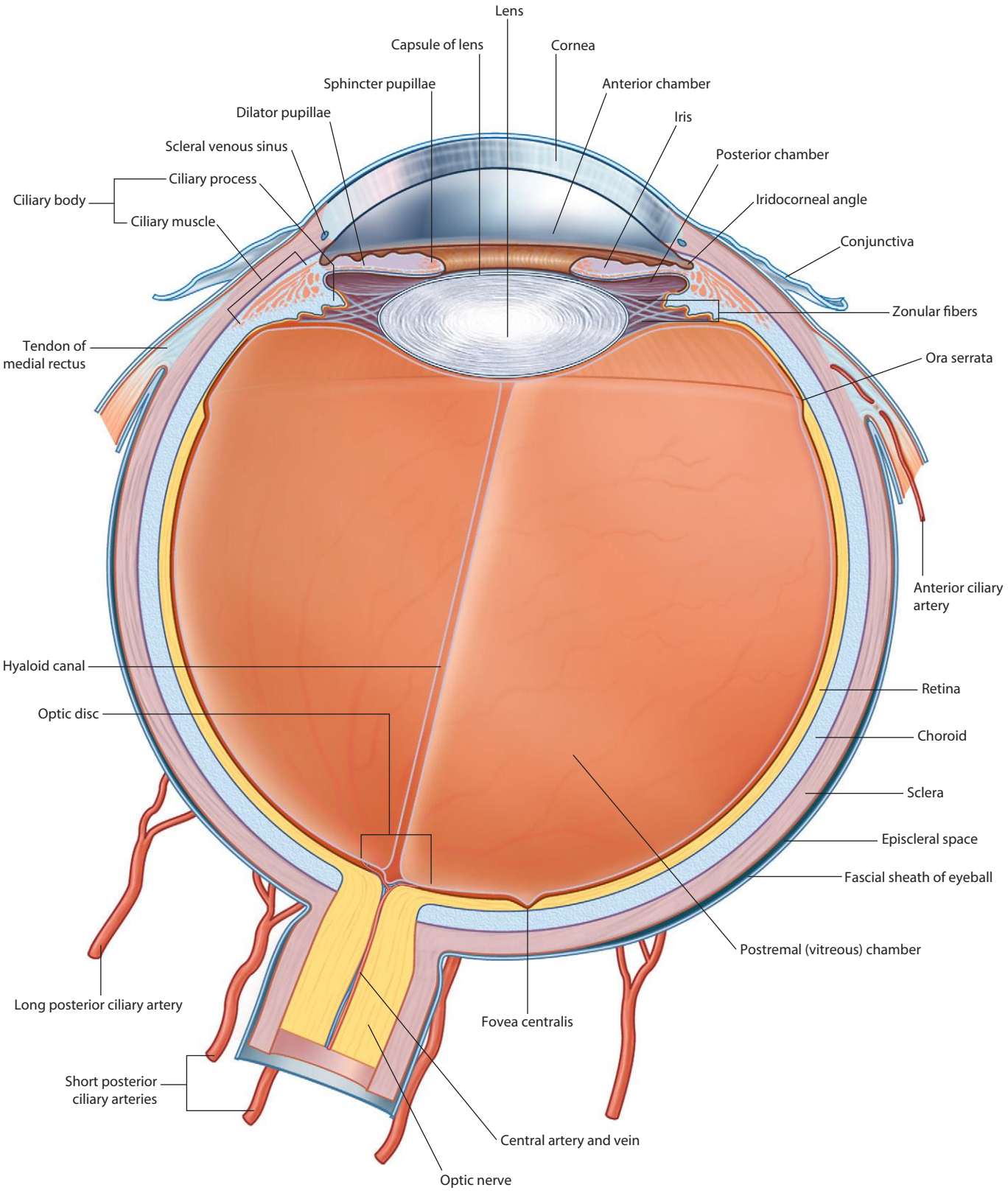

Eyeball (horizontal section)

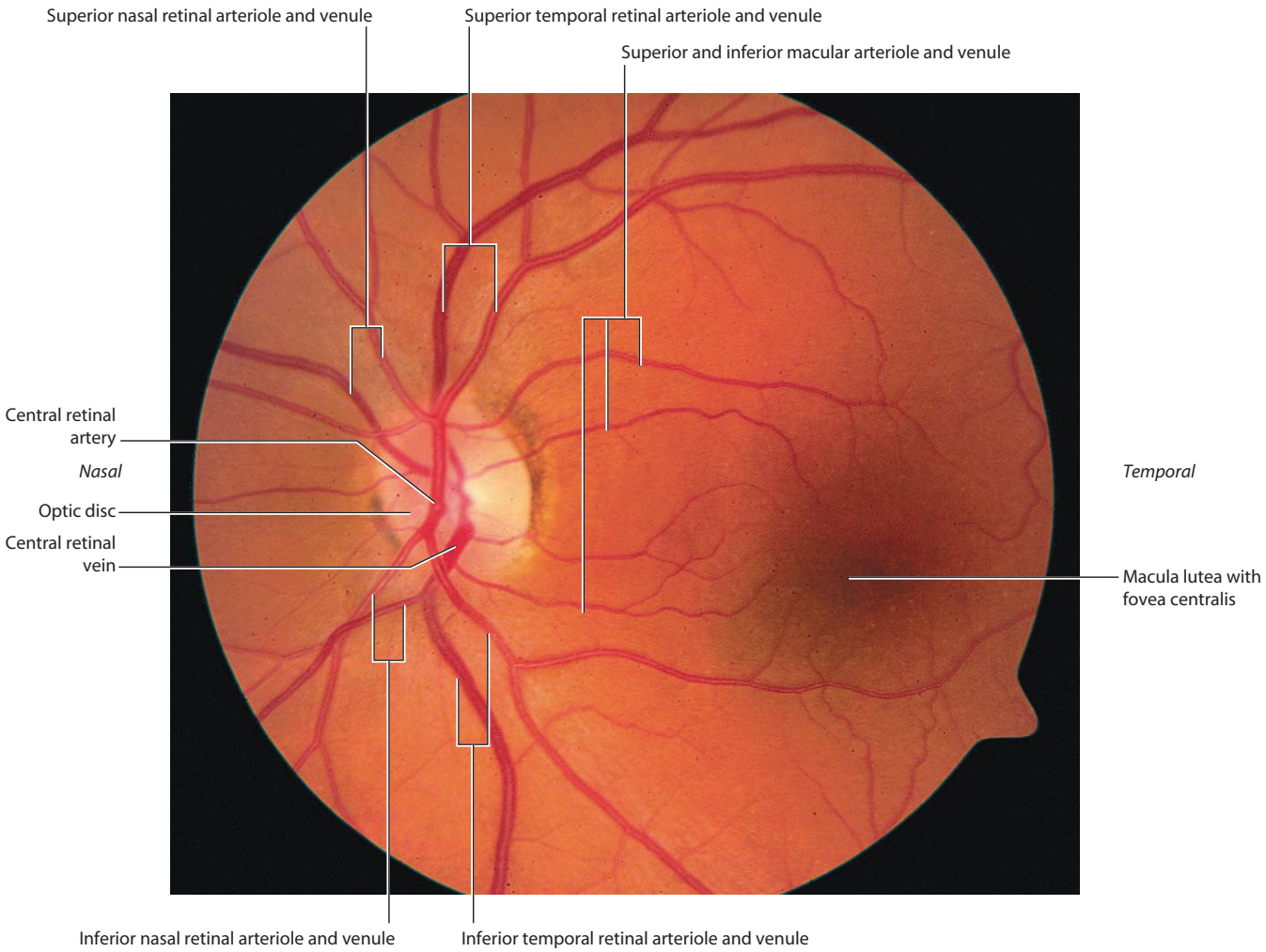

Ophthalmoscopic view of the left retina showing the optic disc, the macula lutea, and the retinal vasculature

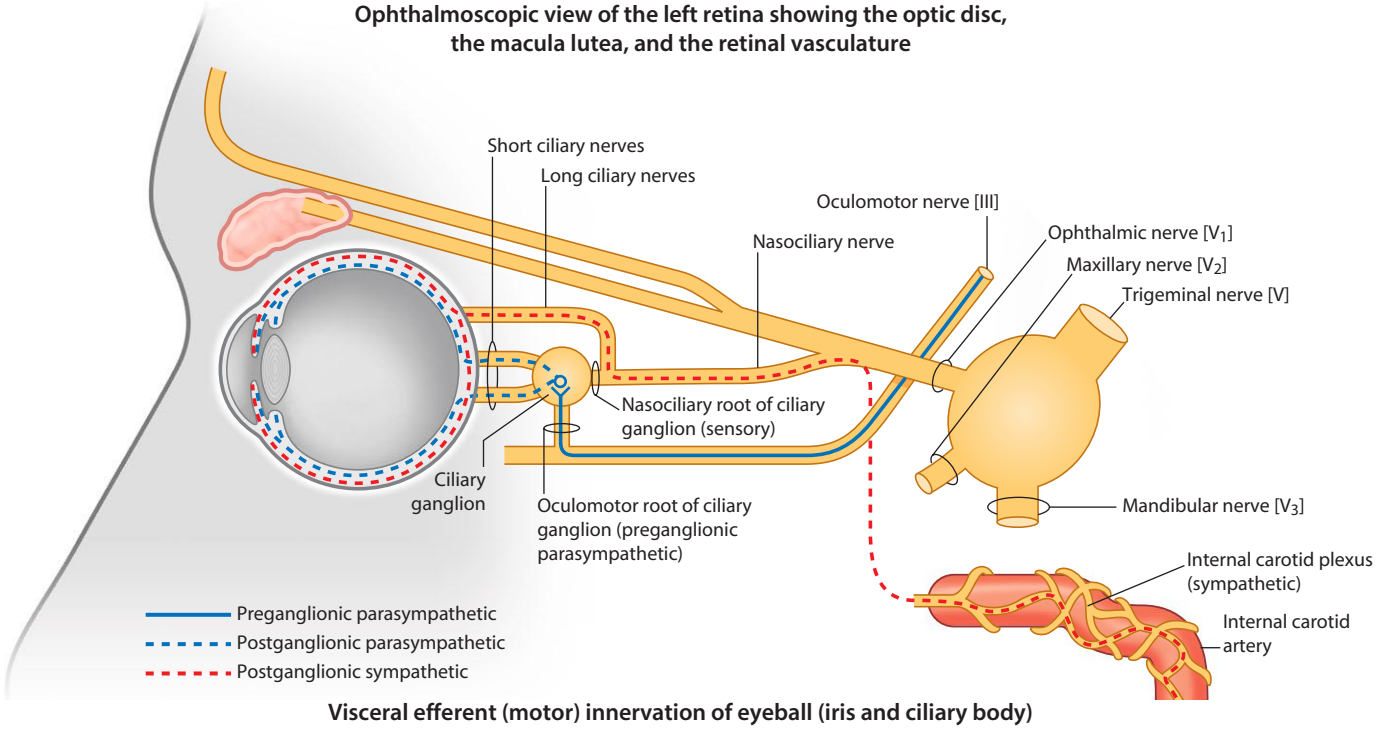

Visceral efferent (motor) innervation of eyeball (iris and ciliary body)

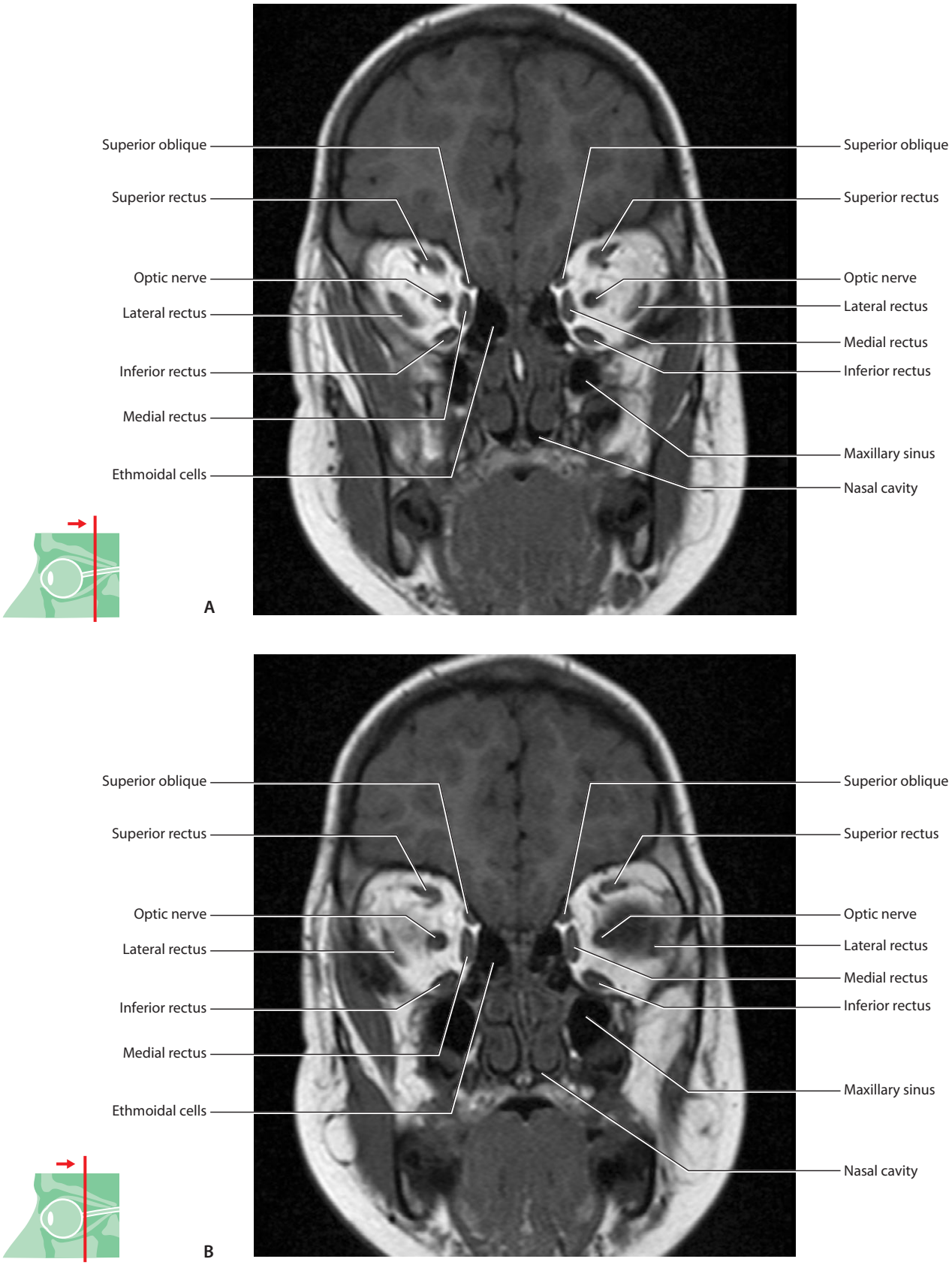

A through D – Coronal sections that pass through the orbit from posterior to anterior showing the extrinsic (extra-ocular) muscles and their relationships with each other and with other structures.
T1-weighted MR images in coronal plane

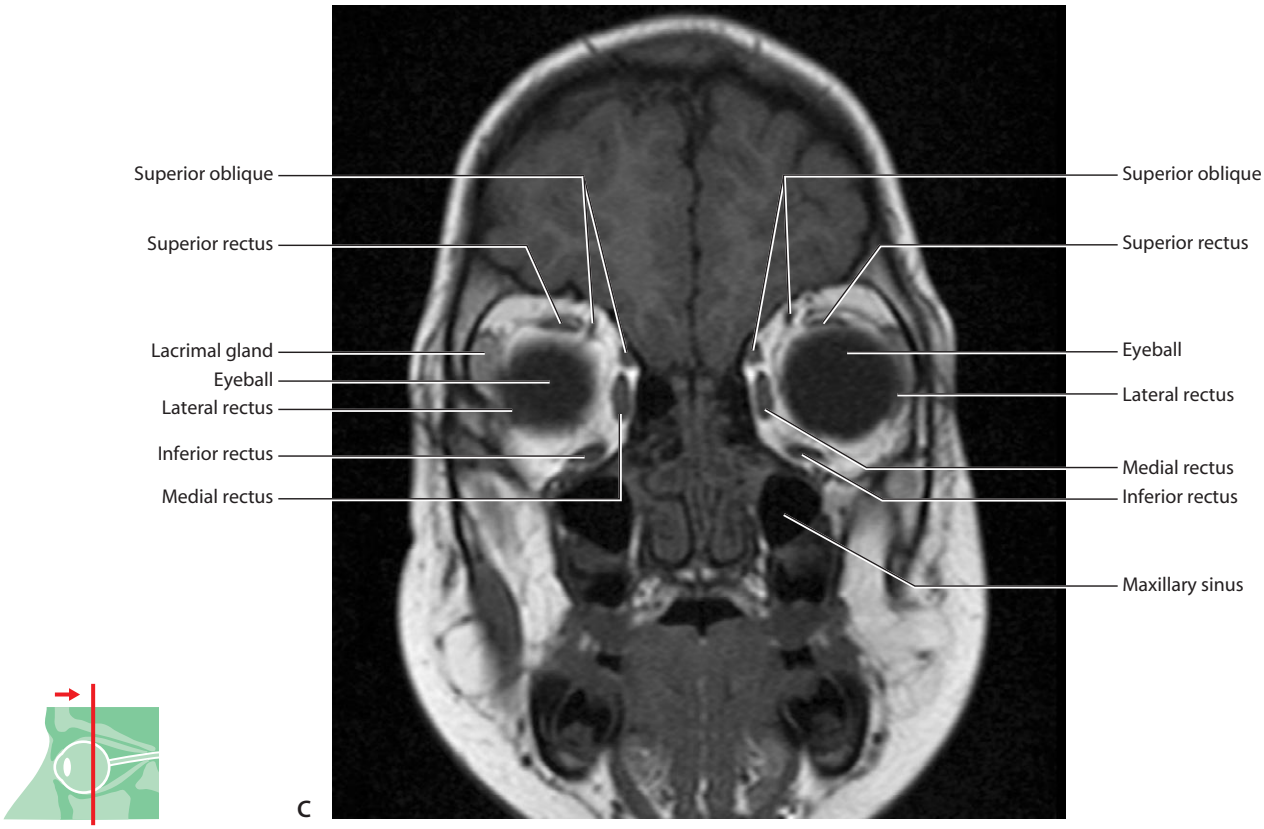
Superior oblique
Superior rectus
Lacrimal gland
Eyeball
Lateral rectus
Inferior rectus
Medial rectus
Superior oblique
Superior rectus
Eyeball
Lateral rectus
Medial rectus
Inferior rectus
Maxillary sinus

C

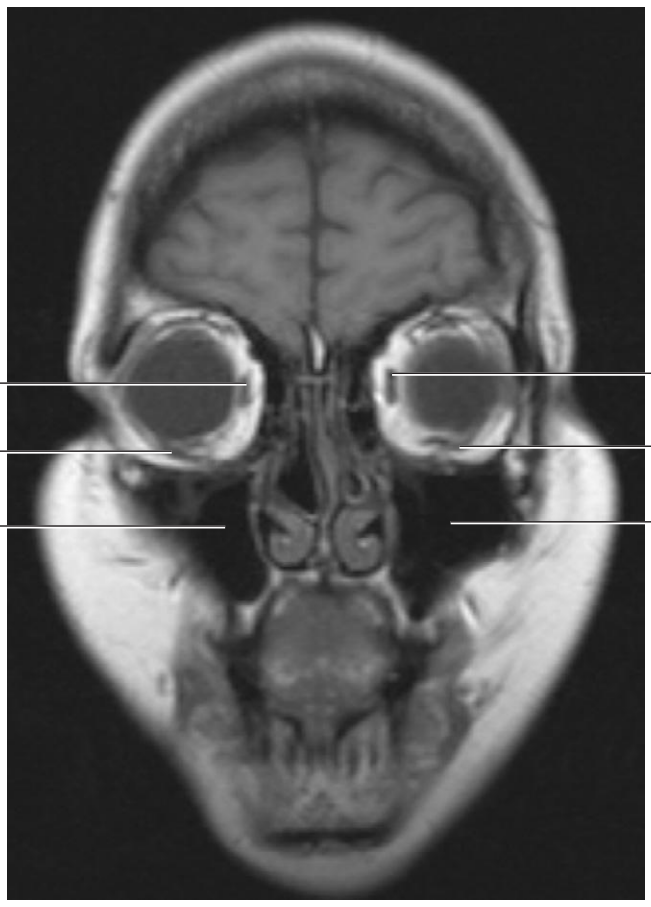
Medial rectus
Inferior oblique
Maxillary sinus
Medial rectus
Inferior oblique
Maxillary sinus

D

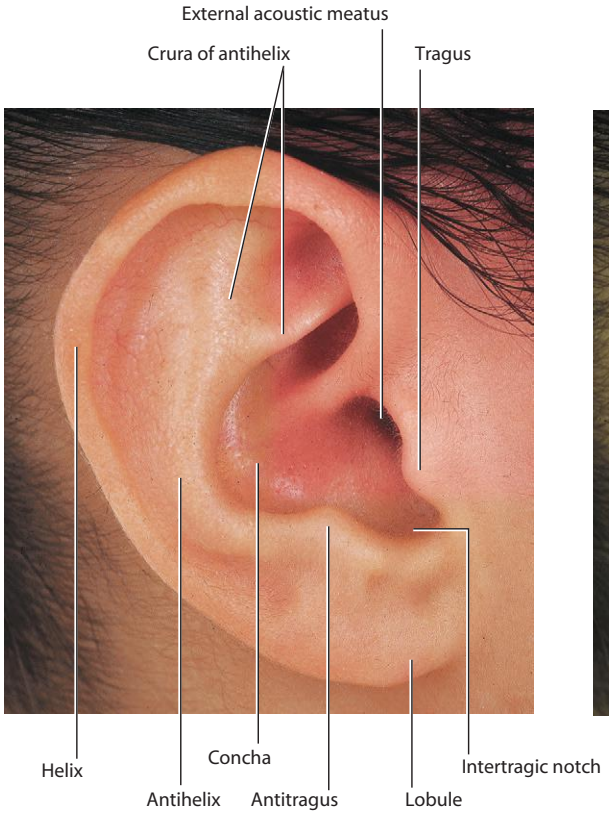

External ear (auricle)

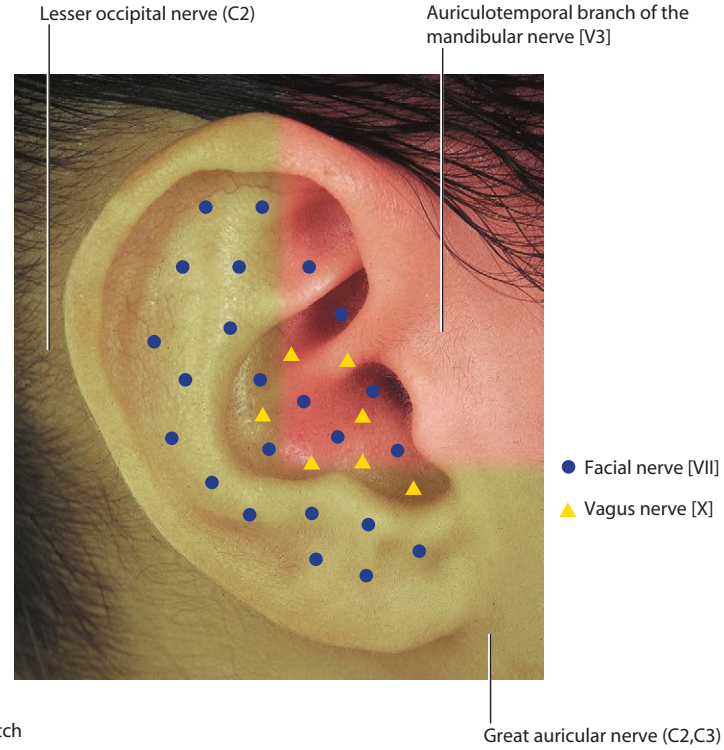

Sensory innervation of the auricle

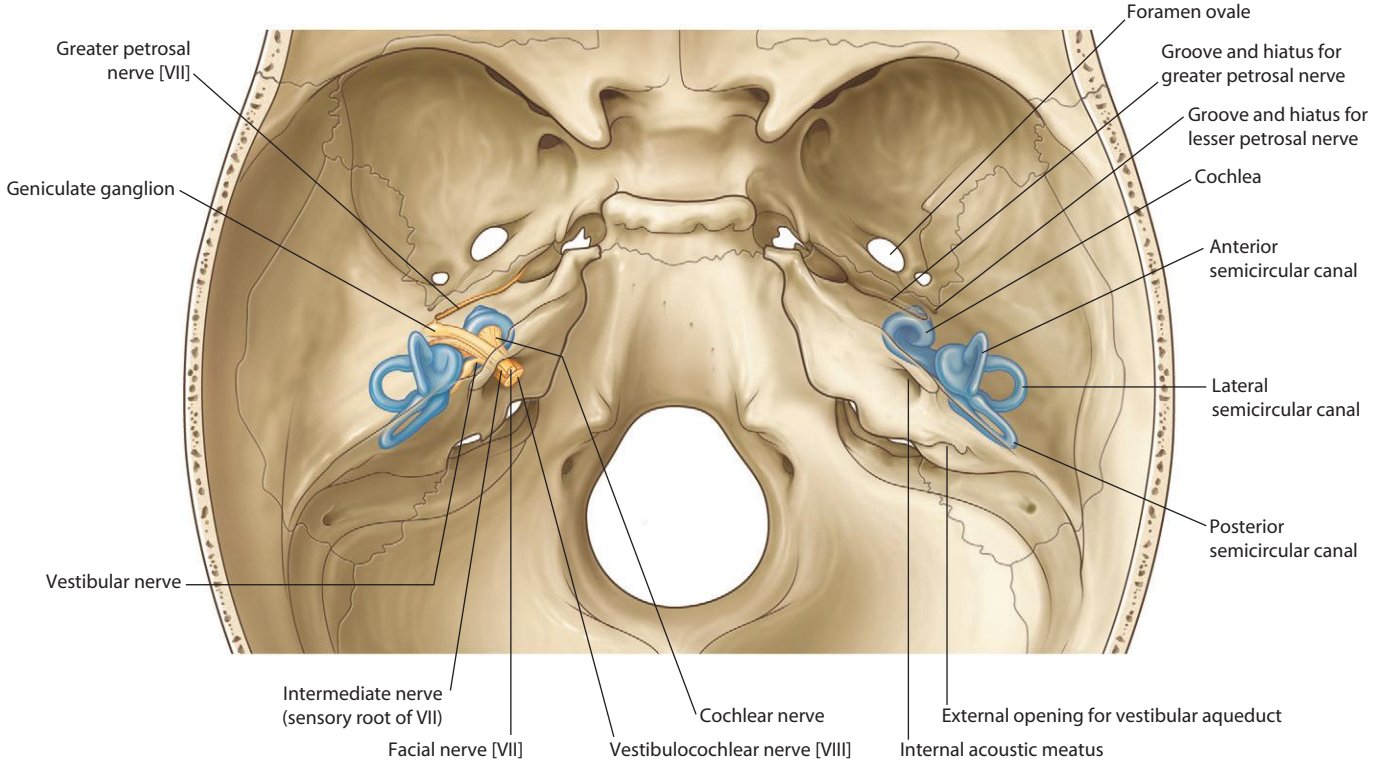

Superior projection of internal ear in the temporal bone

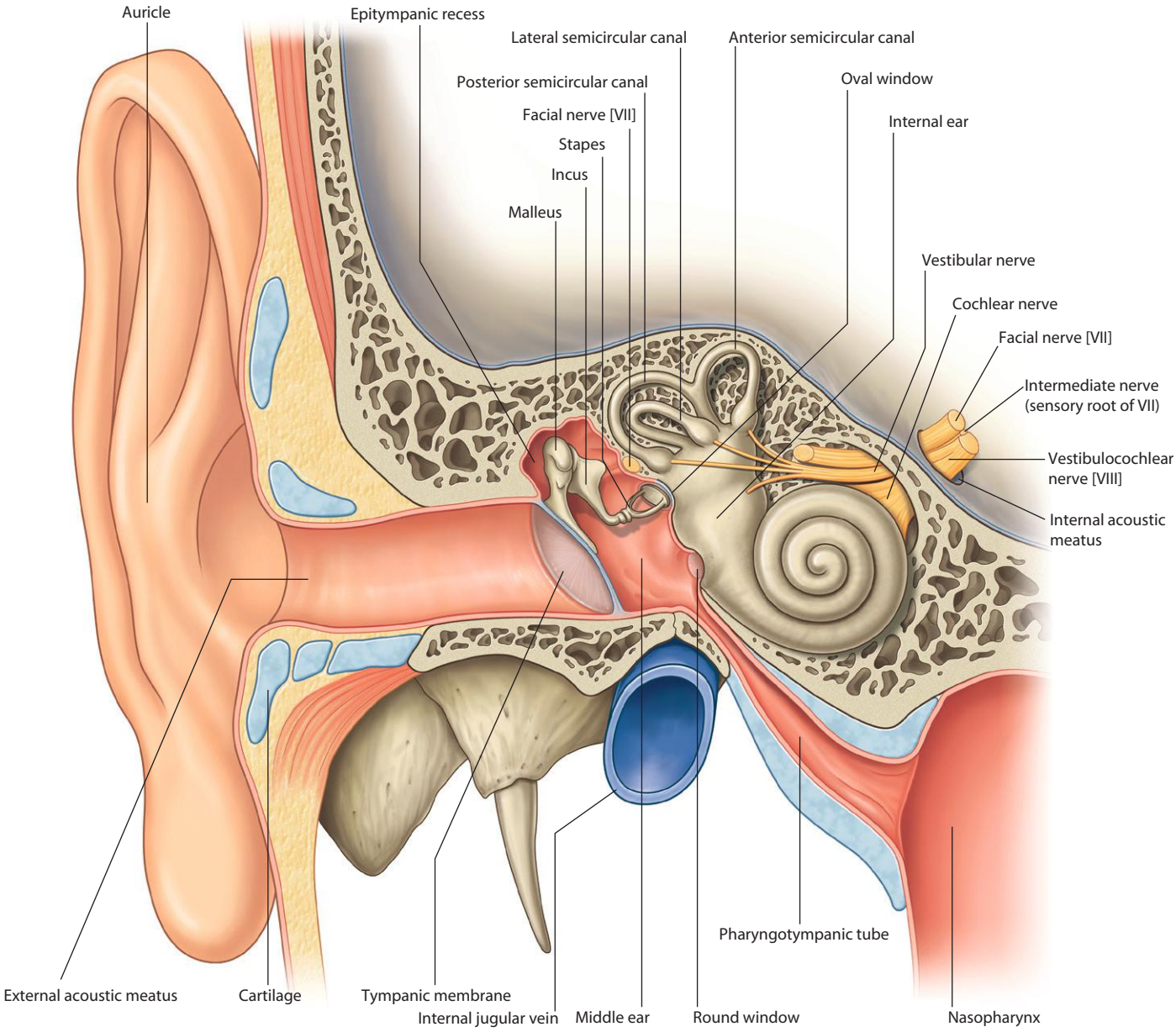

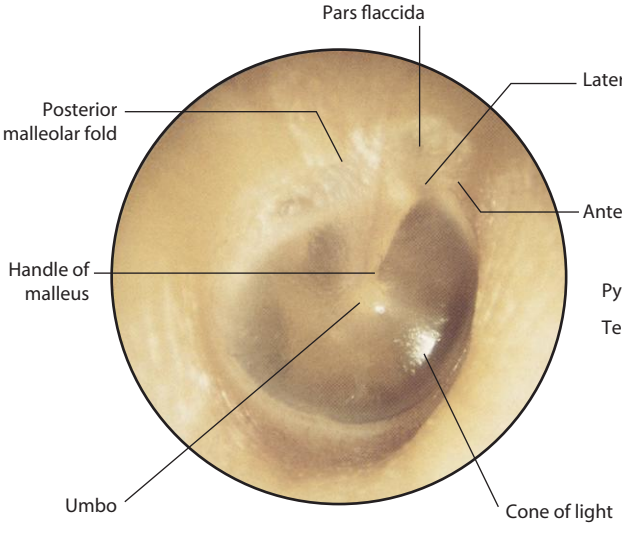

Right tympanic membrane

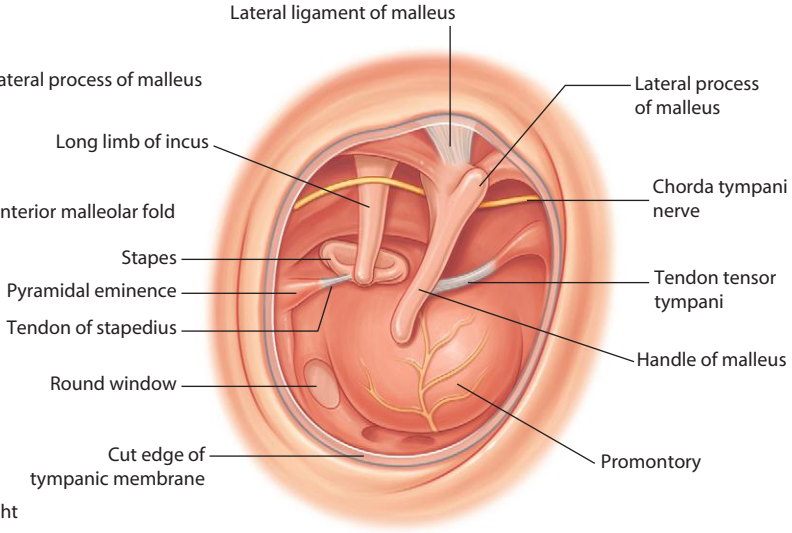

View into right tympanic cavity (tympanic membrane removed)

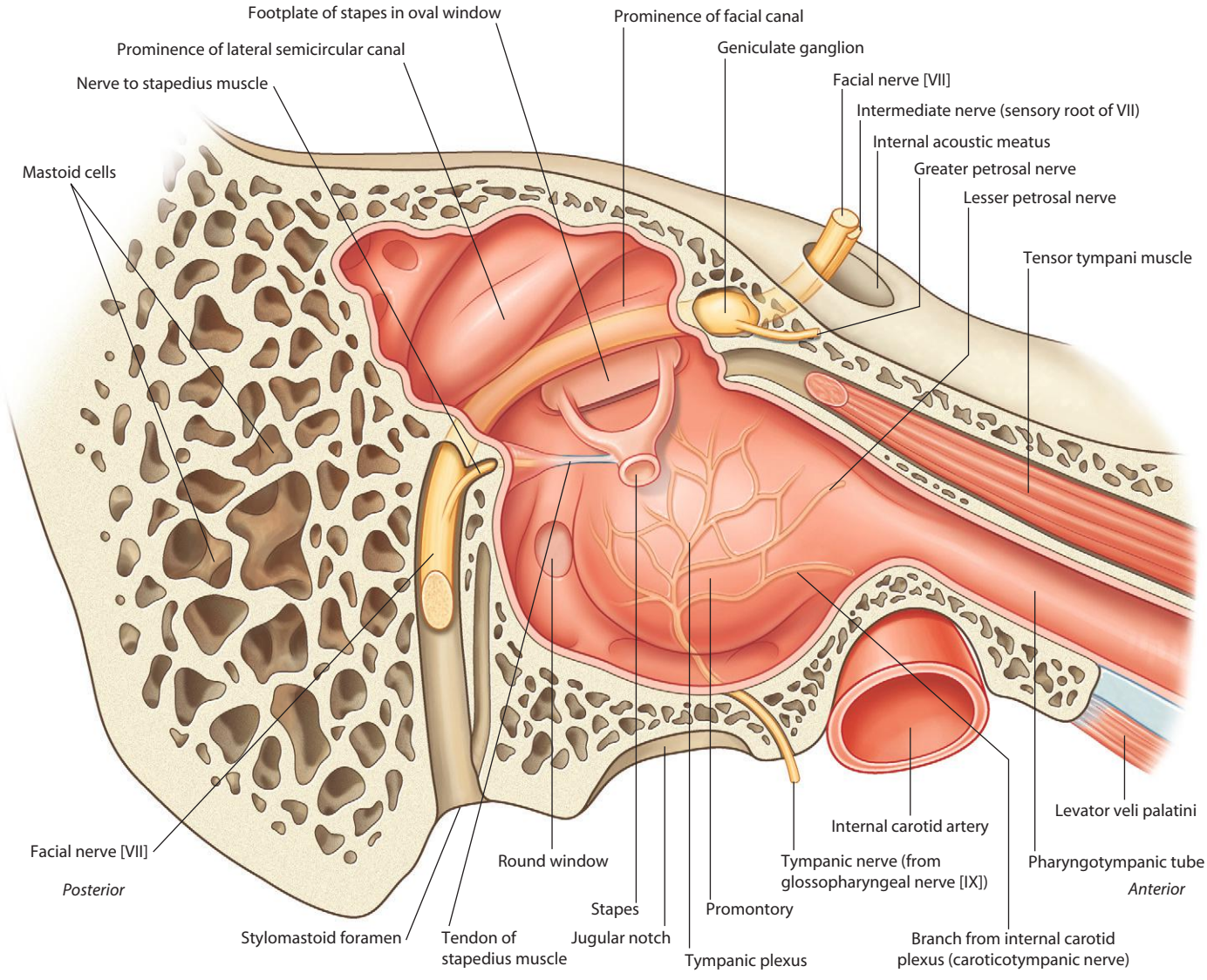

Right medial wall of the middle ear

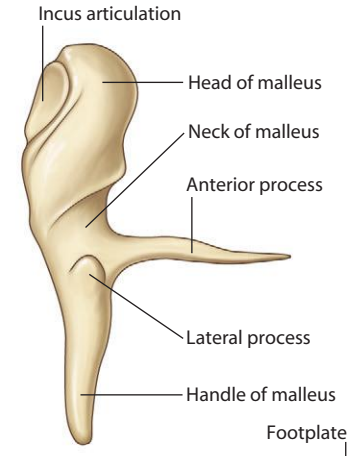

Right malleus (lateral view)

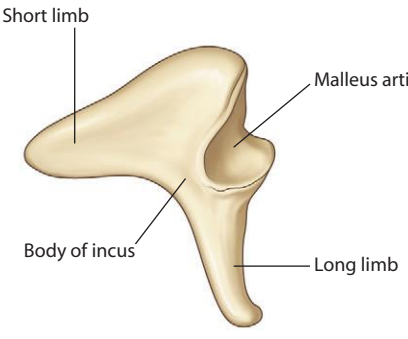

Right incus (lateral view)

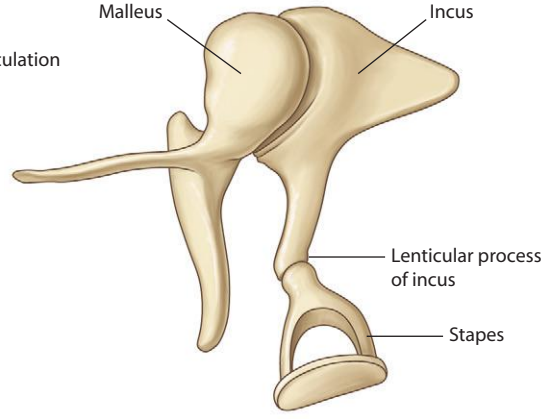

Right auditory ossicles articulated (medial view)

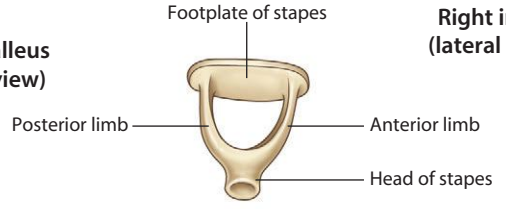

Right stapes (superolateral view)

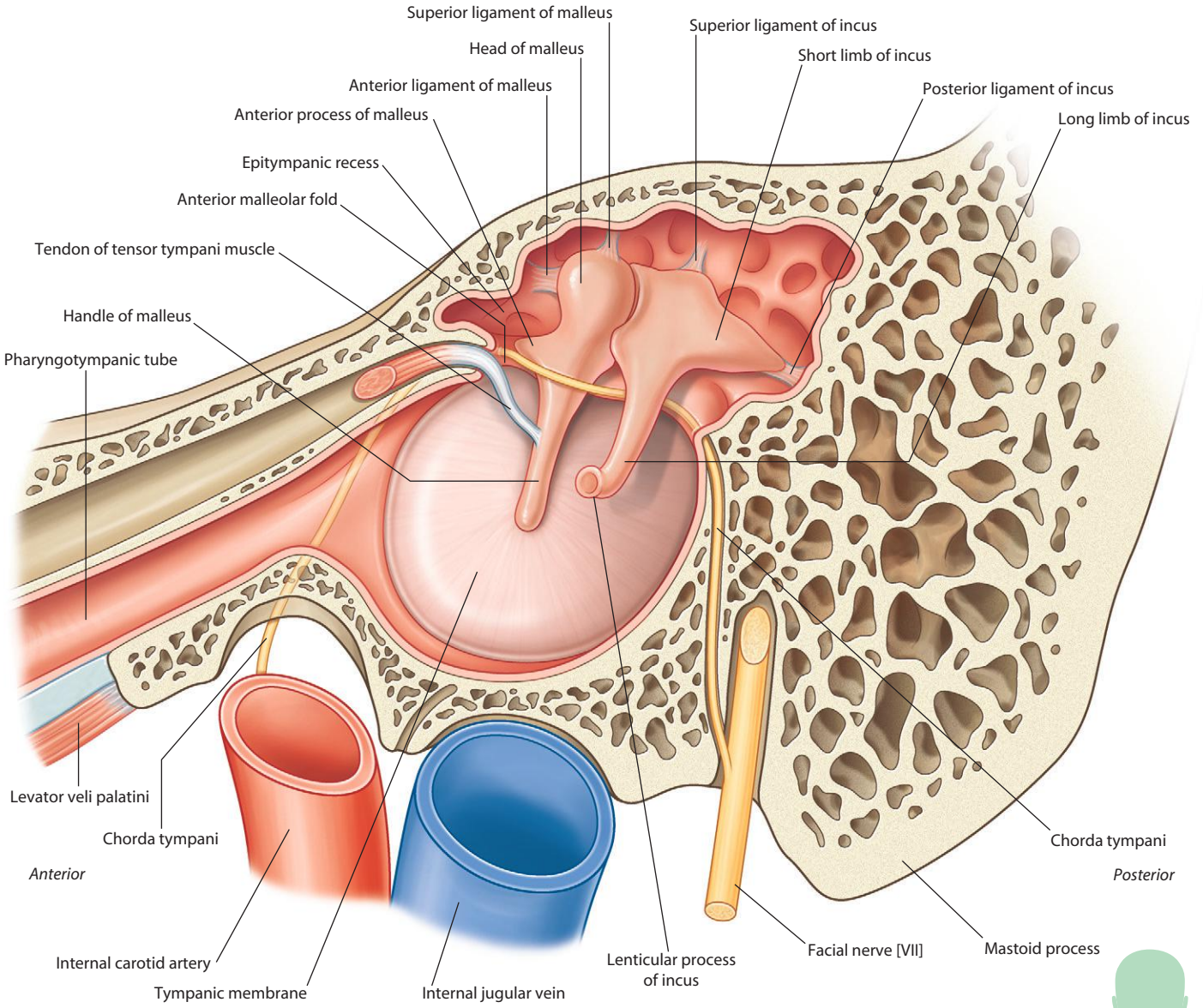

Right lateral wall of the middle ear

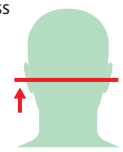

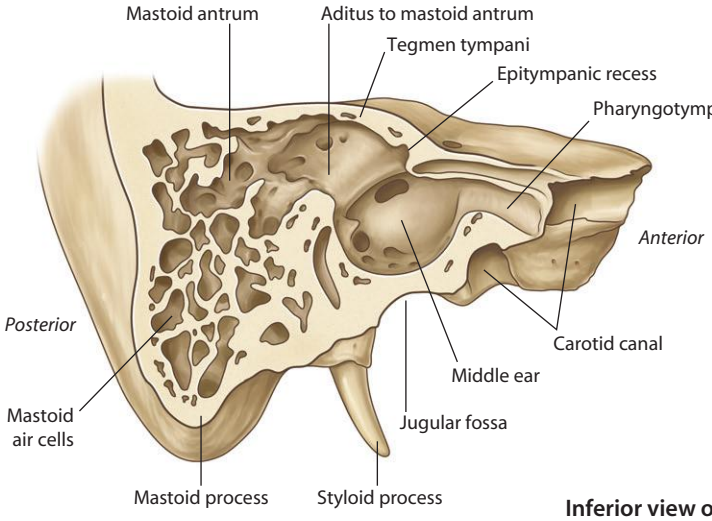

Right mastoid antrum and surrounding bone

Inferior view of the mastoid area on the right side of the skull.
CT image in axial plane

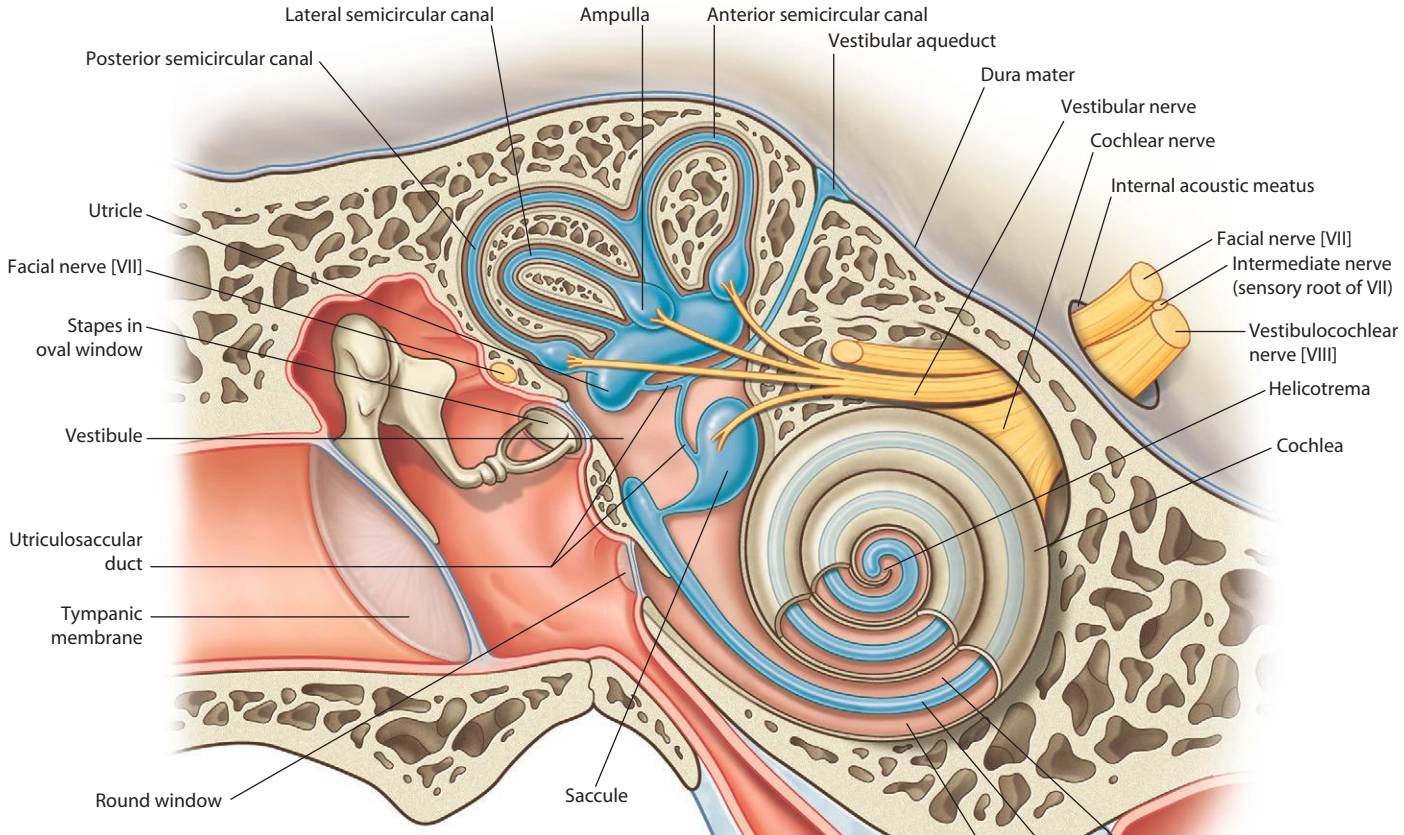

Structures of the internal ear (right)

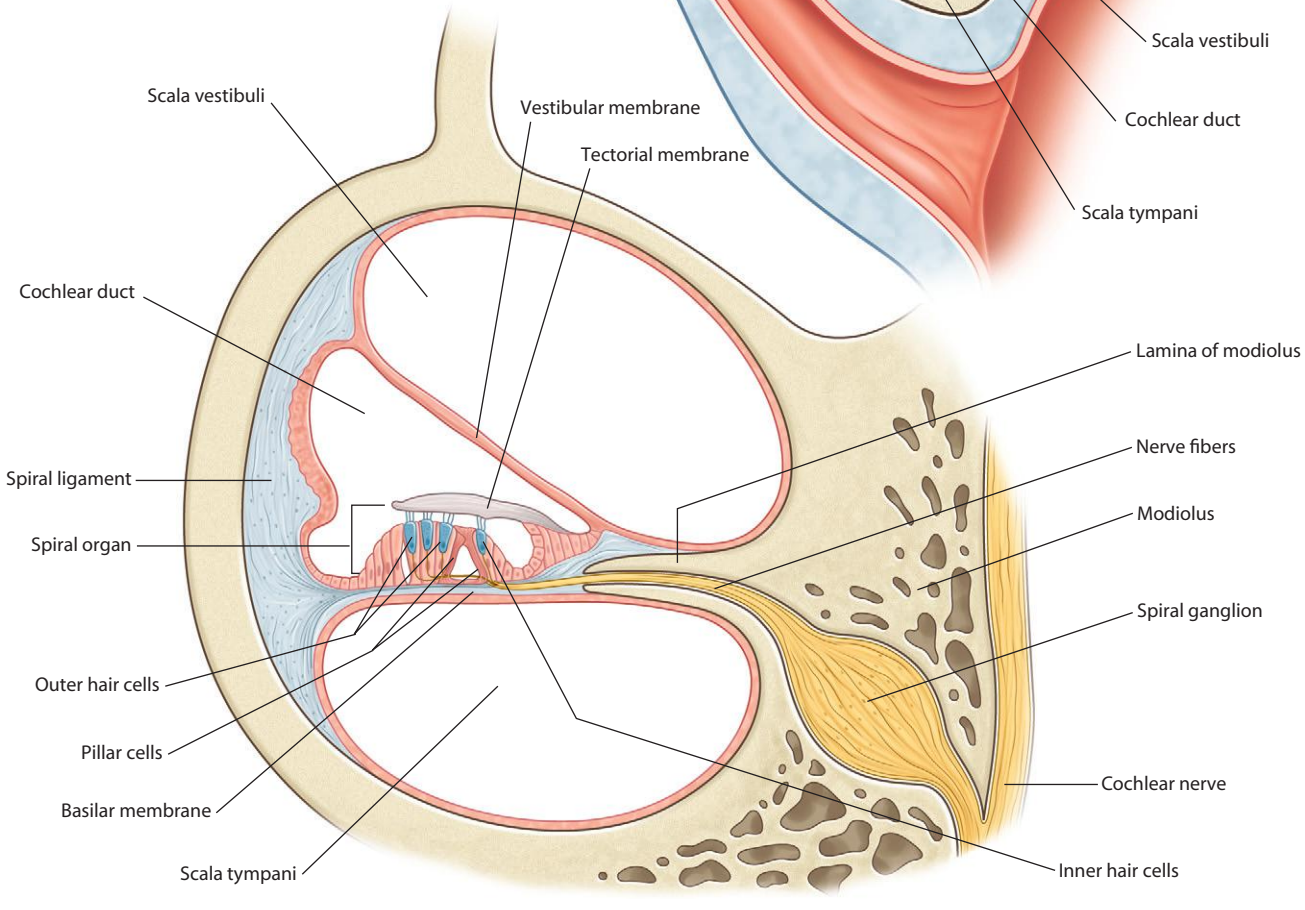

Cross section through cochlea

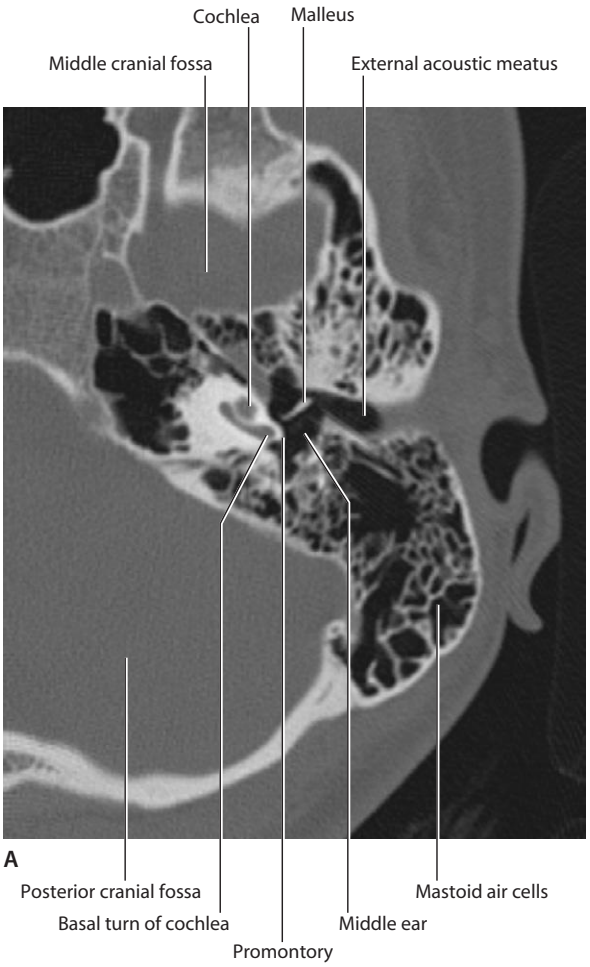

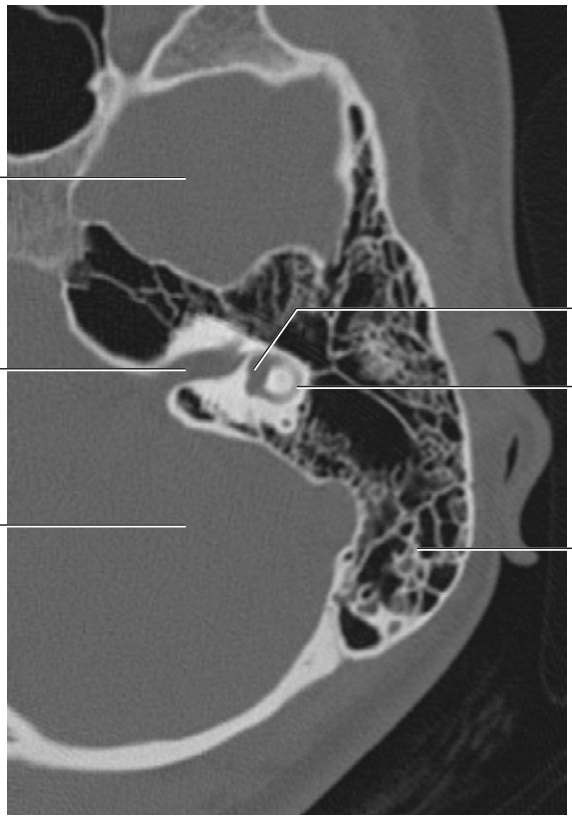

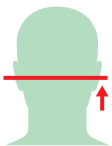

A through C – Axial sections that pass through the left ear from inferior to superior showing various structures in the right ear and their relationships with surrounding structures.
CT images in axial plane

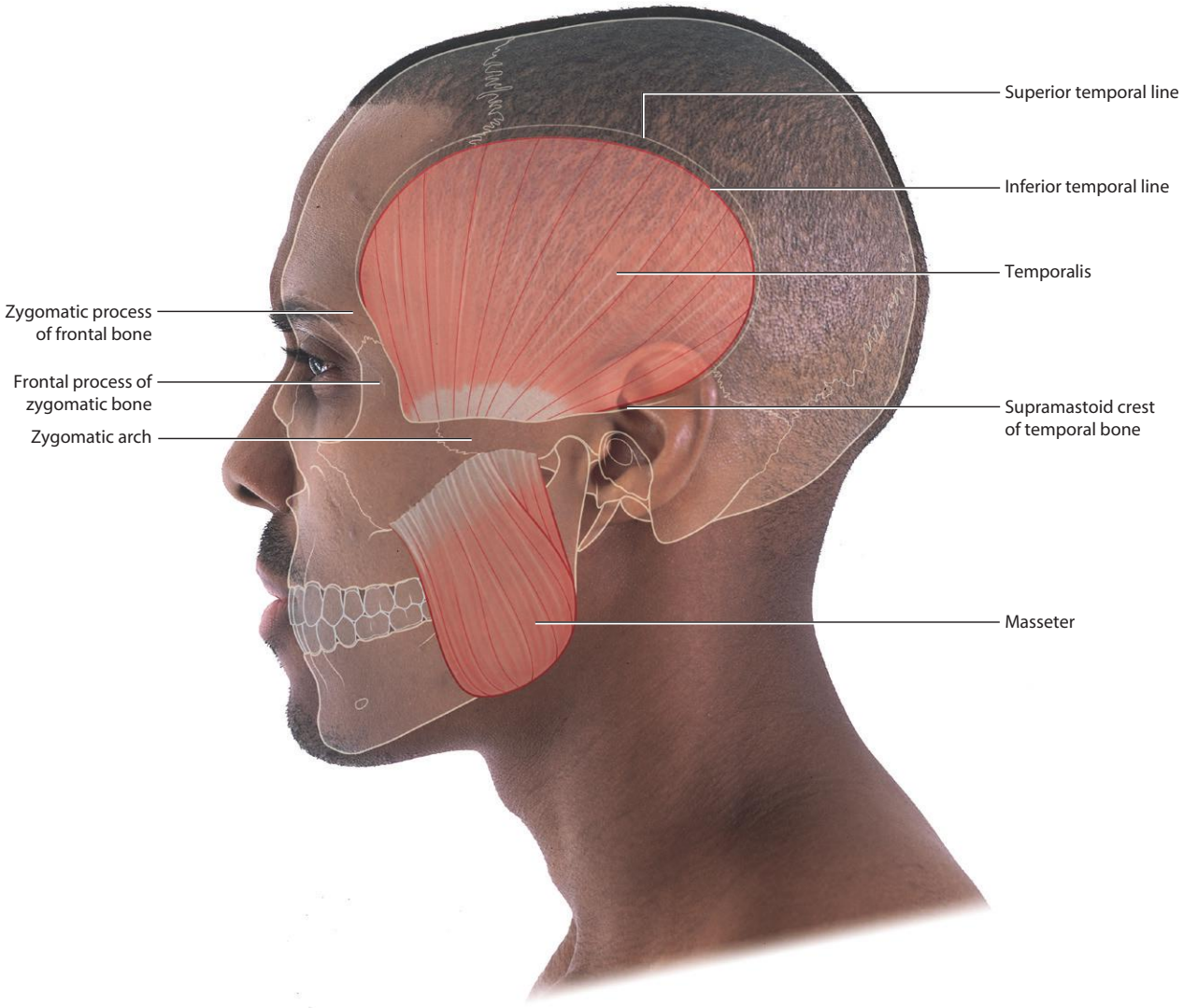

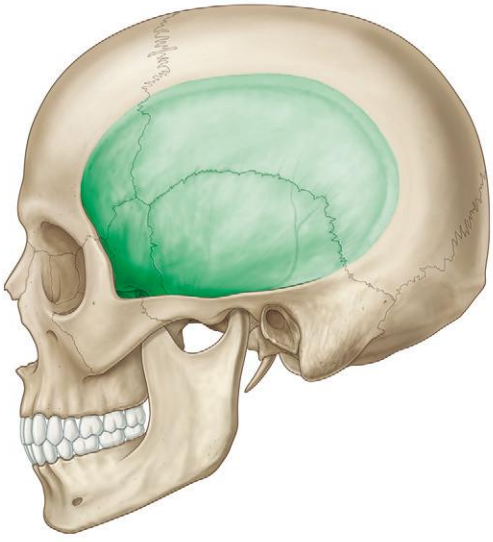

Temporal fossa

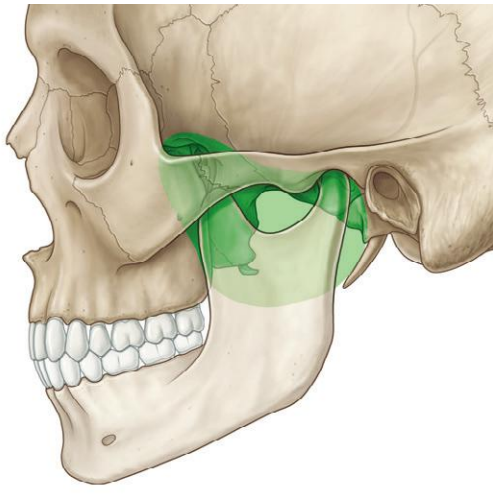

Infratemporal fossa

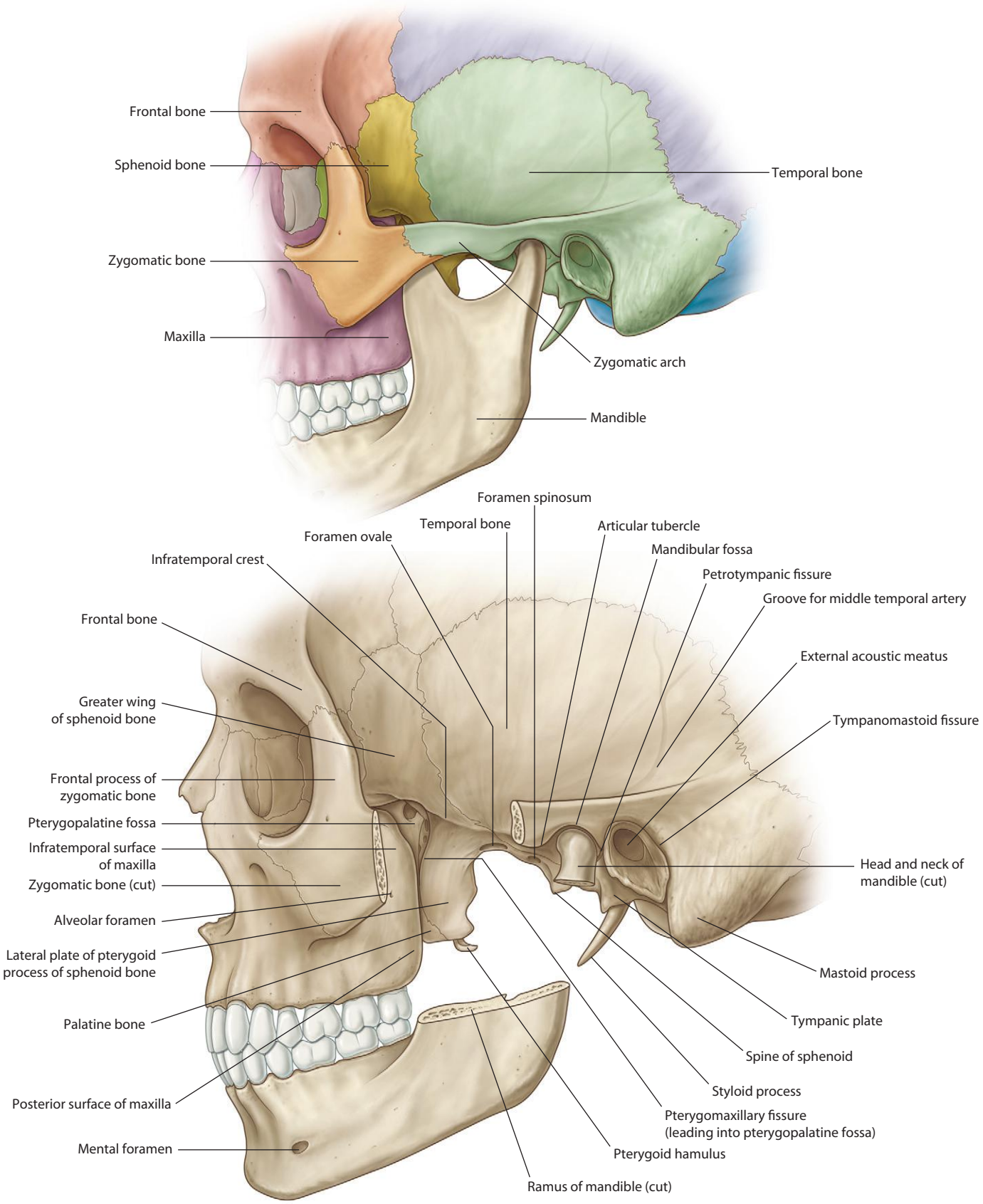

Bones of the temporal and infratemporal fossae

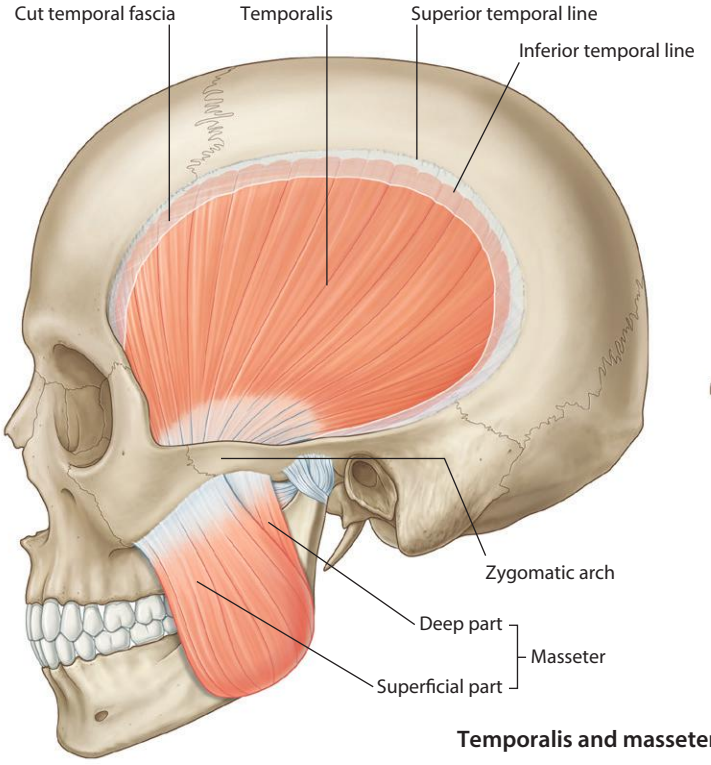

Temporalis and masseter

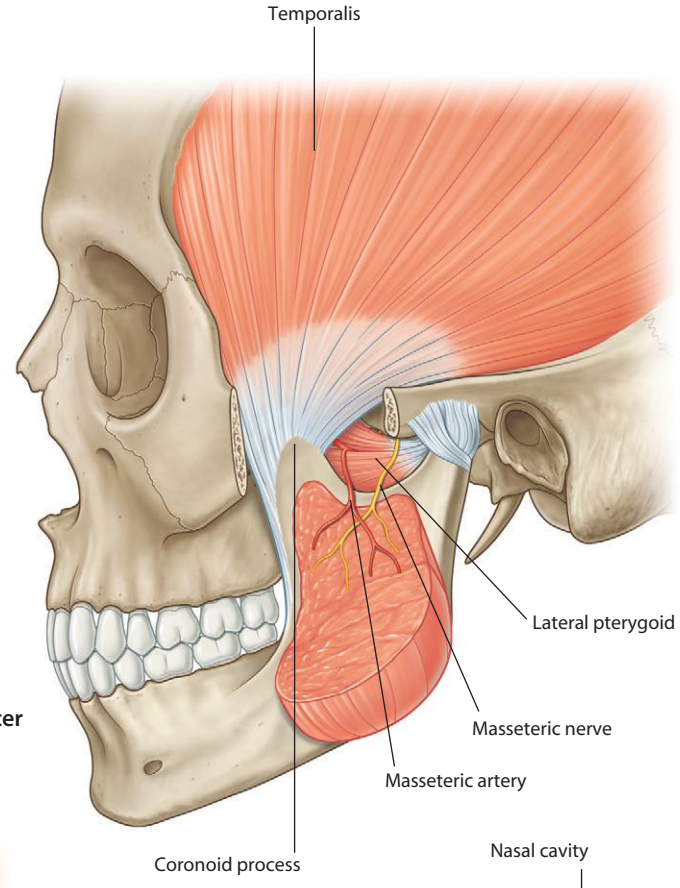

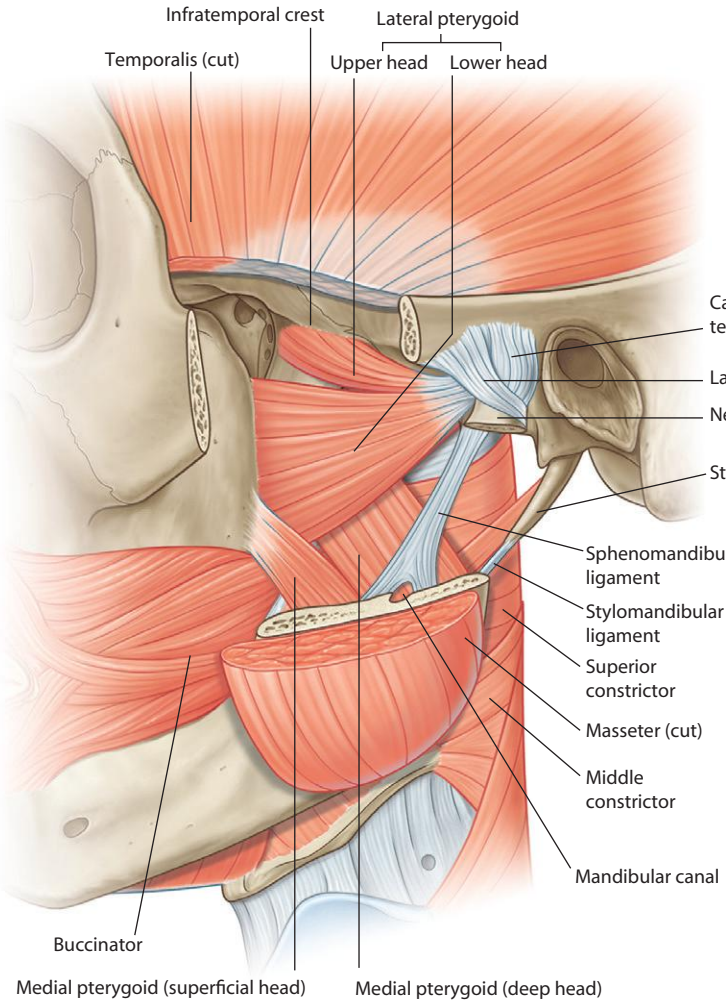

Muscles of the infratemporal fossa

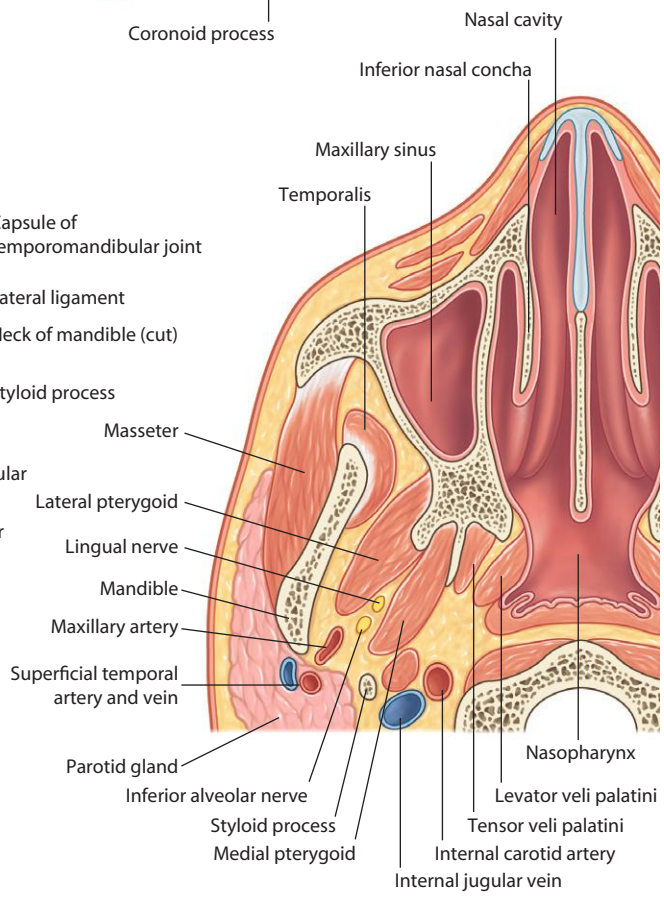

Horizontal (axial) through infratemporal fossa (inferior view)

Muscles of the infratemporal fossa

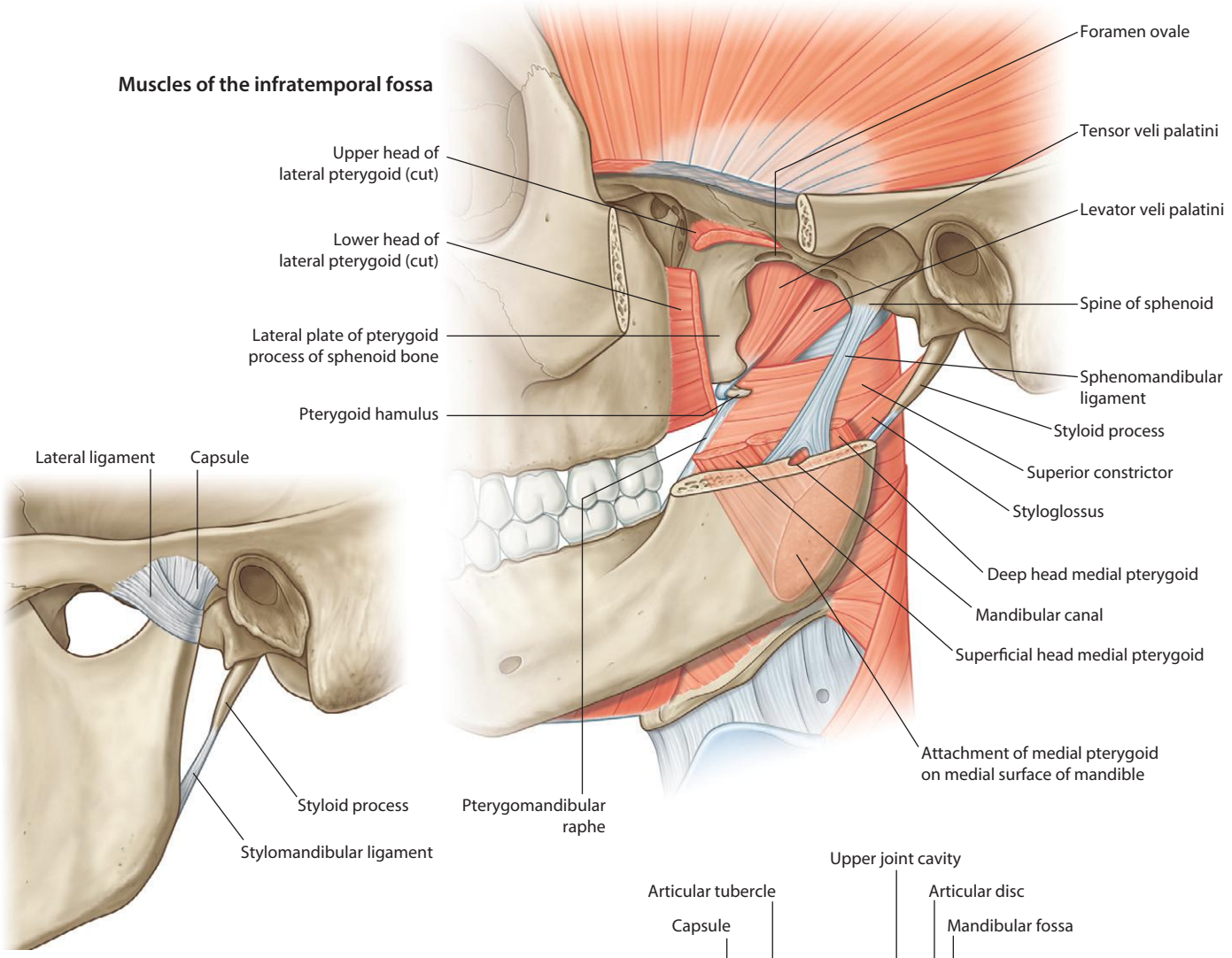

Temporomandibular joint (lateral view)

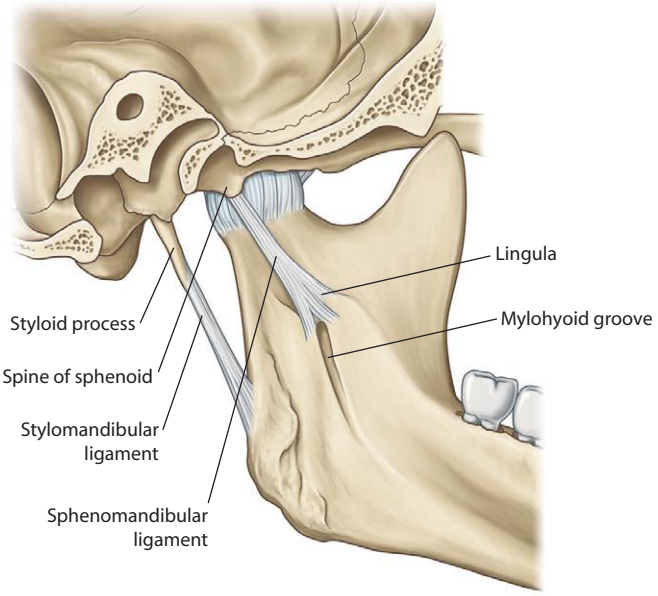

Temporomandibular joint (medial view)

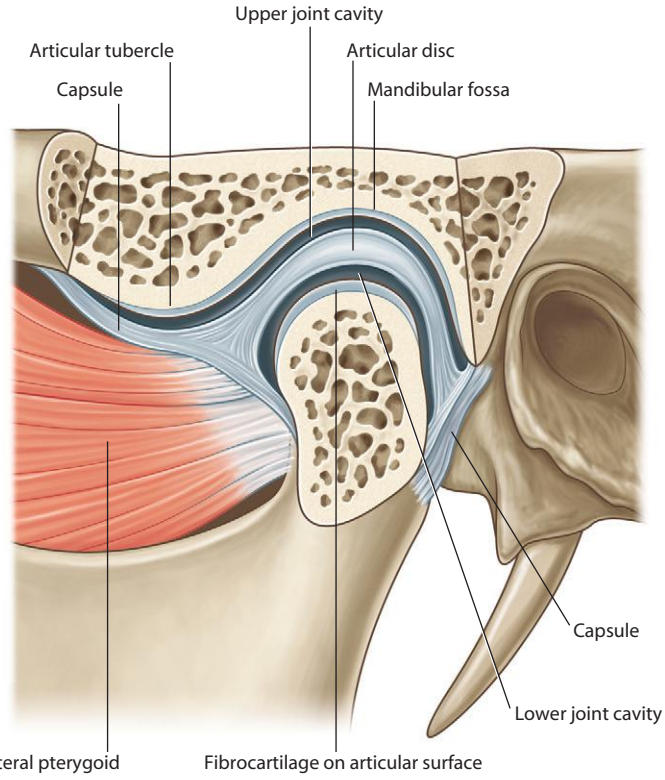

Sagittal section through temporomandibular joint

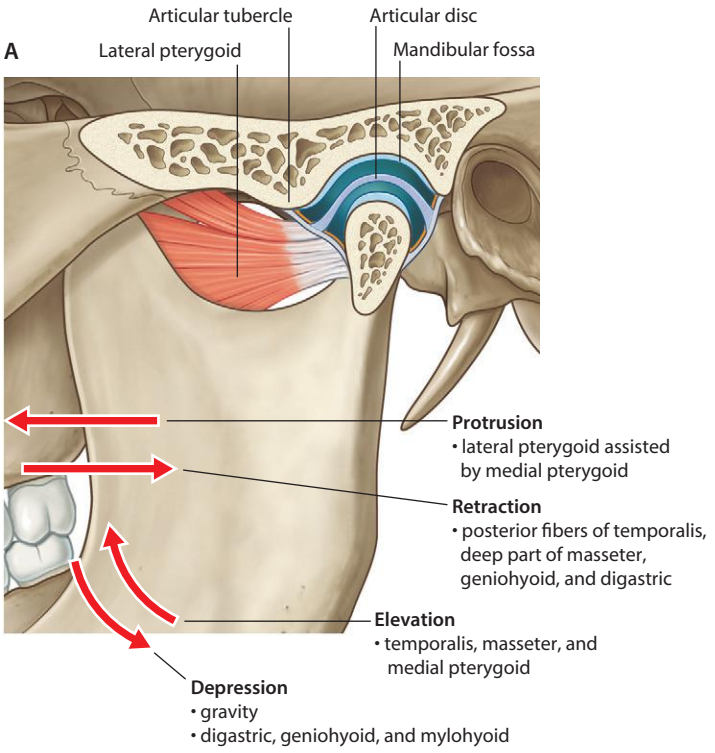

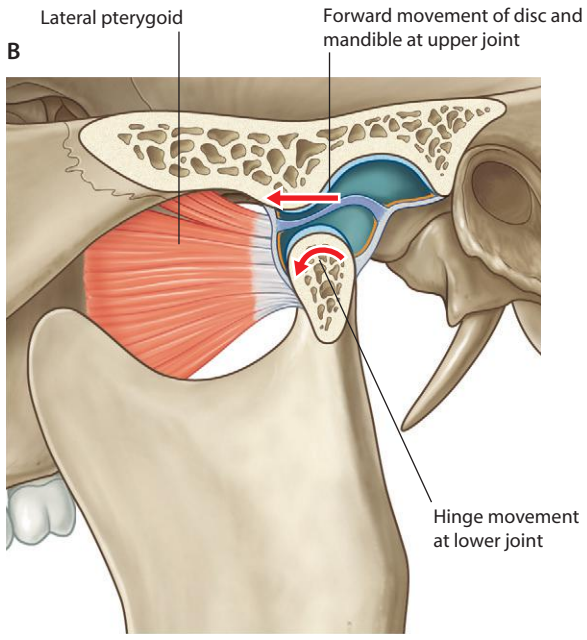

Movements of the temporomandibular joint
A. Mouth closed B. Mouth open

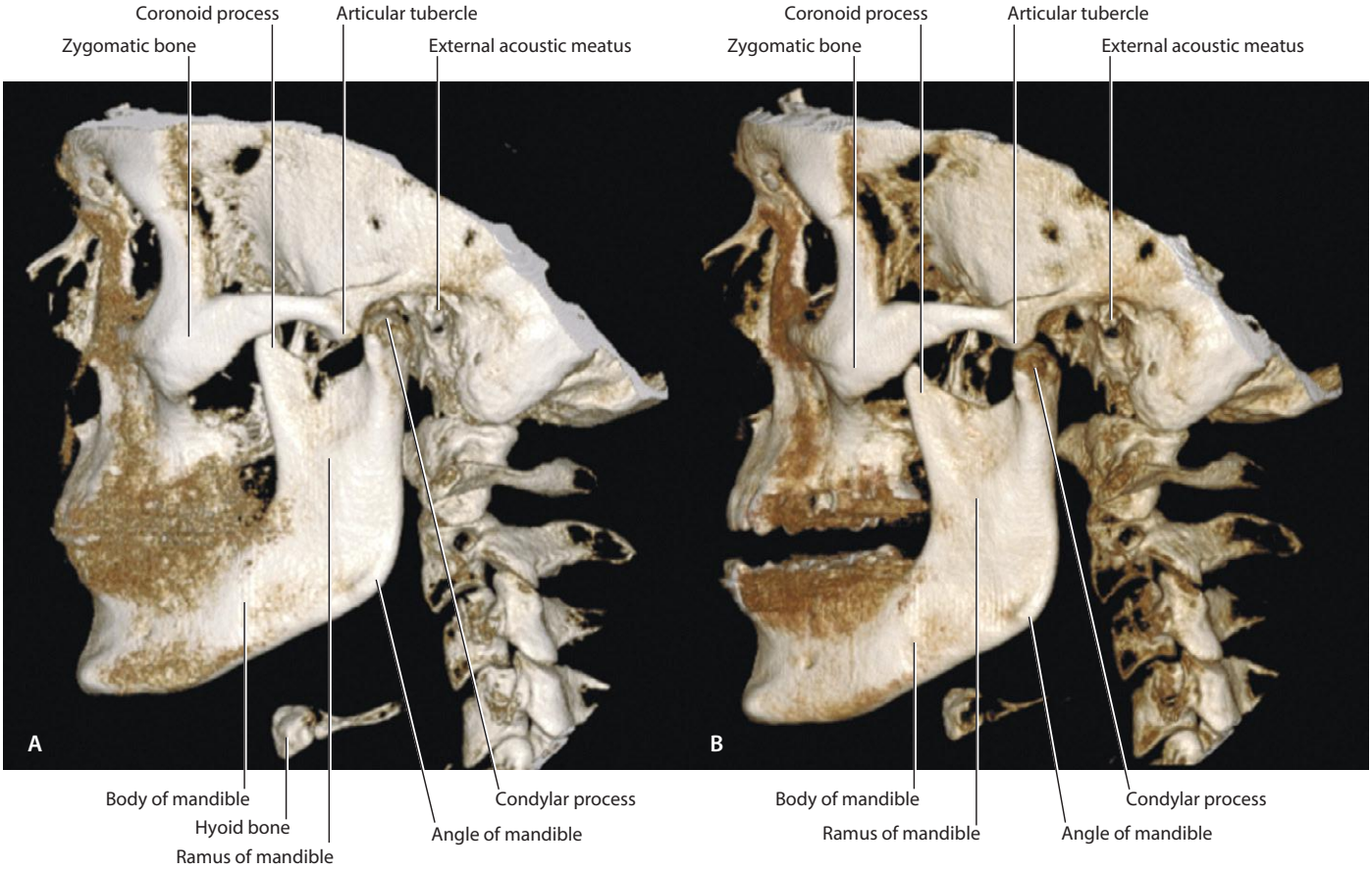

Lateral view of the right temporomandibular joint
A. Mouth closed B. Mouth open.
Image taken with Cone Beam Computerized Tomography (CBCT) technology viewed in the radiographic mode

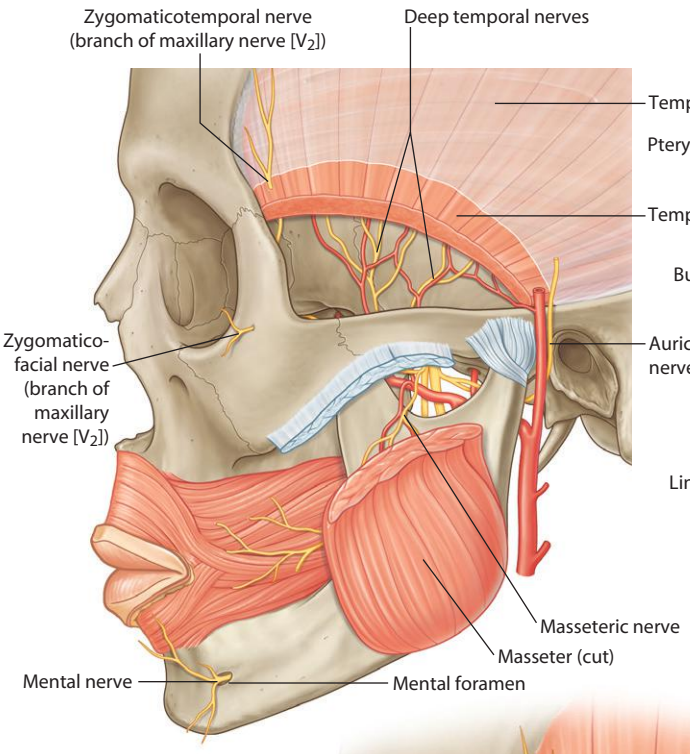

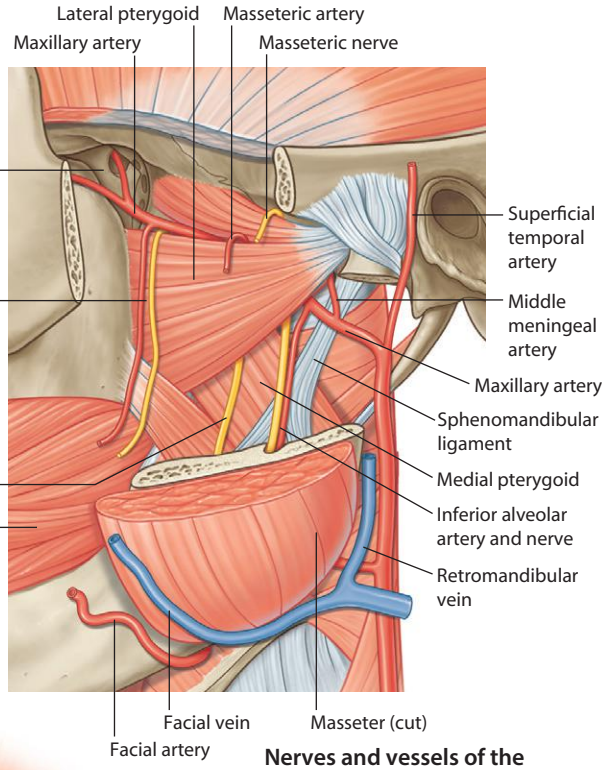

Nerves and vessels of the infratemporal fossa

Nerves of the temporal and infratemporal fossa

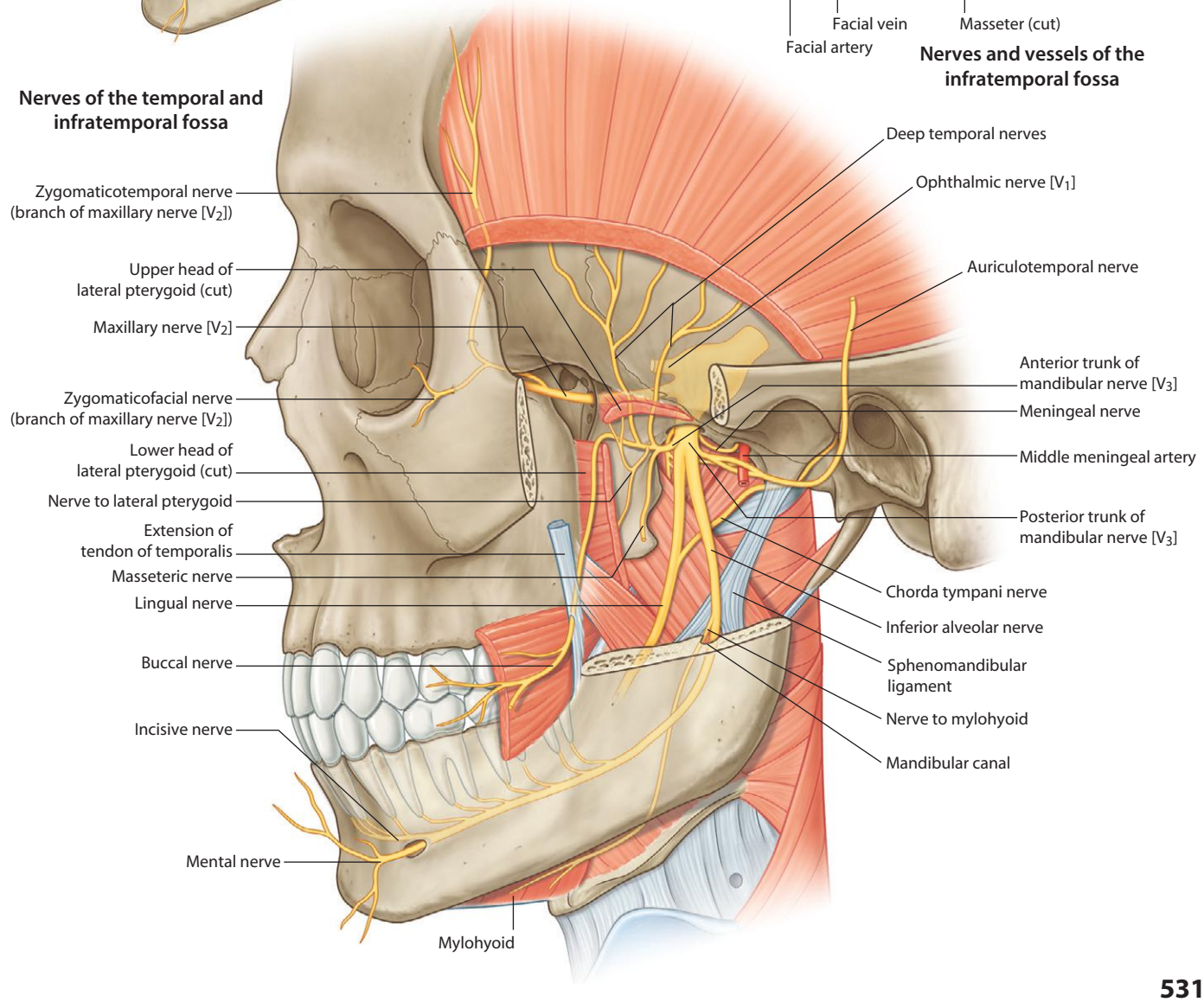

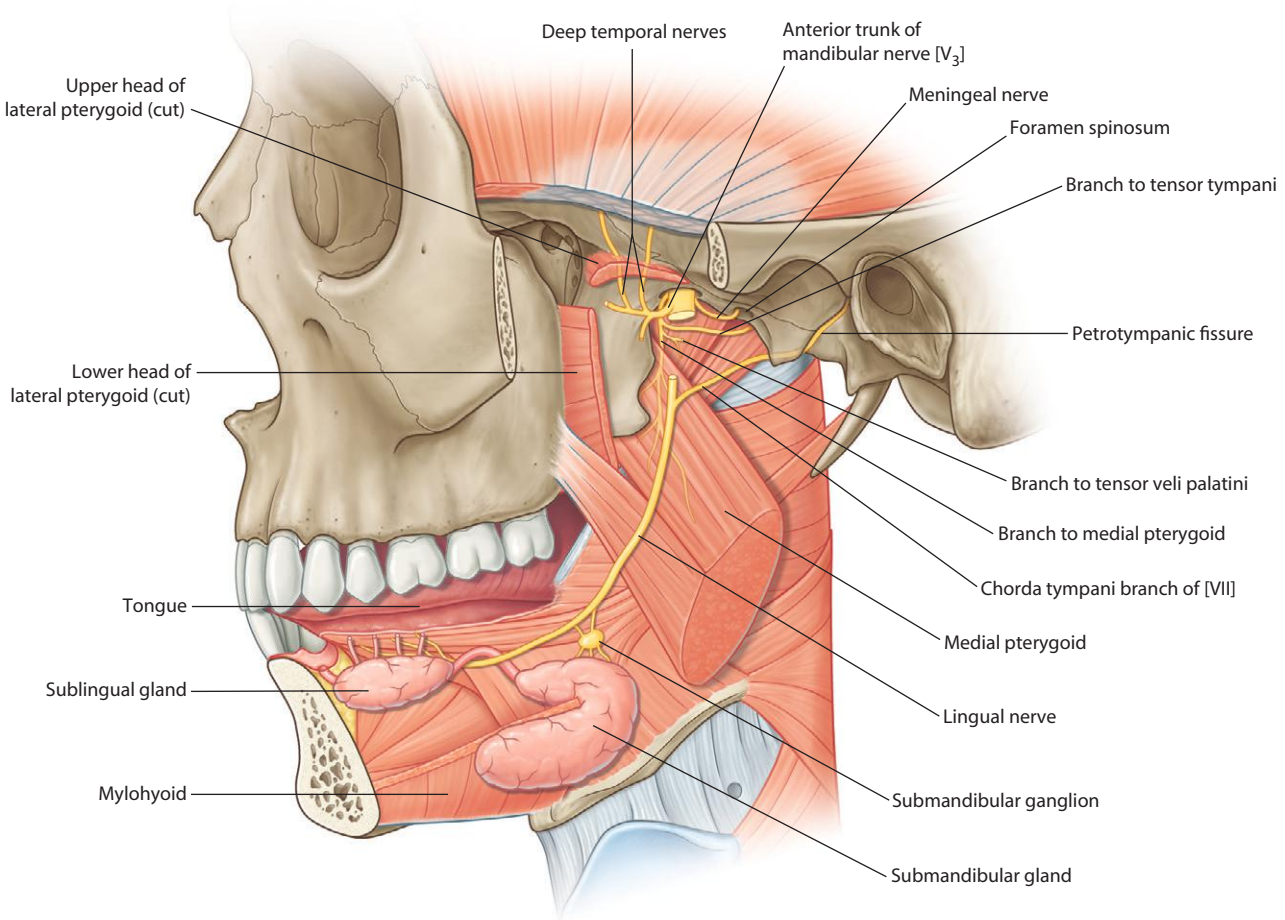

Nerves of the infratemporal fossa

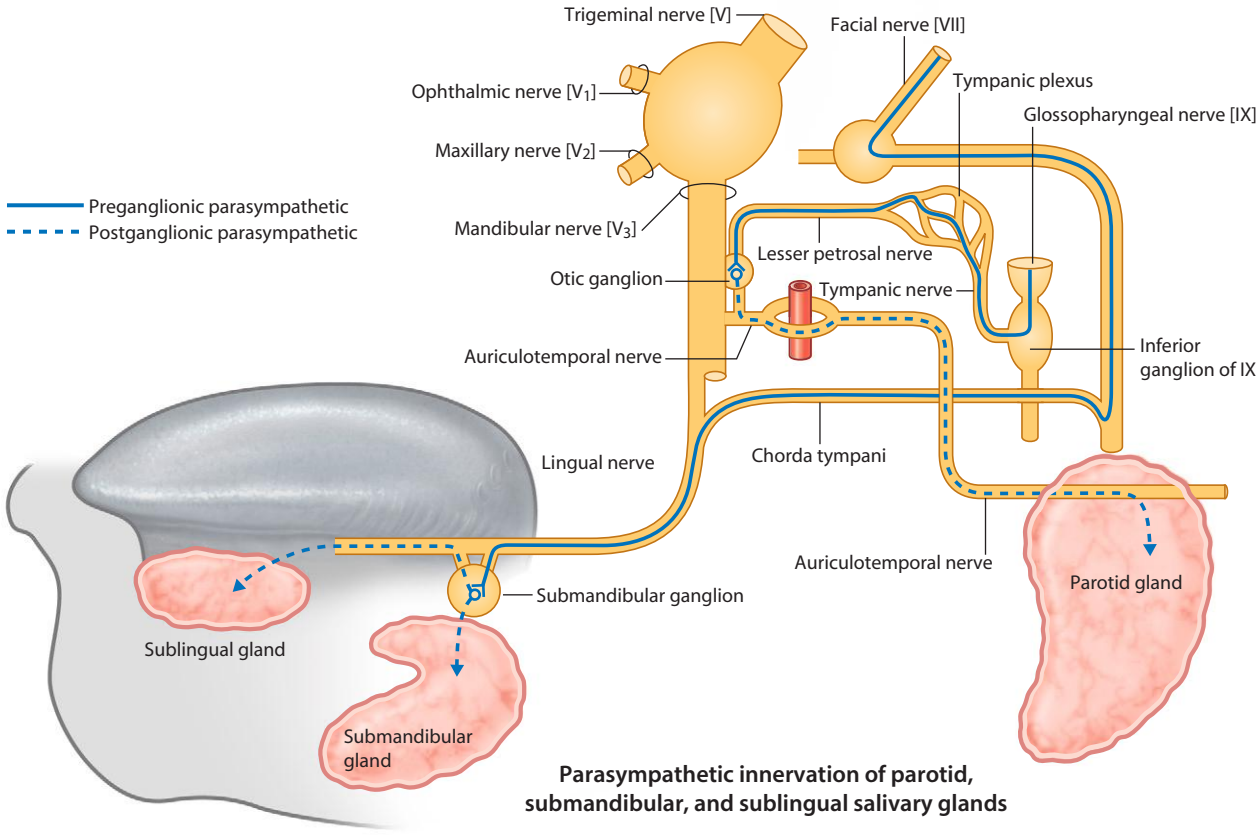

Parasympathetic innervation of parotid, submandibular, and sublingual salivary glands

tahir99-VRG & vip.persianss.ir

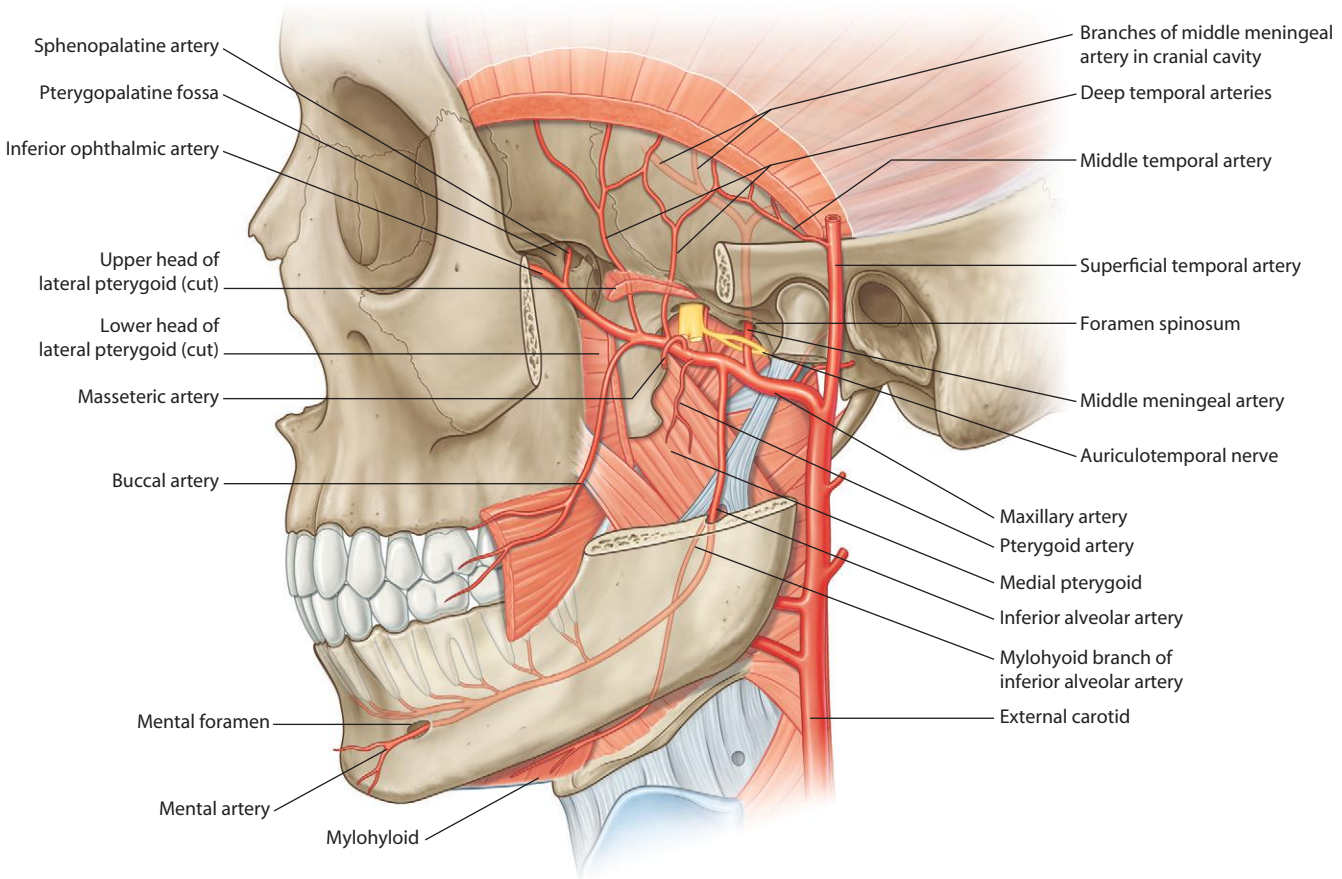

Arteries of the temporal and infratemporal fossae

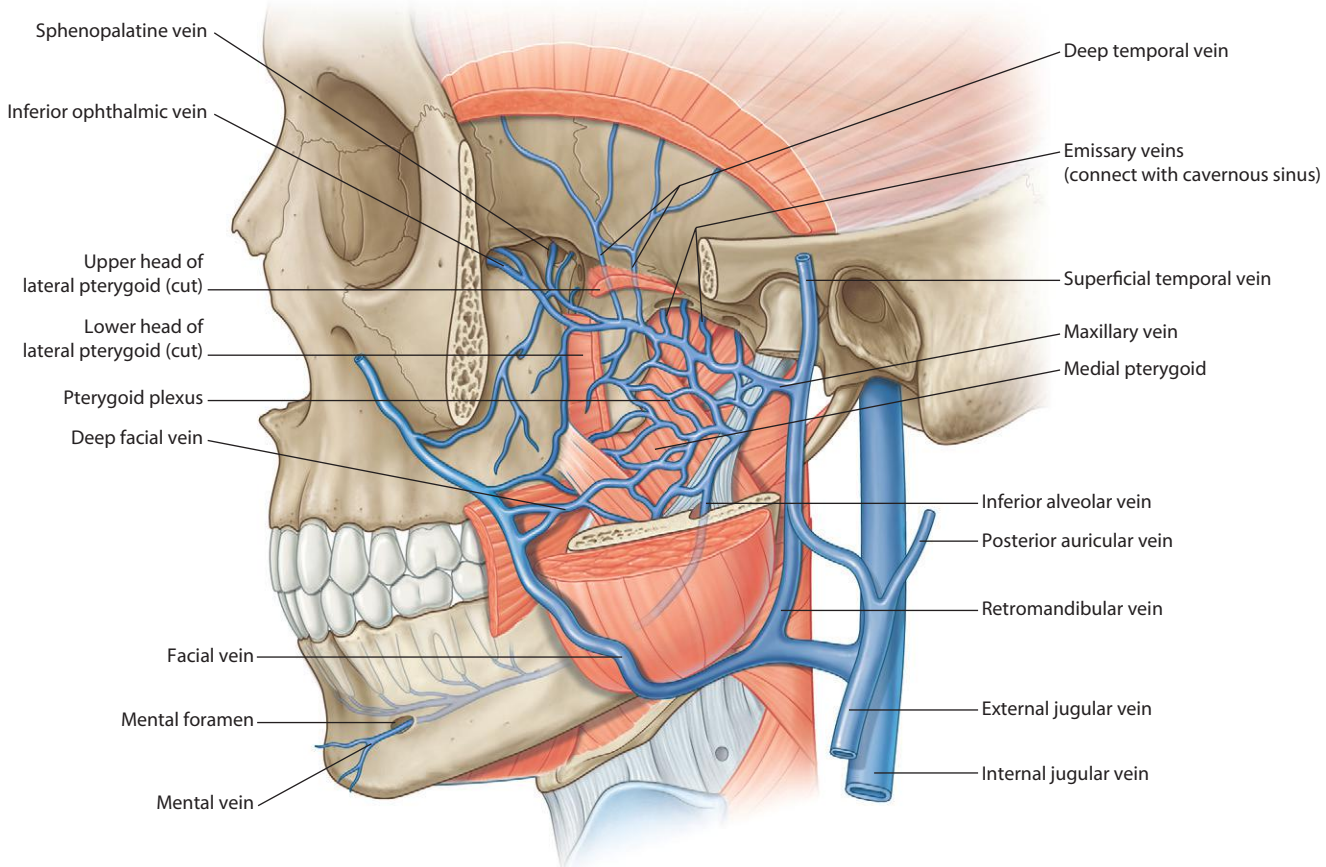

Veins of the temporal and infratemporal fossae

tahir99-VRG & vip.persianss.ir

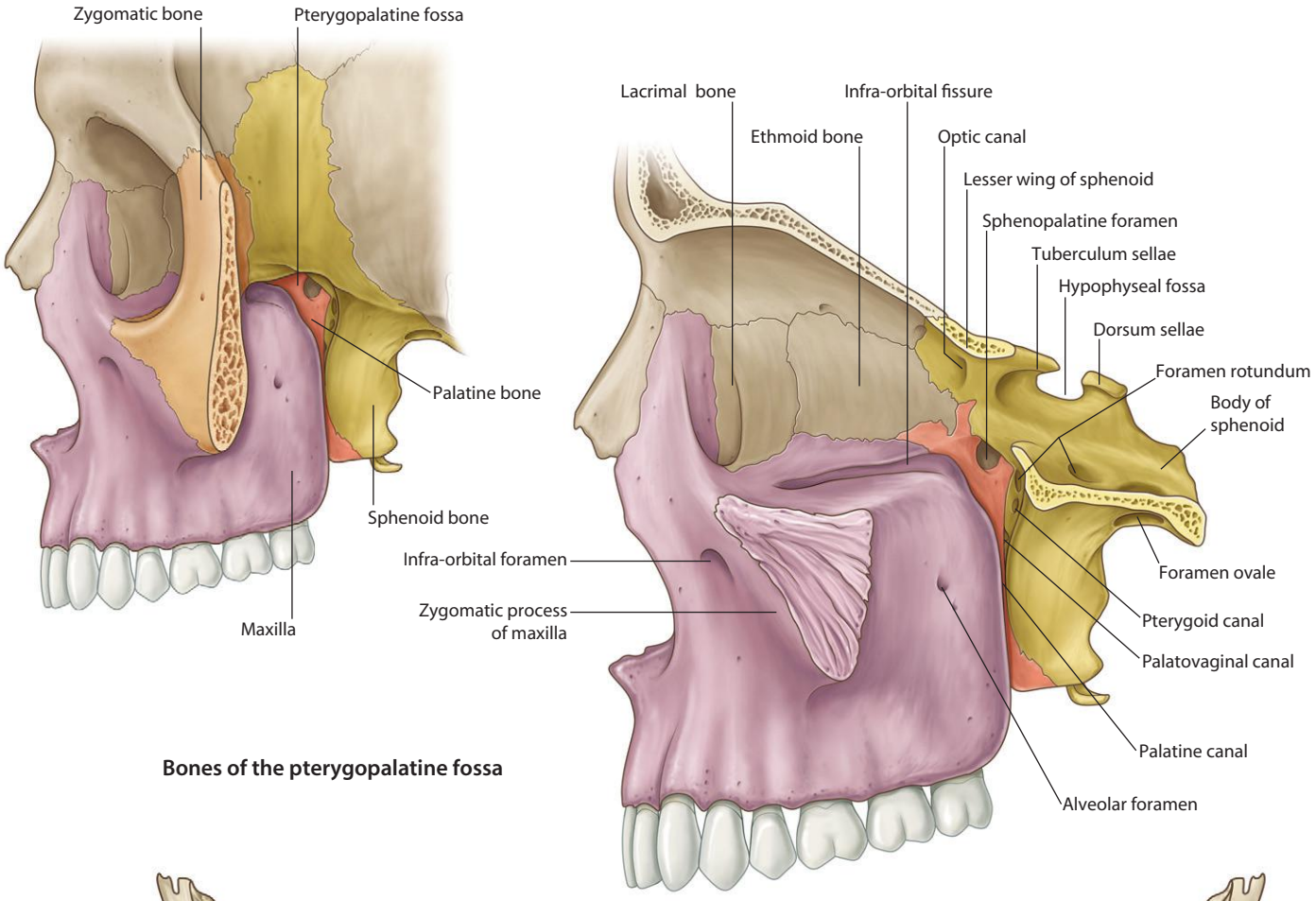

Bones of the pterygopalatine fossa

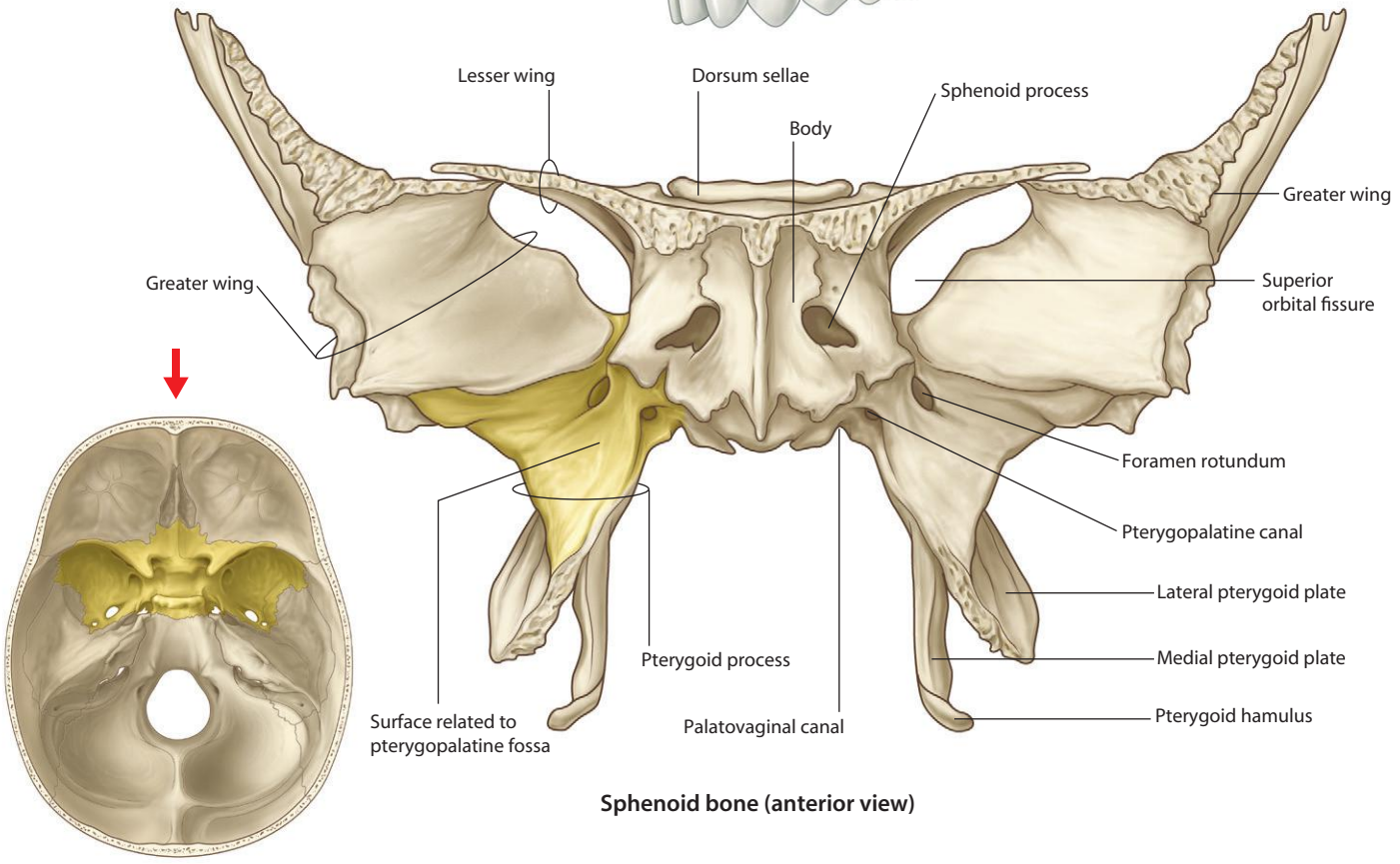

Sphenoid bone (anterior view)

tahir99-VRG & vip.persianss.ir

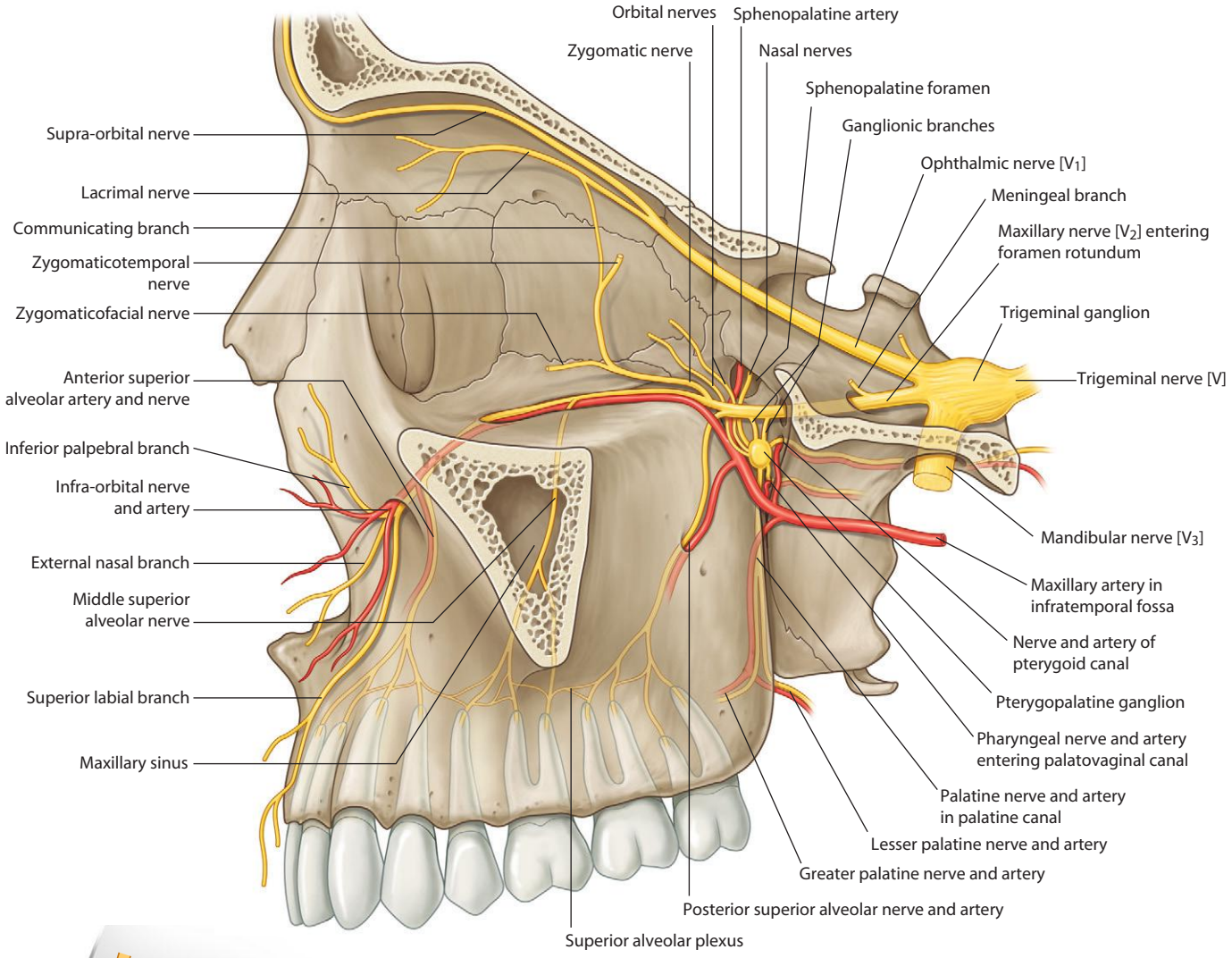

Nerves and arteries of the pterygopalatine fossa

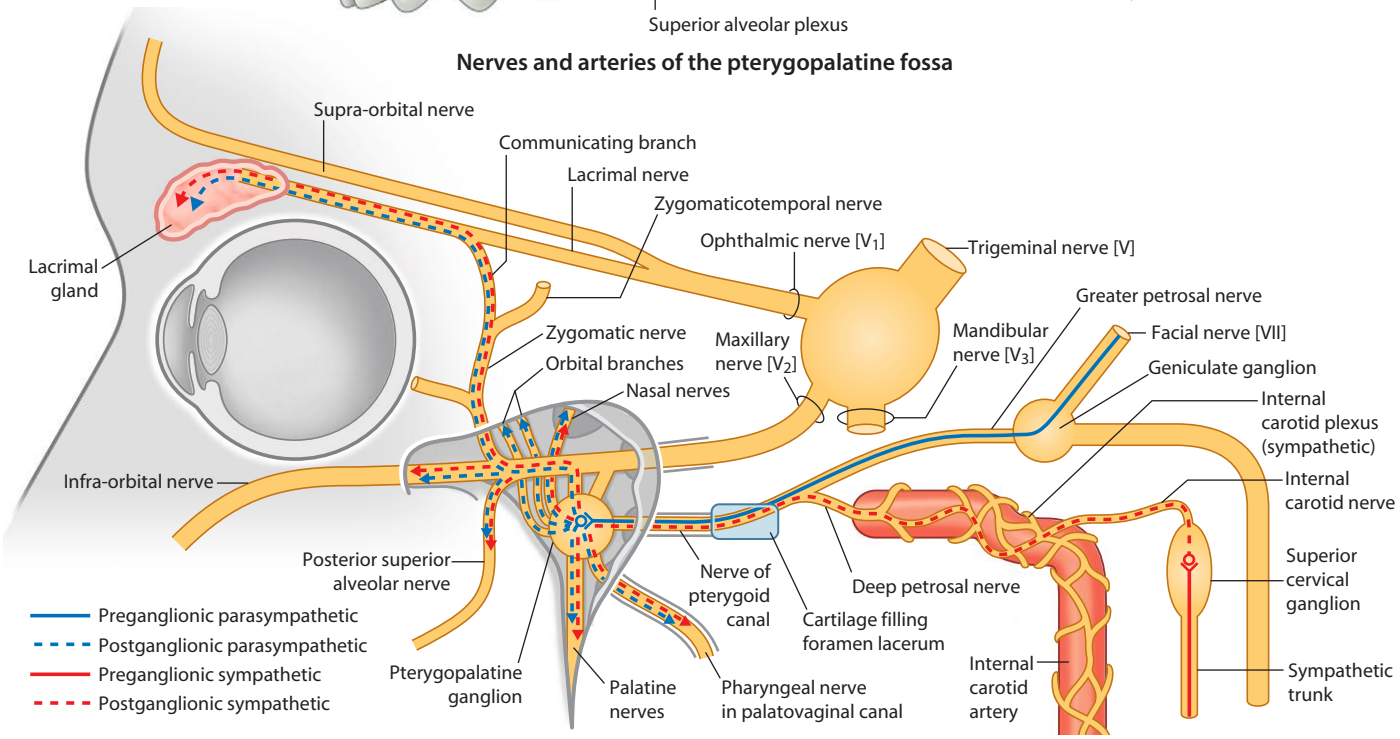

Visceral efferent (motor) pathways through the pterygopalatine fossa

tahir99-VRG & vip.persianss.ir

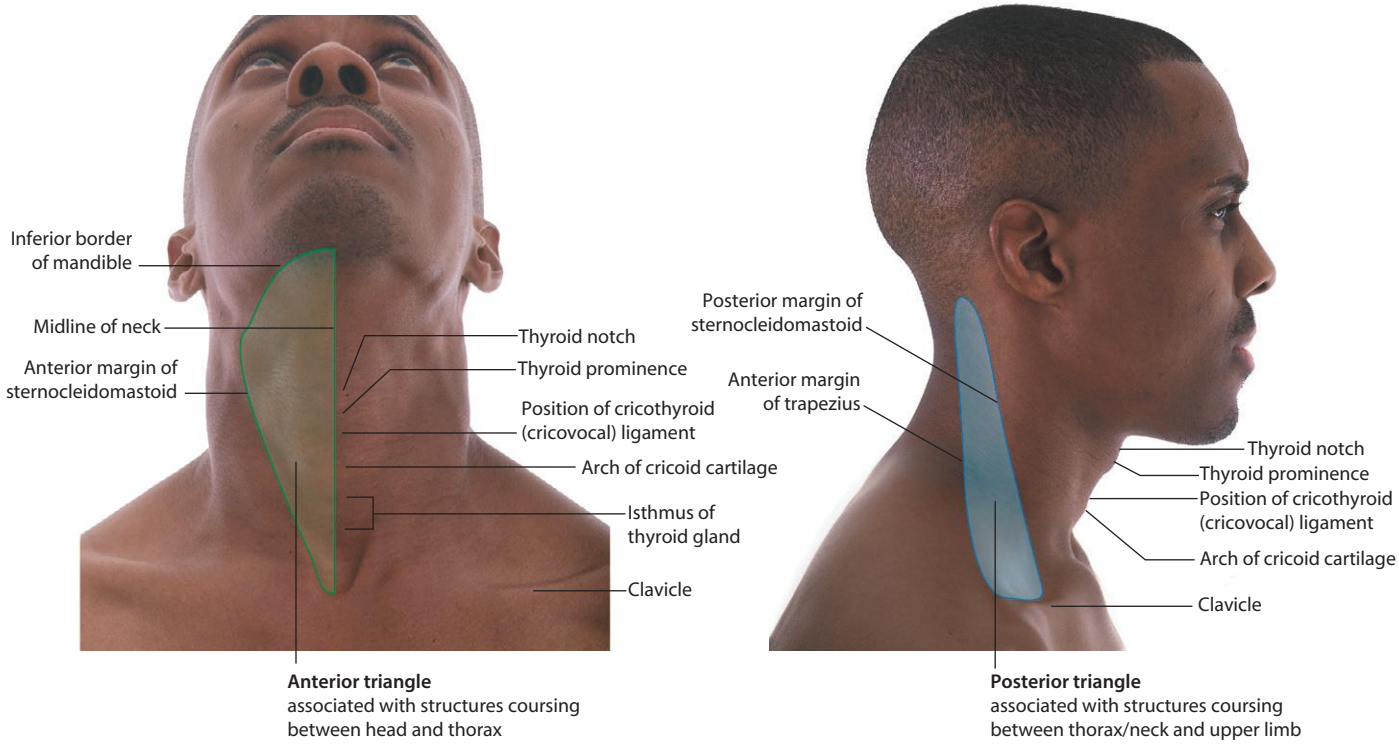

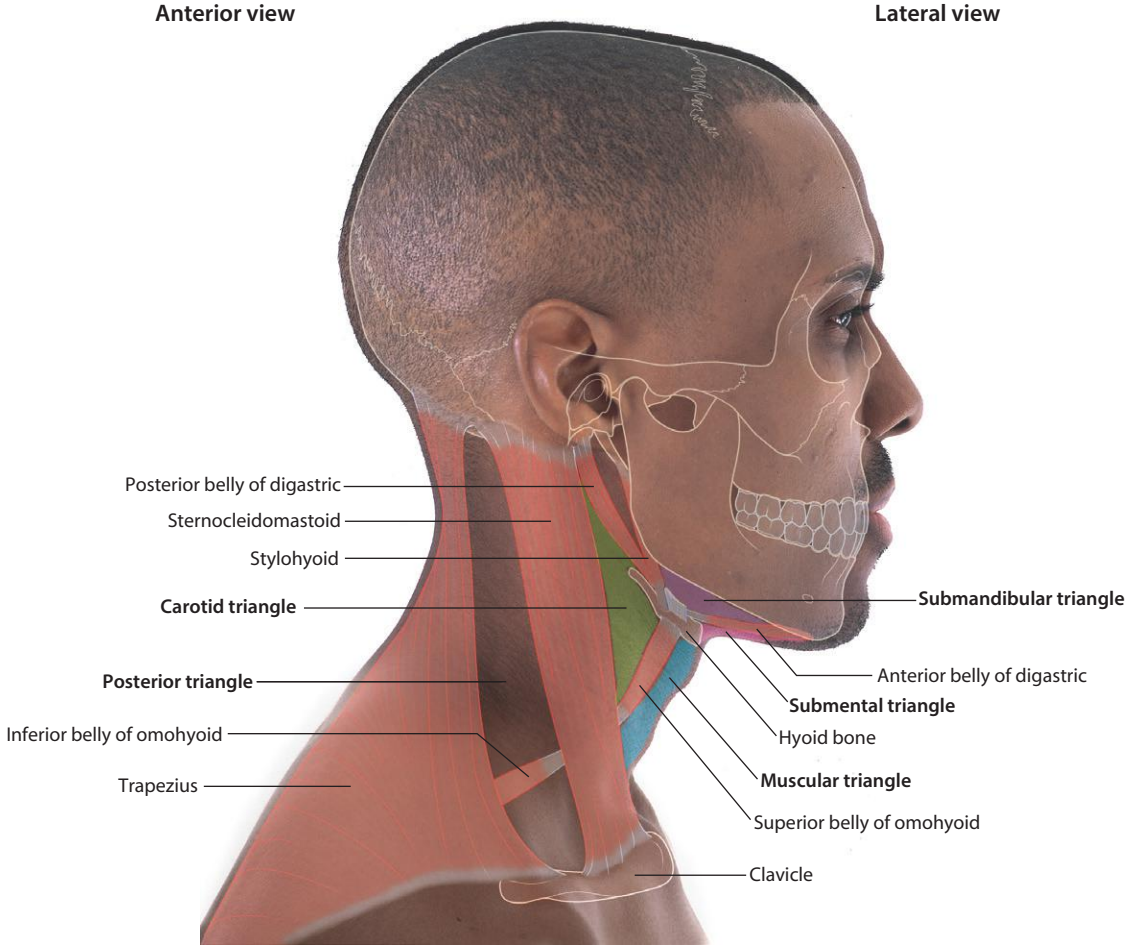

Boundaries and subdivisions of the anterior triangle and boundaries of the posterior triangle

tahir99-VRG & vip.persianss.ir

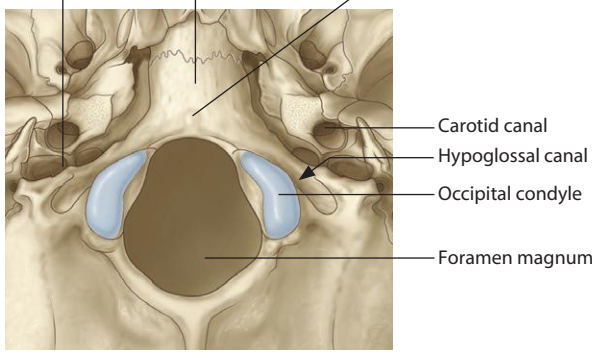

Occipital condyles of skull (inferior view)

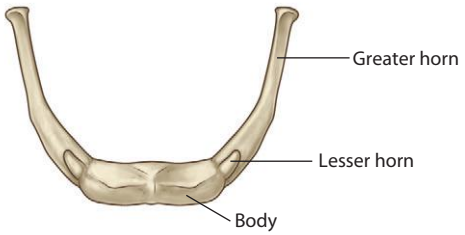

Hyoid bone (superior view)

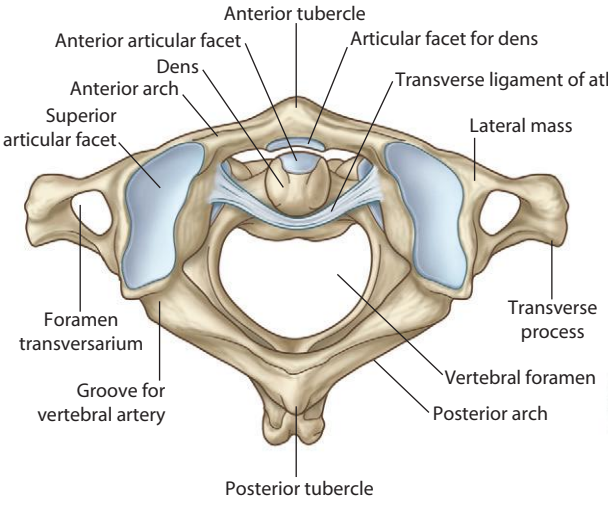

Atlas and axis (superior view)

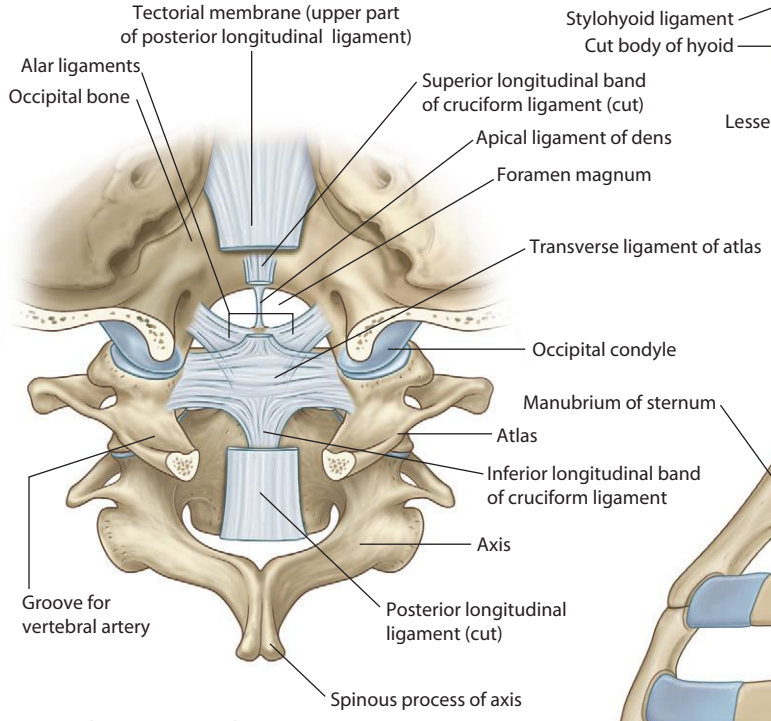

Atlanto-occipital joint (posterior view)

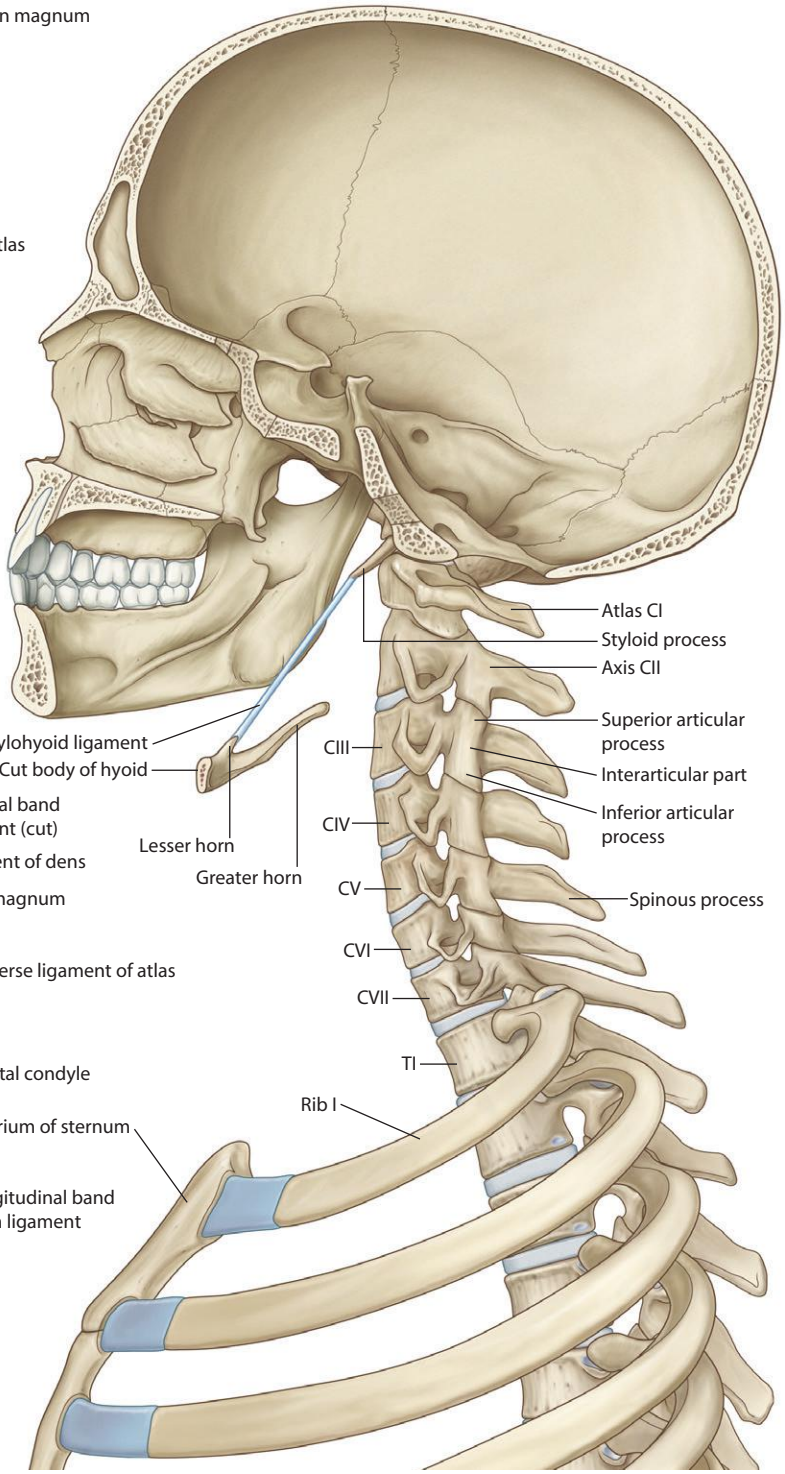

Bones of the neck (lateral view)

tahir99-VRG & vip.persianss.ir

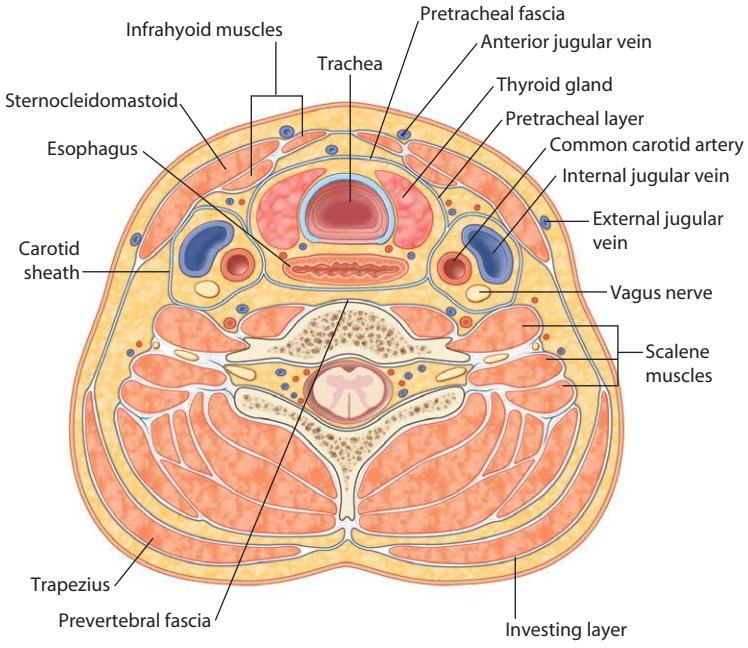

Fascia of the neck (transverse view)

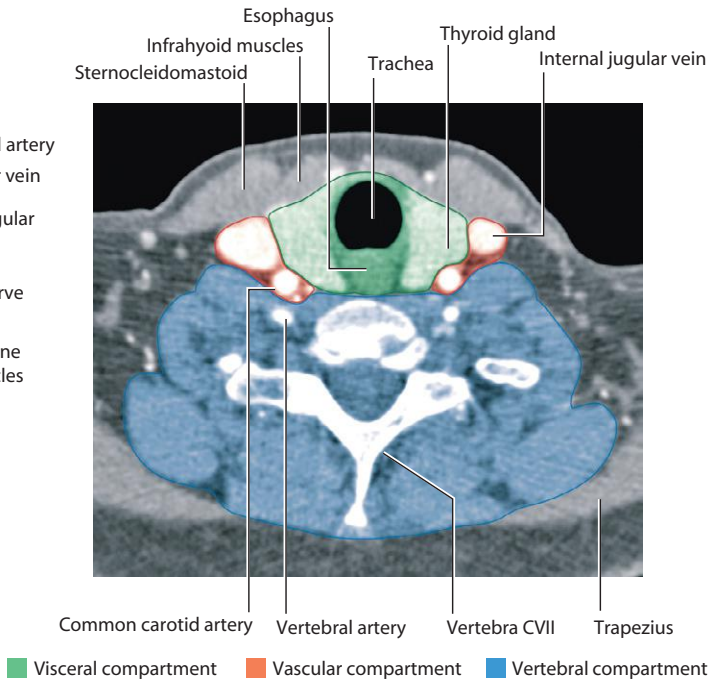

Fascia compartments of the neck.
CT image, with contrast, in axial plane

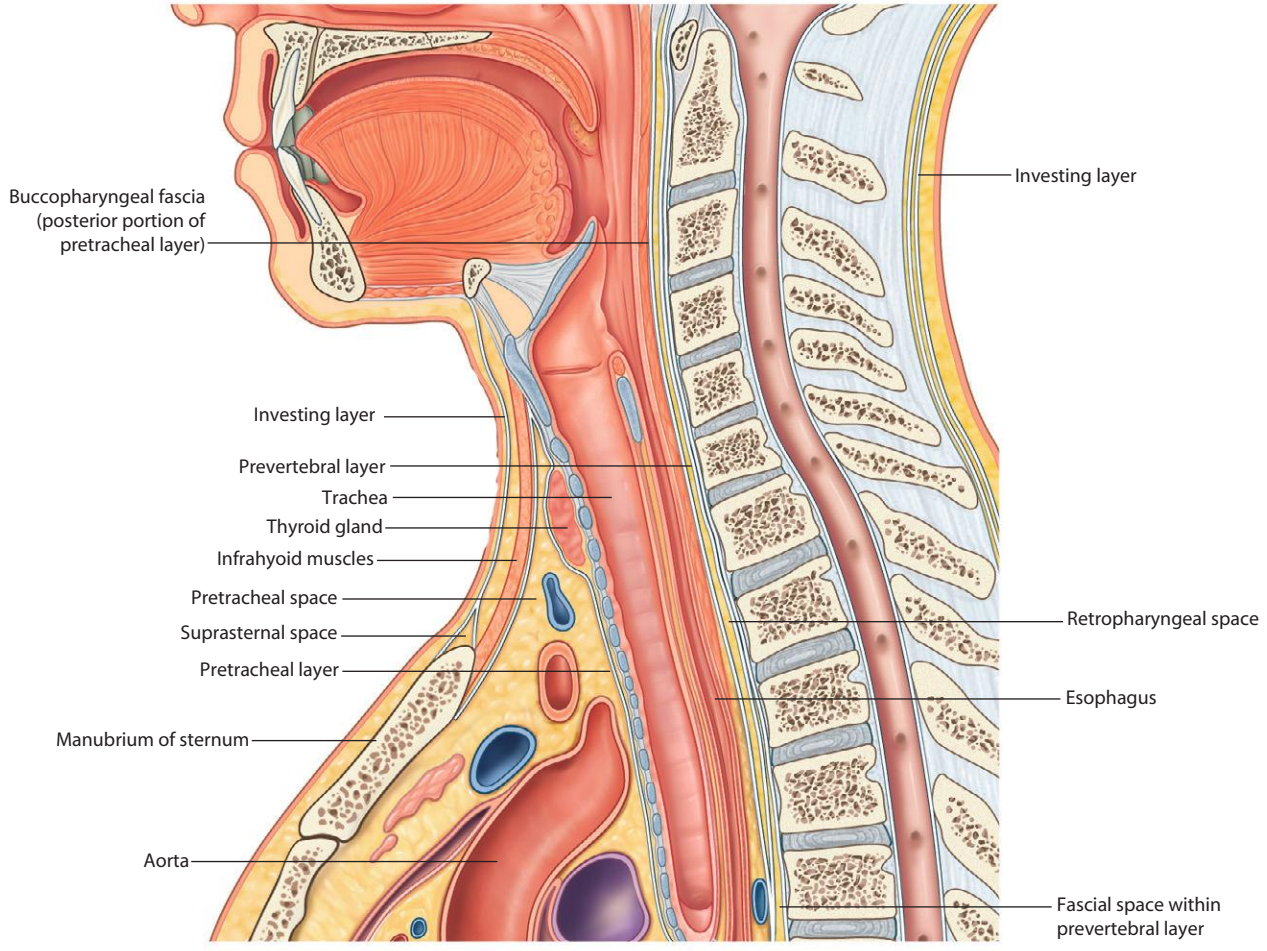

Fascia of the neck (sagittal view)

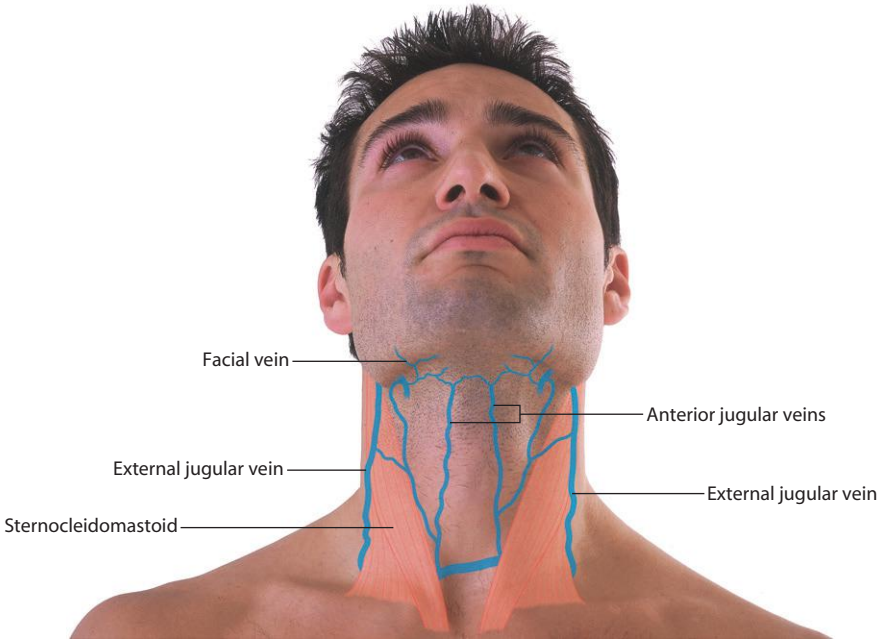

Palpable veins of the neck (or visible)

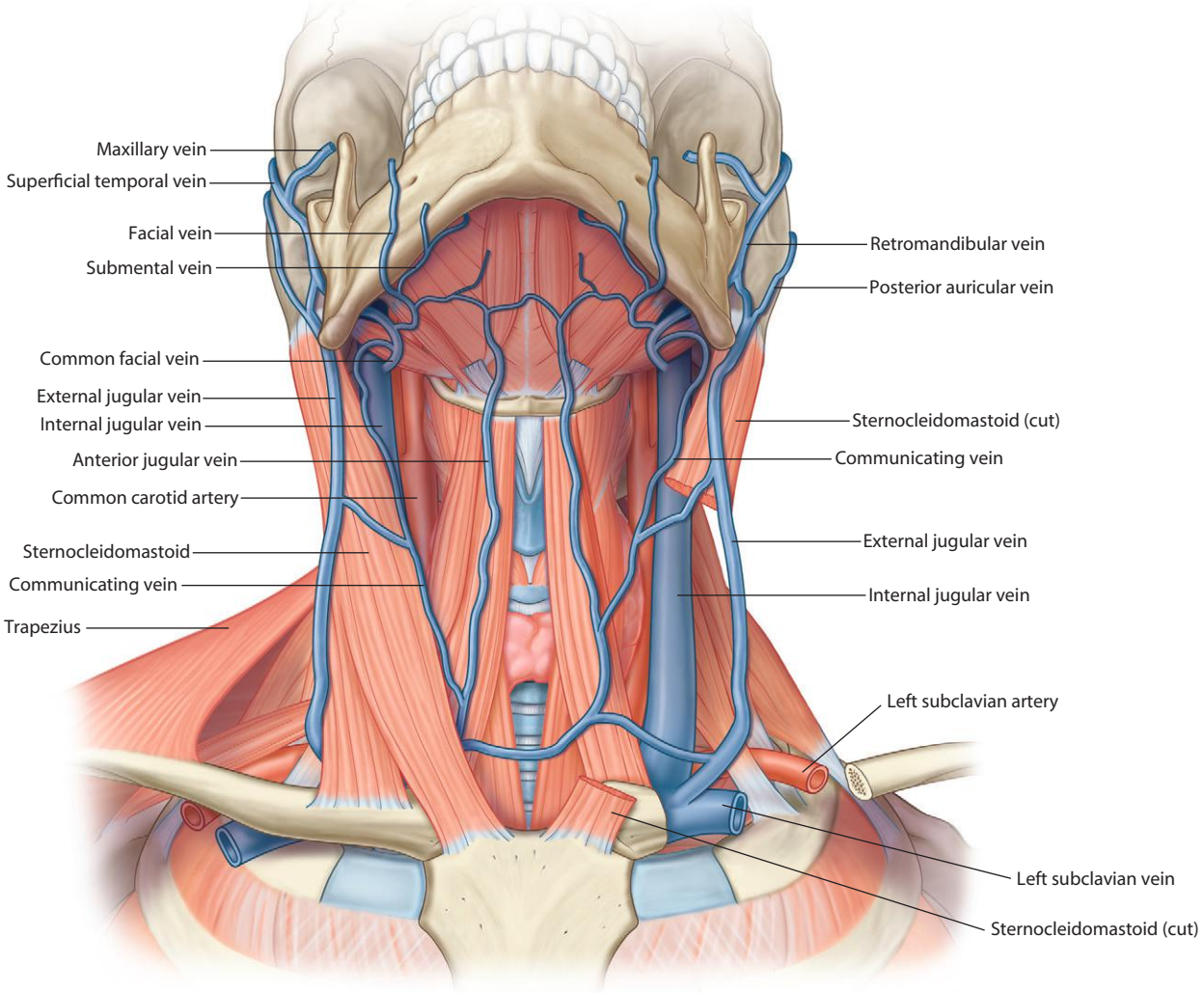

Superficial veins of the neck

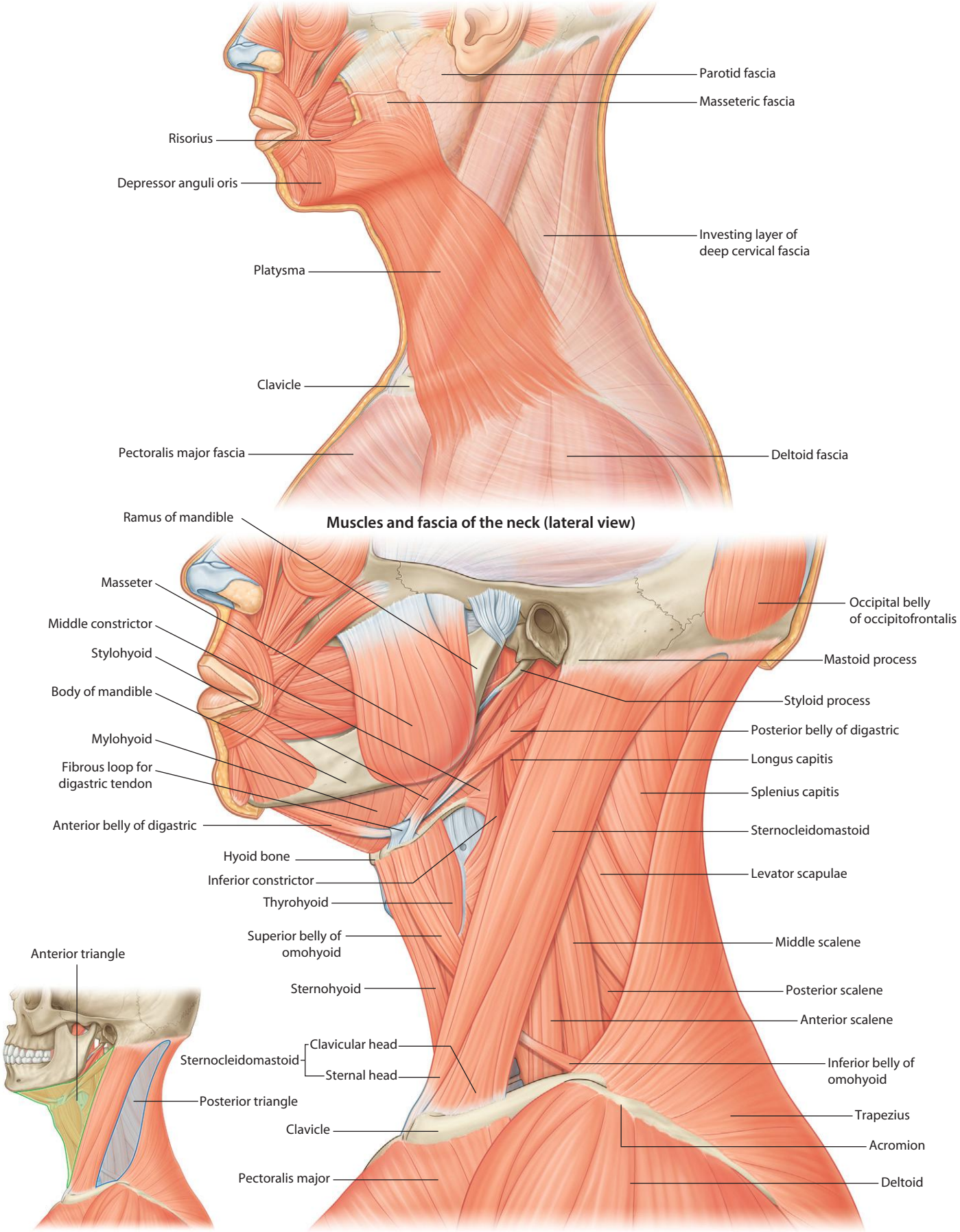

Muscles and fascia of the neck (lateral view)

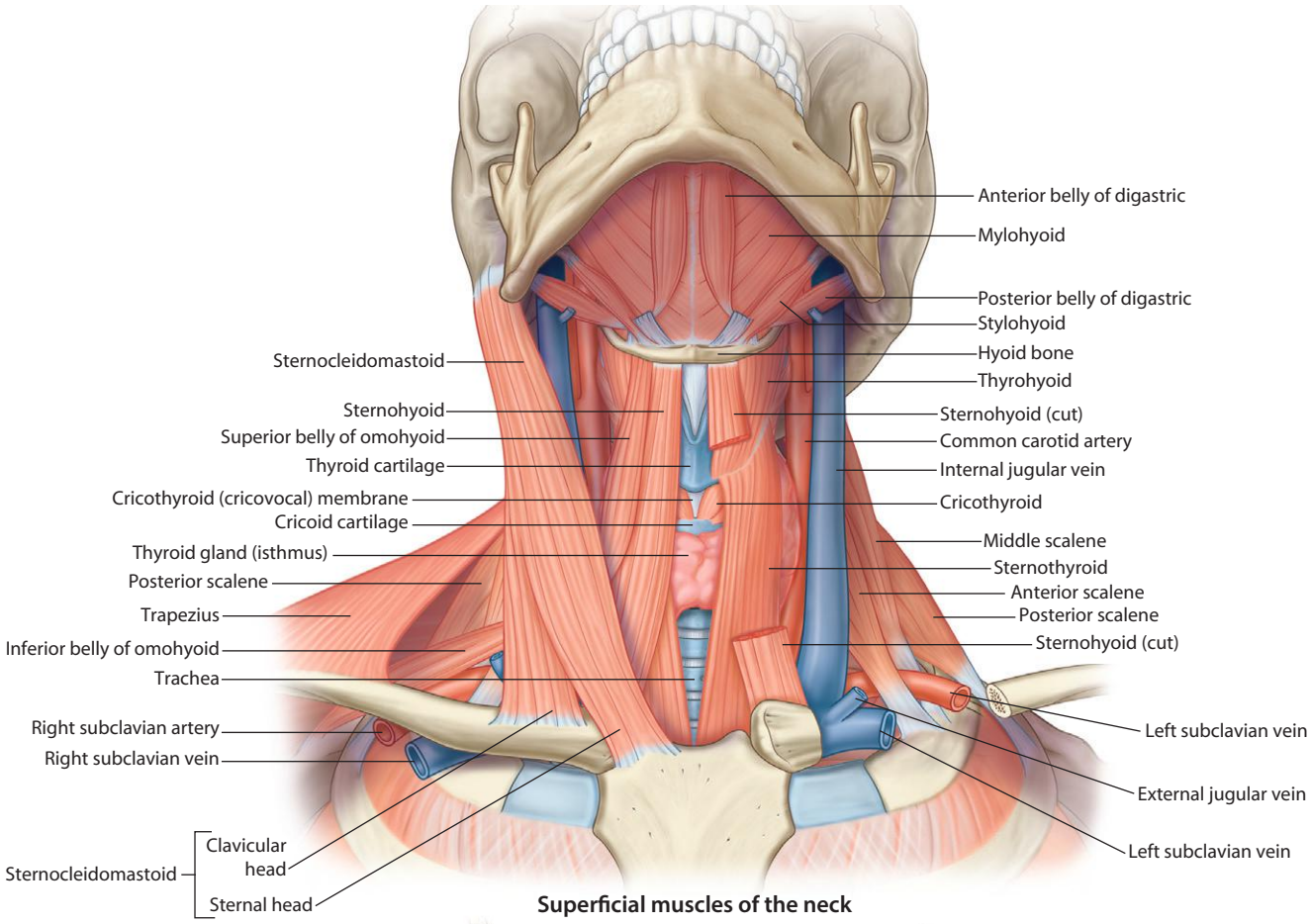

Superficial muscles of the neck

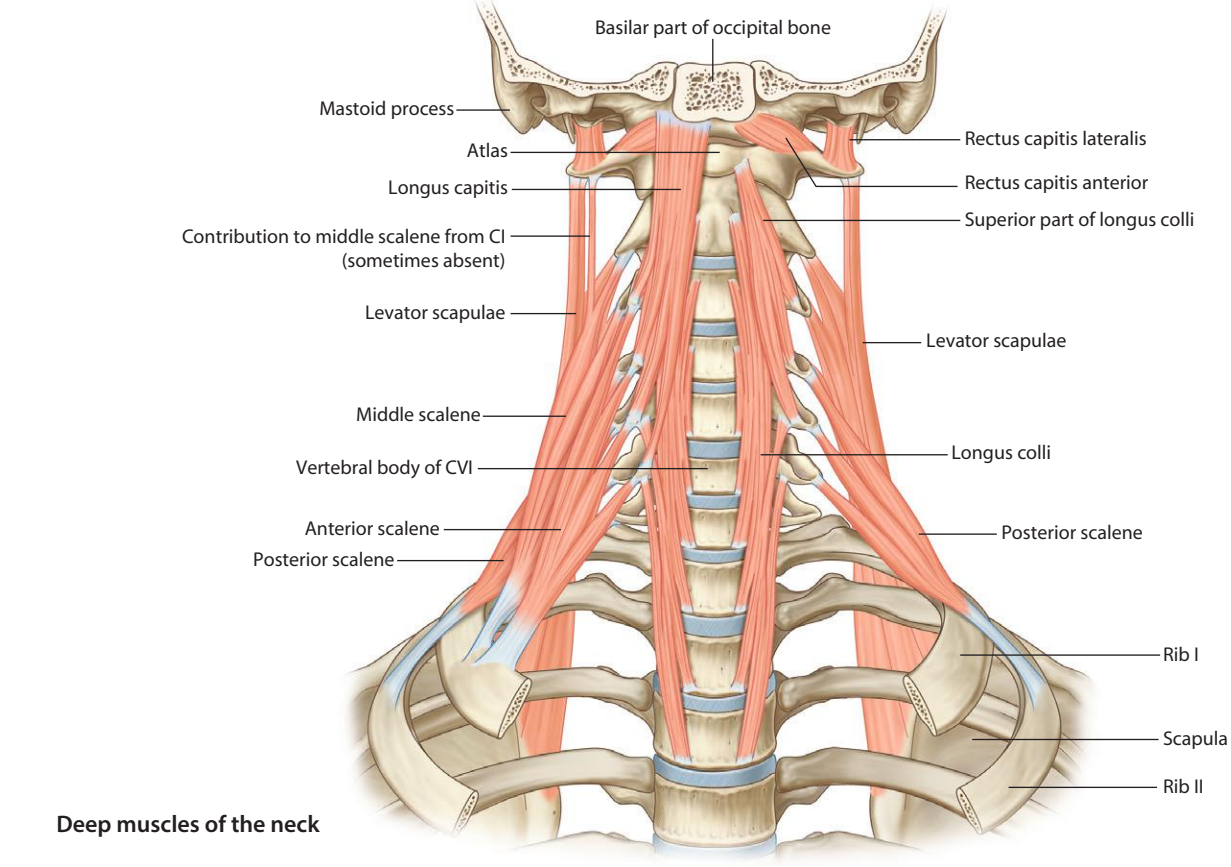

Deep muscles of the neck

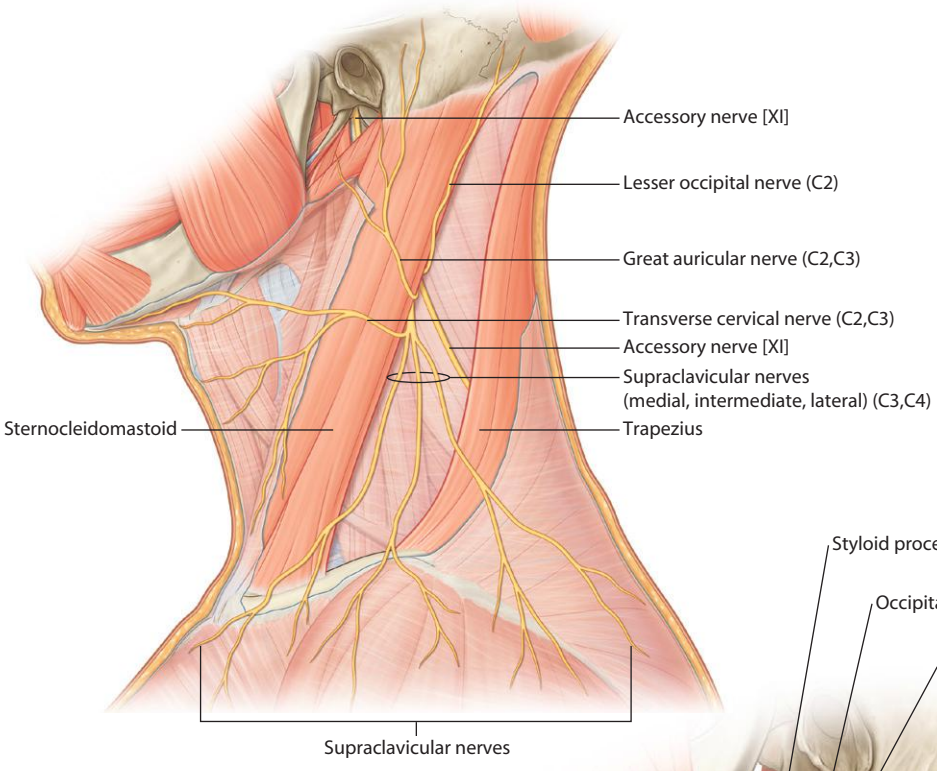

Accessory nerve and branches of the cervical plexus

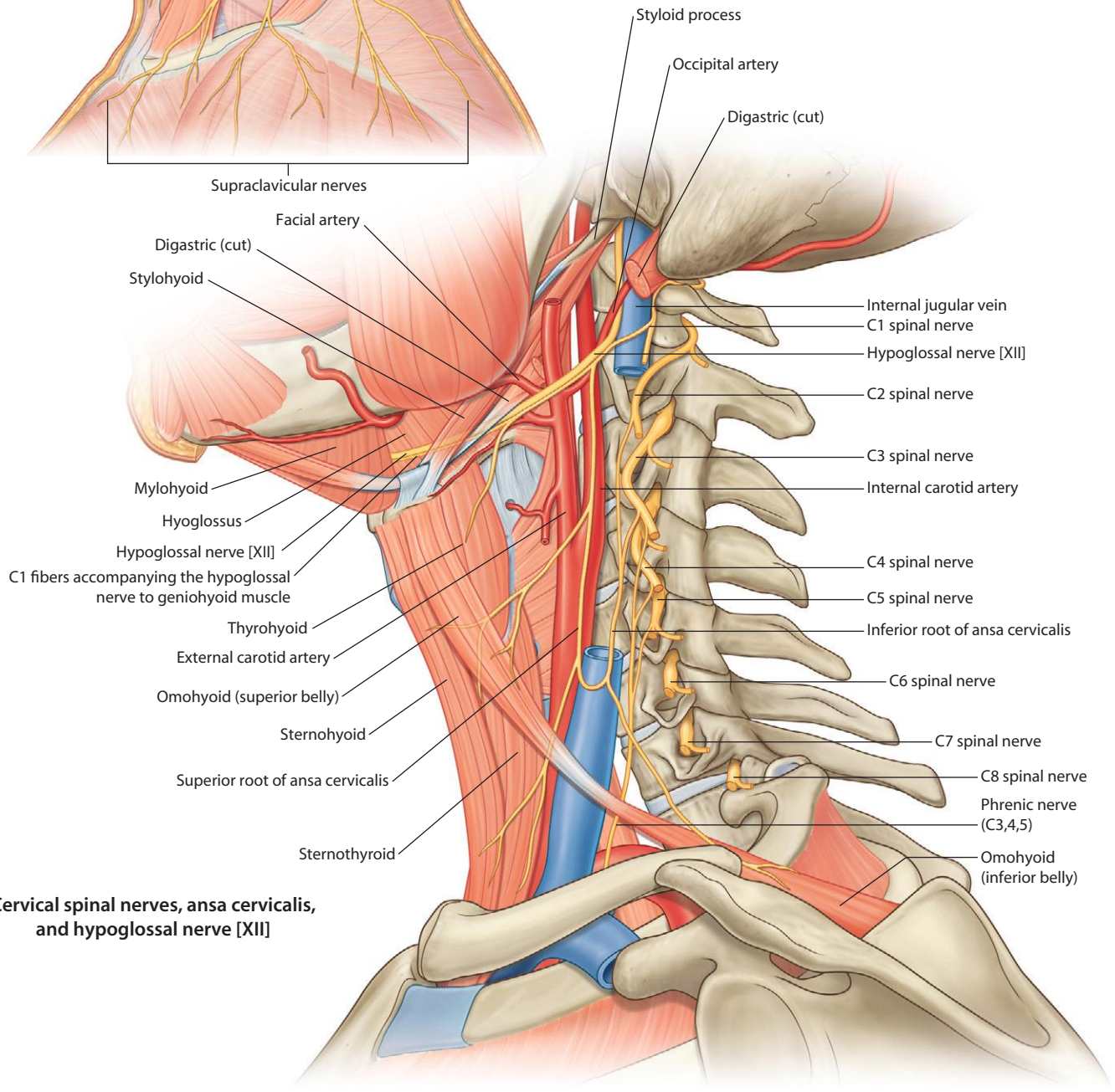

Cervical spinal nerves, ansa cervicalis, and hypoglossal nerve [XII]

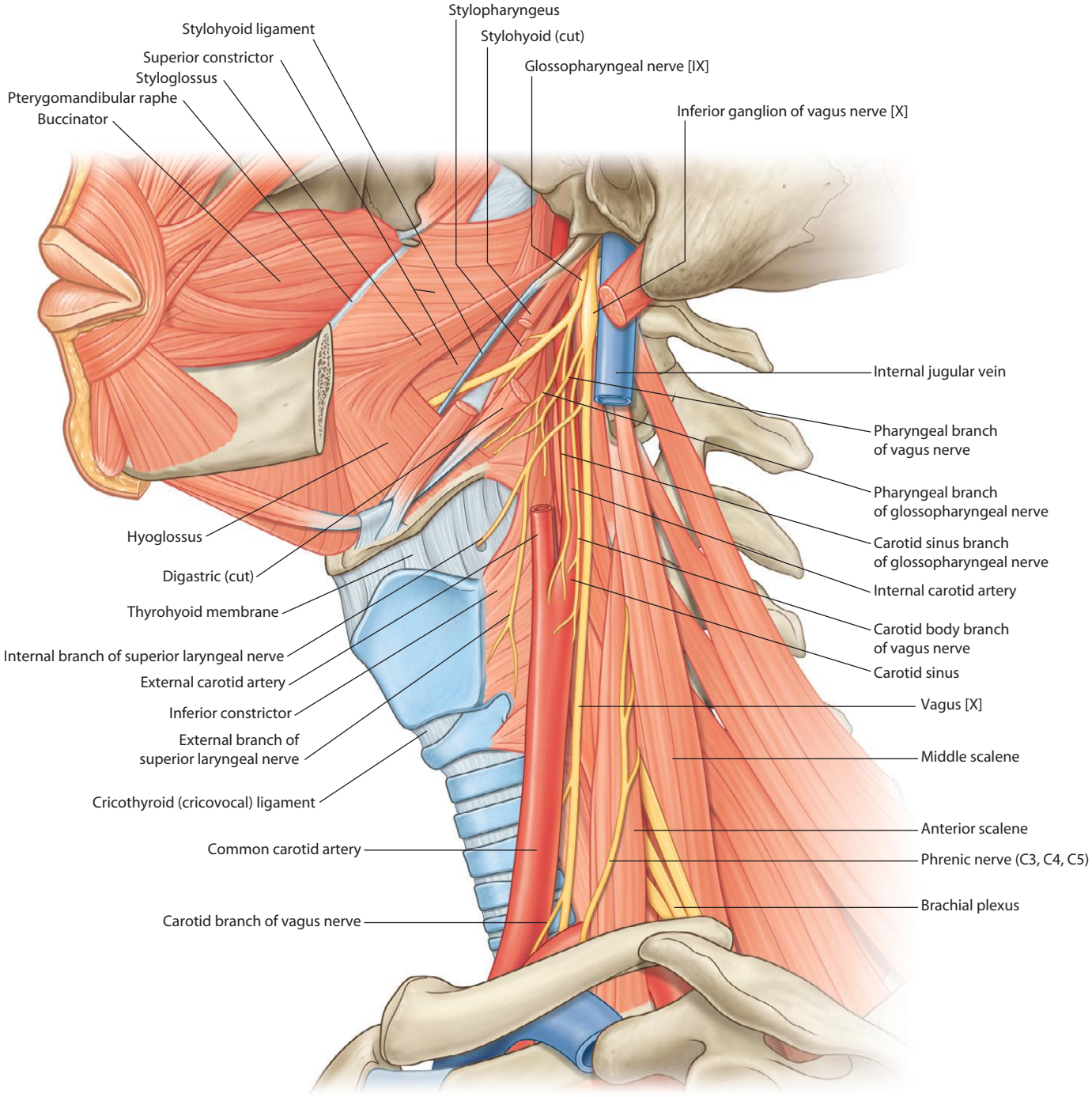

Branches of glossopharyngeal [IX] and vagus nerves [X] in neck

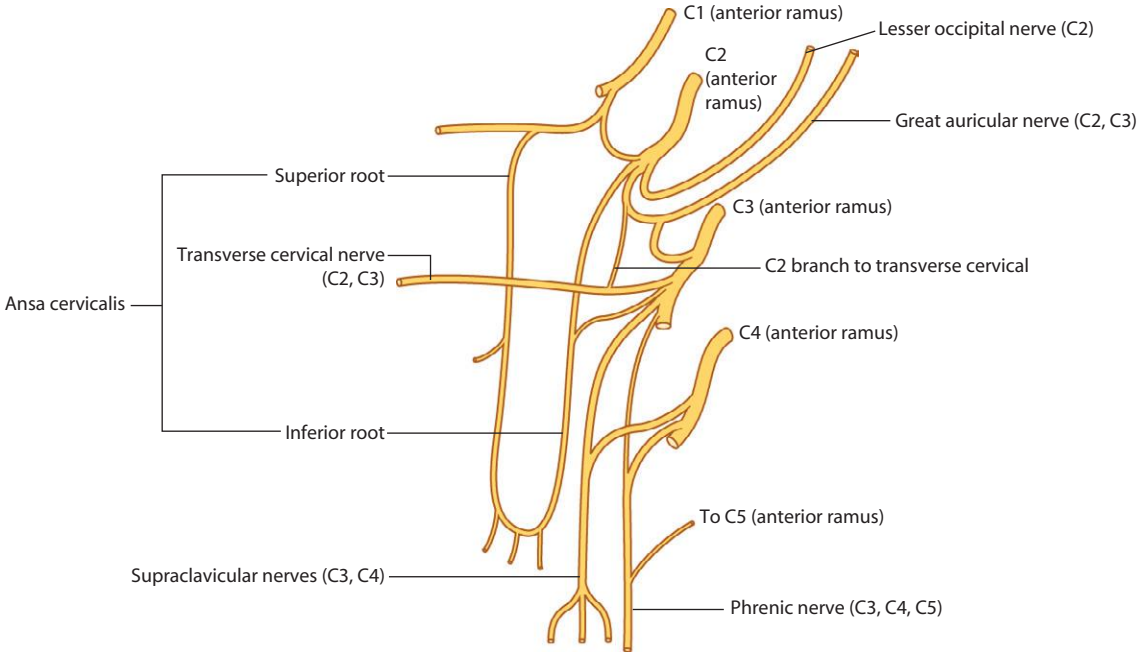

Cervical plexus

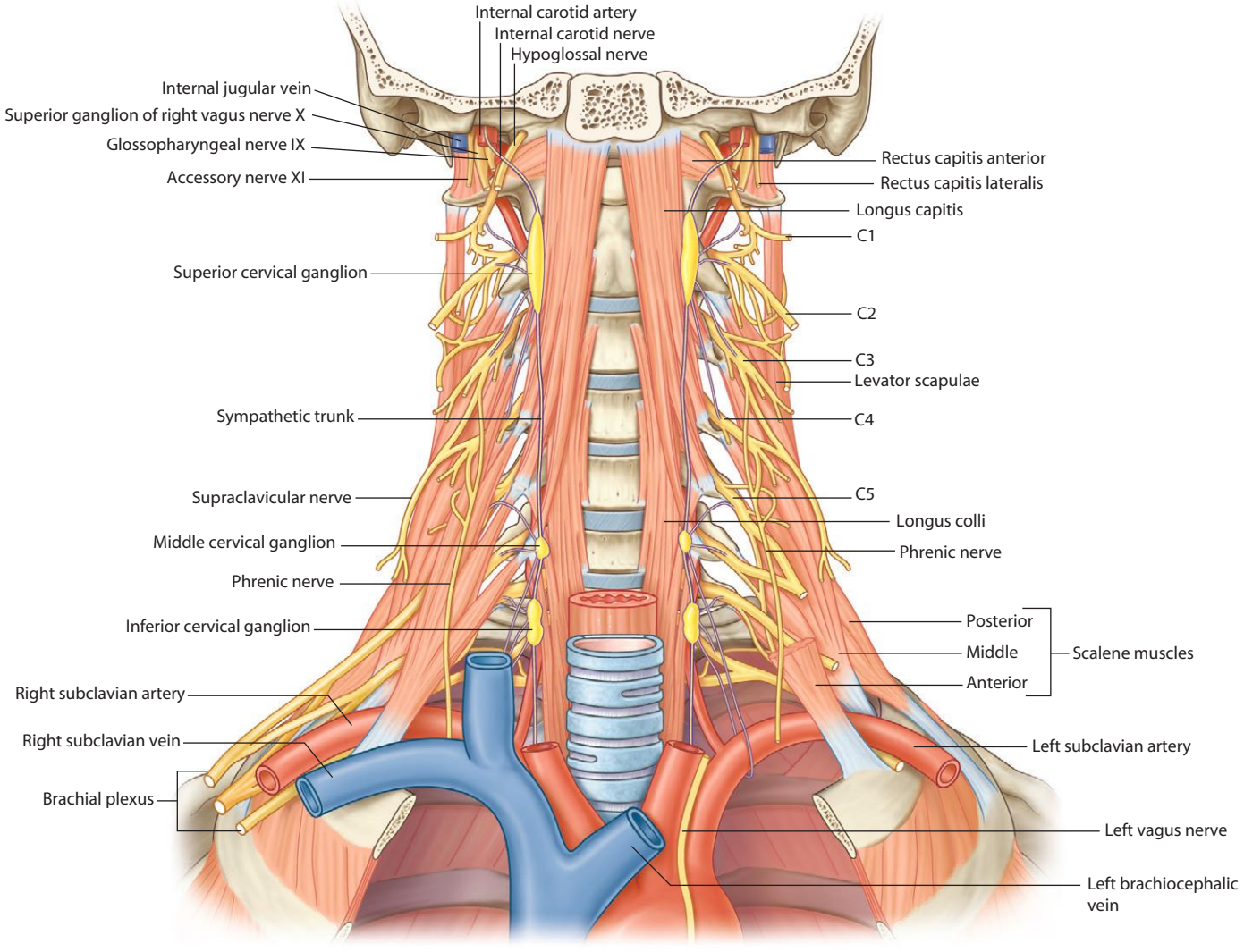

Components of the sympathetic nervous system in the root of the neck

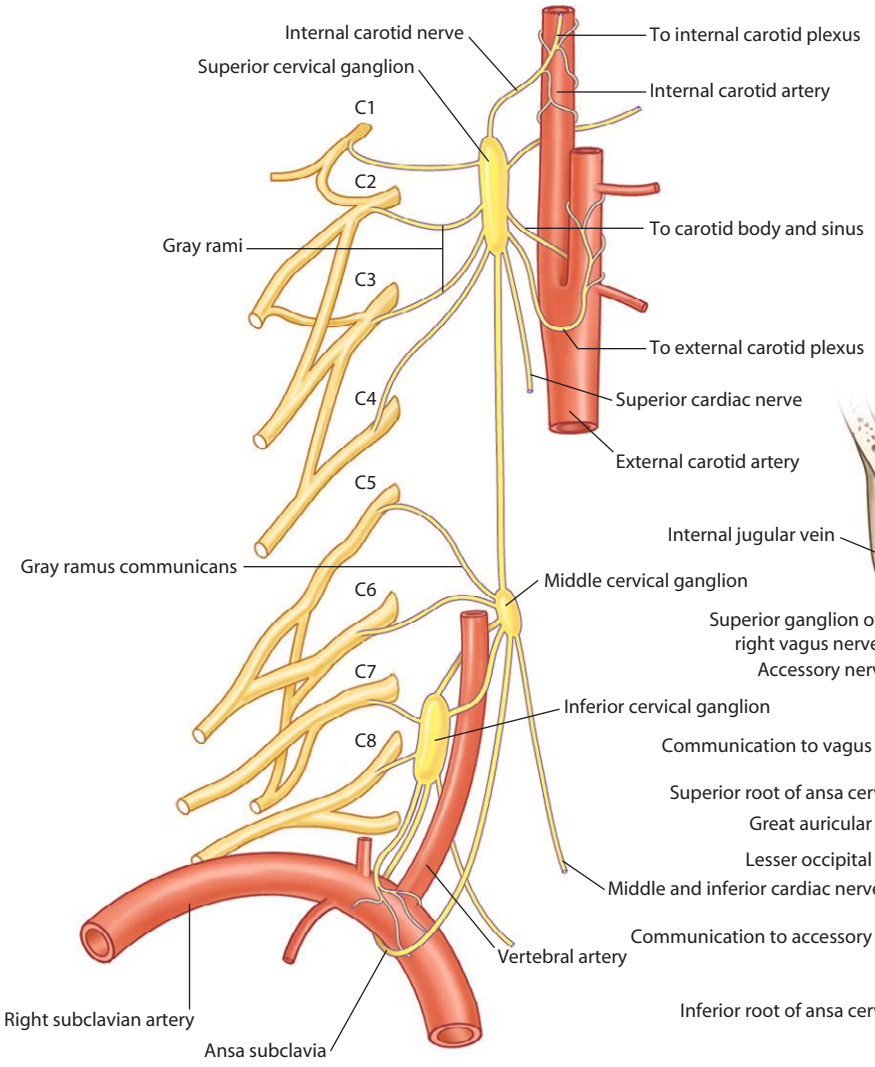

Cervical part of the sympathetic trunk

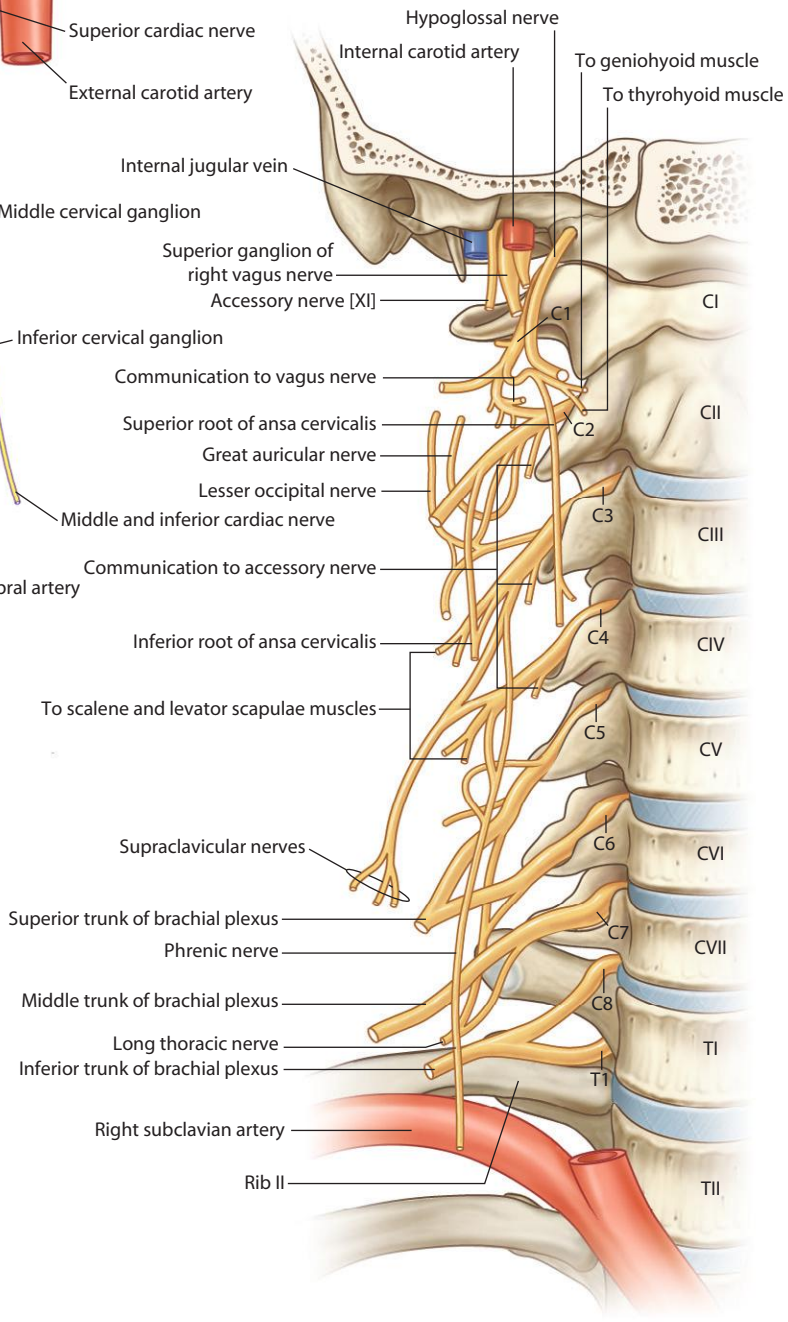

Branches of the cervical plexus (rib I removed)

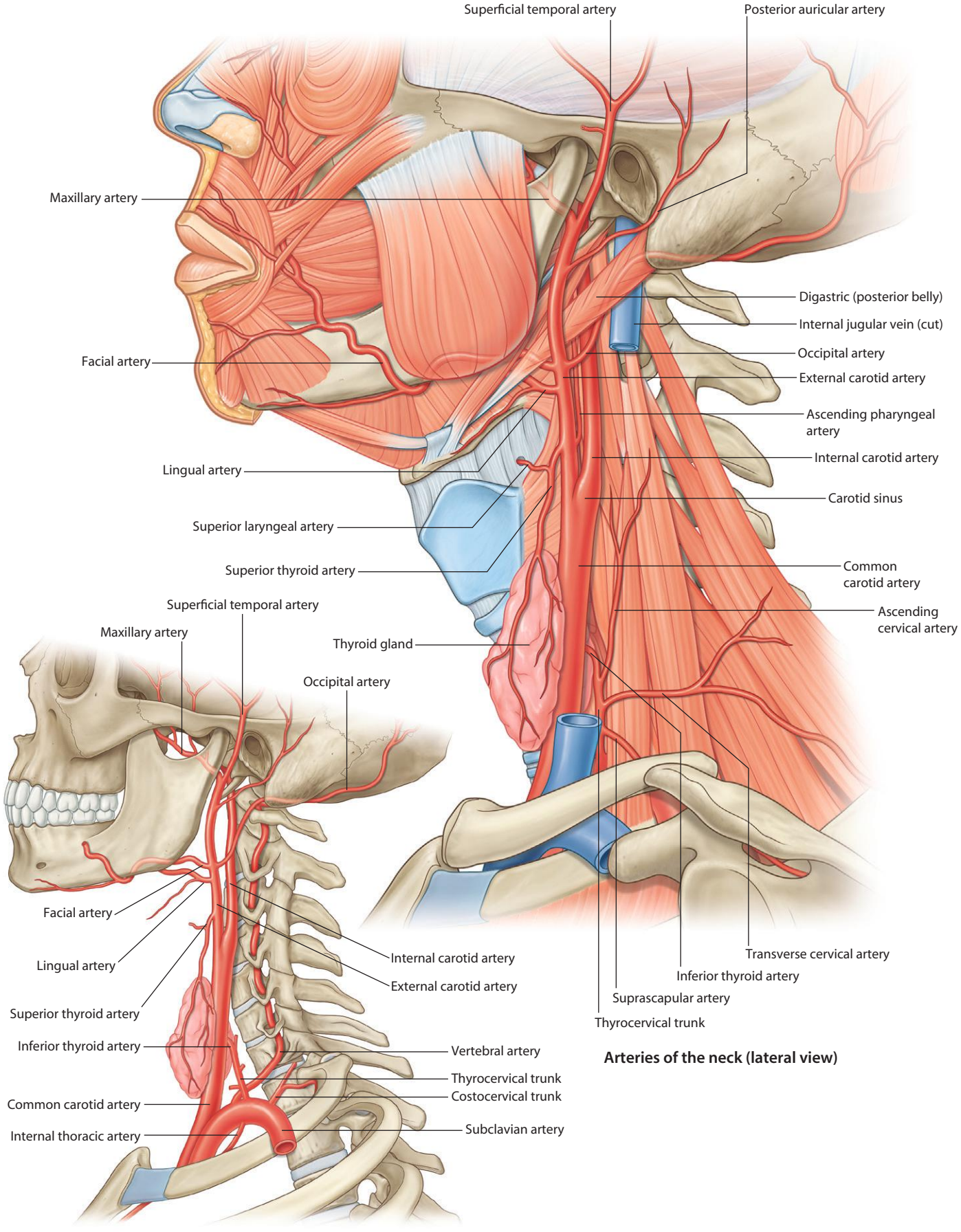

Arteries of the neck (lateral view)

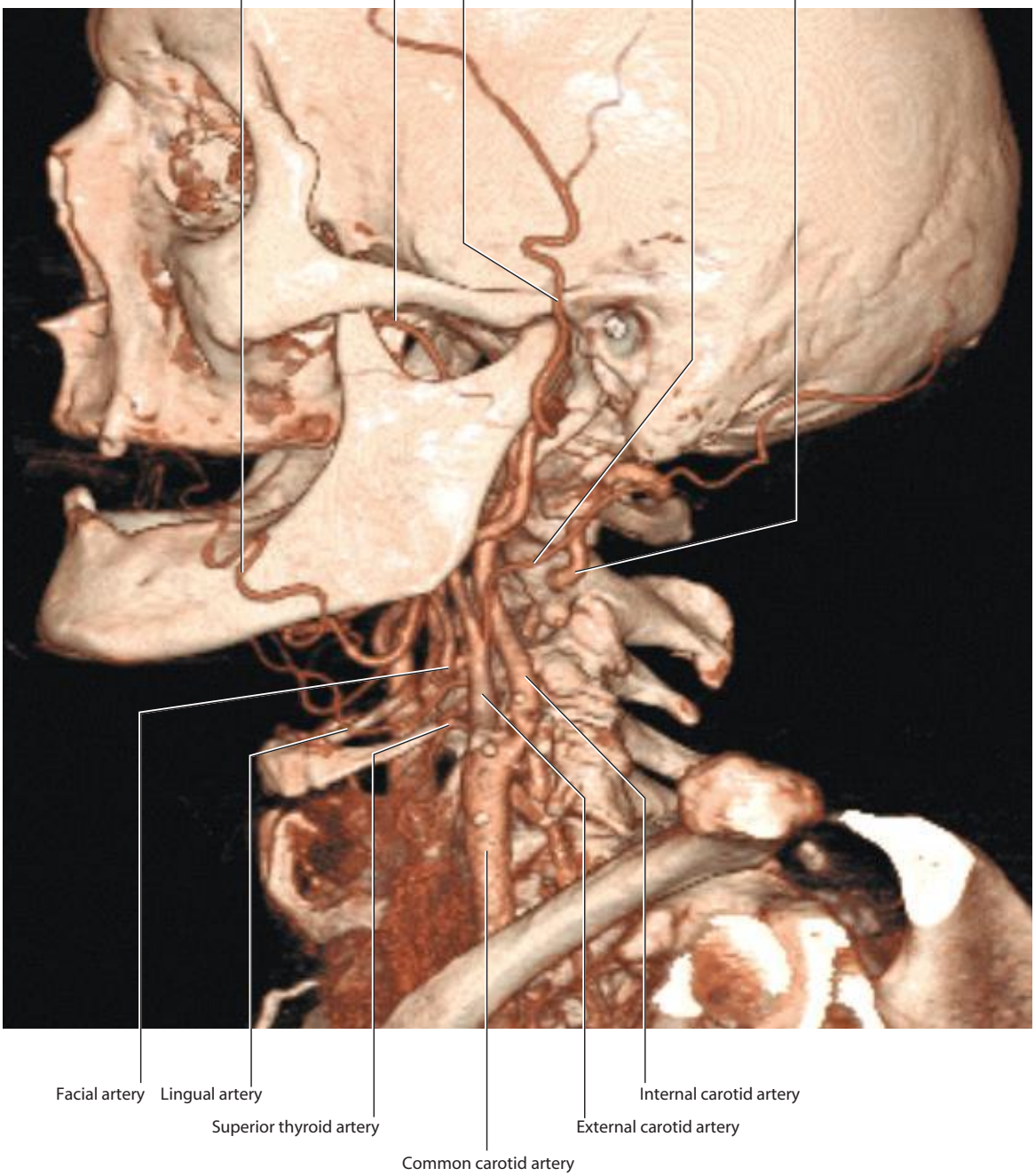

Lateral view of the branches of the external carotid artery.
Volume-rendered angiographic image, with contrast, using multidetector CT

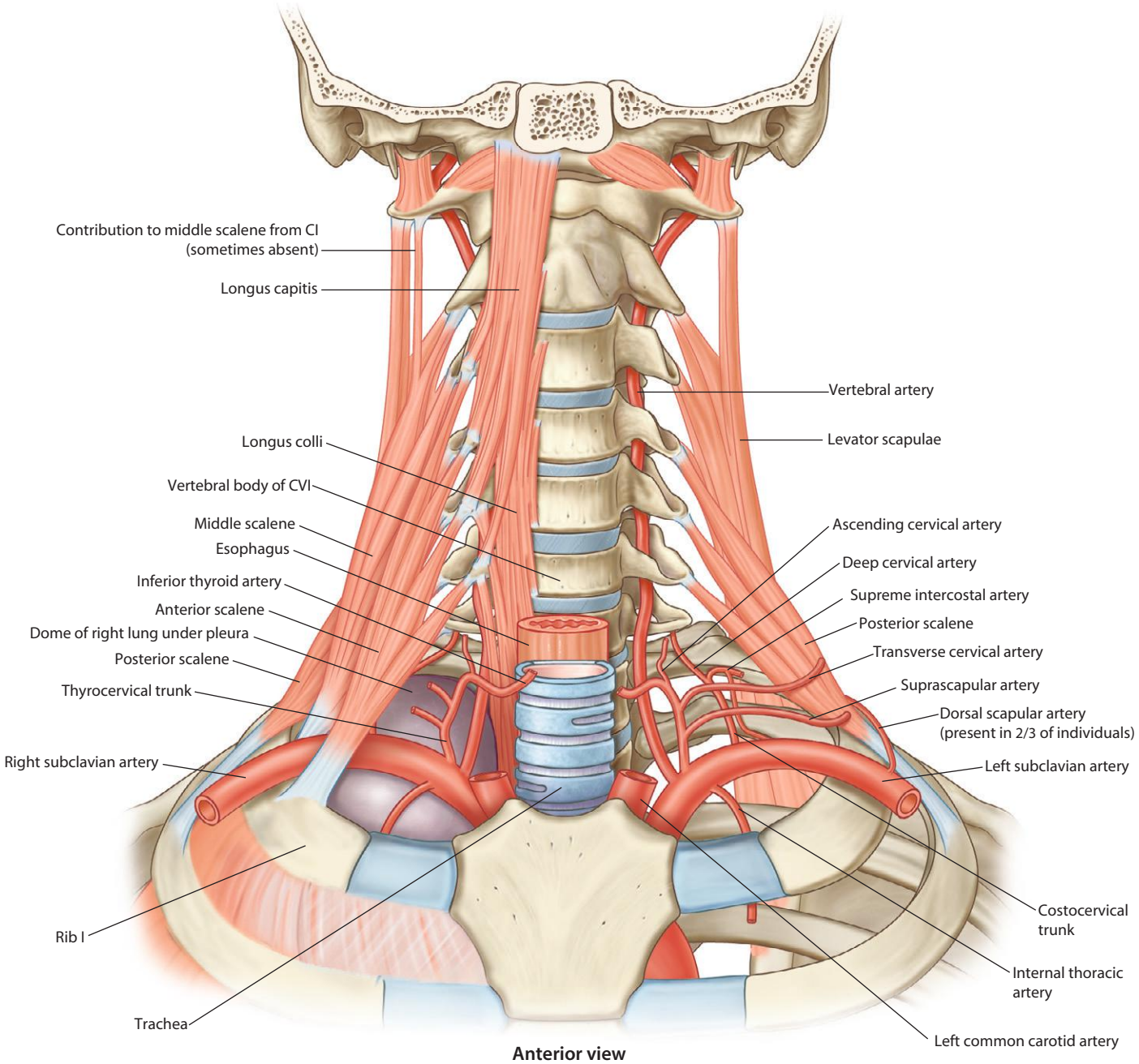

Anterior view

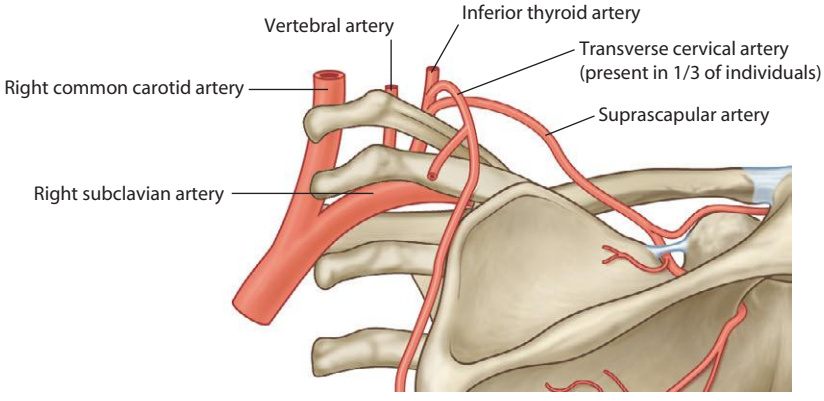

Posterior view

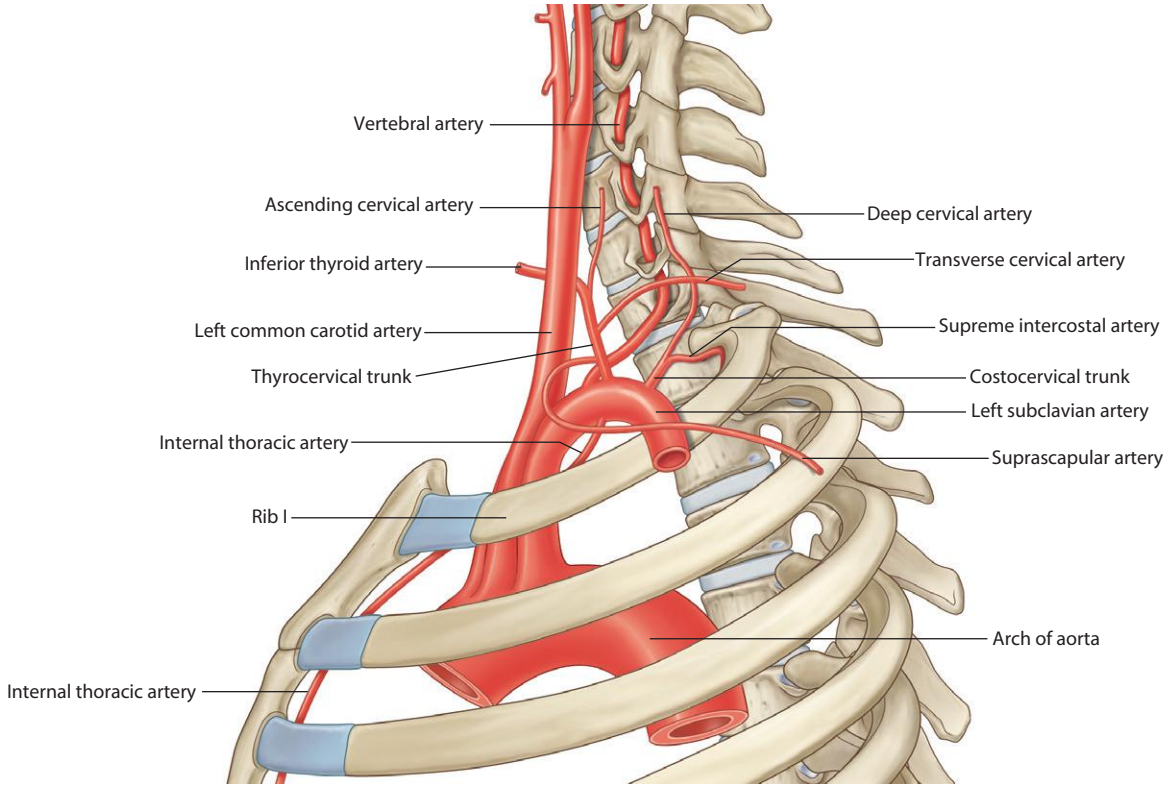

Lateral view

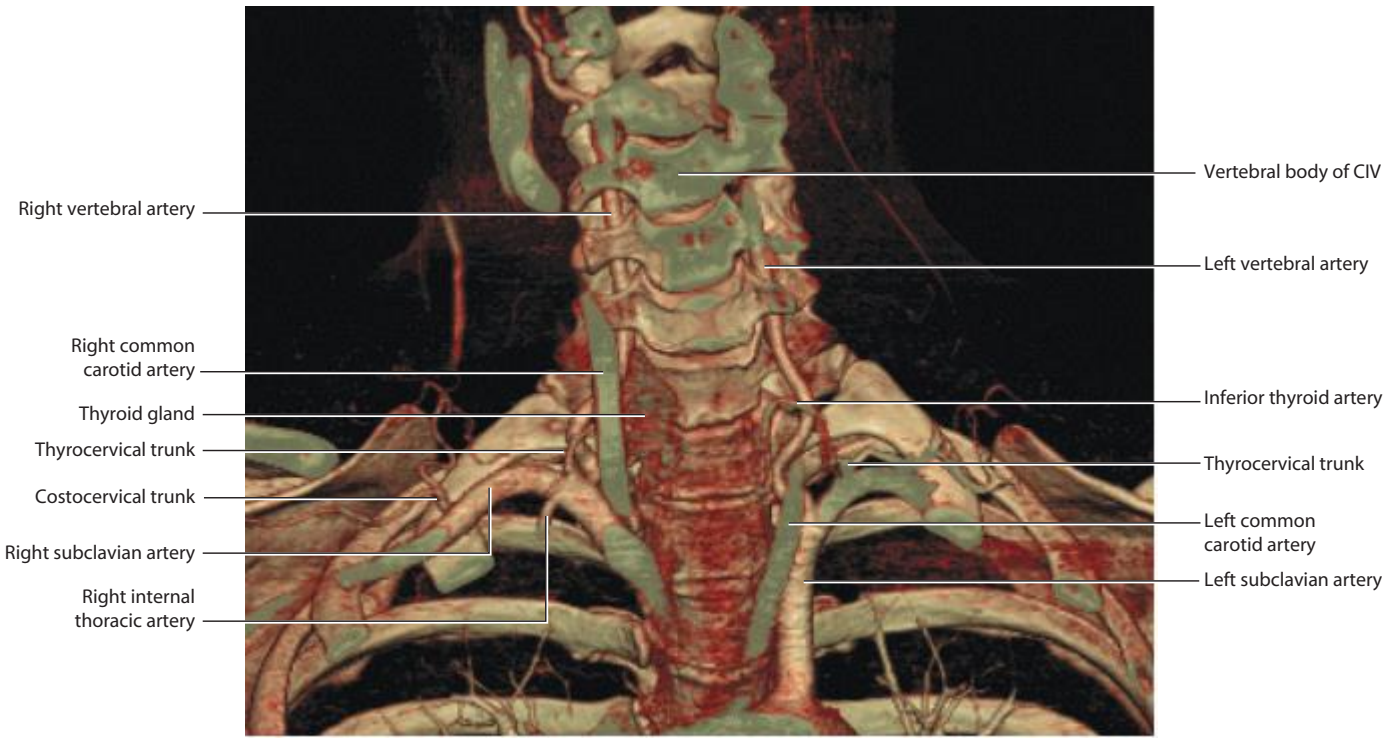

Anterior view of the root of the neck showing the branches of the subclavian arteries.
Volume-rendered angiographic image, with contrast, using multidetector CT

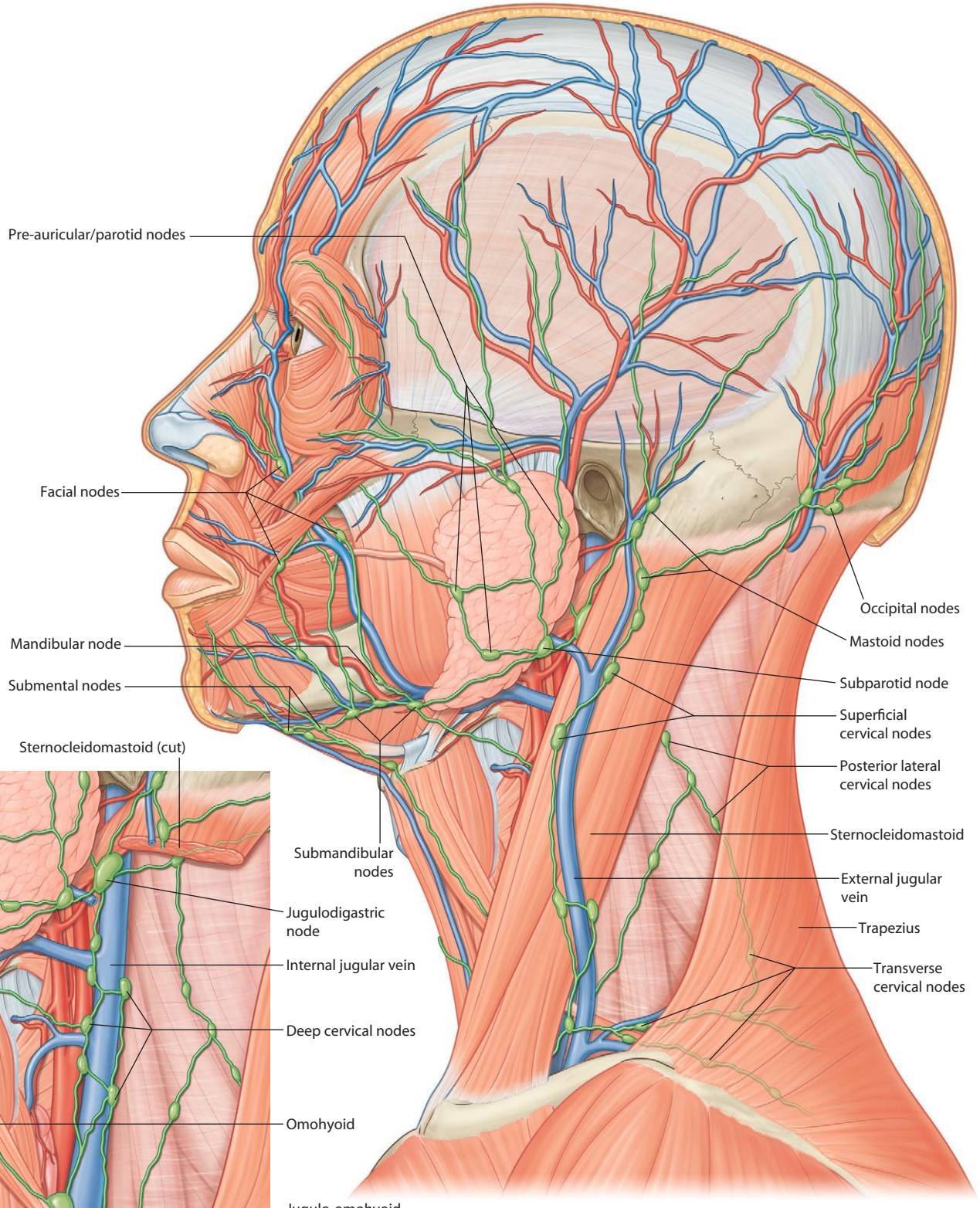

Lymphatic system in the neck

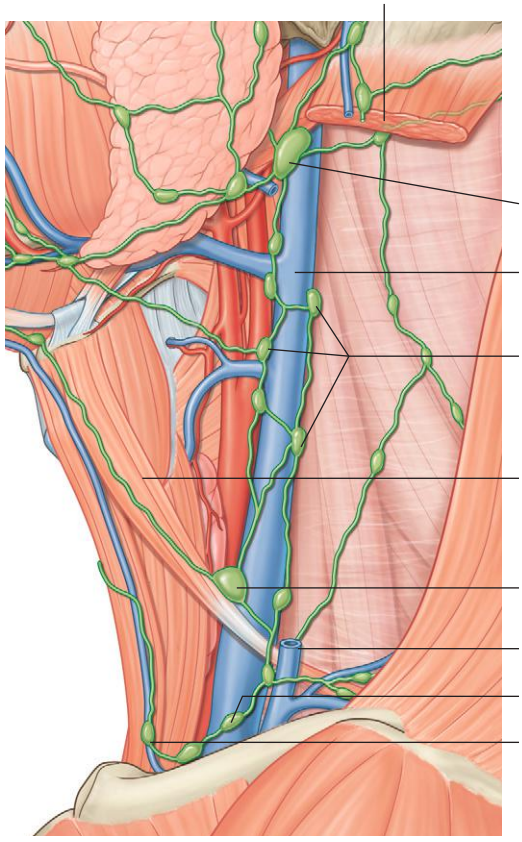

Deep cervical nodes

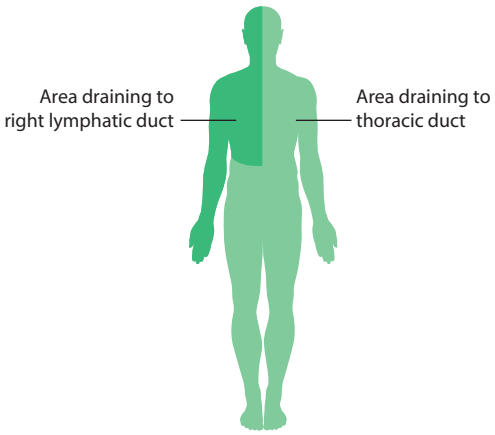

Areas of lymphatic drainage

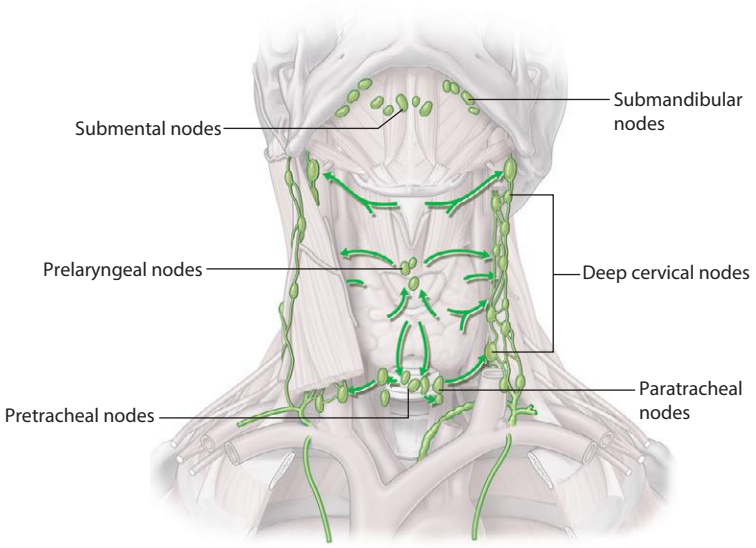

Lymphatic drainage of the thyroid gland, larynx, and trachea

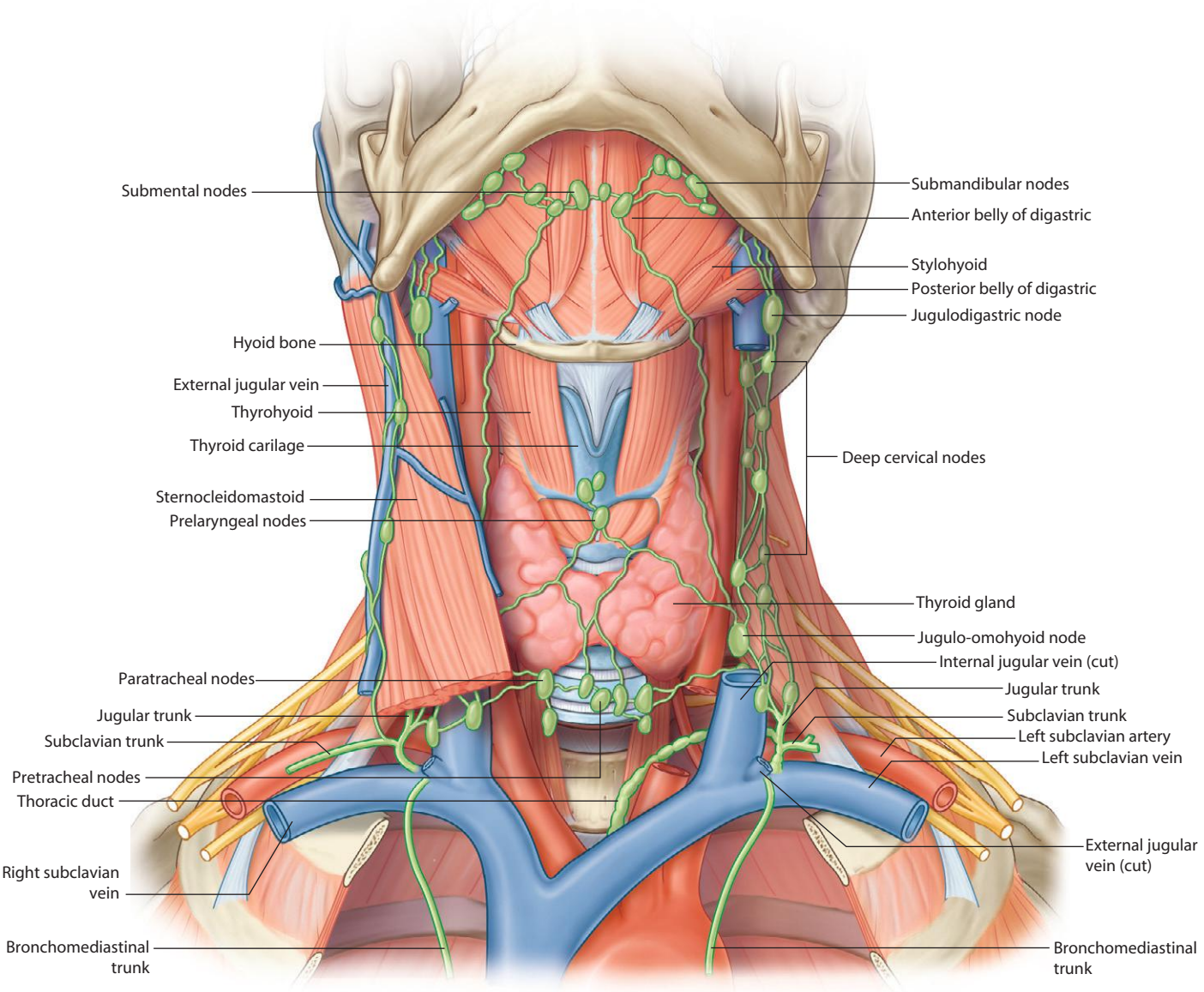

Lymphatic system in the neck

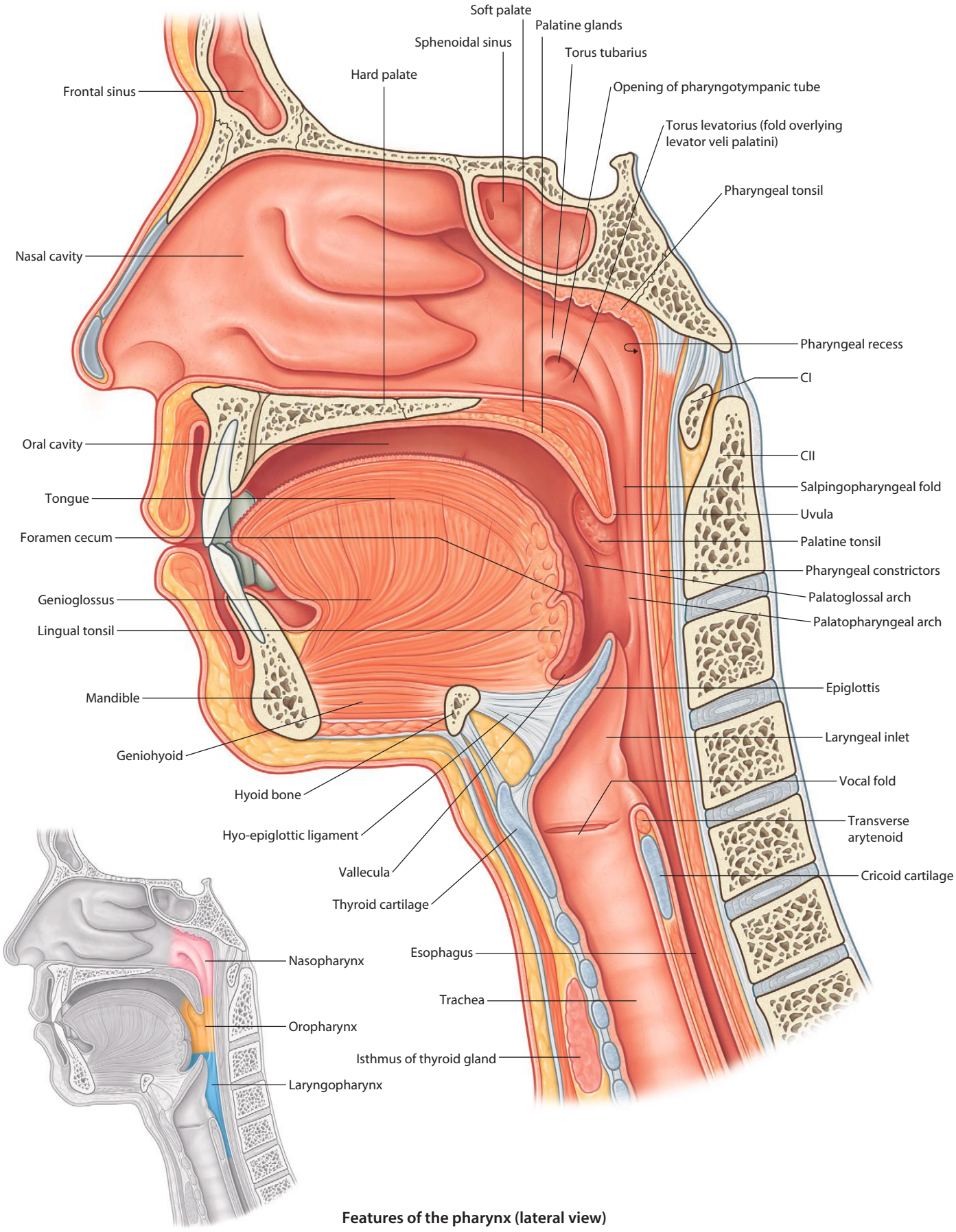

Features of the pharynx (lateral view)

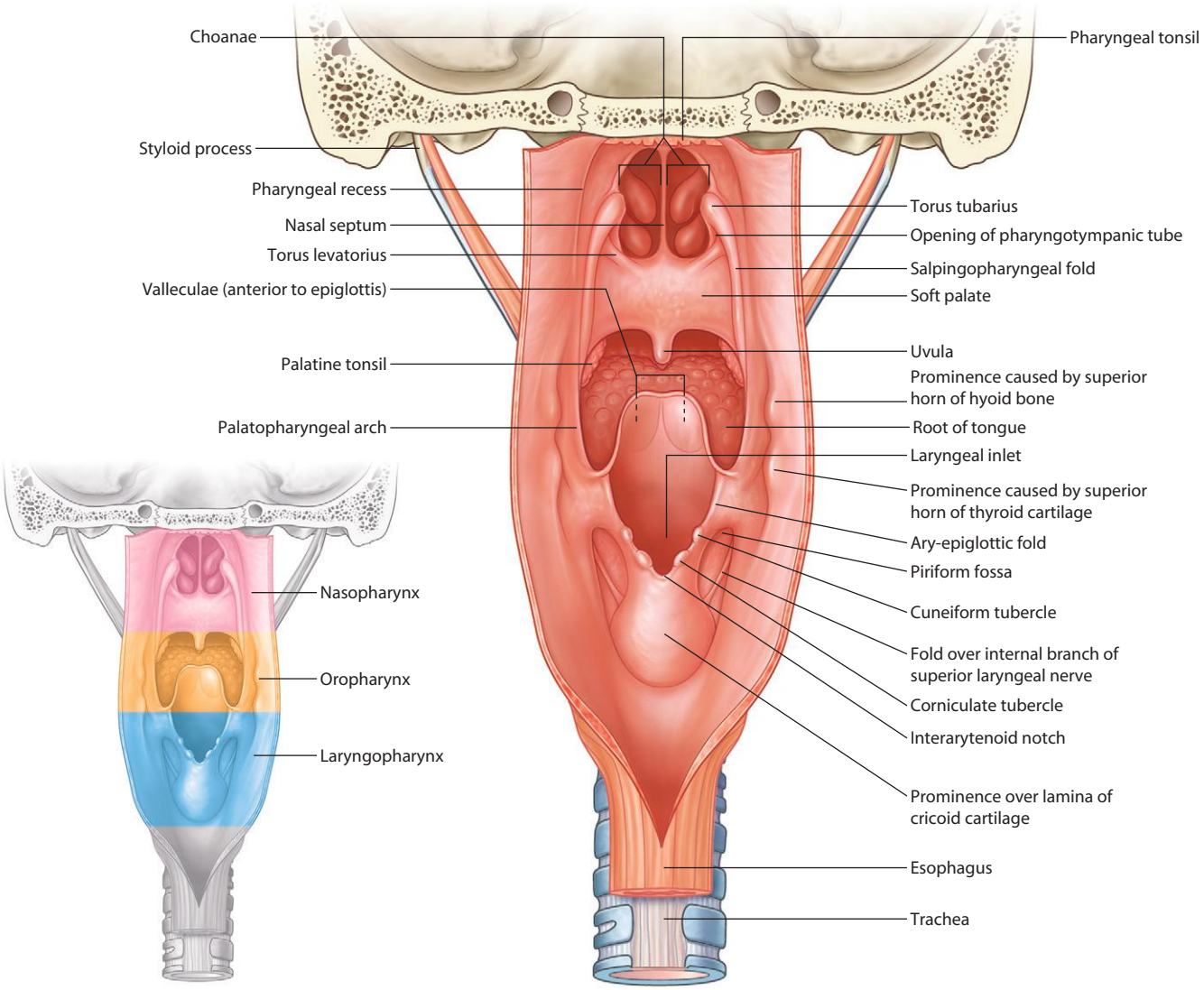

Features of the pharynx
(posterior view with the pharyngeal wall opened)

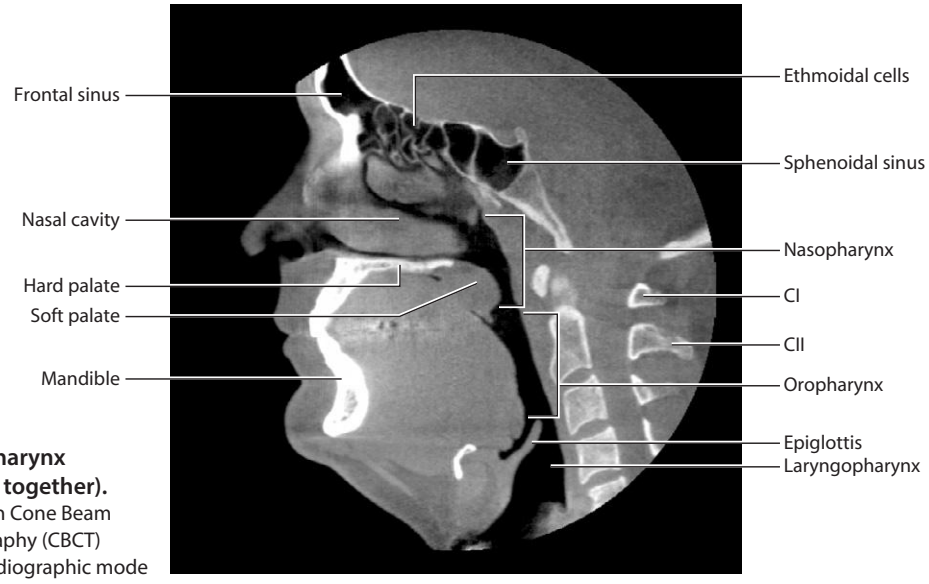

Regions of the pharynx
(mouth closed, teeth together).
Sagittal image taken with Cone Beam Computerized Tomography (CBCT) technology, viewed in the radiographic mode

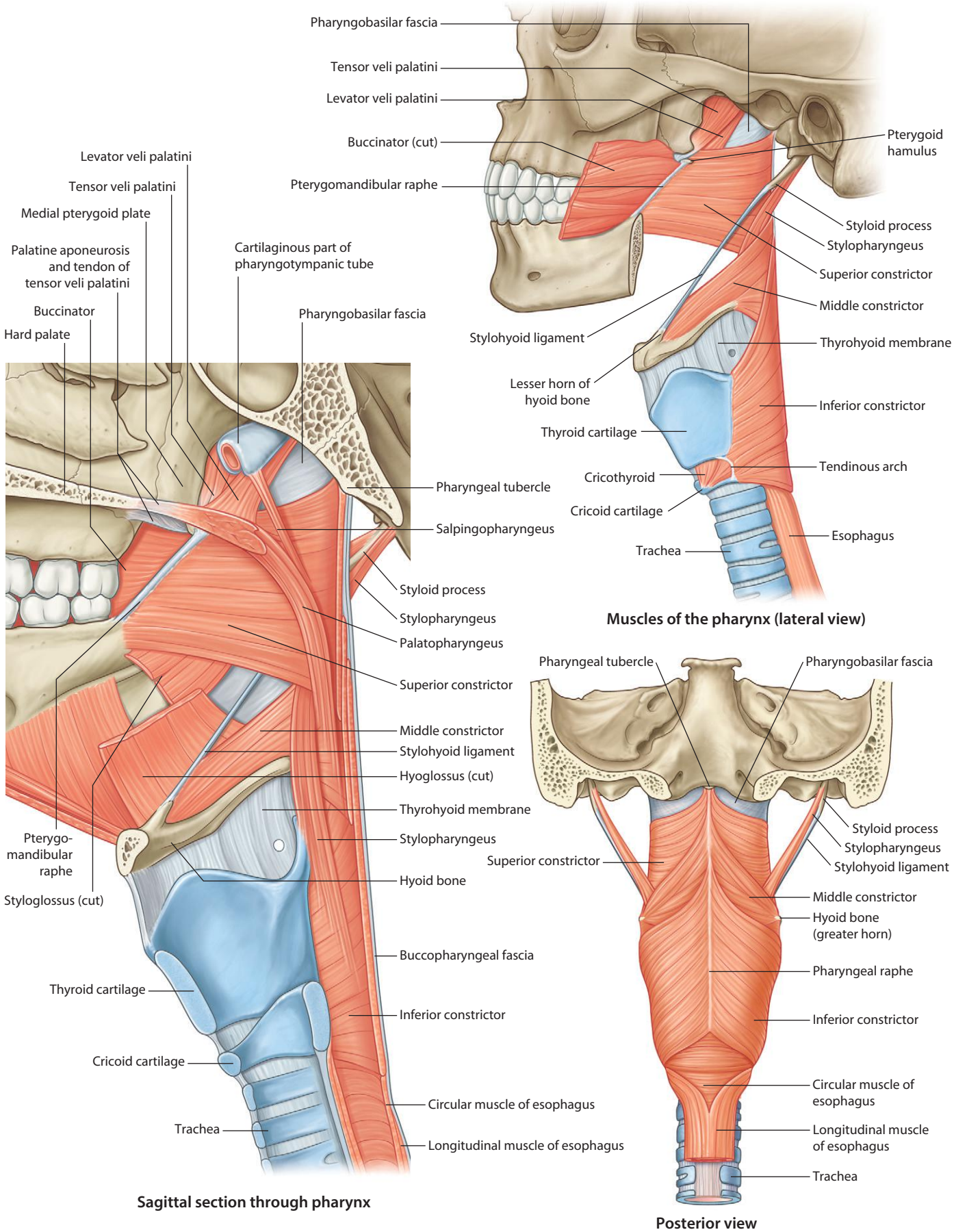

Muscles of the pharynx (lateral view)

Sagittal section through pharynx

Posterior view

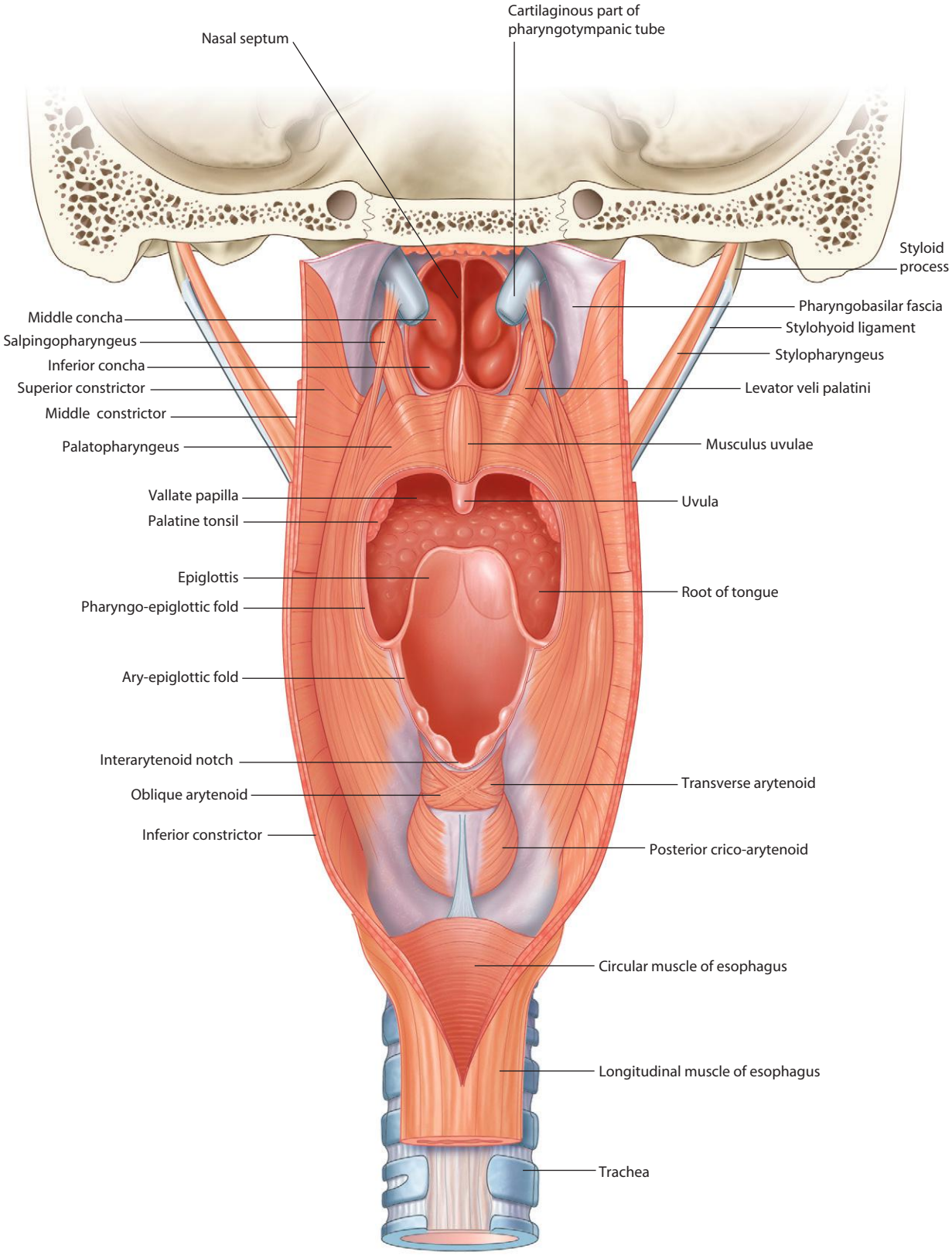

Muscles of the posterior wall of the pharynx

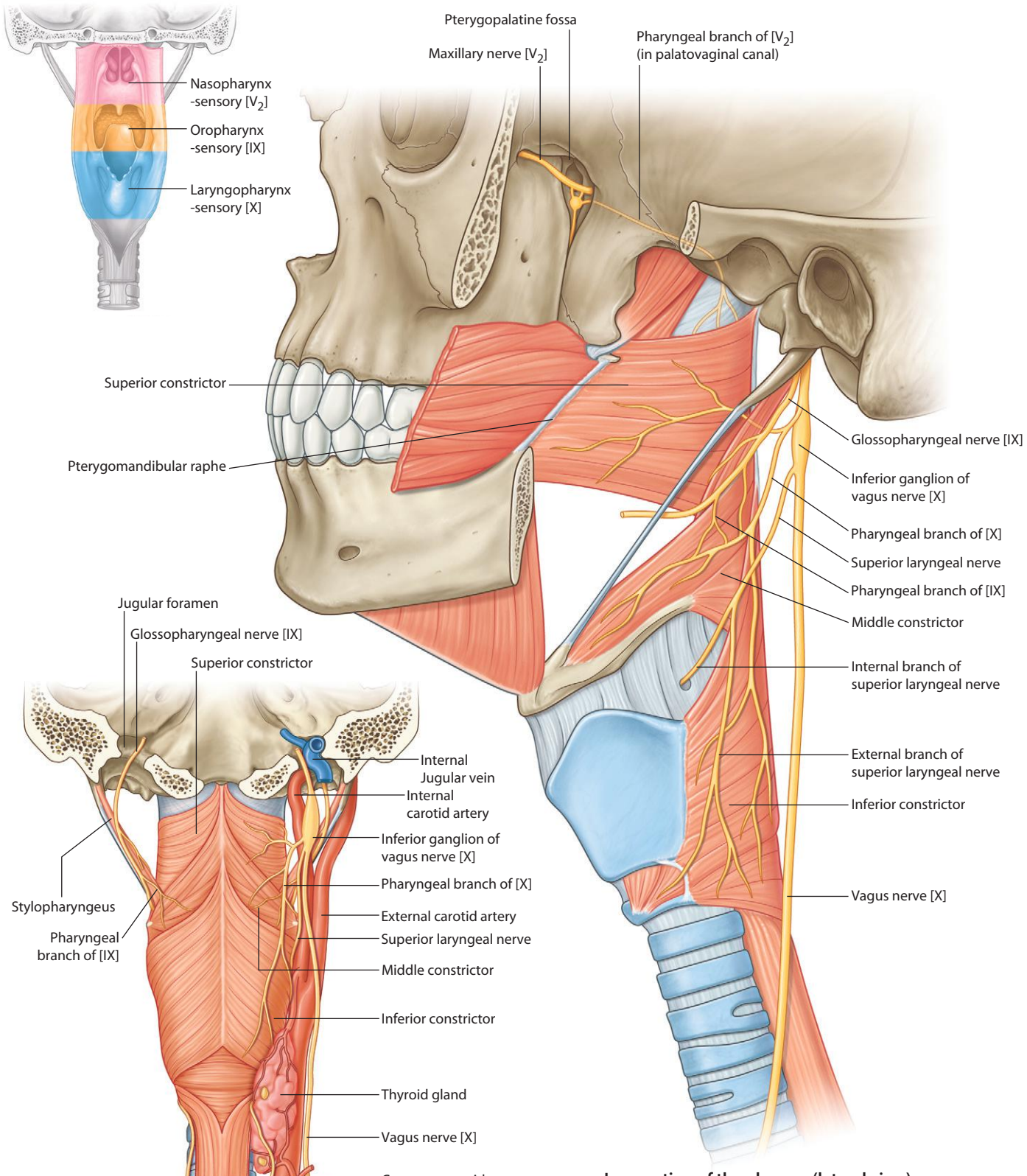

Innervation of the pharynx (lateral view)

Posterior view

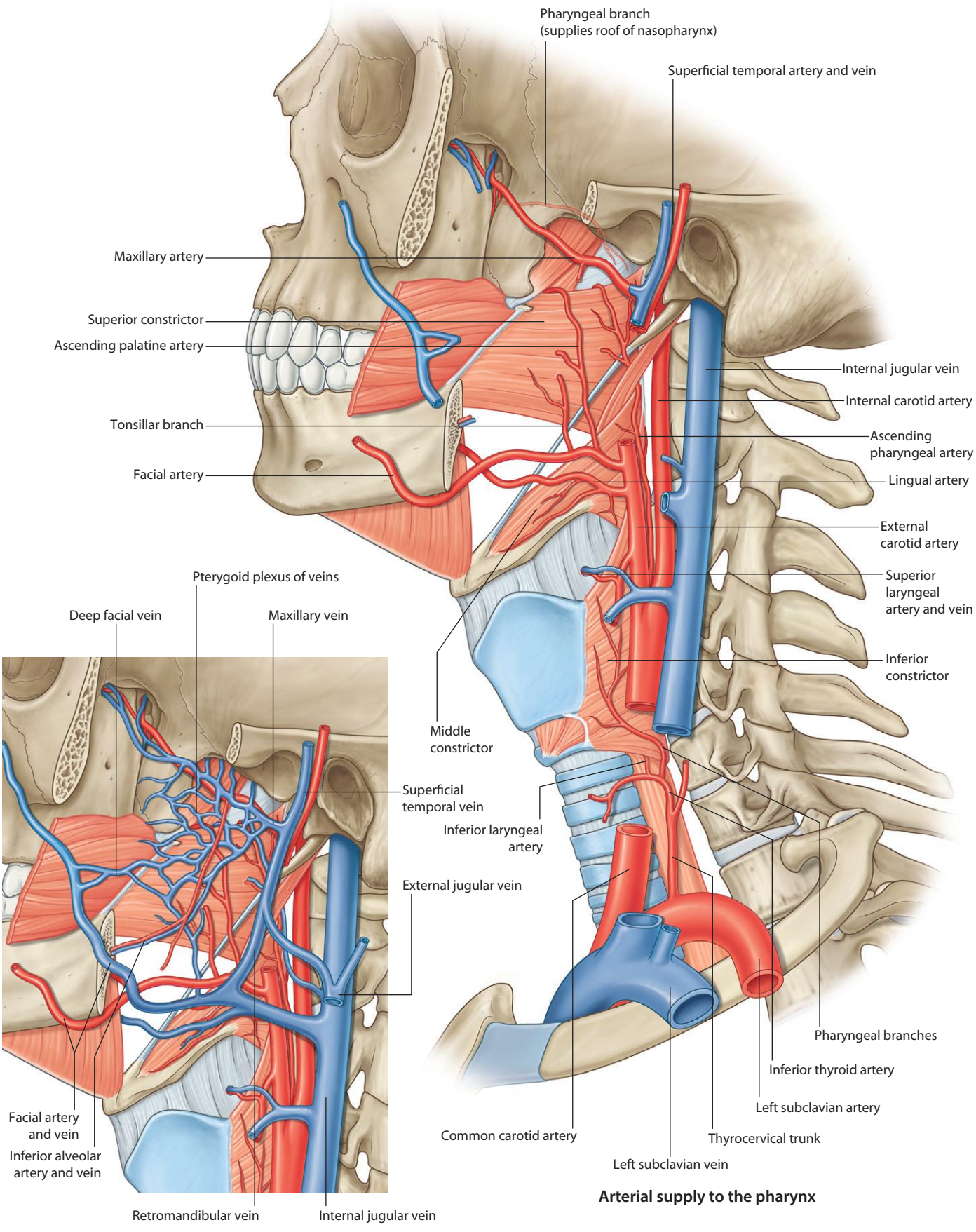

Arterial supply to the pharynx

Venous drainage of the pharynx

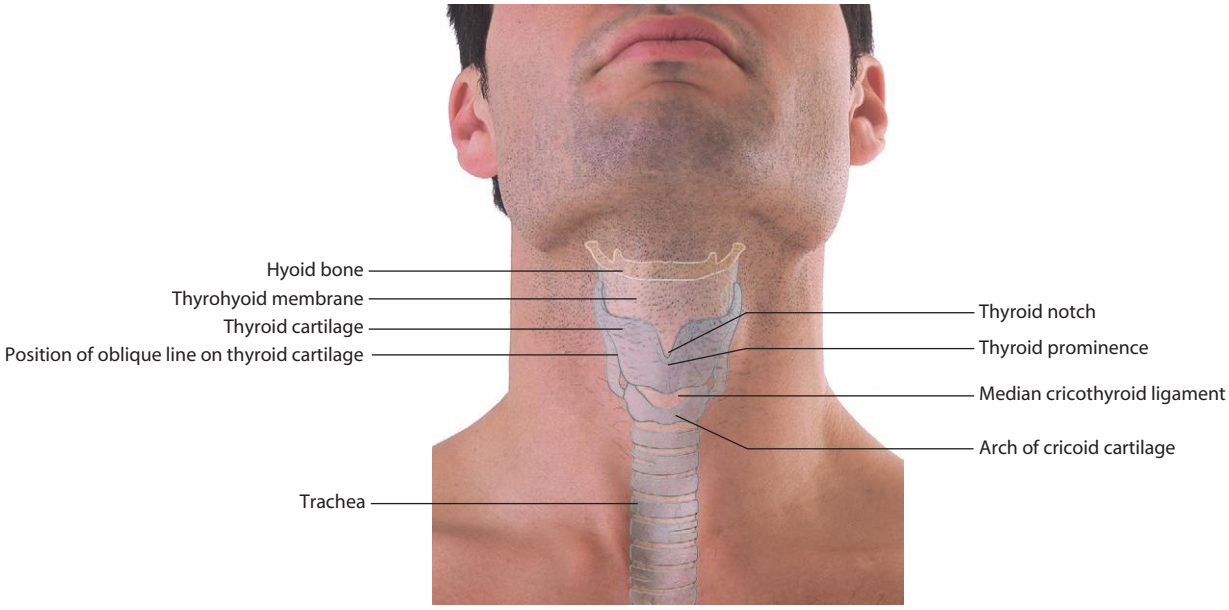

Position of larynx in the neck as it relates to the surface

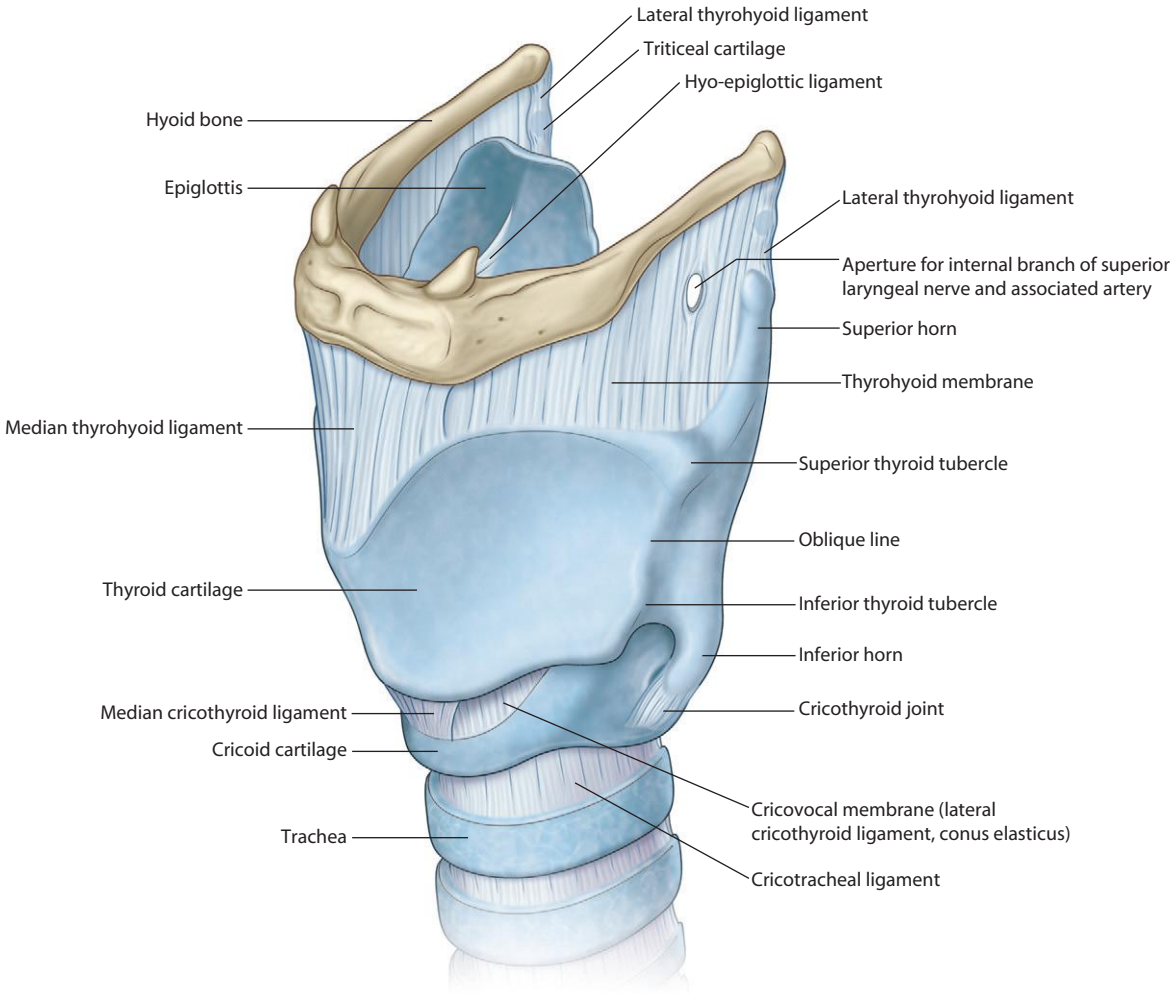

External features of the larynx (anterolateral view)

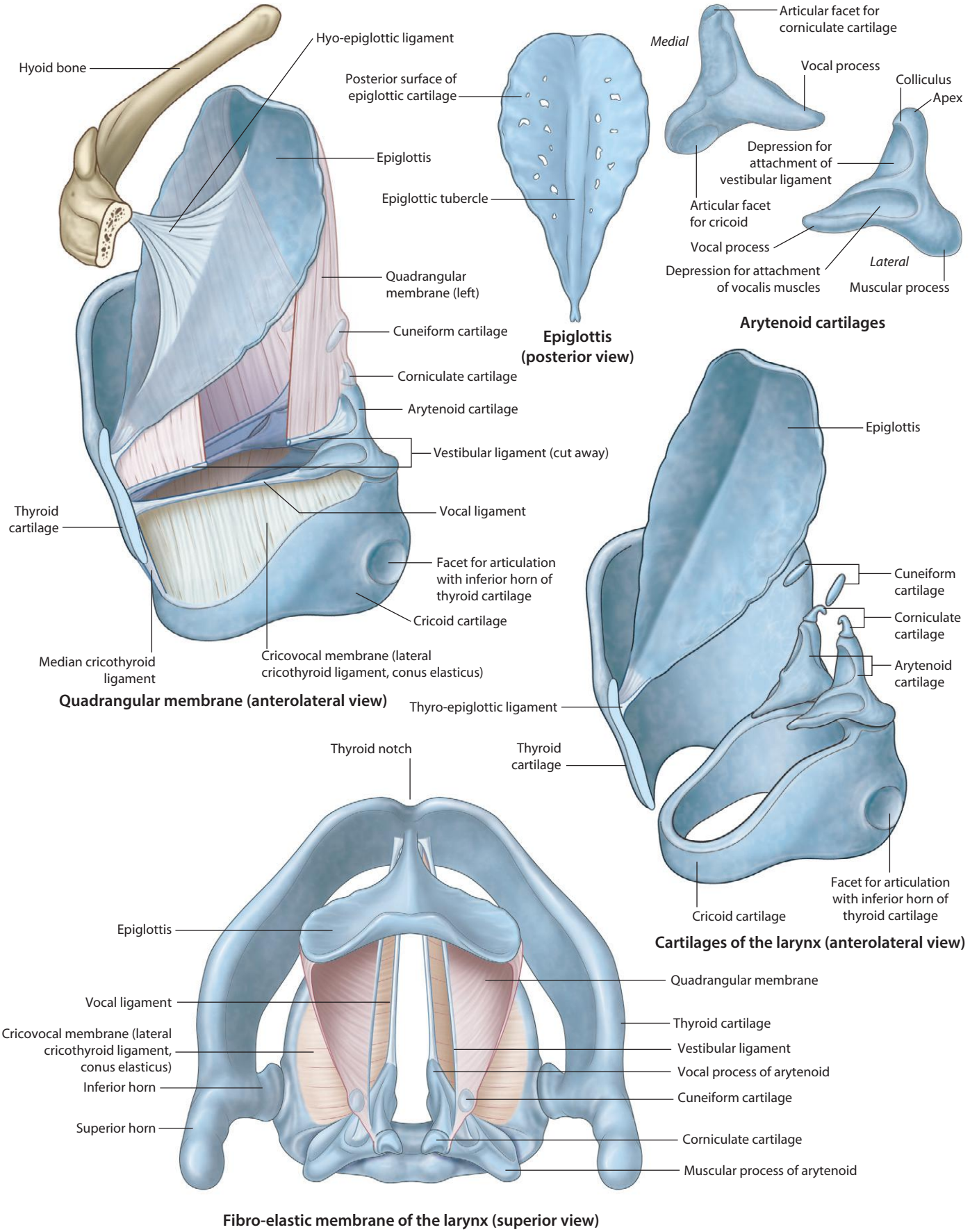
Hyoid bone
Hyo-epiglottic ligament
Epiglottis
Quadrangular membrane (left)
Cuneiform cartilage
Corniculate cartilage
Arytenoid cartilage
Vestibular ligament (cut away)
Vocal ligament
Thyroid cartilage
Facet for articulation with inferior horn of thyroid cartilage
Cricoid cartilage
Median cricothyroid ligament
Cricovocal membrane (lateral cricothyroid ligament, conus elasticus)
Quadrangular membrane (anterolateral view)
Posterior surface of epiglottic cartilage
Epiglottic tubercle
Epiglottis (posterior view)
Medial
Articular facet for corniculate cartilage
Vocal process
Colliculus
Apex
Depression for attachment of vestibular ligament
Articular facet for cricoid
Vocal process
Depression for attachment of vocalis muscles
Lateral
Muscular process
Arytenoid cartilages
Epiglottis
Cuneiform cartilage
Corniculate cartilage
Arytenoid cartilage
Thyro-epiglottic ligament
Thyroid cartilage
Facet for articulation with inferior horn of thyroid cartilage
Cricoid cartilage
Cartilages of the larynx (anterolateral view)
Thyroid notch
Epiglottis
Vocal ligament
Cricovocal membrane (lateral cricothyroid ligament, conus elasticus)
Inferior horn
Superior horn
Quadrangular membrane
Thyroid cartilage
Vestibular ligament
Vocal process of arytenoid
Cuneiform cartilage
Corniculate cartilage
Muscular process of arytenoid
Fibro-elastic membrane of the larynx (superior view)

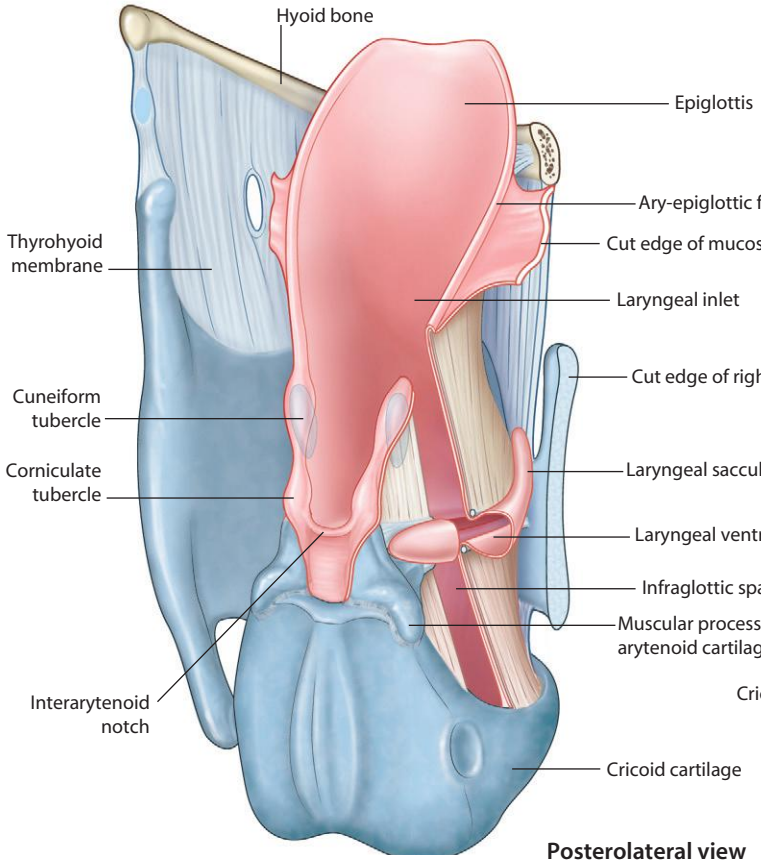

Posterolateral view

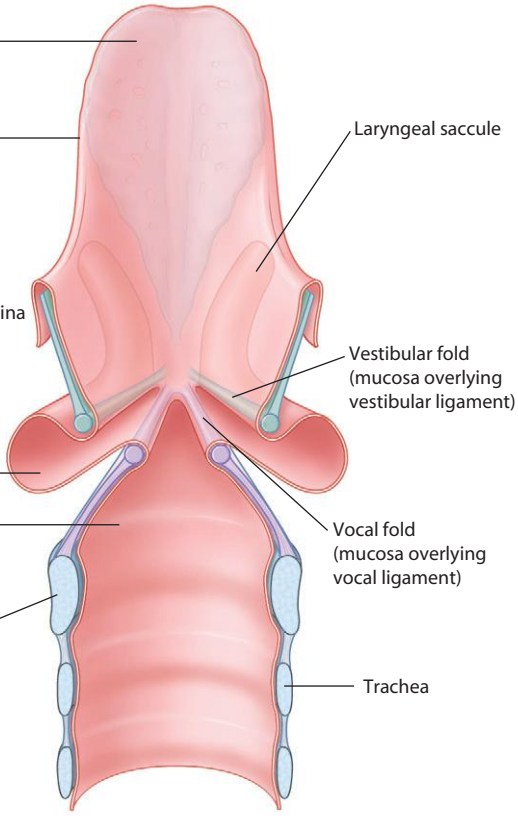

Posterior view (cutaway)

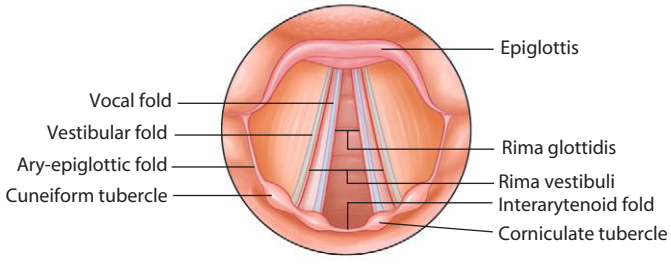

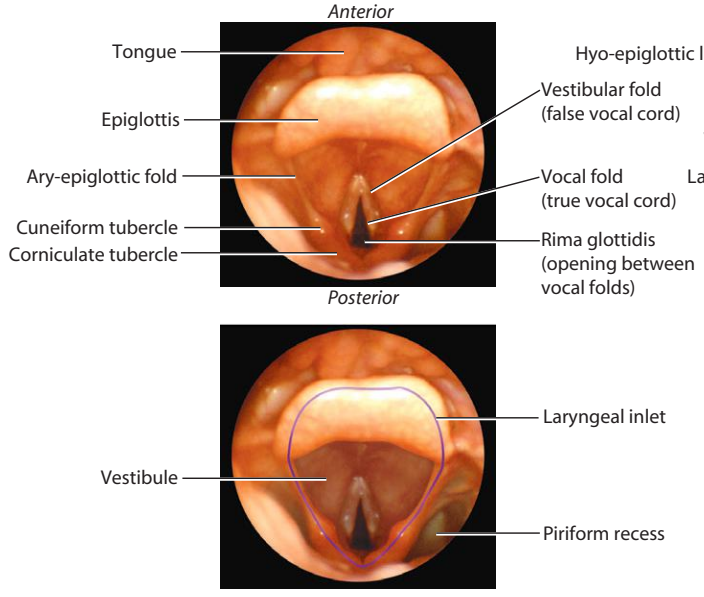

Superior view through the laryngeal inlet

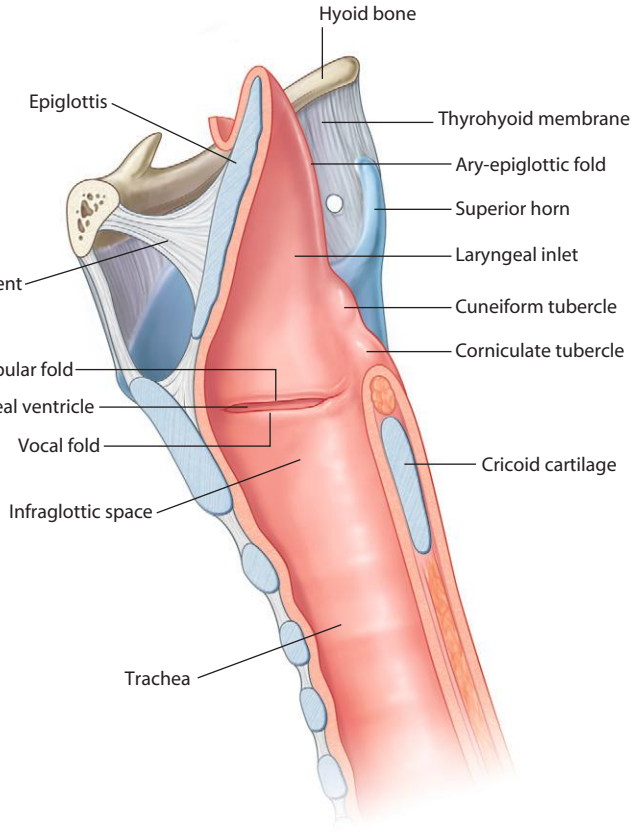

Sagittal section through laryngeal cavity

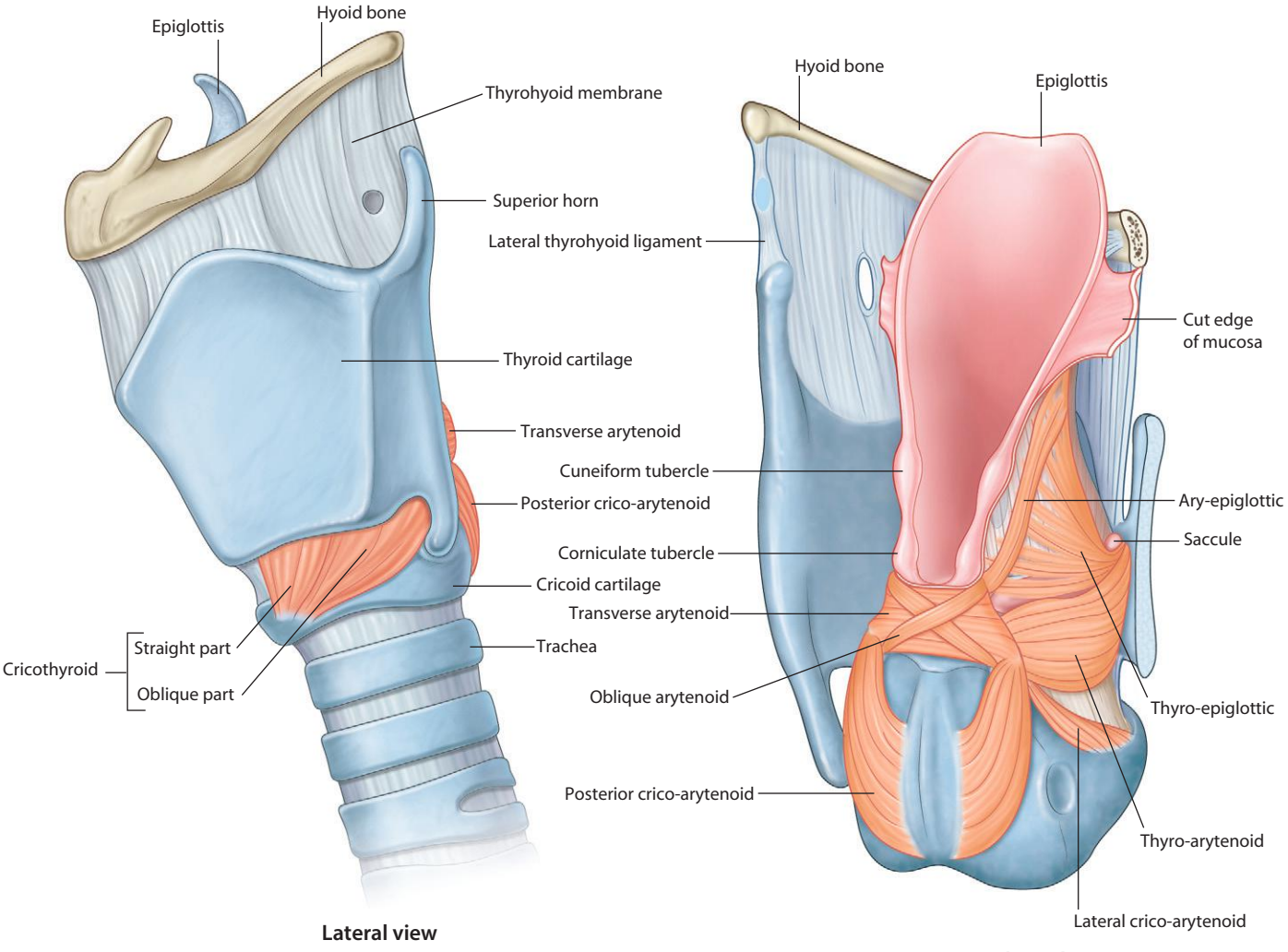

Lateral view

Posterolateral view

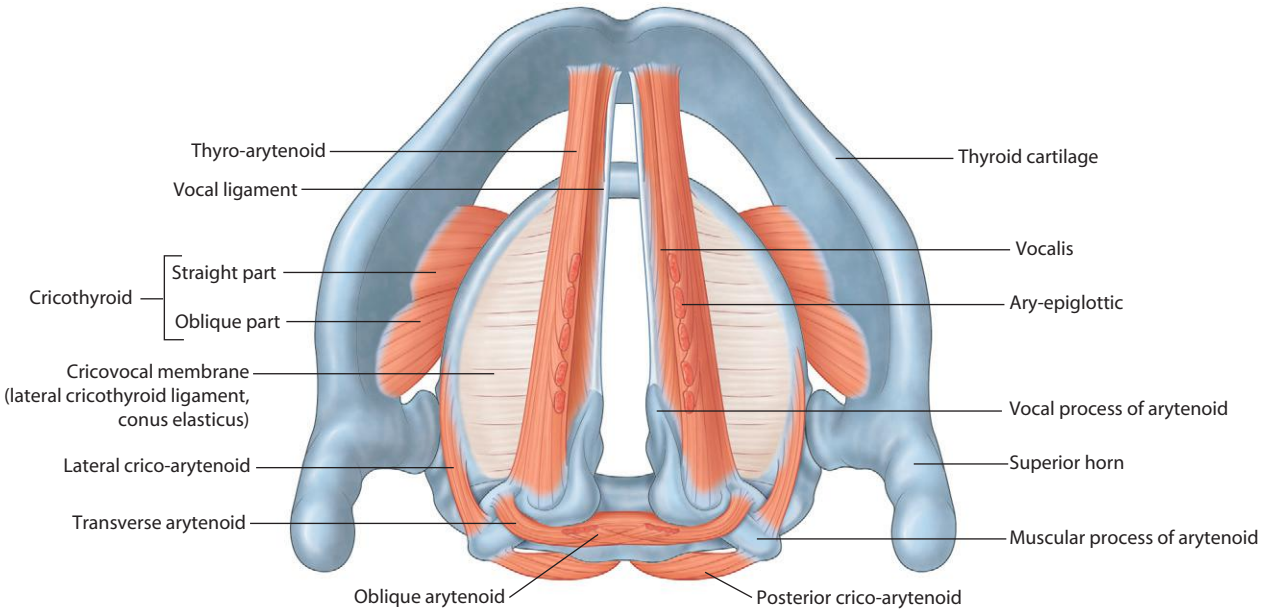

Superior view

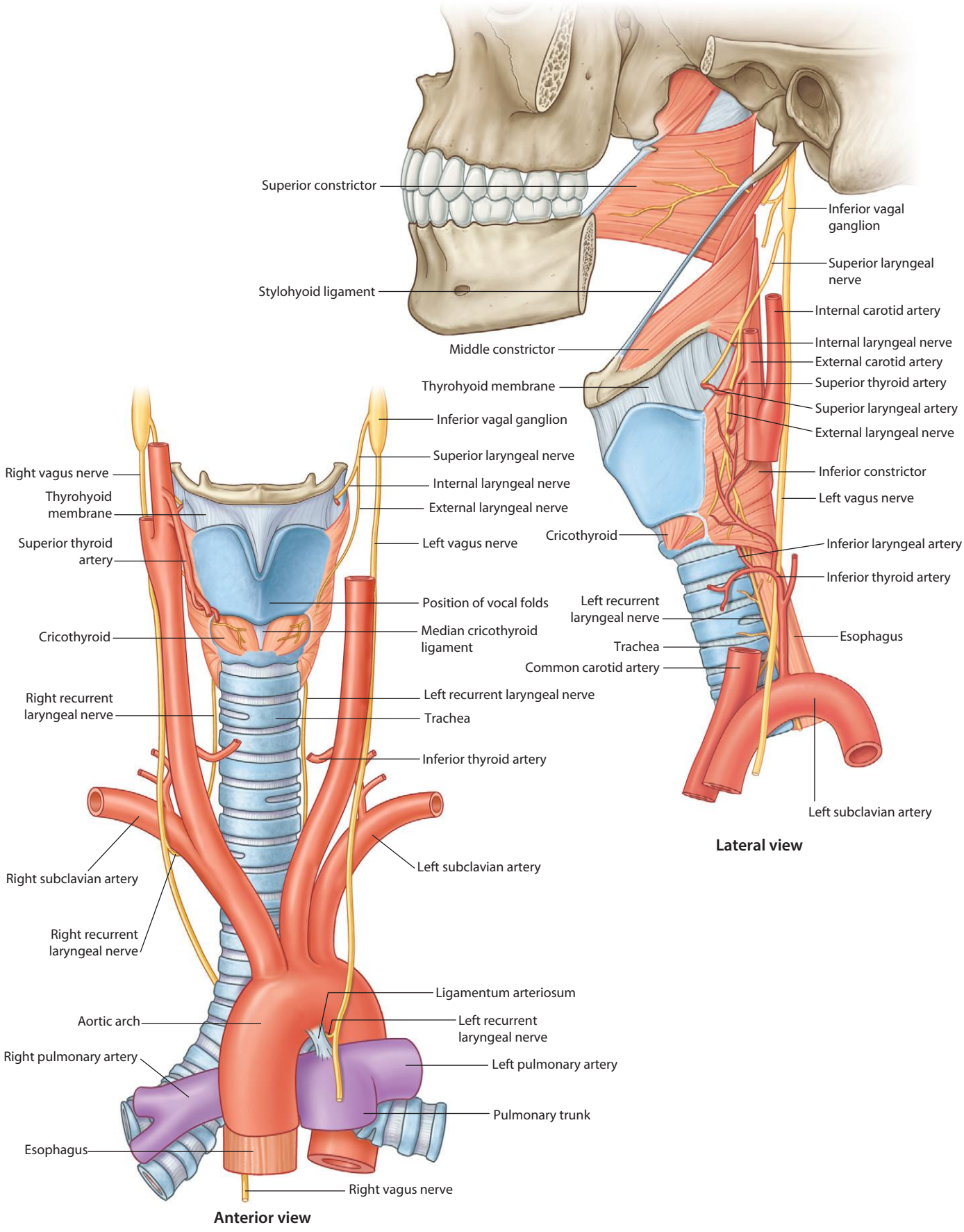
Superior constrictor
Stylohyoid ligament
Middle constrictor
Thyrohyoid membrane
Inferior vagal ganglion
Superior laryngeal nerve
Internal laryngeal nerve
External laryngeal nerve
Left vagus nerve
Right vagus nerve
Thyrohyoid membrane
Superior thyroid artery
Position of vocal folds
Cricothyroid
Median cricothyroid ligament
Right recurrent laryngeal nerve
Left recurrent laryngeal nerve
Trachea
Inferior thyroid artery
Right subclavian artery
Left subclavian artery
Right recurrent laryngeal nerve
Ligamentum arteriosum
Aortic arch
Left recurrent laryngeal nerve
Right pulmonary artery
Left pulmonary artery
Pulmonary trunk
Esophagus
Right vagus nerve
Anterior view
Inferior vagal ganglion
Superior laryngeal nerve
Internal carotid artery
Internal laryngeal nerve
External carotid artery
Superior thyroid artery
Superior laryngeal artery
External laryngeal nerve
Inferior constrictor
Left vagus nerve
Cricothyroid
Inferior laryngeal artery
Inferior thyroid artery
Left recurrent laryngeal nerve
Esophagus
Trachea
Common carotid artery
Left subclavian artery
Lateral view

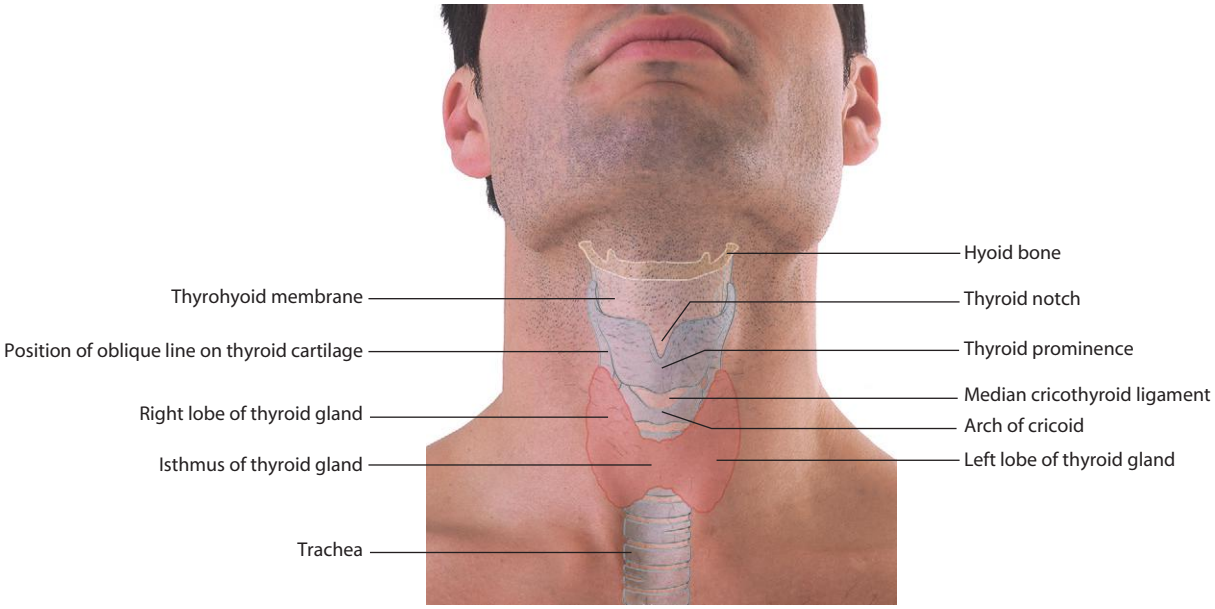

Thyroid gland as it relates to surface

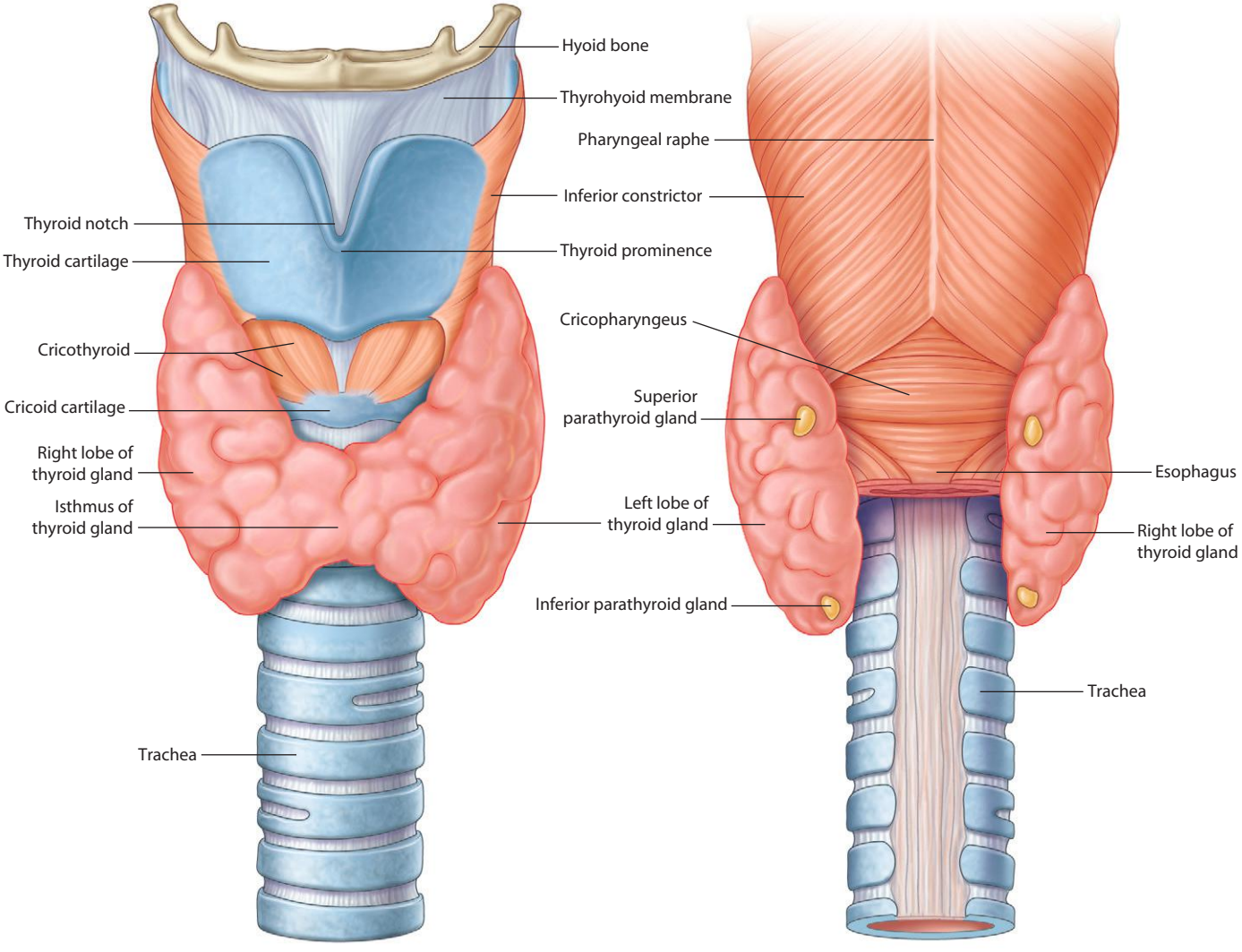

Anterior view **Posterior view**

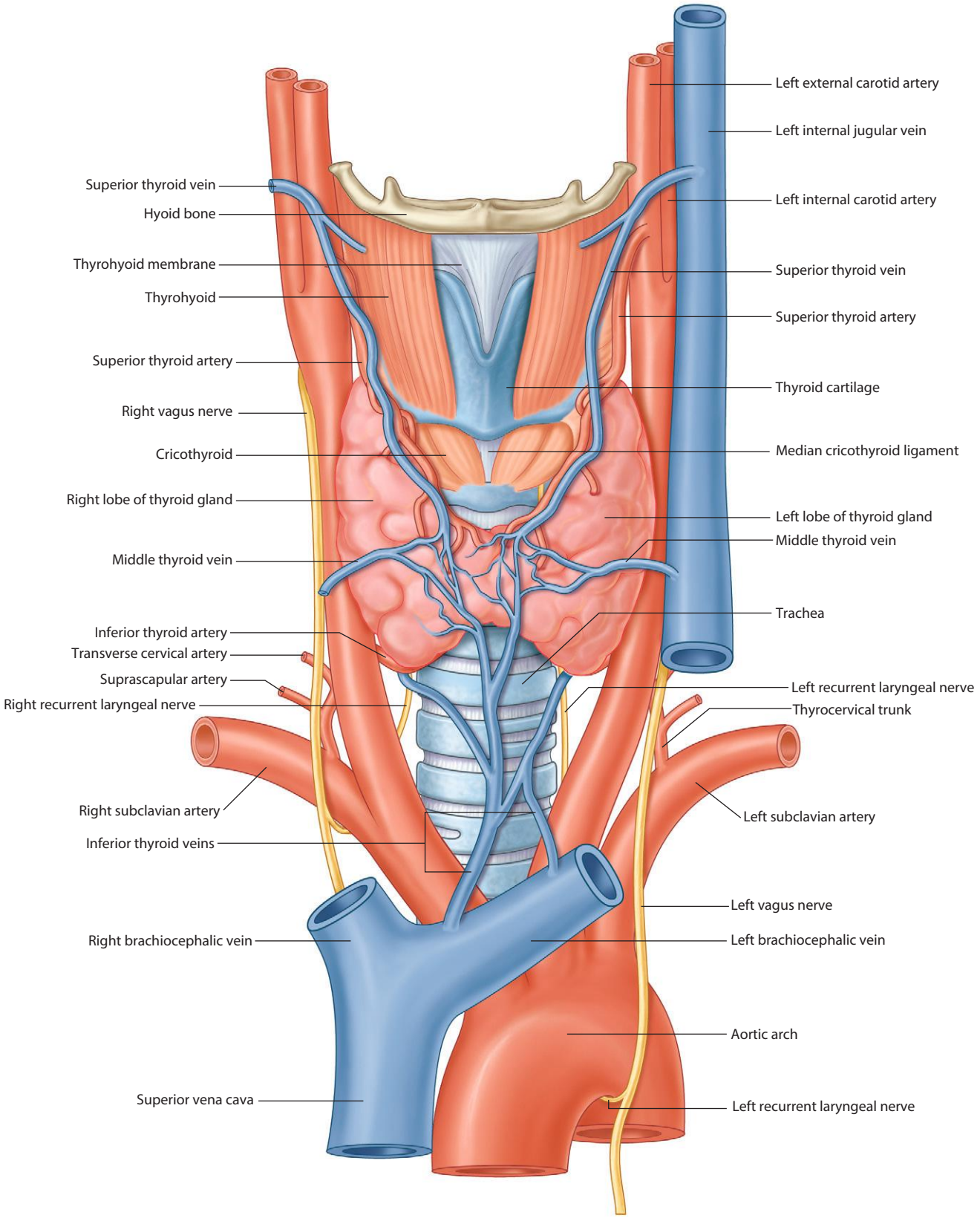

Anterior view

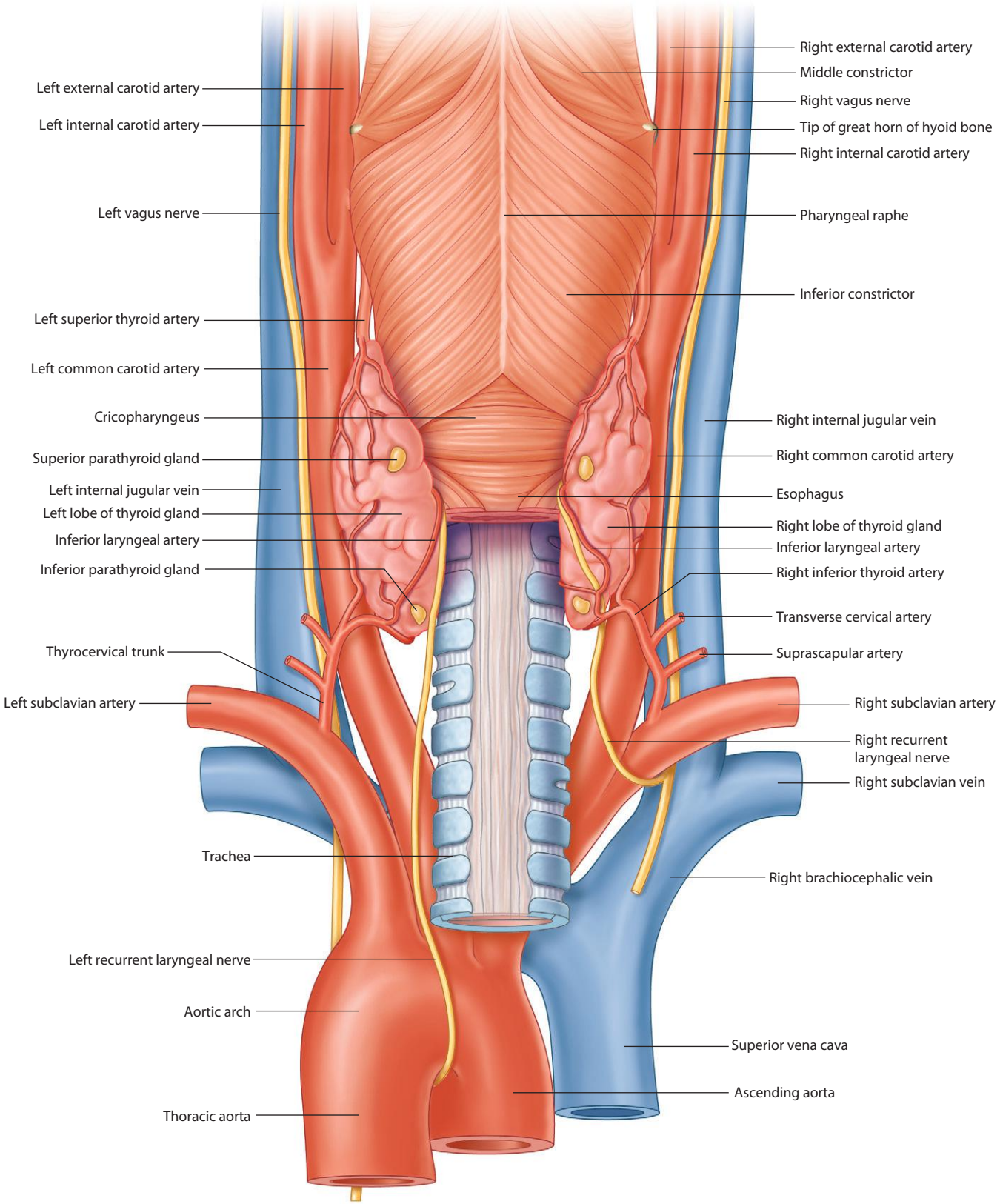

Posterior view

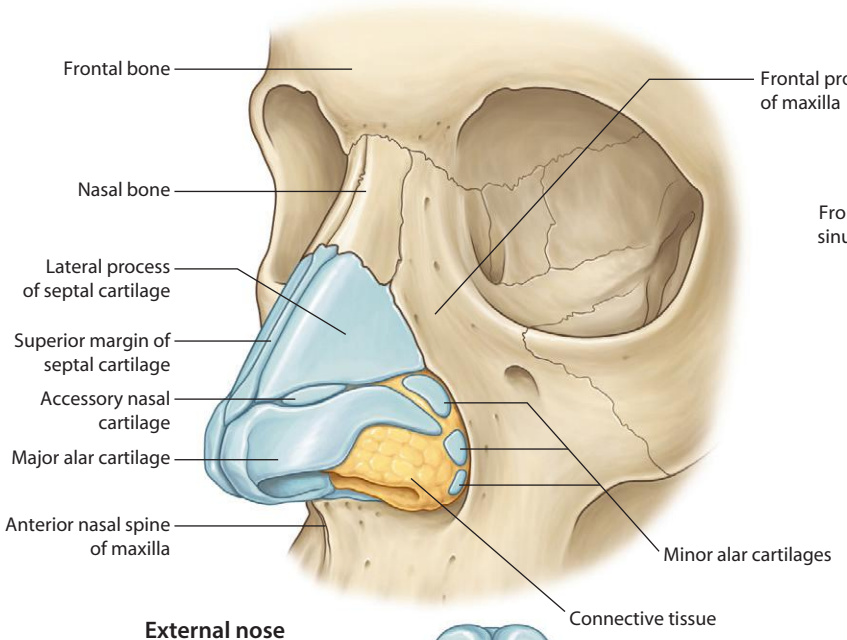

External nose

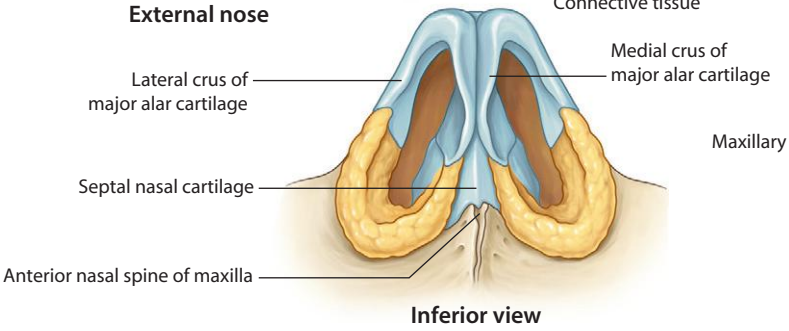

Inferior view

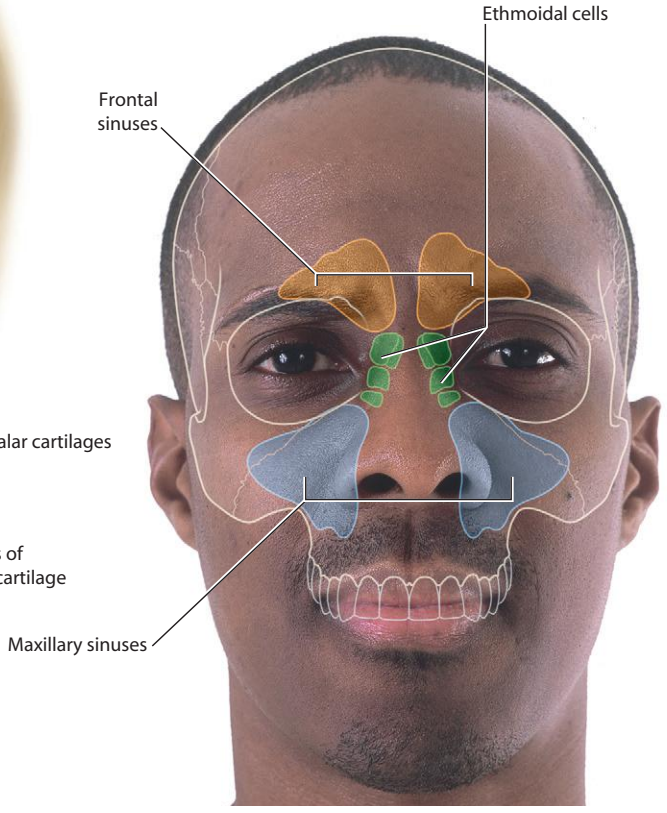

Paranasal sinuses (anterior view)

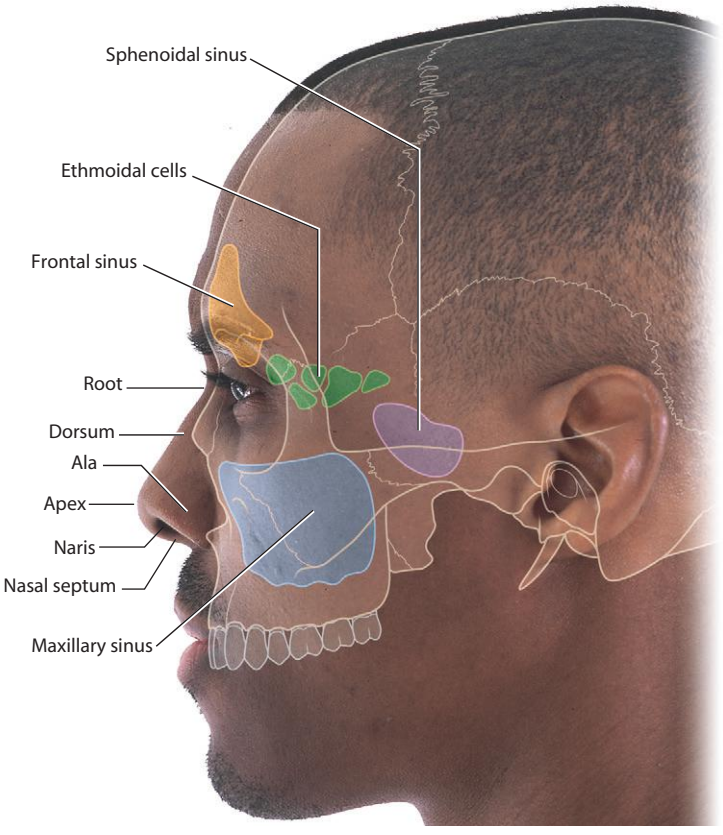

Surface anatomy of nose and paranasal sinuses (lateral view)

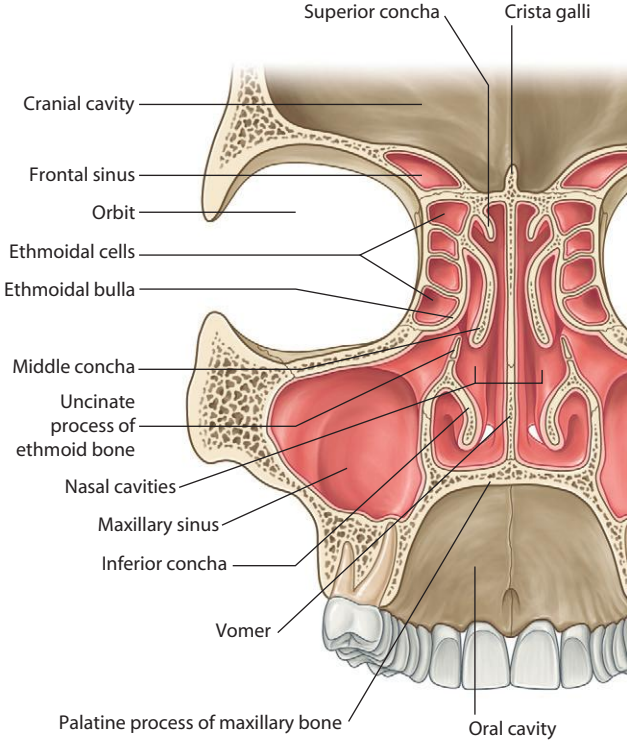

Coronal section through nasal cavity (posterior view)

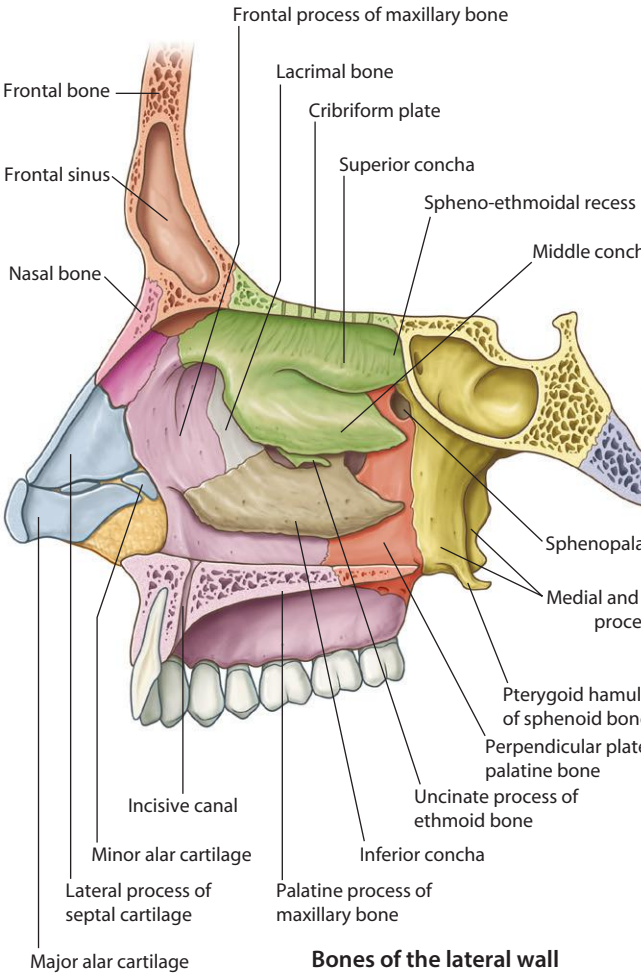

Bones of the lateral wall

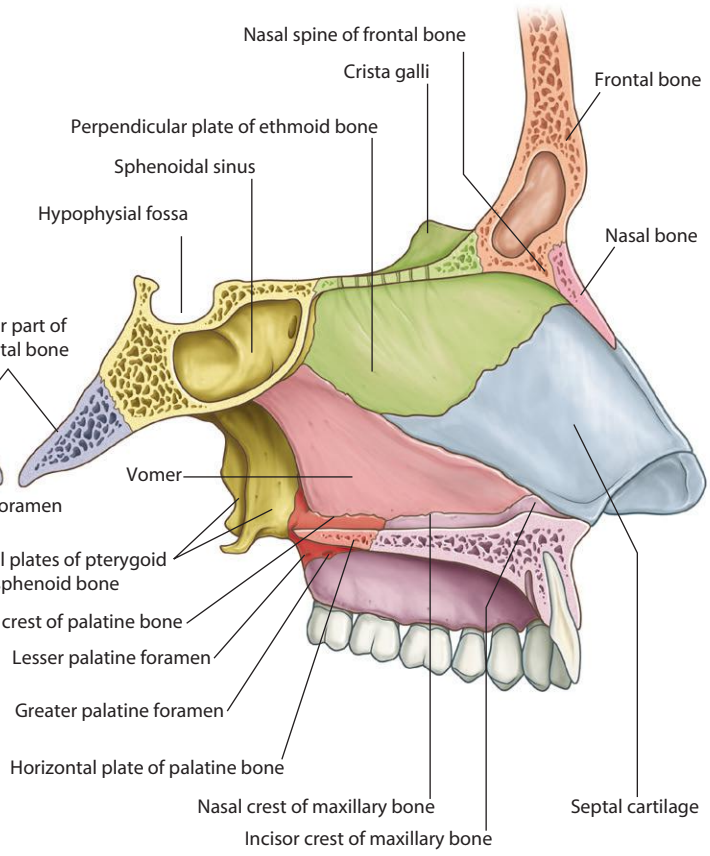

Bones of the medial wall

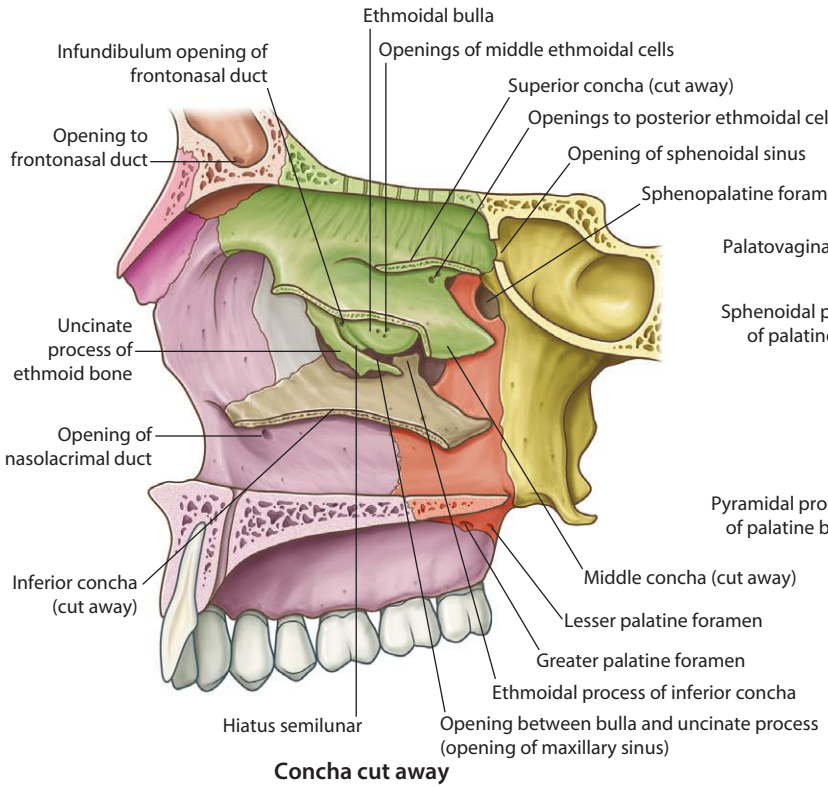

Concha cut away

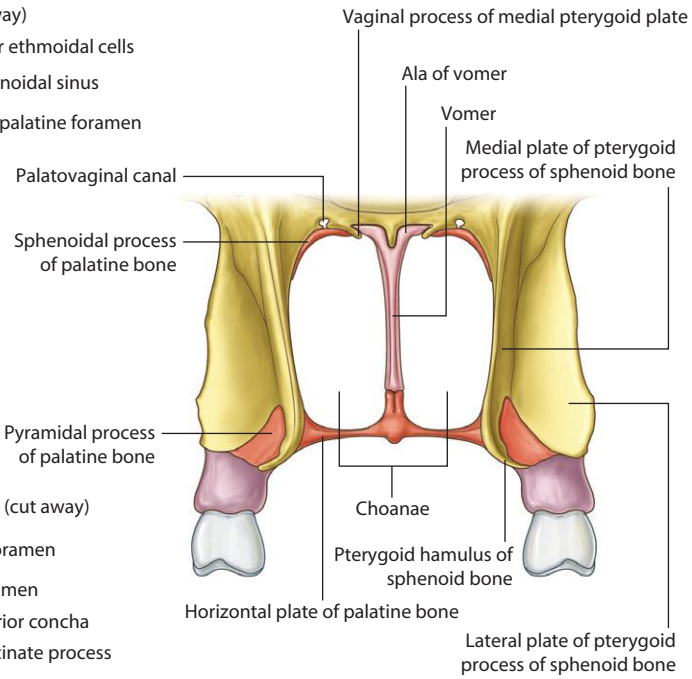

Posterior view

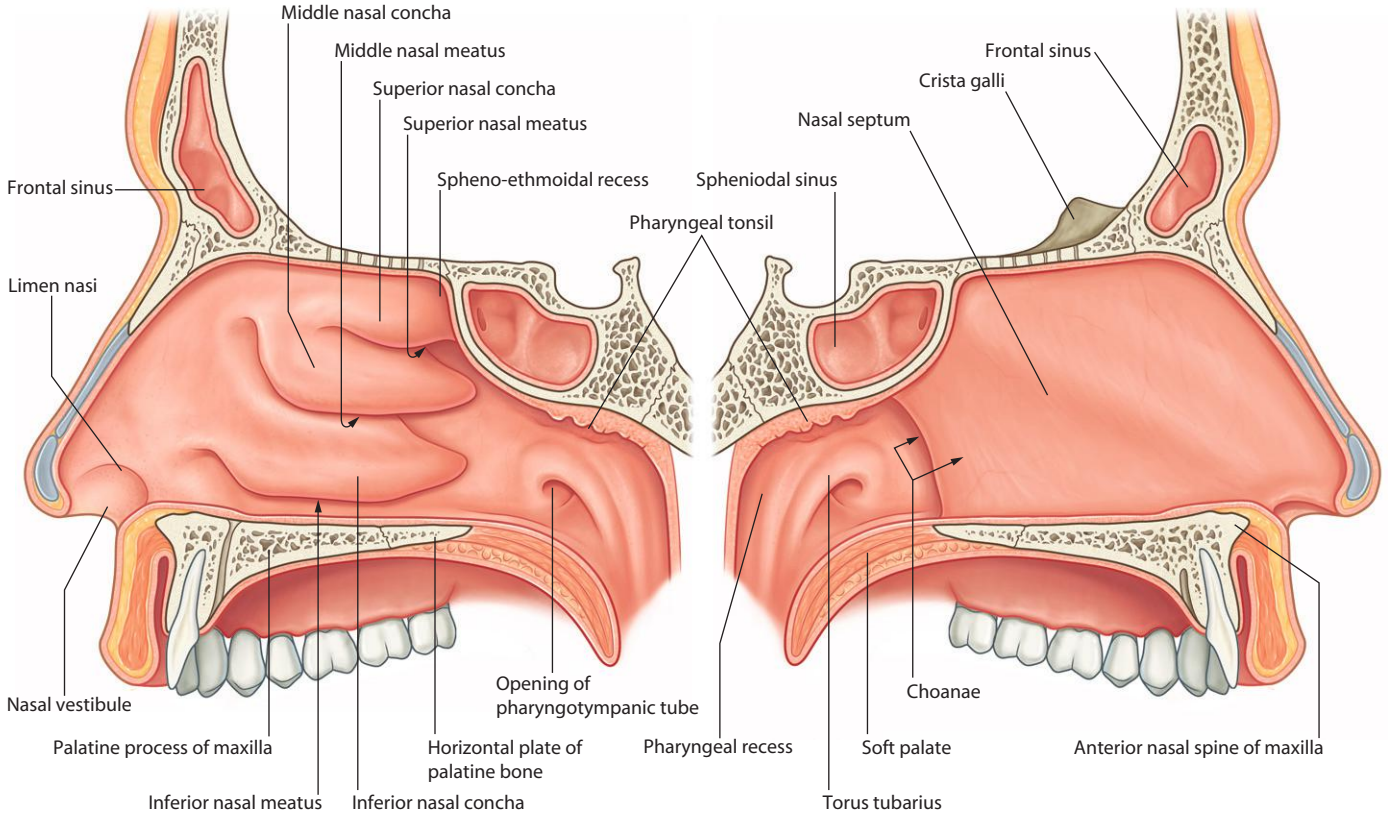

Lateral wall of the nasal cavity **Medial wall of the nasal cavity**

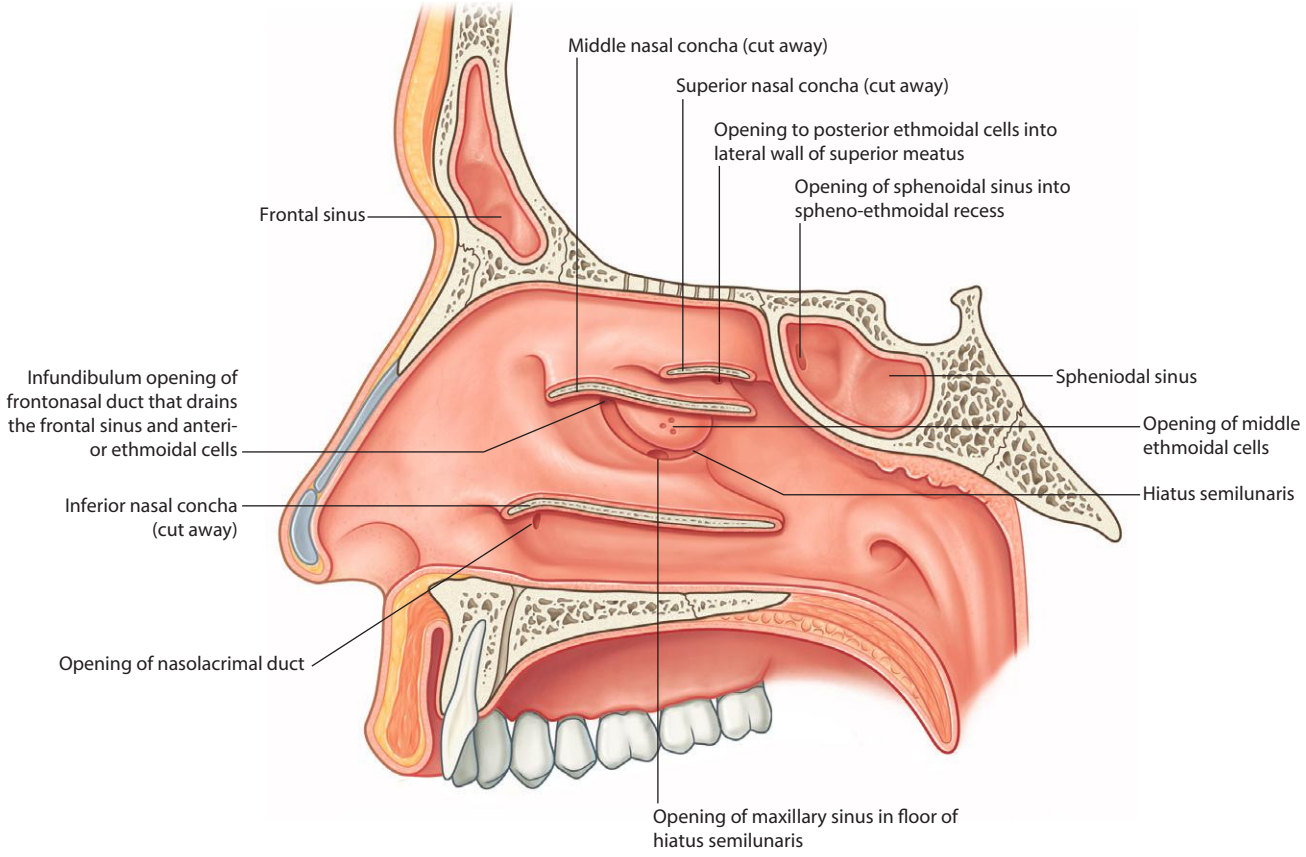

Lateral wall of the nasal cavity, concha cut away

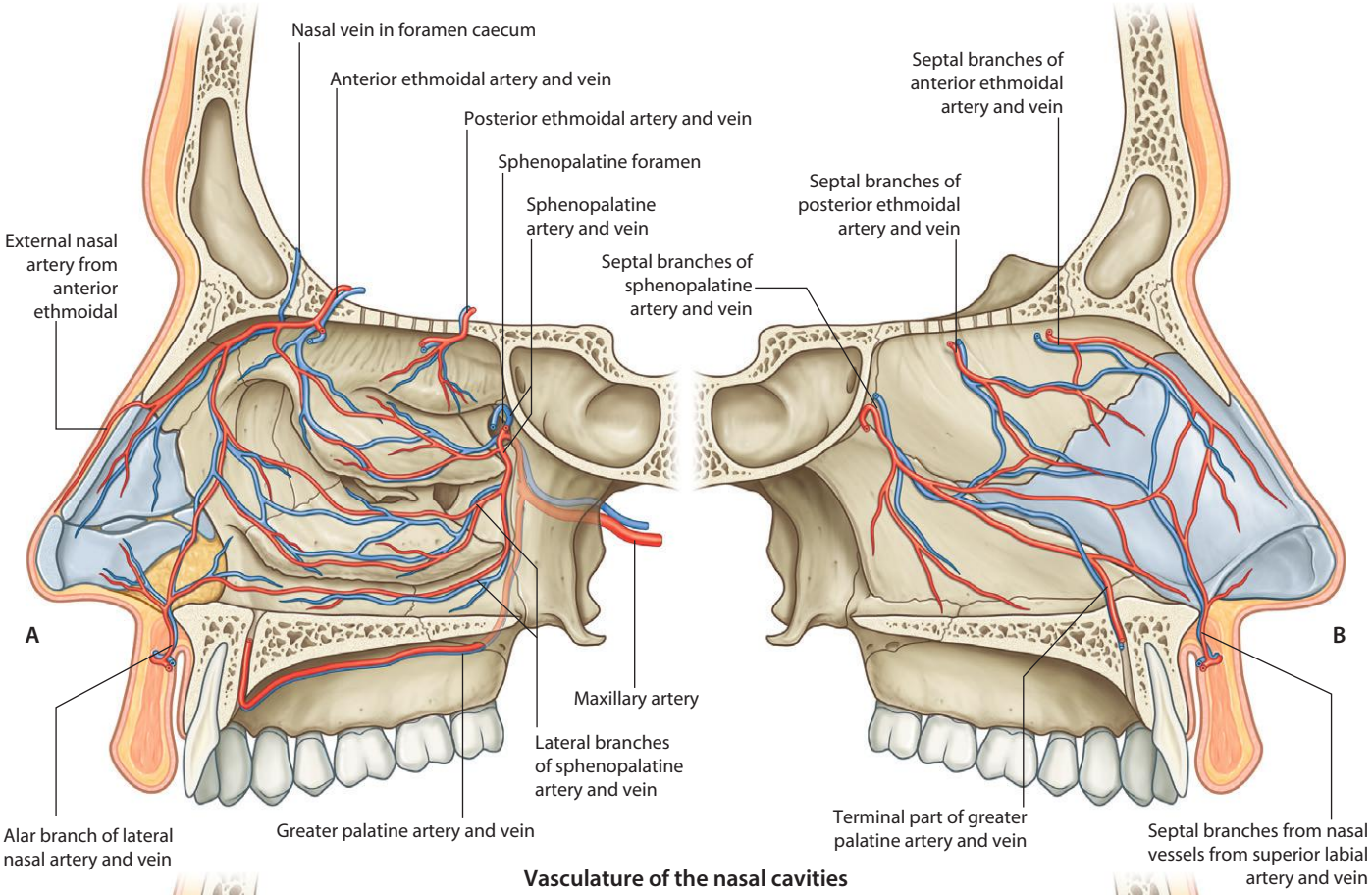

Vasculature of the nasal cavities
A. Lateral wall of right nasal cavity B. Medial wall of right nasal cavity

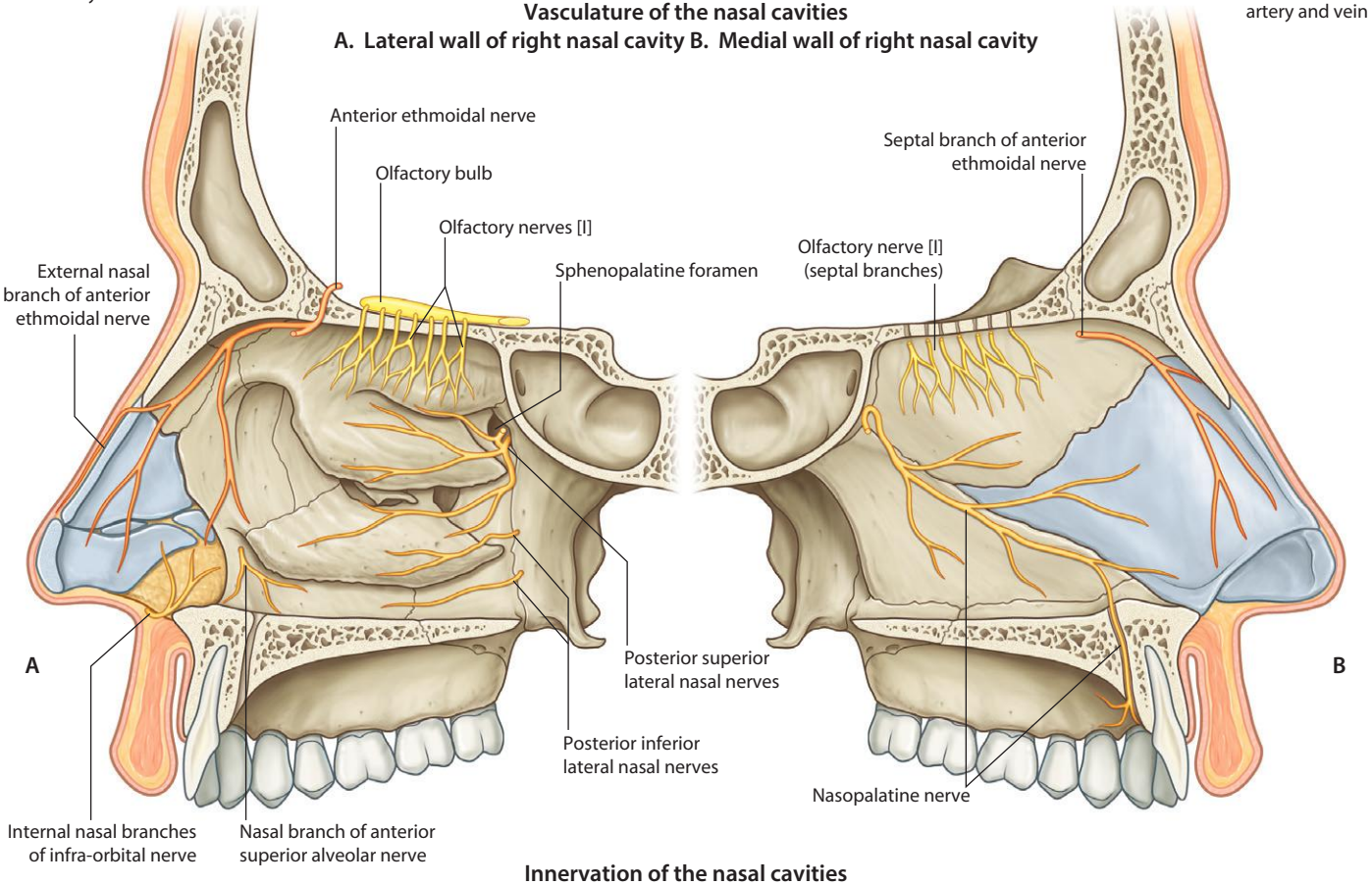

Innervation of the nasal cavities
A. Lateral wall of right nasal cavity B. Medial wall of right nasal cavity

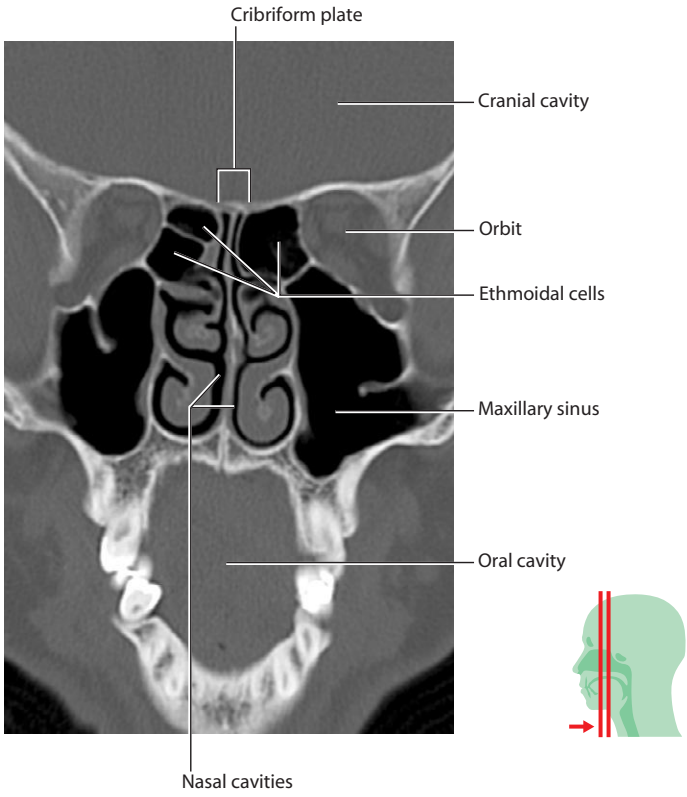

Anterior view of the maxillary sinus and ethmoidal cells.
CT image in coronal plane

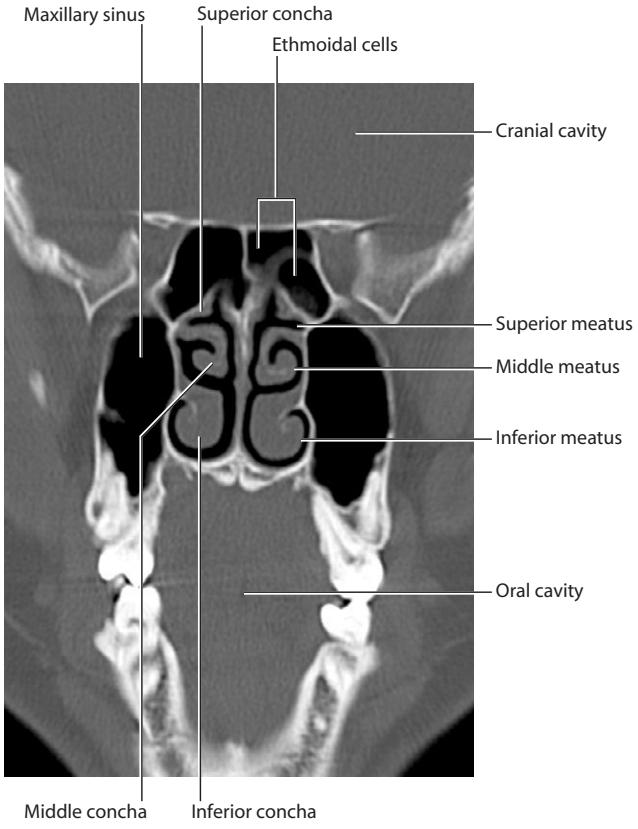

Anterior view looking into the nasal cavity showing the relationship of various structures.
CT image in coronal plane

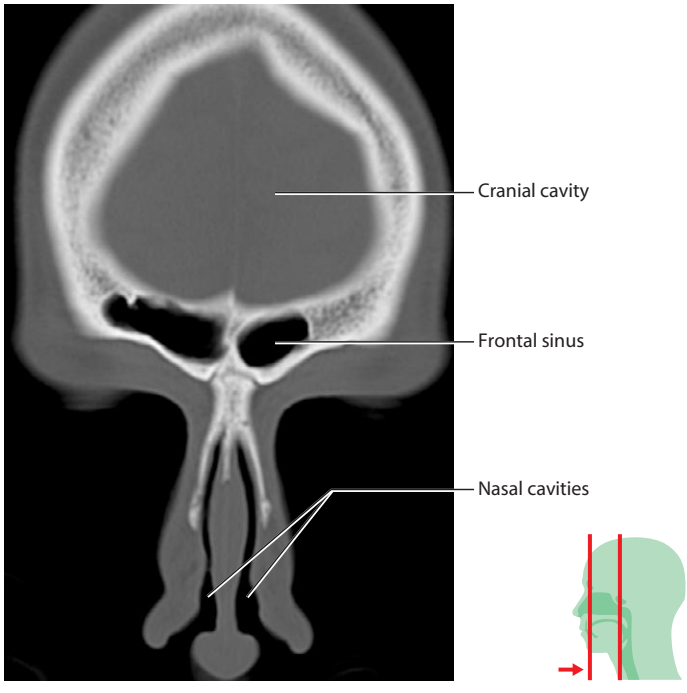

Anterior view of the frontal sinuses.
CT image in coronal plane

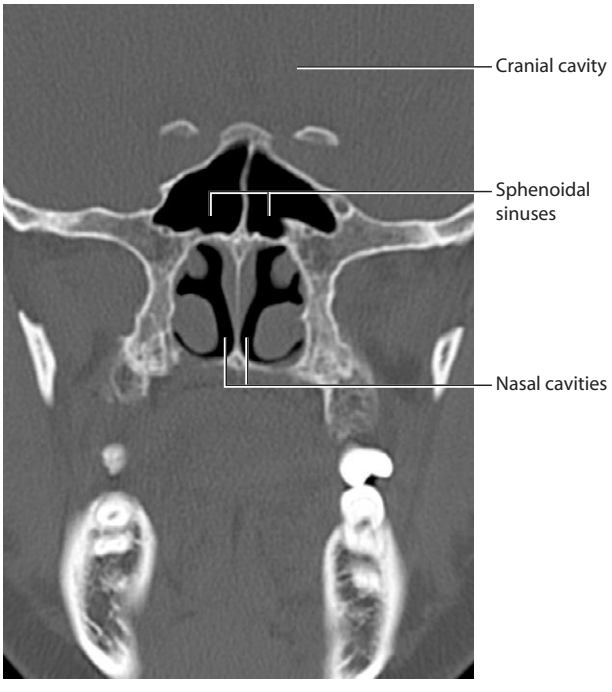

Anterior view of the sphenoidal sinuses showing their relationship to the nasal cavity.
CT image in coronal plane

Axial section showing the relationship among the nasal cavity, nasopharynx, and maxillary sinuses.
CT image in axial plane

Axial section showing the ethmoidal cells and the sphenoidal sinuses and the relationship of these structures to the orbit.
CT image in axial plane

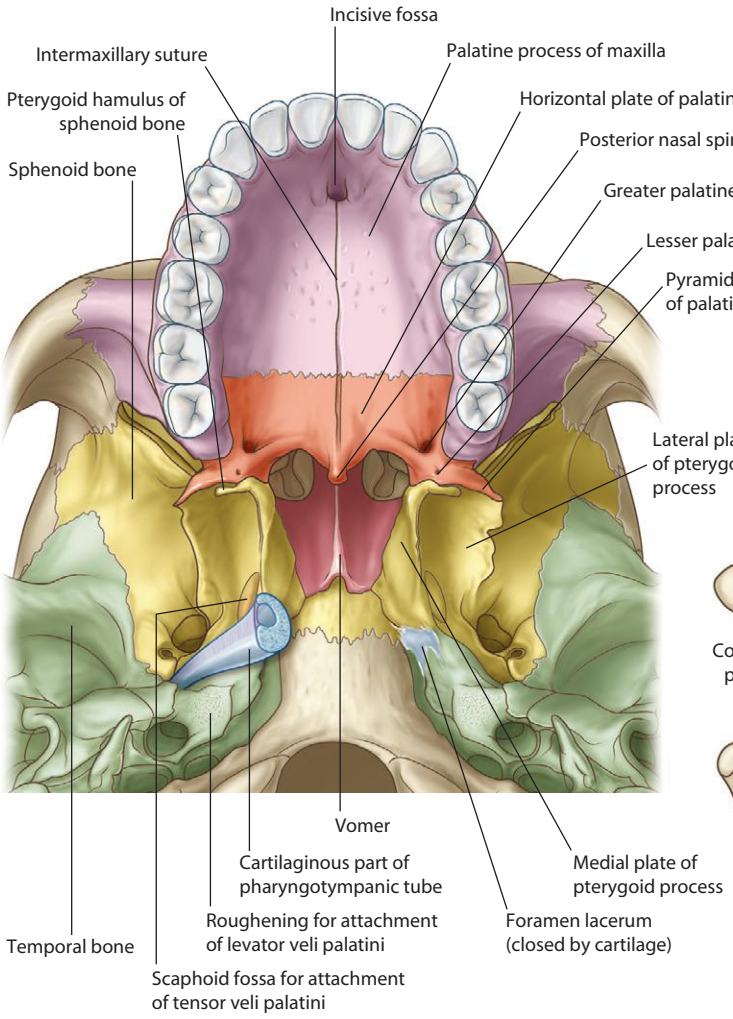

Inferior view of skull

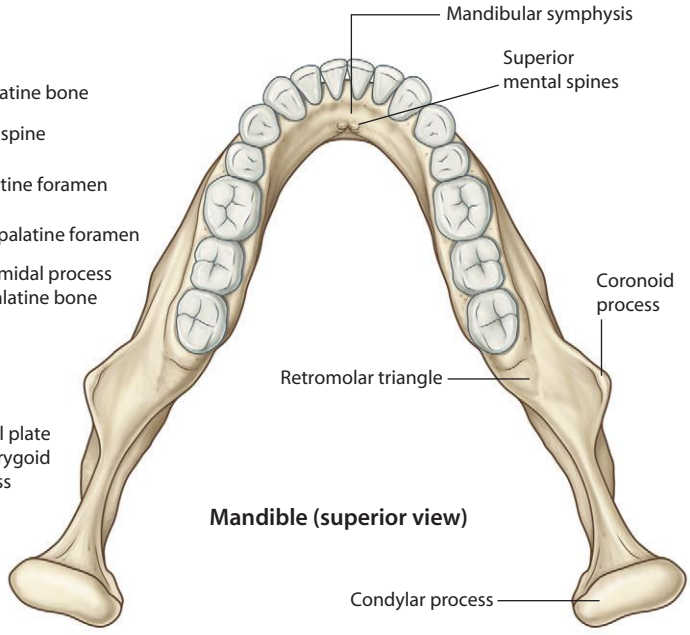

Mandible (superior view)

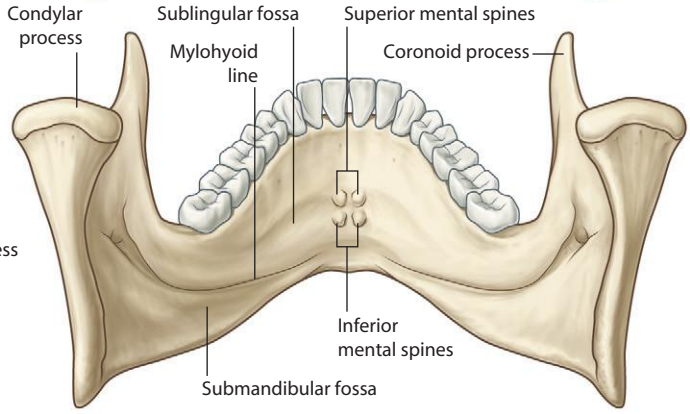

Mandible (posterior view)

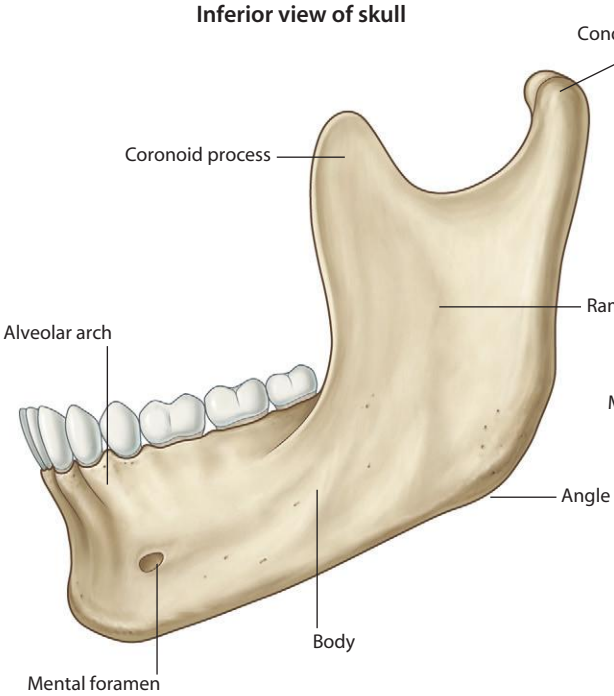

Mandible (lateral view)

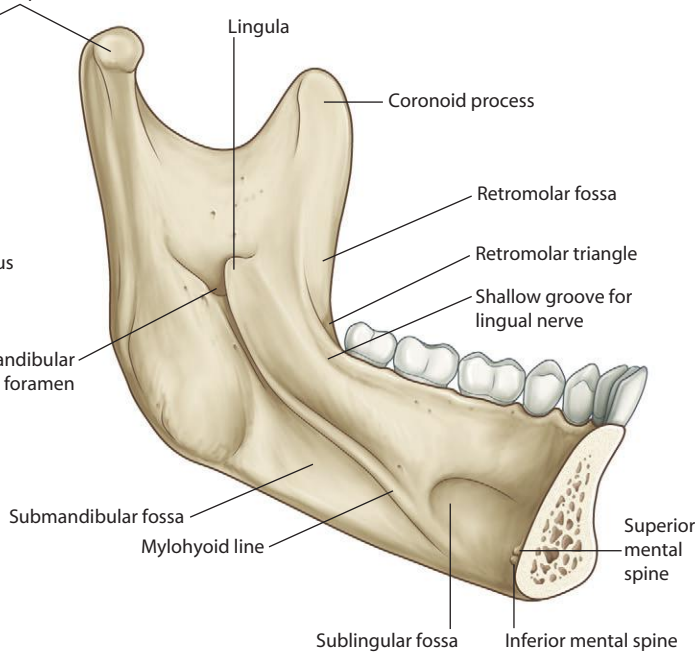

Mandible (medial view)

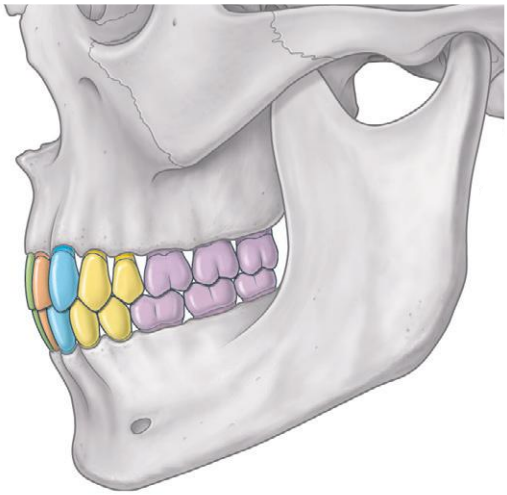

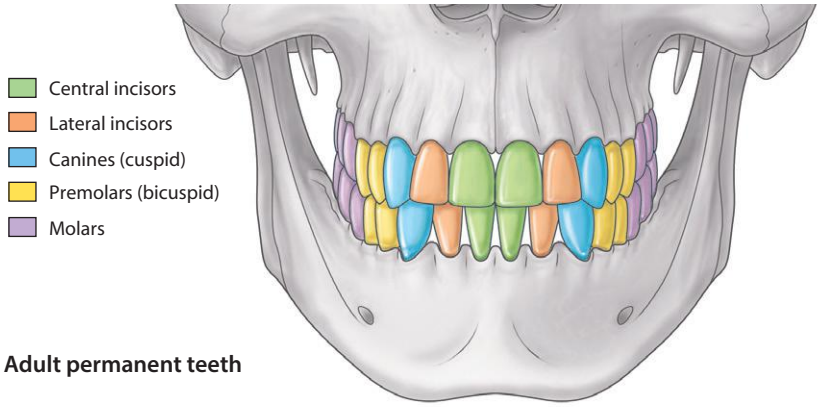

Adult permanent teeth

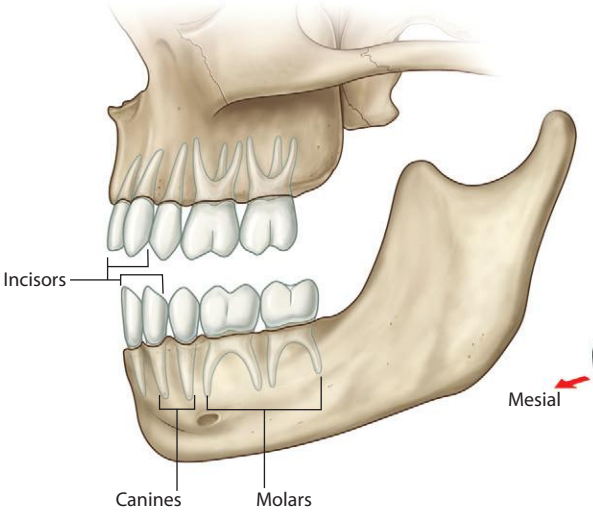

Deciduous (baby) teeth

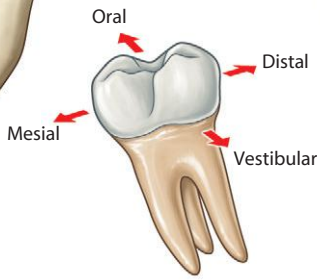

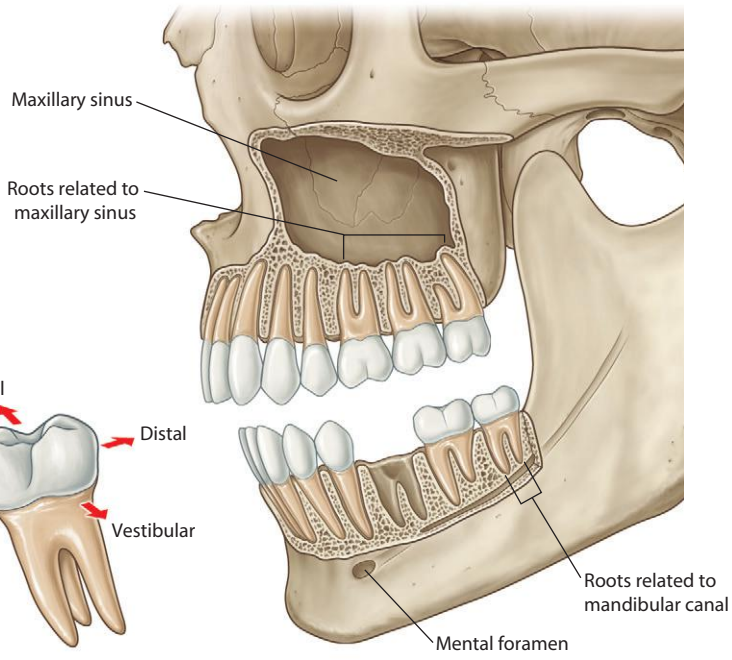

Adult permanent teeth with roots exposed, first molar pulled out

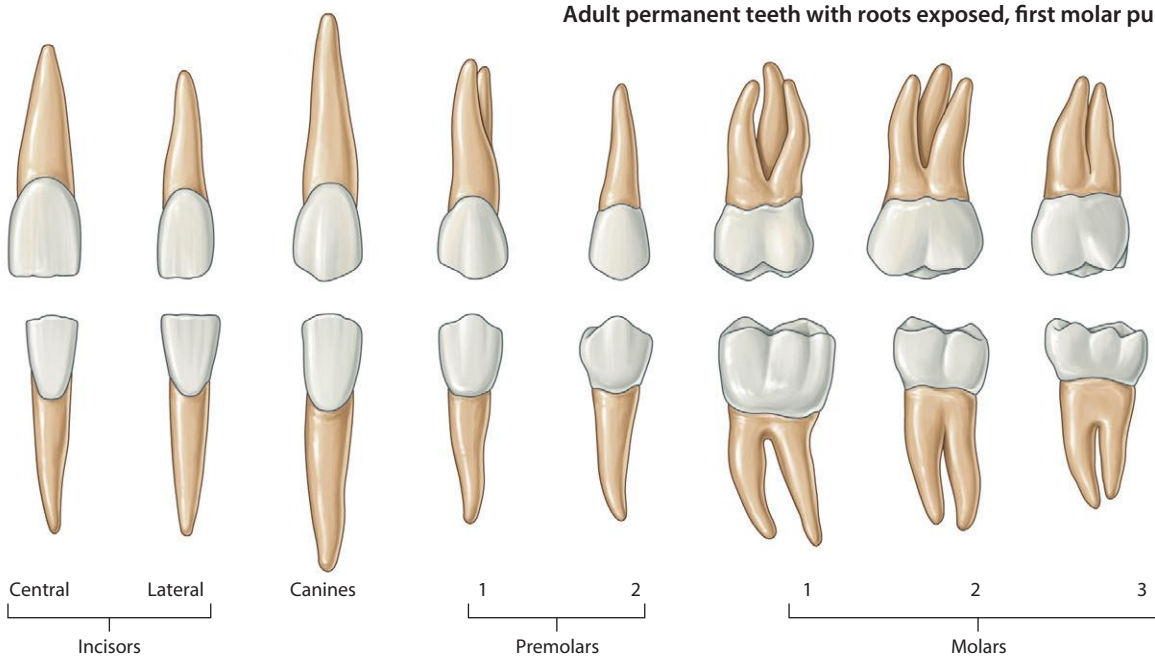

Adult upper and lower permanent teeth (vestibular view)

View of the left side of the face showing the craniofacial structures including the teeth.
Image taken with Cone Beam Computerized Tomography (CBCT) technology, viewed in the Maximum Intensity Projection (MIP) mode, which combines a radiographic view with a view of surface structures

View of the right side of the face showing the craniofacial structures including the teeth.
Image taken with Cone Beam Computerized Tomography (CBCT) technology, viewed in the Maximum Intensity Projection (MIP) mode, which combines a radiographic view with a view of surface structures

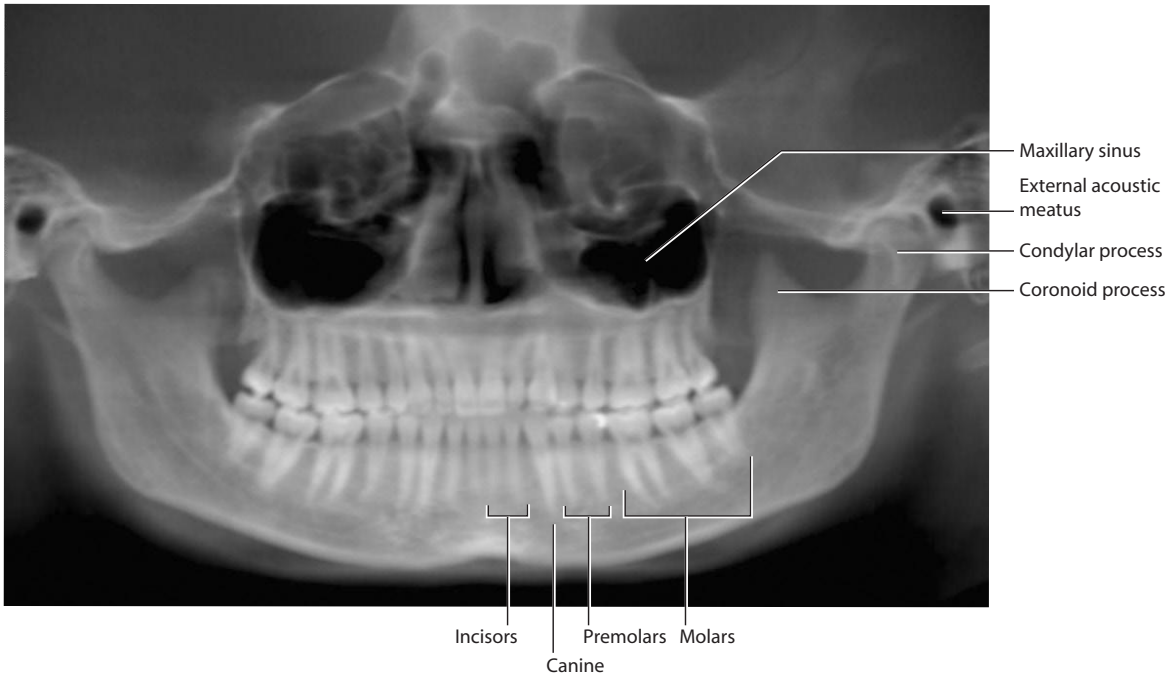

Panoramic view of the teeth (dentition), which also shows the maxillary sinuses and mandibular condylar processes.
Image taken with Cone Beam Computerized Tomography (CBCT) technology

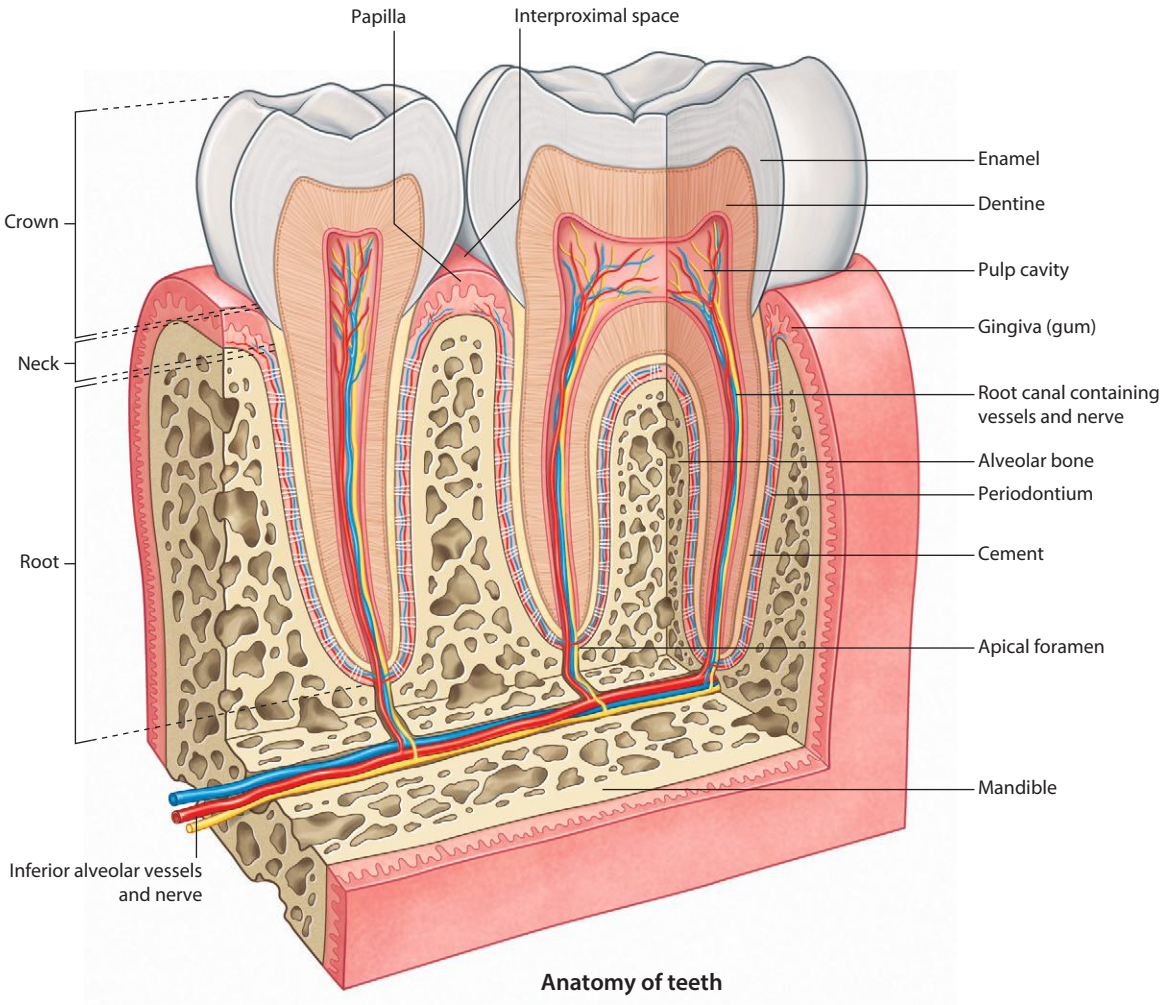

Anatomy of teeth

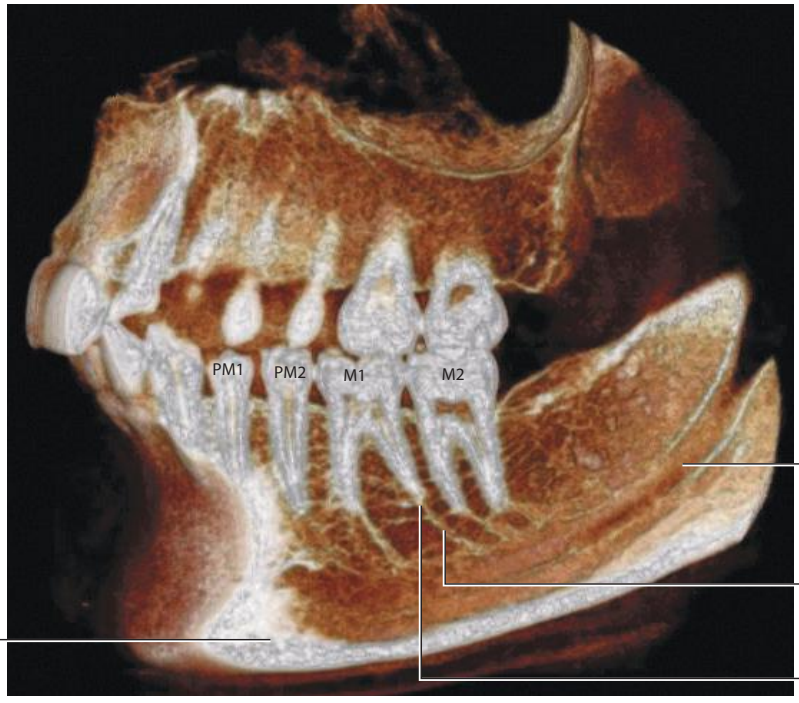

Inside, lingual or sagittal view of the right side of the maxillary and mandibular alveolar processes in occlusion (teeth together).
Image taken with Cone Beam Computerized Tomography (CBCT) technology viewed in the surface mode

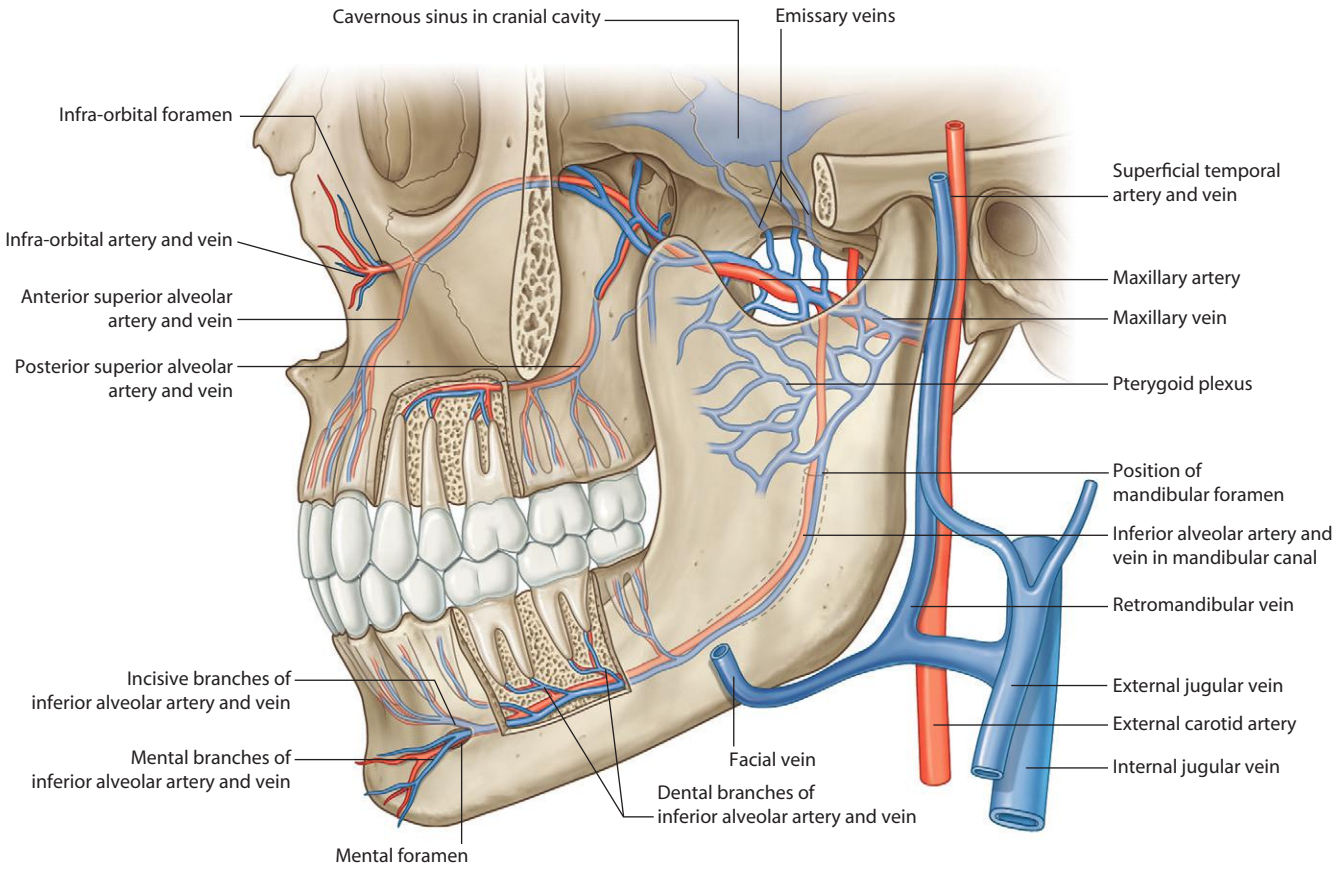

Arteries and veins supplying teeth

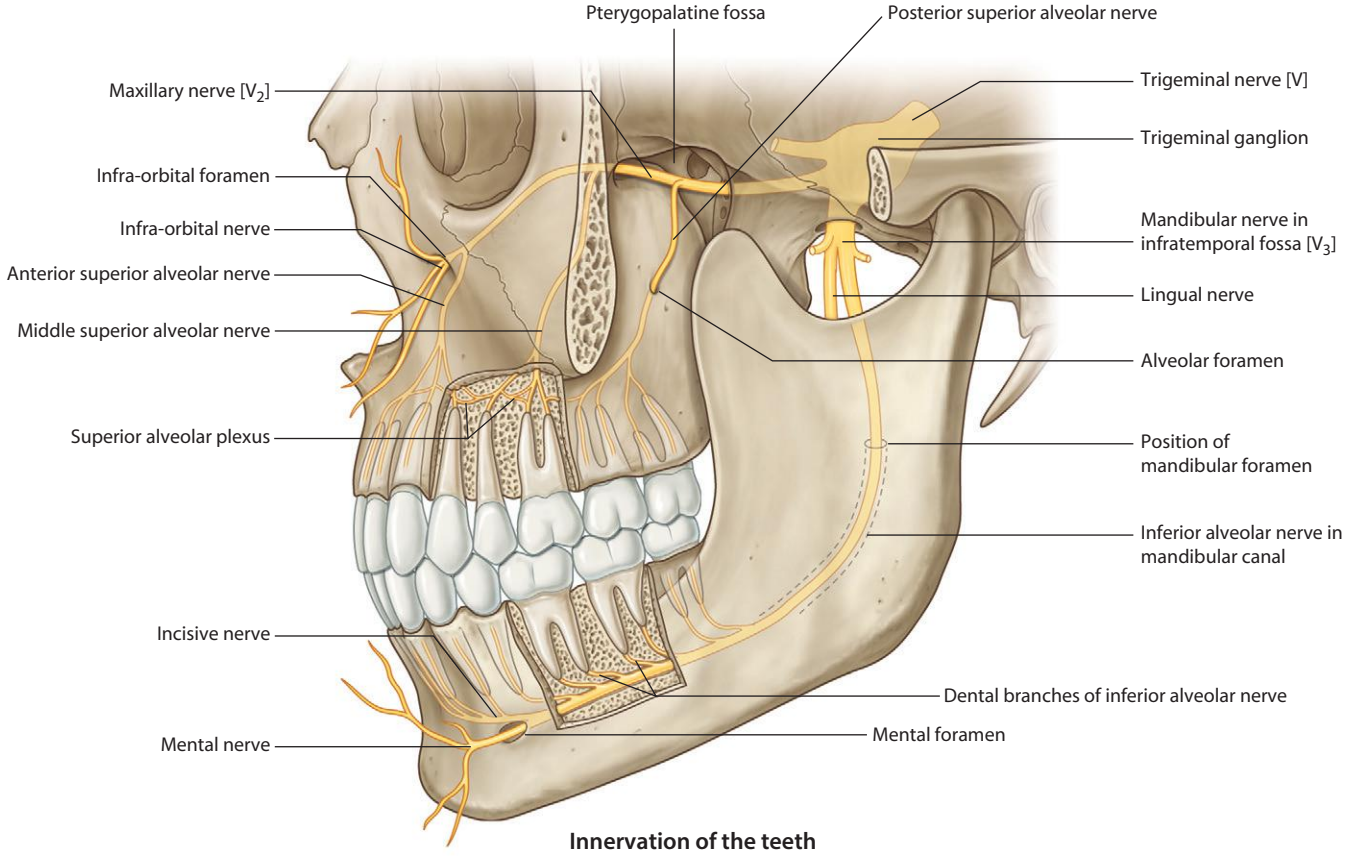

Innervation of the teeth

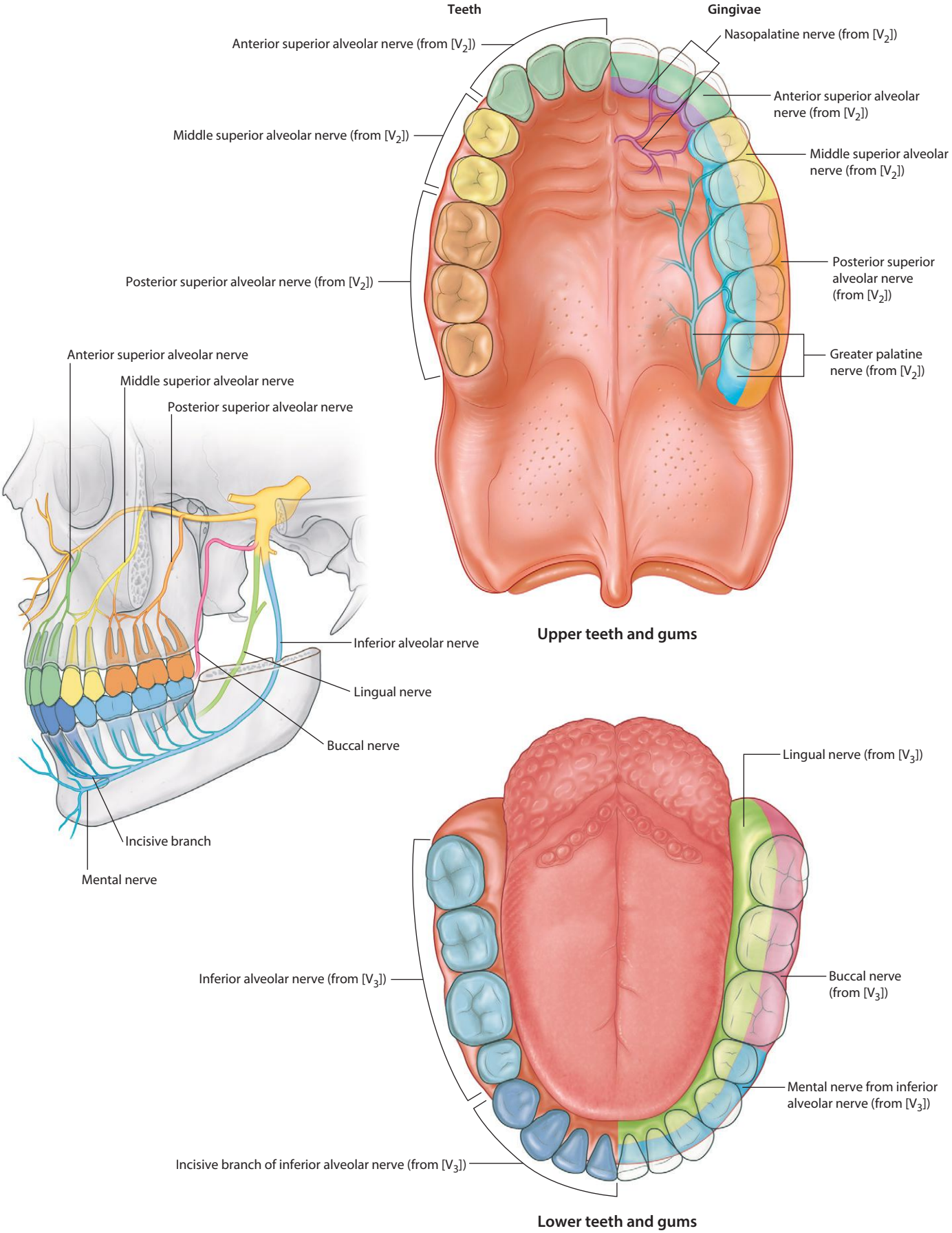
Teeth
Gingivae
Anterior superior alveolar nerve (from [V2])
Nasopalatine nerve (from [V2])
Anterior superior alveolar nerve (from [V2])
Middle superior alveolar nerve (from [V2])
Middle superior alveolar nerve (from [V2])
Posterior superior alveolar nerve (from [V2])
Posterior superior alveolar nerve (from [V2])
Greater palatine nerve (from [V2])
Anterior superior alveolar nerve
Middle superior alveolar nerve
Posterior superior alveolar nerve
Inferior alveolar nerve
Lingual nerve
Buccal nerve
Incisive branch
Mental nerve
Upper teeth and gums
Lingual nerve (from [V3])
Inferior alveolar nerve (from [V3])
Buccal nerve (from [V3])
Mental nerve from inferior alveolar nerve (from [V3])
Incisive branch of inferior alveolar nerve (from [V3])
Lower teeth and gums

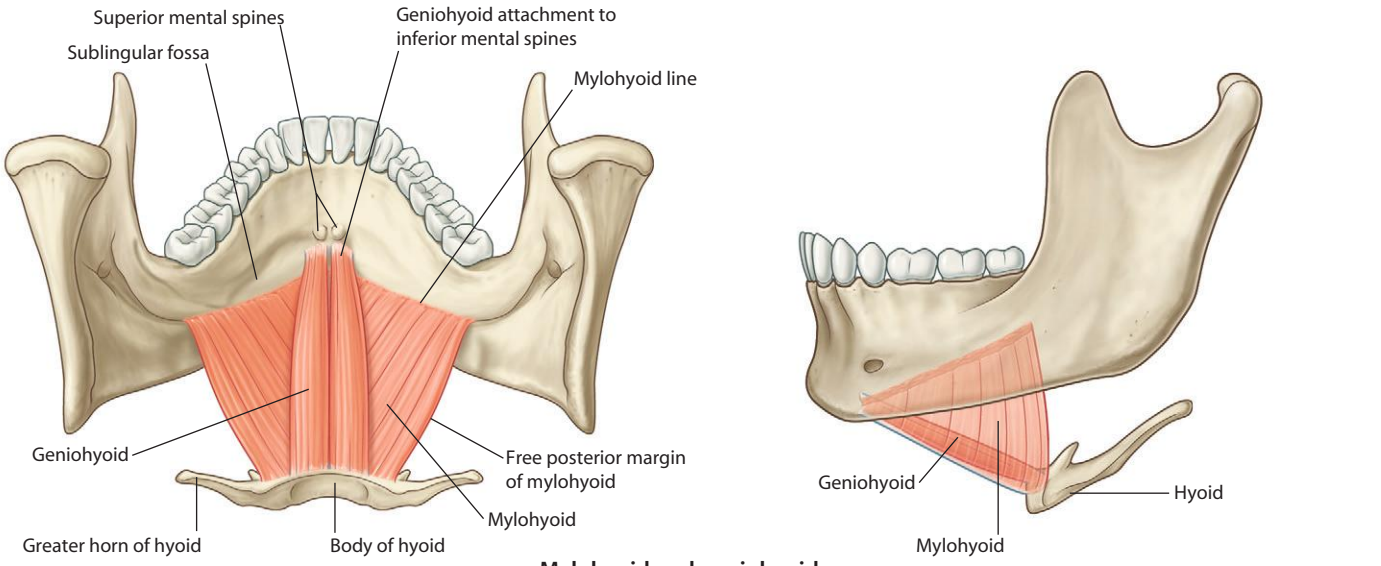

Mylohyoid and geniohyoid

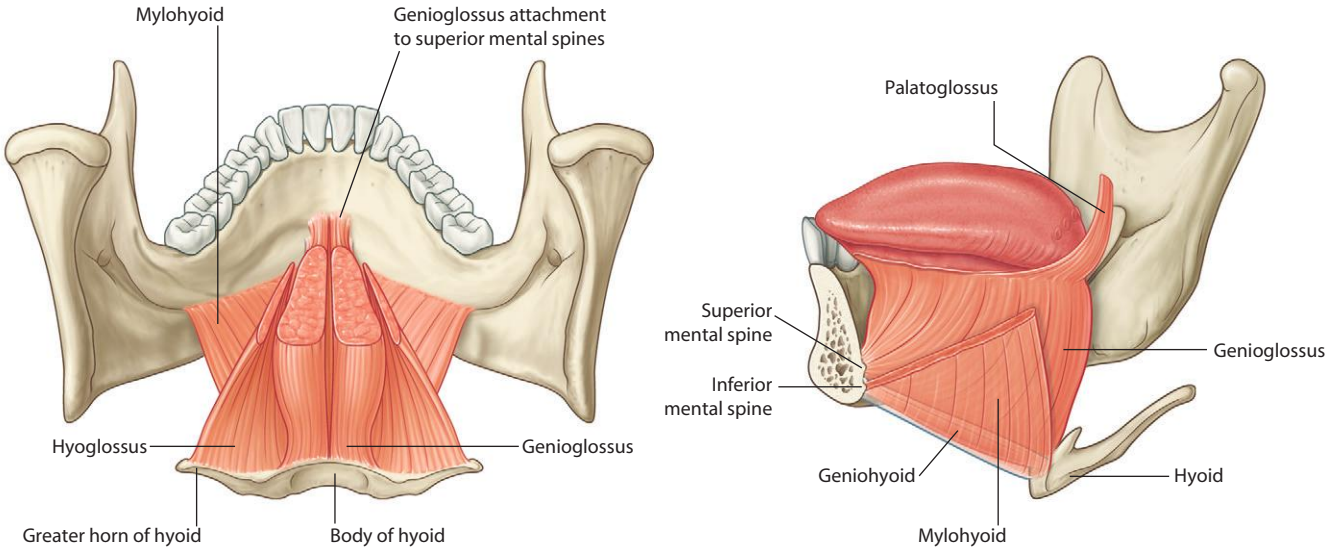

Genioglossus and hyoglossus

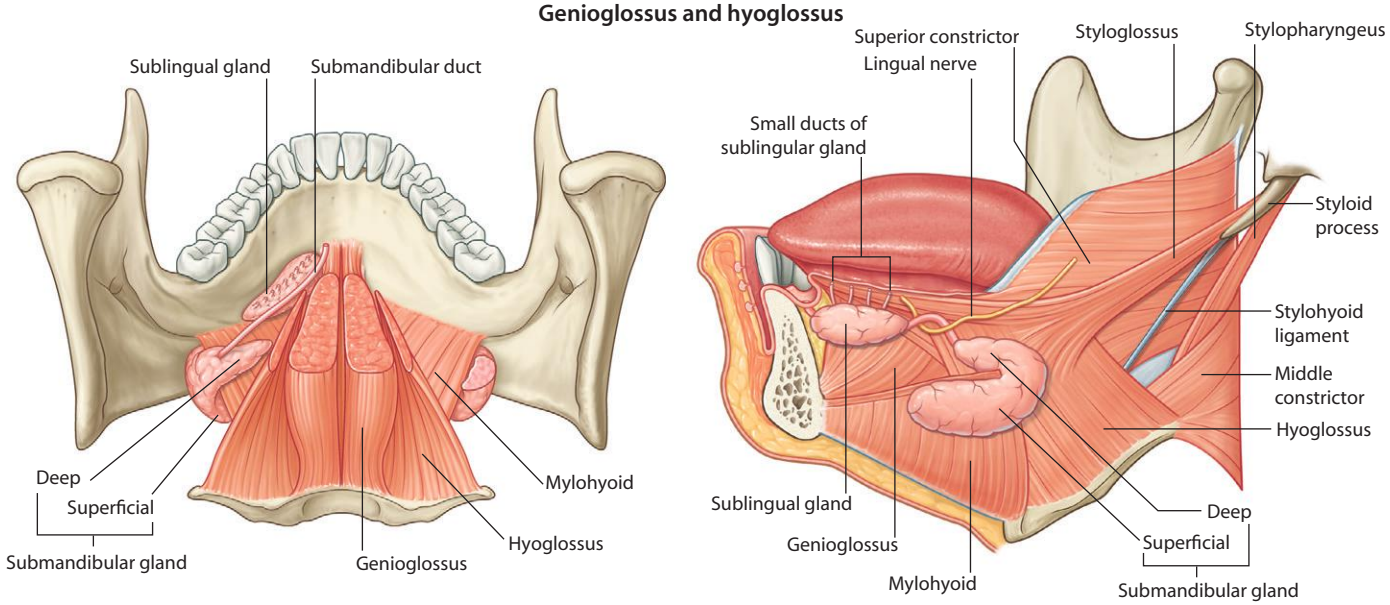

Posterior view **Submandibular and sublingual glands** **Lateral view**

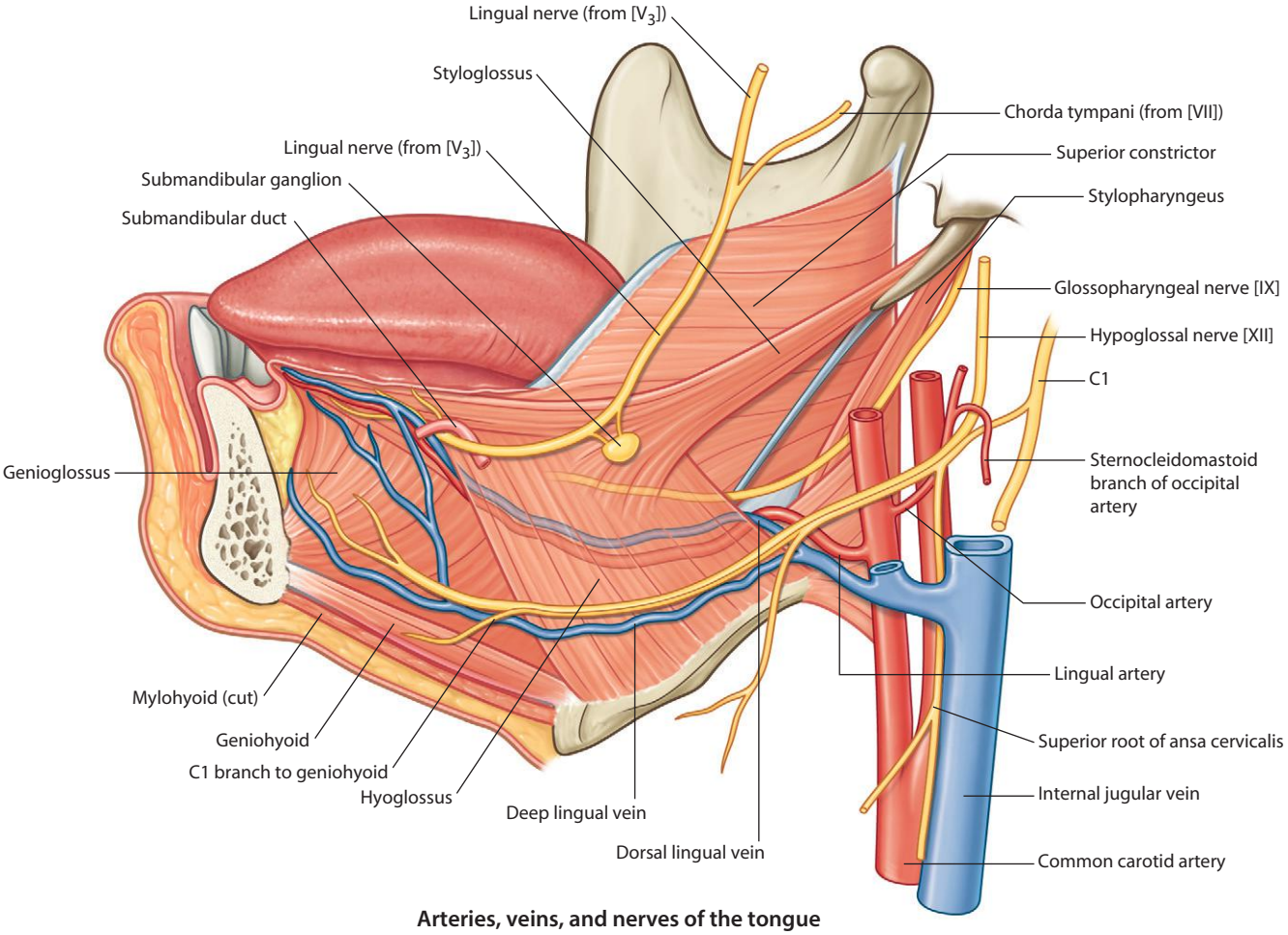

Arteries, veins, and nerves of the tongue

Sensory

Anterior two-thirds (oral)
- general sensation
  Mandibular nerve [V_3] via lingual nerve
- special sensation (taste)
  Facial nerve [VII] via chorda tympani

Posterior one-third (pharyngeal)
- general and special sensation (taste)
  Glossopharyngeal nerve [IX]

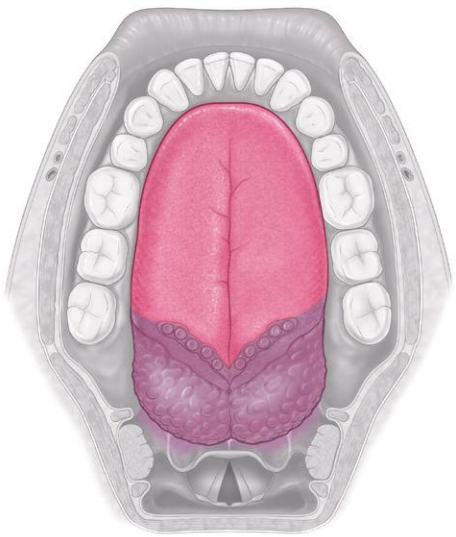

Motor

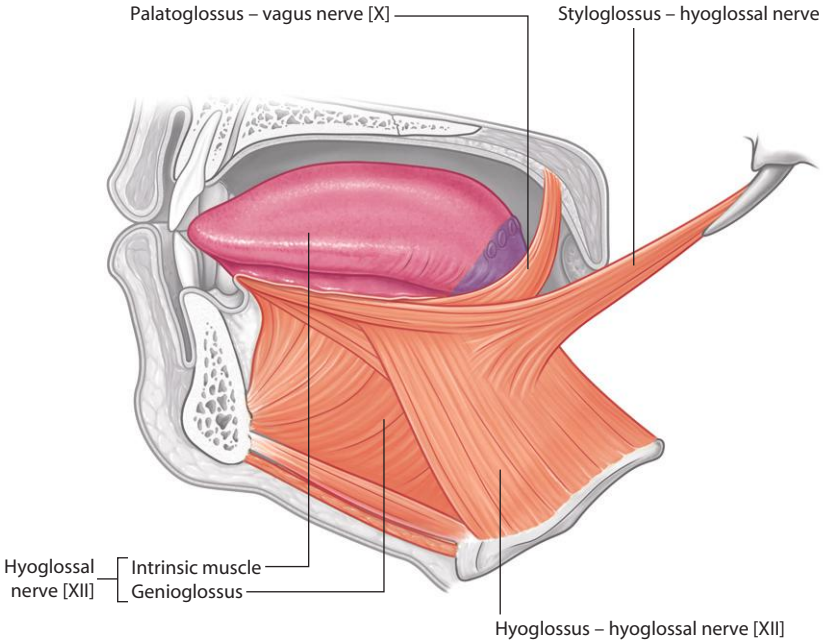

Innervation of the tongue

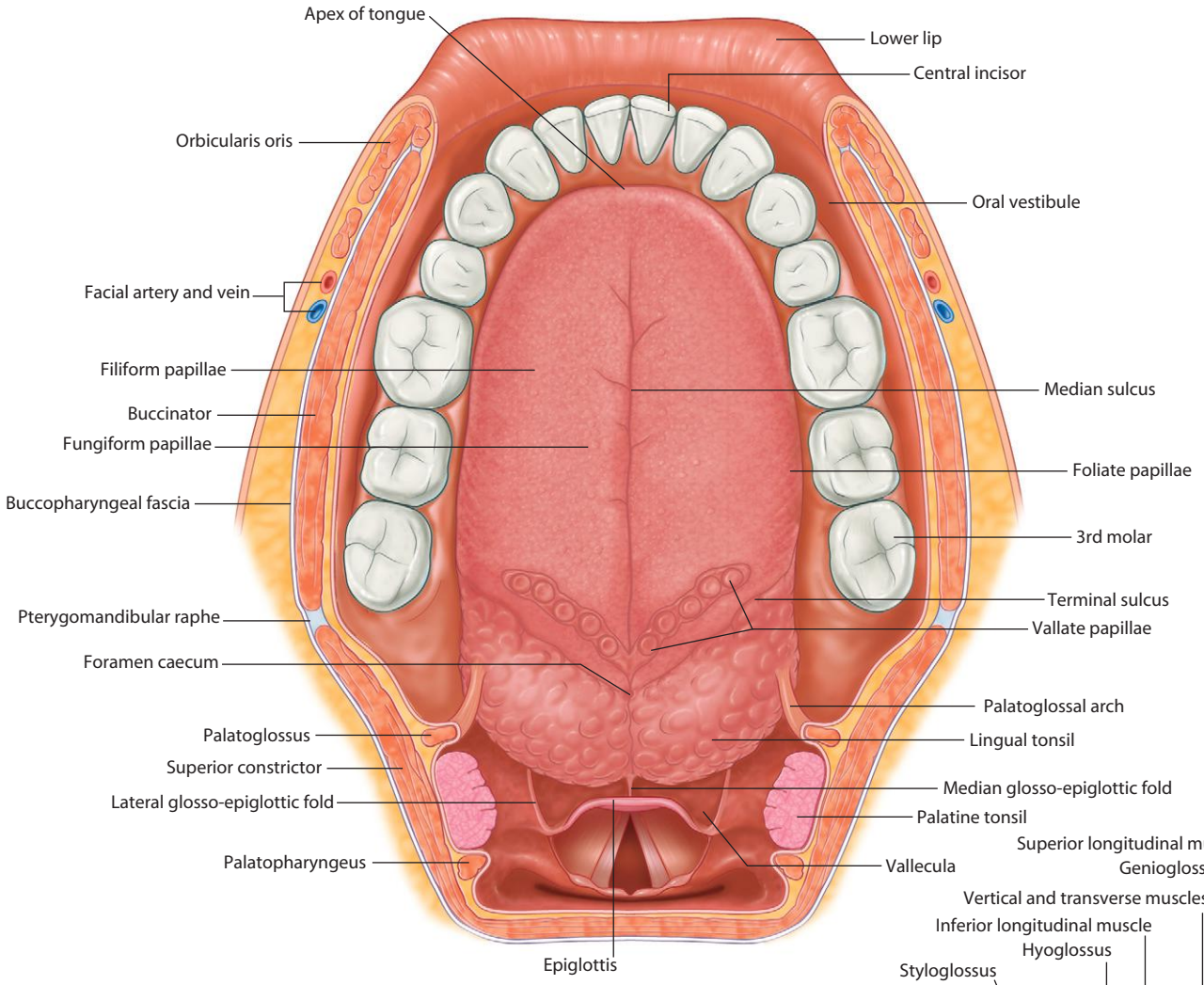

Horizontal section showing superior view of tongue

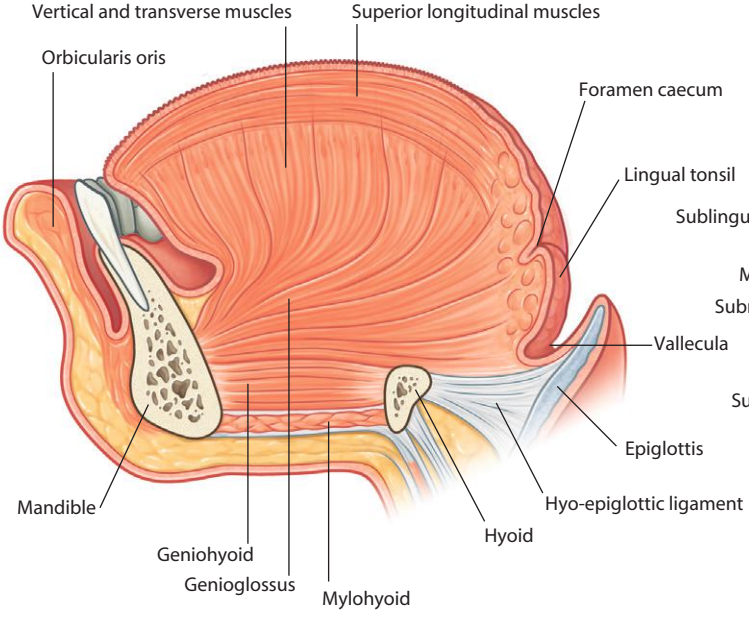

Paramedian sagittal section through tongue

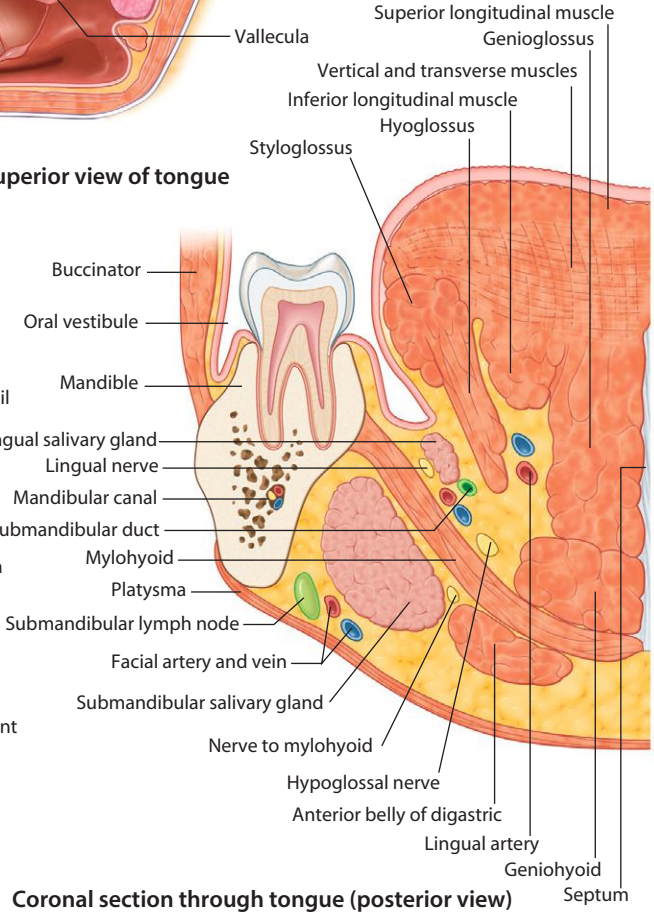

Coronal section through tongue (posterior view)

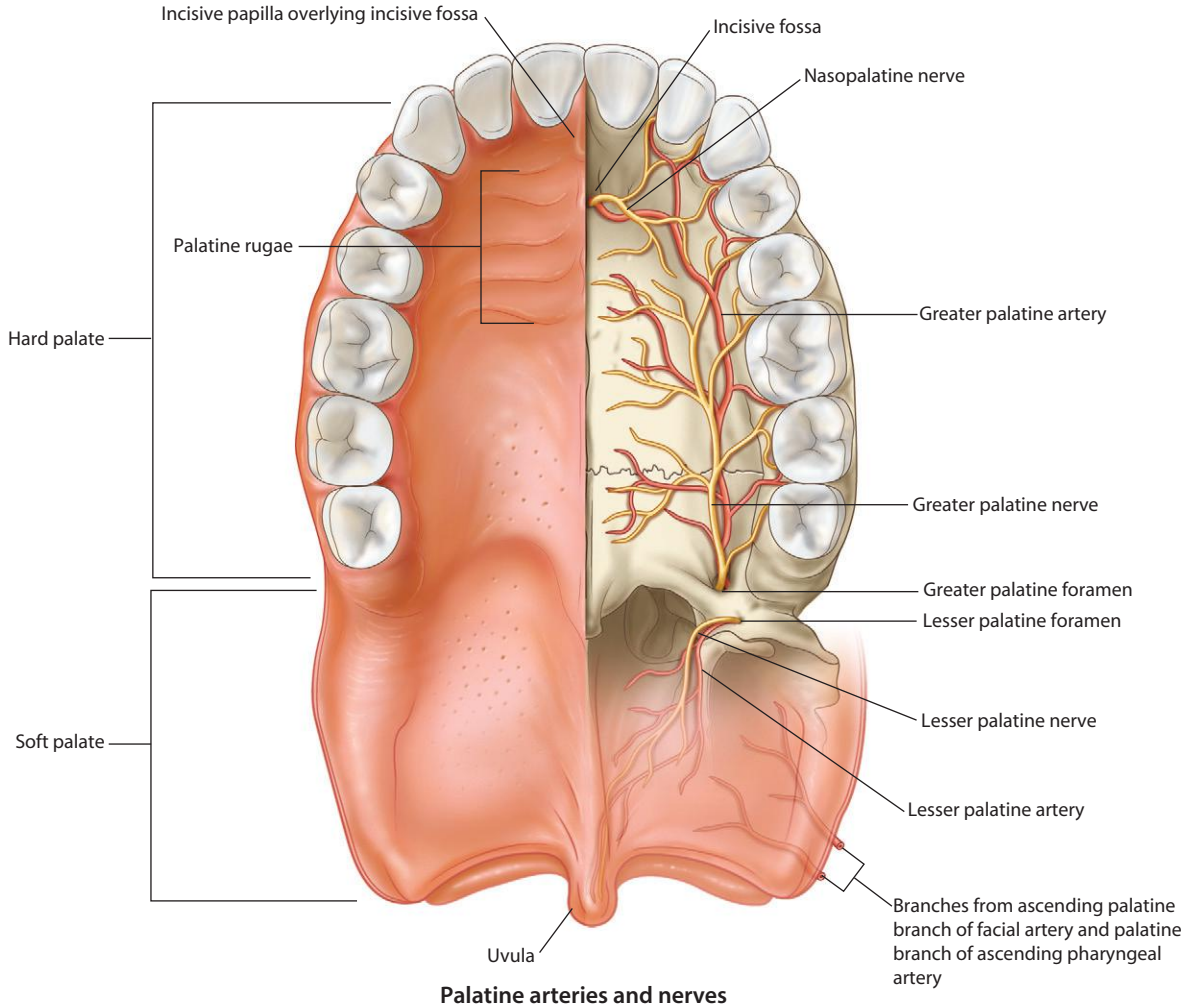

Palatine arteries and nerves

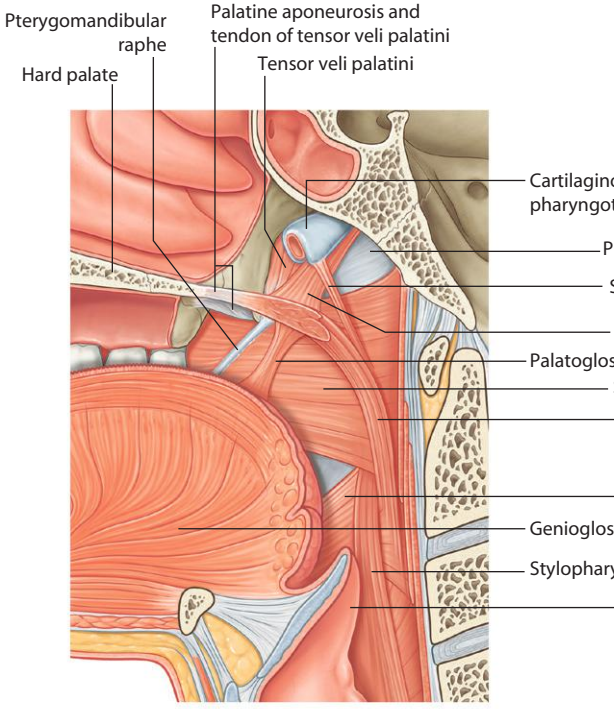

Muscles of the soft palate (sagittal section)

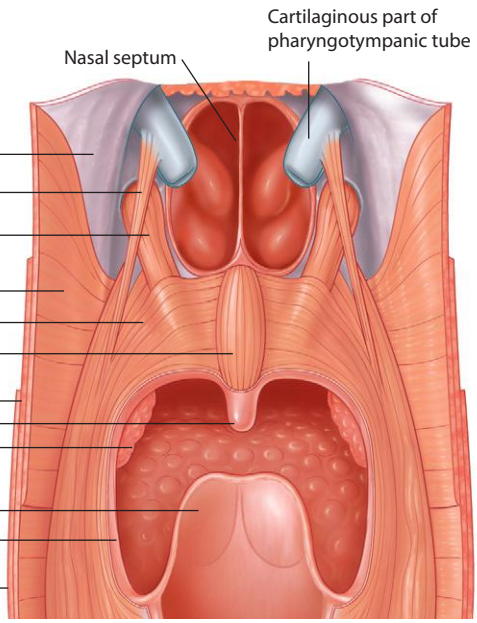

Muscles of the soft palate (posterior view)

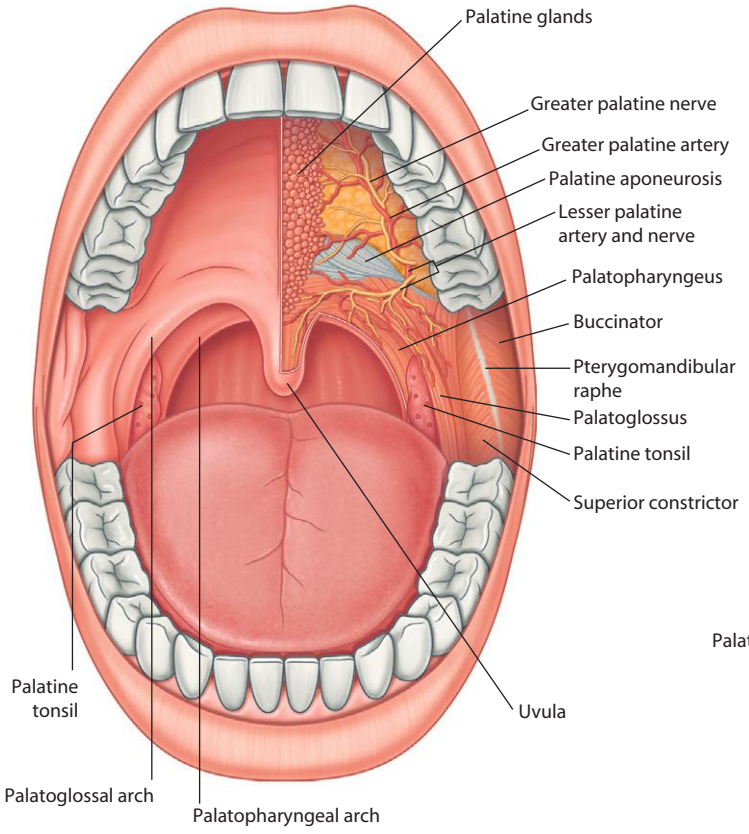

Roof of oral cavity

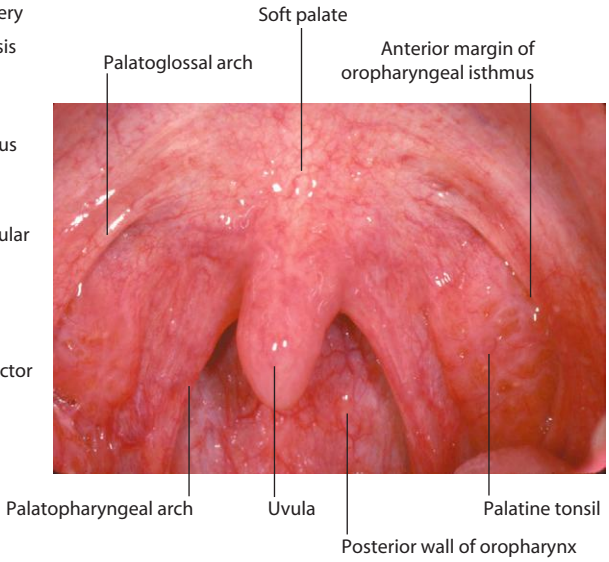

Open mouth showing soft palate

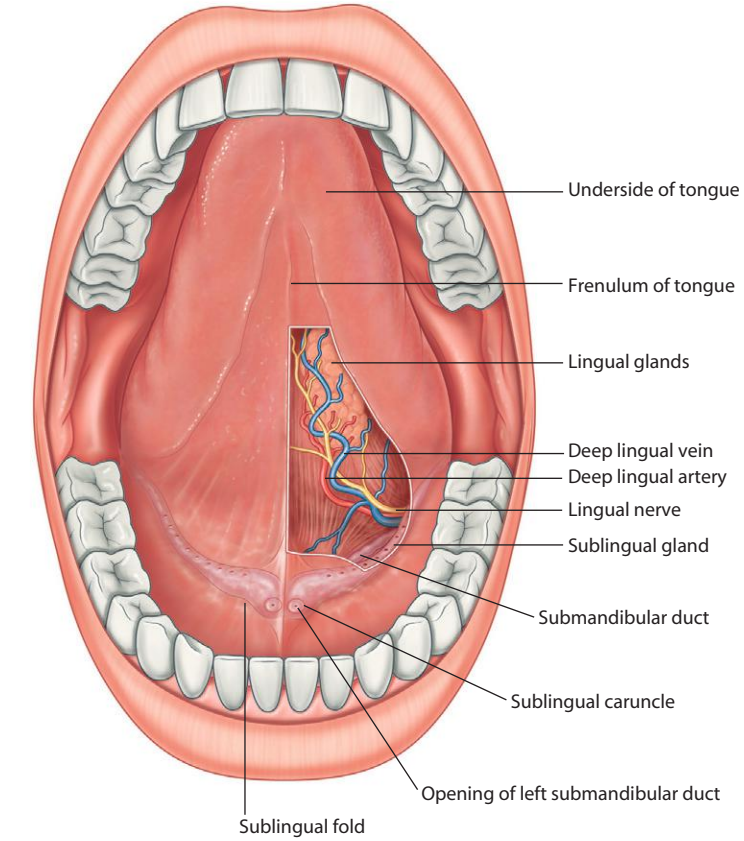

Inferior surface of tongue and floor of oral cavity

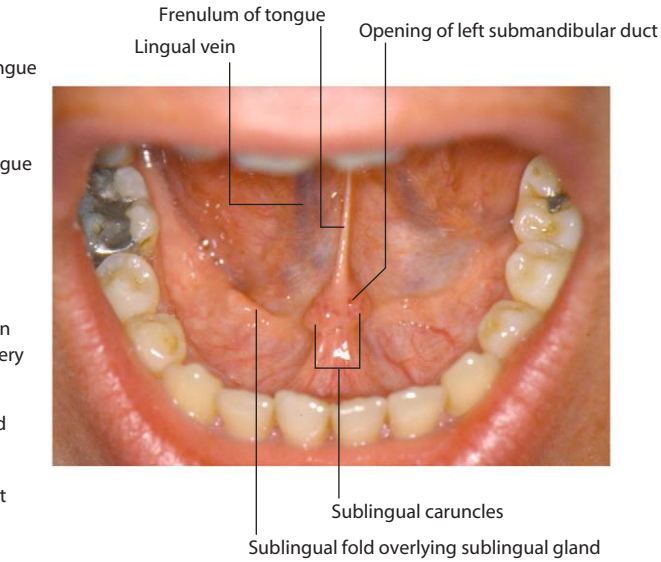

Sublingual glands (anterosuperior view)

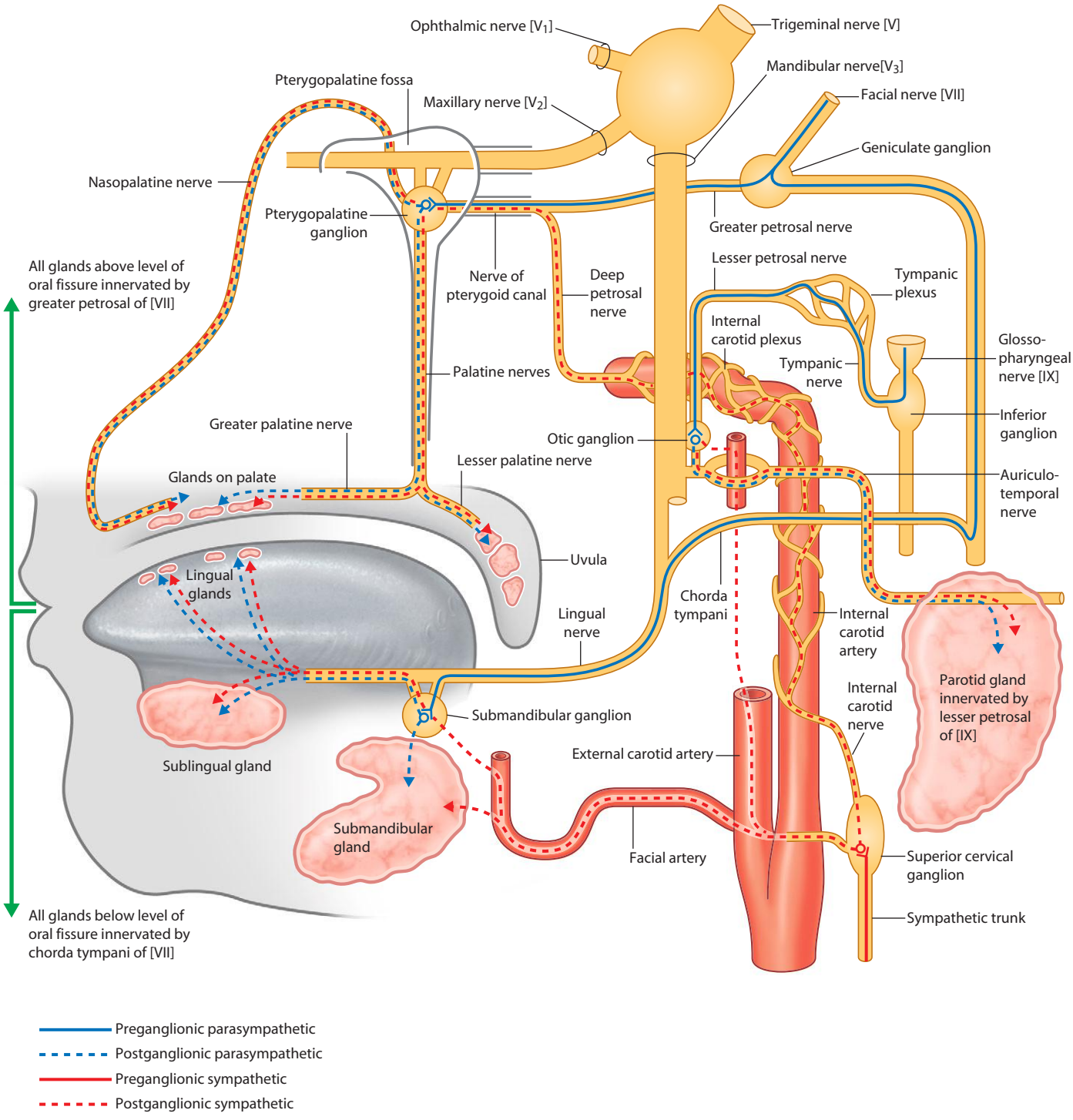

Visceral efferent (motor) innervation of glands related to the oral cavity

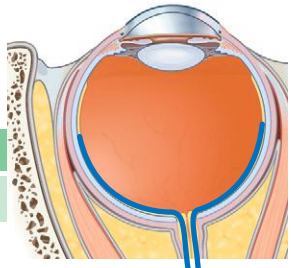

Optic nerve [II]

Special sensory – vision

Olfactory nerve [I]

Special sensory – smell

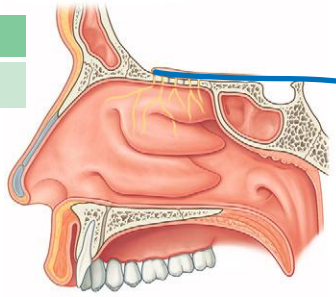

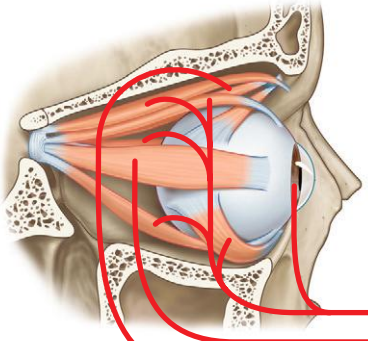

Oculomotor nerve [III]

Somatic motor – five extra-ocular muscles (superior rectus, medial rectus, inferior oblique, inferior rectus, and levator palpebrae superioris)
Visceral motor – ciliary muscles and sphincter pupillae muscles

Trochlear nerve [IV]

Somatic motor – one extra-ocular muscle (superior oblique)

Abducent nerve [VI]

Somatic motor – one extra-ocular muscle (lateral rectus)

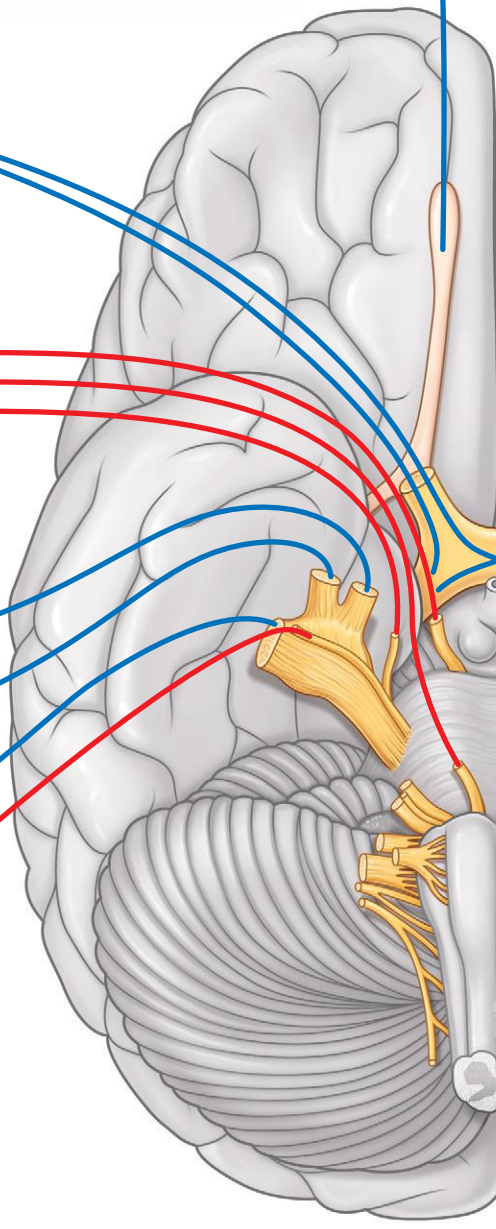

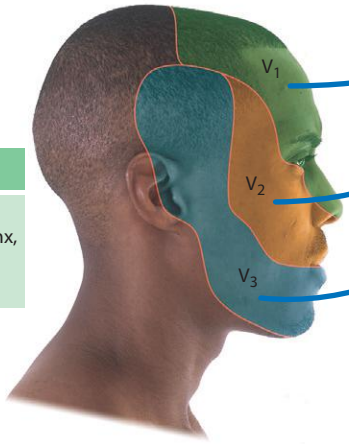

Trigeminal nerve [V] sensory root

Somatic sensory – eyes, orbital contents, face, sinuses, teeth, nasal cavities, oral cavity, nasopharynx, dura, anterior part of external ear, and part of external acoustic meatus

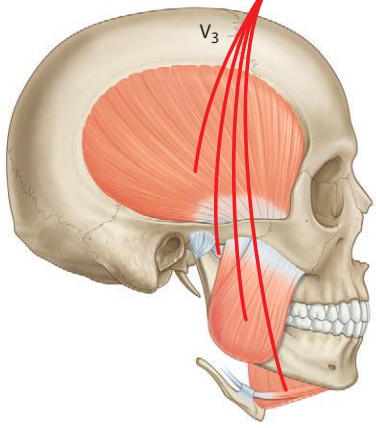

Trigeminal nerve [V] motor root

Branchial motor – the four muscles of mastication (medial pterygoid, lateral pterygoid, masseter, temporalis) and mylohyoid, anterior belly of digastric, tensor tympani, and tensor veli palatini

Efferent (motor) fibers

Afferent (sensory) fibers

Overview of cranial nerves

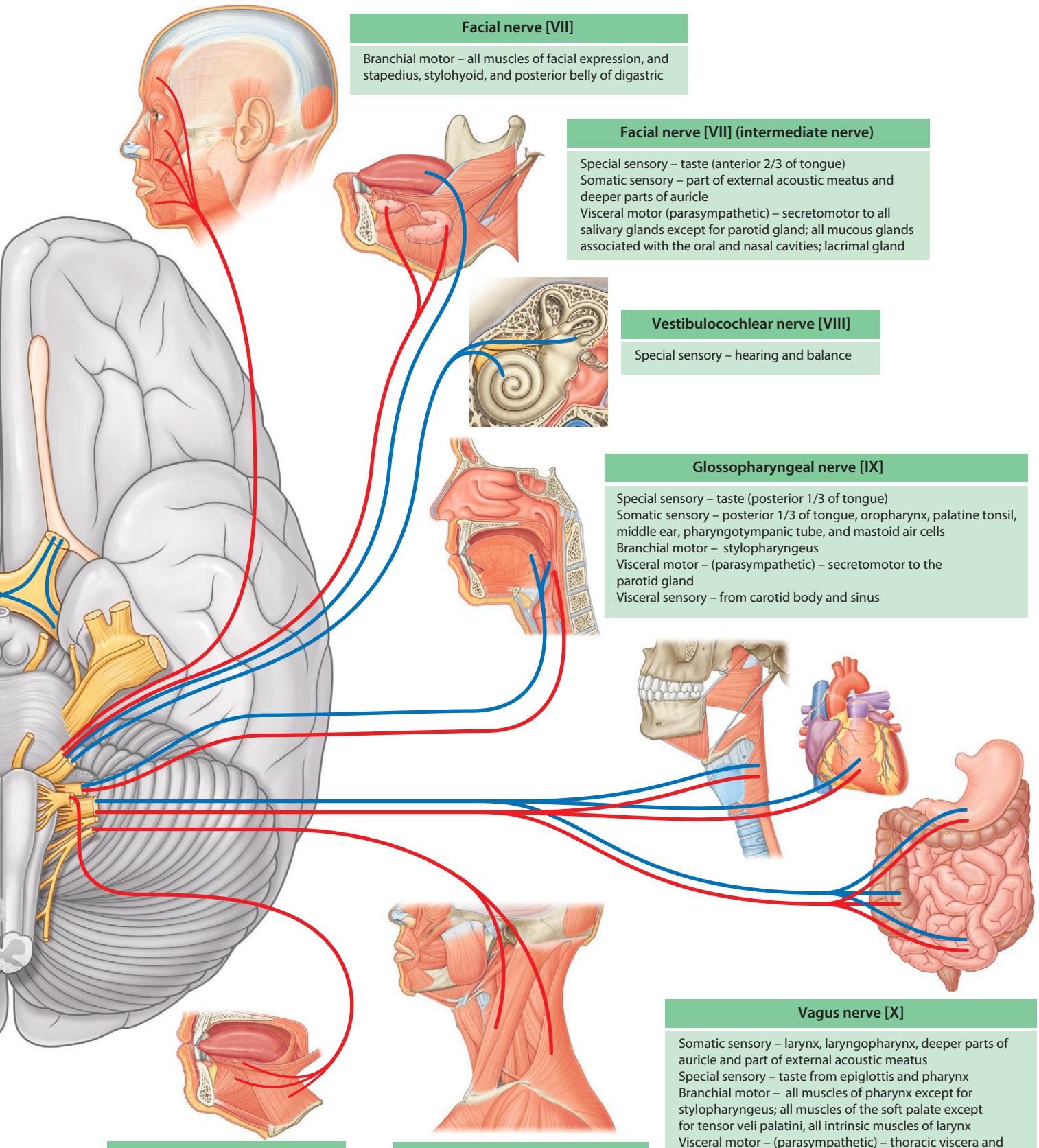

Facial nerve [VII]

Branchial motor – all muscles of facial expression, and stapedius, stylohyoid, and posterior belly of digastric

Facial nerve [VII] (intermediate nerve)

Special sensory – taste (anterior 2/3 of tongue)
Somatic sensory – part of external acoustic meatus and deeper parts of auricle
Visceral motor (parasympathetic) – secretomotor to all salivary glands except for parotid gland; all mucous glands associated with the oral and nasal cavities; lacrimal gland

Vestibulocochlear nerve [VIII]

Special sensory – hearing and balance

Glossopharyngeal nerve [IX]

Special sensory – taste (posterior 1/3 of tongue)
Somatic sensory – posterior 1/3 of tongue, oropharynx, palatine tonsil, middle ear, pharyngotympanic tube, and mastoid air cells
Branchial motor – stylopharyngeus
Visceral motor – (parasympathetic) – secretomotor to the parotid gland
Visceral sensory – from carotid body and sinus

Vagus nerve [X]

Somatic sensory – larynx, laryngopharynx, deeper parts of auricle and part of external acoustic meatus
Special sensory – taste from epiglottis and pharynx
Branchial motor – all muscles of pharynx except for stylopharyngeus; all muscles of the soft palate except for tensor veli palatini, all intrinsic muscles of larynx
Visceral motor – (parasympathetic) – thoracic viscera and abdominal viscera to end of midgut
Visceral sensory – thoracic viscera and abdominal viscera to end of midgut, chemo- and baroreceptors (and in some cases carotid body)

Accessory nerve [XI]

Somatic motor – sternocleidomastoid and trapezius

Hypoglossal nerve [XII]

Somatic motor – all muscles of the tongue except palatoglossus

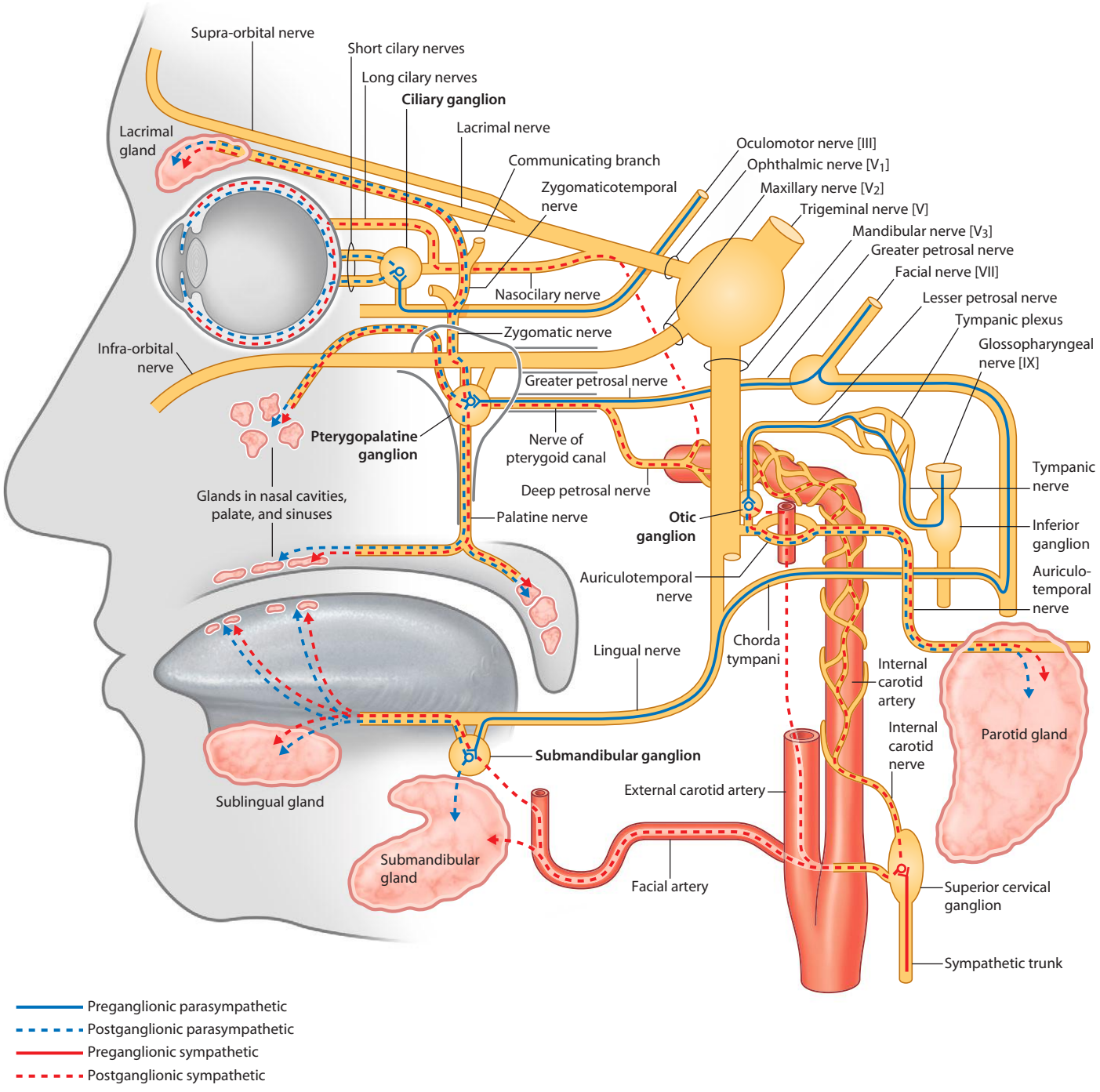

Summary of visceral efferent (motor) pathways in the head

External foramina of the skull

Foramen		Structures passing through foramen
Anterior view		
Supra-orbital foramen	1	Supra-orbital nerve and vessels
Infra-orbital foramen	2	Infra-orbital nerve and vessels
Mental foramen	3	Mental nerve and vessels
Lateral view		
Zygomaticofacial foramen	4	Zygomaticofacial nerve
Superior view		
Parietal foramen	5	Emissary veins

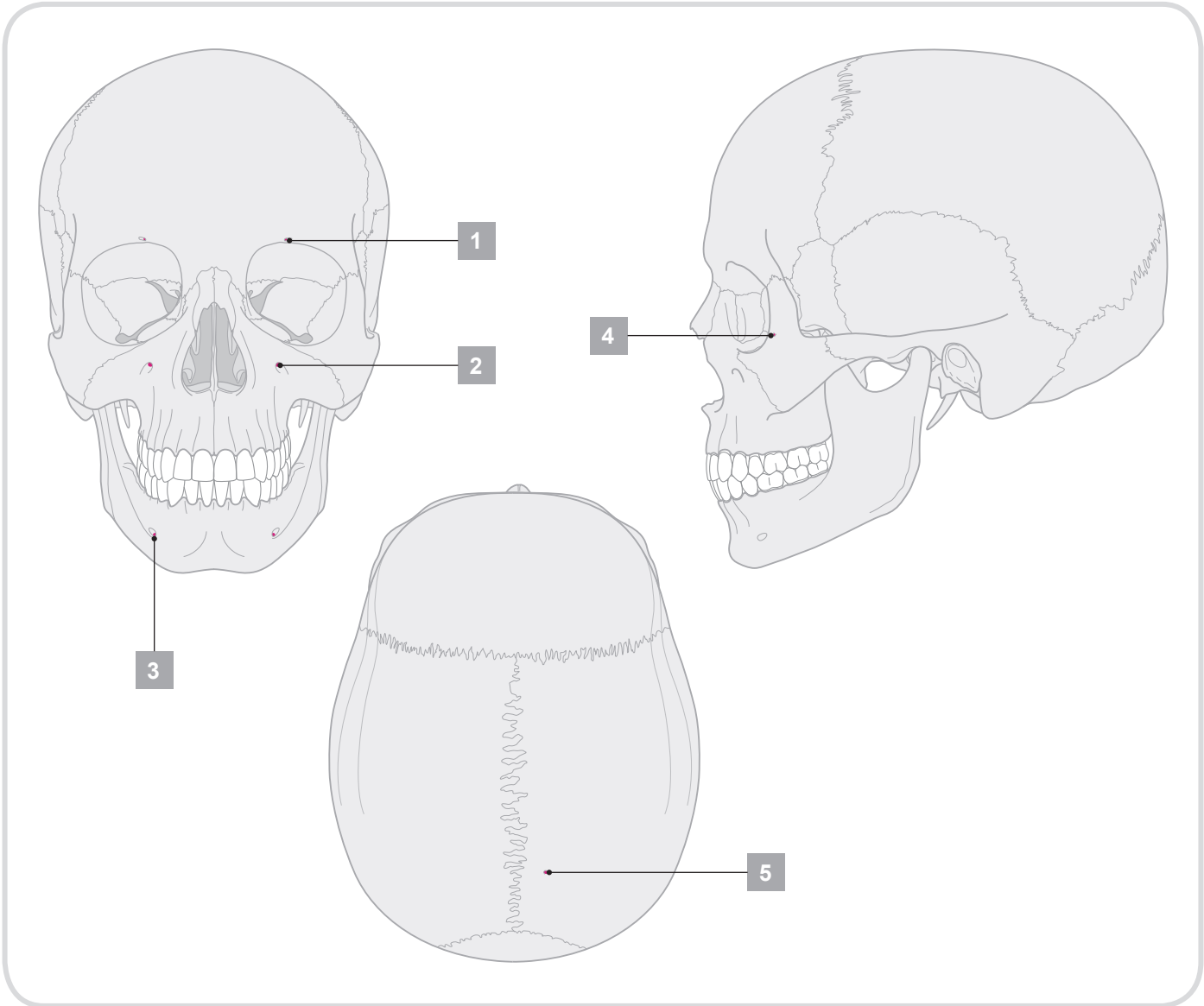

External foramina of the skull

Foramen		Structures passing through foramen
Inferior view		
Incisive foramina	1	Nasopalatine nerve; sphenopalatine vessels
Greater palatine foramen	2	Greater palatine nerve and vessels
Lesser palatine foramina	3	Lesser palatine nerves and vessels
Pterygoid canal	4	Pterygoid nerve and vessels
Foramen ovale	5	Mandibular nerve [V_3]; lesser petrosal nerve
Foramen spinosum	6	Middle meningeal artery
Foramen lacerum	7	Filled with cartilage
Carotid canal	8	Internal carotid artery and nerve plexus
Foramen magnum	9	Continuation of brain and spinal cord; vertebral arteries and nerve plexuses; anterior spinal artery; posterior spinal arteries; roots of accessory nerve [XI]; meninges
Condylar canal	10	Emissary veins
Hypoglossal canal	11	Hypoglossal nerve [XII] and vessels
Jugular foramen	12	Internal jugular vein; inferior petrosal sinus; glossopharyngeal nerve [IX]; vagus nerve [X]; accessory nerve [XI]
Stylomastoid foramen	13	Facial nerve [VII]

Internal foramina of the skull

Anterior cranial fossa		
Foramen caecum	1	Emissary veins to nasal cavity
Olfactory foramina in cribriform plate	2	Olfactory nerves [I]
Middle cranial fossa		
Optic canal	3	Optic nerve [II]; ophthalmic artery
Superior orbital fissure	4	Oculomotor nerve [III]; trochlear nerve [IV]; ophthalmic division of the trigeminal nerve [V_1]; abducent nerve [VI]; ophthalmic veins
Foramen rotundum	5	Maxillary division of the trigeminal nerve [V_2]
Foramen ovale	6	Mandibular division of the trigeminal nerve [V_3]; lesser petrosal nerve
Foramen spinosum	7	Middle meningeal artery
Hiatus for the greater petrosal nerve	8	Greater petrosal nerve
Hiatus for the lesser petrosal nerve	9	Lesser petrosal nerve
Posterior cranial fossa		
Foramen magnum	10	End of brainstem/beginning of spinal cord; vertebral arteries; spinal roots of the accessory nerve; meninges
Internal acoustic meatus	11	Facial nerve [VII]; vestibulocochlear nerve [VIII]; labyrinthine artery
Jugular foramen	12	Glossopharyngeal nerve [IX]; vagus nerve [X]; accessory nerve [XI]; inferior petrosal sinus, sigmoid sinus (forming internal jugular vein)
Hypoglossal canal	13	Hypoglossal nerve [XII]; meningeal branch of the ascending pharyngeal artery
Condylar canal	14	Emissary vein

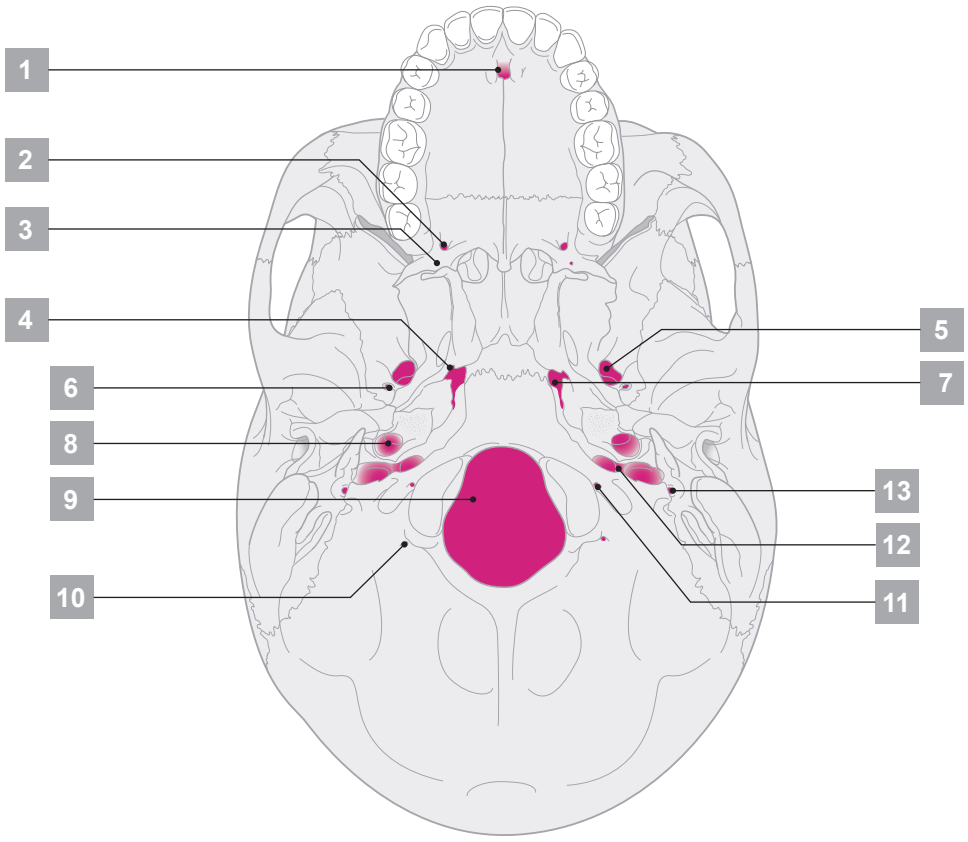
1
2
3
4
5
6
7
8
9
10
11
12
13

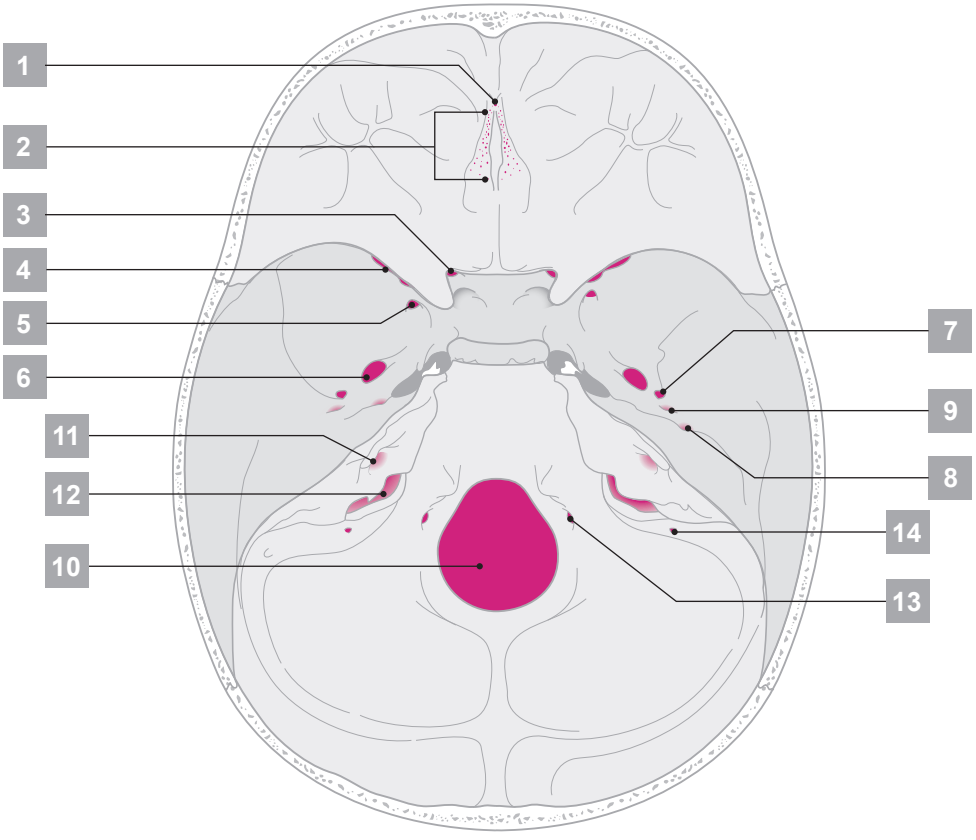
1
2
3
4
5
6
7
8
9
10
11
12
13
14

Muscles of the face

Muscle		Origin	Insertion	Innervation	Function
Orbital group					
Orbicularis oculi —Palpebral part	1	Medial palpebral ligament	Lateral palpebral raphe	Facial nerve [VII]	Closes the eyelids gently
—Orbital part	2	Nasal part of frontal bone; frontal process of maxilla; medial palpebral ligament	Fibers form an uninterrupted ellipse around orbit	Facial nerve [VII]	Closes the eyelids forcefully
Corrugator supercilii	3	Medial end of the superciliary arch	Skin of the medial half of eyebrow	Facial nerve [VII]	Draws the eyebrows medially and downward
Nasal group					
Nasalis —Transverse part	4	Maxilla just lateral to nose	Aponeurosis across dorsum of nose with muscle fibers from the other side	Facial nerve [VII]	Compresses nasal aperture
—Alar part	5	Maxilla over lateral incisor	Alar cartilage of nose	Facial nerve [VII]	Draws cartilage downward and laterally opening nostril
Procerus	6	Nasal bone and upper part of lateral nasal cartilage	Skin of lower forehead between eyebrows	Facial nerve [VII]	Draws down medial angle of eyebrows producing transverse wrinkles over bridge of nose
Depressor septi	7	Maxilla above medial incisor	Mobile part of the nasal septum	Facial nerve [VII]	Pulls nose inferiorly

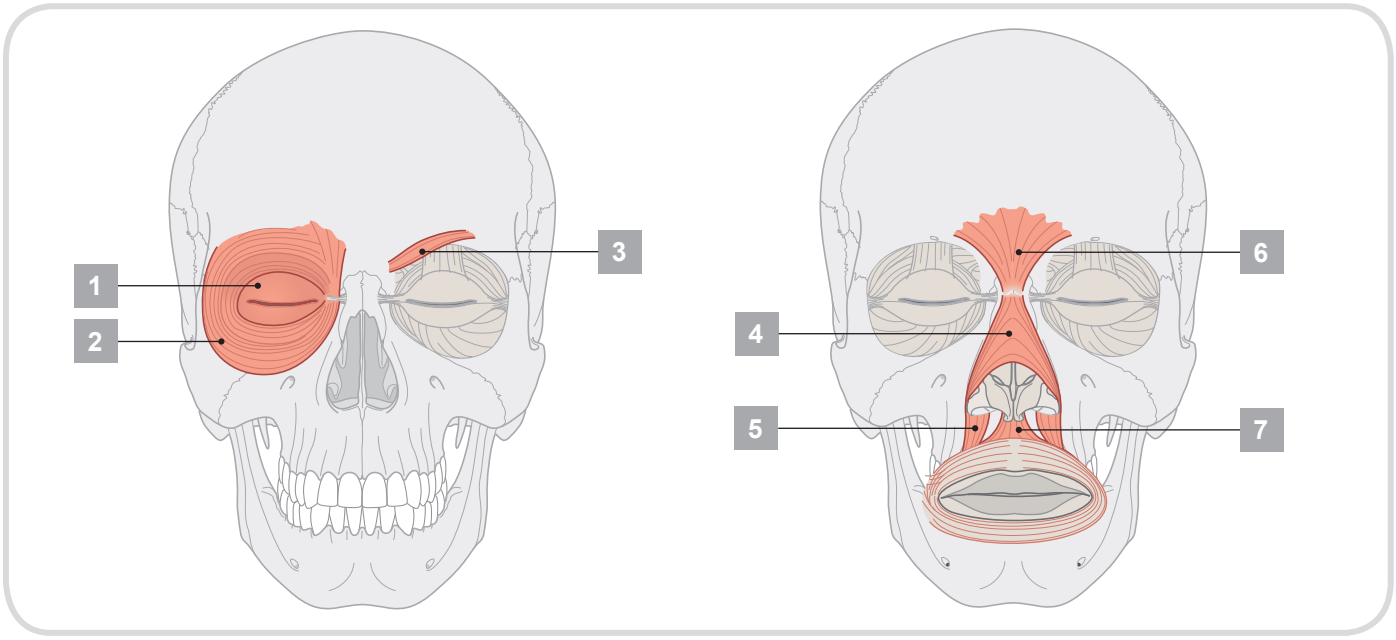

Muscles of the face

Muscle		Origin	Insertion	Innervation	Function
Oral group					
Depressor anguli oris	1	Oblique line of mandible below canine, premolar, and first molar teeth	Skin at the corner of mouth and blending with orbicularis oris	Facial nerve [VII]	Draws corner of mouth down and laterally
Depressor labii inferioris	2	Anterior part of oblique line of mandible	Lower lip at midline; blends with muscle from opposite side	Facial nerve [VII]	Draws lower lip downward and laterally
Mentalis	3	Mandible inferior to incisor teeth	Skin of chin	Facial nerve [VII]	Raises and protrudes lower lip as it wrinkles skin on chin
Risorius	4	Fascia over masseter muscle	Skin at the corner of the mouth	Facial nerve [VII]	Retracts corner of mouth
Zygomaticus major	5	Posterior part of lateral surface of zygomatic bone	Skin at the corner of the mouth	Facial nerve [VII]	Draws the corner of the mouth upward and laterally
Zygomaticus minor	6	Anterior part of lateral surface of zygomatic bone	Upper lip just medial to corner of mouth	Facial nerve [VII]	Draws the upper lip upward
Levator labii superioris	7	Infra-orbital margin of maxilla	Skin of upper lateral half of upper lip	Facial nerve [VII]	Raises upper lip; helps form nasolabial furrow
Levator labii superioris alaeque nasi	8	Frontal process of maxilla	Alar cartilage of nose and upper lip	Facial nerve [VII]	Raises upper lip and opens nostril
Levator anguli oris	9	Maxilla below infra-orbital foramen	Skin at the corner of mouth	Facial nerve [VII]	Raises corner of mouth; helps form nasolabial furrow
Orbicularis oris	10	From muscles in area; maxilla and mandible in midline	Forms ellipse around mouth	Facial nerve [VII]	Closes lips; protrudes lips
Buccinator	11	Posterior parts of maxilla and mandible; pterygomandibular raphe	Blends with orbicularis oris and into lips	Facial nerve [VII]	Presses the cheek against teeth; compresses distended cheeks

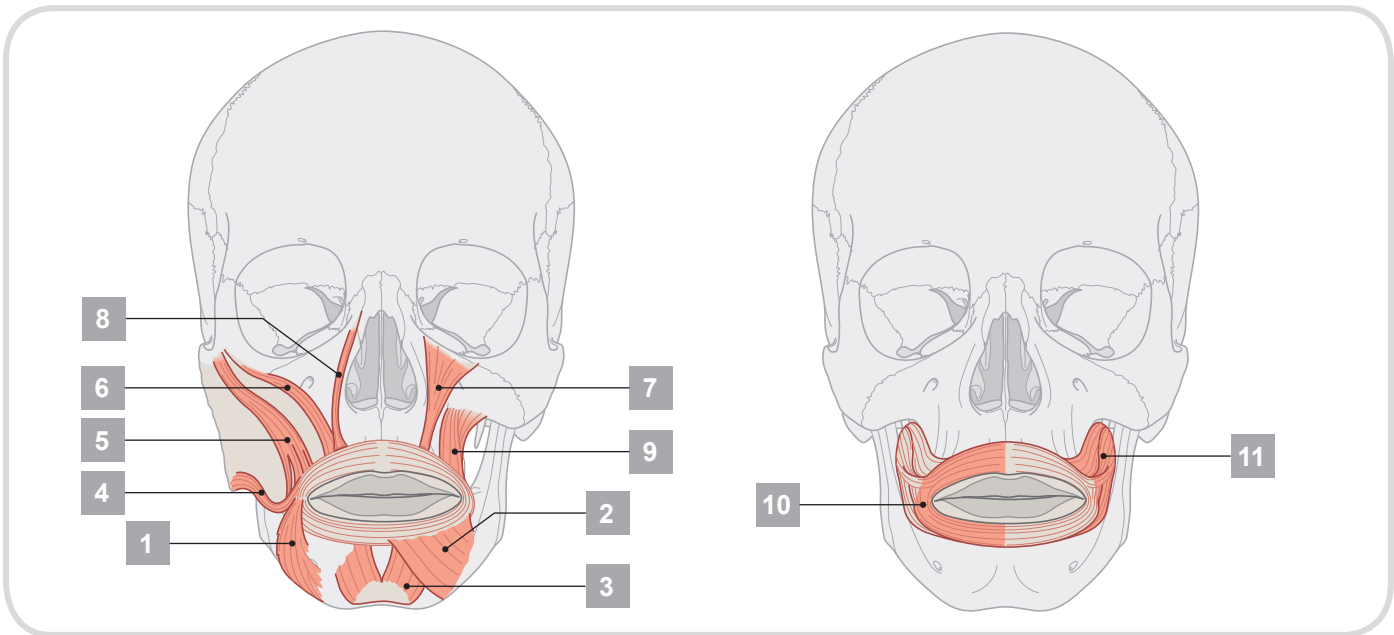

Muscles of the face

Muscle		Origin	Insertion	Innervation	Function
Other muscles or groups					
Anterior auricular	1	Anterior part of temporal fascia	Into helix of ear	Facial nerve [VII]	Draws ear upward and forward
Superior auricular	2	Epicranial aponeurosis on side of head	Upper part of auricle	Facial nerve [VII]	Elevates ear
Posterior auricular	3	Mastoid process of temporal bone	Convexity of concha of ear	Facial nerve [VII]	Draws ear upward and backward
Occipitofrontalis —Frontal belly	4	Skin of eyebrows	Into galea aponeurotica	Facial nerve [VII]	Wrinkles forehead; raises eyebrows
—Occipital belly	5	Lateral part of superior nuchal line of occipital bone and mastoid process of temporal bone	Into galea aponeurotica	Facial nerve [VII]	Draws scalp backward

Extrinsic (extra-ocular) muscles

Muscle		Origin	Insertion	Innervation	Function
Levator palpebrae superioris	1	Lesser wing of sphenoid anterior to optic canal	Anterior surface of tarsal plate; a few fibers to skin and superior conjunctival fornix	Oculomotor nerve [III]—superior branch	Elevation of upper eyelid
Superior rectus	2	Superior part of common tendinous ring	Anterior half of eyeball superiorly	Oculomotor nerve [III]—superior branch	Elevation, adduction, medial rotation of eyeball
Inferior rectus	3	Inferior part of common tendinous ring	Anterior half of eyeball inferiorly	Oculomotor nerve [III]—inferior branch	Depression, adduction, lateral rotation of eyeball
Medial rectus	4	Medial part of common tendinous ring	Anterior half of eyeball medially	Oculomotor nerve [III]—inferior branch	Adduction of eyeball
Lateral rectus	5	Lateral part of common tendinous ring	Anterior half of eyeball laterally	Abducent nerve [VI]	Abduction of eyeball
Superior oblique	6	Body of sphenoid, superior and medial to optic canal	Outer posterior quadrant of eyeball (superior surface)	Trochlear nerve [IV]	Depression, abduction, medial rotation of eyeball
Inferior oblique	7	Medial floor of orbit posterior to rim; maxilla lateral to nasolacrimal groove	Outer posterior quadrant of eyeball (inferior surface)	Oculomotor nerve [III]—inferior branch	Elevation, abduction, lateral rotation of eyeball

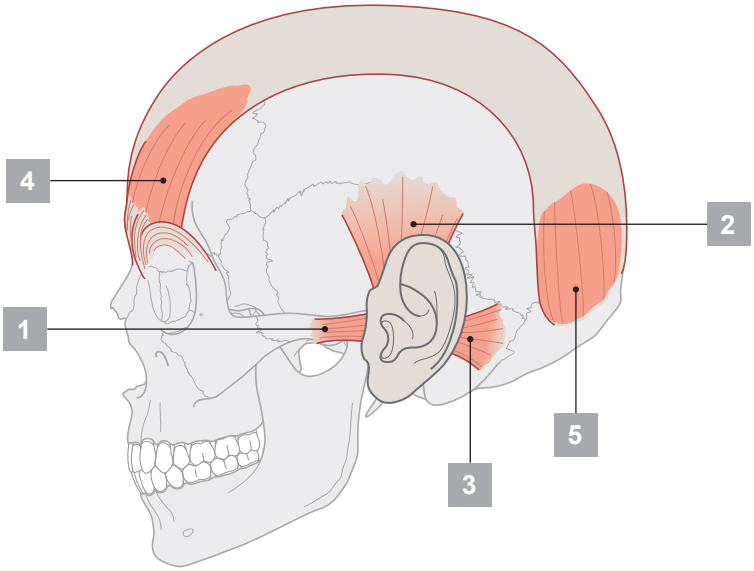
4
2
1
5
3

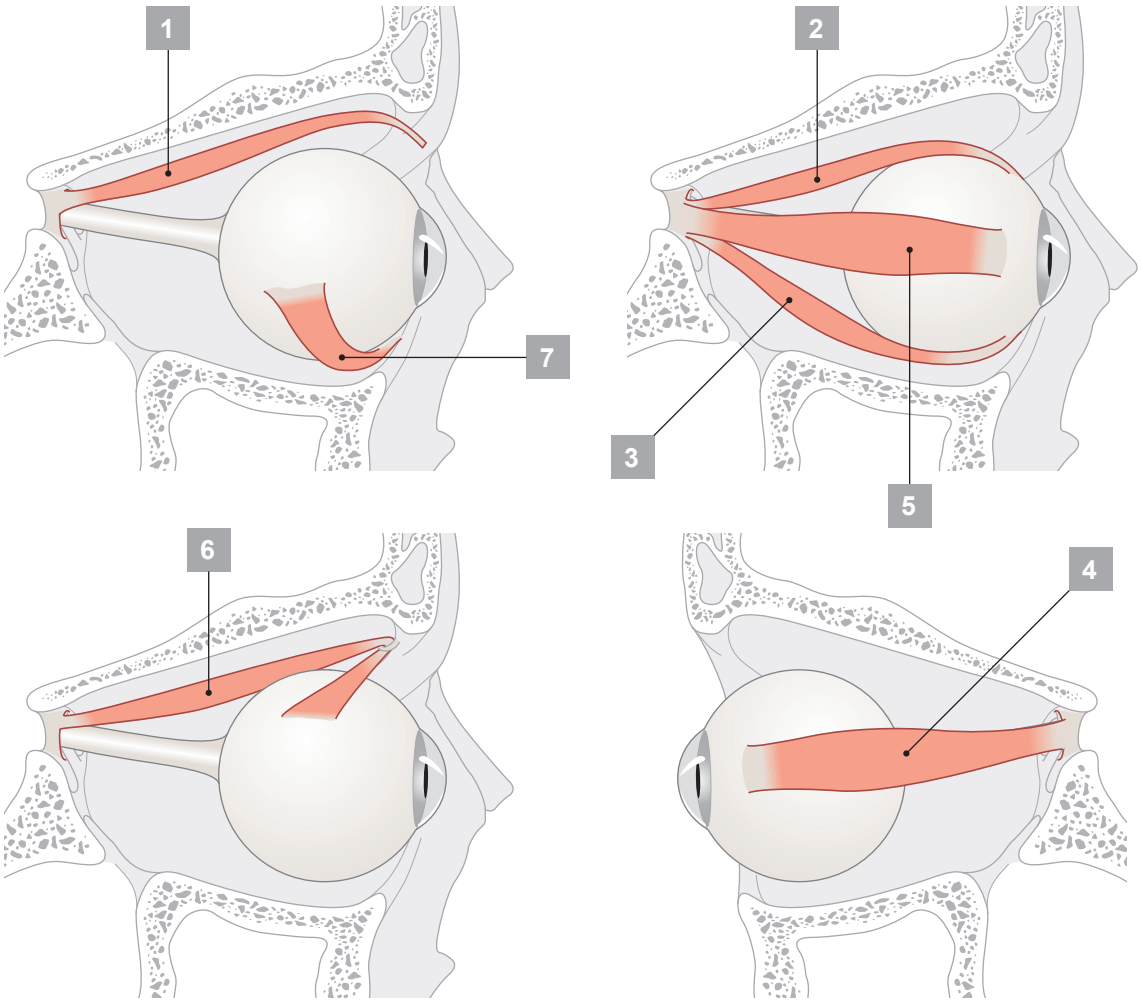
1
7
2
3
5
6
4

Intrinsic muscles of the eye

Muscle		Location	Innervation	Function
Ciliary	1	Muscle fibers in the ciliary body	Parasympathetics from the oculomotor nerve [III]	Constricts ciliary body, relaxes tension on lens, lens become more rounded
Sphincter pupillae	2	Circularly arranged fibers in the iris	Parasympathetics from the oculomotor nerve [III]	Constricts pupil
Dilator pupillae	3	Radially arranged fibers in the iris	Sympathetics from the superior cervical ganglion (T1)	Dilates pupil

Muscles of the middle ear

Muscle		Origin	Insertion	Innervation	Function
Tensor tympani	1	Cartilaginous part of pharyngotympanic tube, greater wing of sphenoid, its own bony canal	Upper part of handle of malleus	Branch from mandibular nerve [V_3]	Contraction pulls handle of malleus medially, tensing tympanic membrane
Stapedius	2	Attached to inside of pyramidal eminence	Neck of stapes	Branch of facial nerve [VII]	Contraction pulls stapes posteriorly, preventing excessive oscillation

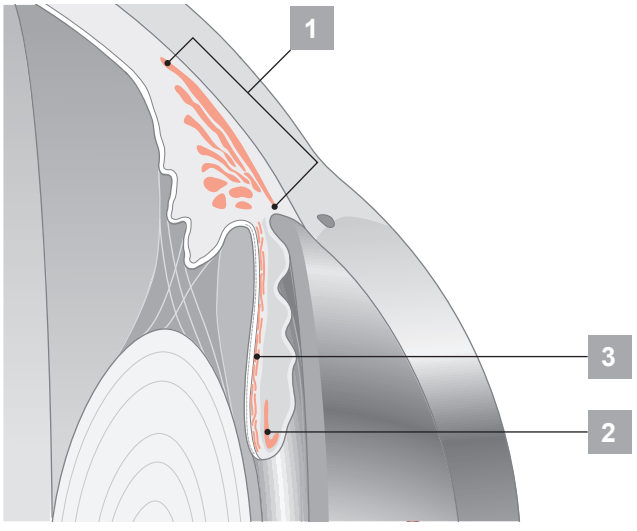

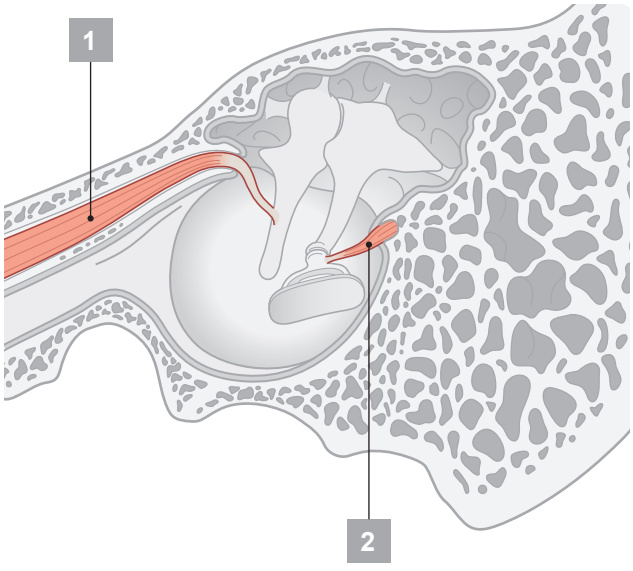

Muscles of mastication

Muscle		Origin	Insertion	Innervation	Function
Masseter	1	Zygomatic arch and maxillary process of the zygomatic bone	Lateral surface of ramus of mandible	Masseteric nerve from the anterior trunk of the mandibular nerve [V_3]	Elevation of mandible
Temporalis	2	Bone of temporal fossa and temporal fascia	Coronoid process of mandible and anterior margin of ramus of mandible almost to last molar tooth	Deep temporal nerves from the anterior trunk of the mandibular nerve [V_3]	Elevation and retraction of mandible
Medial pterygoid	3	Deep head—medial surface of lateral plate of pterygoid process and pyramidal process of palatine bone; superficial head—tuberosity of the maxilla and pyramidal process of palatine bone	Medial surface of mandible near angle	Nerve to medial pterygoid from the mandibular nerve [V_3].	Elevation and side-to-side movements of the mandible
Lateral pterygoid	4	Upper head—roof of infratemporal fossa; lower head—lateral surface of lateral plate of the pterygoid process	Capsule of temporomandibular joint in the region of attachment to the articular disc and to the pterygoid fovea on the neck of mandible	Nerve to lateral pterygoid directly from the anterior trunk of the mandibular nerve [V_3] or from the buccal branch	Protrusion and side-to-side movements of the mandible

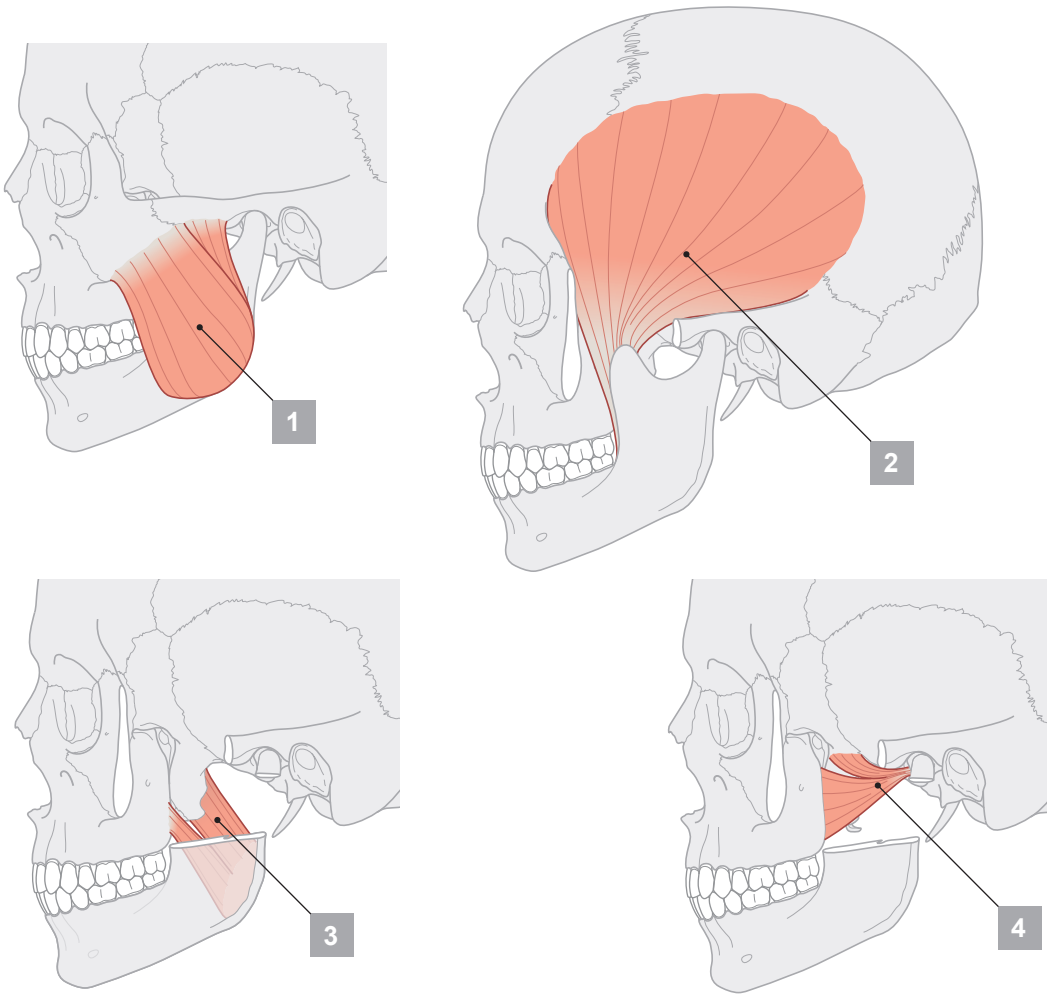

Anterior triangle of neck (suprahyoid and infrahyoid muscles)

Muscle		Origin	Insertion	Innervation	Function
Stylohyoid	1	Base of styloid process	Lateral area of body of hyoid bone	Facial nerve [VII]	Pulls hyoid bone upward in a posterosuperior direction
Digastric —Anterior belly	2	Digastric fossa on lower inside of mandible	Attachment of tendon between two bellies to body of hyoid bone	Mylohyoid nerve from inferior alveolar branch of mandibular nerve [V_3]	Opens mouth by lowering mandible; raises hyoid bone
—Posterior belly	3	Mastoid notch on medial side of mastoid process of temporal bone		Facial nerve [VII]	Pulls hyoid bone upward and back
Mylohyoid	4	Mylohyoid line on mandible	Body of hyoid bone and fibers from muscle on opposite side	Mylohyoid nerve from inferior alveolar branch of mandibular nerve [V_3]	Support and elevation of floor of mouth; elevation of hyoid
Geniohyoid	5	Inferior mental spine on inner surface of mandible	Anterior surface of body of hyoid bone	Branch from anterior ramus of C1 (carried along the hypoglossal nerve [XII])	Fixed mandible elevates and pulls hyoid bone forward; fixed hyoid bone pulls mandible downward and inward
Sternohyoid	6	Posterior aspect of sternoclavicular joint and adjacent manubrium of sternum	Body of hyoid bone medial to attachment of omohyoid muscle	Anterior rami of C1 to C3 through the ansa cervicalis	Depresses hyoid bone after swallowing
Omohyoid	7	Superior border of scapula medial to suprascapular notch	Lower border of body of hyoid bone just lateral to attachment of sternohyoid	Anterior rami of C1 to C3 through the ansa cervicalis	Depresses and fixes hyoid bone
Thyrohyoid	8	Oblique line on lamina of thyroid cartilage	Greater horn and adjacent aspect of body of hyoid bone	Fibers from anterior ramus of C1 carried along hypoglossal nerve [XII]	Depresses hyoid bone, but when hyoid bone is fixed raises larynx
Sternothyroid	9	Posterior surface of manubrium of sternum	Oblique line on lamina of thyroid cartilage	Anterior rami of C1 to C3 through the ansa cervicalis	Draws larynx (thyroid cartilage) downward

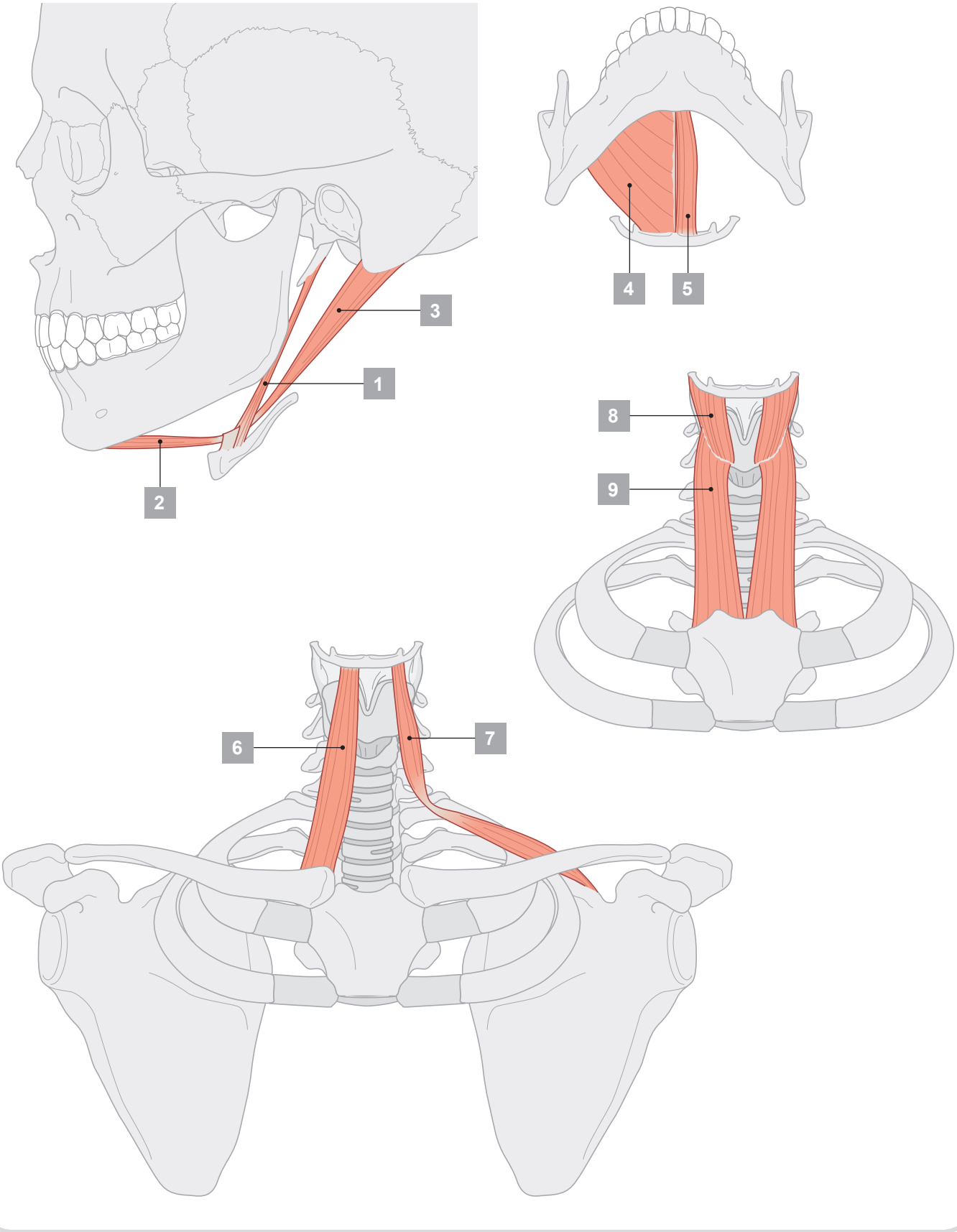
1
2
3
4
5
6
7
8
9

Branches of the external carotid artery

Artery		Parts supplied
Superior thyroid artery	1	Thyrohyoid muscle, internal structures of the larynx, sternocleidomastoid and cricothyroid muscles, thyroid gland
Ascending pharyngeal artery	2	Pharyngeal constrictors and stylopharyngeus muscle, palate, tonsil, pharyngotympanic tube, meninges in posterior cranial fossa
Lingual artery	3	Muscles of the tongue, palatine tonsil, soft palate, epiglottis, floor of mouth, sublingual gland
Facial artery	4	All structures in the face from the inferior border of the mandible anterior to the masseter muscle to the medial corner of the eye, the soft palate, palatine tonsil, pharyngotympanic tube, submandibular gland
Occipital artery	5	Sternocleidomastoid muscle, meninges in posterior cranial fossa, mastoid cells, deep muscles of the back, posterior scalp
Posterior auricular artery	6	Parotid gland and nearby muscles, external ear and scalp posterior to ear, middle and inner ear structures
Superficial temporal artery	7	Parotid gland and duct, masseter muscle, lateral face, anterior part of external ear, temporalis muscle, parietal and temporal fossae
Maxillary artery	8	External acoustic meatus, lateral and medial surface of tympanic membrane, temporomandibular joint, dura mater on lateral wall of skull and inner table of cranial bones, trigeminal ganglion and dura in vicinity, mylohyoid muscle, mandibular teeth, skin on chin, temporalis muscle, outer table of bones of skull in temporal fossa, structures in infratemporal fossa, maxillary sinus, upper teeth and gingivae, infra-orbital skin, palate, roof of pharynx, nasal cavity

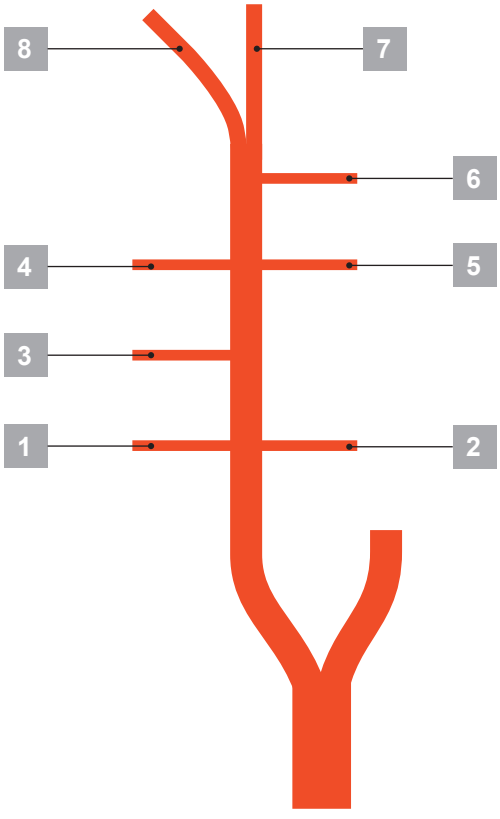

Subdivisions of the anterior triangle of the neck—a regional approach

Subdivision		Boundaries	Contents
Submental triangle (unpaired)	1	Mandibular symphysis; anterior belly of digastric muscle; body of hyoid bone	Submental lymph nodes; tributaries forming the anterior jugular vein
Submandibular triangle (paired)	2	Lower border of mandible; anterior belly of digastric muscle; posterior belly of digastric muscle	Submandibular gland; submandibular lymph nodes; hypoglossal nerve [XII]; mylohyoid nerve; facial artery and vein
Carotid triangle (paired)	3	Posterior belly of digastric muscle; superior belly of omohyoid muscle; anterior border of sternocleido-mastoid muscle	Tributaries to common facial vein; cervical branch of facial nerve [VII]; common carotid artery; external and internal carotid arteries; superior thyroid; ascending pharyngeal; lingual, facial, and occipital arteries; internal jugular vein; vagus [X], accessory [XI], and hypoglossal [XII] nerves; superior and inferior roots of ansa cervicalis; transverse cervical nerve
Muscular triangle (paired)	4	Midline of neck; superior belly of omohyoid muscle; anterior border of sternocleidomastoid muscle	Sternohyoid, omohyoid, sternohyoid, and thyrohyoid muscles; thyroid and parathyroid glands; pharynx

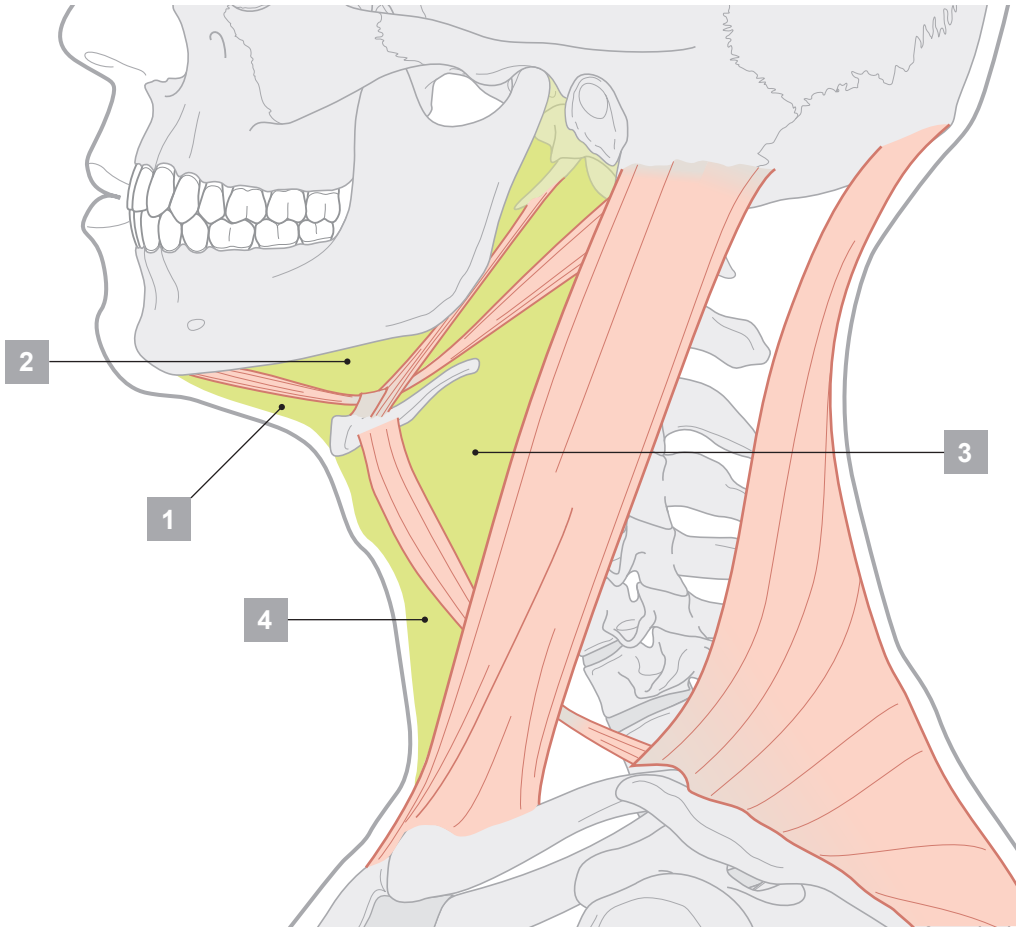

Muscles associated with the posterior triangle of the neck

Parentheses indicate possible involvement

Muscle		Origin	Insertion	Innervation	Function
Sternocleidomastoid —Sternal head	1	Upper part of anterior surface of manubrium of sternum	Lateral one half of superior nuchal line	Accessory nerve [XI] and branches from anterior rami of C2 to C3 (C4)	Individually, will tilt head toward shoulder on same side rotating head to turn face to opposite side; acting together, draw head forward
—Clavicular head	2	Superior surface of medial one third of clavicle	Lateral surface of mastoid process		
Trapezius	3	Superior nuchal line; external occipital protuberance; ligamentum nuchae; spinous processes of vertebrae CVII to TXII	Lateral one third of clavicle; acromion; spine of scapula	Motor—accessory nerve [XI]; proprioception—C3 and C4	Assists in rotating the scapula during abduction of humerus above horizontal; upper fibers—elevate, middle fibers—adduct, lower fibers—depress scapula
Splenius capitis	4	Lower half of ligamentum nuchae; spinous processes of vertebrae CVII to TIV	Mastoid process, skull below lateral one third of superior nuchal line	Posterior rami of middle cervical nerves	Together, draw head backward; individually, draw and rotate head to one side (turn face to same side)
Levator scapulae	5	Transverse processes of CI to CIV	Upper part of medial border of scapula	C3, C4; and dorsal scapular nerve (C4, C5)	Elevates scapula
Posterior scalene	6	Posterior tubercles of transverse processes of vertebrae CIV to CVI	Upper surface of rib II	Anterior rami of C5 to C7	Elevation of rib II
Middle scalene	7	Transverse processes of vertebrae CII to CVII	Upper surface of rib I posterior to the groove for the subclavian artery	Anterior rami of C3 to C7	Elevation of rib I
Anterior scalene	8	Anterior tubercles of the transverse processes of vertebrae CIII to CVI	Scalene tubercle and upper surface of rib I	Anterior rami of C4 to C7	Elevation of rib I
Omohyoid	9	Superior border of scapula medial to scapular notch	Inferior border of body of hyoid bone	Ansa cervicalis; anterior rami of C1 to C3	Depress the hyoid bone

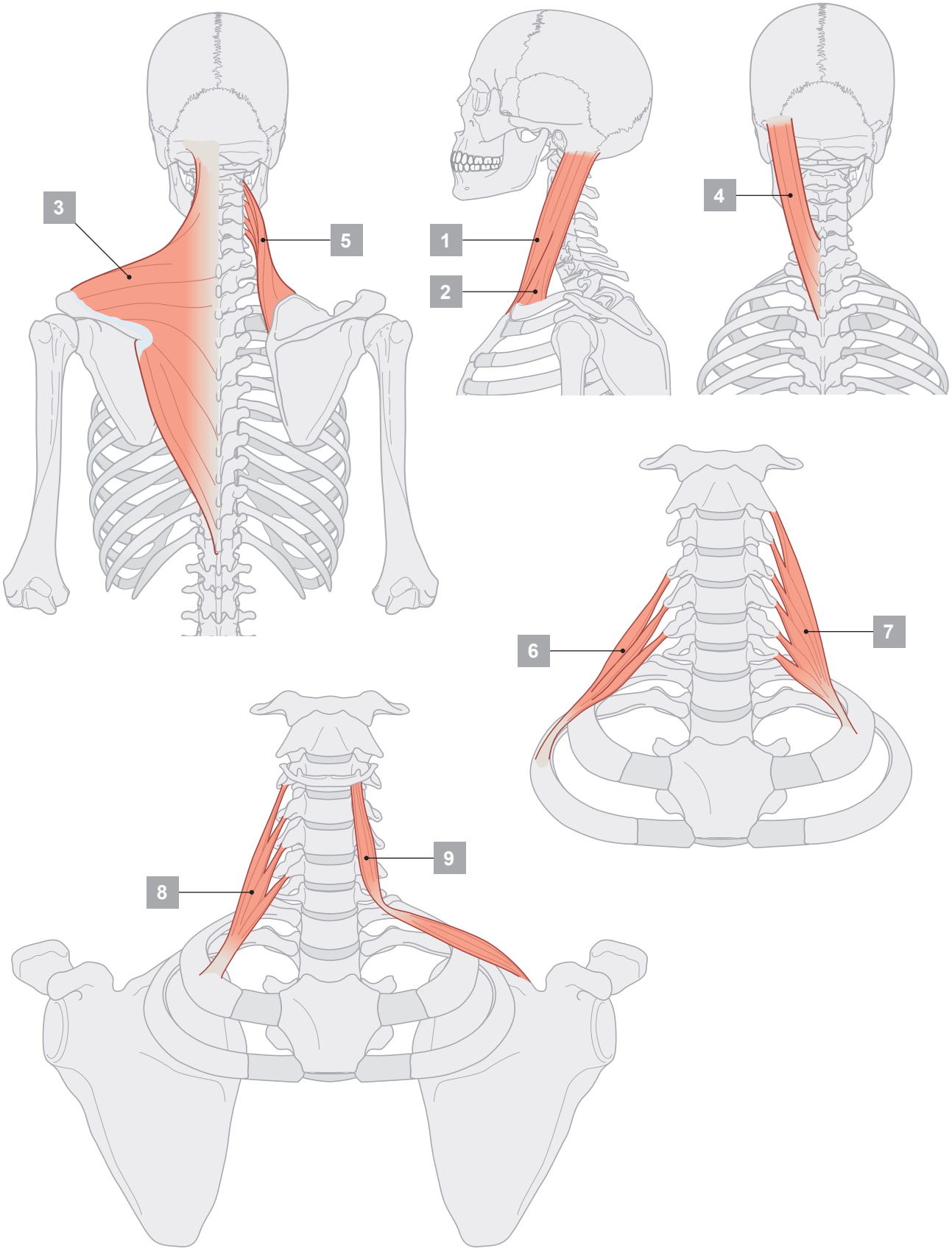
3
5
1
2
4
6
7
8
9

Prevertebral and lateral muscles

Muscle		Origin	Insertion	Innervation	Function
Rectus capitis anterior	1	Anterior surface of lateral part of atlas and its transverse process	Inferior surface of basilar part of occipital bone	Branches from anterior rami of C1, C2	Flexes head at atlanto-occipital joint
Rectus capitis lateralis	2	Superior surface of transverse process of atlas	Inferior surface of jugular process of occipital bone	Branches from anterior rami of C1, C2	Flexes head laterally to same side
Longus colli —Superior oblique part	3	Anterior tubercles of transverse processes of vertebrae CIII to CV	Tubercle of anterior arch of atlas	Branches from anterior rami of C2 to C6	Flexes neck anteriorly and laterally and slight rotation to opposite side
—Inferior oblique part	4	Anterior surface of bodies of vertebrae TI, TII, and maybe TIII	Anterior tubercles of transverse processes of vertebrae CV and CVI		
—Vertical part	5	Anterior surface of bodies of TI to TIII and CV to CVII	Anterior surface of bodies of vertebrae CII to CIV		
Longus capitis	6	Tendinous slips to transverse processes of vertebrae CIII to CVI	Inferior surface of basilar part of occipital bone	Branches from anterior rami of C1 to C3	Flexes the head

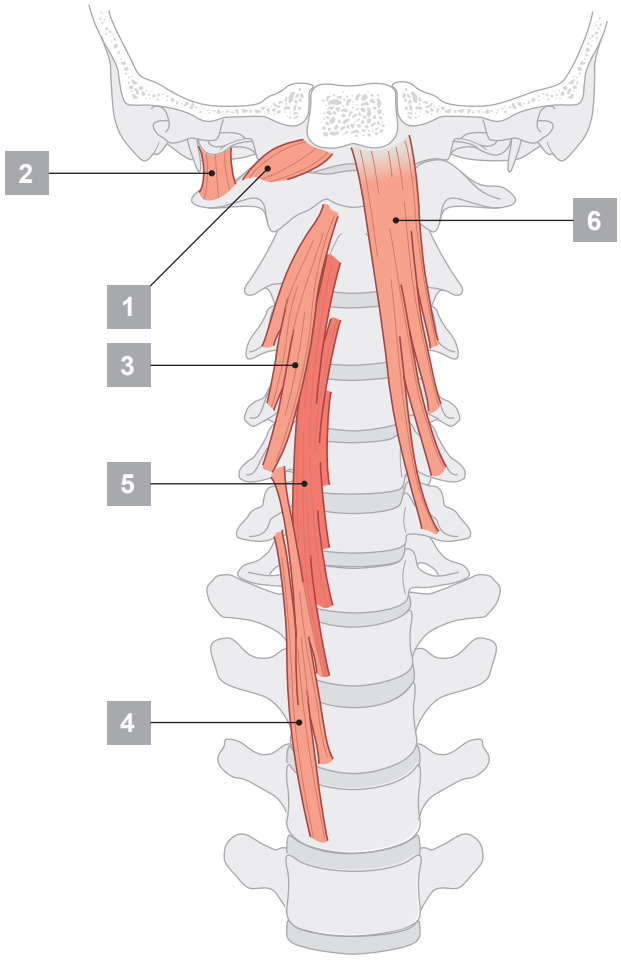

Constrictor muscles of the pharynx

Muscle		Posterior attachment	Anterior attachment	Innervation	Function
Superior constrictor	1	Pharyngeal raphe	Pterygomandibular raphe and adjacent bone on the mandible and pterygoid hamulus	Vagus nerve [X]	Constriction of pharynx
Middle constrictor	2	Pharyngeal raphe	Upper margin of greater horn of hyoid bone and adjacent margins of lesser horn and stylohyoid ligament	Vagus nerve [X]	Constriction of pharynx
Inferior constrictor	3	Pharyngeal raphe	Cricoid cartilage, oblique line of thyroid cartilage, and a ligament that spans between these attachments and crosses the cricothyroid muscle	Vagus nerve [X]	Constriction of pharynx

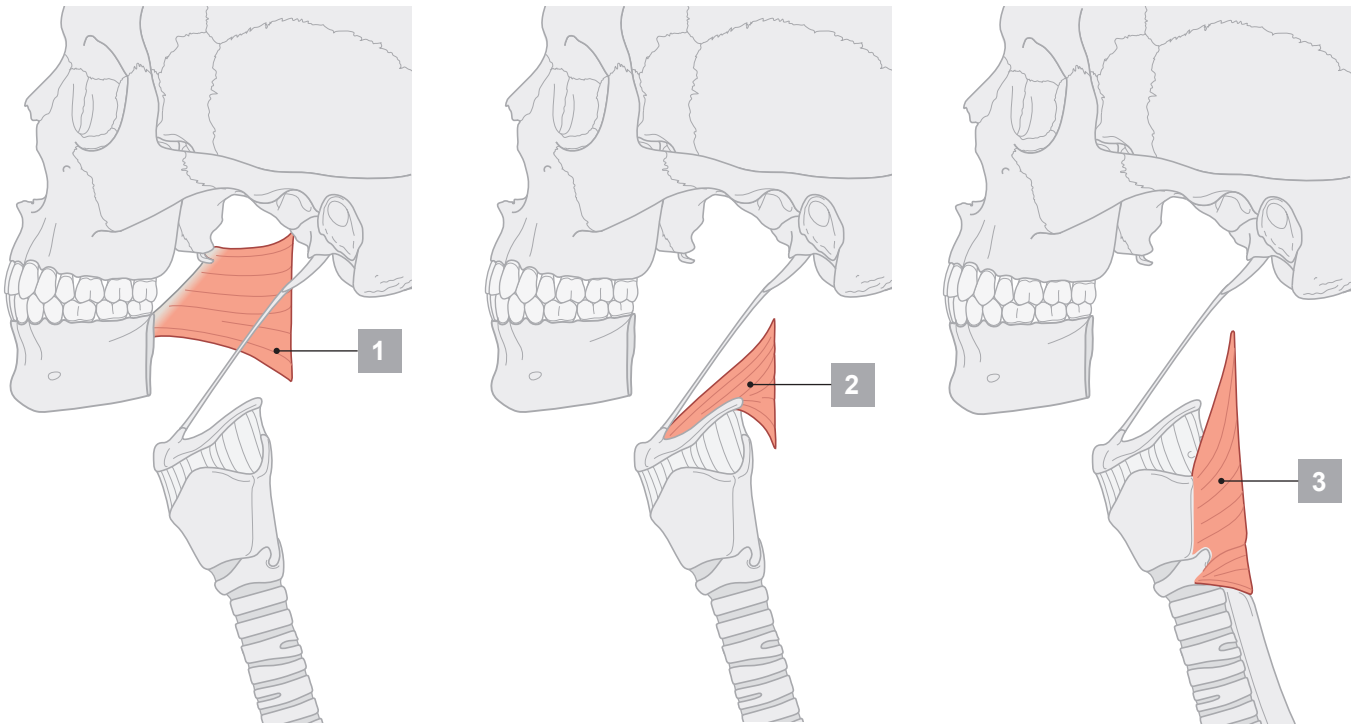

Longitudinal muscles of the pharynx

Muscle		Origin	Insertion	Innervation	Function
Stylopharyngeus	1	Medial side of base of styloid process	Pharyngeal wall	Glossopharyngeal nerve [IX]	Elevation of the pharynx
Salpingopharyngeus	2	Inferior aspect of pharyngeal end of pharyngotympanic tube	Pharyngeal wall	Vagus nerve [X]	Elevation of the pharynx
Palatopharyngeus	3	Upper surface of palatine aponeurosis	Pharyngeal wall	Vagus nerve [X]	Elevation of the pharynx; closure of the oropharyngeal isthmus

Intrinsic muscles of the larynx

Muscle		Origin	Insertion	Innervation	Function
Cricothyroid	1	Anterolateral aspect of arch of cricoid cartilage	Oblique part—inferior horn of the thyroid cartilage; straight part—inferior margin of thyroid cartilage	External branch of superior laryngeal nerve from the vagus nerve [X]	Forward and downward rotation of the thyroid cartilage at the cricothyroid joint
Posterior crico-arytenoid	2	Oval depression on posterior surface of lamina of cricoid cartilage	Posterior surface of muscular process of arytenoid cartilage	Recurrent laryngeal branch of the vagus nerve [X]	Abduction and external rotation of the arytenoid cartilage. The posterior crico-arytenoid muscles are the primary abductors of the vocal folds. In other words, they are the primary openers of the rima glottidis.
Lateral crico-arytenoid	3	Superior surface of arch of cricoid cartilage	Anterior surface of muscular process of arytenoid cartilage	Recurrent laryngeal branch of the vagus nerve [X]	Internal rotation of the arytenoid cartilage and adduction of vocal folds
Transverse arytenoid	4	Lateral border of posterior surface of arytenoid cartilage	Lateral border of posterior surface of opposite arytenoid cartilage	Recurrent laryngeal branch of the vagus nerve [X]	Adduction of arytenoid cartilages
Oblique arytenoid	5	Posterior surface of muscular process of arytenoid cartilage	Posterior surface of apex of adjacent arytenoid cartilage; extends into ary-epiglottic fold	Recurrent laryngeal branch of the vagus nerve [X]	Sphincter of the laryngeal inlet
Thyro-arytenoid	6	Thyroid angle and adjacent cricothyroid ligament	Anterolateral surface of arytenoid cartilage; some fibers continue in ary-epiglottic folds to the lateral margin of the epiglottis	Recurrent laryngeal branch of the vagus nerve [X]	Sphincter of vestibule and of laryngeal inlet
Vocalis	7	Lateral surface of vocal process of arytenoid cartilage	Vocal ligament and thyroid angle	Recurrent laryngeal branch of the vagus nerve [X]	Adjusts tension in vocal folds

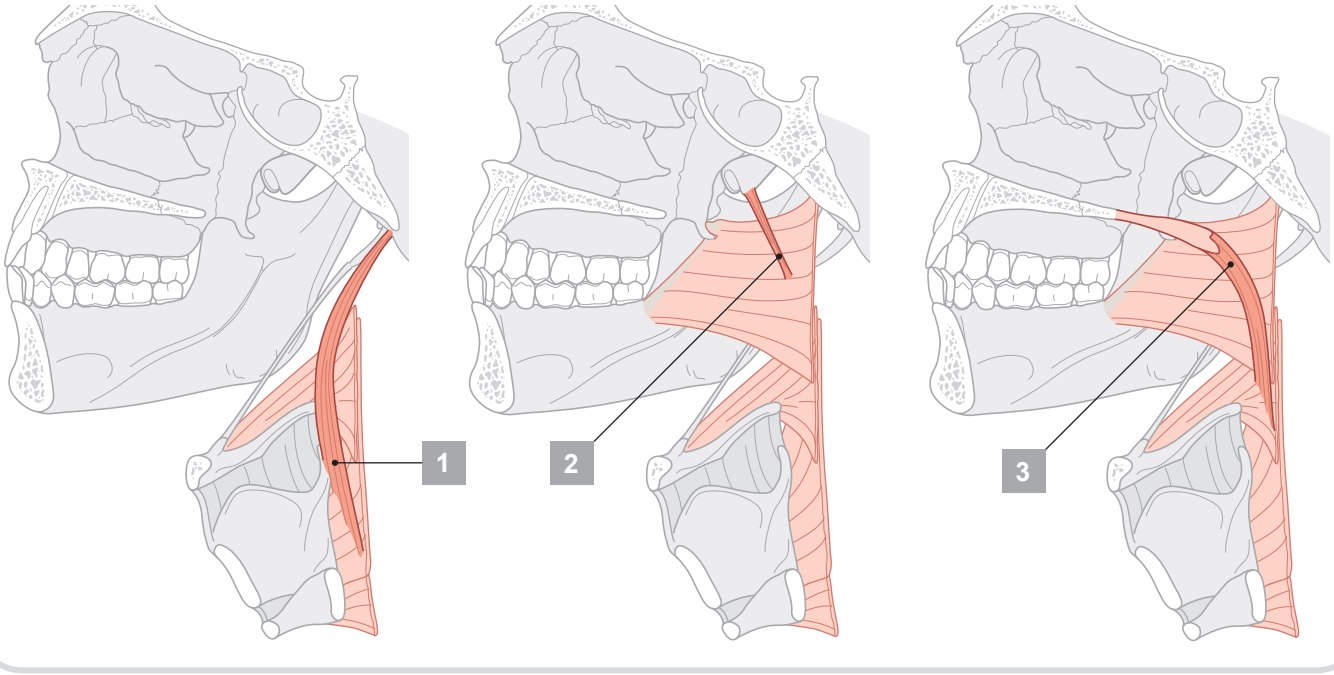
1
2
3

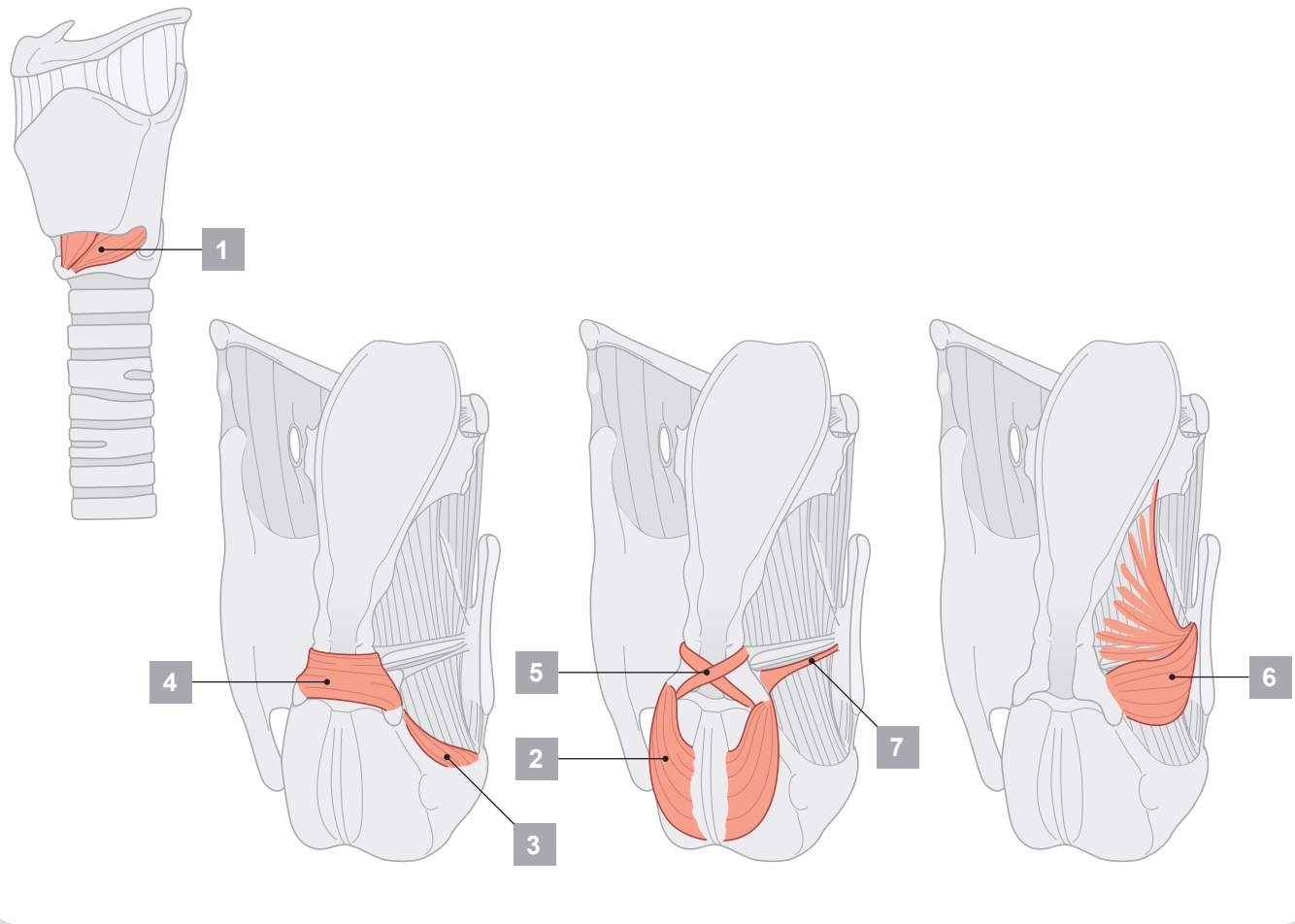
1
4
3
5
2
7
6

Muscles in the floor of the oral cavity

Muscle		Origin	Insertion	Innervation	Function
Mylohyoid	1	Mylohyoid line of mandible	Median fibrous raphe and adjacent part of hyoid bone	Nerve to mylohyoid from the inferior alveolar branch of mandibular nerve [V_3]	
Geniohyoid	2	Inferior mental spines of mandible	Body of hyoid bone	C1	Supports and elevates floor of oral cavity; depresses mandible when hyoid is fixed; elevates and pulls hyoid forward when mandible is fixed

Muscles of the tongue

Muscle		Origin	Insertion	Innervation	Function
Intrinsic					
Superior longitudinal (just deep to surface of tongue)	1	Submucosal connective tissue at the back of the tongue and from the median septum of the tongue	Muscle fibers pass forward and obliquely to submucosal connective tissue and mucosa on margins of tongue	Hypoglossal nerve [XII]	Shortens tongue; curls apex and sides of tongue
Inferior longitudinal (between genioglossus and hyoglossus muscles)	2	Root of tongue (some fibers from hyoid)	Apex of tongue	Hypoglossal nerve [XII]	Shortens tongue; uncurls apex and turns it downward
Transverse	3	Median septum of the tongue	Submucosal connective tissue on lateral margins of tongue	Hypoglossal nerve [XII]	Narrows and elongates tongue
Vertical	4	Submucosal connective tissue on dorsum of tongue	Connective tissue in more ventral regions of tongue	Hypoglossal nerve [XII]	Flattens and widens tongue
Extrinsic					
Genioglossus	5	Superior mental spines	Body of hyoid; entire length of tongue	Hypoglossal nerve [XII]	Protrudes tongue; depresses center of tongue
Hyoglossus	6	Greater horn and adjacent part of body of hyoid bone	Lateral surface of tongue	Hypoglossal nerve [XII]	Depresses tongue
Styloglossus	7	Styloid process (anterolateral surface)	Lateral surface of tongue	Hypoglossal nerve [XII]	Elevates and retracts tongue
Palatoglossus	8	Inferior surface of palatine aponeurosis	Lateral margin of tongue	Vagus nerve [X] (via pharyngeal branch to pharyngeal plexus)	Depresses palate; moves palatoglossal fold toward midline; elevates back of the tongue

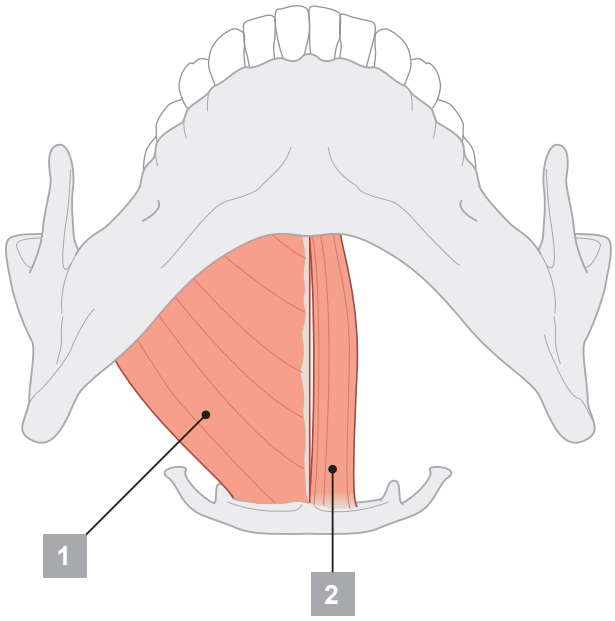
1
2

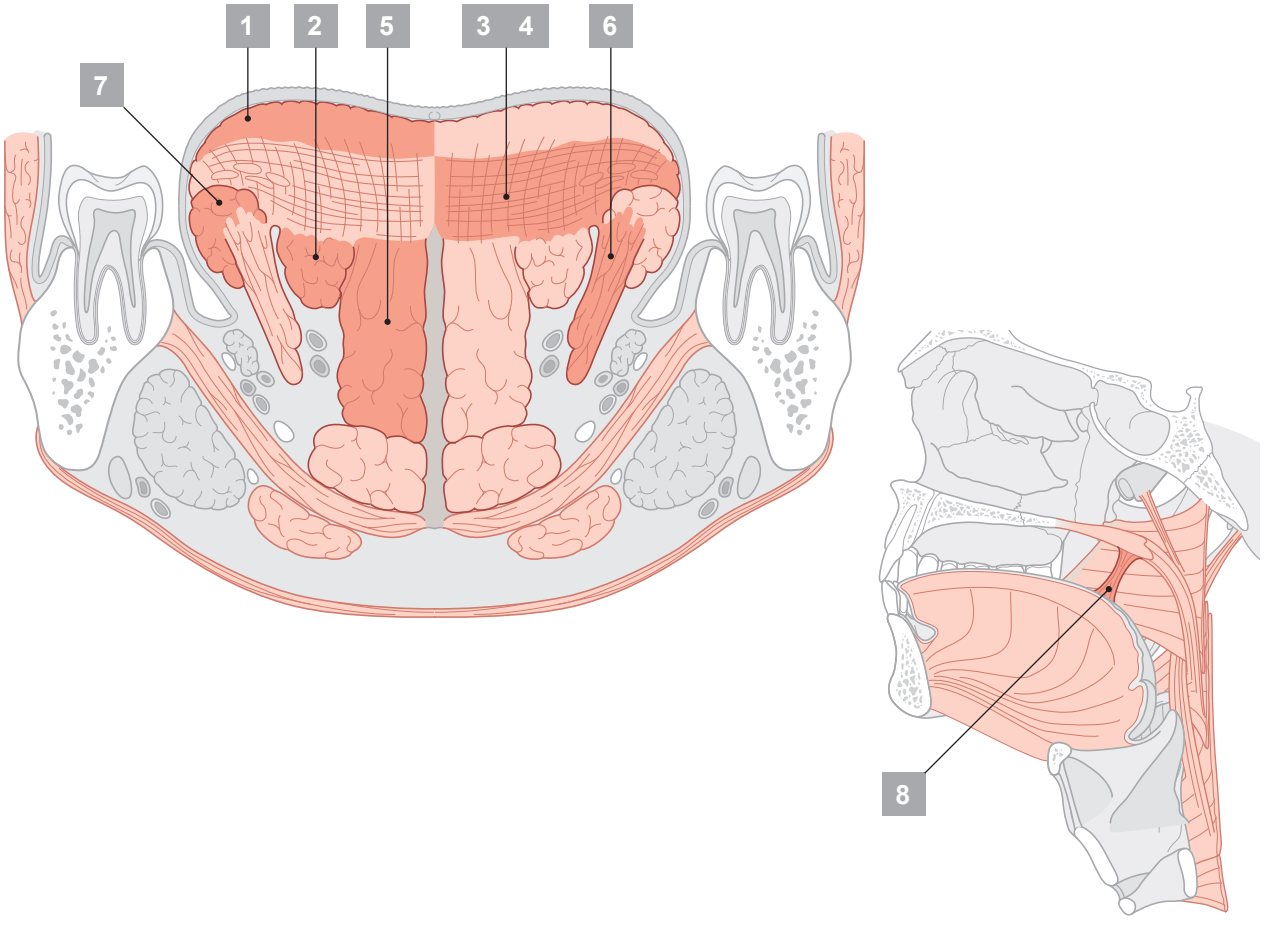
1
2
5
3
4
6
7
8

Muscles of the soft palate

Muscle		Origin	Insertion	Innervation	Function
Tensor veli palatini	1	Scaphoid fossa of sphenoid bone; fibrous part of pharyngotympanic tube; spine of sphenoid	Palatine aponeurosis	Mandibular nerve [V_3] via the branch to medial pterygoid muscle	Tenses the soft palate; opens the pharyngotympanic tube
Levator veli palatini	2	Petrous part of temporal bone anterior to opening for carotid canal	Superior surface of palatine aponeurosis	Vagus nerve [X] via pharyngeal branch to pharyngeal plexus	Only muscle to elevate the soft palate above the neutral position
Palatopharyngeus	3	Superior surface of palatine aponeurosis	Pharyngeal wall	Vagus nerve [X] via pharyngeal branch to pharyngeal plexus	Depresses soft palate; moves palatopharyngeal arch toward midline; elevates pharynx
Palatoglossus	4	Inferior surface of palatine aponeurosis	Lateral margin of tongue	Vagus nerve [X] via pharyngeal branch to pharyngeal plexus	Depresses palate; moves palatoglossal arch toward midline; elevates back of the tongue
Musculus uvulae	5	Posterior nasal spine of hard palate	Connective tissue of uvula	Vagus nerve [X] via pharyngeal branch to pharyngeal plexus	Elevates and retracts uvula; thickens central region of soft palate

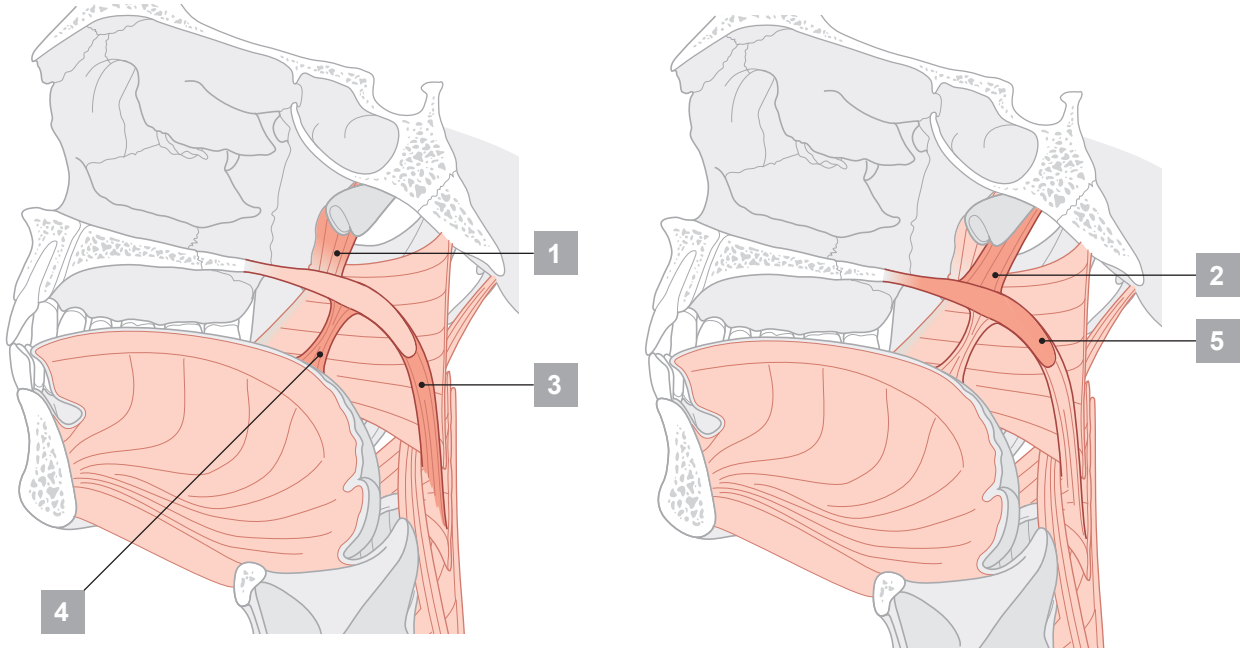

A
Abdomen
  arterial supply of viscera, 157
  coronal section, 156
  dermatomes, 205
  imaging, coronal section, 156
  innervation of, 199
  lymphatics, 198
  muscles of, 137–141
  quadrants and regions of, 135
  referred pain diagram, 202–203
  saggital section, 155
  surface anatomy, 134
  venous drainage of viscera, 180–181
  visceral motor innervation, 201
  visceral sensory innervation, 202–204
Abdominal aorta, 137, 154, 157, 299
  branches of, 192
  imaging, 194–195
  positioning, 195
Abdominal esophagus, 158
Abdominal ostium, 243
Abdominal viscera, 153
Abdominal wall
  anterior, 151
  arteries of, 143
  dermatomes, 145
  innervation of, 144–145
  layers of, 136–137
  posterior, 183
    vessels of, 184
  superficial veins, 182
  transverse section, 137
  vasculature of, 142
Abducent nerve, 498, 513, 584
Abductor digiti minimi, 357–360, 444, 446–447
Abductor hallucis, 356–360
Abductor pollicis brevis, 444, 446–447, 456
Abductor pollicis longus, 9, 431, 435–436
Abductor pollicis longus tendon, 440, 444–445
Accessory ligament, 66
Accessory nerve, 37, 498–499, 542, 585
Acetabular foramen, 297
Acetabular fossa, 294, 297–298
Acetabular labrum, 298
Acetabular ligament, transverse, 297–298
Acetabular roof, 298
Acetabulum, 212, 214, 220, 258, 294
Achilles tendon, 5
Acoustic meatus
  external, 520–521, 527
  internal, 485, 520–522, 524
Acromioclavicular joint, 62, 385, 388
Acromioclavicular ligament, 388, 397
Acromion, of scapula, 4–7, 20, 36, 39, 385–386
Adductor brevis, 8, 305, 309, 316
Adductor canal, 310
Adductor hallucis, 360
Adductor hiatus, 309–310, 327
Adductor longus, 8, 305–306, 309–310, 316
Adductor magnus, 8–9, 301, 305, 307, 309, 313–314, 316, 327
Adductor magnus tendon, 309
Adductor pollicis, 444, 446–447
Adductor tubercle, 304
Adrenal medulla, 204
Adventitia of great vessels, 93
Afferent lymphatic vessels, 12
Ala of nose, 566–567
Ala of sacrum, 212, 214, 220–221, 227, 294–295
Alar cartilage, 566–567
Alveolar arch, 484, 572
Alveolar artery
  anterior superior, 535, 576
  inferior, 507, 533, 576
  posterior superior, 535, 576
Alveolar bone, 575
Alveolar foramen, 527, 534
Alveolar nerve
  anterior superior, 535, 569, 576–577
  inferior, 528, 531, 576
  middle superior, 535, 576–577
  posterior superior, 535, 577
Alveolar plexus, superior, 535, 576
Alveolar process, 478
Alveolar vein
  anterior superior, 576
  inferior, 533, 557, 576
  posterior superior, 576
Ampulla, 524
Anal aperture, 227–229, 255–256, 258
Anal canal, 166, 222, 224, 230
  coronal section, 231
  in sagittal plane, 3
Anal columns, 231
Anal crypt, 231
Anal sinus, 231
Anal sphincter
  external, 231
    cutaneous part, 222, 224, 230
    deep part, 222, 224, 230
    superficial, 222, 224, 230
  internal, 222, 224, 230–231
Anal triangle, 255
Anal valve, 231
Anastomotic loops, 46
Anatomical position, 2
Anatomical snuffbox, 456
Anconeus, 412, 435
Angular artery, 506, 510
Angular gyrus, 494
Angular vein, 506, 510, 515
Ankle, 7, 335
  bones, 293
  imaging, 338
  ligaments, 336–337
Anococcygeal ligament, 228
Anococcygeal nerves, 252
Ansa cervicalis, 544–545, 579
Antebrachial vein, 424, 457
Anterior, as anatomical direction, 2
Anterolateral central arteries, 500
Anteromedial arteries, 500
Anterosuperior margin of pubic symphysis, 221
Antihelix, 520
  crura of, 520
Antitragus, 520
Anular ligament, 420, 422–423, 433, 444
Anulus fibrosus, 32–33
Aorta
  abdominal, 74, 137, 154, 157, 299, 312
    branches of, 192
    imaging, 194–195
    positioning, 195
    retroperitoneal, 186
  arch of, 10, 63, 74, 88, 99
  ascending, 10, 74, 89, 94, 102
  esophageal branches of, 118
  thoracic, 10, 74, 82, 88–89, 101, 107
Aortic arch, 500
Aortic hiatus, 73, 184–185
Aortic nodes, 77, 198, 268–269
Aorticorenal ganglion, 199, 201
Aortic plexus, 199
Aortic valve, 100–101
  auscultation point for, 106
Apical foramen, 575
Apical segment, of lung, 87
Apicoposterior segment
  of bronchi, 87
  of lung, 87
Appendicular artery, 157
Appendix, 12, 166
  in coronal section of abdomen, 156
  orifice of, 168
  positions of, 168
Arachnoid mater, 48–49
Arachnoid trabeculae, 49
Arcuate artery, 346, 355
Arcuate eminence, 485
Arcuate ligament
  lateral, 183, 185
  medial, 73, 183, 185
  median, 73, 183–184
Arcuate line, 136, 140, 151
Arcuate line of ilium, 216, 219–221, 294
Areola, 4, 68–69
Arms
  anterior compartment, 408–409, 431–434
  arteries, 410, 414, 434, 437
  bones, 385
  compartments of, 408
  imaging, 417, 421, 423, 439
  lymphatics, 415, 457
  muscle attachments, 407, 409, 413, 430
  muscles, 408–409, 412–413, 432–433, 435–436
  nerves, 410, 414, 418–419, 424, 434, 437, 458–459
  posterior compartment, 412–414, 435–437
  surface anatomy, 384, 408, 412, 431, 435
  transverse section, 416–417, 438
  veins, 411, 457
Arterial arcades, 165
Arteria rectae, 170
Arteries, 312. *See also individual arteries*
  to abdominal viscera, 157
  abdominal wall, 143
  arm
    anterior compartment, 410, 434
    posterior compartment, 414, 437
  to brain, 500, 502
    imaging, 501
  dural, 492
  eyes, 515
  foot, 354–355, 361–362
  gluteal, 302–303
  hand, 448–450, 454
  hip joint, 299
  infratemporal fossae, 533
  knee, 327
  leg, 342, 346
  nasal cavity, 569
  neck, 546–549
  parotid region, 507
  pelvic, 246
  pterygopalatine fossa, 535
  spleen, 160–161
  stomach, 160–161
  to teeth, 576
  temporal fossae, 533
  thigh, 311
  thoracic wall, 74
  thyroid gland, 564
  tongue, 579
Articular cartilage, 326, 423
Articular cavity, 326
Articular disc, 529
Articular facet
  in elbow, 420
  vertebral, 24, 26

Articularis genus, 305
Articular process
  column of, 23
  inferior, 22
  superior, 295
Articular tubercle, 484, 527, 529
Articulus genus, 326
Ary-epiglottic, 561
Ary-epiglottic fold, 553, 555, 560
Arytenoid
  oblique, 555, 561
  transverse, 552, 555, 561
Arytenoid cartilage, 559–560
Ascending aorta, 10
Ascending colon, 152–153, 162, 166
  in coronal section of abdomen, 156
Asterion, 480
Atlanto-axial joint, 23
  lateral, 23
Atlanto-occipital joint, 499, 537
Atrioventricular bundle, 100, 105
Atrioventricular node, 105
Atrioventricular ring, 100
Atrium
  left, 94–95, 98
  right, 63, 94–97, 101, 103
Auditory ossicles, 522
Auricular artery, posterior, 506–507, 546
Auricular muscle
  anterior, 505
  posterior, 505
  superior, 505
Auricular nerve, great, 542, 544–545
Auricular site for clavicle, 64
Auricular vein, posterior, 506, 533, 539
Auriculotemporal nerve, 503, 531–533
Auscultation, triangle of, 36–37
Auscultation points, 106
Axial plane, 2–3
Axilla, 68
  walls of, 396–397
Axillary artery, 10, 69, 401–402, 410
Axillary nerve, 13, 395, 403, 405, 414
Axillary nodes, 12, 143
  apical, 69
  central, 69
  lateral, 69
  pectoral, 69
  subscapular, 69
Axillary process, 68–69
Axillary vein, 411
Azygos vein, 11, 82, 119, 185

B
Back
  cutaneous nerves, 53
  dermatomes, 53
  muscles of, 36–43
    deep, 40–41
    intermediate, 39
    suboccipital region, 43
    superficial, 37
    surface, 37
    transverse section, 42
  surface anatomy of, 20, 36
  transverse section of thoracic region, 52
Bare area, of liver, 173
Basal segment, posterior
  of bronchi, 87
  of lung, 87
Basilar artery, 500
Basilar membrane, 524
Basilic vein, 11, 384, 394–395, 411, 424, 457
Basivertebral vein, 47
Benign prostatic hypertrophy, 236
Biceps brachii, 8, 395, 408–409, 431
Biceps brachii tendon, 8, 390, 431–432
Biceps femoris, 9, 300, 305, 307, 313–314, 316, 340, 343
Biceps femoris tendon, 5, 292, 313
Bicipital aponeurosis, 408, 424, 431
Bifid spinous process, 24
Bifurcate ligament, 336–337, 352
Bile duct(s), 163, 173, 177–178
Bladder, 147–148, 190, 222, 224, 237
  apex of, 232
  in coronal section of abdomen, 156
  female, 233
  imaging, 235–236
  innervation of, 274
  in situ, 230
  male, 232
  neck of, 232, 235
  positioning, female, 233
  in sagittal plane, 3
  surface projection
    female, 233
    male, 232
  transverse vesical fold, 237
Body, surface of
  anterior view, 4
  posterior view, 5
Bone marrow, 12
Bones. *See* Skeleton; *individual bones*
Bony orbit, 508
Brachial artery, 10, 395, 400–402, 414, 424, 434
Brachialis, 8, 408–409, 424, 431–432
Brachial plexus, 13, 395, 403, 543
  cords of, 403–405
Brachial veins, 11, 411
Brachiocephalic nodes, 77
Brachiocephalic trunk, 10, 82–83, 88, 107, 110, 113, 500
Brachiocephalic vein
  in axial plane, 3
  left, 75, 82, 88, 101, 110, 564
  right, 11, 82, 101, 110, 564–565
Brachioradialis, 8, 408, 412, 424, 431, 435–436
Brain, 494–498
  arterial supply, 500, 502
    imaging, 501
  commissures, 495
  imaging, 495–497
  lobes, 495
Brainstem, 495
Breast, 4, 68–69
Bregma, 483
Bronchial arteries, 82–83, 118
Bronchial cartilage, 86
Bronchial tree, 86
Bronchomediastinal trunk, 77, 551
Bronchopulmonary segments, 87
Bronchus, 83
  inferior lobar, 86, 88
  left main, 86, 88–89
  middle lobar, 88
  right main, 89
  superior lobar, 86, 88
Buccal artery, 507, 533
Buccal nerve, 503, 531, 577
Buccinator, 8, 504–505, 528, 554, 580
Buccopharyngeal fascia, 538, 554, 580
Buck's fascia, 238, 240
Bulbospongiosus, 222, 235, 240, 255–256
Bulbo-urethral duct, 240
Bulbo-urethral gland, 234, 240, 259
Bundle branch, left, 105
Bursae
  deep infrapatellar, 326
  glenohumeral joint, 392
  prepatellar, 326
  semimembranosus, 326
  subtendinous, 326
  suprapatellar, 326

C
Calcaneal artery
  lateral, 361–362
  medial, 361–362
Calcaneal tendon, 5, 9, 292, 352
Calcaneal tubercle, 330
Calcaneal tuberosity, 292–293, 331, 356
Calcaneocuboid joint, 333
Calcaneocuboid ligament, 352
Calcaneofibular ligament, 336–337, 352
Calcaneometatarsal ligament, 356
Calcaneonavicular ligament, 337
Calcaneus, 7, 293, 330–332, 334
Calcarine sulcus, 494–495
Calyx
  major, 188
  minor, 188
Camper's layer, 136–137
Canines, 573
Capitate, 426, 428, 440
Capitis superior, oblique, 41
Capitulum, 6, 406
Capsule
  of lens, 516
  of lymph node, 12
Caput medusae, 182
Cardia, of stomach, 158
Cardiac branches (sympathetic), 110
Cardiac impression, 82–83
Cardiac nerves, sympathetic, 126, 545
Cardiac notch, 82–83, 164
Cardiac orifice, 169
Cardiac plexus, 88, 126
  deep, 107
  superficial, 107
Cardiac skeleton, 100
Cardiac vein(s)
  anterior, 102
  great, 94–95, 99, 102
  middle, 95, 102
  posterior, 102
  small, 94, 102
Cardial notch, of stomach, 158
Caroticotympanic nerve, 522
Carotid artery
  common, 506, 539, 546
    in axial plane, 3
    left, 10, 74, 88, 101, 110, 113, 500, 548–549, 565
    right, 74, 82, 88, 101, 109–110, 400, 500, 548, 565
  external, 492, 500, 506–507, 533, 546
    left, 10, 500, 564
    right, 565
  internal, 500, 506, 546
    left, 10, 500, 564
    right, 500, 565
Carotid canal, 484, 523
Carotid nerve, internal, 535
Carotid sheath, 538
Carotid sinus, 500, 546
Carotid triangle, 536
Carpal arch, dorsal, 454
Carpal artery, 437
Carpal bones, 6, 385, 426
Carpal ligament, 429

Carpal tunnel, 440
  imaging, 441
Carpometacarpal joint, 426, 429
Cauda equina, 13, 33–34, 45, 48
Caudal, as anatomical direction, 2
Caudate lobe, of liver, 173, 175
Caudate process, 175
Caval opening, 73
Cavernous nerve, 254
Cavernous sinus, 493, 498, 500
Cecum, 153, 166, 168–169
  in coronal section of abdomen, 156
Celiac ganglion, 199, 201
Celiac nodes, 198, 268–269
Celiac trunk, 10, 157
  branching of, 161
  distribution of, 160
  imaging, 161
  positioning of, 161
Cement (dental), 575
Central arteries, 516
  anterolateral, 500
Central incisors, 573
Central nodes, 415
Central sulcus, 495
Central tendon of diaphragm, 73, 185
Central vein, 516
Cephalic vein, 11, 384, 394–395, 411, 457
Cerebellar artery
  anterior inferior, 500, 502
  posterior, 499
  posterior inferior, 502
  superior, 499–500, 502
Cerebellar peduncles, 499
Cerebellum, 50, 494–495, 499, 502
Cerebral arterial circle, 500
Cerebral artery
  anterior, 500, 502
  middle, 500, 502
  posterior, 500, 502
Cerebral hemispheres, blood supply, 502
Cervical artery
  ascending, 46, 546, 548–549
  deep, 46, 548–549
  transverse, 37–38, 400, 402, 546, 548–549, 564–565
Cervical cardiac nerves, 88
Cervical ganglia, 200, 544
Cervical nerve(s), 44
  transverse, 542, 544
Cervical nodes, 12
  anterior superficial, 550
  deep, 550–551
  posterior lateral, 550
  superficial, 550
  transverse, 550
Cervical pleura, 80
Cervical plexus, 13, 544–545
Cervical vertebrae, 21–25, 386
Cervical vertebral column, 50
Cervix of uterus, 224, 241, 243, 245
Cervix of vagina, 242
Check ligament, medial, 509
Chest wall
  anterior female, 62
  anterior male, 62
Chiasmatic sulcus, 485
Choanae, 567–568
Chordae tendineae, 97, 99
Chorda tympani nerve, 521, 523, 531–532, 579
Choroid, 509, 516
Choroidal artery
  anterior, 500
  posterior lateral, 500
Choroid plexus, 495
Ciliary artery
  anterior, 516
  long posterior, 515–516
  short posterior, 515–516
Ciliary body, 516
Ciliary ganglion, 513, 517
Ciliary muscle, 516
Ciliary nerves, 513
  long, 517
  short, 517
Ciliary process, 516
Cingulate gyrus, 494
Circle of Willis, 500
Circular muscle of esophagus, 554–555
Circular muscle of rectum, 231
Cisterna chyli, 12, 77, 119, 198
Clavicle, 4, 6–7, 62–63, 71, 114, 385
  articular surface for, 387
  joints and ligaments, 388
  muscle attachments, 388
Clavicopectoral triangle, 408
Clavipectoral fascia, 70, 395
Clinoid process
  anterior, 485
  middle, 485
  posterior, 485
Clitoris
  crus of, 241, 262
  dorsal artery of, 246, 266
  dorsal nerve of, 267
  dorsal vein of, 266
  frenulum of, 257
  glans of, 224, 241, 256
  suspensory ligament of, 262
Clivus, 485
Cluneal nerves
  inferior, 53, 271, 302, 314–315
  medial, 53, 302
  middle, 271
  superior, 271
C1 nerve, 499, 542, 544
C2 nerve, 43, 53, 499, 542, 544
C3 nerve, 43, 53, 542, 544
C4 nerve, 542, 544
C5 nerve, 34, 542, 544
C6 nerve, 34, 542
C7 nerve, 34, 542
C8 nerve, 34, 542
Coccygeal cornu, 294
Coccygeal curvature, 21
Coccygeal nerves, 44
Coccygeal plexus, 252, 265, 271
Coccygeus, 227, 241, 245
Coccyx, 6–7, 21–22, 31, 212–216, 218–220, 226–227, 229
Cochlea, 520, 524
Cochlear duct, 524
Cochlear nerve, 520–521, 524
Colic artery
  left, 157, 170
  middle, 157, 164, 170
  right, 157, 164, 170
Colic flexure, 186
  in coronal plane, 3
  right, 166, 186
Colic impression, on spleen, 159
Colic vein
  left, 180–181
  middle, 181
    branch of, 180
  right, 181
Collateral branches, 72
Collateral ligaments, 351–352, 423, 429
Collateral sulcus, 494
Colliculus
  inferior, 495
  superior, 495
Colon
  ascending, 152–153, 157, 162, 164, 166
    in coronal section of abdomen, 156
  descending, 152, 157, 162, 166, 186
  haustra of, 166
  sigmoid, 147, 157, 166, 169, 222, 224, 230
    in coronal plane, 3
    in coronal section of abdomen, 156
  transverse, 153, 157, 163, 166
    in coronal plane, 3
    in coronal section of abdomen, 156
Colonoscopy, 169
Commissural ligament, 443
Communicating artery
  anterior, 500, 502
  posterior, 500, 502
Communicating vein, 539
Compressor urethrae, 233, 259
Conduction system of heart, 105
Condylar process, 480, 572
Condyle
  in elbow
    lateral, 7
    medial, 7
  in knee
    lateral, 293, 304
    medial, 293, 304
  occipital, 484
Cone of light, 521
Conjoint tendon, 138, 140, 148
Conjunctiva, 509, 516
Conjunctival fornix, 509
Conjunctival sac, 509
Conoid tubercle, 388
Constrictor
  inferior, 540, 554–555, 563, 581
  middle, 528, 540, 554–555, 578, 581
  superior, 528–529, 554, 578, 581–582
Conus arteriosus, 97
Conus elasticus, 559
Conus medullaris, 13, 45
Coraco-acromial ligament, 388, 390
Coracobrachialis, 8, 408–409
Coracoclavicular ligament, 388
Coracohumeral ligament, 390
Coracoid process, 6, 62, 70–71, 385–386, 395
Cornea, 509, 516
Corniculate cartilage, 559
Corniculate tubercle, 553, 560–561
Cornua, 31
Coronal plane, 2–3
Coronal suture, 480, 483
Coronary artery(ies), 103
  left, 94, 100, 102, 104
    anterior interventricular branch, 102–104
    circumflex branch, 102–104
    diagonal anterior interventricular branch, 103
  left-dominant system, 104
  right, 94, 100, 102–103
    marginal branch, 103
    posterior interventricular branch, 103
    sinu-atrial nodal branch, 103
  right-dominant system, 103
  variations, 103–104
Coronary ligament, 172
  anterior, 173
  posterior, 173
Coronary sinus, 94, 96, 99, 102
Coronary sulcus, 94, 100–102
Coronary vessels, 102

Coronoid fossa, 406, 420, 423
Coronoid process, 420, 480, 572
Corpus albicans, 242
Corpus callosum, 495
Corpus cavernosum, 222, 234, 238, 240, 260
Corpus luteum, 242
Corpus spongiosum, 222, 234–235, 238, 240, 260
Corrugator supercilii, 504
Costal cartilage, 64–65, 72
Costal facet
  inferior, 32
  superior, 32
  transverse, 32
Costal groove, 72
Costal margin, 4, 62, 125, 134, 394
Costal pleura, 80, 114
Costocervical trunk, 46, 546, 548–549
  left, 74
  right, 74
Costochondral junction, 67
Costoclavicular ligament, 388
Costodiaphragmatic recess, 63, 79–81
Costomediastinal recess, 79–81
Costotransverse ligament, 32
Costovertebral joint, 66
Costovertebral ligament, radiate, 32
Costoxiphoid ligament, 67
Cranial, as anatomical direction, 2
Cranial cavity, 485
Cranial fossa, 485
Cranial nerves, 498–499, 584–585
Cremasteric muscle, 137–138, 140, 147–148, 234, 238
Cremasteric vessels, 148
Cribriform plate, 485
Crico-arytenoid
  lateral, 561
  posterior, 555, 561
Cricoid arch, 560, 563
Cricoid cartilage, 552, 554, 558–561, 563
Cricopharyngeus, 563, 565
Cricothyroid, 541, 554, 563
Cricothyroid articular capsule, 86
Cricothyroid joint, 558
Cricothyroid ligament, 536, 563
Cricothyroid muscle, 561
Cricotracheal ligament, 558
Cricovocal membrane, 559
Crista galli, 485, 566–568
Crista terminalis, 96
Crown, of tooth, 575
Cruciate ligaments, 323–325
Cruciform ligament, 444
Crura of antihelix, 520
Crus of clitoris, 241, 262
Crus of diaphragm
  left, 119, 183, 185
  right, 73, 119, 183, 185
Crus of penis, 240, 260
Cubital fossa, 4, 384, 424
Cubital nodes (supratrochlear or epitrochlear), 12, 415, 457
Cubital vein, median, 11, 411, 424, 457
Cuboid, 330–332
  tuberosity of, 330
Cuneiform
  intermediate, 330–332
  lateral, 330, 332
  medial, 330–332
Cuneiform cartilage, 559
Cuneiform tubercle, 553, 560–561
Cuneocuboid ligament, 352
Cuneonavicular ligaments, 352
Cuneus, 495
Cupula, 80
Cutaneous nerve(s), 17
  arm, 400, 414, 418–419, 424, 434, 458–459
  femoral lateral, 271
  femoral posterior, 252, 271
  lateral
    of thigh, 196–197
    T3-T11, 125
    T7-T11, 145
  lateral cutaneous branch of, 76
  legs, 347
  perforating, 252
  perineal, 271
  sural, 347
  thoracic, 125
CI vertebra, 7, 21, 23–25, 499
  posterior ramus of, 43
  transverse process of, 43
CII vertebra, 7, 21, 23–24, 50, 537
  posterior ramus of, 43
  spinous process of, 23, 40–41, 43
  transverse process of, 43
CIII vertebra, 23, 537
  posterior ramus of, 43
  spinous process of, 23
CIV vertebra, 23–24, 537
CV vertebra, 22–24, 537
CVI vertebra, 23, 537
CVII vertebra, 6, 537
  spinous process of, 71
Cisterna chyli, 268–269
Cystic artery, 157, 161, 179
Cystic duct, 163, 177–178

D
Dartos fascia, 234, 238
Deciduous teeth, 573
Decussation of pyramids, 499
Deep artery
  of penis, 240
  of thigh, 10, 299, 312, 315–316
Deep nodes, 12
Deep palmar arch, 10
Deep vein, of thigh, 11, 316
Deltoid, 4–5, 8–9, 37, 394–395, 408, 412, 540
Deltoid fascia, 540
Deltoid ligament of ankle, 336
Deltoid tuberosity, 389
Demifacet for articulation, vertebral, 22
Dens, 24
Denticulate ligament, 49
Dentine, 575
Depressor anguli oris, 504–505
Depressor labii inferioris, 504–505
Depressor septi, 504
Dermatomes
  abdominal, 205
  abdominal wall, 145
  arms, 459
  in back, 53
  legs, 366–367
  perineal, 271
  thoracic, 125
Descending colon, 152, 157, 166, 186
Detrusor muscle, 230
Diaphragm, 73, 79
  central tendon of, 73, 185
  in coronal plane, 3
  costal, 73
  crus of
    left, 119, 183, 185
    right, 73, 119, 183, 185
Diaphragm (*Continued*)
  features of, 73
  inferior view, 185
  left dome of, 63
  lumbar part, 73
  positioning of, 185
  right dome of, 63
Diaphragma sellae, 492, 498
Diaphragmatic nodes, 77
Diaphragmatic pleura, 80, 114
Diaphragmatic surface of heart, 94
Diencephalon, 495
Digastric, 541
Digital arteries
  dorsal, 346, 354–355, 456
  palmar, 448–450, 454
  plantar, 361–362
Digital nerves
  dorsal, 455
  palmar, 448, 451, 455–456
  plantar, 361
Digital phalanx, 330
Digital veins
  dorsal, 457
  palmar, 457
Digiti minimi, 356
Dilator pupillae, 516
Directions, anatomical, 2, 573
Distal, as anatomical direction, 2, 573
Dorsal hood, 363
Dorsalis pedis artery, 10, 346, 354–355
Dorsum
  of foot, 2, 4, 353
  of hand, 2, 452
  of nose, 566
Dorsum sellae, 485, 534
Ductus deferens, 147–149, 222, 231, 237–238
  ampulla of, 234, 236–237, 240
  artery of, 239
  left, 234
  positioning, 235
  right, 234
Duodenal cap, 162
Duodenal papilla
  major, 163, 177
  minor, 177
Duodenojejunal flexure, 163, 165, 177
Duodenum, 157, 162–163
  ascending part, 162–163
  in coronal section of abdomen, 156
  descending part, 162–163, 186
  imaging, 163, 169
  inferior part, 162–163
  in situ, 162
  superior part, 162–163
  suspensory muscle of, 163
  vasculature of, 179
Dural arteries, 492
Dural nerves, 492
Dural partitions, 490
Dural sheath, 509

E
Ear(s), 521
  imaging, 525
  internal, 520–521, 524
  left, 94, 97, 99, 101
  middle, 522
  right, 96–97
  surface anatomy, 520
Efferent ductules, 239
Efferent lymphatic vessel, 12

Ejaculatory duct, 234, 236
  beginning of, 237
  opening of, 235
Elbow joint, 7, 385, 420–423
Emissary veins, 533, 576
Enamel (dental), 575
Endocardium, 93
Endometrium, 242
Endoscopy, GI tract, 169
Endothoracic fascia, 72
Epicardium, 124
Epicondyle
  in elbow
    lateral, 6–7, 386, 406, 420, 422, 432–433
    medial, 6–7, 386, 406, 420, 422, 432–433
  in knee
    lateral, 293, 304
    medial, 304
Epicranial aponeurosis, 504–505
Epididymis, 147
  appendix of, 238
  body of, 239
  head of, 149, 234, 239
  tail of, 239
Epigastric artery
  inferior, 142–143, 147, 222, 224, 246–247
    left, 149
    right, 148
  superficial, 143, 238, 299, 312
  superior, 73, 142–143, 185
    right, 74
Epigastric region, 135
Epigastric vein
  inferior, 142, 147, 222, 224, 246–247
    left, 149
    right, 148
  superficial, 238, 364
  superior, 142
    right, 75
Epigastric vessels, inferior, 141
Epiglottis, 552, 555, 558–561, 580
Epiphyseal plate, 298
Episcleral space, 516
Epitrochlear nodes, 415, 457
Epitympanic recess, 521, 523
Epoöphoron, 243
Erectile muscles
  female, 262
  male, 260
Erectile tissue
  female, 262–263
  male, 260–261
Erector spinae, 9, 36, 40–42, 52, 137
Esophageal artery, 157
Esophageal branches, 160
Esophageal hiatus, 73, 183
Esophageal impression, on liver, 173
Esophageal mucosa, 158
Esophageal plexus, 116, 118
Esophageal varices, 182
Esophageal vein, 182
Esophagus, 82, 88, 552–553
  abdominal, 158
  in axial plane, 3
Ethmoidal artery
  anterior, 515, 569
  posterior, 515, 569
Ethmoidal bulla, 566–567
Ethmoidal cells, 566
Ethmoidal foramen
  anterior, 508
  posterior, 508
Ethmoidal nerve, 492, 513, 569
Ethmoid bone, 477, 485–486, 508, 534, 567
Excretory duct of lacrimal gland, 510
Extensor carpi radialis brevis, 412, 435
Extensor carpi radialis brevis tendon, 440
Extensor carpi radialis longus, 9, 412, 435–436
Extensor carpi radialis longus tendon, 440
Extensor carpi ulnaris, 412
Extensor carpi ulnaris tendon, 440
Extensor digiti minimi, 435
Extensor digiti minimi tendon, 440
Extensor digitorum, 9, 412, 435
Extensor digitorum longus, 8, 343–345
Extensor digitorum tendon, 440
Extensor hallucis longus, 8, 345
Extensor hood, 363
Extensor indicis, 9, 436, 440
Extensor pollicis brevis, 9, 435–436
Extensor pollicis brevis tendon, 440
Extensor pollicis longus, 9, 436
Extensor pollicis longus tendon, 440
Extensor retinaculum, 356, 435
Extensor tendons, 292
Extradural fat, 47
Extraperitoneal fascia, 137, 141, 148
Eyeball, 516
Eyelash, 509
Eyelid, 509–510
  inferior, 508
  superior, 508
Eyes, 6
  imaging, 517–519
  movements, 514
  muscles, 512
  nerves, 513, 516
  sagittal section, 509
  vasculature, 515

F
Facial artery(ies), 10, 500, 506, 546
  transverse, 506–507, 510
Facial canal, prominence of, 522
Facial lymphatics, 506
Facial muscles, 504–505
Facial nerve, 499, 506–507, 511, 521–522, 532, 585
Facial nodes, 506, 550
Facial surface anatomy, 508
Facial vasculature, 506
Facial vein, 11, 506, 515, 533, 539
  common, 539
  deep, 507, 557
  transverse, 506–507
Falciform ligament, 141, 151, 164
False ribs, 64
Fat, extradural, 47
Femoral artery, 142–143, 147–148, 238, 315–316, 327
  lateral circumflex, 302, 312, 315
    ascending branch of, 299, 311–312
    descending branch of, 10, 299, 314–315
    transverse branch of, 10, 299, 311–312
  left, 192
  medial circumflex, 299, 302–303, 312, 314–315
Femoral branch, 196
Femoral cutaneous vein, 364
Femoral head, ligament of, 297–298
Femoral nerve, 13, 196, 303, 310–311
  intermediate cutaneous branch, 197
  medial cutaneous nerve from, 197
  muscular branches, 311
Femoral nodes, 12
Femoral sheath, 310
Femoral triangle, 310
Femoral vein, 11, 142–143, 147–148, 238, 316
Femur, 6–7, 293, 295
  distal end, 304
  fovea of, 296
  greater trochanter of, 226
  head of, 296–298
  lesser trochanter of, 226
  neck of, 295–296, 298
  proximal, 296
  shaft of, 296
Fibrocartilaginous joint, 67
Fibroelastic membrane, 559
Fibromuscular stroma, 232, 235
Fibrous capsule, of kidney, 188
Fibrous pericardium, 92–93, 124
Fibrous ring, of aortic valve, 100
Fibrous trigone, 100
Fibula, 7, 329
  head of, 4, 6, 292–293
  proximal end, 304
Fibular artery, 10, 342, 346
  circumflex, 327
Fibular collateral ligament, 308, 320
Fibularis brevis, 340, 343–345
Fibularis brevis tendon, 9, 292, 336, 351
Fibularis longus, 8–9, 300, 340, 343–345
Fibularis longus tendon, 292, 336, 351
Fibularis tertius, 345
Fibular nerve, 13
  common, 314–315, 342, 346
  deep, 346–347, 354–355
  superficial, 346–347, 354
Fibular retinaculum, 336
Fibular trochlea, 330–331
Fibular vein, posterior, 11
Filiform papillae, 580
Filum terminale, 44–45
Fimbriae, 242
Flank
  left, 135
  right, 135
Flexor carpi radialis, 8, 408, 424, 431–432
Flexor carpi radialis tendon, 431–432, 440, 444–445
Flexor carpi ulnaris, 9, 412, 424, 431–432
Flexor carpi ulnaris tendon, 432, 444–445
Flexor digiti minimi, 444
Flexor digiti minimi brevis, 357–360, 446–447
Flexor digitorum brevis, 357–358
Flexor digitorum longus, 9, 341, 357
Flexor digitorum longus tendon, 351
Flexor digitorum profundus, 8, 433, 436
Flexor digitorum profundus tendons, 431–432, 440, 444–445
Flexor digitorum superficialis, 431–433
Flexor digitorum superficialis tendons, 431–432, 440, 444–446
Flexor hallucis brevis, 357–360
Flexor hallucis longus, 9, 341, 360
Flexor hallucis longus tendon, 351
Flexor pollicis brevis, 444, 446–447
Flexor pollicis longus, 8, 431–433
Flexor pollicis longus tendon, 431–432, 440, 444–445
Flexor retinaculum, 363, 431–432, 440, 444–445
Floating ribs, 64
Foliate papillae, 580
Foot
  arteries, 354–355, 361–362
  bones of, 293, 330–333
  dorsum of, 2, 4, 353
  innervation, 354–355, 361–362
  joints, 333
  ligaments, 351–352
  median longitudinal arch, 331
  muscle attachments, 350

Foot (*Continued*)
musculature, plantar, 357–360
plantar surface of, 2
surface anatomy, 353
transverse arch, 331
Foramen lacerum, 484, 572
Foramen magnum, 484–485, 500
Foramen ovale, 484–485, 520, 527, 529, 534
valve of, 98
Foramen rotundum, 485, 534
Foramen spinosum, 484–485, 527, 532–533
Foramen transversum, 24
Foregut, innervation of, 201–203
Fornix, 495
Fossa ovalis, 96
limbus of, 96
Fourchette, 257
Fovea centralis, 516
Fovea of femur, 296
Free taenia, 168
Frontal bone, 6, 477–478, 480, 483, 508, 527, 567
Frontal crest, 485
Frontalis, 8
Frontal lobe, 495, 502
Frontal nerve, 513
Frontal operculum, 494
Frontal process of maxilla, 478
Frontal process of zygomatic bone, 526
Frontal sinus, 552, 566–568
Frontal suture, 477–478
Frontobasal artery, lateral, 502
Frontonasal duct, 567
Fundiform ligament of penis, 238, 240, 260
Fundus, of bladder, 232
Fungiform papillae, 580

G
Gallbladder, 152–153, 163, 176–177
body of, 173, 177
in coronal plane, 3
in coronal section of abdomen, 156
neck of, 173, 177
positioning of, 177
Ganglion impar, 200, 253–254
Gastric artery(ies)
left, 157, 160, 179
right, 157, 160, 179
short, 157, 160, 179
Gastric canal, 158
Gastric folds, 158
Gastric impression
of liver, 173
of spleen, 159
Gastric mucosa, 158
Gastric vein
left, 180–181
right, 181
short, 180–181
Gastric vessels, short, 159
Gastrocnemius, 5, 8–9, 292, 300, 305, 307, 340, 343–344
Gastroduodenal artery, 157, 160–161, 163, 179
branches of, 160
Gastroesophageal junction, 169
Gastrointestinal tract, imaging, 169
Gastro-omental artery
left, 157, 159–160, 179
right, 157, 160–161
Gastro-omental vein
left, 159, 179–181
right, 181
Gemellus inferior, 9, 301, 313
Gemellus superior, 9, 301, 305, 313
Genicular artery
descending, 312, 315, 327
articular branch, 311–312, 315
saphenous branch, 311–312, 315, 327
inferior lateral, 312, 314–315, 327, 342
inferior medial, 314–315, 327, 346
medial genicular, 312
superior lateral, 311–312, 314–315, 327, 342
superior medial, 314–315, 327, 342
Geniculate ganglion, 520, 522, 535
Genioglossus, 552, 578, 580–581
Geniohyoid, 552, 578, 580
Genital branch, 196
Genitofemoral nerve, 196–197
femoral branch of, 148, 197, 303
genital branch of, 147–149, 151, 238
Gingiva, 575, 577
Glabella, 478
Glans of clitoris, 224, 241, 256
Glans penis, 4, 20, 212, 234, 240, 250, 260
Glenohumeral joint, 390–392, 399
Glenohumeral ligament, 390
Glenoid cavity, 387
Glenoid labrum, 398
Glossoepiglottic fold, 580
Glossopharyngeal nerve, 498–499, 532, 543–544, 556, 579, 585
Gluteal artery
inferior, 192, 246, 302–303, 312, 314–315
superior, 192, 246, 248, 264, 299, 302, 312, 314–315
deep branch of, 302–303, 314–315
superficial branch, 303, 314–315
Gluteal fold, 5, 213, 215, 292
Gluteal line
inferior, 294
posterior, 294
Gluteal nerve
inferior, 252, 254, 265, 302
superior, 252–254, 265, 302–303, 315
Gluteal region, 300–302
Gluteal surface, 215, 220, 294
Gluteal tuberosity, 296
Gluteal vein
inferior, 302
superior, 247–248, 264, 302
right, 193
Gluteus maximus, 9, 255–256, 292, 301–302, 305, 307, 316
Gluteus medius, 9, 301–302, 305, 307
Gluteus minimus, 301, 305
Gonadal vein, left, 180
Gonadal vessels, 190
left, 184
right, 184, 190
Gracilis, 8–9, 301, 306–307, 309–310, 316, 340
Gracilis tendon, 309
Granular foveolae, 483
Gray ramus communicans, 78, 253, 403
Greater omentum, 152
Greater trochanter, 6–7
Greater tubercle, 6–7
Great saphenous vein, 11
Great vessels, adventitia of, 93
Groin
left, 135
right, 135
Gut tube, 137

H
Hair cells
inner, 524
outer, 524
Hallucis longus, extensor, 8
Hamate, 426, 428, 440
Hamulus, 484
Hands
arteries, 448–450, 454
bones, 385, 426, 428
dorsal hoods, 453
dorsum of, 452
imaging, 427
joints, 429
ligaments, 429
lymphatics, 457
muscle attachments, 442
muscles, 446–447
nerves, 448–449, 451, 455
surface anatomy, 384, 443, 452
tendon sheaths of, 444
veins, 457
Hard palate, 484, 552, 554, 581
Haustra of colon, 166
Head
nerves, 586
surface anatomy, 476
Head of fibula, 4
Heart
anterior surface of, 94
base of, 95
chambers of, 101
computed tomography of, 94
conduction system of, 105
in coronal plane, 3
diaphragmatic surface of, 95
innervation of, 107
visceral afferents, 127
visceral motor, 126
posterior view of, 94–95
sounds, 106
valves of, 101
vasculature, 102–104
visceral afferents from, 127
Helicotrema, 524
Helix, 520
Hemi-azygos vein, 75, 82, 119, 185
accessory, 47, 75, 83, 116
Hemorrhoids, 182
Hepatic artery
common, 10, 157, 160–161, 179
distribution of, 179
left, 157, 179
proper, 156–157, 160, 163
left branch, 174
right branch of, 174
right, 157, 179
Hepatic duct
common, 163, 174, 177–178
in coronal section of abdomen, 156
left, 177–178
right, 177, 179
Hepatic vein(s), 11, 160, 184, 193
arrangement of, 174
in coronal section of abdomen, 156
entering inferior vena cava, 174
intermediate, 174
left, 174
right, 174
Hepatoduodenal ligament, 164
Hepatopancreatic ampulla, 177
Hernias, inguinal, 150
direct, 150
indirect, 150
Hesselbach's triangle, 150–151
Hiatus semilunar, 567–568
Hilum, 82, 110
of spleen, 159

Hindgut, innervation of, 201–203
Hip joint, 7, 293, 297–298
  arterial supply, 299
  ligaments, 309
Hoods, dorsal, of hand, 453
Horizontal fissure, 81–82
Horizontal plane, 2
Humeral artery
  anterior circumflex, 10, 395, 400–402, 410, 414
  posterior circumflex, 395, 400–402, 410, 414
Humeral ligament, 390
  transverse, 396, 399
Humeral nodes, 415
Humeral nutrient artery, 402, 410, 414
Humeral vein
  anterior circumflex, 411
  posterior circumflex, 411
Humeroradial joint, 420
Humero-ulnar joint, 420
Humerus, 6–7, 36–37, 70, 385–386
  distal end, 406
  greater tubercle, 389
  head of, 389
  lesser tubercle, 389
  middle facet, 389
  neck of, 389
  proximal, 389
  superior facet, 389
Hyaline cartilage, 32
Hyaloid canal, 516
Hymen, 257
Hyoepiglottic ligament, 558–559, 580
Hyoglossus, 554, 578–579
Hyoid bone, 537, 552, 560–561
Hypochondrium
  left, 135
  right, 135
Hypogastric nerve, 272
  left, 253
  right, 199–200, 253–254
Hypogastric plexus, 199, 254
  inferior, 201, 253–254, 272
  superior, 199–200, 254, 272
Hypoglossal canal, 484–485
Hypoglossal nerve, 498–499, 542, 545, 579, 585
Hypophyseal arteries, 500
Hypophyseal fossa, 485, 534, 567
Hypothalamic sulcus, 495
Hypothalamus, 495
Hypothenar eminence, 384, 443, 446
Hypothenar muscles, 8, 434

I
Ileal artery, 164, 170
Ileal vein, 164, 180–181
Ileocecal fold, 168
Ileocecal fold flaps, 168
Ileocecal junction, 168
  in coronal section of abdomen, 156
Ileocolic artery, 157, 170
  in coronal section of abdomen, 156
Ileocolic vein, 181
  in coronal section of abdomen, 156
Ileum, 164–166, 168
  in coronal section of abdomen, 156
  imaging, 165
Iliac artery
  common, 222, 224, 311–312
    left, 10, 251
    retroperitoneal, 186
    right, 184, 190, 192, 246–247
Iliac artery (*Continued*)
  deep circumflex, 142–143, 149, 192, 246, 299, 312
  external, 143, 148, 192, 222, 224, 246–247, 299, 311
    left, 10, 190
    retroperitoneal, 186
    right, 264
  internal, 192, 198, 222, 224, 246, 264, 299
    anterior trunk, 264
    left, 10, 190
    right, 190, 248
  superficial circumflex, 142–143, 299, 312
Iliac crest, 5, 7, 20, 36, 39–41, 212–216, 220, 226–227, 295
  tubercle of, 294
Iliac fossa, 196, 212, 214, 216, 294–295
Iliac nodes, 12
  common, 198, 268–269
  external, 198, 268–270
  internal, 198, 268–270
Iliac spine
  anterior inferior, 220–221, 295
  anterior superior, 4, 134, 218, 220–221, 226–227, 293, 295
  posterior inferior, 294
  posterior superior, 7, 40, 220, 226–227, 293–295
Iliac tuberosity, 294
Iliacus, 147, 151, 164, 183, 222, 224, 231, 305–306, 308, 310–311
Iliacus fossa, 310
Iliac vein(s)
  common, 193, 222, 224, 251
    left, 11, 190
    right, 247
  deep circumflex, 142, 149
  external, 11, 148, 182, 222, 224, 246–247
    left, 184, 190, 193
    right, 190, 193, 264
  internal, 11, 222, 224, 247, 251, 264
    anterior trunk, 264
    left, 248
    right, 193
  superficial circumflex, 142, 364
Iliococcygeus, 227–229, 231, 245, 258, 260, 262
Iliocostalis, 40, 71
Iliocostalis cervicis, 40, 71
Iliocostalis lumborum, 40
Iliocostalis thoracis, 40
Iliofemoral ligament, 226, 299
Iliohypogastric nerve, 53, 144, 196, 303
  anterior cutaneous branch of, 145, 197
  lateral cutaneous branch of, 144, 197
Ilioinguinal nerve, 144, 148, 196–197, 238, 271, 303
Iliolumbar artery, 192, 246, 248
  iliac branch of, 192
Iliolumbar ligament, 218
Iliolumbar vein, 248
Iliopsoas, 8, 305, 308, 316
Iliopubic eminence, 216
Iliotibial tract, 8–9, 292, 300, 306, 316, 327
Ilium, 6, 294
  arcuate line, 216, 220–221
  gluteal surface of, 213, 220
Imaging, of spinal cord, 50–51
Incisive canal, 567
Incisive fossa, 484, 572, 581
Incisive nerve, 531, 576
Incisors, 573
Incus, 521–523
  ligament of, 523
Inferior, as anatomical direction, 2
Infraclavicular nodes, 415
Infraglenoid tubercle, 387
Infraglottic space, 560
Infrahyoid muscles, 538
Infraorbital artery, 507, 510, 535, 576
Infraorbital fissure, 534
Infraorbital foramen, 478, 480, 508, 534
Infraorbital groove, 508
Infraorbital nerve, 510, 535, 569, 576
Infraorbital vein, 507, 515, 576
Infrapatellar bursa, 326
Infraspinatus muscle, 9, 37–39, 52, 398–399, 412
Infraspinous fossa, 387
Infratemporal bones, 527
Infratemporal crest, 527
Infratemporal fossae, 526, 528–529
  arteries, 533
  nerves, 532
  veins, 533
Infratrochlear artery, 510
Infratrochlear nerve, 503, 510, 513
Infratrochlear vein, 510
Inguinal canal, 146, 148–149, 234
Inguinal hernias, 150
  direct, 150
  indirect, 150
Inguinal ligament, 138, 143, 148, 151, 183, 212, 214, 219, 238, 308, 310
  surface, 134
Inguinal nodes, 12
  deep, 268–269
  inferior superficial, 268–269
  superficial, 365
  superolateral superficial, 269
  superomedial superficial, 268–269
Inguinal region
  female, 146–147
  male, 146–147
Inguinal ring
  deep, 146, 148–149, 151
  superficial, 138, 146, 148, 234, 238
Inguinal triangle, 151
  right, 150
Inion, 482
Insula, 502
Interarytenoid fold, 560
Interarytenoid notch, 553, 555, 560
Intercarpal ligament, 426, 429
Interchondral joint, 67
Interclavicular ligament, 388
Intercondylar fossa, 326
Intercondylar line, 304
Intercostal artery(ies), 72, 78, 143
  anterior, 74
    collateral branch of, 74
  left supreme, 75, 118
  posterior, 46, 74
    collateral branch of, 74
    left, 46
    right, 46
  right supreme, 74
  supreme, 548–549
Intercostal membrane, external, 70, 72
Intercostal muscle, 68, 72
  external, 8–9, 52, 71–72, 396
  innermost, 52, 72
  internal, 8, 52, 71–72
Intercostal nerve(s), 13, 32, 72, 76, 78, 119, 202
  anterior cutaneous branch of, 76, 125, 145
  lateral cutaneous branch of, 76, 144
  sixth thoracic, 69
  small collateral branch of, 76
  thoracic, 69

Intercostal nodes, 77
Intercostal space, 64
Intercostal vein, 72
  left superior, 75
  posterior, 47
Intercostal vessels, 142
Intercostobrachial nerve, 403–404, 418
Intercuneiform ligaments, 352
Intergluteal cleft, 5, 20, 213, 215
Intermaxillary suture, 572
Intermediate nerve, 520–522
Interossei muscles, 360
Interosseous artery
  anterior, 434
  common, 410, 434, 437
  posterior, 434, 437
  recurrent, 414, 434, 437
Interosseous membrane, 326, 433
Interosseous nerve, 434, 437
Interphalangeal joints, 333, 429, 453
Intersphincteric groove, 231
Interspinalis cervicis, 43
Interspinous ligament, 35
Interthalamic adhesion, 495
Intertragic notch, 520
Intertransversarius, 41
Intertrochanteric crest, 293, 295–296, 299
Intertrochanteric line, 293, 295–296
Intertubercular plane, 135
Intertubercular sulcus, 386, 389
Interureteric fold, 233
Interventricular septum, 124
Interventricular sulcus, anterior, 94, 101
Interventricular vein, anterior, 102
Interventricular vessels, anterior, 99
Intervertebral disc, 21, 24, 32
  LV-SI, 218–219
Intervertebral disc problems, 33–34
Intervertebral disc protrusion, 33
Intervertebral foramen, 26, 32, 48
Intervertebral vein, 47
Intestinal nodes, 12
Intestinal trunk, 198
Intestine
  large, 12, 166
    imaging, 167
    surface projections, 166
  small, 152–153, 186
    in coronal plane, 3
    lymph nodes in, 12
    in sagittal plane, 3
Intra-articular ligament, 66
Intraparietal sulcus, 494
Investing layer, 538
Iridocorneal angle, 516
Iris, 508–509
Ischial ramus, 294–295
Ischial spine, 7, 212–221, 227–229, 293, 295
Ischial tuberosity, 7, 213, 215, 220, 229, 255–256, 258, 294, 297, 299, 301
Ischio-anal fossa, 151, 231
Ischiocavernosus, 240, 255–256, 260
Ischiococcygeus, 227–229
Ischiofemoral ligament, 226, 299
Ischiopubic arch, 259
Ischiopubic ramus, 220, 229
Ischium, 6, 294
  ramus of, 212–216, 220

J
Jejunal artery, 164, 170
Jejunal vein, 164, 180–181
Jejunum, 164–165, 186
  in coronal section of abdomen, 156
  imaging, 165
Joint(s)
  acromioclavicular, 62, 385, 388
  ankle, 7, 335
  atlanto-axial, 23
  atlanto-occipital, 499, 537
  calcaneocuboid, 333
  carpometacarpal, 426, 429
  clavicular, 388
  costovertebral, 66
  cricothyroid, 558
  elbow, 7, 385, 420–423
  fibrocartilaginous, 67
  foot, 333
  in hand, 429
  hip, 7, 293, 297–298
  humeroradial, 420
  humero-ulnar, 420
  interchondral, 67
  interphalangeal, 333, 429, 453
  knee, 7, 318–319, 322–325
  lumbosacral, 218
  manubriosternal, 64, 67
  metacarpophalangeal, 429
  metatarsophalangeal, 292, 333
  midcarpal, 426
  radio-ulnar, 420, 425
  sacro-iliac, 6, 31, 214, 219, 221, 227, 294–295
  shoulder, 7, 385–386
  spinal, 35–36
  sternoclavicular, 62, 386, 388
  sternocostal, 64, 66–67
  subtalar, 333
  synovial, 66–67
  talocalcaneonavicular, 333
  tarsometatarsal, 333
  temporomandibular, 528–530
  tibiofibular, 318
  wrist, 7, 385, 425–427
  xiphisternal, 64, 67
  zygapophyseal, 24, 28–29
Jugular foramen, 484–485
Jugular notch, 62, 64, 522
Jugular trunk, 77, 551
Jugular tubercle, 485
Jugular vein
  anterior, 11, 539
  external, 11, 506, 533, 539, 557
  internal, 11, 75, 77, 82, 110, 506–507, 533, 539, 557
    left, 101, 109–110, 564
    right, 101, 109, 395, 565
Jugulodigastric node, 506, 550–551
Jugulo-omohyoid node, 506, 550–551

K
Kidney(s)
  anterior surface structures, 186
  fascia surrounding, 186
  fat surrounding, 186
  fibrous capsule of, 188
  gross structure of, 188
  hilum of, 188
  imaging, 189
  inferior pole of, 188
  lateral border, 188
  left, 160, 163, 186
  medial border, 188
  posterior surface structures, 186
  retroperitoneal position of, 186
Kidney(s) (*Continued*)
  right, 160, 163
    anterior surface, 188
    internal structure, 188
    retroperitoneal, 186
  superior pole of, 188
  surface projection of, 186
  vasculature, 190–191
  visceral sensory diagram, 204–205
Knee
  arteries, 327
  bones of, 293
  bursa, 326
  capsule, 326–327
  ligaments of, 320–321
  surface, 327
Knee joint, 7, 293, 318–319, 322–325

L
Labial artery
  inferior, 506
  posterior, 266
  superior, 506
Labial vein
  inferior, 506
  posterior, 266
  superior, 506
Labium majus, 224, 257
Labium minus, 224, 256–257
Labyrinthine artery, 500
Lacrimal apparatus, 510
Lacrimal artery, 510, 515
Lacrimal bone, 477, 480, 486, 508, 534
Lacrimal canaliculi, 510
Lacrimal caruncle, 510
Lacrimal crest, 510
Lacrimal fold, 510
Lacrimal gland, 510–511
Lacrimal lake, 508
Lacrimal nerve, 503, 510–511, 513, 535
Lacrimal papilla, 510
Lacrimal punctum, 510
Lacrimal sac, 509
Lacrimal sac fossa, 512
Lactiferous ducts, 68
Lactiferous sinuses, 68
Lacunar ligament, 148, 151, 217
Lambda, 483
Lambdoid suture, 480, 482–483
Large intestine, 12, 166–167
  imaging, 167
  surface projections, 166
Laryngeal artery
  inferior, 565
  superior, 546
Laryngeal cartilage, 559
Laryngeal cavity, 560
Laryngeal inlet, 552–553, 560
Laryngeal nerve, 562
  external, 562
  internal, 562
  left recurrent, 107, 110, 556, 562, 564
  right recurrent, 88, 107, 110, 556, 562, 564
  superior, 543, 556, 562
Laryngeal saccule, 560
Laryngeal vein, superior, 557
Laryngeal ventricle, 560
Laryngopharynx, 552–553
Larynx, 4
  external features, 558
  muscles, 561
  nerves, 562
  surface anatomy, 558, 563

Lateral, as anatomical direction, 2
Lateral ligament, 528
Latissimus dorsi, 5, 36–38, 137–138, 394–395, 408
Leg
  arteries, 342, 346
  bones, 293
  dermatomes, 366–367
  imaging, 349
  ligaments, 322
  lymphatics, 365
  menisci, 322–323
  muscle attachments, 339
  muscles, 340–341, 343–345
  nerves, 342, 346–347
  superficial muscles, 340
  surface anatomy, 292
  transverse section, 348–349
  veins, 364
Lens, 509, 516
Lesser curvature, of stomach, 158
Lesser omentum, 154, 164
Lesser trochanter, 6–7
Levator anguli oris, 504–505
Levator ani, 151, 222, 224, 227–229, 231, 235, 259–260
Levatores costarum, 41
Levator labii superioris, 504–505
Levator labii superioris alaeque nasi, 504–505
Levator palpebrae superioris, 509, 512
Levator palpebrae superioris tendon, 504, 509–510
Levator scapulae, 9, 36–39, 540–541
Levator veli palatini, 522–523, 529, 554–555, 581
Ligamenta flava, 35
Ligamentum arteriosum, 92, 94, 97, 109–110, 116
Ligamentum nuchae, 20, 35–36, 39–40
Ligamentum venosum, fissure for, 173
Limbus, of fossa ovalis, 96
Linea alba, 134, 136–137, 141
Linea aspera, 293, 295–296
Lingual artery, 500, 507, 546, 579, 582
Lingual glands, 582
Lingual gyrus, 494–495
Lingual nerve, 528, 532, 576–577, 580, 582
Lingual tonsil, 12, 552, 580
Lingual vein
  deep, 579, 582
  dorsal, 579
Lingula, 82–83, 529, 572
Lip, lower, 580
Liver, 172, 186
  anterior medial segment V, 175
  anterior surface, 172
  caudate lobe of, 173, 175
  in coronal plane, 3
  in coronal section of abdomen, 156
  inferior border of, 164, 172
  lateral segment II, 175
  lateral segment III, 175
  left lobe of, 152–153, 164
  location of, 172
  medial segment IV, 175
  posterior lateral segment VII, 175
  posterior surface of, 173
  quadrate lobe, 173
  right anterior lateral segment VI, 175
  right lobe of, 152–153, 172
  round ligament of, 151, 153, 164, 172
  segments of, 175
  surface projection of, 172
  vessels of, 174
  visceral surface of, 173
L1 nerve, 43, 53, 144, 148
  anterior ramus, 303
  lateral cutaneous branch of, 144
L2 nerve, anterior ramus, 303
L3 nerve, anterior ramus, 303
L4 nerve, 34
L5 nerve, 34
Lobule, 520
Longissimus, 40, 71
Longissimus capitis, 40, 43
Longissimus cervicis, 40
Longissimus thoracis, 40
Longitudinal axis, 2
Longitudinal ligament, anterior, 218–219
Longitudinal muscle
  of esophagus, 554–555
  of rectum, 231
  of tongue, 580
Longus capitis, 540–541
Longus colli, 541
Lumbar arteries, 192
Lumbar ganglia, 200
Lumbar meninges, 48
Lumbar nerves, 34, 44
Lumbar node, 198, 268–269
Lumbar plexus, 13, 196
  cutaneous distribution, 197
Lumbar triangle, 37
Lumbar trunk
  left, 198
  right, 198
Lumbar vein, ascending, 119
Lumbar vertebrae, 21–22, 27–30
Lumbosacral articular surface, 294
Lumbosacral joint, 218
Lumbosacral ligament, 218
Lumbosacral trunk, 196, 252–253, 303
Lumbricals, 357–358, 445–446
Lunate, 426, 428
Lunate surface, 297
Lung(s)
  apex of, 88
  left, 79, 83
  right, 79, 82
Lunule, 100
LI vertebra, 21
LIII vertebra, 22
LIV vertebra, 29–30, 33
LV vertebra, 21, 27–28, 31, 219, 222, 224, 294
Lymphatic drainage, 551
Lymphatic duct, right, 12
Lymphatic system, 12
  in abdomen, 198
  in abdominal wall, 143
  in arms, 415, 457
  facial, 506
  in hands, 457
  in legs, 365
  in neck, 550–551
  in perineum, 270
    female, 269
    male, 268
  in thoracic wall, 77
Lymphatic trunk(s), 69
  termination of, 77

M
Malleolar artery
  anterior lateral, 346, 354–355
  anterior medial, 346, 354–355
Malleolar fold
  anterior, 521, 523
  posterior, 521
Malleolus, 4, 6–7
  lateral, 4, 6–7, 292–293, 343
Malleus, 521–522
  ligament of, 521, 523
Mammary gland, 68
Mammillary body, 494, 499
Mammography, 69
Mandible, 6, 477, 527, 552
  alveolar part, 478
  angle of, 7, 480, 572
  bay of, 478
  body of, 480, 572
  lateral view, 572
  medial view, 572
  posterior view, 572
  ramus of, 478, 480, 572
  superior view, 572
Mandibular canal, 528–529, 580
Mandibular fossa, 484, 527
Mandibular nerve, 492, 498–499, 503, 511, 517, 531–532, 535, 576
Mandibular node, 550
Mandibular symphysis, 572
Manubriosternal joint, 64, 67
Manubrium of sternum, 3, 6, 62, 64, 386, 538
Marginal artery, 157, 170
Marginal sulcus, 495
Marginal vessels, 102
Masseter, 8, 504–505, 526, 528, 540
Masseteric artery, 533
Masseteric fascia, 540
Masseteric nerve, 531
Mastoid air cells, 522–523
Mastoid antrum, 523
Mastoid nodes, 506, 550
Mastoid notch, 482, 484
Mastoid process, 7, 43, 480, 482, 484, 523, 527, 540
Maxilla, 6, 477–478, 527
Maxilla bone, 480, 487
Maxillary artery, 492, 500, 507, 533, 535, 546, 576
Maxillary nerve, 492, 498, 503, 511, 517, 531–532, 535, 556, 576
Maxillary sinus(es), 535, 566, 573
Maxillary vein, 507, 533, 539, 557, 576
Medial, as anatomical direction, 2
Median nerve, 13, 395, 403, 405, 410, 424, 434, 455
Mediastinal pleura, 93, 108–109
Mediastinal plexus, 110
Mediastinum, 79, 91, 116
  anterior, 91
  imaging, 113, 115, 117, 120, 121–122
  inferior, 91
  middle, 91
  posterior, 91, 118–119
  subdivisions of, 91
  superior, 91, 108
    imaging, 111
    nerves of, 110
    trachea in, 112
    transverse section at TIV, 121
    transverse section at TV, 122
    vasculature, 109–110
  transverse section at TIII, 120
Medulla
  adrenal, 204
  renal, 188
Medulla oblongata, 494–495
Medullary arteries, segmental, 46
Medullary sinus, 12
Medullary vellum
  inferior, 495
  superior, 495

Meningeal artery, 492
  middle, 507, 531, 533
  recurrent, 515
Meningeal nerve, 531–532
Meninges, 48–49, 490
Meniscus (menisci), 324–325
  lateral, 320, 323
  medial, 323
Mental artery, 507, 533
Mental foramen, 478, 480, 527, 533, 572–573
Mentalis, 504–505
Mental nerve, 503, 531, 576
Mental protuberance, 478
Mental spines, 572, 578
Mental tubercle, 478
Mental vein, 533
Mesenteric artery(ies), 170
  inferior, 10, 157, 160, 170, 184, 190, 192
  superior, 10, 157, 160, 170, 179–180, 184, 190, 192, 268
    branching, 171
    in coronal section of abdomen, 156
    positioning of, 171
Mesenteric ganglion
  inferior, 201
  superior, 199
Mesenteric nodes
  inferior, 198, 268–269
  superior, 198, 268–269
Mesenteric vein
  inferior, 11, 179–181
  retroperitoneal, 186
  superior, 11, 160, 179–181, 186
    in coronal section of abdomen, 156
Mesenteric vessels, superior, 164
Mesentery, 156, 164
Mesial, as anatomical direction, 573
Meso-appendix, 168
Mesocolon, transverse, 186
Mesosalpinx, 243
Metacarpal artery
  dorsal, 454
  palmar, 448–450
Metacarpal ligaments, 429, 443, 445
Metacarpals, 6, 385, 426, 428
Metacarpal vein, dorsal, 456–457
Metacarpophalangeal joint, 429
Metatarsal arteries
  deep, 346
  dorsal, 355
  plantar, 355, 362
Metatarsal ligaments, 351–352, 356
Metatarsals, 6–7, 293, 330–332
Metatarsophalangeal joint(s), 333
  of great toe, 292
Metencephalon, 494
Midbrain, 499
Midcarpal joint, 426
Middle lobe of lung, 82
Midgut, innervation of, 201–203
Midline raphe, 235, 240, 260
Mitral valve, 98–99, 101
  auscultation position for, 106
Modiolus, 524
  lamina of, 524
Molars, 573
Mons pubis, 256
Mucosa
  esophageal, 158
  gastric, 158
  of rectum, 231
  tracheal, 86
Mucosal linings of naval cavity, 568
Multifidus, 41, 43
Muscle(s). *See also individual muscles*
  abdomen, 137–141
  arm, 408–409, 412–413, 432–433, 435–436
  back, 36–43
  eye, 512
  facial, 504–505
  foot, plantar, 357–360
  gluteal, 300–301
  hand, 446–447
  infratemporal fossa, 528–529
  knee, 327
  larynx, 561
  leg, 340–341, 343–345
  neck, 540–541
  oral cavity, 578
  palate, 581
  pharynx, 554–555
  rotator cuff, 398–399
  thigh, 305
  thoracic wall, 72
Muscle attachments
  clavicle, 388
  foot, 350
  hand, 442
  lower leg, 339
  shoulder, 407
  skull, 488–489
  thigh, 305, 308–309, 313
  upper limb, 392–393, 409, 413, 430
Muscular triangle, 536
Musculi pectinati, 96
Musculocutaneous nerve, 13, 395, 403–405, 410, 424
Musculofascial pouch, 234
Musculophrenic artery, 74, 142–143
Musculophrenic vein, right, 75
Musculus uvulae, 555, 581
Mylohyoid, 531–532, 540–541, 578, 580
Mylohyoid line, 572
Myometrium, 242

N
Naris, 566
Nasal aperture, posterior, 484
Nasal artery
  dorsal, 515
  external, 569
  lateral, 506, 569
Nasal bone, 477–478, 480, 483, 566–567
Nasal cartilage, accessory, 566
Nasal cavity, 510, 552, 566
  bones, 567
  imaging, 570–571
  mucosal linings, 568
  nerves, 569
Nasal concha
  inferior, 477–478, 566–568
  middle, 510, 566–568
  superior, 566–568
Nasal crest, 478
Nasalis, 504–505
Nasal meatus
  inferior, 510, 568
  middle, 568
  superior, 568
Nasal nerve(s), 535
  external, 503
  posterior inferior lateral, 569
  posterior superior lateral, 569
Nasal septum, 555, 568
Nasal spine
  anterior, 478
  posterior, 484, 572
Nasal vein, 569
  lateral, 506, 569
Nasal vestibule, 568
Nasion, 478
Nasociliary nerve, 513, 517
Nasofrontal vein, 515
Nasolacrimal duct, 510, 567–568
Nasopalatine nerve, 569, 577, 581
Nasopharynx, 552–553
Navicular, 330–332
Navicular fossa, 234, 240
Neck. *See also* Larynx; Pharynx
  arteries, 546–549
  bones, 537
  compartments, 538
  fascia, 538
  imaging, 547, 549, 553
  lymphatics, 550–551
  muscles, 540–541, 554–555
  nerves, 542–544
  surface anatomy, 476, 536
  veins, 539
Nerve(s), 13–17. *See also individual nerves*
  abdominal, 199
  abdominal wall, 144–145
  arm, 424
    anterior compartment, 410, 434
    cutaneous, 418–419, 458–459
    posterior compartment, 414, 437
  in back, cutaneous, 53
  bladder, 274
  cardiac, 107
  cranial, 498–499, 584–585
  cutaneous, 17
    arm, 400, 414, 418–419, 424, 434, 458–459
    femoral lateral, 271
    femoral posterior, 252, 271
    lateral
      of thigh, 196–197
      T7-T11, 145
    lateral cutaneous branch of, 76
    legs, 347
    perforating, 252
    perineal, 271
    sural, 347
  dural, 492
  eyes, 513, 516
  facial, 506
  foot, 354–355, 361–362
  gluteal, 302–303
  gums, 577
  hand, 448–449, 451, 455
  head, 586
  infratemporal fossae, 533
  lacrimal gland, 511
  larynx, 562
  leg, 342, 346–347
  nasal cavity, 569
  neck, 542–544
  oral cavity, 583
  parasympathetic, 15
  pelvic, 252–253
  perineal, 267
  pharynx, 556
  pterygopalatine fossa, 535
  reproductive system
    female, 273
    male, 272
  spinal, 44–45, 47
    anterior rami of, 252
    nomenclature of, 44

Nerve(s) (*Continued*)
sympathetic, 14
teeth, 576–577
thigh, 311, 314
thoracic wall, 76
tongue, 579
Nipple, 4, 68
Nodule, in aortic valve, 100
Nose, 566. *See also entries at* Nasal
Nuchal line
inferior, 482, 484
superior, 37, 40, 482, 484
Nucleus pulposus, 32
herniation of, 33–34
Nucleus solitarius, 127

O
Oblique fissure, 81–83, 85
Oblique line, 478
Oblique muscles (in eyes)
inferior, 512, 514
superior, 512, 514
Oblique muscles (in trunk)
external, 8–9, 37–39, 42, 71, 136–138, 141–142, 148, 238
internal, 8–9, 42, 136–138, 141–142, 148, 238
Oblique vein, of left atrium, 102
Obliquus capitis inferior, 41, 43
Obliquus capitis superior, 41, 43
Obturator artery, 234, 246, 248, 251, 264, 297, 299, 312
posterior branch, 299
Obturator canal, 153, 219, 226–228
Obturator externus, 8, 305, 311
Obturator foramen, 196, 212–216, 218, 220–221, 232, 258, 295
Obturator internus, 9, 151, 226, 228–229, 240, 258, 262, 301, 305
fascia covering, 227
tendon of, 226, 258
Obturator membrane, 151, 153, 217, 219, 297
Obturator nerve, 13, 196–197, 252, 254, 265, 271, 303, 311, 316
cutaneous branch, 197
muscular branches, 311
posterior branch, 311
Obturator node, 270
Obturator vein, 234, 247–248, 251, 264
Obtuse margin, 94, 101
Occipital artery, 43, 492, 500, 506–507, 546, 579
Occipital bone, 7, 40, 477, 480, 482–483, 485
Occipital condyles, 484, 537
Occipital crest
external, 482
internal, 485
Occipitalis, 9
Occipital lobe, 495
Occipital nerve
greater, 43, 53
lesser, 542, 544–545
third, 43, 53
Occipital nodes, 506, 550
Occipital pole, 494
Occipital protuberance, external, 7, 35, 37, 482, 484–485
Occipital vein, 506–507, 539
Occipitofrontalis, 504–505, 540
Occipitomastoid suture, 480, 482
Occipitotemporal gyri, 494
Oculomotor nerve, 498–499, 513, 517, 584
Odontoid process, 24
Olecranon, 5, 7, 384–385, 406, 412, 420, 423
Olecranon fossa, 406, 423
Olfactory bulb, 494, 498–499, 569
Olfactory nerves, 498, 569, 584
Olfactory tract, 494, 499
Olive, 499
Omental appendices, 166
Omental bursa, 154
Omental foramen, 164
Omentum
greater, 152
lesser, 154
Omohyoid, 540–541
Ophthalmic artery, 500
inferior, 533
Ophthalmic nerve, 492, 498–499, 503, 511, 513, 517, 531–532, 535
Ophthalmic vein(s), 507
inferior, 515, 533
superior, 515
Opponens digiti minimi, 360, 444, 446–447
Opponens pollicis, 446–447, 456
Optic canal, 485, 508, 534
Optic chiasm, 495, 498–499
Optic disc, 516
Optic nerve, 498–499, 509, 513, 516, 584
Oral, as anatomical direction, 573
Oral cavity, 552
bones, 572–573, 575
imaging, 574
muscles, 578
nerves, 583
root of, 582
Oral vestibule, 580
Ora serrata, 516
Orbicularis oculi, 8, 504–505, 509
Orbicularis oris, 8, 504–505, 580
Orbital fissure
inferior, 478, 508
superior, 478, 485, 508, 534
Orbital gyri, 494
Orbital nerves, 535
Orbital septum, 504, 509–510
Orbital sulci, 494
Oropharyngeal isthmus, 582
Oropharynx, 552–553, 582
Otic ganglion, 532
Oval window, 521–522, 524
Ovarian artery, 10, 249
left, 147
right, 192
Ovarian plexus, 199
Ovarian vein(s), 11, 193, 249
left, 147
Ovarian vessels, 242
Ovary(ies), 147, 224, 241–243
structure of, 242
suspensory ligament, 224, 242

P
Palate, 581–582
hard, 484, 552, 554, 581
soft, 552–553, 568, 581
Palatine aponeurosis, 581–582
Palatine artery, 535
greater, 569, 581–582
lesser, 535, 581–582
Palatine bone, 477, 508, 527, 534
Palatine canal, 534
Palatine foramen, 484, 572, 581
Palatine glands, 552, 582
Palatine nerve, 535
greater, 577, 581–582
lesser, 535, 581–582
Palatine rugae, 581
Palatine tonsil, 12, 552, 580–582
Palatine vein, greater, 569
Palatoglossal arch, 552, 580, 582
Palatoglossus, 578–582
Palatopharyngeal arch, 552, 582
Palatopharyngeus, 554–555, 580–582
Palatovaginal canal, 534, 567
Palmar aponeurosis, 432, 443
Palmar arch
deep, 10
superficial, 10
Palmar interosseous, 446–447
Palmaris brevis, 443
Palmaris longus, 8, 408, 424, 432
Palmaris longus tendon, 431–432, 440, 443
Palmar ligament, 429, 445–446
Palmar surface, of hand, 2
Palpable bone
anterior view, 6
superior view, 7
Palpebral fissure, 510
Palpebral ligament, 504, 510
Pampiniform plexus, 149, 238–239
Pancreas, 154, 176–177, 186
anterior surface of, 176
body of, 162, 176
fundus of, 177
head of, 156, 162, 176
imaging, 176
neck of, 162
positioning of, 178
retroperitoneal, 186
tail of, 176
uncinate process, 176
vasculature of, 179
Pancreatic artery
dorsal, 179
inferior, 179
Pancreatic duct
accessory, 177
main, 177
Pancreatic notch, 176
Pancreaticoduodenal artery
anterior inferior, 160, 179
anterior superior, 160
inferior, 157, 160
posterior, 157
posterior inferior, 160, 179
posterior superior, 160, 179
superior, 157, 160
Pancreaticoduodenal vein, 181
Papillary muscle
anterior, 97, 99, 105
posterior, 97, 99, 105
septal, 97
Paracentral lobule, 495
Paracolic gutter
left, 153
right, 153
Parahippocampal gyrus, 494
Paranasal sinuses, 566
Paranephric fat, 186
Parasternal nodes, 69, 77
Parasympathetic nerves, 15
in face, 532
Parathyroid gland
inferior, 563, 565
superior, 563, 565
Paratracheal nodes, 551
Para-urethral gland, opening of duct, 257
Parietal bone, 7, 477, 480, 482–483, 485
Parietal foramen, 483

Parietal lobe, 495
Parietal peritoneum, 136–137, 141, 148, 222
Parietal pleura, 72, 79–81, 124
  cervical, 92
Parietomastoid suture, 480
Parieto-occipital sulcus, 495
Parotid duct, 504–505
Parotid fascia, 540
Parotid gland, 504, 506–507, 528
Parotid nodes, 506, 550
Parotid region
  arteries, 507
  veins, 507
Pars flaccida, 521
Pars opercularis, 494
Pars orbitalis, 494
Pars triangularis, 494
Patella, 4, 6, 292, 304
Patellar ligament, 308, 320, 327
Patellar retinaculum, 327
Patellar surface, 304
Pecten pubis, 212, 216, 221, 294
Pectineal line, 212, 216, 221, 294
Pectineus, 8, 305–306, 309–310, 316
  nerve to, 311
Pectoral fascia, 68
Pectoralis major, 3–4, 8, 68–70, 408, 540
  abdominal part, 138, 394
  in axial plane, 70
  clavicular part, 394
  sternocostal part, 394
Pectoralis major fascia, 540
Pectoralis minor, 8, 68, 70–71, 395
Pectoral nerve
  lateral, 70, 395, 403–404
  medial, 70, 395, 403–404
Pectoral nodes, 415
Pectoral region, 71, 394
Pedicle, 22, 30, 45
Pelvic bone, 293–294
Pelvic brim, 221
Pelvic cavity
  female, 277–283
  floor, 227–229
  imaging, 275–283
  lateral wall, 226
  male, 230, 275–277
Pelvic fascia, 245
Pelvic girdle, 216
  imaging, 217
  orientation of, 221
Pelvic inlet, 220
Pelvic nerve plexus, 253
Pelvic outlet, 220
Pelvis
  arterial supply of, 246
  articulated, 212–214, 295
  lymphatics, 270
    female, 269
    male, 268
  renal, 186, 188
  subpubic angle in
    female, 214
    male, 212
  surface anatomy
    female, 214–215
    male, 212–213
  venous drainage of, 247
  viscera
    female, 224
      imaging, 225
    male, 222
      imaging, 223
    vasculature, 248
Penis, 4, 240
  bulb of, 222, 234–235, 260
    artery of, 266
    vein of, 266
  crus of, 240, 260
  deep artery of, 240, 266
  dorsal arteries of, 238, 245, 250, 264, 266
  dorsal nerve of, 265, 267, 271
  dorsal veins of, 238, 245, 250, 264
  frenulum of, 240
  fundiform ligament of, 238, 240, 260
  glans, 20, 212, 234, 240, 250, 260
  prepuce of, 240
  skin of, 240
  suspensory ligament of, 222, 240, 260
  venous drainage, 250
Pericardiacophrenic artery, 92, 114
  left, 108
Pericardiacophrenic vein, 92, 114
  left, 109
  right, 109
Pericardiacophrenic vessels, 92
Pericardial cavity, 93
Pericardial layers, 93
Pericardial reflections, 94–95
Pericardial sac, 93
Pericardial sinus
  oblique, 93, 124
  transverse, 93
Pericardium, 92, 109–110
  fibrous, 92–93, 124
  serous, 93, 124
Peridontium, 575
Perineal artery, 264
  transverse branches, 266
Perineal branches, 314
Perineal membrane, 151, 230, 232–233, 235, 240, 259
Perineal muscle
  deep transverse, 230, 234, 259
  superficial transverse, 240, 255–256, 262
Perineal nerve, 265, 267, 271
  posterior labial branch, 267
  posterior scrotal branch, 267
Perineal pouch
  deep, 151, 230, 232–233, 235, 241, 259
    motor branches, 267
    muscles of, 259
  superficial, 235
Perineal vein, 247, 264
  transverse branches, 266
Perinephric fat, 186
Perineum
  borders of, 258
  ceiling of, 258
  dermatomes, 271
  female, 258
  lymphatics, 270
    female, 269
    male, 268
  male, 222, 258
    imaging, 223
  nerves of, 267
  surface anatomy
    female, 214–215, 256–257
    male, 212–213, 254, 257
  vasculature of, 266
Periorbita, 509
Periosteum, 509
Peritoneal cavity, 137
  arrangement of abdominal contents, 155
  greater and lesser sacs of, 154
  imaging, 155
Peritoneum, 224, 237
  parietal, 136–137, 141, 148, 222
  visceral, 222
Pes anserinus, 305
Petrosal nerve
  deep, 535
  greater, 511, 520, 535
  lesser, 522
Petrosal sinus, 493
Petrotympanic fissure, 527, 532
Peyer's patch, 12
Phalanges (foot), 6, 293, 330–332
Phalanges (hand), 6, 385, 426, 428
Pharyngeal artery, 492, 535
  ascending, 546
Pharyngeal constrictor(s), 552
  superior, 505
Pharyngeal nerve, 535
Pharyngeal raphe, 554
Pharyngeal recess, 552, 568
Pharyngeal tonsil, 12, 552–553, 568
Pharyngeal tubercle, 484, 554
Pharyngobasilar fascia, 554–555, 581
Pharyngo-epiglottic fold, 555
Pharyngotympanic tube, 521–523, 552–555, 568, 572
Pharynx, 552–553
  innervation, 556
  muscles, 554–555
  veins, 556
Phrenic artery
  inferior
    left, 185, 192
      recurrent branch of, 192
    right, 192
  interior, 190
  right, 185
    inferior, 185
Phrenic nerve(s), 13, 202, 403, 543–544
  left, 92, 185
  right, 92, 114
Phrenic vein(s), inferior
  left, 193
  right, 193
Pia arterial plexus, 46
Pia mater, 48–49
Pillar cells, 524
Pineal gland, 495, 499
Piriform aperture, 478
Piriform fossa, 553
Piriformis, 9, 226–229, 241, 258, 301–303, 305
Piriform recess, 560
Pisiform, 426, 428, 440
Pisohamate ligament, 429, 432, 445
Pisometacarpal ligament, 429, 432, 445
Pituitary gland, 494–495, 498
Planes, anatomical, 2
Plantar aponeurosis, 356
Plantar artery
  deep, 346, 354, 362
  lateral, 361–362
  medial, 361–362
Plantar calcaneonavicular ligament, 351
Plantar cuboideonavicular ligament, 351
Plantar cuneonavicular ligament, 351
Plantar interossei, 359–360
Plantaris, 9, 305, 307, 340–341
Plantar ligament, 336, 351
  long, 351–352
Plantar lymph vessels, 365
Plantar metatarsal ligaments, 351
Plantar nerve
  lateral, 347, 361–362
  medial, 347, 361–362

Plantar surface, of foot, 2
Plantar tarsometatarsal ligaments, 351
Platysma, 504–505, 540, 580
Pleural cavity(ies), 79
  left, 79
Pleural recesses, surface projections of, 81
Pons, 494–495, 499
Pontine arteries, 500
Popliteal artery, 10, 314–315, 327, 342, 346
Popliteal fossa, 5, 328
Popliteal ligament, 320
Popliteal nodes, 12, 365
Popliteal vein, 11, 342, 365
Popliteus, 9, 305, 341
Popliteus tendon, 320
Porta hepatis, 173
Portal hypertension, venous enlargement in, 182
Portal triad, 174
Portal vein, 11, 162, 174, 179
  in coronal section of abdomen, 156
  formation of, 181
  left branch, 174
  right branch, 174
Portosystemic anastomoses, 182
Postcentral gyrus, 494
Postcentral sulcus, 494
Posterior, as anatomical direction, 2
Posterior cord, 405
Posterior segment, of lung, 87
Posterior triangle, 536
Posterolateral arteries, 500
Posteromedial arteries, 500
Postremal chamber, 516
Preaortic nodes, 198, 268–269
Preauricular nodes, 506, 550
Precuneus, 495
Prelaryngeal nodes, 551
Premolars, 573
Pre-occipital notch, 494
Prepatellar bursa, 326
Prepuce of penis, 240
Presymphyseal node, 268
Pretracheal layer, 538
Pretracheal nodes, 551
Pretracheal space, 538
Prevertebral layer of neck, 538
Prevertebral plexus, 14, 201, 253
Princeps pollicis artery, 449–450
Procerus, 504–505
Processus vaginalis, ligamentous remnant of, 239
Profunda brachii artery, 10, 395, 400–402, 410, 414
Pronator quadratus, 8, 431–433, 444
Pronator teres, 8, 408, 424, 431–432, 436
Prostate, 151, 222, 230, 232, 235–237
  anterior region, 236
  capsule of, 232, 235
  central zone, 236
  glandular elements, 235
  imaging, 235–237
  peripheral zone, 236
  transitional zone, 236
  venous drainage, 250
Prostatic ducts, openings of, 235
Prostatic fascia, 245
Prostatic plexus, 245, 250, 254
Prostatic sinus, 235
Prostatic urethra, 222, 232, 235
Prostatic utricle, 235
Proximal, as anatomical direction, 2
Psoas major, 29, 42, 137, 147, 151, 183, 185–186, 268, 311
Psoas minor, 183, 268
Pterion, 480
Pterygoid(s), 554
  lateral, 528–530, 532
  medial, 528–529, 532
Pterygoid artery, 533
Pterygoid canal, 484, 534–535
Pterygoid fossa, 484
Pterygoid hamulus, 527, 529, 534, 567, 572
Pterygoid plate, 534
  medial, 554
Pterygoid plexus of veins, 507, 515, 557, 576
Pterygoid process, 572
Pterygomandibular raphe, 505, 529, 554, 580, 582
Pterygomaxillary fissure, 527
Pterygopalatine canal, 534
Pterygopalatine fossa, 527, 534–535, 556
Pterygopalatine ganglion, 511, 535
Pubic crest, 216, 219–221, 294
Pubic ligament, inferior, 229, 258
Pubic ramus
  inferior, 212–214, 216, 220–221, 231, 294–295, 297
  superior, 212–216, 294–295
Pubic region, 135
Pubic symphysis, 4, 6, 134, 139, 212–216, 218–222, 224, 226–229, 295
  anterosuperior margin, 221
Pubic tubercle, 134, 137, 212, 214, 216, 218, 220–221, 226, 232, 294–295, 297
Pubic vessels, 148
Pubis, 6
  body of, 213, 215
Pubocervical ligament, 245
Pubococcygeus, 227–229, 231, 245, 258, 260, 262
Pubofemoral ligament, 299
Puboprostatic ligament, 232, 245
Puborectalis, 227, 229, 231, 258, 260, 262
Pubovesical ligament, 233
Pudendal artery, 264
  external
    deep, 238, 299, 312
    superficial, 142–143, 299
  internal, 246, 251, 264, 266, 299, 303
    left, 245
    right, 250
Pudendal canal, 231
Pudendal nerve, 246, 252–254, 265, 267, 274, 302
Pudendal vein, 264
  external, 364
  internal, 182, 247, 251, 264, 266
    left, 245
    right, 250
  superficial external, 142, 238
Pulmonary artery(ies), 82–83, 98–99
  left, 88–89, 94–95, 109–110
  right, 88, 94–95
    branches of, 101, 109–110
Pulmonary ligament, 80, 82–83
Pulmonary plexus, 88
  posterior, 88
Pulmonary trunk, 63, 74, 89
Pulmonary valve, 97, 101
Pulmonary vein(s), 82–83, 88, 98–99, 109
  left, 88, 94–95, 101, 109–110
  right, 93–95, 101, 110, 114
Pulmonary vessels, 88
  imaging, 89–90
Pulp cavity, 575
Pupil, 508
Pyloric antrum, 158, 162
  in coronal section of abdomen, 156
Pyloric canal, 158
Pyloric orifice, 158, 177
Pyloric sphincter, 169
Pylorus, 158, 169
Pyramid, 499
Pyramidal eminence, 521
Pyramidalis, 140, 149
Pyramid in renal medulla, 188

Q
Quadrangular membrane, 559
Quadrangular space, 414
Quadrate lobe, of liver, 173
Quadratus femoris, 9, 301–302, 305, 313
Quadratus lumborum, 41–42, 137, 183–186, 192
Quadratus plantae, 358, 360
Quadriceps femoris, 305, 308, 343
Quadriceps femoris tendon, 320, 344

R
Radial artery, 10, 410, 424, 434, 437, 456
Radial collateral artery, 401–402, 410, 414, 434
Radial collateral ligament, 422
Radial fossa, 406
Radial groove, 389
Radialis indicis artery, 448–450, 456
Radial nerve, 13, 395, 400, 405, 410, 414, 424, 437
Radial notch, 406, 420, 425
Radial recurrent artery, 410, 414, 434
Radial recurrent vein, 411
Radial styloid process, 425
Radial tuberosity, 420, 425
Radial vein, 11
Radiate ligament, 66
Radicular artery
  anterior, 46
  posterior, 46
Radicular vein
  anterior, 47
  posterior, 47
Radiocarpal ligament, 429
Radio-ulnar joint, 420, 425
Radio-ulnar ligament, 429
Radius, 6–7, 385, 425, 433
  borders of, 425
  head of, 7, 420, 425
  neck of, 425
  proximal end, 406
Rami communicantes, 32, 45
Ramus of ischium, 212–216, 220
Ramus of mandible, 478, 480, 572
Rectal artery
  inferior, 246, 250–251, 266
  middle, 192, 246, 248, 251
  superior, 157, 170, 190, 248, 251
Rectal fascia, 231
Rectal nerve, inferior, 265, 267
  cutaneous branches, 271
Rectal neurovascular bundle, 251
Rectal vein
  inferior, 247, 250–251, 266
  middle, 182, 247–248, 250–251
  superior, 181, 248, 251
Rectal venous plexus
  external, 231, 251
  internal, 231, 251
  perimuscular, 251
Rectal vessels, superior, 186
Recto-uterine pouch, 224, 243, 245
Rectovaginal septum, 245
Rectovesical pouch, 222
Rectovesical septum, 245
Rectum, 147, 157, 166, 169, 222, 231
  circular muscle of, 231
  coronal section, 231
  inferior transverse fold, 231

Rectum (*Continued*)
in situ, 230
longitudinal muscle, 231
middle transverse fold of, 231
mucosa of, 231
positioning of, 231
in sagittal plane, 3
surface projection, female, 231
venous drainage of, 251
Rectus
inferior, 509, 512, 514
lateral, 509, 512, 514
medial, 509, 512, 514
superior, 509, 512, 514
Rectus abdominis, 8, 136–137, 140–142, 149
position of tendinous intersection, 134
Rectus capitis anterior, 541
Rectus capitis lateralis, 541
Rectus capitis posterior major, 41, 43
Rectus capitis posterior minor, 41, 43
Rectus femoris, 8, 300, 305–306, 308, 310, 316
Rectus sheath, 8
anterior wall, 136, 141
organization of, 141
posterior wall, 136–137, 141, 151
Referred pain diagram, abdominal, 202–203
Regional vertebrae, 22
Renal artery
left, 10, 190, 192, 268
right, 190, 192
Renal column, 188
Renal cortex, 188
Renal impression
on liver, 173
on spleen, 159
Renal medulla, 188
Renal papilla, 188
Renal pelvis, 186, 188
Renal sinus, 188
Renal vasculature, 190–191
Renal vein(s), 193
left, 147, 190
right, 190
Reproductive system
female, 241–244
innervation, 273
male, 234–240
innervation, 272
Rete testes, 239
Reticular fiber, 12
Retina, 509, 516
Retinal artery, central, 515
Retromandibular vein, 506–507, 533, 539, 557, 576
Retromolar fossa, 572
Retromolar triangle, 572
Retropharyngeal space, 538
Retropubic space, 222
Rhomboid major, 9, 36–38, 52, 398, 412
Rhomboid minor, 9, 36–38, 398
Rib(s)
I, 6, 63–65
II, 64–65
III, 64
IV, 64
V, 64–65
VI, 64
VII, 64
VIII, 64
IX, 64
X, 64
XI, 63–64, 73, 186
XII, 63–65, 73, 185–186
anatomy of, 65
Rib(s) (*Continued*)
articulations of, 66–67
demifacets for articulation of, 22
false, 64
floating, 64
head of, 65
neck of, 65
placement of, 63
true, 64
Rima glottidis, 560
Rima vestibuli, 560
Risorius, 504–505, 540
Root canal, 575
Rotator cuff muscles, 398–399
Rotatores thoracis, 41
Round window, 521–522, 524

S
Saccule, 524, 561
Sacral artery(ies)
lateral, 46, 192, 246, 248
median, 184, 192, 246, 251
Sacral canal, 216, 220, 228, 294
Sacral cornua, 31, 215, 294
Sacral crest
lateral, 31
median, 31
Sacral curvature, 21
Sacral dimple, at posterior iliac spine, 5, 20, 215
Sacral foramina, 31
anterior, 214, 295
posterior, 213, 215, 226, 294–295
Sacral ganglia, 200
Sacral hiatus, 213, 215, 294–295
Sacral meninges, 48
Sacral nerve(s), 34, 44, 196
Sacral node
lateral, 268–270
median, 270
middle, 268
Sacral plexus, 13, 252
Sacral promontory, 3, 221
Sacral vein
lateral, 247–248
median, 193, 247, 251
Sacrococcygeal ligaments, 218–219, 228
Sacro-iliac joint, 6, 31, 214, 219–221, 227, 294–295
Sacro-iliac ligament
anterior, 218–219
interosseous, 219
posterior, 218–219, 226
Sacrospinous ligament, 218–219, 226, 228, 301, 303
Sacrotuberous ligament, 219–220, 226, 228–229, 258–260, 262, 301, 303
Sacrum, 6–7, 21–22, 31, 212–216, 218, 220–221, 226–228, 293–294
ala of, 212, 220–221, 227, 295
articular surface of, 219
Sagittal axis, 2
Sagittal plane, 2–3
Sagittal sinus, 493
Sagittal suture, 482–483
Salivary glands, 578
Salpingopharyngeal fold, 552–553
Salpingopharyngeus, 554–555, 581
Saphenous hiatus, 364–365
Saphenous nerve, 13, 310–311, 346, 354
from femoral nerve, 197
Saphenous vein
accessory, 364
great, 11, 268–269, 310, 316, 364
small, 11, 364
Sartorius, 8, 292, 300, 305–308, 310, 316, 340, 344
nerve to, 311
Sartorius tendon, 308
Scala tympani, 524
Scala vestibuli, 524
Scalene(s), 8, 538
anterior, 394, 540–541
middle, 394–395, 541
posterior, 394, 540–541
Scalp, 490
Scaphoid, 426, 428, 456
Scaphoid fossa, 484, 572
Scapula, 6–7, 385–386
acromion of, 5–6, 20, 36, 39
anterior view, 387
in axial plane, 3, 70
inferior angle of, 5, 7, 20, 36–37, 63, 387
lateral border of, 387
lateral view, 387
medial border of, 5, 387
muscles of, 398–399
spine of, 5, 20, 36–38, 385
superior angle of, 7, 36, 63, 387
in transverse section of thoracic vertebral column, 52
Scapular artery
circumflex, 401–402, 410, 414
dorsal, 37, 400, 548
Scapular ligament, 386, 400
Scapular nerve, dorsal, 37–38, 403–405
Scarpa's layer, 136–137, 238
Sciatic foramen
greater, 218–219, 226, 253, 301
lesser, 218–219, 226
Sciatic nerve, 13, 252, 302–303, 314–316
muscular branch, 314–315
Sciatic notch
greater, 213, 215, 294
lesser, 216
Sclera, 508–509, 516
Scleral venous sinus, 516
Scrotal artery, posterior, 250, 264, 266
Scrotal nerve, posterior, 265
Scrotal raphe, 257
Scrotal vein, posterior, 250, 264, 266
Scrotum, 4, 212, 238
septum of, 238
skin of, 238
Secretory lobules, of mammary gland, 68
Segmental muscles, 41
Semicircular canal
anterior, 520–521, 524
lateral, 520–521, 524
posterior, 520–521, 524
Semilunar cusp, 97, 100
Semilunar line, 134
Semimembranosus, 300, 305, 307, 313–314, 316, 340
Semimembranosus bursa, 326
Semimembranosus tendon, 313, 320
Seminal colliculus, 235–236
Seminal vesicle, 234, 236–237, 240
imaging, 236
positioning, 235
Seminiferous tubule, 239
Semispinalis capitis, 9, 39–40, 43
Semispinalis cervicis, 43
Semispinalis thoracis, 41
Semitendinosus, 9, 300–301, 307, 313–314, 316, 340
Semitendinosus tendon, 313
Septal cartilage, 566–567
Septomarginal trabecula, 97, 105
Septum pellucidum, 495

tahir99-VRG & vip.persianss.ir

Serous pericardium, 93
  visceral layer of, 124
Serratus anterior, 8, 38–39, 52, 70–71, 138, 396, 398
  in axial plane, 70
Serratus posterior inferior, 39, 71
Serratus posterior superior, 39, 71
Sesamoids, 331–332, 359, 428
Shoulder
  bones, 386
  muscle attachments, 407
  vessels and nerves, 400
Shoulder joint, 7, 385–386
Sigmoid arteries, 157, 170
Sigmoid colon, 147, 157, 166, 222, 224, 230
  in coronal section of abdomen, 156
  in transverse plane, 3
Sigmoid sinus, 493
Sigmoid vein, 181
Sinu-atrial node, 105
SI vertebra, body of, 219
Skeleton
  anterior view of, 6
  cardiac, 100
  posterior view of, 7
Skull
  anterior view, 478–479
  arteries, 492
  bones, 477
  cavity, 485
  imaging, 479, 481
  inferior view, 484
  lateral view, 480–481
  muscle attachments, 488–489
  posterior view, 482
  roof, 483
  superior view, 483
  venous sinuses, 493
Small intestine, 152–153, 164
  in coronal plane, 3
  lymph nodes in, 12
  in sagittal plane, 3
S1 nerve, 53
S3 nerve, 53
Soft palate, 552–553, 568, 581
Soleal line, 293
Soleus, 8–9, 341, 343–344
Somatic afferents, 127
Somatic sensory fiber, 127
Spermatic cord, 138–139, 147–148, 234
  positioning, 239
Spermatic fascia
  external, 149, 238
  internal, 149
Spheno-ethmoidal recess, 568
Sphenoidal sinus, 498, 552, 566–568
Sphenoid bone, 477, 484–485, 527, 534, 572
Sphenomandibular ligament, 528–529
Sphenopalatine artery, 533, 535, 569
Sphenopalatine foramen, 534, 567, 569
Sphenopalatine vein, 533, 569
Sphenoparietal sinus, 493
Sphenoparietal suture, 480
Sphenosquamous suture, 480
Sphincter pupillae, 516
Sphincter urethrovaginalis, 233, 259
Spinal artery
  anterior, 46, 49, 502
  posterior, 46, 49, 499, 502
    left, 46
    right, 46
  segmental, 46
Spinal cord, 23, 26, 32, 45
  cervical enlargement of, 45, 50
Spinal cord (*Continued*)
  in cranium, 498
  features of, 45
  imaging of, 50–51
  lumbosacral enlargement of, 45
  segmental supply of, 46
  vasculature of, 46
  venous drainage of, 47
Spinal ganglion, 127
Spinalis, 40
Spinalis cervicis, 43
Spinalis thoracis, 40
Spinal joints and ligaments, 35–36
Spinal nerves, 34, 44–45, 76
  anterior rami of, 252
  meningeal branches, 49
Spinal vein
  anterior, 47
  posterior, 47
Spiral ganglion, 524
Spiral ligament, 524
Spiral organ, 524
Spiral valve, 178
Splanchnic nerve(s), 114, 200
  greater, 116, 119, 185, 199–201
  least, 119, 199–200, 274
  lesser, 119, 185, 199–200, 274
  lumbar, 199–201, 274
  pelvic, 199–201, 252–254, 272, 274
  sacral, 200–201, 253–254, 274
  thoracic, 200
Spleen, 153, 157, 160, 186
  in abdominal cavity, 159
  arteries of, 160–161
  in coronal section of abdomen, 156
  hilum of, 159
  imaging of, 159
  location of, 159
  surface projection of, 159
  surfaces of, 159
Splenic artery, 10, 157, 159–160, 179
Splenic vein, 11, 159, 179–181
Splenic vessels, 179
Splenius capitis, 9, 36–40, 43, 71, 540
Splenius cervicis, 9, 39–40, 71
Splenorenal ligament, 159
Squamous suture, 480
Stapedius muscle nerve, 522
Stapedius tendon, 522
Stapes, 521–522
Sternal angle, 62
Sternal notch, 4
Sternoclavicular joint, 62, 386, 388
Sternocleidomastoid, 4, 8–9, 43, 504, 538, 540–541
Sternocostal joint, 64, 66–67
Sternocostal ligaments, 67
Sternohyoid, 540–541
Sternothyroid, 541
Sternum, 64
  in axial plane, 70
  body of, 6, 62, 72
  manubrium of, 3, 6, 62, 64, 72, 386, 538
Stomach, 152, 160, 186
  arteries of, 160–161
  body of, 158, 169
  in coronal plane, 3
  in coronal section of abdomen, 156
  external features, 158
  fundus of, 169
  imaging, 158
  internal features, 158
  positioning of, 158
  surface projection of, 158
Straight sinus, 493
Striate artery, middle, 500
Styloglossus, 529, 554, 579
Stylohyoid, 540–541
Stylohyoid ligament, 537, 554–555, 578
Styloid process, 480, 484, 523, 527, 529, 540, 554–555
  radial, 425
Stylomandibular ligament, 528–529
Stylomastoid foramen, 484, 522
Stylopharyngeus, 554–555, 578, 581
Subarachnoid space, 48
Subclavian artery, 46, 70, 402, 546
  left, 10, 74, 83, 88, 101, 109–110, 113, 500, 548–549, 564
    in axial plane, 3
  right, 10, 74, 82, 88, 101, 109–110, 395, 500, 548, 564–565
Subclavian groove, 388
Subclavian nerve, 403
Subclavian trunk, 77, 551
Subclavian vein, 411
  left, 11, 75, 101, 110, 539, 557
  right, 11–12, 77, 82, 101, 109–110, 565
Subclavicular nodes, 550
Subclavius, 70–71, 116, 395
Subcostal artery, 143, 192
Subcostal muscles, 72
Subcostal nerve, T12, 76, 144
  anterior cutaneous branch of, 125, 145
  lateral cutaneous branch of, 125, 144
Subcostal plane, 135
Subcostal vein, left, 75
Subepicardial fat, 93
Sublingual caruncle, 582
Sublingual fold, 582
Sublingual gland, 532, 578, 580, 582
Sublingular fossa, 572
Submandibular duct, 578, 580, 582
Submandibular fossa, 572
Submandibular ganglion, 532, 579
Submandibular gland, 532
Submandibular nodes, 12, 506, 550–551, 580
Submental nodes, 506, 550–551
Submental vein, 539
Subparotid node, 550
Subphrenic recess, 154
Subpopliteal recess, 326
Subpubic angle
  female, 214
  male, 212
Subscapular artery, 401–402, 410
Subscapular fossa, 387
Subscapularis, 52, 398–399
Subscapular nerve, 403, 405
Subscapular nodes, 415
Subtalar joint, 333
Subtendinous bursa, 326
Sulcus terminalis, 94–95
Superciliary notch, 478
Superficial temporal artery, 10
Superior, as anatomical direction, 2
Superolateral nodes, 365
Superomedial nodes, 365
Supinator, 8–9, 424, 432, 436
Supinator crest, 406
Supraclavicular nerve(s), 418, 542, 544–545
  intermediate, 125
  lateral, 125
  medial, 125
Supracondylar line
  lateral, 304
  medial, 304
Supracondylar ridge, 406
Supraduodenal artery, 157, 160, 163, 179

tahir99-VRG & vip.persianss.ir

Supraglenoid tubercle, 387
Supramandibular triangle, 536
Supramarginal gyrus, 494
Supramastoid crest of temporal bone, 526
Supra-orbital artery, 506, 510, 515
Supra-orbital foramen, 480
Supra-orbital nerve, 503, 510–511, 513, 535
Supra-orbital notch, 478, 508
Supra-orbital vein, 506, 510, 515
Suprapatellar bursa, 326
Suprapatellar fat, 326
Suprarenal artery
  inferior
    left, 190
    right, 190, 192
  middle, 184
    left, 190
    right, 192
  superior
    left, 190, 192
    right, 190, 192
Suprarenal gland, 160
  left, 184, 186, 190, 193
  right, 184, 186, 190, 192
Suprarenal impression, on liver, 173
Suprarenal vein(s)
  left, 190, 193
  right, 190, 193
Suprascapular artery, 400, 402, 414, 546, 548–549, 564–565
Suprascapularis, 395
Suprascapular nerve, 400, 403
Suprascapular notch, 386–387
Supraspinatus muscle, 9, 38–39, 395, 398
Supraspinous fossa, 386–387
Supraspinous ligament, 35, 218
Suprasternal space, 538
Supratrochlear artery, 506, 510, 515
Supratrochlear nerve, 503, 510, 513
Supratrochlear nodes, 415, 457
Supratrochlear vein, 506, 510, 515
Sural arteries, 314, 342
Sural nerve, 13, 315, 342, 347
Surface anatomy
  of abdomen, 134
  of arm, 408, 412, 431, 435
  of back, 20, 36
  of body
    anterior view, 4
    posterior view, 5
  of ears, 520
  of face, 508
  of foot, 353
  of gluteal region, 300
  of hand, 443, 452
  of head, 476
  of knee, 327
  of larynx, 558, 563
  of lower limbs, 292
  of mediastinum, 91
  of neck, 476, 536
  of pelvis and perineum
    female, 214–215, 256–257
    male, 212–213, 255, 257
  of superior mediastinum, 108
  of thorax, 62
  of upper limbs, 384
Suspensory ligament
  of clitoris, 262
  of eye, 509
  of ovary, 224, 242
  of penis, 68, 222, 240, 260
Sustentaculum tali, 330–331, 336
Sutural bone, 482
Sympathetic cardiac nerves, 126
Sympathetic ganglia, 32, 199
  cervical, 126, 403
  fifth thoracic, 88
  third thoracic, 107
Sympathetic nerves, 14
Sympathetic trunk, 78, 119, 544–545
  left, 107, 254
  left lumbar, 253
  right, 88, 107, 254
Synovial membrane
  in lower limbs, 297–298
  in upper limbs, 390, 422
Synovial sheaths, in hand, 444

T
Taenia, free, 168
Taenia coli, 164, 166
Talocalcaneal ligament, 336–337, 352
Talocalcaneonavicular joint, 333
Talofibular ligament, 336–337
  anterior, 352
Talonavicular ligament, 336, 352
Talus, 6, 330–332, 334
Tarsal artery
  lateral, 346
  medial, 346
Tarsal bones, 6
Tarsal gland, 509
Tarsal muscle, superior, 509
Tarsal sinus, 331
Tarsal tunnel, 363
Tarsometatarsal joints, 333
Tarsometatarsal ligaments, 352
Tarsus
  inferior, 509–510, 512
  superior, 509–510
Tectorial membrane, 524
Teeth, 573
  anatomy, 575
  crown of, 575
  imaging, 574–575
  neck of, 575
  nerves, 576–577
  root of, 575
  vasculature, 576
Tegmen tympani, 485, 523
Temporal artery
  deep, 533
  middle, 533
  superficial, 500, 506–507, 510, 533, 546, 576
Temporal bone(s), 477, 480, 485, 527, 572
  mastoid process of, 43
Temporal fossae, 526, 528–529
  arteries, 533
  nerves, 532
  veins, 533
Temporal gyri, 494
Temporalis, 8, 504, 526, 528
Temporal line
  inferior, 526
  superior, 526
Temporal lobe, 495
Temporal nerves, deep, 531–532
Temporal sulcus, superior, 494
Temporal vein
  deep, 533
  superficial, 11, 506–507, 510, 533, 539, 557, 576
Temporomandibular joint, 528–530
Tendinous arch, of levator ani, 227–228, 231
Tendinous intersection, 140
Tensor fasciae latae, 8, 292, 300–302, 305–307, 316
Tensor tympani muscle, 522
Tensor tympani tendon, 521, 523
Tensor veli palatini, 528–529, 554, 581
Tentorium cerebelli, 492, 498
Teres major, 9, 37–39, 52, 398–399, 412–413
Teres minor, 9, 38–39, 398–399, 412
Testes, 20, 147, 239
  appendix of, 238
  lobules of, 238
Testicular artery, 10, 148, 162, 238–239
  right, 147, 192
Testicular plexus, 199
Testicular vein(s), 11, 148, 162, 193
Thalamus, 495, 499
Thenar eminence, 384, 443, 446
Thenar muscles, 8, 434, 440
Thigh
  arteries, 311–312, 314
  bones of, 293
  compartments of, 306–307
  deep artery of, 299, 312, 316
  deep vein of, 11, 316
  lateral cutaneous nerve of, 196–197
  muscle attachments, 305, 308–309, 313
  musculature, 306–309, 313
  nerves, 311, 314
  transverse section, 316–317
Thoracic aorta, 10, 74, 82, 88–89, 101, 107
Thoracic aperture
  inferior, 63
  superior, 63
Thoracic artery
  internal, 10, 69, 74, 92, 143, 546, 548–549
    mammary branches of, 69
  lateral, 69–70, 401–402, 410
  superior, 401–402, 410
Thoracic cavity, 79
  left, 116–117
  right, 114–115
Thoracic curvature, 21
Thoracic duct, 12, 77, 124, 185, 551
Thoracic ganglia, 200
Thoracic meninges, 48–49
Thoracic nerves, 44, 395, 403, 545
Thoracic vein(s)
  internal, 75, 109
  lateral, 142
Thoracic vertebrae, 21–22, 26–27, 74
Thoracic visceral plexus, 14
Thoracic wall, 72
  anterior, 71
  arteries of, 74
  lateral, 71
  lymphatics of, 77
  posterior, 71
  veins, 75
Thoraco-acromial artery, 70, 401, 410
  acromial branch, 395, 402
  clavicular branch, 395, 402
  deltoid branch, 395, 402
  pectoral branch of, 69, 402
Thoracodorsal artery, 401–402
Thoracodorsal nerve, 405
Thoracoepigastric vein, 142
Thoracolumbar fascia, 37, 39, 42
Thorax
  bony framework of, 63–64
  dermatomes and cutaneous nerves of, 125
  surface anatomy, 62
  transverse section, 124
Thymus gland, 12, 108
Thyro-arytenoid, 561
Thyrocervical trunk, 546, 548–549, 564
Thyro-epiglottic, 561

tahir99-VRG & vip.persianss.ir

Thyro-epiglottic ligament, 559
Thyrohyoid, 540–541
Thyrohyoid ligament, 558, 561
Thyrohyoid membrane, 554, 558, 560–561, 563
Thyroid artery
  inferior, 546, 548–549, 564–565
  superior, 500, 546, 564–565
Thyroid cartilage, 552, 554, 558–559, 561, 563
  inferior horn of, 86
  left lamina of, 86
  superior horn of, 86
Thyroid gland, 551–552, 563
  isthmus of, 563
  left lobe, 563, 565
  right lobe, 563
  vasculature, 564
Thyroid notch, 536, 558, 563
  superior, 86
Thyroid prominence, 536, 558, 563
Thyroid tubercle, 558
Thyroid vein(s)
  inferior, 109, 564
  middle, 564
  superior, 564
Tibia, 4, 6–7, 292, 329
  proximal end, 304
Tibial artery
  anterior, 10, 311–312, 314–315, 327, 342, 346, 354–355
  posterior, 10, 311–312, 327, 342, 355, 362
Tibial collateral ligament, 308, 320
Tibialis anterior, 8, 300, 343–345
Tibialis anterior tendon, 351
Tibialis posterior, 341
Tibialis posterior tendon, 351–352
Tibial nerve, 13, 314–315, 342, 361–362
Tibial recurrent artery, anterior, 312
Tibial tuberosity, 4, 6, 292, 304
Tibial vein
  anterior, 11
  posterior, 11
Tibiofibular joint, 318
Tibiofibular ligament, 336–337
T10 nerve, 144
T12 nerve, 76, 144
  lateral cutaneous branch of, 144
Tongue, 532, 552, 579
  apex of, 580
  arteries, 579
  frenulum of, 582
  inferior surface, 582
  root of, 553, 555
  veins, 579
Tonsils, 12, 552–553, 568, 580–582
Torus levatorius, 552
Torus tubularis, 552–553, 568
Trabecula, 12
Trabeculae carneae, 97, 99
Trachea, 79, 88, 110, 552–553
  in axial plane, 3
  bifurcation of, 113
  positioning of, 63
  in superior mediastinum, 112
Tracheal bifurcation, 86
Tracheal cartilages, 86
Tracheal mucosa, 86
Tracheal nodes, 12, 77
Tracheobronchial nodes, 114
Tragus, 520
Transversalis fascia, 42, 136–137, 140–142, 148
Transverse colon, 153, 157, 163
  in coronal plane, 3
  in coronal section of abdomen, 156
Transverse fasciculi, 356
Transverse plane, 2
Transverse ridges, of sacrum, 294
Transverse sinus, 493
Transversospinales muscles, 41–42
Transversus abdominis, 8, 40, 42, 136–137, 141–142, 148, 183
  aponeurosis of, 137, 139
Transversus thoracis muscles, 72
Trapezium, 426, 428, 440
Trapezius, 5, 8–9, 36–37, 394–395, 408, 412, 504
Trapezoid, 426, 428, 440
Trapezoid line, 388
Triangle, lumbar, 37
Triangle of auscultation, 36–37
Triangular interval, 399, 414
Triangular ligament, right, 172–173
Triceps brachii, 9, 394, 398–399, 408, 412–413, 431–432, 435
Tricuspid valve, 96–97, 100–101
  auscultation point for, 106
Trigeminal ganglion, 498–499, 535
Trigeminal impression, 485
Trigeminal nerve, 13, 498–499, 511, 517, 532, 535, 584
  cutaneous distribution, 503
  mandibular division, 531
Trigone, 230, 232–233, 235, 240
Triquetrum, 426, 428, 440
Triticeal cartilage, 558
Trochanter
  greater, 6–7, 226, 292–293, 295–296, 298–299, 301, 308
  lesser, 6–7, 226, 293, 295–296, 298–299, 301
Trochanteric fossa, 296
Trochlea, 6, 406, 512
Trochlear nerve, 498–499, 513, 584
Trochlear notch, 406
True ribs, 64
Tuberculum sellae, 485, 534
Tunica albuginea, 239–240, 242
Tunica vaginalis, 234, 238–239
  parietal layer of, 149
  visceral layer of, 149
TI vertebra, 21, 26, 63, 537
  spinous process of, 5
TII vertebra, 64
TIII vertebra, 26–27
TV vertebra, 22
TIX vertebra, 26
TXII vertebra, 21, 26–27, 63–64
  spinous process of, 5, 20, 63
Tympanic membrane, 521, 524
Tympanic nerve, 522
Tympanic plate, 527
Tympanic plexus, 522, 532
Tympanomastoid fissure, 527

U
Ulna, 6–7, 385, 425
  proximal end, 406
  tuberosity of, 420
Ulnar artery, 10, 410, 424, 434, 437
Ulnar collateral artery, 401–402, 410, 414, 437
Ulnar collateral ligament, 429
Ulnar collateral vein, 411
Ulnar nerve, 13, 395, 403–405, 410, 424, 434, 437, 451
Ulnar notch, 425
Ulnar recurrent artery, 410, 414, 434, 437
Ulnar vein, 11
Ulnocarpal ligament, 429
Umbilical artery, 246, 248, 251
Umbilical fold
  lateral, 149
    left, 151
  left bilateral, 141
  medial, right, 151
  median, 151
Umbilical ligament
  medial, 149
  median, 141, 149
    right, 141
Umbilical region, 135
Umbilicus, 4, 134
Umbo, 521
Uncinate process, 24, 176, 567
Uncovertebral joint, 24
Uncus, 494–495
Urachus, 222, 224, 230, 232
Ureter(s), 224
  left, 147, 160, 162, 184, 232–233, 237
    retroperitoneal, 186
  right, 160, 232–233, 237
    retroperitoneal, 186
  surface projection of, 186
  visceral sensory diagram, 204–205
Ureteric orifice, 230, 232–233, 235
Urethra, 236
  female, 224, 233
  membranous, 222, 235
  penile, 236
  prostatic, 222, 232, 235
  in sagittal plane, 3
  spongy, 222, 234, 240
Urethral orifice, external, 20
  female, 256
  male, 240, 257
Urethral sphincter
  external, 20, 224, 230, 232–233, 235–236, 259
  internal, 230
Urogenital hiatus, 227–229, 258
Urogenital triangle, 255
Uterine artery, 248–249
Uterine tube, 147, 224, 241–242
  ampulla of, 242
  folds of, 242
  infundibulum of, 242
  isthmus of, 242
Uterine vein, 248–249
Uterosacral ligament, 224, 243, 245
Uterus, 147, 242–243
  body of, 224, 241
  external os, 224, 241
  fundus of, 242–243
  imaging, 244
  innervation, 273
  internal os, 242
  round ligament of, 146–147, 224, 241–243
  in sagittal plane, 3
  surface projections, 242
  vasculature of, 249
Utricle
  auricular, 524
  prostatic, 235
Utriculosaccular duct, 524
Uvula, 552–553, 555, 581

V
Vagal ganglion, inferior, 127, 562
Vagal trunk, 118
  anterior, 199–201
  posterior, 199–201

tahir99-VRG & vip.persianss.ir

Vagina, 224
  fornix, posterior, 224
  posterior fornix, 241
  in sagittal plane, 3
Vaginal artery, 246, 248–249
Vaginal orifice, 224, 233, 256
Vaginal wall, 242
Vagus nerve, 585
  cardiac branches of, 110
  carotid body branch, 543
  in cranium, 498–499
  dorsal motor nucleus, 126
  inferior ganglion of, 556
  left, 88, 107, 110, 118, 201, 562
  parasympathetic cardiac branches, 126
  pharyngeal branch, 543
  in pharynx, 556
  right, 88, 107, 110, 118, 201, 562
  thoracic cardiac branch of, 107
Vallate papilla, 555, 580
Vallecula, 552, 580
Valve(s)
  aortic, 100–101
    auscultation point for, 106
  of foramen ovale, 98
  heart, 101
  of inferior vena cava, 96
  of lymph node, 12
  mitral, 98–99, 101
    auscultation point for, 106
  pulmonary, 97, 101
  tricuspid, 97
    auscultation point for, 106
Vasa recta, 165, 170
Vasculature. *See* Arteries; Vein(s)
Vastus intermedius, 305, 308, 316
Vastus lateralis, 8, 292, 300–301, 305–308, 316, 327, 340, 343–344
Vastus medialis, 8, 292, 305–306, 308, 316, 327, 344
Vein(s). *See also individual veins*
  arm, 411, 457
  eyes, 515
  facial, 506
  hands, 457
  infratemporal fossae, 533
  leg, 364
  nasal cavity, 569
  neck, 539
  parotid region, 507
  pelvic, 247
  pharynx, 556
  of prostate and penis, 250
Vein(s) (*Continued*)
  rectal, 251
  teeth, 576
  temporal fossae, 533
  thoracic wall, 75
  thyroid gland, 564
  tongue, 579
Vena cava
  inferior, 11, 75, 82, 94, 96–99, 101, 160, 186, 193
    abdominal, imaging, 194
    imaging, 194
    valve of, 96
  superior, 11, 63, 74, 82, 89, 94–99, 101, 564
Venous arch, dorsal, 292, 364
Venous plexus, rectal
  external, 231
  internal, 231
Venous sinuses, dural, 493
Ventricle
  left, 63, 93–95, 98–99, 101
  right, 74, 94, 96, 97, 103, 105
Vertebra(e). *See also individual vertebrae*
  cervical, 21–25
  lumbar, 21–22, 27–30
  regional, 22
  thoracic, 21–22, 26–27, 74
Vertebral artery, 10, 43, 46, 402, 499–500, 546, 548–549
  left, 500
  right, 500
Vertebral canal, 33
Vertebral column, 7
  anterior view, 21
  cervical, 50
  lateral view, 21
  posterior view, 21
  splanchnic nerves and, 200
  upper thoracic, 50
Vertebral foramen, 22
Vertebral plexus, anterior
  external, 47
  internal, 47
Vertebral spinous process, 20
Vertebra prominens, 5, 20, 23
Vertical axis, 2
Vesical artery
  inferior, 246, 248
  superior, 246, 248
Vesical fascia, 230, 232
Vesical plexus, 247, 250
Vesical vein
  inferior, 247–248, 251
  superior, 245, 247–248, 251
Vesico-uterine pouch, 224, 245
Vesicular appendix, 243
Vestibular, as anatomical direction, 573
Vestibular aqueduct, 524
Vestibular fold, 560
Vestibular gland, greater, 241, 262
  opening of duct, 257
Vestibular ligament, 559
Vestibular nerve, 520–521, 524
Vestibule, 524
Vestibulocochlear nerve, 498–499, 520–521, 524, 585
Visceral pleura, 79, 124
Vitreous chamber, 516
Vocal fold, 552, 560
Vocalis, 561
Vocal ligament, 559, 561
Vocal process of arytenoid, 559, 561
Vomer, 477, 484, 486, 566–567, 572
Vorticose veins, 515

W
White ramus communicans, 78, 126
Wrist crease, 443
Wrist joint, 7, 385, 425–427

X
Xiphisternal joint, 64, 67
Xiphoid process, 4, 6, 62–64, 134

Z
Zona orbicularis, 298–299
Zonular fibers, 516
Zygapophyseal joint, 24, 28–29, 218–219
  capsule of, 35
Zygomatic arch, 526–527
Zygomatic bone, 6, 477, 480, 483, 508, 527, 534
Zygomatic nerve, 535
Zygomaticofacial artery, 506
Zygomaticofacial bone, 480
Zygomaticofacial nerve, 503, 531, 535
Zygomaticofacial vein, 506
Zygomaticotemporal artery, 506
Zygomaticotemporal nerves, 503, 511, 531, 535
Zygomaticotemporal vein, 506
Zygomatic process of frontal bone, 478, 526
Zygomatic process of maxilla, 478
Zygomatic process of temporal bone, 480
Zygomaticus major, 504–505
Zygomaticus minor, 504–505

tahir99-VRG & vip.persianss.ir

This page intentionally left blank

tahir99-VRG & vip.persianss.ir

This page intentionally left blank

tahir99-VRG & vip.persianss.ir

This page intentionally left blank

tahir99-VRG & vip.persianss.ir

This page intentionally left blank

tahir99-VRG & vip.persianss.ir

This page intentionally left blank

tahir99-VRG & vip.persianss.ir

This page intentionally left blank

tahir99-VRG & vip.persianss.ir